

RHINOLOGY

# Clinical study of extrapulmonary head and neck tuberculosis in an urban setting

## *Studio clinico riguardo la tubercolosi extrapolmonare in ambiente urbano*

S. MONGA<sup>1</sup>, J.N. MALIK<sup>1</sup>, S. JAN<sup>1</sup>, S. BAHADUR<sup>1</sup>, S. JETLEY<sup>2</sup>, H. KAUR<sup>3</sup>

<sup>1</sup> Department of Otorhinolaryngology and Head & Neck Surgery, Hamdard Institute of Medical Sciences & Research and HAHC Hospital, Jamia Hamdard University, Delhi, India; <sup>2</sup> Department of Pathology, Hamdard Institute of Medical Sciences & Research and HAHC Hospital, Jamia Hamdard University, Delhi, India; <sup>3</sup> Department of Computer Science & Engineering, Jamia Hamdard University, Delhi, India

### SUMMARY

Tuberculosis (TB) of the head and neck region is quite common in endemic countries, but is still misdiagnosed due to its varied presentation and different sites of involvement. The aims of the present study were to present the diversities of presentation of head and neck tuberculosis with the diagnostic predicaments faced during evaluation and to assess treatment response to anti-tubercular treatment (ATT). We analysed 48 patients with head and neck tuberculosis who presented to the Department of Otorhinolaryngology in our tertiary care urban hospital over a period of two years from 2013 to 2015 and recorded their data, which included presenting complaints, local and systemic examination findings, investigation results and treatment outcomes. The results showed that majority (64.5%) of cases were female and none of the patients were HIV positive. The most common manifestation was cervical lymphadenopathy (81.25%) with level II being the most commonly affected (31.3%). Three of the 48 patients had coexisting pulmonary TB. Fine needle aspiration cytology (FNAC), histopathological diagnosis and acid fast bacilli (AFB) staining were used to confirm diagnosis. All patients were treated with Category I ATT, which achieved cure in 96.8% of cases. Though cervical lymphadenitis is the most common presentation of head and neck TB, isolated involvement of the sinonasal region, larynx, oral cavity and other sub-sites are not solely unknown entities. It is, therefore, important for clinicians to be aware of atypical and misleading presentations and consider TB as a major differential diagnosis in the head and neck region, even in non-immunocompromised individuals.

KEY WORDS: Extrapulmonary tuberculosis • Cervical lymphadenopathy • Head and neck • Anti-tubercular therapy

### RIASSUNTO

*La tubercolosi del distretto testa collo è abbastanza comune nei paesi endemici, ma è ancora sottostimata a causa della presentazione clinica assai variabile e a causa dei differenti siti coinvolti. Pertanto, gli obiettivi di questo studio sono stati quelli di voler descrivere la variabilità di presentazione clinica dei pazienti affetti da tubercolosi del distretto testa-collo, durante la cui valutazione ci si scontra con notevoli difficoltà diagnostiche, e stimare la risposta di questi pazienti al trattamento anti-tuberculare (ATT). Sono stati reclutati 48 pazienti affetti da tubercolosi del distretto testa-collo, i quali si sono presentati tra il 2013 e il 2015 presso il dipartimento di Otorinolaringoiatria del nostro centro di III livello; per ciascuno di essi sono stati raccolti sintomi, reperti obiettivi locali e sistemici, risultati diagnostici e risultati del trattamento. Dai dati è emerso che la maggioranza dei casi (64,5%) erano femmine, e nessuno dei pazienti era HIV positivo. Le modalità di presentazione più comuni sono state le linfadenopatie cervicali (81,25%), e in particolare quelle coinvolgenti il livello IIB (31,3%). 3 pazienti su 48 erano affetti contemporaneamente da tubercolosi polmonare. Per confermare la diagnosi sono stati utilizzati l'esame citologico su agoaspirato con ago sottile, l'esame istopatologico e la colorazione per evidenziare l'alcol-acido resistenza. Tutti i pazienti sono stati trattati con antituberculari di prima scelta, i quali hanno permesso di raggiungere la guarigione nel 96,8%. Nonostante la linfadenite cervicale è la più comune forma di presentazione della tubercolosi del distretto testa-collo, i coinvolgimenti isolati della regione naso-sinusale, della laringe, della cavità orale o di altre sotto-sedi non sono entità sconosciute. Ciononostante, è importante prestare attenzione a queste presentazioni atipiche e misconosciute e considerarle nella diagnosi differenziale del testa-collo, anche in individui non immunocompromessi.*

PAROLE CHIAVE: Tubercolosi extrapolmonare • Linfadenopatie cervicali • Testa-collo • Terapia anti-tuberculare

Acta Otorhinolaryngol Ital 2017;37:493-499

### Introduction

Tuberculosis (TB) remains a major problem for mankind worldwide, especially in Asia and Africa. There are around 9 million new cases and 2 million deaths from TB worldwide. India has 23% of world's share. As per the

WHO TB report, the incidence in India was 167/100,000 population with a mortality of 17/100,000 population for the year 2014. Among the total 1.68 million cases of TB notified in the year 2014, 275,000 cases were of extrapulmonary tuberculosis (EPTB)<sup>1</sup>.

Despite introduction and improvements in anti-tubercular chemotherapy, TB (pulmonary and extrapulmonary) is still a leading cause of morbidity and mortality in India. Among the factors associated with the rising incidence of TB in India are increased prevalence of immunodeficiency through HIV, drug addiction, increasingly more clusters of poverty and overcrowding.

While pulmonary TB is the most common presentation, EPTB is also a significant disease entity. In the head and neck region, TB affects the lymph nodes, larynx, middle ear, sinonasal region, oral cavity and pharynx.

The incidence of TB in the head and neck region is quite frequent and provide an interesting area of study because of diverse presentations and due to changing clinical scenarios that have occurred over the past years<sup>2</sup>. These days, gradually evolving patterns of TB that do not manifest characteristic clinical symptoms are frequent, while acute fulminant rapidly progressive patterns are sporadically observed<sup>3</sup>.

The aims and objectives of this study were to analyze the clinical profile of head and neck TB patients with radiological, haematological and microbiological investigations and to assess response of these patients to ATT.

## Materials and methods

This was a prospective study done in the Department of Otorhinolaryngology and Head Neck Surgery at the Hamdard Institute of Medical Sciences & Research and HAHC Hospital over a period of two years, from 2013 to 2015. All new patients with EPTB of the head and neck region were included in the study. Cases of previous failure, relapse and defaulters were excluded from the study as they are to be managed differently in accordance with the existing Revised National Tuberculosis Control Programme (RNTCP) and WHO guidelines.

Data was obtained from each patient included in the study regarding age, gender, socioeconomic status, tobacco or alcohol addiction, co-morbidities, contact history of TB and presenting and constitutional symptoms. After complete ENT and systemic examination, relevant investigations including haemogram with ESR (Erythrocyte Sedimentation Rate), blood sugar (random), liver and kidney

function tests, Mantoux test, HIV and HBsAg were done. Presence/absence of pulmonary TB was diagnosed based on radiological and microbiological (sputum smear) examinations. Fine needle lymph node cytology and/or histopathological examination (HPE) of biopsy of the involved tissue was done.

Treatment was done as per the RNTCP (Revised National Tuberculosis Control Programme) and WHO guidelines. Patients were started on six months of TB drug treatment consisting of a two month "intensive" treatment phase followed by a four month "continuation" phase. For the two month "intensive" TB drug treatment phase, patients received: isoniazid (5 mg/kg body wt), rifampicin (10 mg/kg body wt), pyrazinamide (25 mg/kg body wt) and ethambutol (15 mg/kg body wt) followed by isoniazid with rifampicin at the same dosage for the "continuation" phase. These patients were then followed up during the treatment period and outcomes analysed over a six month period<sup>4</sup>.

## Results

A total of 48 patients were diagnosed with Head and Neck EPTB in our institute during the period of study. Out of these, 17 were males and 31 females with a male to female ratio of 1:1.8, with most patients being in the adult age group, Figure 1. All patients were HIV-I & II and HBsAg negative. Routine baseline investigations like haemogram, random blood sugar, LFT and KFT were normal in all. None of the patients had any major medical co-morbidities. Out of the total, only 3 were smokers (6.2%).

The most common site of EPTB in the head and neck was cervical lymph nodes (39 patients) followed by sinonasal TB (three patients) - Figure 2. In addition, one had laryngeal TB, two lip TB, one cheek TB, one cutaneous TB of the head and neck region and one was diagnosed as a case of parapharyngeal tubercular abscess. Detailed data of all patients is presented in Table I.

Patients with tubercular cervical lymphadenopathy accounted for 81.25% (39/48) of all cases. The chief complaint with cervical lymph node TB was neck swelling (unilateral 37 and bilateral two cases) - Figure 3. The most

**Table I.** Selected data of patients with head and neck TB.

Site/ diagnosis	Number	Mantoux (induration $\geq$ 10 mm diameter)	ESR	Concomittant pulmonary TB	H/o contact with TB	Response
Cervical lymph node TB	39	37	27	3 (7.6%)	5	97.4% (38/39)
Sinonasal TB	3	2	2	0	0	100%
Lip TB	2	1	1	0	1	100%
Laryngeal TB	1	1	1	0	0	100%
Parapharyngeal TB	1	1	1	0	0	100%
Cutaneous TB	1	1	1	0	0	100%
Cheek TB	1	1	1	0	0	100%
TOTAL	48	44 (91.6%)	34 (70.8%)	3 (6.2%)	6 (12.5%)	97.9%

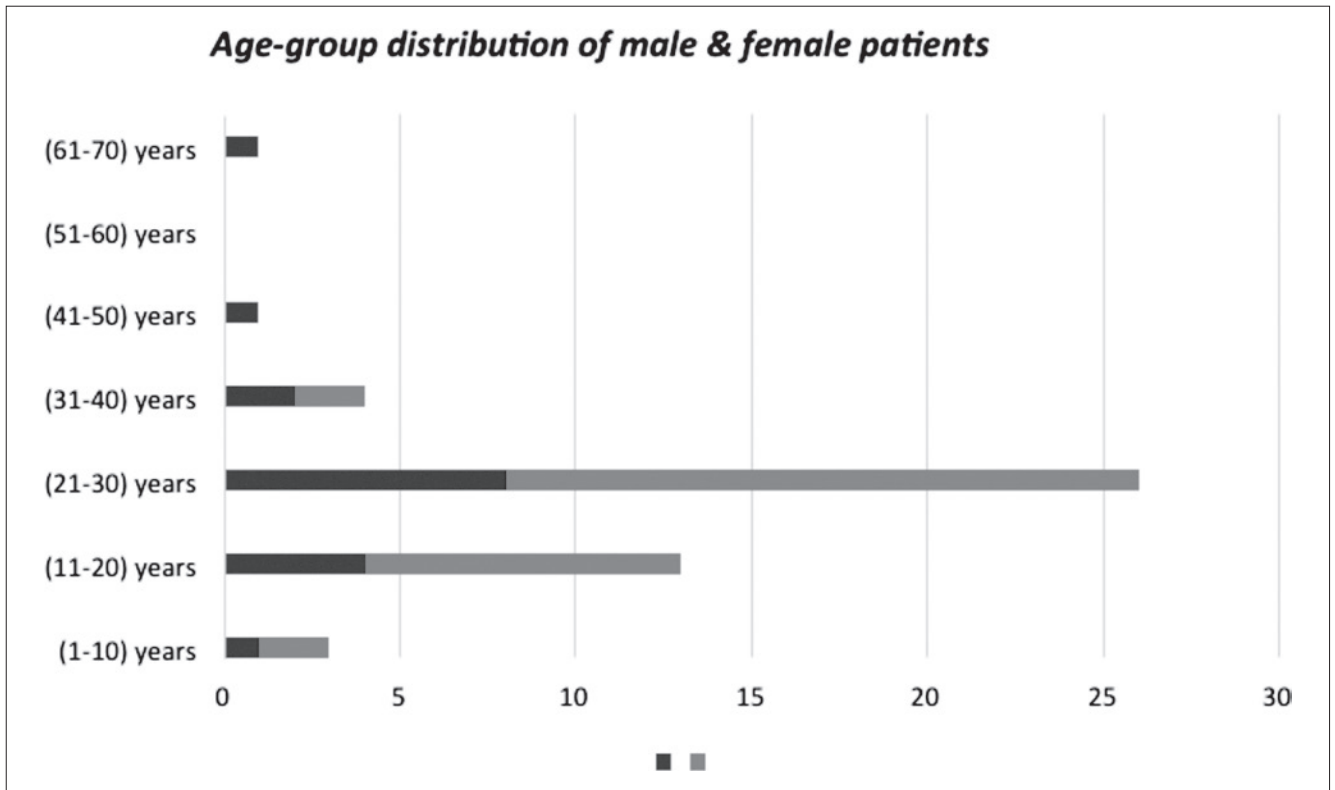


Fig. 1. Age and gender distribution of the patients.

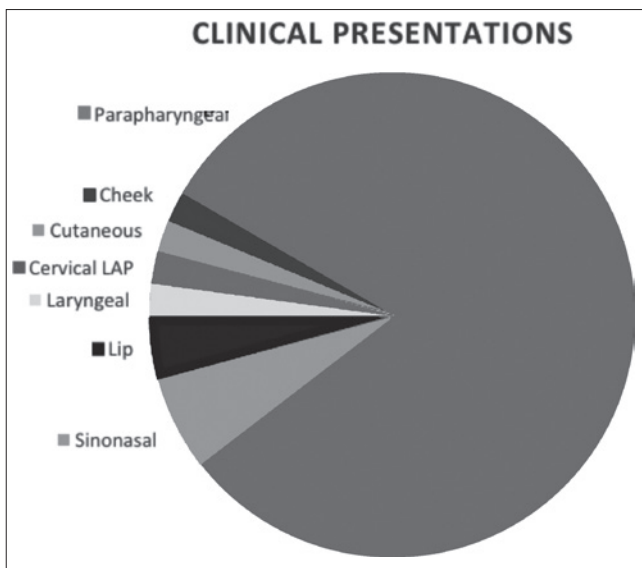


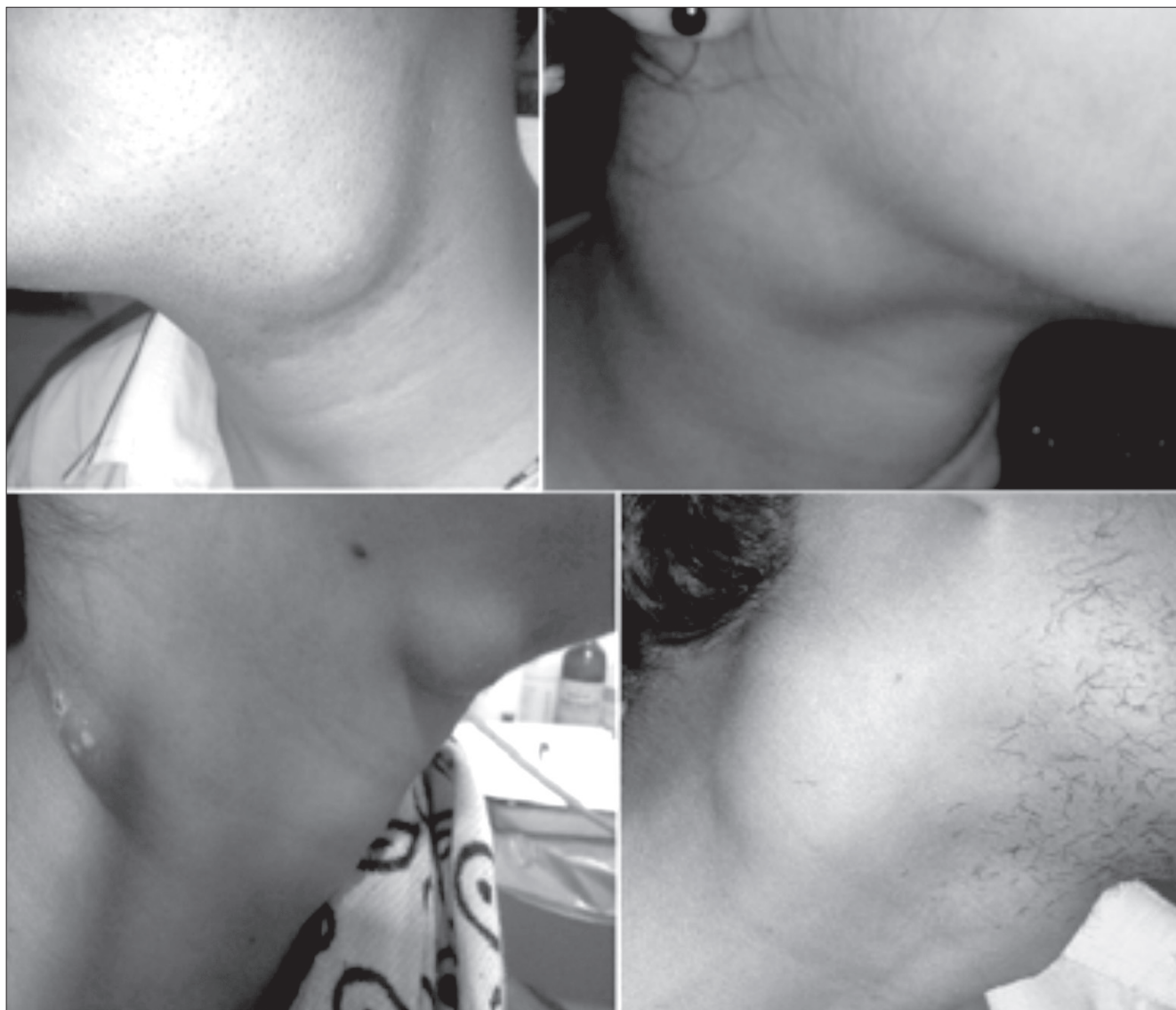Fig. 2. Site of various EPTB head and neck cases.

commonly affected lymph node was level II (31.3%), followed by level V (25.4%). Further information is shown in Table II.

The commonest age group affected was 21-30 years. There were 11 males and 28 females. These patients also had other complaints including fever 22 (56.4%), weight loss 8 (20.5%) and cough with expectoration 3(7.6%). All patients were sent for FNAC. All except

two exhibited granulomatous lymphadenitis of tubercular origin on cytopathology and only 8 were ZN staining positive for AFB. Those two cases had to undergo lymph node excision biopsy for confirmation. Further ancillary investigations for TB were carried out. In majority of cases (n = 37), Mantoux was positive (induration ≥ 10 mm diameter). ESR was raised in 27 patients. Three (7.6%) of these 39 patients had concomitant pulmonary TB. All patients were started on Category I ATT as per RNTCP guidelines. Patients were followed every two weeks for the first two months and monthly thereafter until the completion of treatment or as per need. All responded well to the prescribed ATT with the resolution of symptoms except one patient who had to be given treatment for MDR-TB to which he responded. Routine investigations of all patients remained within normal limits except one patient who suffered from derangement of LFT with the onset of ATT for which further evaluation and dose adjustments were required.

Three patients (6.2%) with nasal TB presented with symptoms of blood-tinged nasal discharge and obstruction. Out of these, two were males and one female. They were diagnosed by nasal endoscopy and biopsy of the inflammatory nasal tissue (Fig. 4), which showed granulomatous lesions of tubercular origin on HPE. None had pulmonary TB. All three responded well to Category I ATT with resolution of disease.



**Fig. 3.** Different presentations of cervical tuberculosis.

Two patients (4.1%), one male and other female, presented with complaints of lower lip swelling which were positive for TB on cytopathology.

One patient, a young male, presented with a short history of pain and swelling in front of the neck. CECT scan of neck demonstrated involvement of the larynx with erosion of the thyroid cartilage. He was diagnosed on open biopsy by HPE to be laryngeal TB.

One case, a young male, presented with pain throat and dysphagia with fever of 2 weeks' duration. On examination he had a posterior pharyngeal wall bulge which on needle aspiration came out to be pus that was positive for AFB bacilli. CT imaging revealed retropharyngeal abscess with right parapharyngeal extension without associated caries cervical spine (Fig. 5).

One teenage female presented with multiple refractory ulcerations of the facial skin (Fig. 6) which on HPE of biopsies

revealed chronic granulomatous lesion consistent with TB.

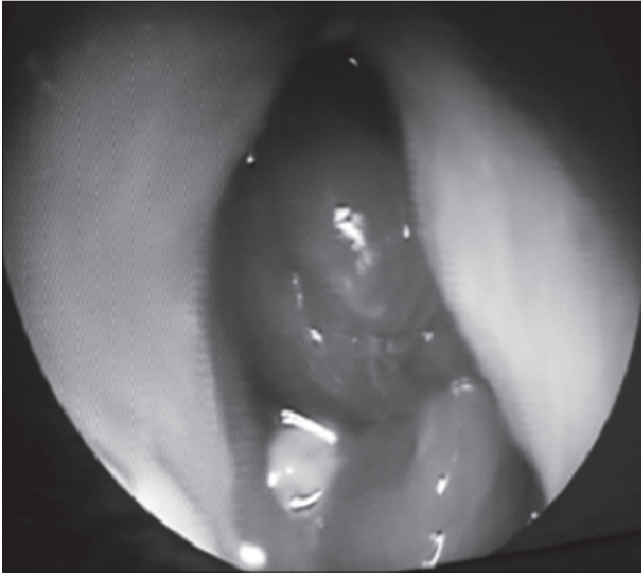
One patient, a teenage male presented with right cheek swelling which on FNAC showed findings suggestive of buccal space tubercular abscess.

All these patients were Mantoux positive and had raised ESR. None had pulmonary TB. All were started

**Table II.** Distribution by level of cervical lymph node involvement.

Levels of lymph nodes involved		No. of cases	Percentage
Level I	IA	2	3.9%
	IB	6	11.7%
Level II		16	31.3%
Level III		11	21.5%
Level IV		3	5.8%
Level V		13	25.4%
Level VI		0	0





**Fig. 4.** Endoscopic picture showing polypoidal mucosa and caseous material in sinonasal tuberculosis.

on Category I ATT and were followed for six months. All responded to treatment with resolution of disease. None had any derangements of routine baseline investigations.

## Discussion

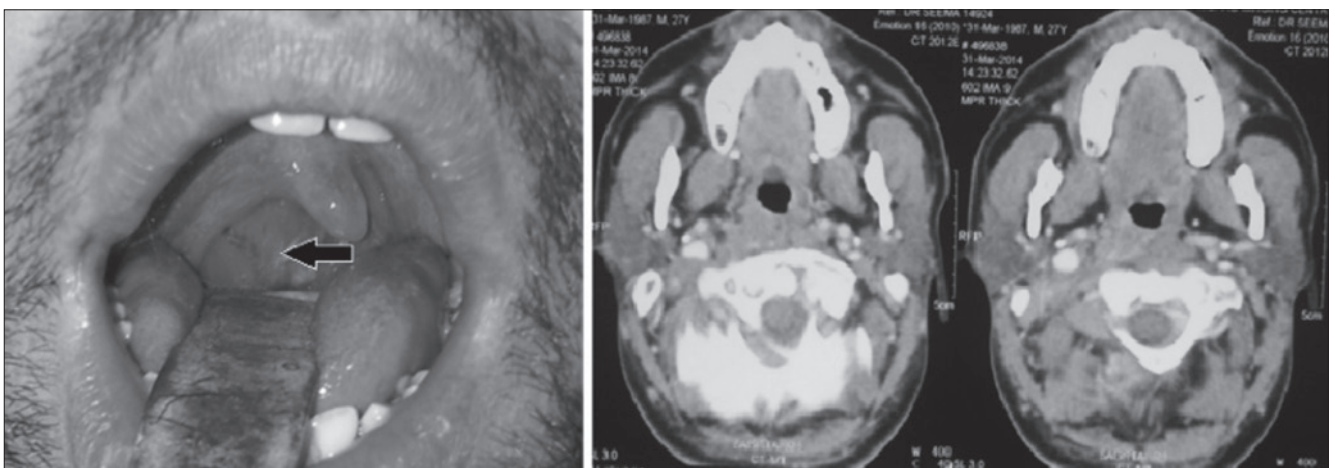
The female predominance in our study group (64.5% females) is somewhat different from data reported in other Indian studies, which have shown a clear-cut male dominance<sup>5,6</sup>.

The mean age of subjects was 23.4 years and most patients were in the age group of 21-30 years. This was similar to the finding observed in the studies Arora et al.<sup>(7)</sup> and Soumyajit Das et al.<sup>8</sup> in which the most common age group affected was 15-24 years.

Association of socioeconomic status and TB is not well studied, but a study from China by Liu et al.<sup>9</sup> indicated

that it is more prevalent in the lower socioeconomic strata. This could be attributed to various factors such as malnutrition, overcrowding, etc. In our study, the economic profile was taken into account as per revised Modified B G Prasad socioeconomic scale<sup>10</sup>, and it was observed that most patients were in scale III i.e. middle class (54.1%) - Table III. This is probably due to factors like increasing health awareness in this class and also to the demographics of the hospital catchment area.

In the present study, the most common site of EPTB in the head and neck region was in the cervical lymph nodes (81.25%) followed by sinonasal TB (6.2%), oral cavity (4.1%), laryngeal TB, retropharyngeal region, buccal space and cutaneous TB of the head and neck region (one case each representing 2.05%). In a study by Akkara et al.<sup>5</sup>, the most common site in their 211 patients was the cervical lymph node (201 patients, 95.3%), followed by the middle ear (2.8%), larynx (1.4%) and nasal cavity (0.5%). In the study by Ricciardiello et al.<sup>3</sup>, the most common site was the cervical lymph nodes (94.12%), followed by the larynx (4.33%), palatine tonsil (0.62%), oral cavity (0.31%), middle ear (0.31%) and nasal cavity (0.31%). In another study by Choudhary<sup>11</sup> in a South London hospital on 33 patients with head and neck TB, they found that 58% (n = 19) had cervical LAP, 9 (27%) salivary gland TB, 2 (6%) laryngeal T, and one (3%) each of nasopharyngeal, hypopharyngeal and ear TB. Thus, while most Indian and International studies reported that the cervical lymph node was the most commonly affected, it is noteworthy that the present study also shows a relatively high proportion of sinonasal TB in the study group. In the present study, the pattern of lymphadenopathy showed multiple lymph node group involvement in 14 (35.8%) cases, and the commonest involved group was level II (31.3%), either alone or in association with other levels. This corresponds to the findings of other studies (Soumyajit Das et al.<sup>8</sup>, BC Jha et al.<sup>12</sup>). On the other hand, Akkara et al.<sup>5</sup> and Dharma Baskota et al.<sup>13</sup> noted that the



**Fig. 5.** Clinical presentation and radiological findings of parapharyngeal tuberculosis.

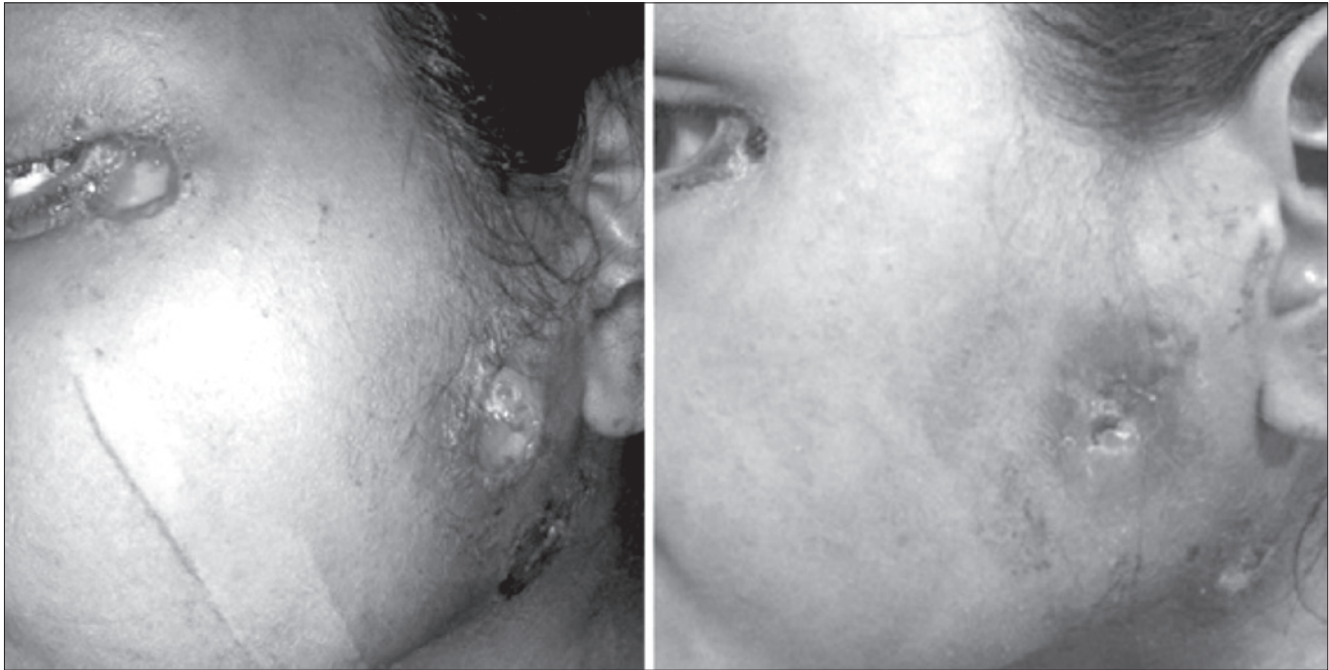


Fig. 6. Cutaneous tuberculosis before and after 2 months of ATT.

posterior triangle was the most commonly affected lymph node. In our study, level V was next, in 25.4% of cases, followed by level III (21.5%), level IB (11.7%), level IV (5.8%) and level IA (3.9%). Level VI and VII involvement was not observed. In the majority of these cases (94.8%), diagnosis was established based on FNAC. The most consistent feature was that of epithelioid granuloma with Langhan's giant cell, acute neutrophilic infiltration with or without evidence of necrosis. AFB by ZN staining could be demonstrated in 8 of 39 patients who underwent FNAC. However, in 2 (5.1%) cases surgical excision biopsy was needed to confirm the diagnosis. Malakar et al.<sup>14</sup> also found that FNAC was sensitive to detect tubercular lymphadenopathy in 79.1% of cases. However, in their study, in 41.6% of patients with tubercular lymphadenopathy, the aspirates were positive for AFB. It has been suggested by Chakravarty et al.<sup>6</sup> that the paucibacillary nature of the tissue other than sputum compromises the diagnosis rate in TB. Three of these cases in our study also had concomitant pulmonary TB (7.7%).

Table III. Patient distribution as per Revised modified BG Prasad socioeconomic classification scale (2014).

Socioeconomic class (with per capita monthly income in Rupees)	Number of patients (%)
Upper class (5357 & above)	2 (4.1%)
Upper middle class (2652-5356)	8 (16.6%)
Middle class (1570-2651)	26 (54.1%)
Lower middle class (812-1569)	10 (20.8%)
Lower class (< 811)	2 (4.1%)

Although culture of mycobacteria in special media is the gold standard for diagnosis of tuberculosis, cultivation has limited yield and is a slow technique that often takes weeks, so that the results are generally received when the patient is already on treatment. Alternatively, the tissue may be subjected to molecular diagnostic methods like polymerase chain reaction or even DNA specific probes for rapid diagnosis and subtyping of mycobacteria, especially in paucibacillary samples. The GeneXpert platform based *Xpert MTB/RIF* is commonly used, which has also been advocated by the WHO especially for diagnosis in HIV patients<sup>1</sup>. However, these techniques are not only expensive and technically demanding, but also not routinely available in many centres in India.

Although nasal TB is a very rare entity even in countries with high disease load, we observed three cases over the two year period. Primary TB of the nasal cavity or oral cavity are seen rarely in countries even with high disease load like India. However, we observed three cases of primary sinonasal and two cases of lip TB without pulmonary involvement over a period of two years. Most common symptom in sinonasal TB was blood tinged nasal discharge, and in the oral cavity the commonest presentation was lower lip cystic swelling. All these five cases were diagnosed by HPE of the biopsy taken from the involved site. Akkara et al.<sup>5</sup> found only one case of nasal TB and no oral TB in their study of 211 head and neck EPTB, while Soumyajit Das et al.<sup>8</sup> did not report any case.

Though hoarseness is the commonest presenting complaints in laryngeal TB due to spread from associated

pulmonary involvement, our patient was a young male who presented with chief complaints of painful swelling over the anterior aspect of neck, which on CT showed necrosis of the thyroid cartilage; HPE of the biopsy confirmed it as TB. He had no associated pulmonary involvement.

We did not observe any case of tubercular otitis media or thyroid gland TB in our two year study.

Contact history in a diagnosed case of TB was present in 5 (12.8%) of cases, while in the majority of cases (87.2%) it was absent. It is similar to the trend seen in the study by Soumyajit Das et al.<sup>8</sup>, which reported 34.9% of cases with positive contact history; history of contact was absent in 65% cases.

Constitutional symptoms were present in 29 (59%) of cases, while it was absent in 41% of cases similar to the study by Soumyajit Das et al.<sup>8</sup>, where they were present in 38.1% of cases.

Category I treatment (as per present RNTCP) was found to be effective in all except one case showing favourable response at the end of 6 months of treatment. This result is similar to the that observed in study by Soumyajit Das et al.<sup>8</sup>, which showed 96.8% of treatment success. In addition, there were no significant derangements in baseline investigations during treatment except in one case.

## Conclusions

TB of head and neck region can have atypical and varied manifestations in an endemic country such as India. Otolaryngologists should be aware of the diagnostic dilemmas presented in these patients in order to avoid misdiagnosis and unnecessary delay in treatment, especially in cases without pulmonary involvement. A team approach of surgeons, chest physicians, microbiologists and pathologists for management is highly recommended. Category I ATT as per RNTCP is quite effective for EPTB of the head and neck region.

## References

<sup>1</sup> Global tuberculosis report 2015 [Internet]. Geneva World

Health Organization 2015. Available at: [http://www.who.int/tb/publications/global\\_report/en/](http://www.who.int/tb/publications/global_report/en/). Accessed March 01, 2016.

- <sup>2</sup> Aisenberg GM, Jacobson K, Chemaly RF, et al. *Extrapulmonary tuberculosis active infection misdiagnosed as cancer: Mycobacterium tuberculosis disease in patients at a comprehensive cancer center (2001-2005)*. Cancer 2005;104: 2882-7.
- <sup>3</sup> Ricciardiello F, Martufi S, Cardone M, et al. *Otorhinolaryngology-related tuberculosis*. Acta Otorhinolaryngol Ital 2006;26:38-42.
- <sup>4</sup> *Treatment of Tuberculosis: Guidelines. 4<sup>th</sup> edition*. Geneva: World Health Organization; 2010. 3, Standard treatment regimens.
- <sup>5</sup> Akkara SA, Singhanian A, Akkara AG, et al. *A study of manifestations of extrapulmonary tuberculosis in the ENT region*. Indian J Otolaryngol Head Neck Surg 2014;66:46-50.
- <sup>6</sup> Chakravorty S, Sen MK, Tyagi JS. *Diagnosis of extrapulmonary tuberculosis by smear, culture, and PCR using universal sample processing technology*. J Clin Microbiol 2005;43:4357-62.
- <sup>7</sup> Arora VK, Gupta R. *Trends of extra-pulmonary tuberculosis under Revised National Tuberculosis Control Programme: A study from South Delhi*. Indian J Tuberc 2006;53:77-83.
- <sup>8</sup> Das S, Das D, Bhuyan UT, et al. *Head and neck tuberculosis: scenario in a tertiary care hospital of North Eastern India*. J Clin Diagn Res 2016;10:MC04-7.
- <sup>9</sup> JJ Liu, HY Yao, EY Liu. *Analysis of factors affecting the epidemiology of tuberculosis in China*. Int J Tuberc Lung Dis 2005;9:450-4.
- <sup>10</sup> Mangal A, Kumar V, Panesar S, et al. *Updated BG Prasad socioeconomic classification, 2014: a commentary*. Indian J Public Health 2015;59:42-4.
- <sup>11</sup> Choudhury N, Bruch G, Kothari P, et al. *4 years' experience of head and neck tuberculosis in a south London hospital*. J R Soc Med 2005;98:267-9.
- <sup>12</sup> Jha BC, Dass A, Nagarkar NM, et al. *Cervical tuberculous lymphadenopathy: changing clinical pattern and concepts in management*. Postgrad Med J 2001;77:185-7.
- <sup>13</sup> Baskota DK, Prasad R, Sinha BK, et al. *Distribution of lymph nodes in the neck in cases of tuberculous cervical lymphadenitis*. Acta Otolaryngol 2004;124:1095-8.
- <sup>14</sup> Malakar D, Jajoo I, Swarup K, et al. *A clinical evaluation of fine needle aspiration cytology in the diagnosis of lymphadenopathy*. Ind J Tub 1991;38:17-9.

Received: May 27, 2016 - Accepted: January 15, 2017

Address for correspondence: Junaid Nasim Malik, Department of Otorhinolaryngology and Head & Neck Surgery, Hamdard Institute of Medical Sciences & Research and HAH Hospital, Jamia Hamdard University, 10062 Delhi, India. Tel. +91 9811710433. E-mail: drjunaidnasim@yahoo.co.in