

# Otorhinolaryngologica Italica

Volume 37

2

April 2017

*Official Journal of the Italian Society of Otorhinolaryngology  
Head and Neck Surgery*

Organo Ufficiale della Società Italiana di Otorinolaringologia  
e Chirurgia Cervico-Facciale

## **INNOVATIONS AND NEW FRONTIERS IN THE MINIMALLY INVASIVE MANAGEMENT OF OBSTRUCTIVE SALIVARY GLAND DISORDERS**

*by Marco Benazzo, Lorenzo Pignataro, Pasquale Capaccio, Pietro Canzi*

Diagnostic work-up in obstructive and inflammatory salivary gland disorders

Salivary biomarkers and proteomics: future diagnostic and clinical utilities

Sialendoscopy for salivary stones: principles, technical skills  
and therapeutic experience

Salivary lithotripsy in the era of sialendoscopy

Sialendoscope-assisted transoral removal of hilo-parenchymal  
sub-mandibular stones: surgical results and subjective scores

Sialendoscopy-assisted transfacial removal of parotid calculi

Salivary duct stenosis: diagnosis and treatment

Complications of traditional and modern therapeutic salivary approaches

Sialendoscopic management of autoimmune sialadenitis: a review of literature

Interventional sialendoscopy for radioiodine-induced sialadenitis: quo vadis?

Modern management of paediatric obstructive salivary disorders:  
long-term clinical experience

Botulinum toxin therapy: functional silencing of salivary disorders

# ACTA

PACINI  
EDITORE  
MEDICINA

[www.actaitalica.it](http://www.actaitalica.it)



# ACTA

## Otorhinolaryngologica Italica

*Official Journal of the Italian Society of Otorhinolaryngology - Head and Neck Surgery*  
Organo Ufficiale della Società Italiana di Otorinolaringologia e Chirurgia Cervico-Facciale

Former Editors-in-Chief: C. Calearo†, E. de Campora, A. Staffieri, M. Piemonte, F. Chiesa

### Editorial Board

*Editor-in-Chief:*

G. Paludetti

*President of S.I.O.:*

C.A. Leone

*Former Presidents of S.I.O.  
and Editors-in-Chief:*

D. Felisati, L. Coppo, G. Zaoli, P. Miani,  
G. Motta, L. Marcucci, A. Ottaviani,  
P. Puxeddu, M. Maurizi, G. Sperati,  
D. Passali, E. de Campora, A. Sartoris,  
P. Laudadio, M. De Benedetto,  
S. Conticello, D. Casolino,  
A. Rinaldi Ceroni, M. Piemonte,  
A. Staffieri, F. Chiesa, R. Fiorella,  
A. Camaioni, A. Serra, G. Spriano,  
R. Filipo

### Editorial Staff

*Editor-in-Chief:*

G. Paludetti

*Deputy Editor:*

J. Galli

*Associate Editors:*

G. Almadori, F. Ottaviani

*Editorial Coordinator:*

E. De Corso

*Editorial Assistant:*

P. Moore

*Treasurer:*

L. de Campora

### Italian Scientific Board

L. Bellussi, G. Danesi, C. Grandi,

A. Martini, L. Pignataro, F. Raso,

R. Speciale, I. Tasca

### International Scientific Board

J. Betka, P. Clement, M. Halmagyi,

L.P. Kowalski, M. Pais Clemente,

J. Shah, H. Stammberger, R. Laszig,

G. O'Donoghue, R.J. Salvi, R. Leemans,

M. Remacle, F. Marshal, H.P. Zenner,

B. Scola Yurrita, R.W. Gilbert

### Editorial Office

*Editor-in-Chief:*

G. Paludetti

Department of Head and Neck Surgery -  
Otorhinolaryngology

Catholic University of the Sacred Heart

“A. Gemelli” Hospital

L.go F. Vito, 1 - 00168 Rome, Italy

Tel. +39 06 30154439

Fax + 39 06 3051194

actaitalicaorl@rm.unicatt.it

*Editorial Coordinator:*

E. De Corso

eugenio.decorso@policlinicogemelli.it

*Editorial Secretariat:*

G. Di Cintio

dicintiogiovanni@gmail.com

### Argomenti di Acta

**Otorhinolaryngologica Italica**

*Editor-in-Chief:* G. Paludetti

*Editorial Coordinator:* M.R. Marchese

raffaellamarchese@gmail.com

© Copyright 2017 by

Società Italiana di Otorinolaringologia

e Chirurgia Cervico-Facciale

Via Luigi Pigorini, 6/3

00162 Rome, Italy

### Publisher

Pacini Editore Srl

Via Gherardesca, 1

56121 Pisa, Italy

Tel. +39 050 313011

Fax +39 050 3130300

info@pacinieditore.it

www.pacinimedicina.it

*Acta Otorhinolaryngologica Italica is cited  
in Index Medicus, MEDLINE, PubMed  
Central, Science Citation Index Expanded,  
Scopus, DOAJ, Open-J Gate, Free Medical  
Journals, Index Copernicus, Socolar*

*Journal Citation Reports:*

*Impact Factor 1.531*

*Acta Otorhinolaryngologica Italica is  
available on Google Scholar*

PACINI  
EDITORE  
MEDICINA

www.actaitalica.it



# Contents

## Innovations and new frontiers in the minimally invasive management of obstructive salivary gland disorders

*Novità e nuove frontiere nel trattamento mini-invasivo dei disordini salivari ostruttivi*

by M. Benazzo, L. Pignataro, P. Capaccio, P. Canzi

|  |      |     |
|--|------|-----|
| Diagnostic work-up in obstructive and inflammatory salivary gland disorders<br><i>Work-up diagnostico nella patologia ostruttiva e infiammatoria delle ghiandole salivari</i><br>L. Ugga, M. Ravanelli, A.A. Pallottino, D. Farina, R. Maroldi . . . . .   | pag. | 83  |
| Salivary biomarkers and proteomics: future diagnostic and clinical utilities<br><i>Biomarkers e proteomica salivari: prospettive future cliniche e diagnostiche</i><br>M. Castagnola, E. Scarano, G.C. Passali, I. Messina, T. Cabras, F. Iavarone, G. Di Cintio, A. Fiorita, E. De Corso, G. Paludetti . . . . .                              | »    | 94  |
| Sialendoscopy for salivary stones: principles, technical skills and therapeutic experience<br><i>Il ruolo della scialoendoscopia nel trattamento delle litiasi salivari: principi di base, aspetti tecnici ed esperienza clinica</i><br>F. Carta, P. Farneti, S.Cantore, G. Macrì, N. Chuchueva, L. Cuffaro, E. Pasquini, R. Puxeddu . . . . . | »    | 102 |
| Salivary lithotripsy in the era of sialendoscopy<br><i>La litotrissia salivare nell'era della scialoendoscopia</i><br>P. Capaccio, S. Torretta, L. Pignataro, M. Koch . . . . .  | »    | 113 |
| Sialendoscope-assisted transoral removal of hilo-parenchymal sub-mandibular stones: surgical results and subjective scores<br><i>L'asportazione transorale scialoendoscopico-assistita dei calcoli ilo-parenchimali sottomandibolari: risultati chirurgici e soggettivi</i><br>P. Capaccio, M. Gaffuri, V. Rossi, L. Pignataro . . . . .       | »    | 122 |
| Sialendoscopy-assisted transfacial removal of parotid calculi<br><i>L'asportazione transfacciale scialoendoscopico-assistita dei calcoli parotidei</i><br>A.J. Hills, A.M. Holden, M. McGurk . . . . .   | »    | 128 |
| Salivary duct stenosis: diagnosis and treatment<br><i>Stenosi duttali salivari: diagnosi e terapia</i><br>M. Koch, H.Iro . . . . .   | »    | 132 |
| Complications of traditional and modern therapeutic salivary approaches<br><i>Complicanze degli approcci terapeutici tradizionali e moderni alle ghiandole salivari</i><br>O. Nahlieli . . . . .   | »    | 142 |
| Sialendoscopic management of autoimmune sialadenitis: a review of literature<br><i>Trattamento scialoendoscopico delle scialoadeniti autoimmuni: revisione della letteratura</i><br>A. Gallo, S. Martellucci, M. Fusconi, G. Pagliuca, A. Greco, A. De Virgilio, M. De Vincentiis . . . . .  | »    | 148 |
| Interventional sialendoscopy for radioiodine-induced sialadenitis: quo vadis?<br><i>La scialoendoscopia interventistica per le scialoadeniti radioiodio-indotte: quo vadis?</i><br>P. Canzi, S. Cacciola, P. Capaccio, F. Pagella, A. Occhini, L. Pignataro, M. Benazzo . . . . .  | »    | 155 |
| Modern management of paediatric obstructive salivary disorders: long-term clinical experience<br><i>La gestione moderna dei disordini ostruttivi salivari in età pediatrica: esperienza clinica a lungo termine</i><br>P. Capaccio, P. Canzi, M. Gaffuri, A. Occhini, M. Benazzo, F. Ottaviani, L. Pignataro . . . . .                         | »    | 160 |
| Botulinum toxin therapy: functional silencing of salivary disorders<br><i>Terapia con tossina botulinica: silenziamento funzionale dei disordini salivari</i><br>A. Lovato, D.A. Restivo, G. Ottaviano, G. Marioni, R. Marchese-Ragona . . . . .   | »    | 168 |

# Diagnostic work-up in obstructive and inflammatory salivary gland disorders

## *Work-up diagnostico nella patologia ostruttiva e infiammatoria delle ghiandole salivari*

L. UGGA<sup>1</sup>, M. RAVANELLI<sup>2</sup>, A.A. PALLOTTINO<sup>3</sup>, D. FARINA<sup>2</sup>, R. MAROLDI<sup>2</sup>

<sup>1</sup> Department of Advanced Biomedical Sciences, "Federico II" University, Naples, Italy; <sup>2</sup> Department of Radiology, University of Brescia, Brescia, Italy; <sup>3</sup> Department of Radiology, Campus Biomedico University, Rome, Italy

### SUMMARY

Inflammatory and obstructive disorders of the salivary glands are caused by very different pathological conditions affecting the gland tissue and/or the excretory system. The clinical setting is essential to address the appropriate diagnostic imaging work-up. According to history and physical examination, four main clinical scenarios can be recognised: (1) acute generalised swelling of major salivary glands; (2) acute swelling of a single major salivary gland; (3) chronic generalised swelling of major salivary glands, associated or not with "dry mouth"; (4) chronic or prolonged swelling of a single major salivary gland. The algorithm for imaging salivary glands depends on the scenario with which the patient presents to the clinician. Imaging is essential to confirm clinical diagnosis, define the extent of the disease and identify complications. Imaging techniques include ultrasound (US), computed tomography (CT) and magnetic resonance (MR) with MR sialography.

**KEY WORDS:** Salivary glands • Sialadenitis • Sialolithiasis • MRI • MR sialography

### RIASSUNTO

*La patologia infiammatoria ed ostruttiva delle ghiandole salivari riconosce molteplici eziologie con coinvolgimento del parenchima ghiandolare e/o del sistema escretore. Il quadro clinico è essenziale per indirizzare l'integrazione diagnostica con adeguate metodiche di imaging. Sulla base dell'anamnesi e dell'esame obiettivo, possono riconoscersi quattro scenari clinici: (1) tumefazione acuta generalizzata delle ghiandole salivari maggiori; (2) tumefazione acuta di un'unica ghiandola salivare maggiore; (3) tumefazione cronica generalizzata delle ghiandole salivari maggiori associata o meno a xerostomia; (4) tumefazione cronica o persistente di una singola ghiandola salivare maggiore. L'algoritmo diagnostico per la scelta della metodica di imaging più appropriata dipende quindi dallo scenario clinico. L'imaging è essenziale per confermare la diagnosi clinica, per definire l'estensione della patologia ed identificare eventuali complicanze. Le metodiche di imaging disponibili includono l'ecografia, la tomografia computerizzata e la risonanza magnetica, anche con scialografia RM.*

**PAROLE CHIAVE:** Ghiandole salivari • Scialoadenite • Scialolitiasi • MRI • Scialografia RM

Acta Otorhinolaryngol Ital 2017;37:83-93

## Introduction

Inflammatory and obstructive disorders are more frequently observed in the major salivary glands (parotid, submandibular and sublingual) than in the small and scattered minor salivary glands. These disorders can be caused by very different conditions. This range can be simplified into two settings: the first includes diseases that target the gland tissue, while in the second the abnormality is mainly in the excretory system. An example of the first group is the interstitial infiltration of the gland as observed in acute viral infections or lymphoepithelial disease, whereas abnormalities in the composition (acute dehydration, previous irradiation) or the impaired drainage of the saliva (strictures, sialiectasis, neoplastic compression of the main duct) are typical of the excretory system. Both the latter condi-

tions may lead to the formation of calculi and facilitate bacterial infections. In summary, inflammation may be present without any excretory system obstruction, or it can lead itself to changes in the composition or drainage of saliva, a condition turning into acute or chronic inflammation. It is the clinical scenario that determines the appropriate diagnostic imaging work-up, which includes studies such as ultrasound (US), CT, MR with MR sialography. US-guided fine-needle aspiration and cytology may be indicated to achieve correct diagnosis.

## Clinical scenarios

A complete history and focused physical examination are crucial in evaluation of patients with obstructive/inflammatory salivary gland disorders. Key points should

include the acute onset or long persistence of gland swelling, rate of change in the size of the gland (rapid or slow), associated fever or pain, drug exposures, history of malignancy and chronic illnesses such as rheumatologic diseases or sicca syndrome. Physical examination should include inspection of the face to observe swelling, induration, draining fistulae, scars from previous trauma, facial nerve paresis or paralysis, dryness or inflammation of the eye, and/or other masses. Careful inspection of the oral cavity should evaluate masses, swelling or lesions of the oral cavity, particularly in the Wharton's or Stensen's ducts area, and include massage (bimanually, when possible) of the gland to measure tenderness and determine if there is turbidity or purulence in the saliva, and assess the size and texture of the glandular tissue<sup>1</sup>. According to history and physical examination, four main clinical scenarios can be devised:

1. acute generalised swelling of parotid glands. Viral infection is the most probable cause. Less frequently the other major salivary glands are involved. Imaging is usually not indicated;
2. acute swelling of a single major salivary gland (parotid/submandibular). If associated with fever and pain (in some cases with a salivary colic), it raises the suspicion of sialolithiasis and/or acute suppurative sialadenitis. US is the first level imaging study indicated;
3. chronic generalised swelling of major salivary glands: several causes have to be considered. Bilateral painless and prolonged parotid swelling without signs of excretory abnormalities may indicate sialoadenosis (sialosis). It is a disorder usually associated with liver dysfunction, diabetes, or malnutrition<sup>2</sup>. If chronic diffuse swelling associated with "dry mouth" is observed, conditions leading to progressive parenchymal gland infiltration should be considered: Sjögren's syndrome, HIV sialadenitis and radiation-induced sialadenitis. In addition, systemic symptoms may be present in Sjögren's syndrome, sarcoidosis, IgG4-related disease and mycobacterial disease. The presence of adenopathies suggests chronic sialadenitis, including HIV-related and mycobacterial sialadenitis. US is indicated to assess changes both in the parenchymal echoic pattern and in the intra-extra-glandular excretory system;
4. chronic (prolonged) swelling of a single major salivary gland may be caused by (recurrent) sialolithiasis and sialadenitis. If unrelated to a previous confirmed diagnosis of sialolithiasis, a neoplastic cause has to be ruled out. A persistent soft and tender lump close to the gland may suggest a mucocele (ranula) or cystic lesion (branchial cyst, lymphatic malformation). Also in these conditions, US is indicated, and if necessary it can be combined with fine needle aspiration.

The algorithm for imaging the salivary glands depends

on the scenario with which the patient presents to the clinician<sup>3</sup>. In most conditions, US is the first test. Cross-sectional imaging is indicated to obtain a panoramic view and a better characterisation. In the setting of a patient with acute sialadenitis and suspicion of extra-glandular complications such as a neck abscess, contrast-enhanced CT is the modality chosen due to its high spatial resolution, the possibility to detect calcified stones and fast acquisition time. In chronic disorders, MR is the best imaging modality to study major and minor salivary glands due to its higher contrast resolution, multiparametric evaluation and submillimetric spatial resolution. Moreover, MR sialography has almost fully replaced conventional sialography in clinical practice.

## Imaging modalities

### *Conventional sialography*

In conventional sialography, the injection of a positive contrast medium into the opening of Stensen/Wharton's ducts reveals the anatomy of the main duct and intra-glandular branches. Nowadays, sialography is infrequently employed because of the progressive improvements in CT and MR imaging, as well as changes in the clinical management of major salivary gland non-neoplastic disease.

### *Ultrasound*

Ultrasound is a useful technique for detection of nodules of the parotid and submandibular glands. The examination should be carried out with the highest-frequency transducer possible to permit accurate evaluation of the nodule and/or the parenchyma<sup>4</sup>. The deep portions of the parotid gland require the use of less detailed lower-frequency linear probes (5-7 MHz), given the need for deeper penetration. Nevertheless, the deep part of the gland, close to the stylomandibular notch, or the parapharyngeal space are difficult to image, frequently hidden by the mandible. For lesions located/extended into the deep parotid gland, cross-sectional imaging is recommended<sup>5</sup>.

### *CT*

CT is the preferred imaging modality for acute sialadenitis given its spatial resolution and sensitivity to calcification. Limitations of CT include extensive dental artifacts that cannot be avoided with angled axial imaging, contraindications to the use of contrast agent and radiation concerns in the paediatric population. Iodinated contrast intravenous administration is helpful for evaluation of lesion enhancement, assessment of lymph nodes, analysis of the extent of inflammation in infections, and for understanding the vascularity of lesions<sup>5</sup>. Contiguous, axial, thin 2-mm slices are typically acquired from the skull base to the hyoid bone and

the images are reformatted at 1 mm for display. On CT systems where multiplanar reformats are not possible, axial images should be acquired parallel to the occlusal plane of the maxilla or the inferior border of the mandible to best visualise the course of Stensen's duct or Wharton's duct. Multiplanar reformats are performed in the coronal and sagittal plane <sup>6</sup>.

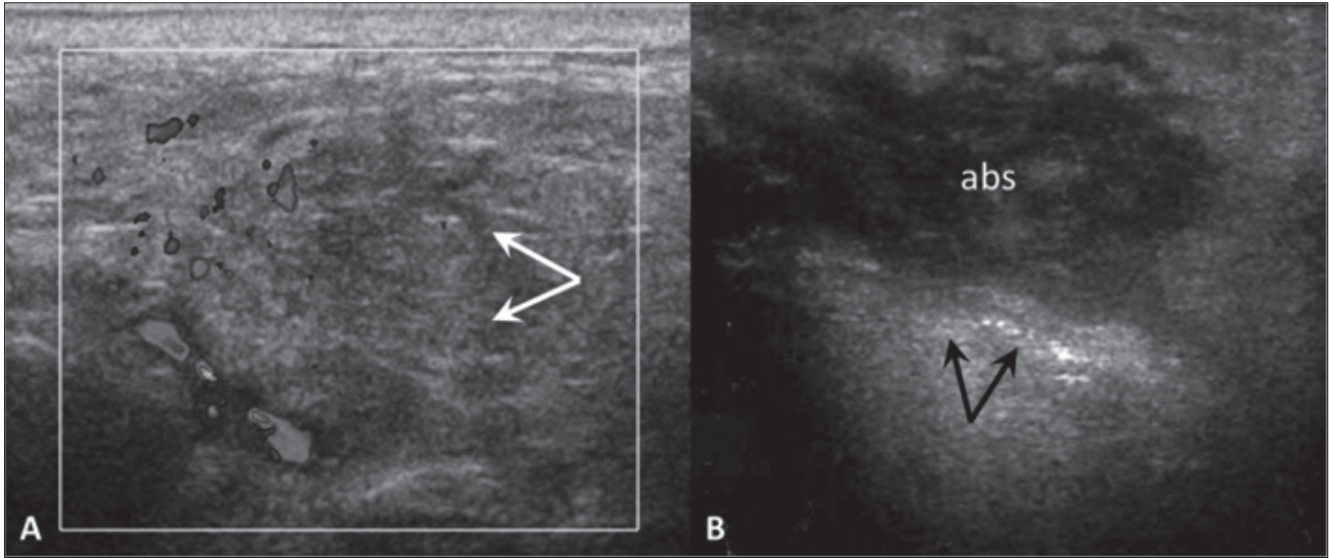
#### *MR and MR sialography*

The superior tissue contrast with MR permits excellent discrimination of the parenchyma and ductal structures. The use of fluid-sensitive pulse sequences allows for non-invasive sialography. Most MR sequences are obtained with a 3 mm slice thickness and 0.5 mm to 2 mm interslice gaps with a multi-channel head coil. Superficial coils may be used to achieve a better spatial resolution for superficial structures. A recent study demonstrated that high resolution MR imaging with a microscopy coil can readily delineate the labial glands <sup>7</sup>. T1-weighted imaging allows better tissue contrast in parotid glands because of the presence of fat tissue within the stroma, yielding a high T1 signal. T2-weighted and post-contrast fat-suppressed T1-weighting imaging are also recommended. Because fat also has high T2 signal on fast spin echo imaging, fat suppression on T2-weighted images helps to generate tissue specificity. Axial and coronal views are generally obtained. Non-enhanced T1-weighted images combined with non-fat-suppressed fast spin-echo T2-weighted images are optimal for delineation of lesions and prediction of the nature of parotid gland pathology. The administration of a paramagnetic contrast agent is helpful to distinguish between solid and cystic components. Contrast administration also helps to evaluate the margins of the mass and its extension into surrounding tissue planes. Diffusion-weighted MR imaging, quantified by apparent diffusion coefficient (ADC), evaluates the diffusion of water molecules. A study of normal and diseased salivary glands with ADC mapping showed that ADC values increased in sialadenitis and decreased in abscess. These changes in ADC may be due to changes in the extracellular water content and its viscosity in the gland parenchyma <sup>8</sup>. MR sialography is a noninvasive method to characterise the ductal structure of the parotid and submandibular glands, providing an excellent alternative to conventional sialography. It is performed with a fat-suppressed heavily T2-weighted high-resolution fast spin echo sequence with a surface coil or multichannel head coil. Several studies have demonstrated that MR sialography is generally as accurate as conventional sialography in detecting obstructions, stenosis and stricture of the main ducts, but it is limited by the acquisition time required for a single sequence and susceptibility to motion <sup>5,6,9</sup>.

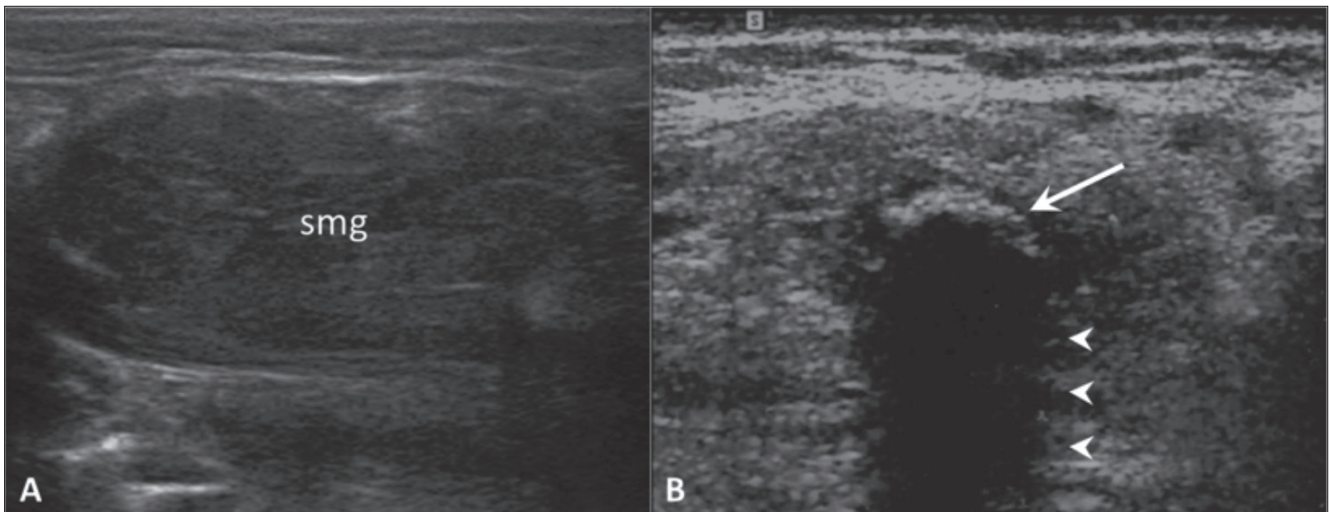
## **Infectious sialadenitis**

### *Acute suppurative sialadenitis and salivary gland emergencies*

Acute suppurative sialadenitis is a bacterial infection characterised by the sudden onset of painful unilateral, occasionally bilateral, parotid swelling with the submandibular salivary gland infrequently involved; it is usually related to inflammation or ductal obstruction. Retrograde non-obstructive infections are more frequent in the parotid glands. Obstructive sialadenitis is usually observed in the submandibular glands, most commonly due to calculi and possibly complicated by bacterial infection. Usually imaging is not necessary at initial presentation. However, if there is no improvement after 48 hours, imaging is recommended to identify/rule out an abscess or an obstructive process such as sialolithiasis. Imaging is also indicated when sepsis is suspected, or if the diagnosis is uncertain. Imaging options include CT, MR sialography, or US. If sialolithiasis with secondary sialadenitis is suspected, US is indicated as it detects up to 90% of stones 2 mm or greater. With CT, thin slices must be acquired to better identify very small calculi. When treatment planning requires demonstrating the calculus (or stricture) and overall excretory system, MR sialography is indicated. MR sialography does not require intraductal injection of contrast agent. It assesses the overall ductal architecture of the gland. It is possibly superior to US in stone detection, but is limited by time requirements. This limitation hampers its wide use. In sialadenitis, inflammatory changes of major salivary gland limited to the parenchyma can be adequately shown by US. If extra-glandular extension is suspected, contrast-enhanced CT is the most sensitive tool for detecting and mapping the deep extent of an abscess. On CT imaging and also on MR, initially the inflamed gland appears enlarged, shows abnormal high attenuation or T2 intensity and a relevant post-contrast enhancement <sup>10</sup>. Signs to be scrutinised include thickening of fascia and infiltration of subcutaneous fat. Thickening of deep cervical fascia and infiltration of cervical fat produce a "dirty fat" appearance. Cellulitis of the gland can lead to formation of a focal abscess <sup>11</sup> (Figs. 1-4). Reconstructions of the CT volume in the coronal plane are indispensable to evaluate the extent and topographic relationship of cellulitis or abscess (floor of the mouth for submandibular lesions and skull base for parotid gland) <sup>10</sup>. The mortality for suppurative parotitis has improved dramatically in the era of antibiotics, but is still reported to be 20% to 40%. Potential complications are rare, but can be serious. These include abscess extension into deep spaces of the neck and mediastinum, septic thrombophlebitis of the jugular vein (Lemierre's syndrome), osteomyelitis of the mandible, sepsis, respiratory obstruction and rupture through the external auditory canal with spontaneous drainage through the face <sup>12,13</sup>.



**Fig. 1.** Acute parotid sialadenitis (A). Enlarged, hypoechoic parotid gland (arrows), colour Doppler shows increased blood flow. Parotid gland abscess (B). US demonstrates a heterogeneous hypoechoic collection (abs) within the parotid gland: internal echoes, poorly defined borders and posterior acoustic enhancement (arrows).



**Fig. 2.** Obstructive sialadenitis. On US, the submandibular gland (smg) appears enlarged and hypoechoic (A). Highly reflective echogenic focus within the Wharton's duct (arrow) with prominent posterior acoustic shadowing (arrowheads), consistent with a sialolith (B).

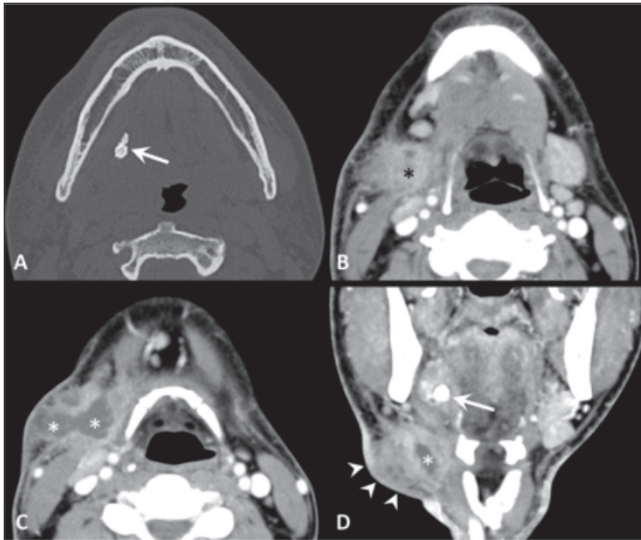
### *Tuberculosis*

Tuberculous (TB) sialadenitis with primary or secondary manifestations in the lymph nodes of the parotid gland is more frequently observed in developing countries. However, in the last few years, non-tuberculous mycobacteria are more often diagnosed. Particularly in children with enlarging, non-tender mass with violaceous skin discoloration, unresponsive to conventional antibiotics, this diagnosis must be taken into consideration. The diagnosis may be suggested by US when enlarged intra-parotid lymph nodes and a diffusely enlarged parotid gland are demonstrated. Contrast-enhanced CT most commonly shows asymmetric cervical lymphadenopathy and contiguous low-density, necrotic, ring-enhancing masses in-

volving the subcutaneous fat and skin <sup>14</sup>. TB sialadenitis more often affects the parotid gland (70%) where two different clinical presentations are usually observed: one is like acute sialadenitis, with imaging features resembling acute sialadenitis with abscess; the other mimics a salivary gland tumour. In this setting, it is necessary to rule out other conditions presenting with single gland enlargement combined with abnormal lymph nodes such as lymphoma or metastatic disease <sup>15</sup>.

### *Viral sialadenitis*

Several viruses have been associated with sialadenitis. Among these, the paramyxovirus (mumps) is the best known of the sialoadenotropic viruses. On US,

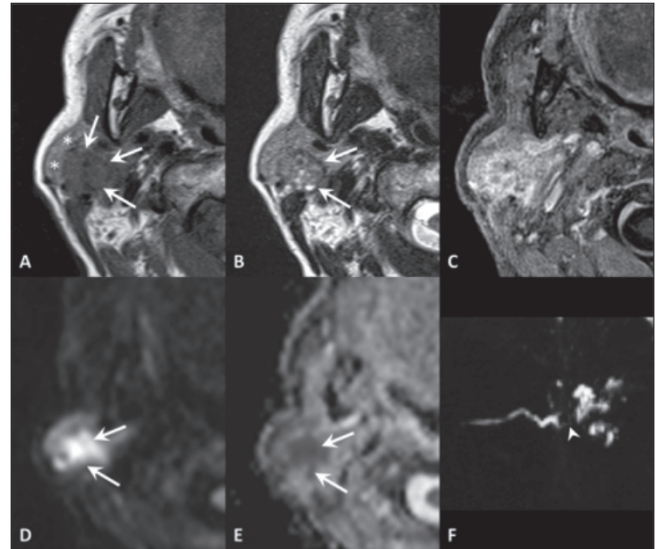


**Fig. 3.** Obstructive sialadenitis complicated by extra-glandular abscess, contrast-enhanced CT. (A) The bone window image demonstrates a mineralised stone (arrow) within the right Wharton's duct. (B-D) The soft tissue window images show enlargement of the right submandibular gland (black asterisk), thickening of the submandibular fat tissue producing a "dirty fat" appearance. At the level of the neck swelling (arrowheads), CT demonstrates an abscess (white asterisks) in the submandibular space. The calculus is shown also the coronal plane (arrow).

the glands are enlarged with a more rounded shape, a convex lateral surface and a hypoechoic structure. CT and MR are not indicated and rarely performed in acute viral sialadenitis. On CT or MR images, the inflamed glands appear enlarged and may show abnormal (hyperdense) attenuation or intensity (high-signal intensity on T2 weighted images), enhancing after administration of contrast agent.

#### *Human immunodeficiency virus*

Persistent, painless parotid enlargement, usually bilateral, occurs in about 5% of HIV-positive patients. As the disease progresses, the lymphoproliferative activity of parotid lymph nodes or proliferation of lymphocytes that are normally present within the gland or have infiltrated into the gland will result in an enlarged parotid gland. Bilateral benign parotid lymphoepithelial cysts can also develop and cause progressive glandular swellings. These cysts are thought to originate from included epithelium in the intraparotid lymph nodes<sup>2</sup>. US demonstrates large anechoic/hypoechoic areas with debris and septa (lymphoepithelial cysts) combined with large oval hypoechoic areas (enlarged intraparotid nodes). Benign lymphoepithelial lesions and cysts have non-specific CT and MR features (Fig. 5). In these patients, additional abnormalities in the Waldeyer ring (tonsillar hypertrophy) and reactive cervical adenopathy are frequently present<sup>16 17</sup>.



**Fig. 4.** Focal obstructive sialadenitis. MR axial SE T1 (A), TSE T2 (B), VIBE after contrast administration (C), DWI b1000 (D) with ADC map (E); sialo-MR (maximum intensity projection in the sagittal plane) (F). Sudden onset of painful swelling of the right parotid gland. The focal inflamed area (arrows) can be detected because of its mass-effect on the adjacent gland tissue (asterisks), greater post-contrast enhancement and diffusion restriction. The MR sialography shows a filling defect (arrowhead) and intraglandular duct ectasia.

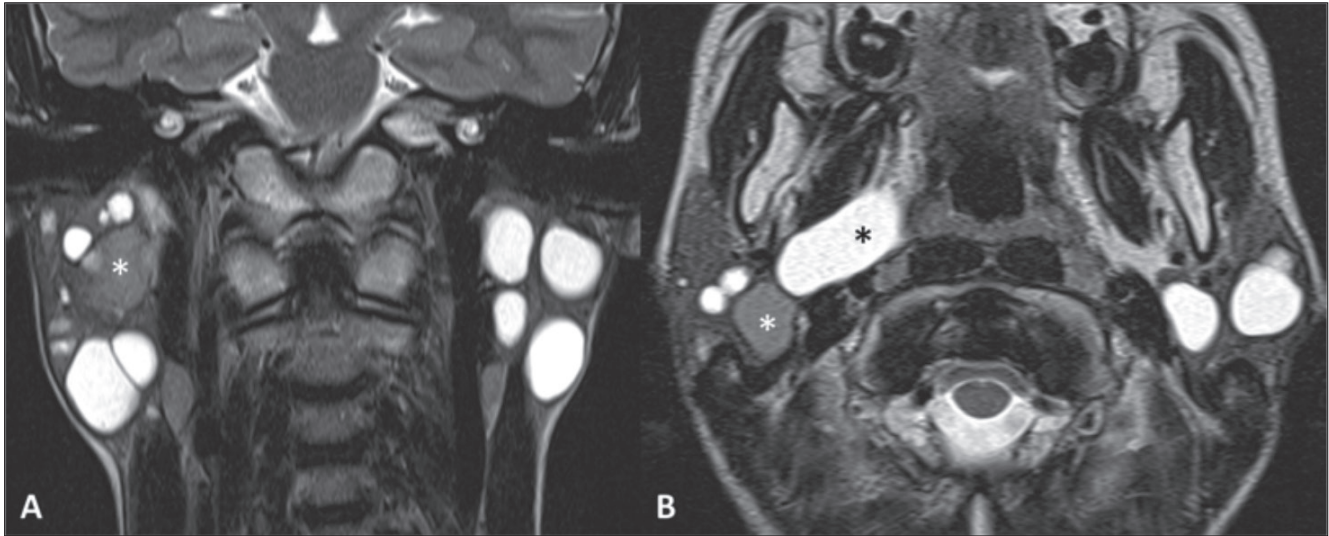
## Chronic sialadenitis and related conditions

### *Sjögren's syndrome and lymphoepithelial sialadenitis*

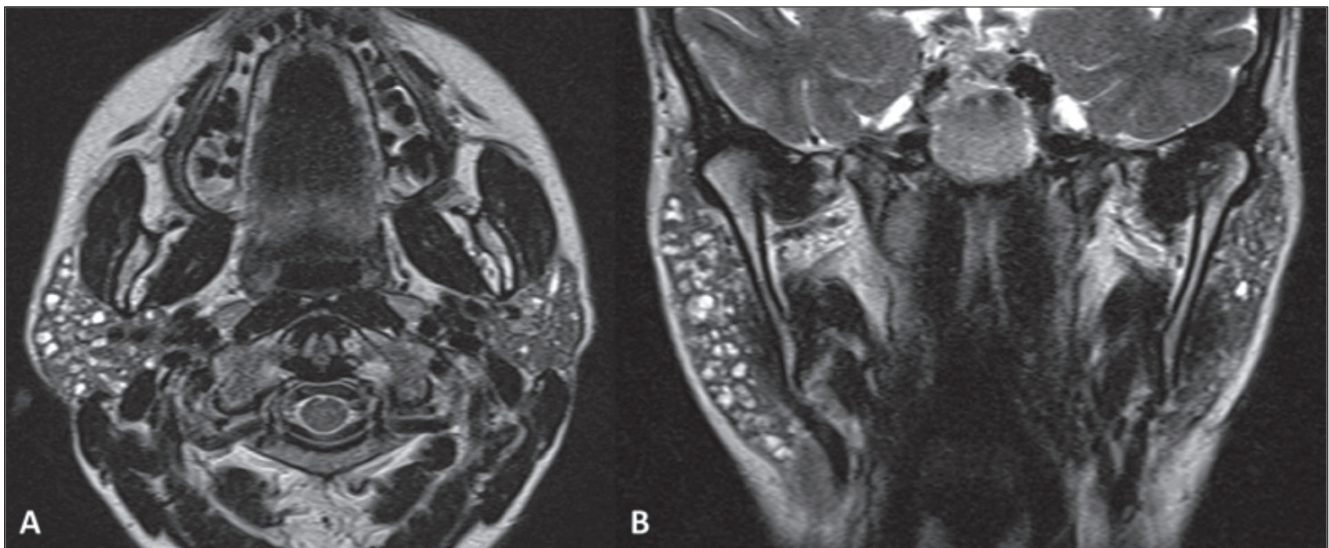
Sjögren's syndrome is a multisystem autoimmune disease, mostly affecting women. It is characterised by a diffuse lymphoid proliferation in the exocrine salivary and lacrimal glands leading to lymphocytic sialadenitis, parenchymal replacement and progressive dilatation of intraparenchymal ducts. MR and US are more accurate than CT in assessing the severity of the disease. In the early stage of the disease, MR shows only enlarged and homogenous parotid glands. As the disease progresses, tiny ductal dilatation and parenchymal lymphocytic infiltration result in a non-homogeneous dotted or nodular pattern ("salt and pepper"). This corresponds to intermediate disease. In this stage, US shows dilated ducts and lymphoproliferative lesions as a pattern of anechoic and hypoechoic scattered areas. On CT, the accurate scrutiny of thin slices may show multiple hypodense "spots" reflecting duct dilations<sup>18</sup>. The advanced stages are characterised by marked non-homogeneous appearance of the glands: large dilated intraglandular ducts (foci of high T2 signals) are combined with an overall decrease in T2 signal (focal accumulation of lymphocytes and fibrous tissue). This combination gives rise to a "honeycomb" pattern<sup>11</sup> (Fig. 6).

The progressive changes in size of intraglandular ducts have been evaluated with high resolution MR sialography. An equivalent of the sialographic staging of Sjögren's





**Fig. 5.** Bilateral benign parotid lymphoepithelial cysts in a HIV-positive patient. MR TSE T2-weighted sequences on the coronal (A) and axial (B) planes. Multiple cystic lesions in the parotid glands, among which a high-protein content cyst (white asterisk) and a cyst extending in the right parapharyngeal space reaching the lateral wall of oropharynx.



**Fig. 6.** Sjögren's syndrome – intermediate disease. MR TSE T2-weighted sequences on the axial (A) and coronal (B) planes. Bilateral parotid tiny ductal dilatation, particularly evident on the right.

syndrome described by Rubin and Holt in 1957 is now applied to MR sialography, as follows<sup>17 19</sup>:

- Stage I. Punctate contrast collection 1 mm;
- Stage II. Globular contrast collection 1 to 2 mm;
- Stage III. Cavitory contrast collection 2 mm;
- Stage IV. Destruction of gland parenchyma.

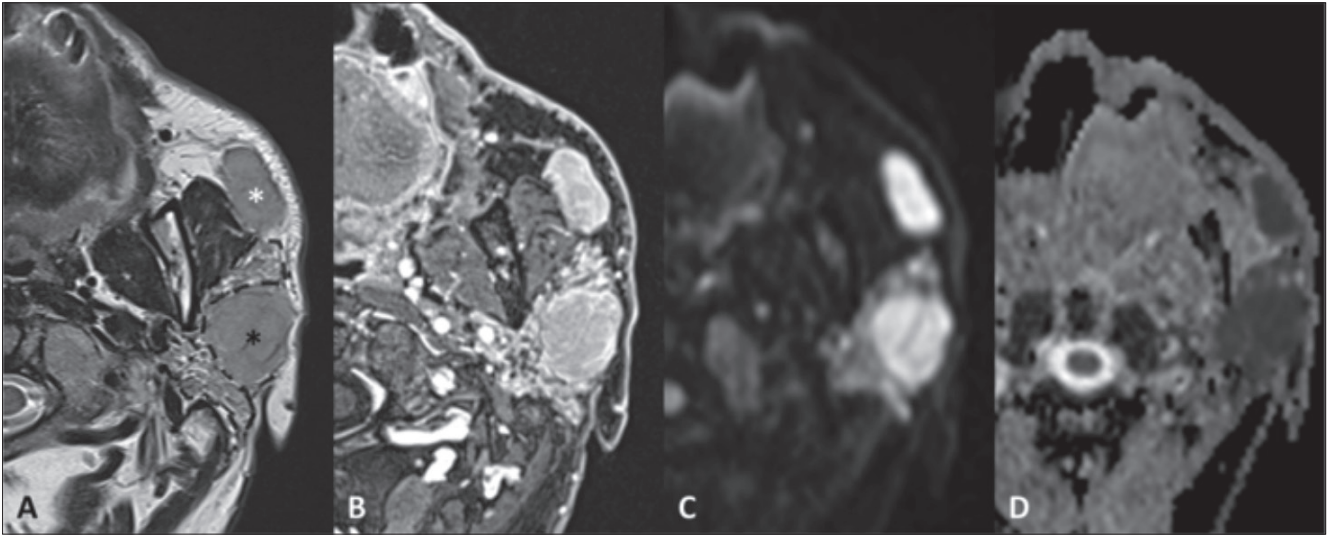
Makula et al. consider MR imaging to be unnecessary as a routine method in the diagnosis of Sjögren's syndrome. They consider US adequate for both the diagnosis and the follow-up<sup>20</sup>.

Patients with primary Sjögren's syndrome have an increased risk of non-Hodgkin's lymphoma, particularly extranodal marginal zone B-cell lymphoma of mucosa-

associated lymphoid tissue (MALT) type, most of which occur in the salivary glands (Fig. 7).

#### *Sarcoidosis*

Parotid gland involvement is demonstrated in 6%–30% of patients with sarcoidosis. On MR images, the affected parotid glands are typically enlarged, with increased signal intensity on T2-weighted images and enhancement on contrast-enhanced images<sup>21</sup>. Large granulomas have been described as multiple benign-appearing, non-cavitating, intraparotid nodules ("foamy parotids")<sup>22</sup>. Diagnosis is established when clinical and imaging findings are integrated with histology<sup>24</sup>.



**Fig. 7.** Lymphoma of mucosa-associated lymphoid tissue (MALT) in a patient with primary Sjögren's syndrome. MR TSE T2 (A), VIBE after contrast administration (B), DWI b1000 (C) with ADC map (D). MR scan shows a lesion of the superficial portion of the parotid gland (black asterisk), displacing the remaining part of the gland (dashed line), with enhancement and high diffusion restriction. A second lesion with similar features is evident at the anterior extension of the gland (white asterisk).

#### *Radiation-induced sialadenitis*

Radiation-induced sialadenitis is a sequela of external beam radiation or radioactive iodine therapy for thyroid carcinoma. Combining medical history with clinical examination facilitates a diagnosis of hyposalivation due to radiation sialadenitis, and imaging is not required. The pathologic changes are characterised by a combination of patches of inflammatory infiltrates mixed with areas of fibrosis and volume reduction. It results in a marked heterogeneous appearance<sup>23,24</sup>. On US, these structural changes translate into hypo- or isoechoic areas (relative to adjacent muscles) with multiple hyperechoic lines or spots. On MR, the early post-RT changes are characterised by enlarged glands with hyperintensity on T2-weighted images and marked enhancement. At later stages, the signal intensity of the glands decreases while the volume constantly reduces, leading to gland shrinking, and the enhancement also diminishes. MR sialography demonstrates a reduced visibility of the ducts in the salivary glands that received more than 20 Gy<sup>23</sup>.

#### *IgG4-related disease*

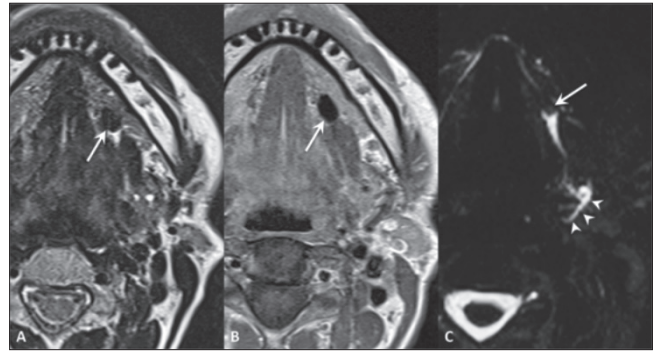
In the head and neck, the salivary glands are the most frequently involved anatomic structures by IgG4-related disease, with the submandibular gland being the most common target. Chronic sclerosing sialadenitis (Kuttner tumour) and Mikulicz's disease are now considered to be part of the spectrum of IgG4-related disease. Kuttner tumour typically affects one or both submandibular glands and clinically presents as a "hard swelling". US shows diffuse enlargement of the submandibular glands with multiple ill-defined hypoechoic foci scattered against a heterogeneous background giving rise to "mottled, net-like" appearance and minimally increased vascularity.

Enlarged glands show homogeneous attenuation on CT and low to intermediate signal intensity on T2-weighted images and intermediate signal intensity on T1-weighted images on MR imaging with associated homogeneous enhancement. Multiple enlarged lymph nodes are commonly seen. Differential diagnosis includes malignant salivary gland tumours, if unilateral involvement is seen; lymphoma and the acute phase of Sjögren's syndrome, in case of bilateral lesions. Mikulicz's disease is clinically defined as bilateral painless swelling of the submandibular, sublingual, parotid and lacrimal glands for a duration of at least 3 months. Cross sectional imaging shows bilateral symmetric swelling of the involved glands. At CT, lesions usually demonstrate homogeneous attenuation and enhancement. On MR imaging, lesions typically demonstrate a homogeneous low to intermediate signal intensity on T2-weighted images and low signal intensity on T1-weighted images, with homogeneous enhancement following contrast agent administration. Differential lesions to be considered include the acute phase of Sjögren's, lymphoma, sarcoidosis and mumps<sup>25,26</sup>.

#### *Sialolithiasis*

Sialolithiasis is the main cause of obstructive salivary diseases, being involved in 66% of cases and accounting for about 50% of major salivary gland diseases. Sialolithiasis affects the submandibular gland in 80-90% of cases, mainly unilaterally, without a preferred side. This different incidence of calculi between the parotid and submandibular gland is partially related to the ascendant and sharper angled duct system of the submandibular gland and the type of secretion, mainly mucous. The sublingual and other minor salivary glands are rarely affected.

Currently, US represents an excellent first-level diagnostic technique insofar as, in experienced hands, it reveals ductal and highly mineralised stones with a diameter of at least 1.5-3 mm<sup>27</sup>. Because of this size-related threshold, US does not allow a reliable exclusion of very small salivary gland calculi. Therefore, further diagnostic investigations are recommended to detect calculi in patients with normal US findings and suspected lithiasis<sup>28</sup>. In the work-up, it is important to differentiate calculi located in the main ducts from those placed in the intraglandular ducts, as their treatment may require removal of the gland<sup>29</sup>. Sonographically, intraductal concretions appear as bright curvilinear echo complexes with a posterior shadowing. In calculi smaller than 2 mm, the shadow may be missing. In symptomatic sialolithiasis, a concomitant dilatation of the ductal system or inflammation is often visualised<sup>29</sup>. CT, MRI and MR sialography can be reserved to patients with negative or inconclusive US results and a clinical presentation suggesting ductal obstruction. An important advantage of MR sialography is the fact that the structural anatomy of the salivary glands remains unchanged with this technique, which allows an exact delimitation of the glandular parenchyma and duct. In US, the parenchyma and ducts may be compressed by the transducer. MR sialography consists of two steps: an anatomical study, which contributes to define the dimensional, morphological and structural features of the parotid and submandibular glands and the relationship with adjacent structures; and a sialographic study, which represents the ductal components and possible intraductal filling defects. In addition, it offers simultaneous assessment of both the parotid and submandibular glands even in acute inflammation<sup>9,30</sup> (Figs. 8, 9).



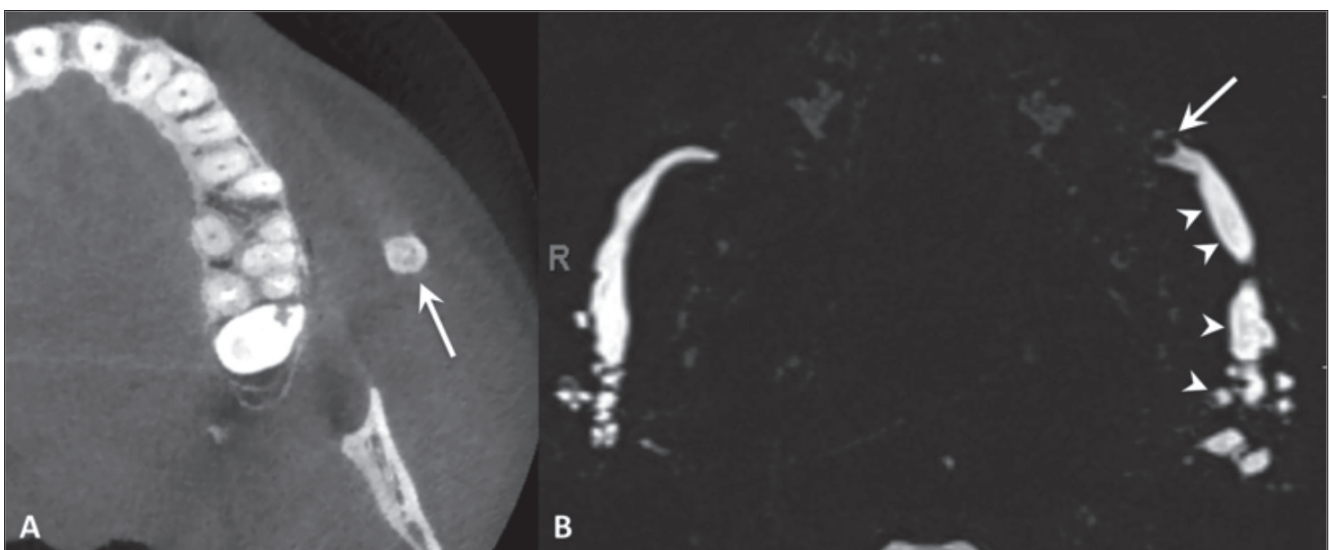
**Fig. 8.** Wharton's duct sialolithiasis. MR TSE T2 (A), SE T1 (B) and MR sialography (maximum intensity projection in the axial plane) (C). Hypointense mineralised stone in the left Wharton's duct, to which corresponds a filling defect on sialo-MR (arrows); moderate ducts dilatation (arrowheads).

#### Sialadenosis

Sialadenosis, or sialosis, is defined as a bilateral persistent, painless, soft, non-neoplastic, non-inflammatory swelling usually involving both parotid glands and at times the submandibular salivary glands. Sialadenosis is associated with a variety of conditions that include alcoholism, endocrine disorders (particularly diabetes mellitus) and malnutrition, which in our society usually results from anorexia nervosa<sup>2</sup>. Diagnosis is best achieved by integrating the patient's medical history, clinical signs and symptoms of glandular swelling and information derived from available investigative procedures that show bilateral enlargement of the parotid glands with fatty infiltration in the end stage of disease<sup>18</sup>.

#### Cystic lesions

Cystic lesions may occur in both minor and major salivary glands; their size is usually related to the site of ori-

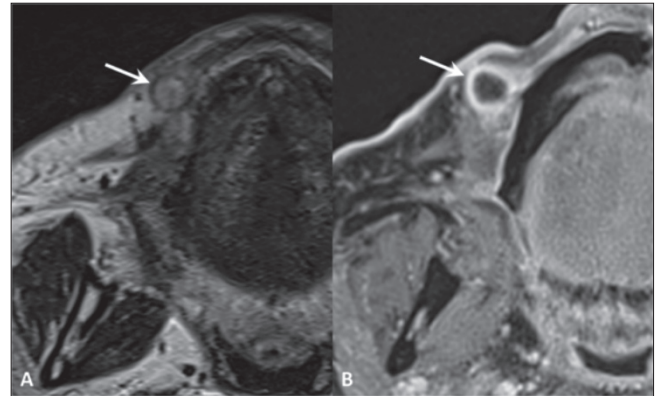


**Fig. 9.** Stensen's duct sialolithiasis. Cone-beam CT (A) and MR sialography (maximum intensity projection in the axial plane) (B). Highly mineralised stone in the left Stensen's duct, corresponding to a filling defect on MR sialography (arrow) causing a marked dilatation of the ductal system (arrowheads); dilatation of the contralateral ductal system is also evident.

gin, reaching greatest dimensions in major salivary glands. Mucous retention cysts may develop consequent to a duct obstruction, representing true cysts, generally unilocular, with epithelial linings. Conversely, a mucocele is a benign, mucus-containing pseudocystic lesion caused by a mucus extravasation. The common site of occurrence of mucocele is the lower lip, followed by tongue, floor of mouth (ranula), and the buccal mucosa. When the mucocele content becomes infected, the lesion is defined as mucopyocele (Fig. 10). Sublingual glands are more at risk for duct obstructions because of the small caliber of the drainage ducts.

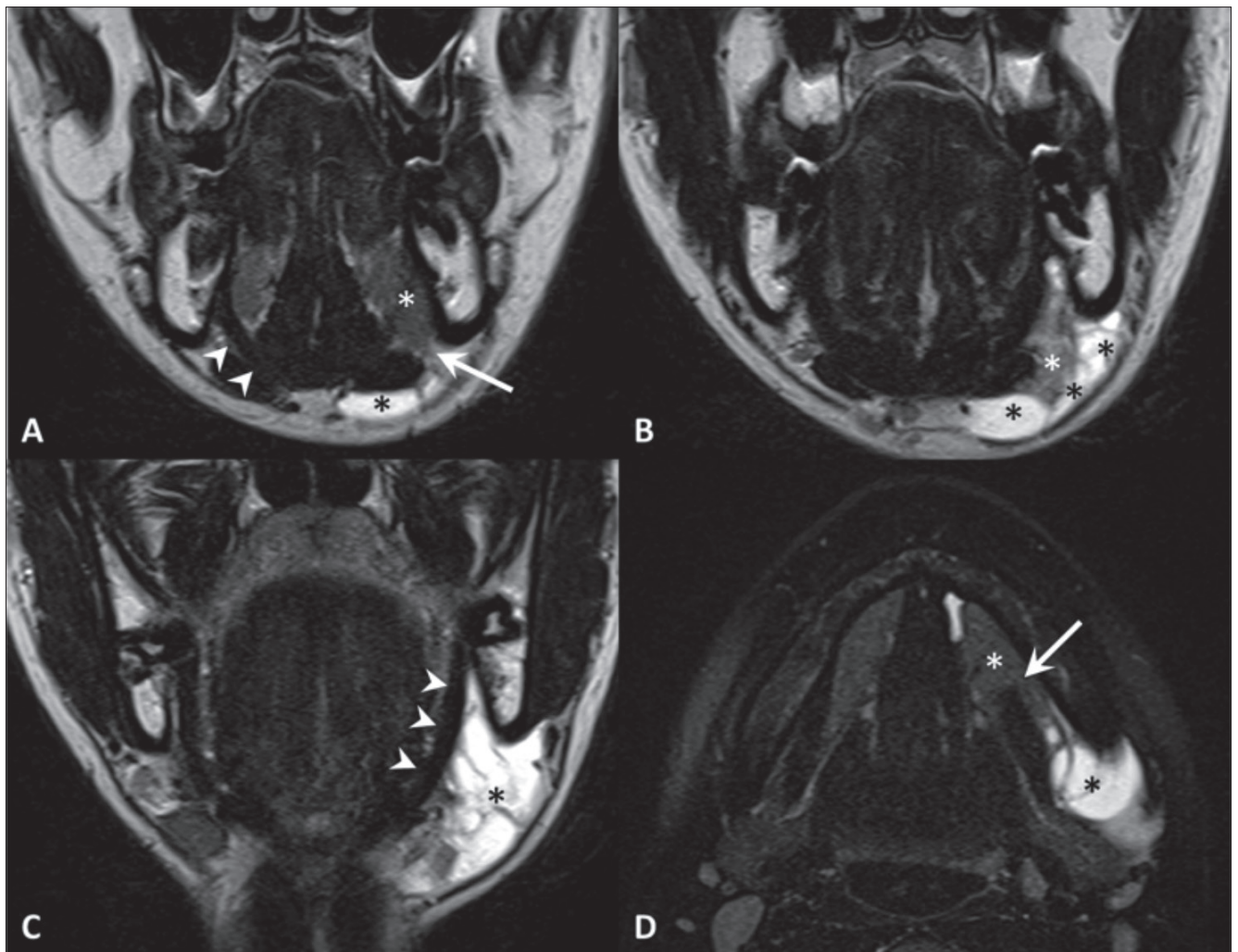
#### Ranula

The term ranula refers to a mucous retention cyst that occurs primarily in the sublingual gland. A ranula can occur in two forms: simple ranula, the most common, is a retention cyst that remains above the level of the mylohyoid muscle and deep or plunging ranula, which represents a submucosal mucus extravasation phenomenon (pseudocyst) that develops as a leakage from a sublingual duct.



**Fig. 10.** Mucopyocele. MR TSE T2 (A) and post-contrast VIBE (B). Spherical lesion within the soft tissues of the lip with ring-enhancement and hypointensity on T2, corresponding to a mucopyocele of a labial gland (arrow).

Secretory leakage occurs when the duct wall is lacerated, probably from trauma. The rapid accumulation of fluid is cyst-like in appearance and presents itself as either an intraoral or extraoral swelling. Plunging ranula may extend



**Fig. 11.** Plunging ranula. TSE T2, coronal plane (A-C, anterior to posterior), TSE T2 with fat-saturation, axial plane (D). MR shows a defect of the mylohyoid muscle (arrow) with sublingual gland (white asterisk) herniation. Note the normal appearance of the contralateral and ipsilateral (in a posterior slice) mylohyoid muscle (arrowheads). Plunging ranula (black asterisks) extends posteriorly in the submandibular space.

through the mylohyoid muscle and deeper soft tissue to produce a submental or lateral neck swelling termed plunging or cervical ranula. The plunging ranula often infiltrates adjacent tissue planes, extending inferiorly and dorsally to the submandibular gland region, while ventrally it may cross the midline to the contralateral floor of the mouth. US is very useful in determining the extent of the plunging ranula, confirming the cystic nature of the lesion, assessing the status of the mylohyoid muscle (a defect demonstrated in nearly 100% of cases) and evaluating the sublingual gland for rupture or herniation<sup>31</sup>. On CT, the simple ranula is usually a roughly ovoid-shaped cyst with a homogeneous central attenuation region of 10 to 20 HU. On MR imaging, a ranula's characteristic appearance is generally dominated by its high water content. Thus, it has a low T1-weighted, an intermediate proton density, and a high T2-weighted signal intensity. This appearance, especially in a plunging ranula, may resemble that of a lymphatic malformation (Fig. 11).

#### Branchial cleft cysts

First branchial cleft cysts are usually periauricular or periparotid/intraparotid. These latter cysts/sinus tracts are classified as type II and are the most common first branchial cleft cyst. On US, they are usually solitary anechoic masses with posterior acoustic shadowing. On CT imaging, first branchial cleft anomalies usually present as a cystic mass superficial/within/deep to the parotid salivary gland<sup>32</sup>. They are hyperintense on T2-weighted imaging and hypointense on T1-weighted imaging. As with other branchial cleft anomalies, cyst wall thickness and enhancement varies with the degree of inflammation. In contrast, a second branchial cleft cyst is often seen deep to the platysma, anterior to the sternocleidomastoid muscle, posterior to the submandibular gland, and lateral to the carotid sheath. It often lies inferiorly to the parotid gland<sup>5</sup>.

## Tumour-like lesions

#### Necrotising sialometaplasia

Necrotising sialometaplasia is a benign, ulcerative, self-limiting inflammatory disease of the minor salivary glands. It probably results from a compromised vasculature supplying salivary gland tissue. The palatine salivary glands represent the most frequent group involved<sup>33</sup>. On MRI, it presents as a lobulated submucosal lesion of the hard palate, hyperintense on T2 and hypointense on T1 weighted images; after contrast administration, a thin peripheral rim of enhancement may be observed. CT demonstrates the absence of bone erosion<sup>34</sup>.

## Conclusions

Obstructive and inflammatory disorders of the salivary glands are commonly seen in the major salivary glands

due to a various pathological conditions, affecting both the glandular tissue and/o the escretory system.

The appropriate diagnostic imaging workout is determined by the clinical scenario which is essential to narrow the list of differential diagnosis.

US-guided fine needle aspiration and cytology may also attribute to achieve the correct diagnosis.

## References

- Blitzer A. *Inflammatory and obstructive disorders of salivary glands*. J Dent Res 1987;66 Spec No:675-9.
- Mandel L, Surattanont F. *Bilateral parotid swelling: a review*. Oral Surg Oral Med Oral Pathol Oral Radiol Endod 2002;93:221-37.
- Wilson KF, Meier JD, Ward PD. *Salivary gland disorders*. Am Fam Physician 2014;89:882-8.
- Bialek EJ, Jakubowski W, Zajkowski P, et al. *US of the major salivary glands: anatomy and spatial relationships, pathologic conditions, and pitfalls*. Radiographics 2006;26:745-63.
- Prasad RS. *Parotid gland imaging*. Otolaryngol Clin North Am 2016;49:285-312.
- Mosier KM. *Diagnostic radiographic imaging for salivary endoscopy*. Otolaryngol Clin North Am 2009;42:949-72.
- Sumi M, Yamada T, Takagi Y, et al. *MR imaging of labial glands*. AJNR Am J Neuroradiol 2007;28:1552-6.
- Sumi M, Takagi Y, Uetani M, et al. *Diffusion-weighted echoplanar MR imaging of the salivary glands*. AJR Am J Roentgenol 2002;178:959-65.
- Becker M, Marchal F, Becker CD, et al. *Sialolithiasis and salivary ductal stenosis: diagnostic accuracy of MR sialography with a three-dimensional extended-phase conjugate-symmetry rapid spin-echo sequence*. Radiology 2000;217:347-58.
- Yousem DM, Kraut MA, Chalian AA. *Major salivary gland imaging*. Radiology 2000;216:19-29.
- Shah GV. *MR imaging of salivary glands*. Neuroimaging Clin N Am 2004;14:777-808.
- Armstrong MA, Turturro MA. *Salivary gland emergencies*. Emerg Med Clin North Am 2013;31:481-99.
- Maroldi R, Farina D, Ravanelli M, et al. *Emergency imaging assessment of deep neck space infections*. Semin Ultrasound CT MR 2012;33:432-42.
- Robson CD, Hazra R, Barnes PD, et al. *Nontuberculous mycobacterial infection of the head and neck in immunocompetent children: CT and MR findings*. AJNR Am J Neuroradiol 1999;20:1829-35.
- Zenk J, Iro H, Klintworth N, et al. *Diagnostic imaging in sialadenitis*. Oral Maxillofac Surg Clin North Am 2009;21:275-92.
- Gadodia A, Bhalla AS, Sharma R, et al. *Bilateral parotid swelling: a radiological review*. Dentomaxillofac Radiol 2011;40:403-14.
- Madani G, Beale T. *Inflammatory conditions of the salivary glands*. Semin Ultrasound CT MR 2006;27:440-51.
- Mandel L. *Salivary gland disorders*. Med Clin North Am 2014;98:1407-49.
- Rubin P, Holt JF. *Secretory sialography in diseases of the*

- major salivary glands. *Am J Roentgenol Radium Ther Nucl Med* 1957;77:575-98.
- <sup>20</sup> Makula E, Pokorny G, Rajtár M, et al. *Parotid gland ultrasonography as a diagnostic tool in primary Sjögren's syndrome*. *Br J Rheumatol* 1996;35:972-7.
- <sup>21</sup> Koyama T, Ueda H, Togashi K, et al. *Radiologic manifestations of sarcoidosis in various organs*. *Radiographics* 2004;24:87-104.
- <sup>22</sup> Nwawka OK, Nadgir R, Fujita A, et al. *Granulomatous disease in the head and neck: developing a differential diagnosis*. *Radiographics* 2014;34:1240-56.
- <sup>23</sup> Cheng SC, Wu VW, Kwong DL, et al. *Assessment of post-radiotherapy salivary glands*. *Br J Radiol* 2011;84:393-402.
- <sup>24</sup> Ying M, Wu VW, Kwong DL. *Comparison of sonographic appearance of normal and postradiotherapy parotid glands: a preliminary study*. *Ultrasound Med Biol* 2007;33:1244-50.
- <sup>25</sup> Fujita A, Sakai O, Chapman MN, et al. *IgG4-related disease of the head and neck: CT and MR imaging manifestations*. *Radiographics* 2012;32:1945-58.
- <sup>26</sup> Katabathina VS, Khalil S, Shin S, et al. *Immunoglobulin G4-related disease: recent advances in pathogenesis and imaging findings*. *Radiol Clin North Am* 2016;54:535-51.
- <sup>27</sup> Capaccio P, Torretta S, Ottavian F, et al. *Modern management of obstructive salivary diseases*. *Acta Otorhinolaryngol Ital* 2007;27:161-72.
- <sup>28</sup> Terraz S, Poletti PA, Dulguerov P, et al. *How reliable is sonography in the assessment of sialolithiasis?* *AJR Am J Roentgenol* 2013;201:W104-9.
- <sup>29</sup> Gritzmann N, Rettenbacher T, Hollerweger A, et al. *Sonography of the salivary glands*. *Eur Radiol* 2003;13:964-75.
- <sup>30</sup> Andretta M, Tregnaghi A, Prosenikliev V, et al. *Current opinions in sialolithiasis diagnosis and treatment*. *Acta Otorhinolaryngol Ital* 2005;25:145-9.
- <sup>31</sup> Jain P, Jain R, Morton RP, et al. *Plunging ranulas: high-resolution ultrasound for diagnosis and surgical management*. *Eur Radiol* 2010;20:1442-9.
- <sup>32</sup> Adams A, Mankad K, Offiah C, et al. *Branchial cleft anomalies: a pictorial review of embryological development and spectrum of imaging findings*. *Insights Imaging* 2016;7:69-76.
- <sup>33</sup> Abrams AM, Melrose RJ, Howell FV. *Necrotizing sialometaplasia. A disease simulating malignancy*. *Cancer* 1973;32:130-5.
- <sup>34</sup> Farina D, Gavazzi E, Avigo C, et al. *Case report. MRI findings of necrotizing sialometaplasia*. *Br J Radiol* 2008;81:e173-5.

Received: September 15, 2016 - Accepted: December 12, 2016

# Salivary biomarkers and proteomics: future diagnostic and clinical utilities

## *Biomarkers e proteomica salivari: prospettive future cliniche e diagnostiche*

M. CASTAGNOLA<sup>1</sup>, E. SCARANO<sup>2</sup>, G.C. PASSALI<sup>2</sup>, I. MESSANA<sup>3</sup>, T. CABRAS<sup>4</sup>, F. IAVARONE<sup>5</sup>, G. DI CINTIO<sup>2</sup>, A. FIORITA<sup>2</sup>, E. DE CORSO<sup>2</sup>, G. PALUDETTI<sup>2</sup>

<sup>1</sup> Institute of Biochemistry and Clinical Biochemistry, Catholic University, Rome, Istituto di Chimica del Riconoscimento Molecolare C.N.R. Rome, Italy; <sup>2</sup> Department of Head and Neck Surgery, “A. Gemelli” Hospital Foundation, Catholic University, Rome, Italy; <sup>3</sup> Life and Environmental Sciences Department, University of Cagliari, and Istituto di Chimica del Riconoscimento Molecolare C.N.R. Rome, Italy; <sup>4</sup> Life and Environmental Sciences Department, University of Cagliari, Italy; <sup>5</sup> Institute of Biochemistry and Clinical Biochemistry, Catholic University, Rome, Italy

### SUMMARY

Saliva testing is a non-invasive and inexpensive test that can serve as a source of information useful for diagnosis of disease. As we enter the era of genomic technologies and –omic research, collection of saliva has increased. Recent proteomic platforms have analysed the human salivary proteome and characterised about 3000 differentially expressed proteins and peptides: in saliva, more than 90% of proteins in weight are derived from the secretion of three couples of “major” glands; all the other components are derived from minor glands, gingival crevicular fluid, mucosal exudates and oral microflora. The most common aim of proteomic analysis is to discriminate between physiological and pathological conditions. A proteomic protocol to analyze the whole saliva proteome is not currently available. It is possible distinguish two type of proteomic platforms: top-down proteomics investigates intact naturally-occurring structure of a protein under examination; bottom-up proteomics analyses peptide fragments after pre-digestion (typically with trypsin). Because of this heterogeneity, many different biomarkers may be proposed for the same pathology. The salivary proteome has been characterised in several diseases: oral squamous cell carcinoma and oral leukoplakia, chronic graft-versus-host disease Sjögren’s syndrome and other autoimmune disorders such as SAPHO, schizophrenia and bipolar disorder, and genetic diseases like Down’s Syndrome and Wilson disease. The results of research reported herein suggest that in the near future human saliva will be a relevant diagnostic fluid for clinical diagnosis and prognosis.

KEY WORDS: Saliva • Proteome • Salivary biomarkers

### RIASSUNTO

*Lo studio della proteomica salivare, test economico e non invasivo, rappresenta una fonte di numerose informazioni, ed è utile per la diagnosi di svariate malattie. Da quando siamo entrati nell’era della tecnologia genomica e delle scienze “omiche”, la raccolta di campioni salivari è aumentata esponenzialmente. Recenti piattaforme proteomiche hanno analizzato il proteoma salivare umano, caratterizzando circa 3000 peptidi e proteine, espressi in maniera differente: più del 90% in peso deriva dalla secrezione delle tre ghiandole salivari maggiori, mentre la restante parte proviene dalle ghiandole salivari minori, dal fluido crevicolare gengivale, da essudati mucosi e dalla microflora orale. L’obiettivo principale dell’analisi proteomica è discriminare tra condizioni fisiologiche e patologiche. Ad oggi, tuttavia, non esiste un preciso protocollo che permetta di analizzare l’intero proteoma salivare, pertanto sono state realizzate svariate strategie. Innanzitutto, è possibile distinguere due tipologie di piattaforme proteomiche: l’approccio “top-down” prevede l’analisi delle proteine sotto esame come entità intatte; nell’approccio “bottom-up” la caratterizzazione della proteina avviene mediante lo studio dei peptidi ottenuti dopo digestione enzimatica (con tripsina tipicamente). A causa di questa eterogeneità, per una stessa patologia sono stati proposti differenti biomarkers. Il proteoma salivare è stato caratterizzato in numerose malattie: carcinoma squamoso e leucoplachie orali, malattia del trapianto contro l’ospite (GVHD) cronica, sindrome di Sjögren e altri disordini autoimmuni come la sindrome SAPHO (sinovite, acne, pustolosi, iperostosi e osteite), schizofrenia e disordine bipolare, malattie genetiche come la sindrome di Down o la malattia di Wilson. In conclusione, i risultati delle ricerche riportate in questa review suggeriscono che nel prossimo futuro la saliva diverrà un fluido di indubbia rilevanza diagnostica utile per fini clinici, sia diagnostici, sia prognostici.*

PAROLE CHIAVE: Saliva • Proteoma • Biomarkers salivari

Acta Otorhinolaryngol Ital 2017;37:94-101

### Introduction

Saliva is a very attractive body fluid for diagnosis of disease for many reasons: i) collection of saliva is usually economical, safe, easy and can be performed without the help of healthcare workers (it allows for home-based sam-

pling); ii) it is considered an acceptable and non-invasive process by patients because it does not provoke any pain (and can be easily collected for patients in the paediatric age range) <sup>1</sup>. Recent proteomic platforms have analysed the human salivary proteome, characterising about 3000

differentially expressed proteins and peptides, many of them of microbiological origin<sup>2</sup>. A careful evaluation of this huge amount of data so far achievable will allow, in the near future, to tailor therapeutic interventions by assessment of thousands of parameters. Today, proteomic technologies are extremely complex, expensive and of limited accessibility. It is, however, not difficult to foresee an explosion in -omics research applications in the next years, with production of simple, inexpensive and ergonomic instruments, that can be applied to small salivary samples for early diagnosis of different pathologies. The aim of this review is to briefly describe the most salient aspects of current proteomic researches and other -omic sciences carried out on human saliva with particular regard to its potential use as a diagnostic fluid and to underline the most demanding and challenging perspectives.

### The human saliva proteome

As with any bodily fluid, whole human saliva has specific characteristics, and some recent reviews have described the distinctiveness of its proteome<sup>3,4</sup>. More than 90% in weight of the about 3,000 protein components detected in saliva<sup>5</sup> are derived from the secretion of three couples of "major" glands, parotid, sub-mandibular and sub-lingual (Sm-Sl) glands, and pertain to the classes of proline-rich proteins (PRPs; divided in acidic, basic and basic glycosylated),  $\alpha$ -amylases, mucins, salivary ("S-type") cystatins, histatins, statherin and P-B peptide. All these components and derivatives account for about 200 proteins/peptides. All the other components detected in saliva represent the remaining 10% in weight. Some of these, i.e. lipocalin, are secreted by minor glands (labial, palatine, buccal and lingual, i.e. von Ebner glands)<sup>5</sup>. Others, such as  $\alpha$ -defensins and  $\beta$ -thymosins, derive mainly from gingival crevicular fluid<sup>6,7</sup>. Human serum albumin and other plasmatic proteins are probably the products of mucosal exudates, while others are of exogenous (oral microflora) origin.

Major families of secreted salivary proteins are polymorphic, and various post-translational modifications (PTMs) occur before secretion, such as glycosylation, phosphorylation, exo- and endo-proteolytic cleavages, as reported in recent reviews<sup>1,3,8</sup>. A small percentage of histatin 1 is submitted to tyrosine sulphation<sup>9</sup>. Cystatin B is detectable mainly as S-glutathionyl and S-cysteinyl derivatives<sup>10</sup>. The most common aim of proteomic analysis is to discriminate between physiological and pathological conditions. In the presence of multiple sources, such as in the case of salivary glands, quantitative alteration of one source might be compensated by others. The composition of whole saliva varies depending on different physiological conditions. Minor glands secrete during the night spontaneously at a low rate. In daytime and at rest, movements of the tongue and lips, and mucosal dryness stimu-

late secretion, particularly by the submandibular gland (unstimulated secretion). In response to strong stimuli, parotid contributions become more dominant, with a flow-rate about twice as high as that from the submandibular gland when chewing. On the whole, the flow rate of resting as well as stimulated saliva is higher in the afternoon than in the morning, the peak occurring in the middle of the afternoon. Age is another important variable affecting the salivary proteome. Indeed, recent studies have indicated that secretion of specific peptides is noticeably different in the paediatric age with respect to adults<sup>11,12</sup>. This dynamism is challenging for proteomic investigations of human saliva<sup>3</sup> and all sources of variability must be carefully considered for choice of the proper control group. Nonetheless, because many PTMs occurring during glandular secretion are under the action of enzymes common to other exocrine and endocrine glands, qualitative and quantitative alterations may be a clue of parallel malfunctions of other exocrine and endocrine glands, and therefore a signal of systemic diseases.

### Proteomic platforms for the study of human saliva

Because a proteomic strategy able to characterise the whole saliva proteome does not exist<sup>12</sup> and many studies on the same disease have been carried out with different instruments and experimental plans, it is not surprising that different biomarkers have been proposed for the same pathology. However, different biomarkers are sometimes reported when applying similar platforms to the same pathology, generating legitimate doubts on the robustness of the experimental plan utilised, on the number of samples under study and on the choice of proper controls<sup>13</sup>. These aspects were nicely outlined in several studies<sup>14,15</sup> showing that the increased number of components under observation strongly enhances the possibility to detect variations connected to inter-individual polymorphisms. With the exception of Sjögren's syndrome, several studies carried out to detect biomarkers in the same disease have often produced inconsistent results. It is advised that an adequate number of samples are analysed that can provide highly significant statistical differences, to strictly follow identical experimental protocols for different groups of samples and to analyze them in random order. The use of ELISA methods for validation of proteomic results has also been debated<sup>12</sup>, because the antibody utilised may not have the proper selectivity to discriminate between the proteoforms connected with development of the disease.

Different classifications are available for proteomic platforms. Depending on the sample, they are first divided into bottom-up and top-down platforms. Top-down proteomics investigates the intact naturally occurring structure of a protein under examination, avoiding as much as



possible any sample alterations. Bottom-up proteomics is centered on pre-digestion of the sample (typically with trypsin) followed by the analysis of peptide fragments by high-throughput analytical methods. The presence of a protein in the sample is inferred by the detection of one or more of its specific (proteotypic) fragments, implying bi-univocal correspondence between the parent protein and its fragments<sup>12</sup>. The majority of proteins are submitted to extensive post-translational modifications, cleavages included, before reaching a mature functional structure. As a consequence, the minimalistic approach of the bottom-up strategy can result in the relevant loss of important molecular information. PTMs are difficult highlight in bottom-up shotgun experiments, where the vast majority of peptide sequences are often associated with a specific cDNA sequence, thus leveling out at a statistical level the presence of a PTM. Moreover, the association of molecular maturation events associated with the specific onset of a defined PTM will not be directly accessible by bottom-up shot-gun experiments. This defect is relevant for the proteome of human saliva, where many proteins, i.e. basic and acidic PRPs, are not very susceptible to the action of proteolytic enzymes and disclose very similar sequences. Thereby, many fragments cannot be related to a specific parent protein. Nonetheless, bottom-up platforms have shown the best throughput in terms of number of detected components. The sensitivity of new generation mass spectrometers is enough to reveal thousands of peptides in a single analysis, while the main problem is related to the increase in time necessary for the different separation steps<sup>16</sup>. Therefore, improvements in the separation platform utilised in shot-gun proteomics reflect in easier peptide detection. In this way, shot-gun proteomics covers the highest range of detectable components, regardless of their mass, because the proteolytic digestion of large proteins can almost always generate proteotypic peptides that can disclose the presence of the parent protein in a complex mixture. For these reasons, the number of salivary components currently detectable by shot-gun approaches is more than five times greater than the number of components detected by any other platform. Top-down platforms are intrinsically limited by the sample treatments necessary for coupling with mass spectrometry (typically treatment with formic acid or trifluoroacetic acid), which inevitably excludes proteins that are insoluble in acidic solution. Moreover, intact high-molecular weight proteins and heterogeneous glycosylated proteins are not accessible, in their naturally occurring forms, even to the best high-level MS apparatus. Platforms based on 2-D-electrophoresis are affected by poor reproducibility and to avoid bias it is often necessary to run multiple replica of the same sample. The results obtainable by MALDI-TOF-MS are strongly dependent on the formation of the matrix layer. Therefore, any proteomic platform has advantages and

drawbacks. For all the above reported reasons, the best way to carry out a robust biomarker identification is to analyse an adequate number of samples with different proteomic methodologies, even though this possibility is not accessible to the majority of laboratories<sup>12,15</sup>.

## Human saliva as diagnostic body fluid

Several excellent reviews have recently been published outlining the possibility to use saliva as a diagnostic fluid<sup>17-19</sup>. As a consequence, we will report only some of the most recent research carried out in the last three years, apologising for relevant omissions. More than 90% of oral cancers are oral squamous cell carcinoma (OSCC). Many patients are diagnosed with the tumour at a late state with poor prognosis and low survival rate; early diagnosis of OSCC is thus urgent problem for clinicians. Many recent proteomic studies have been devoted to the search for early salivary biomarkers of OSCC and other oral cancers. The results obtained add further information to numerous previous studies on this topic, which have suggested 17 up-regulated protein biomarkers<sup>17</sup>. Among these, interleukins 6, 8 and 1 $\beta$ , cyclin D1 thioredoxin and profiling 1 seem to be the most promising. The proteome of saliva from three groups of patients (healthy controls, individuals with potentially malignant disorders (OPMD) and OSCC patients) was investigated by SDS-PAGE coupled to LC-MS/MS. In the control, OPMD and OSCC groups 958, 845 and 1030 salivary proteins were detected, respectively. By label free quantification, 22 overexpressed proteins were detected in the OSCC group. Among these, resistin (RETN) was validated by ELISA thus confirming proteomic data. RETN levels had significant correlation with late-stage primary tumours, advanced overall stage and lymphnode metastasis<sup>20</sup>. The same group used a spectral counting-based label free quantification platform to identify 64 protein candidates for OSCC<sup>21</sup>. Retrieving mRNA expression from public-domain based transcriptome data sets, they were able to reduce the number of potential candidates to 19. Among these, thrombospondin-2 was identified as the best biomarker because higher levels were associated with a higher overall pathological state, positive perineural invasion and poorer prognosis<sup>21</sup>. Using nano-LC-MS/MS and validation by Western blot and ELISA, Jou et al.<sup>22</sup> were able to identify S100A8 as a potential biomarker of OSCC. High level of S100A8 appeared in 3.4, 13.9, 92.9 and 100% of saliva of OSCC patients with T1, T2, T3 and T4 stages, respectively. The AUROC curve indicated high sensitivity, specificity and accuracy of S100based ELISA as a detector. A comparative 2-D electrophoretic analysis of whole saliva of patients with OSCC (n = 12) and healthy controls (n = 12) was able to identify  $\alpha$ 1-antitrypsin (AAT), haptoglobin  $\beta$  chains (HAP), complement C3, haemopexin and transthyretin as potential OSCC biomarkers, which were

validated by ELISA. In particular, a strong association of ATT and HAP with OSCC was further supported by immunochemical staining of cancer tissues<sup>23</sup>. A targeted proteomic strategy applying a MS selected reaction monitoring (SRM) assay to 14 OSCC candidate biomarker proteins suggested that AAT, complement C3, 4B, factor B, and leucine-rich  $\alpha$ -2-glycoprotein are associated with increased risk to develop OSCC<sup>24</sup>.

Using an affinity-based depletion method to eliminate amylase and albumin coupled to high-resolution MS, Sivadasan et al.<sup>25</sup> were able to identify 1256 salivary proteins and to update the salivary proteome to 3449 proteins, 806 of which were differentially expressed in oral cancer tissues<sup>25</sup>. The authors provide a list of 139 proteins along with their proteotypic peptides, which might serve as a reference for targeted investigations as secretory markers for clinical applications in oral malignancies. A study carried out with a 2D-PAGE platform and Western blot validation identified (among 880 spots, corresponding to 151 different gene products) galectine-7 as a good salivary biomarker for OSCC, with a specificity of 90% and a sensitivity of 80.5% ( $n = 10$ )<sup>26</sup>. The search for early biomarkers of OSCC was also carried out with transcriptomic and metabolomic platforms and some articles have reviewed these topics<sup>18,27</sup>. A metabolomic study carried out with uHPLC coupled to Q-TOF MS on whole saliva from 37 OSCC patients, 32 patients with oral leukoplakia (OLK) and 34 healthy subjects showed characteristic metabolic signatures for the three groups. A panel of five metabolites (phenylalanine, valine, n-eicosanoid acid, lactic acid and  $\gamma$ -aminobutyric acid) was selected by statistical methods. After evaluation of the predictive power of the five metabolites, the authors established that valine, lactic acid and phenylalanine in combination yielded satisfactory accuracy (0.89 and 0.97), sensitivity (86.5% and 94.6%), specificity (82.4% and 84.4%) and positive predictive value (81.6% and 87.5%) in distinguishing OSCC from controls and OLK, respectively<sup>28</sup>. A similar metabolomic study carried out with hydrophilic interaction chromatography (HILIC) coupled to TOF-MS on whole saliva of OSCC patients identified five potential biomarkers: propionylcholine, N-acetyl-L-phenylalanine, sphinganine, phytosphingosine and S-carboxymethyl-L-cysteine. Their combination yielded satisfactory accuracy (0.977), sensitivity (100%) and specificity (96.7%) in distinguishing early stage of OSCC from controls<sup>29</sup>.

Recent research has suggested that potential biomarkers in other cancer types may be present in human saliva. A study carried out by nano-HPLC-Q-TOF MS investigated the proteome profiles of plasma and saliva of patients with fibroadenoma ( $n = 10$ ), infiltrating ductal carcinoma ( $n = 10$ ) and healthy controls ( $n = 8$ ). The major differentially expressed proteins in the saliva of patients compared with controls were  $\alpha$ 2-macroglobulin and ceruloplasmin, which should be further validated as potential

biomarkers of impalpable breast lesions<sup>30</sup>. A differential proteomic analysis using tandem mass tags technology was performed to characterise potential salivary biomarkers for gastric cancer detection. More than 500 proteins were identified and quantified, and three were successfully verified by ELISA, namely cystatin B, triose-phosphate isomerase and a protein called “deleted in malignant tumor 1 protein”. The combination of these three biomarkers could reach 85% sensitivity and 80% specificity for the detection of gastric cancer with accuracy of 0.93<sup>31</sup>. A 2D-electrophoretic analysis coupled off-line with MS identification of the tryptic digest of the spots identified 22 proteins selectively expressed in patients with oral leukoplakia<sup>32</sup>. Immunohistochemical validation suggested that keratin 10 was an interesting potential biomarker of OLK and should be further investigated. A transcriptomic platform identified five mRNA biomarkers (CCNI, EGFR, FGF19, FRS2 and GREB1) that after logistic regression model can differentiate lung cancer patients from normal subjects<sup>33</sup>.

The proteome of saliva seems to have the potential to discriminate many other diseases. Two groups have investigated whole human saliva to find potential signatures in oral chronic graft-versus-host-disease (cGVHD), a severe immunological complication occurring after allogeneic haematopoietic stem cell transplantation<sup>34,35</sup>. A LC-MS/MS study observed a reduction of salivary lactoperoxidase, lactotransferrin and several proteins included in the cysteine proteinase inhibitor family suggesting impaired oral antimicrobial host immunity in cGVHD patients<sup>34</sup>. Another study performed utilising iTRAQ labeling followed by HPLC-ESI-MS/MS and ELISA validation showed decreased expression of IL-1 receptor antagonist and cystatin B in saliva of patients with active oral cGVHD. ROC analysis revealed that these two markers were able to distinguish oral cGVHD with a sensitivity of 85% and specificity of 60%<sup>35</sup>.

Many proteomic studies in the past were devoted to the characterisation of salivary biomarkers of Sjögren’s syndrome (pSS) and this topic has been reviewed in depth<sup>36-38</sup>. A recent study investigated the expression of thymosins  $\beta$ 4 and  $\beta$ 10 in patients with pSS and in patients with autoimmune diseases: systemic sclerosis [SSc], systemic lupus erythematosus [SLE] and rheumatoid arthritis [RA], with and without sicca syndrome [ss]. This research showed that higher salivary T $\beta$  expression characterised patients with pSS, while T $\beta$ <sub>4</sub> sulfoxide and T $\beta$ <sub>10</sub> salivary expression were selectively present in patients with sicca symptoms, suggesting a different role for T $\beta$ <sub>4</sub> and T $\beta$ <sub>10</sub> in patients with pSS who have ss and other autoimmune disease<sup>39</sup>. A metabolomic analysis of saliva from patients with pSS carried out with a GC-MS platform was able to detect a total of 88 metabolites, 41 of which were observed at reduced levels in samples from pSS patients. The reduced presence of glycine, tyrosine, uric acid and

fucose observed might reflect salivary gland destruction due to chronic sialoadenitis<sup>40</sup>. A top-down HPLC-ESI-MS and MS/MS platform was able to detect a signature in whole saliva of patients with synovitis, acne, pustulosis, hyperostosis and osteitis (SAPHO) syndrome, another rare, often unrecognised, rheumatological disease with prominent inflammatory cutaneous and articular symptoms characterised by musculoskeletal manifestations (synovitis, hyperostosis, osteomyelitis) associated with dermatological conditions (severe acne and pustulosis). The acidic soluble fraction of whole saliva from 10 adult women affected by SAPHO syndrome and from a group of 28 healthy women was analysed by RP-HPLC-ESI-MS and showed a significantly decreased concentration of cystatin S1 and SN, histatins, the major acidic PRPs, P-C and P-B peptides in saliva of SAPHO subjects with respect to controls. Histatins showed positive correlations with C reactive protein, cystatin S1, histatins 3, histatin 5 and a positive correlation with the neutrophil count, while histatin 3 correlated positively with total white cell count and negatively with the erythrocyte sedimentation rate. The levels and frequency of S100A12 protein showed a trend to increase in SAPHO patients, which was probably related to the inflammatory response and to the altered neutrophil responses to functional stimuli that characterize SAPHO syndrome, suggesting a possible application as a salivary biomarker<sup>41</sup>.

Proteomics of saliva can contribute to the detection of early markers of psychiatric diseases<sup>42</sup>. A recent study carried out with a top-down HPLC-ESI-MS and MS/MS platform investigated whole saliva of 32 subjects with diagnosis of schizophrenia (SZ), 17 with diagnosis of bipolar disorder (BD) and 31 healthy subjects divided in non-smokers (HN; n = 19) and smokers (HS; n = 12). Both SZ and BD revealed more than 10 fold mean increase of  $\alpha$ -defensins 1-4, S100A12, cystatin A and S-derivatives of cystatin B levels with respect to the HN and HS control groups. This study confirmed schizophrenia-associated dysregulation of an immune pathway of peripheral white blood cells and suggested that the dysregulation in the BD group could involve the activation of more specific cell type than that of SZ group<sup>43</sup>. A proteomic analysis of saliva in HIV-positive heroin addicts performed by a longitudinal HPLC-MS based quantitative platform investigated saliva samples taken from 8 HIV-positive (HIV+) and 11 -negative (HIV-) heroin addicts. In addition, saliva samples were investigated from 11 HIV- non-heroin addicted healthy controls. In the HIV+ group, 58 proteins were identified that show significant correlations with cognitive scores, implicating disruption of protein quality control pathways by HIV<sup>44</sup>.

Saliva proteome was able to detect signatures that are characteristics of genetic diseases. Whole saliva of 36 Down's syndrome subjects, divided in age groups 10-17 yr and 18-50 yr, was analysed by a top-down proteomic

approach, and the HPLC-ESI-MS profiles were compared with sex- and age-matched control groups. The main results suggested that levels of the antimicrobial  $\alpha$ -defensins 1 and 2 and histatins 3 and 5 were significantly increased in whole saliva of older Down's syndrome subjects with respect to controls and that S100A7, S100A8, and S100A12 levels were significantly increased in whole saliva of Down's syndrome subjects in comparison with controls. The increased levels of S100A7 and S100A12 may be of particular interest as a biomarker of early onset of Alzheimer's disease, which is frequently associated with Down's syndrome<sup>45</sup>. A proteomic analysis was carried out by a top-down proteomic platform on whole saliva of Wilson's disease patients. Wilson's disease is a rare inherited disorder of copper metabolism, manifesting hepatic, neurological and psychiatric symptoms. The qualitative/quantitative characterisation of the salivary proteome/peptidome of 32 Wilson's disease patients exhibited significant higher levels of S100A9 and S100A8 proteoforms, and their oxidised forms with respect to controls. Oxidation occurred on methionine and tryptophan residues, and on the unique cysteine residue, in position 42 in S100A8, and 3 in S100A9, that generated glutathionylated, cysteinylated, sulphinic, sulphonic, and disulphide dimeric forms. These findings showed that the salivary proteome of Wilson's disease patients reflected oxidative stress and inflammatory conditions characteristic of the pathology<sup>46</sup>.

A quantitative proteomic analysis based on limited protein separation within the zone of the stacking gel of the 1D SDS-PAGE and using isotope-coded synthetic peptides as internal standards was employed to study the whole saliva proteome of HIV-1 infected individuals. Expression levels of members of the calcium-binding S100 protein family and "deleted in malignant brain tumours 1 protein" were up-regulated, while that of mucin 5B was down-regulated in HIV-1 seropositive saliva samples, suggesting new perspectives for monitoring HIV-infection and understanding the mechanism of HIV-1 infectivity<sup>47</sup>. Since whole saliva contains variegate microflora, several platforms were recently developed to investigate the human salivary metaproteome. A platform combined protein dynamic range compression (DRC), multidimensional peptide fractionation and high-mass accuracy MS/MS with a two-step peptide identification method using a database of human proteins plus those translated from oral microbe genomes was recently studied. Peptides were identified from 124 microbial species. *Streptococcus*, *Rothia*, *Actinomyces*, *Prevotella*, *Neisseria*, *Veilonella*, *Lactobacillus*, *Selenomonas*, *Pseudomonas*, *Staphylococcus* and *Campylobacter* were abundant among the 65 genera from 12 phyla represented. Taxonomic diversity was broadly consistent with metagenomic studies of saliva<sup>48</sup>. A bottom-up shotgun nano-HPLC-ESI-MS platform was applied to saliva samples of 10 patients with periodontitis, 10 patients with

dental caries and 10 orally healthy individuals detecting a total of 35,664 unique peptides from 4,161 different proteins, of which 1,946 and 2,090 were of bacterial and human origin, respectively. The human protein profiles displayed significant overexpression of the complement system and inflammatory markers in periodontitis and dental caries compared to healthy controls, while bacterial proteome profiles and functional annotation were very similar in health and disease. Similar bacterial proteomes in healthy and diseased individuals suggests that the salivary microbiota predominantly thrives in a planktonic state expressing no disease-associated characteristics of metabolic activity<sup>49</sup>.

## Conclusions

Saliva is already used routinely by clinical laboratories for detection of secretory IgA antibodies, determination of salivary cortisol, hormones and for genetic purposes. However, the results of the research reported in this review suggest that in the near future human saliva will be a relevant diagnostic fluid for clinical diagnosis and prognosis. The application of holistic technologies such as proteomics and other -omic sciences to saliva should soon provide a picture of the incredible complexity of each individual, capturing his/her distinct and unique metabolic fingerprint and the pathways involved in the health/disease state transition and its reverse. Omic sciences are contributing to the identification and characterisation of salivary components, including DNA, RNA, proteins, metabolites and microorganisms. Saliva may contain real-time information describing our overall physiological condition. The -omic studies are showing that, like blood and tissue biopsies, oral fluids can be a source of biochemical data capable of detecting diseases, not only restricted to local disorders like oral cancer and Sjögren's syndrome, but systemic pathologies like genetic, autoimmune, cardiovascular and metabolic diseases as well as viral/bacterial infections and cancers. The main advantage is its easy and non-invasive collection. Moreover, several recent studies are demonstrating that the proteome of whole saliva can be divided in several subproteomes, because this body fluid derives from the contribution of different sources. The future increase of the selectivity, resolution and sensitivity of the proteomic MS-based platforms will allow proteomes deriving from these different sources to be investigated in greater detail. The metaproteomic analyses of human oral microbiota<sup>48,49</sup> are a nice example of exploitation of subproteomes of saliva for future diagnosis of infectious and opportunistic diseases. Moreover, human saliva contains extracellular vesicles<sup>50</sup> that can be easily separated and utilised for diagnosis of a large set of diseases with particular regard for cancer. Even though this topic must still be largely explored, a recent study showed the feasibility of the analysis of the subproteome

offered by oral vesicles established that it can contribute to early diagnosis and prognosis of OSCC<sup>51</sup>. Another interesting oral subproteome is constituted by gingival crevicular fluid, arising from the gingival plexus of blood vessels in the gingival corium, subjacent to the epithelium lining the dento-gingival space, as it contains a diverse population of cells, including bacteria from the adjacent plaque mass, transmigrating leucocytes and desquamated epithelial cells, which are passively washed out into the oral cavity<sup>52</sup>. Its proteome and peptidome has been already investigated<sup>52-54</sup>. This fluid could be useful for the discovery of novel periodontal disease markers<sup>55</sup>. Nonetheless, the efforts needed to reach the above aims are still demanding. An emblematic example is represented by various proteomic studies performed to find salivary biomarkers of OSCC. It is surprising that many of these studies showed little overlap. The only potential biomarkers common to several proteomic studies on OSCC were ATT and some components of the complement, which should be largely investigated to establish their sensitivity, specificity, accuracy and positive predictive value. As discussed in the previous sections, since different proteomic platforms cover different proteomes, it is not surprising that different proteomic methodologies identify different biomarkers. However, if the proteomic platforms utilised are similar, the disagreement could partly derive from the low number of patients available in different clinical centers (fortunately). Due to the medical relevance of OSCC, it seems opportune to organise a network of proteomic laboratories to share samples and results of similar pathologies and to organise multicentre research to identify biomarkers characterised by highly significant statistical parameters that can be soon transferred to routine clinical use.

## References

- 1 Tabak, LA. *A revolution in biomedical assessment: the development of salivary diagnostics*. J Dent Educ 2001;65:1335-9.
- 2 Grassl N, Kulak NA, Pichler G, et al. *Ultra-deep and quantitative saliva proteome reveals dynamics of the oral microbiome*. Genome Med 2016;8:44.
- 3 Helmerhorst EJ, Oppenheim FG. *Saliva: a dynamic proteome*. J Dent Res 2007;86:680-93.
- 4 Messana I, Inzitari R, Fanali C, et al. *Facts and artifacts in proteomics of body fluids. What proteomics of saliva is telling us?* J Sep Sci 2008;31:1948-63.
- 5 Siqueira WL, Salih E, Wan DL, et al. *Proteome of human minor salivary gland secretion*. J Dent Res 2008;87:445-50.
- 6 Pisano E, Cabras T, Montaldo C, et al. *Peptides of human gingival crevicular fluid determined by HPLC-ESI-MS*. Eur J Oral Sci 2005;113:462-8.
- 7 Inzitari R, Cabras T, Pisano E, et al. *HPLC-ESI-MS analysis of oral human fluids reveals that gingival crevicular fluid is the main source of thymosins beta 4 and beta10*. J Sep Sci 2009;32:57-63.

- <sup>8</sup> Oppenheim FG, Salih E, Siqueira WL, et al. *Salivary proteome and its genetic polymorphisms*. *Ann NY Acad Sci* 2007;1098:22-50.
- <sup>9</sup> Cabras T, Fanali C, Monteiro JA, et al. *Tyrosine polysulfation of human salivary histatin 1. A post-translational modification specific of the submandibular gland*. *J Proteome Res* 2007;6:2472-80.
- <sup>10</sup> Cabras T, Manconi B, Iavarone F, et al. *RP-HPLC-ESI-MS evidenced that salivary cystatin B is detectable in adult human saliva mostly as S-modified derivatives: S-glutathionyl, S-cysteinyl and S-S 2-mer*. *J Proteomics* 2012;75:908-13.
- <sup>11</sup> Castagnola M, Inzitari R, Fanali C, et al. *The surprising composition of the salivary proteome of preterm human newborn*. *Mol Cell Proteomics* 2011;10:M110.003467.
- <sup>12</sup> Messana I, Cabras T, Iavarone F, et al. *Unraveling the different proteomic platforms*. *J Sep Sci* 2013;36:128-39.
- <sup>13</sup> Castagnola M, Cabras T, Iavarone F, et al. *The human salivary proteome: a critical overview of the results obtained by different proteomic platforms*. *Expert Rev Proteomics* 2012;9:33-46.
- <sup>14</sup> Quintana M, Palicki O, Lucchi G, et al. *Inter-individual variability of protein patterns in saliva of healthy adults*. *J Proteomics* 2009;72:822-30.
- <sup>15</sup> Al-Tarawneh SK, Border MB, Dibble CF, et al. *Defining salivary biomarkers using mass spectrometry-based proteomics: a systematic review*. *OMICS* 2011;15:353-61.
- <sup>16</sup> Michalski A, Cox J, Mann M. *More than 100,000 detectable peptide species elute in single shotgun proteomics runs but the majority is inaccessible to data-dependent LC-MS/MS*. *J Proteome Res* 2011;10:1785-93.
- <sup>17</sup> Wang Q, Yu Q, Lin Q, et al. *Emerging salivary biomarkers by mass spectrometry*. *Clin Chim Acta* 2015;438:214-21.
- <sup>18</sup> Schafer CA, Schafer JJ, Yakob M, et al. *Saliva diagnostics: utilizing oral fluids to determine health status*. *Monogr Oral Sci* 2014;24:88-98.
- <sup>19</sup> Cuevas-Córdoba B, Santiago-García J. *Saliva: a fluid of study for OMICS*. *OMICS* 2014;18:87-97.
- <sup>20</sup> Wu CC, Chu HW, Hsu CW, et al. *Saliva proteome profiling reveals potential salivary biomarkers for detection of oral cavity squamous cell carcinoma*. *Proteomics* 2015;15:3394-404.
- <sup>21</sup> Hsu CW, Yu JS, Peng PH, et al. *Secretome profiling of primary cells reveals that THBS2 is a salivary biomarker of oral cavity squamous cell carcinoma*. *J Proteome Res* 2014;13:4796-807.
- <sup>22</sup> Jou YJ, Hua CH, Lin CD, et al. *S100A8 as potential salivary biomarker of oral squamous cell carcinoma using nanoLC-MS/MS*. *Clin Chim Acta* 2014;436:121-9.
- <sup>23</sup> Jessie K, Jayapalan JJ, Ong KC, et al. *Aberrant proteins in the saliva of patients with oral squamous cell carcinoma*. *Electrophoresis* 2013;34:2495-502.
- <sup>24</sup> Kawahara R, Bollinger JG, Rivera C, et al. *A targeted proteomic strategy for the measurement of oral cancer candidate biomarkers in human saliva*. *Proteomics* 2016;16:159-73.
- <sup>25</sup> Sivadasan P, Gupta MK, Sathé GJ, et al. *Human salivary proteome--a resource of potential biomarkers for oral cancer*. *Proteomics* 2015;127(Pt A):89-95.
- <sup>26</sup> Krapfenbauer K, Drucker E, Thurnher D. *Identification of tumour-related proteins as potential screening markers by proteome analysis-protein profiles of human saliva as a predictive and prognostic tool*. *EPMA J* 2014;5:20.
- <sup>27</sup> Bonne NJ, Wong DT. *Salivary biomarker development using genomic, proteomic and metabolomic approaches*. *Genome Med* 2012;4:82.
- <sup>28</sup> Wei J, Xie G, Zhou Z, et al. *Salivary metabolite signatures of oral cancer and leukoplakia*. *Int J Cancer* 2011;129:2207-17.
- <sup>29</sup> Wang Q, Gao P, Wang X, et al. *The early diagnosis and monitoring of squamous cell carcinoma via saliva metabolomics*. *Sci Rep* 2014;4:6802.
- <sup>30</sup> Delmonico L, Bravo M, Silvestre RT, et al. *Proteomic profile of saliva and plasma from women with impalpable breast lesions*. *Oncol Lett* 2016;12:2145-52.
- <sup>31</sup> Xiao H, Zhang Y, Kim Y, et al. *Differential proteomic analysis of human saliva using tandem mass tags quantification for gastric cancer detection*. *Sci Rep* 2016;6:22165.
- <sup>32</sup> Camisasca DR, da Rós Gonçalves L, Soares MR, et al. *A proteomic approach to compare saliva from individuals with and without oral leukoplakia*. *J Proteomics* 2017;151:43-52.
- <sup>33</sup> Zhang L, Xiao H, Zhou H, et al. *Development of transcriptomic biomarker signature in human saliva to detect lung cancer*. *Cell Mol Life Sci* 2012;69:3341-50.
- <sup>34</sup> Bassim CW, Ambatipudi KS, Mays JW, et al. *Quantitative salivary proteomic differences in oral chronic graft-versus-host disease*. *J Clin Immunol* 2012;32:1390-9.
- <sup>35</sup> Devic I, Shi M, Schubert MM, et al. *Proteomic analysis of saliva from patients with oral chronic graft-versus-host disease*. *Biol Blood Marrow Transplant* 2014;20:1048-55.
- <sup>36</sup> Castagnola M, Picciotti PM, Messana I, et al. *Potential applications of human saliva as diagnostic fluid*. *Acta Otorhinolaryngol Ital* 2011;31:347-57.
- <sup>37</sup> Chen W, Cao H, Lin J, et al. *Biomarkers for primary Sjögren's syndrome*. *Genomics Proteomics Bioinformatics* 2015;13:219-23.
- <sup>38</sup> Katsiogiannis S, Wong DT. *The proteomics of saliva in Sjögren's syndrome*. *Rheum Dis Clin North Am* 2016;42:449-56.
- <sup>39</sup> Bosello S, Peluso G, Iavarone F, et al. *Thymosin  $\beta$ 4 and  $\beta$ 10 in Sjögren's syndrome: saliva proteomics and minor salivary glands expression*. *Arthritis Res Ther* 2016;18:229.
- <sup>40</sup> Kageyama G, Saegusa J, Irino Y, et al. *Metabolomics analysis of saliva from patients with primary Sjögren's syndrome*. *Clin Exp Immunol* 2015;182:149-53.
- <sup>41</sup> Sanna M, Firinu D, Manconi PE, et al. *The salivary proteome profile in patients affected by SAPHO syndrome characterized by a top-down RP-HPLC-ESI-MS platform*. *Mol Biosyst* 2015;11:1552-62.
- <sup>42</sup> Wormwood KL, Aslebagh R, Channaveerappa D, et al. *Salivary proteomics and biomarkers in neurology and psychiatry*. *Proteomics Clin Appl* 2015;9:899-906.
- <sup>43</sup> Iavarone F, Melis M, Platania G, et al. *Characterization of salivary proteins of schizophrenic and bipolar disorder patients by top-down proteomics*. *J Proteomics* 2014;103:15-22.
- <sup>44</sup> Dominy SS, Brown JN, Ryder MI, et al. *Proteomic analysis of saliva in HIV-positive heroin addicts reveals proteins correlated with cognition*. *PLoS One* 2014;9:e89366.
- <sup>45</sup> Cabras T, Pisano E, Montaldo C, et al. *Significant modifi-*

- cations of the salivary proteome potentially associated with complications of Down syndrome revealed by top-down proteomics. Mol Cell Proteomics* 2013;12:1844-52.
- <sup>46</sup> Cabras T, Sanna M, Manconi B, et al. *Proteomic investigation of whole saliva in Wilson's disease. J Proteomics* 2015;128:154-63.
- <sup>47</sup> Zhang N, Zhang Z, Feng S, et al. *Quantitative analysis of differentially expressed saliva proteins in human immunodeficiency virus type 1 (HIV-1) infected individuals. Anal Chim Acta* 2013;774:61-6.
- <sup>48</sup> Jagtap P, McGowan T, Bandhakavi S, et al. *Deep metaproteomic analysis of human salivary supernatant. Proteomics* 2012;12:992-1001.
- <sup>49</sup> Belstrøm D, Jersie-Christensen RR, Lyon D, et al. *Metaproteomics of saliva identifies human protein markers specific for individuals with periodontitis and dental caries compared to orally healthy controls. Peer J* 2016;4:e2433.
- <sup>50</sup> Sun Y, Xia Z, Shang Z, Sun K, et al. *Facile preparation of salivary extracellular vesicles for cancer proteomics. Sci Rep* 2016;6:24669.
- <sup>51</sup> Winck FV, Prado Ribeiro AC, Ramos Domingues R, et al. *Insights into immune responses in oral cancer through proteomic analysis of saliva and salivary extracellular vesicles. Sci Rep* 2015;5:16305.
- <sup>52</sup> Pisano E, Cabras T, Montaldo C, et al. *Peptides of human gingival crevicular fluid determined by HPLC-ESI-MS. Eur J Oral Sci* 2005;113:462-8.
- <sup>53</sup> Bostanci N, Heywood W, Mills K, et al. *Application of label-free absolute quantitative proteomics in human gingival crevicular fluid by LC/MS E (gingival exudatome). J Proteome Res* 2010;9:2191-9.
- <sup>54</sup> Preianò M, Falcone D, Maggisano G, et al. *Assessment of pre-analytical and analytical variables affecting peptidome profiling of gingival crevicular fluid by MALDI-TOF mass spectrometry. Clin Chim Acta* 2014;437:120-8.
- <sup>55</sup> Tsuchida S, Satoh M, Kawashima Y, et al. *Application of quantitative proteomic analysis using tandem mass tags for discovery and identification of novel biomarkers in periodontal disease. Proteomics* 2013;13:2339-50.

Received: September 15, 2016 - Accepted: December 12, 2016

# Sialendoscopy for salivary stones: principles, technical skills and therapeutic experience

## *Il ruolo della scialoendoscopia nel trattamento delle litiasi salivari: principi di base, aspetti tecnici ed esperienza clinica*

F. CARTA<sup>1</sup>, P. FARNETI<sup>2</sup>, S. CANTORE<sup>2</sup>, G. MACRI<sup>2</sup>, N. CHUCHUEVA<sup>1,3</sup>, L. CUFFARO<sup>1</sup>, E. PASQUINI<sup>4</sup>, R. PUXEDDU<sup>1</sup>

<sup>1</sup> Department of Otorhinolaryngology, University of Cagliari, Azienda Ospedaliero Universitaria di Cagliari, Italy;

<sup>2</sup> Ear, Nose and Throat Unit of Sant'Orsola-Malpighi Hospital, Bologna, Italy; <sup>3</sup> I.M. Sechenov First Moscow State Medical University, 11991, Moscow, Russia; <sup>4</sup> Ear, Nose and Throat Metropolitan Unit - Surgical Department - AUSL Bologna, Bellaria Hospital, Bologna, Italy

All the authors contributed equally to the manuscript

### SUMMARY

*Obstructive sialadenitis is the most common non-neoplastic disease of the salivary glands, and sialendoscopy is increasingly used in both diagnosis and treatment, associated in selected cases with endoscopic laser lithotripsy. Sialendoscopy is also used for combined minimally invasive external and endoscopic approaches in patients with larger and proximal stones that would require excessively long laser procedures. The present paper reports on the technical experience from the Ear, Nose and Throat Unit of the Sant'Orsola-Malpighi Hospital of Bologna, and from the Department of Otorhinolaryngology of the University Hospital of Cagliari, Italy, including the retrospective analysis of the endoscopic and endoscopic assisted procedures performed on 48 patients (26 females and 22 males; median age 45.3; range 8-83 years) treated for chronic obstructive sialadenitis at the University Hospital of Cagliari from November 2010 to April 2016. The results from the Sant'Orsola-Malpighi Hospital of Bologna have been previously published. The technical aspects of sialendoscopy are carefully described. The retrospective analysis of the University Hospital of Cagliari shows that the disease was unilateral in 40 patients and bilateral in 8; a total of 56 major salivary glands were treated (22 submandibular glands and 34 parotids). Five patients underwent bilateral sialendoscopy for juvenile recurrent parotitis. 10 patients were treated for non-lithiasic obstructive disease. In 33 patients (68.75%) the obstruction was caused by salivary stones (bilateral parotid lithiasis in 1 case). Only 8 patients needed a sialectomy (5 submandibular glands and 3 parotids). The conservative approach to obstructive sialadenitis is feasible and can be performed either purely endoscopically or in a combined modality, with a high percentage of success. The procedure must be performed with dedicated instrumentation by a skilled surgeon after proper training since minor to major complications can be encountered. Sialectomy should be the "extrema ratio" after failure of a conservative approach.*

KEY WORDS: Sialendoscopy • Obstructive sialadenitis • Salivary glands • Lithiasis

### RIASSUNTO

*La scialoadenite cronica ostruttiva rappresenta una delle più frequenti patologie non-neoplastiche delle ghiandole salivari e la scialoendoscopia è sempre più utilizzata nella sua diagnosi e nel suo trattamento, associata o meno con la litotripsia laser. La scialoendoscopia può essere inoltre associata ad approcci esterni mini-invasivi nelle litiasi troppo voluminose per essere rimosse con un approccio unicamente endoscopico. Il presente articolo riporta l'esperienza delle Cliniche Otorinolaringoiatriche dell'Ospedale Sant'Orsola-Malpighi di Bologna e dell'Azienda Ospedaliero Universitaria di Cagliari, Italia. È stata eseguita un'analisi retrospettiva su 48 pazienti (26 femmine, 22 maschi; età media di 45,3 anni; range 8-83 anni) trattati per patologia cronica ostruttiva delle ghiandole salivari maggiori mediante procedure chirurgiche endoscopiche o combinate da novembre 2010 ad aprile 2016 presso l'Azienda-Ospedaliero-Universitaria di Cagliari. I risultati dell'Ospedale Sant'Orsola-Malpighi di Bologna erano stati precedentemente pubblicati. Gli aspetti tecnici della scialoendoscopia sono stati accuratamente descritti. I pazienti trattati presso l'Azienda Ospedaliero Universitaria di Cagliari presentavano una patologia unilaterale in 40 casi e bilaterale in 8 casi; sono state trattate 56 ghiandole salivari maggiori (22 sottomandibolari e 34 parotidi). 5 pazienti sono stati sottoposti a scialoendoscopia bilaterale per parotite ricorrente giovanile, 10 per patologia ostruttiva non litiasica e 33 (68,75%) presentavano calcoli salivari (1 paziente presentava una litiasi parotideica bilaterale). Solo 8 pazienti sono stati sottoposti a scialectomia radicale per via esterna (5 scialectomie sottomandibolare e 3 parotidectomie). La chirurgia conservativa nei pazienti con scialoadenite cronica ostruttiva appare efficace e può essere realizzata mediante un approccio puramente endoscopico o combinato, con un'alta percentuale di successo. La procedura richiede una strumentazione adeguata e deve essere eseguita da un chirurgo esperto, che abbia svolto un training specifico scialoendoscopico, in modo da evitare le possibili complicanze maggiori e minori. La scialectomia tradizionale rappresenta la "extrema ratio", limitata nei casi in cui un approccio conservativo sia risultato inefficace o controindicato.*

PAROLE CHIAVE: Scialoendoscopia • Scialoadenite ostruttiva • Ghiandole salivari • Litiasi

## Introduction

Obstructive sialadenitis is the most common non-neoplastic disease of the salivary glands<sup>1</sup>. Salivary stones are one of the main causes of chronic sialadenitis, and account for approximately 50% of major salivary gland diseases. Most salivary calculi (80%-95%) occur in the submandibular gland, whereas 5%-20% are found in the parotid gland, while the sublingual gland and the minor salivary glands account for no more than 2%<sup>1</sup>. Other aetiologies of salivary duct obstruction include strictures, mucoid debris, anatomic ductal abnormalities and scar tissue<sup>2</sup>. Initial treatment of obstructive sialadenitis is usually conservative with hydration, salivary flow stimulation, anti-inflammatory medication and antibiotics when bacterial infection is suspected. However, when initial treatment fails, further intervention is needed. The classic external approach is sialectomy with a potential incidence of injuries to the lingual and facial nerves, as well as complications such as bleeding, infection and scar<sup>3,4</sup>. The management of salivary obstruction has changed dramatically over the past 20 years<sup>5</sup>. Flexible endoscopes, thin enough to be introduced into the salivary pathway were proposed for the first time by Katz<sup>6,7</sup>; subsequently, the introduction of micro-instruments allowed for conservative minimally invasive treatment of salivary gland diseases like the removal of granulation tissue, dilatation of stenotic ducts and retrieval of stones with forceps or basket<sup>8</sup>. At the beginning, stones of more than 4 mm in diameter represented the boundaries of an endoscopic approach, but the association with extracorporeal or intracorporeal lithotripsy allowed the removal of bigger stones<sup>9,10</sup>. Nowadays, sialendoscopy is considered a beneficial technique since it is less invasive, has a lower morbidity rate compared to other techniques<sup>11</sup>, and can also be combined with *minimal* external approaches<sup>12</sup>. Combined endoscopic and external approaches can also be performed with operative microscope and intraoperative nerve monitoring (NIM) systems to reduce complications. Sialendoscopy requires a high level of dedicated experience, especially if balloon dilatation or laser lithotripsy is carried out; as a consequence, proper training is highly recommended. The present paper will review all available sialendoscopic instrumentation and techniques, and analyses the potential results attainable in diagnostic and therapeutic sialendoscopy.

## Materials and methods

The present paper is based on the technical experience from the Ear, Nose and Throat Unit of the Sant'Orsola-Malpighi Hospital in Bologna, and from the Department of Otorhinolaryngology of the University Hospital of Cagliari, Italy, including the retrospective analysis of the endoscopic and endoscopic assisted procedures per-

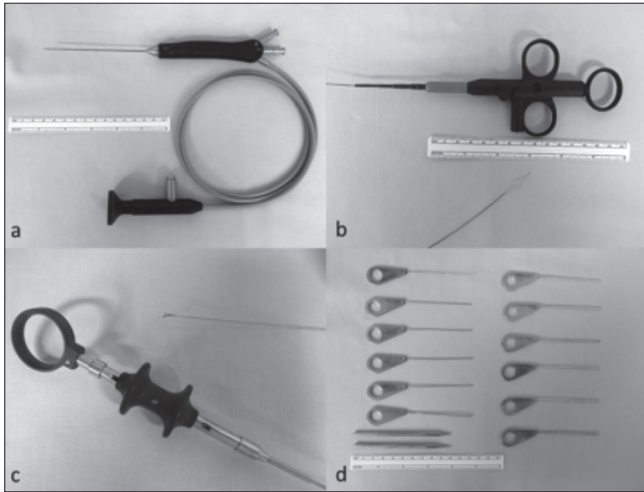
formed on 48 patients treated for chronic obstructive sialadenitis at the University Hospital of Cagliari, Italy, from November 2010 to April 2016. Patients of our early series who underwent extracorporeal lithotripsy, and those who were treated for submandibular lithiasis by a combined endoscopic and intraoral procedure with marsupialization of the duct were not considered in the present article. The results of the Sant'Orsola-Malpighi Hospital of Bologna, Italy, have been already published by Farneti et al<sup>13</sup>.

Data collected included details of patients, clinical presentation, management and outcomes.

All adult patients underwent computed tomography (CT) or magnetic resonance imaging (MRI) whereas children underwent ultrasound (US) or MRI. Sialendoscopy was always performed in patients with unclear obstructive sialadenitis, but when ductal disease was identified, such as mucous plugs, strictures or granulation tissue, sialendoscopy was converted in interventional by using sialendoscopes with operative channel, forceps, balloons, or baskets. Stones between 2 and 15 mm, and those that were impossible to retrieve using a wire basket or grasping forceps were fragmented before the endoscopic removal with intraoperative lithotripsy or removed with a combined approach.

The endoscopic approach to the salivary glands requires specific instrumentation classified in several categories: Karl Storz® and Fentex® semi-rigid sialendoscopes with a direct view at 0°. Flexible endoscopes are advantageous as it is possible to move them through ductal kinks and bends. Their use is usually atraumatic, but handling can be difficult. They are fragile, have a short lifespan and are not autoclavable<sup>14</sup>. Rigid endoscopes use a pure lens system with good optical quality and better resolution. These endoscopes have larger diameters but are more stable, and can be autoclaved. The camera is fixed directly onto the ocular attached to the endoscope, resulting in a cumbersome handling<sup>14</sup>. Semi-rigid endoscopes are a compromise between flexible and rigid instruments<sup>14</sup> and actually represent the gold standard for sialendoscopy. Handling is easier and image quality is good. Modular and compact types are available. In modular endoscopes, the optical fibres used for light and image transmission are combined into a single probe-like component. This can be used in combination with different sheaths<sup>14</sup>. Compact "all-in-one" endoscopes combine a fibre light transmission, a fibre image transmission, a working channel and an irrigation channel within one instrument (Fig. 1a). The outer tube covers, stabilises and protects all of the components, resulting in a minimum outer diameter of the whole system. The outer diameter is of paramount importance for the introduction of the scopes and its advancement inside the narrow ductal system. There are two types of compact endoscopes: the diagnostic sialendoscope with only an irrigation channel of 0.25 mm and an outer diameter of 0.9 mm, generally used for primary explora-

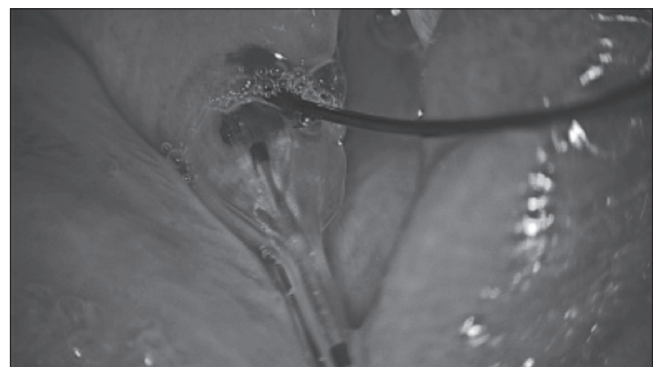




**Fig. 1.** Sialendoscopic instruments. a: *Compact semi-rigid endoscope with 0.4 mm working channel.* b: *Four wire basket.* c: *Forceps.* d: *Progressive salivary probe and conic dilator.*

tion especially in paediatric ducts or fibrous or stenotic ducts, and the operative sialendoscope, a double-lumen device with a working channel for the insertion of dedicated tools (i.e. baskets, forceps, balloons and/or laser fibres) that allows therapeutic tasks<sup>14 15</sup>. The operative endoscopes are manufactured with outer diameters of 1.1 and 1.6 mm and operative channels of 0.4 and 0.8 mm, respectively. The 0.4 mm working channel allows passage of the basket and laser probe or micro burr, while for other instruments like grasping forceps or biopsy forceps the 0.6 mm diameter is needed. To maintain the best optical quality of the endoscope, it is important to add a full high definition (HD) system. This permits to obtain higher image resolution with better details and depth of focus using filters. The camera is always correctly oriented with the endoscope in order to handle it efficiently. The Dormia baskets, which are composed of four or more wires, are used for removing stones, mucous plugs and foreign bodies; this device is activated by the surgeon. The endoluminal object must be mobile and, when captured, the surgeon can pull it out. Baskets are currently available in different sizes and the more frequent outer diameter is 0.4 mm (Fig. 1b). Forceps measuring 0.8 mm of diameter are available in two different shapes: grasping forceps with a serrated surface on the jaws, and biopsy cup forceps with sharp cutting edges that could also be used for stone fragmentation and removal (Fig. 1c)<sup>14</sup>. Drills or micro burrs have diameters from 0.38 to 0.4 mm. They could be used for stone fragmentation and dilatation of filiform or complete stenosis. An electrically powered motor system and shifter system can be especially helpful for hard stones<sup>14</sup>. In some patients, the identification of the papilla required the aid of an operative microscope (Carl Zeiss®, Germany, Microscope ZEISS S7 - focal length 250 mm). The papilla can be dilated using a set of commercially available

probes in 12 sizes of increasing diameter (from 0000 to 8 as shown in Fig. 1d) (Karl Storz®, Germany). They can be particularly useful in cases of a narrow papilla, but these instruments can easily cause a ductal perforation or a false path. Conic dilator (length 10-14 cm) should be used instead of a salivary probe for gentle dilation of the papilla with a lower risk of a ductal perforation. In the present series, papillotomy was performed in the earlier cases, and was then converted in a dilatation or by the incision of the duct proximal to the papilla in the submandibular gland. For the parotid, the papilla was always dilated. Low-pressure and high-pressure balloons are available. The former have only limited efficacy, mainly for thin membrane-like strictures, and have a high risk of rupturing. The second require a special syringe system for inflation and can be used for dilatation of lesions and strictures in the submandibular (Fig. 2) and parotid salivary ducts<sup>14</sup>. Patients with strictures were also treated without complications with the aid of an expandable off-label compliant balloon angiocatheter (Boston Scientific®) or a Lacrycath off labels non-compliant balloon (QuestFigMedical®, U.S.A.), 5 mm in diameter, after obtaining consent from the patient. In the present series, the holmium:YAG (yttrium-aluminium-garnet) laser has been routinely used for endoscopic lithotripsy. This is a pulsed, solid-state laser that produces light at a wavelength of 2.1 µm in the near-infrared region. It also has a high absorption coefficient in water, suggesting a safety advantage if used in an aqueous environment such as saliva. It creates a shock-wave when the laser is activated and the tip of the fibre is placed perpendicular to the surface of the stone. Lithotripsy is then carried on by a cavitation technique until the stone is completely fragmented<sup>9</sup>. The semi-flexible fibre with diameter of 200 or 365 µm holmium:YAG laser (Lumenis®, Israel) was used with a power of 2.5 W–3.5 W, a rate of 5 Hz/s, and energy of 0.5 J–0.7 J. Laser lithotripsy was always planned under general anaesthesia. This laser is a non dedicated tool. Sialendoscopy was also performed using the Image1 S System™ (Storz, Germany), an innovative digital post-processing technique, already described for the



**Fig. 2.** Balloon dilatation of Wharton's duct.

evaluation of mucosal precancerous lesions<sup>16</sup>, that emphasises specific colour renderings through the spectral separation of the spectral light information obtained within the camera console and enhances the appearance of recorded images by adapted colour processing algorithms, using five different defined modalities of amplifications of the images (Clara, Chroma, Clara + Chroma, Spectra A, Spectra B).

Stents are available in different shapes, lengths, diameters and materials. In the present series, at the end of the procedure, the terminal part of a suction catheter or, more recently, a salivary stent with a diameter of 1.68 mm (Schaitkin salivary duct cannula, Hood®, U.S.A.) was inserted into the duct to avoid strictures. The stent was sutured with 5/0 Prolene, and maintained for 2 weeks. Stents can be useful in the prevention of restenosis after the dilatation of ductal strictures or to avoid a papillary stenosis and secondary iatrogenic obstruction after papillotomy. Stent placements may also be helpful in the regeneration of ductal defects and in keeping a wide luminal diameter after the ductal walls are primarily closed from incision<sup>17</sup>.

External facial nerve dissection, when indicated during minimally invasive external approaches, was always performed by coupling the intraoperative microscope with the NIM (Medtronic NIM Response® 3.0 - 4 channels). Typical parameters used at our institution are: stimulus intensity of 0.5-0.7 mA, duration of the stimulus of 100 microsec, rate of stimulus of 4 bursts and event threshold of 100  $\mu$ V.

All patients were given antibiotics for 7 days postoperatively and reviewed 2 weeks postoperatively at the time of the removal of the stent, and were then followed up for a minimum of 3 months.

The literature review was based on the MEDLINE search, using "sialendoscopy", "endoscopy", "salivary glands", "lithiasis", "lithotripsy", and "holmium:YAG laser" as keywords.

## Results

Forty-eight patients treated at the University Hospital of Cagliari were included in the present study (26 females and 22 males; median age 45.3; range of 8-83 years) with a unilateral (n = 40) or bilateral (n = 8) pathology; a total of 56 major salivary glands were treated endoscopically with curative intent (22 submandibular glands and 34 parotids), for a total of 68 procedures performed.

Five patients underwent bilateral sialendoscopy for juvenile recurrent parotitis. Ten patients were treated for non-lithiasic obstructive disease: 4 patients for stenosis (1 in the submandibular gland and 3 in the parotid gland), 5 patients for chronic sialadenitis (2 in the submandibular gland and 1 in the parotid gland, bilateral chronic obstructive parotitis in 1 case, and 1 patient presented with a submandibular and contralateral parotid sialadenitis), and 1 patient underwent combined approach to the parotid, that

allowed for the precise diagnosis of sialoceles and subsequent definitive treatment in form of total parotidectomy. In 33 patients (68.75%), the obstruction was caused by stones (1 patient presented a bilateral parotid lithiasis); in 7 cases the lithiasis was associated with a simultaneous cause (kinking in 3 cases and stricture in 4 cases). In 11 patients treatment was an endoscopic surgery without the use of laser (7 in the submandibular gland and 4 in the parotid gland), 20 patients underwent holmium:YAG laser sialendoscopy (11 in the submandibular gland, 8 in the parotid gland, and 1 in the parotid gland bilaterally), and 2 patients underwent the stone removal through a combined approach on the parotid gland.

A single procedure was not effective in 12 cases. In 4 patients a second endoscopic treatment was effective to resolve a recurrence of parotid gland sialadenitis (2 patients developed recurrence of symptoms, which were immediately resolved by endoscopic dilatation, 1 patient presented with chronic sialadenitis after successful removal of salivary stones through laser sialendoscopy, requiring sialendoscopic washing of the salivary ducts and 1 patient resolved the pathology after a second holmium:YAG laser sialendoscopy associated with the balloon dilatation for a residual stone previously missing), while 8 patients underwent definitive traditional open neck sialectomy (5 submandibular sialectomies and 3 total parotidectomies): two patients with submandibular (1 case) and parotid (1 case) sialolithiasis treated during the early series, when the laser lithotripsy was not available, underwent delayed sialectomy after sialendoscopy that showed the unfeasibility of the endoscopic removal of a salivary stone. Two submandibular sialectomies were performed in patients with lithiasis after holmium:YAG laser sialendoscopy that showed the unfeasibility of the endoscopic procedure during the same general anaesthesia. Two submandibular sialectomies were performed during the same general anaesthesia after an endoscopic procedure without holmium:YAG laser that showed the unfeasibility of the conservative approach (one lithiasis associated with severe chronic inflammation, and one fibrotic stenosis). One patient, who had his parotid stone removed successfully after laser lithotripsy, developed intractable stenosis that required parotidectomy, and 1 patient needed a total parotidectomy after the diagnosis of obstructive sialoceles performed through a combined approach procedure. Five patients who underwent sialendoscopy were treated under local anaesthesia. We had one perforation of the duct due to the high-pressure saline washing that required sialectomy (submandibular). Clinical data of the entire cohort of patients are summarised in Table I. Number and size of stones according to definitive treatment are detailed in Table II. Results of procedures done from January 2009 and December 2013 at the Ear, Nose and Throat Unit of Sant'Orsola Hospital of Bologna as already published by Farneti et al.<sup>13</sup> are summarised in Table III.

**Table I.** Cohort of patients treated at the University Hospital of Cagliari.

| Case  | Sex | Age | Gland  | No. stones | Size        | Laser | Stent | Resolution of symptoms | Baloon | Recurrence | Further treatment                          |
|-------|-----|-----|--------|------------|-------------|-------|-------|------------------------|--------|------------|--|
| 1     | M   | 58  | SM     | /          | /           | -     | -     | Y                      | Y      | N          | -  |
| 2     | M   | 53  | SM     | 1          | 10          | -     | -     | N                      | -      | -          | Delayed sialectomy                         |
| 3     | M   | 40  | P      | 1          | 10          | -     | -     | N                      | -      | -          | Delayed sialectomy                         |
| 4     | F   | 8   | P      | /          | /           | -     | -     | Y                      | -      | Y          | Washing + dilatation                       |
| 5     | F   | 83  | SM     | 1          | 4           | -     | -     | Y                      | -      | N          | -  |
| 6     | F   | 26  | SM     | 1          | 4           | -     | -     | Y                      | -      | N          | -  |
| 7     | M   | 44  | SM     | 1          | 7           | Y     | Y     | Y                      | -      | N          | -  |
| 8     | F   | 34  | SM     | 1          | 8           | Y     | -     | Y                      | -      | N          | -  |
| 9     | F   | 40  | SM     | 1          | 6           | Y     | -     | Y                      | -      | N          | -  |
| 10    | F   | 38  | SM     | 1          | 10          | Y     | -     | Y                      | -      | N          | -  |
| 11    | F   | 67  | P      | 1          | 11          | Y     | Y     | Y                      | -      | N          | -  |
| 12*   | F   | 58  | P      | 3          | 4-5-7       | Y     | Y     | Y                      | -      | Y          | Washing                                    |
| 13    | F   | 30  | P Bil. | /          | /           | -     | -     | Y                      | -      | N          | -  |
| 14    | M   | 51  | P      | 1          | 7           | Y     | -     | Y                      | Y      | Y          | Delayed sialectomy for long-term stricture |
| 15    | M   | 78  | P Bil. | 1+1        | 4-8.5       | Y     | Y     | Y                      | -      | Y          | Yag:Holmium + dilatation                   |
| 16    | M   | 12  | P Bil. | /          | /           | -     | -     | Y                      | Y      | N          | -  |
| 17    | M   | 62  | SM     | 1          | 3.5         | -     | Y     | Y                      | Y      | N          | -  |
| 18**  | M   | 69  | SM     | 1          | 15          | Y     | -     | -                      | -      | -          | Sialectomy                                 |
| 19    | F   | 19  | P      | 1          | 4           | Y     | Y     | Y                      | -      | N          | -  |
| 20    | M   | 40  | SM     | 1          | 14          | Y     | Y     | Y                      | Y      | N          | -  |
| 21    | F   | 65  | P      | 2          | 1-4         | Y     | Y     | Y                      | Y      | N          | -  |
| 22**  | M   | 45  | SM     | /          | -           | -     | -     | -                      | Y      | -          | Sialectomy                                 |
| 23    | M   | 52  | P      | /          | /           | -     | -     | Y                      | Y      | N          | -  |
| 24    | F   | 58  | P      | /          | /           | -     | -     | Y                      | Y      | Y          | Washing + dilatation                       |
| 25**  | M   | 26  | SM     | 1          | > 10        | -     | -     | -                      | -      | -          | Sialectomy                                 |
| 26    | M   | 37  | P      | 1          | 1           | -     | -     | Y                      | Y      | N          | -  |
| 27    | M   | 38  | SM     | 2          | 8-6         | Y     | Y     | Y                      | -      | N          | -  |
| 28    | M   | 37  | P      | 1          | 6           | Y     | Y     | Y                      | -      | N          | -  |
| 29    | F   | 27  | P      | 2          | 3-5         | -     | -     | Y                      | -      | N          | -  |
| 30    | F   | 19  | SM     | 2          | 1-4.5       | -     | Y     | Y                      | -      | N          | -  |
| 31    | F   | 9   | P Bil. | /          | /           | -     | -     | Y                      | -      | N          | -  |
| 32    | M   | 39  | SM     | 1          | 8           | Y     | Y     | Y                      | -      | N          | -  |
| 33**  | F   | 53  | SM     | 1          | 15          | Y     | -     | -                      | -      | -          | Sialectomy after ductal perforation        |
| 34    | F   | 42  | P      | 1          | 10          | Y     | Y     | Y                      | -      | N          | -  |
| 35    | F   | 63  | SM     | 1          | 9           | -     | Y     | Y                      | -      | N          | -  |
| 36    | F   | 63  | P + SM | /          | /           | -     | -     | Y                      | -      | N          | -  |
| 37    | F   | 9   | P Bil. | /          | /           | -     | -     | Y                      | Y      | N          | -  |
| 38    | M   | 10  | P Bil. | /          | /           | -     | -     | Y                      | -      | N          | -  |
| 39    | M   | 9   | P Bil. | /          | /           | -     | -     | Y                      | -      | N          | -  |
| 40    | F   | 56  | P      | /          | /           | -     | -     | Y                      | Y      | N          | -  |
| 41    | F   | 38  | P      | 3          | 2-4-4       | Y     | Y     | Y                      | -      | N          | -  |
| 42    | M   | 42  | SM     | 1          | 8           | Y     | Y     | Y                      | -      | N          | -  |
| 43*** | M   | 59  | P      | 1          | 11          | -     | Y     | Y                      | -      | N          | -  |
| 44    | F   | 30  | SM     | 1          | 4           | Y     | Y     | Y                      | -      | N          | -  |
| 45    | F   | 76  | P      | /          | /           | -     | Y     | Y                      | Y      | N          | -  |
| 46*** | M   | 40  | P      | 1          | 8           | -     | -     | Y                      | -      | N          | -  |
| 47    | F   | 46  | SM     | 3          | 1.8-1.8-1.8 | -     | -     | Y                      | -      | N          | -  |
| 48*** | F   | 48  | P      | /          | /           | -     | -     | N                      | -      | -          | Delayed sialectomy                         |

\*Case n. 12 had 3 stones but only the stone of 7 mm was removed after fragmentation. \*\*The sialectomy was performed after the endoscopic procedure during the same anaesthesia. \*\*\*Patients treated through a combined approach.

**Table II.** Stone dimensions.

| Groups  | No. of stones | Mean   | Range    |
|---|---------------|--------|----------|
| Stones removed through submandibular endoscopic surgery without laser | 9             | 3.5 mm | 1-9 mm   |
| Stones removed through submandibular holmium:YAG laser sialendoscopy  | 10            | 7.9 mm | 4-14 mm  |
| Stones definitively removed through submandibular sialectomy          | 4             | 2.5 mm | 10-15 mm |
| Stones removed through parotid endoscopic surgery without laser       | 5             | 3.6 mm | 1-5 mm   |
| Stones removed through parotid holmium:YAG laser sialendoscopy        | 13            | 5.6 mm | 1-11 mm  |
| Stones removed through combined approach to the parotid gland         | 2             | 9.5 mm | 8-11 mm  |
| Stones definitively removed through total parotidectomy               | 1             | 10 mm  | 10 mm    |

**Table III.** Results of procedures done from January 2009 and December 2013 at the Ear, Nose and Throat Unit of Sant'Orsola Hospital of Bologna. SM = submandibular; GA = general anesthesia; LA = local anaesthesia; CN = cranial nerve; RJP=recurrent juvenile parotitis; N/A = data not available.

| Procedures | Patients | Parotid/<br>SM | Complications   | SM<br>resection               | GA/LA  | Pathologies   | Stone<br>Removal   | Results  |
|------------|----------|----------------|---|-------------------------------|--------|---|--|--|
| 141        | 118      | 74/67          | 3 infections<br>2 basket wire breaking<br>1 transient paresis of VII CN<br>1 lingual paresthesia<br>1 distal stenosis | 3<br>of 130 glands<br>treated | 40/101 | 62 Lithiasis<br>40 Diagnostic<br>26 Stenosis<br>6 RJP<br>6 Mucous plug<br>1 Polyp | 26 Basket<br>27 Combined<br>technique<br>9 Not removed at<br>first attempt | 102 Asymptomatic<br>(72.3%)<br>37 Recurrence of<br>symptoms (26.3%)<br>2 N/A data (1.4%) |

## Discussion

Sialendoscopic techniques are relatively new and are increasingly used in the management of non-neoplastic diseases of the major salivary glands. Since histopathological studies suggest that salivary glands removed for sialolithiasis have normal glandular architecture<sup>18</sup>, organ preservation should be the first goal of every treatment<sup>10</sup>, reducing the morbidity of the open surgery.

At present, US represents an excellent first-level diagnostic technique in preoperative work-up. However, Deenadayal et al. observed that US is a good modality with high sensitivity for lithiasis, but it has low sensitivity in non-lithiasic obstructions<sup>19</sup>. In our series, the majority of patients were investigated through CT to exclude or confirm the presence of stones and to assess their precise dimensions and number. Furthermore, CT is routinely requested by the surgeon to precisely locate the stone.

Sialendoscopy alone is nowadays part of the main diagnostic tools, improving the sensitivity of traditional imaging approaches<sup>19</sup>. It offers an additional advantage due to its therapeutic action in dilating the salivary ducts with high-pressure saline solution, washing and, consequently, treating moderate stenosis and strictures. Sialendoscopy is indicated for diagnosis of sialolithiasis, stenosis, foreign bodies, polyps, recurrent sialadenitis and sialadenosis<sup>15</sup>. The basic surgical procedure is divided in three steps: location of the papilla and introduction of the sialendoscope, diagnosis (from main duct to third or fourth salivary division branches) and therapeutic steps<sup>20</sup>.

The identification of the papilla can be difficult. Therefore, magnifying loupes or a microscope can be helpful. The visibility of the papilla can be enhanced with the massage

of the gland with one hand until the leak of saliva makes it more visible; this technique can be improved by using sialagogues like ascorbic acid or lemon juice<sup>21</sup>. Lidocaine hydrochloride 10 g/100 ml spray should be used as a local anaesthetic. The natural papilla diameter is about 0.5 mm<sup>22</sup>, and its dilation is thus necessary to allow the access of the endoscope through the duct, and can be performed with different methods. The "classic technique" is realised by dilating the papilla with progressive salivary probes<sup>23</sup>. A conic dilatator can be useful to maximise the dilatation of the ducts at the end of the procedure. It can also be used at the first instance when the papilla is easily detectable to avoid lesions of the duct, which are more frequent with progressive salivary probes. The "guided puncture technique" begins with the introduction of the probe of smaller diameter 0000 that is successively replaced from a guide in titanium of same diameter (principle of Seldinger)<sup>24</sup>. A conical dilator is introduced on this guide to expand the papilla progressively. The dilator is then removed and the endoscope is introduced using the guide through the working channel. The guide is removed when a ductal image is correctly obtained. When the papilla is not easily localised, a "surgical" less conservative technique can be performed as described by Nahlieli<sup>25</sup>. An incision is made at the level of the oral pelvis parallel to the axis of the duct, looking for it carefully on the medial aspect of the sublingual gland. Once detected the duct, it is necessary to open it for 1 mm to allow insertion of the endoscope without losing pressure during irrigation. This technique is reserved when an atraumatic approach is not possible for papillary hypertrophy, papillary stenosis or extremely small ductal orifices. The as-

sistant's role is fundamental: it is necessary to provide a correct visualisation of the surgical field and to support the surgeon in managing operative instruments.

After the introduction of the tip of the endoscope, the ductal system is dilated by continuous irrigation with 0.9% saline solution using 20 or 50 mL syringes to avoid the collapse of the duct<sup>26</sup>. When the procedure is performed under local anaesthetic, irrigation should start using 2% lidocaine hydrochloride. Additionally, irrigation helps to remove debris, such as fibrin or small stone fragments. The diagnostic step permits exploration of the entire ductal system from the main duct to the secondary and third/fourth branches. The duct must be pulled with no traumatic peri-papillary traction to make the duct assume a rectilinear shape that facilitates its exploration<sup>20</sup>. This step can be best performed using small diagnostic 0.8 mm endoscopes that can easily follow the duct and the smaller branches, and show possible pathological findings (i.e. stones, stenosis, ductal inflammation). The main difficulties found during the exploration of specific tracts of the salivary tracts include: at the "comma area" of Wharton's duct, where the duct turns inferiorly at the posterior border of the mylohyoid muscle, in the area posterior to the curvature of the Stensen's duct (around the masseter muscle), and when the duct passes through the buccinator muscle<sup>25</sup>.

Sialendoscopy can be both diagnostic and therapeutic in the same procedure, while other imaging techniques, even if minimally invasive, can be useful only for diagnosis<sup>27</sup>. The therapeutic step of sialendoscopy can target the cause of the obstructive sialadenitis. Sialendoscopy alone or with mucous plug removal, is generally enough to resolve juvenile recurrent parotitis, as observed in the literature and in our series (5 cases)<sup>28,29</sup>. Symptoms of chronic sialadenitis, Sjögren's syndrome and radiation-induced sialadenitis (either after external radiation therapy or as a sequela of radioactive iodine treatment for thyroid carcinoma) are generally improved through washing and dilatation<sup>30,31</sup>.

Management of stenosis or other anatomic malformations often requires endo-luminal dilation, which can be easily achieved with high-pressure balloons, microdrills, forceps, or simply with a larger endoscope<sup>27</sup>. Sionis et al.<sup>32</sup> showed that non-compliant balloon offers steady dilatation of the duct with only minor disruption of the epithelium, this confirmed histologically after dilatation of the Wharton's duct on 4 cadavers. In this experimental study, the use of a 6-mm non-compliant balloon was feasible and safe in a conservative approach to the Wharton's duct without risking the rupture of the wall. In our series, endoscopic procedures for non-lithiasic diseases were effective in 86.7% of patients (13/15), and 90.1% of salivary glands (20/22): 1 patient underwent submandibular sialectomy for a severe stricture of the Wharton's duct, and 1 patient needed definitive sialectomy after diagnosis of parotid sialoceles during an endoscopic assisted procedure.

In literature sialolithiasis is the most frequent cause of chronic obstructive sialadenitis<sup>1</sup> (in our series, 68.75% of patients were treated for salivary stones). The removal of distal stones (proximal to the papilla) of the submandibular gland is possible through a minimal-invasive non-endoscopic intraoral approach with no major complications. The trans-oral removal of the stone could be coupled with the operating microscope, and the lithiasis can be retrieved through the papilla after dilatation or by incising the duct at the level of the stone. The role of the endoscopic approach to lithiasis of major salivary glands has been detailed in a recent Italian consensus by Gallo et al.<sup>15</sup>.

*Distal duct/papilla.* If there are mobile ductal stones < 5 mm, sialendoscopy with basket retrieval may be the first attempt, and papillotomy may be necessary; if the stones are impacted, transoral duct slitting is generally performed before interventional sialendoscopy.

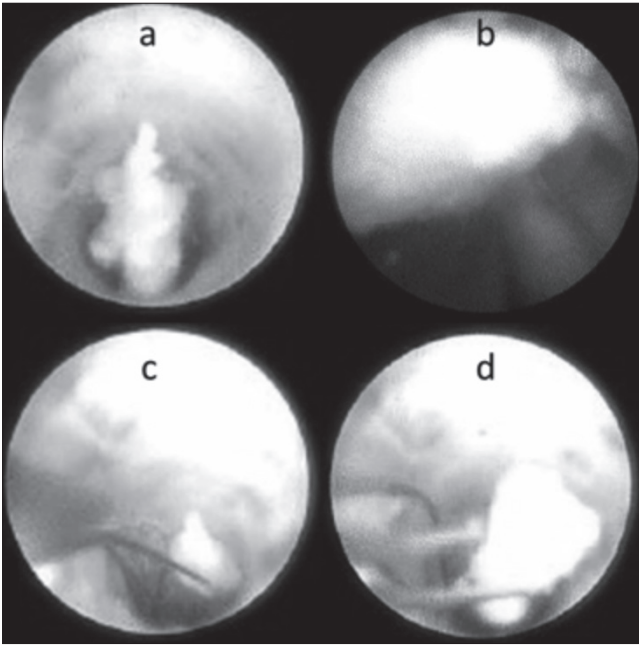
*Proximal duct/hilum.* In case of small, mobile stones < 5 mm attempting to remove the stone with a wire basket or grasping forceps is indicated; if stones are > 7 mm and palpable, a transoral duct incision or combined endoscopic-guided removal can be performed if fragmentation tools are not available.

*Intraparenchymal.* Mobile stones < 7 mm can be removed via interventional sialendoscopy if they are impacted; stones > 7 mm up to 10 mm can be fragmented allowing endoscopic removal.

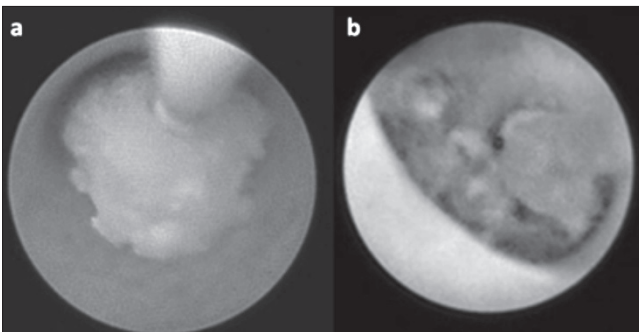
When a ductal stenosis is associated with the lithiasis, it is also possible to dilate a stenotic duct by using an expandable balloon catheter, as observed in 5 patients of our series.

Stones less than 5 mm with regular contour (round or oval) and with its major axis perpendicular to main duct are the most simple to extract: simply using the basket that is placed behind the stone, opening it (entrapping the stone) and then gently retracting it (Fig. 3).

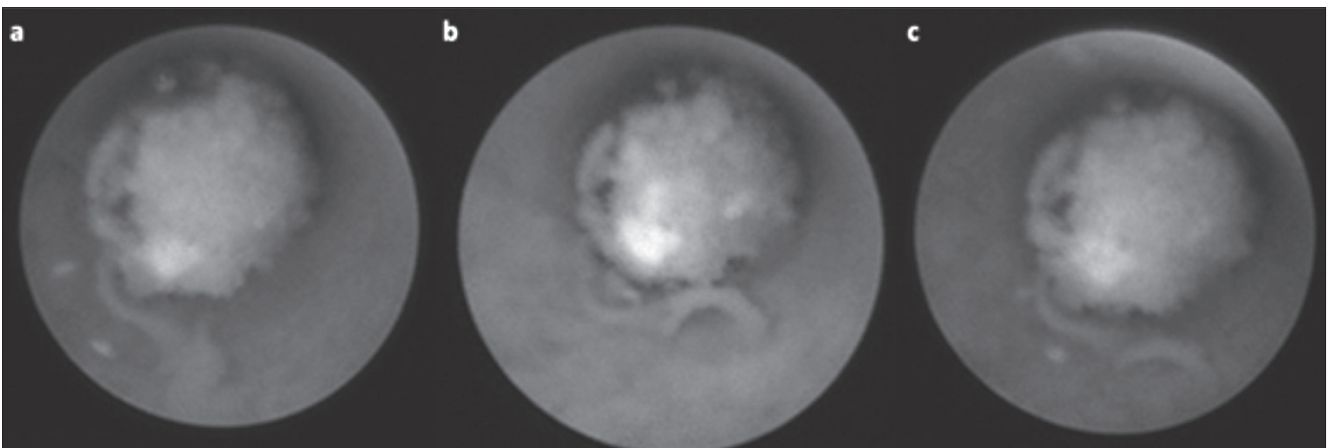
The classic main limitation for sialendoscopy in sialolithiasis is the size of the stone, but the different techniques described for stone fragmentation (external lithotripsy, electrohydraulic, piezoelectric, electromagnetic and pneumoblastic lithotripsy, holmium:YAG lithotripsy)<sup>9,33-36</sup> allow to treat even larger stones through a conservative endoscopic approach. Sialolithotripsy is a non-invasive method of fragmenting salivary stones into smaller portions to favour their flushing out from the salivary duct system spontaneously or after salivation induced by citric acid or other sialogogues<sup>2</sup>. The shock-waves may be generated extra-corporeal using piezoelectric and electromagnetic techniques or intracorporeal using laser or pneumatic endoscopic devices. The main limitation of extracorporeal lithotripsy is that it often leaves stone fragments inside the duct system<sup>18</sup>. Piezoelectric technique exploits the pressure wave produced in water by the expansion of crystals due to the application of voltage. The crystals are placed on a concave disk that converges the wave on a 3 mm area



**Fig. 3.** Stone removal with basket. a: Stone in the salivary duct. b: Positioning of the basket behind stone. c: Opening of the basket. d: Entrapment of the stone.



**Fig. 4.** Endoscopic view of a parotid stone before (a) and after (b) holmium:YAG laser fragmentation.



**Fig. 5.** Endoscopic view of a ductal stones with the following different modalities of amplifications of the Image1 S System™ images: White Light (a), Spectra A (b), Spectra B (c).

to a depth of 11 mm<sup>37</sup>. In the electromagnetic technique, the ultrasound-guided shock-wave is generated by a small-diameter, cylindrical, electromagnetic source, and focuses on the salivary stones by means of a parabolic reflector within the cushion. The pulse frequency of the wave may vary from 0.5 to 2 Hz and no more than 4000 shock-waves may be administered per session. Continuous sonographic monitoring allows direct visualisation of the degree of fragmentation during treatment and avoids lesions to the surrounding tissues<sup>38</sup>. Intracorporeal laser lithotripsy includes different devices distinguished according to laser or pneumatic energy. Different lasers with a large variety of diameters and connectors are available from multiple manufacturers and only bare fibres are used. Fibres are fragile and should not be angularly bent<sup>14</sup>. A holmium:YAG laser is compatible with a conventional silica fibre, making it suitable for both endoscopic and percutaneous use. A pulsed dye laser has shown efficacy and low morbidity, as the high energy delivered is not absorbed by tissues. Unfortunately, its high cost and specificity for salivary stones make it unaffordable for a single referral centre<sup>39</sup>. An erbium laser emits a wavelength that coincides with the highest water absorption peak, thus providing this laser with unique characteristics in a variety of surgical applications. Hollow metal wave guides optimised for an Er:YAG laser were end-sealed with a polished sapphire rod of 0.63 mm, designed to adapt to the laser and the endoscope. Raif et al. described 5 stones fully fragmented and 7 prepared for extraction by mini-forceps out of 21 stones treated with this technique<sup>40</sup>. The thulium YAG laser was demonstrated to be effective in stone fragmentation with a low rate of complications (12.7% ductal perforations reported by Durbec et al.)<sup>41</sup>. A pneumatic lithotripter permits the fragmentation of the stone through a CO<sub>2</sub> gas-driven system. The mechanical shock is transmitted through the tip of the instrument probe directly to the stone and is atraumatic to the surrounding tissues.

In the present series, endoscopic lithotripsy was always performed with a holmium:YAG laser (20 patients, 21 salivary glands) (Fig. 4). This tool allowed to fragment and remove larger stones with minimal complications and to extract the stones after a single procedure in 16 of 21 cases (76.2%), a second endoscopic procedure was necessary to resolve the pathology in 2 cases (9.5%): in 1 case endoscopic washing was necessary to remove mucous plugs, while a second laser holmium:YAG lithotripsy was necessary in 1 case to remove a residual stone. As a consequence, only 3 of 21 salivary glands treated with sialendoscopic removal after lithotripsy (14.3%) required a definitive sialectomy. Parotid stones treated by holmium:YAG laser lithotripsy (mean delivered energy of 0.11 kJ) were between 1 and 11 mm in size (mean 5.6 mm), larger than parotid stones removed through endoscopy without fragmentation (1-5 mm in size, mean 3.6 mm). In our series we did not experience any perforation of the ductal system due to laser. In our experience, sialendoscopy was also coupled with Image1 S Systems to allow better discrimination between stones and the wall of the duct (Fig. 5). After all therapeutic procedures, a final exploration of all the branches of the salivary duct is appropriate to detect any other associated pathologies.

Sialendoscopy can be done under local or general anaesthesia as a one-day procedure, and preserves the gland with recovery of function and without risk of damage to nerves, all without an external incision. In the present series, most cases were treated under general anaesthesia since endoscopic lithotripsy can result in a prolonged and painful procedure for the continuous irrigation and dilation of the ductal system, while in the series of Farneti et al. general anaesthesia was used in 28.4% of cases<sup>13</sup>.

Proximal salivary gland stones with a diameter between 8 and 11 mm were also managed through a sialendoscope-assisted procedure, a minimal invasive technique for identification and external removal of impacted parotid lithiasis. Identification of the stone is made using a 1.1 mm-sialendoscope and the stone can be removed through a minimal facial-lift skin incision (Fig. 6). After the incision, the duct is identified under microscopic view. Facial nerve branches that can cross the hilum and the duct are identified with the aid of a nerve stimulator with minimal exposure of the wall of the duct, allowing stone extraction and Stensen's duct microsuture (Fig. 7), without complications.

According to the literature, sialendoscopy is an effective procedure in 79-86.4% of cases<sup>42,43</sup>. Adverse events after sialendoscopy are unusual and not severe<sup>10</sup>. However, the accidental tearing of the ductal wall can potentially lead to extravasation of the irrigation solution and debris during sialendoscopy, with consequent neck swelling, airway obstruction, or deep neck abscesses<sup>32,10</sup>. In case of partial success or failure of minimal-invasive procedures, sialectomy still remains a valid option<sup>10</sup>.

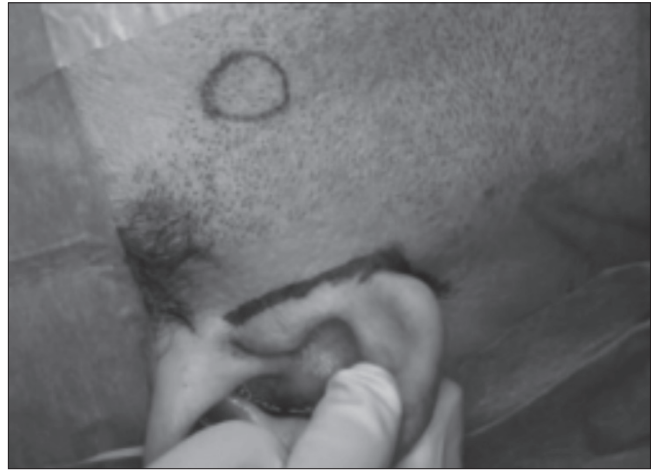

Fig. 6. Minimal facial-lift skin incision for a right parotid stone.

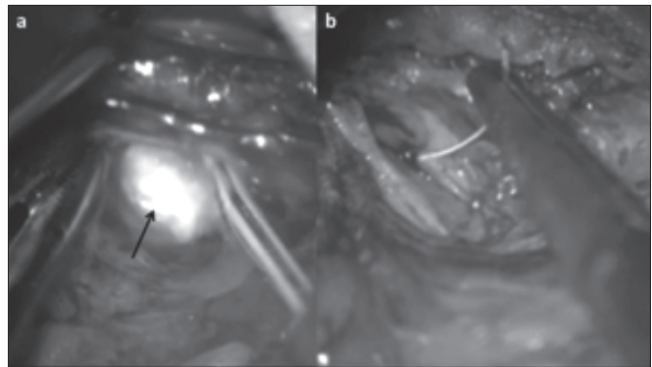


Fig. 7. Parotid stone (arrow) extraction (a) and Stensen's duct suture (b).

## Conclusions

Gland preservation should be considered whenever feasible, especially in patients with parotid gland disease. Sialendoscopy allows for endoscopic visualisation of the ductal system and its development is fundamental for a surgical minimal invasive approach to obstructive sialadenitis, which is a remarkable improvement in otolaryngology and readily available for the benefit of patients. This technique has the great advantage of identifying and removing the most common causes of obstruction in the same procedure. The widespread diffusion of this endoscopic technique has reduced the indications for the traditional open sialectomy (no scar, no risk of facial and lingual nerve injuries). The only contraindication is acute ductal infection, temporary paraesthesia of the lingual or facial nerves, infections, oedema and ductal perforation. Maximum success can only be attained by the reasonable combination of all new minimally invasive techniques.

## References

- 1 Bodner L. *Salivary gland calculi: diagnostic imaging and surgical management*. Compendium 1993;14:572,574-6, 578 passim.

- 2 Capaccio P, Torretta S, Ottavian F, et al. *Modern management of obstructive salivary diseases*. Acta Otorhinolaryngol Ital 2007;27:161-72.
- 3 Berini-Aytes L, Gay-Escoda C. *Morbidity associated with removal of the submandibular gland*. J Craniomaxillofac Surg 1992;20:216-9.
- 4 Moeller K, Esser D, Boeger D, et al. *Parotidectomy and submandibulectomy for benign diseases in Thuringia, Germany: a population-based study on epidemiology and outcome*. Eur Arch Otorhinolaryngol 2013;270:1149-55.
- 5 McGurk M, Brown J. *Alternatives for the treatment of salivary duct obstruction*. Otolaryngol Clin North Am 2009;42:1073-85.
- 6 Katz P. *New method of examination of the salivary glands: the fiberscope*. Inf Dent 1990;72:785-6.
- 7 Katz P. *Endoscopy of the salivary glands*. Ann Radiol 1991;34:110-3.
- 8 Marchal F, Dulguerov P, Lehmann W. *Interventional sialendoscopy*. N Engl J Med 1999;341:1242-3.
- 9 Sionis S, Caria RA, Trucas M, et al. *Sialendoscopy with and without holmium:YAG laser-assisted lithotripsy in the management of obstructive sialadenitis of major salivary glands*. Br J Oral Maxillofac Surg 2014;52:58-62.
- 10 Atienza G, López-Cedrún JL. *Management of obstructive salivary disorders by sialendoscopy: a systematic review*. Br J Oral Maxillofac Surg 2015;53:507-19.
- 11 Marchal F, Dulguerov P. *Sialolithiasis management: the state of the art*. Arch Otolaryngol Head Neck Surg 2003;129:951-6.
- 12 Sun YT, Lee KS, Hung SH, et al. *Sialendoscopy with holmium:YAG laser treatment for multiple large sialolithiasis of the Wharton duct: a case report and literature review*. J Oral Maxillofac Surg 2014;72:2491-6.
- 13 Farneti P, Macrì G, Gramellini G, et al. *Learning curve in diagnostic and interventional sialendoscopy for obstructive salivary diseases*. Acta Otorhinolaryngol Ital 2015;35:325-31.
- 14 Geisthoff UW. *Technology of sialendoscopy*. Otolaryngol Clin North Am 2009;42:1001-8.
- 15 Gallo A, Benazzo M, Capaccio P, et al. *Sialendoscopy: state of the art, challenges and further perspectives*. Round Table, 101<sup>st</sup> SIO National Congress, Catania 2014. Acta Otorhinolaryngol Ital 2015;35:217-33.
- 16 Carta F, Sionis S, Cocco D, et al. *Enhanced contact endoscopy for the assessment of the neoangiogenic changes in precancerous and cancerous lesions of the oral cavity and oropharynx*. Eur Arch Otorhinolaryngol 2016;273:1895-903.
- 17 Su CH, Lee KS, Tseng TM, et al. *Post-sialendoscopy ductoplasty by salivary stent placements*. Eur Arch Otorhinolaryngol 2016;273:189-95.
- 18 Marchal F, Kurt AM, Dulguerov P, et al. *Histopathology of submandibular glands removed for sialolithiasis*. Ann Otol Rhinol Laryngol 2001;110:464-9.
- 19 Deenadayal DS, Bommakanti V. *Sialendoscopy: a review of 133 cases*. International Journal of Otolaryngology and Head & Neck Surgery 2016;5:28-33.
- 20 Lari N, Chossegros C, Thierry G, et al. *Sialoendoscopie des glandes salivaires*. Rev Stomatol Chir Maxillofac 2008;109:167-71.
- 21 Luers JC, Vent J, Beutner D. *Methylene blue for easy and safe detection of salivary duct papilla in sialendoscopy*. Otolaryngol Head Neck Surg 2008;139:466-7.
- 22 Zenk J, Zikarsky B, Hosemann WG, et al. *The diameter of the Stenon and Wharton ducts: significance for diagnosis and therapy*. HNO 1998;46:980-5.
- 23 Marchal F, Becker M, Dulguerov P, et al. *Interventional sialendoscopy*. Laryngoscope 2000;110:318-20.
- 24 Chossegros C, Guyot L, Richard O, et al. *A technical improvement in sialendoscopy to enter the salivary ducts*. Laryngoscope 2006;116:842-4.
- 25 Nahlieli O, Baruchin AM. *Sialendoscopy: three years' experience as a diagnostic and treatment modality*. J Oral Maxillofac Surg 1997;55:912-8.
- 26 Geisthoff UW. *Basic sialendoscopy techniques*. Otolaryngol Clin N Am 2009;42:1029-52.
- 27 Faure M, Boem A, Taffin C, et al. *Diagnostic and interventional sialendoscopy*. Rev Stomatol Chir Maxillofac 2005;106:250-2.
- 28 Canzi P, Occhini A, Pagella F, et al. *Sialendoscopy in juvenile recurrent parotitis: a review of the literature*. Acta Otorhinolaryngol Ital 2013;33:367-73.
- 29 Schneider H, Koch M, Künzel J, et al. *Juvenile recurrent parotitis: a retrospective comparison of sialendoscopy versus conservative therapy*. Laryngoscope 2014;124:451-5.
- 30 De Luca R, Trodella M, Vicidomini A, et al. *Endoscopic management of salivary gland obstructive diseases in patients with Sjögren's syndrome*. J Craniomaxillofac Surg 2015;43:1643-9.
- 31 Kim JW, Han GS, Lee SH, et al. *Sialoendoscopic treatment for radioiodine induced sialadenitis*. Laryngoscope 2007;117:133-6.
- 32 Sionis S, Vedele A, Brennan PA, et al. *Balloon catheter sialoplasty: a safety and feasibility pilot study*. Br J Oral Maxillofac Surg 2013;51:228-30.
- 33 Iro H, Schneider T, Nitsche N, et al. *Extracorporeal piezoelectric lithotripsy of salivary calculi. Initial clinical experiences*. HNO 1990;38:251-5.
- 34 Reimers M, Vavrina J, Schlegel C. *Results after shock wave lithotripsy for salivary gland stones*. Schweizerische medizinische Wochenschrift 1999;122S-6S.
- 35 Iro H, Nitsche N, Meier J, et al. *Piezoelectric shock wave lithotripsy of salivary gland stones: an in vitro feasibility study*. J Lithotr Stone Dis 1991;3:211-6.
- 36 Iro H, Benzel W, Gode U, et al. *Pneumatische intra-korporale Lithotripsie von Speichelsteinen: in-vitro und tierexperimentelle Untersuchungen*. HNO 1995;43:172-6.
- 37 Iro H, Zenk J, Waldfahrer F, et al. *Extracorporeal shock-wave lithotripsy of parotid stones: results of a prospective trial*. Ann Otol Rhinol Laryngol 1998;107:860-4.
- 38 Ottaviani F, Capaccio P, Rivolta R, et al. *Salivary gland stones: US evaluation in shock wave lithotripsy*. Radiology 1997;204:437-41.
- 39 Martellucci S, Pagliuca G, de Vincentiis M, et al. *Ho:Yag laser for sialolithiasis of Wharton's duct*. Otolaryngol Head Neck Surg 2013;148:770-4.
- 40 Raif J, Vardi M, Nahlieli O, et al. *An Er:YAG laser endoscopic fiber delivery system for lithotripsy of salivary stones*. Lasers Surg Med 2006;38:580-7.



- <sup>41</sup> Durbec M, Dinkel E, Vigier S, et al. *Thulium-YAG laser sialendoscopy for parotid and submandibular sialolithiasis*. *Lasers Surg Med* 2012;44:783-6.
- <sup>42</sup> Cordesmeyer R, Winterhoff J, Kauffmann P, et al. *Sialendoscopy as a diagnostic and therapeutic option for obstructive diseases of the large salivary glands-a retrospective analysis*. *Clin Oral Investig* 2015;11:1-6.
- <sup>43</sup> Meyer A, Delas B, Hibon R, et al. *Sialendoscopy: A new diagnostic and therapeutic tool*. *Eur Ann Otorhinolaryngol Head Neck Dis* 2013;130:61-5.

Received: September 15, 2016 - Accepted: December 12, 2016

Address for correspondence: Filippo Carta, Policlinico D. Casula, Department of Otorhinolaryngology, Azienda-Ospedaliero-Universitaria, University of Cagliari, School of Medicine. SS 554 km 4,500, 09124 Monserrato (CA), Italy. Tel. +39 070 51096411. E-mail: filippocarta@unica.it, pippocarta@tiscali.it

# Salivary lithotripsy in the era of sialendoscopy

## *La litotrissia salivare nell'era della scialoendoscopia*

P. CAPACCIO<sup>1</sup>, S. TORRETTA<sup>2</sup>, L. PIGNATARO<sup>2</sup>, M. KOCH<sup>3</sup>

<sup>1</sup> Department of Biomedical, Surgical and Dental Sciences; <sup>2</sup> Department of Clinical Sciences and Community Health, Fondazione IRCCS Ca' Granda Ospedale Maggiore Policlinico, Università degli Studi di Milano, Milan, Italy;

<sup>3</sup> Department of Otorhinolaryngology, Head and Neck Surgery; Friedrich Alexander University of Erlangen Nuremberg, Germany

### SUMMARY

The traditional management of obstructive salivary disorders has been replaced by minimally-invasive gland-preserving techniques including shock-wave lithotripsy, sialendoscopy, interventional radiology and endoscopically video-assisted trans-oral and cervical stone retrieval, of which sialendoscopy is considered to be the method of first choice. Primary endoscopically controlled stone extraction without prior fragmentation is only possible in 15-20% of cases; in more than 80%, fragmentation is necessary because of the size, impaction and location of the stone, or an alternative treatment such as transoral duct surgery or combined approaches are required. Moreover, about 10-20% of all stones cannot be adequately accessed by means of a sialendoscope or any alternative surgical method and, in such cases, extra-corporeal shock wave lithotripsy (ESWL) is the treatment of choice. However, in endoscopically accessible stones, ESWL is being gradually replaced by endoscopically assisted intra-corporeal techniques, including endoscopically guided laser and pneumatic intra-corporeal lithotripsy. We describe the currently most widely used techniques for salivary lithotripsy, including ESWL, and endoscopically guided laser, electrohydraulic, electrokinetic and pneumatic intra-corporeal lithotripsy, and discuss their indications given the widespread use of advanced rehabilitative sialendoscopy and combined therapeutic approaches.

**KEY WORDS:** Extracorporeal lithotripsy • Salivary gland • Sialolithiasis • Stones • Obstructive sialadenitis • Laser • Pneumatic lithotripsy

### RIASSUNTO

*Negli ultimi decenni i tradizionali approcci terapeutici alla patologia ostruttiva salivare sono stati gradualmente sostituiti da trattamenti conservativi e mini-invasivi tra cui la litotrissia salivare, la scialoendoscopia, le tecniche di radiologia interventistica e la rimozione vidoendoscopica di calcoli per via trans-orale o trans-cervicale. Tra queste tecniche la scialoendoscopia è attualmente considerata il trattamento di scelta, tuttavia la sola scialoendoscopia interventistica non preceduta da tecniche di frammentazione garantisce una completa rimozione dei calcoli salivari all'incirca nel 15-20% dei casi. Inoltre il 10-20% dei calcoli non è raggiungibile endoscopicamente o con altri approcci chirurgici. In questi casi la litotrissia salivare extracorporea rappresenta il trattamento di scelta. Nonostante ciò negli ultimi anni la litotrissia salivare extracorporea è stata gradualmente sostituita dalle tecniche di frammentazione intracorporee eseguite sotto controllo endoscopico tra cui la litotrissia salivare intracorporea laser e pneumatica video-assistita. In questo articolo verranno descritte le tecniche e le indicazioni residue alla litotrissia salivare, comprendente la litotrissia extracorporea e la litotrissia salivare intracorporea laser, elettroidraulica, elettrocinetica e pneumatica video-assistite. Verranno inoltre fornite le indicazioni residue di tali trattamenti.*

**PAROLE CHIAVE:** Litotrissia extracorporea • Ghiandola salivare • Scialolitiasi • Calcoli • Scialoadenite ostruttiva • Laser • Litotrissia pneumatica

Acta Otorhinolaryngol Ital 2017;37:113-121

### Introduction

Sialolithiasis is the main cause of obstructive salivary disease: it is detected in about two-thirds of cases, and is responsible for about 50% of all salivary gland disorders<sup>1,2</sup>. Some clinical studies have reported that the incidence of symptomatic sialolithiasis is about 60 cases per million per year in the United Kingdom, corresponding to a prevalence of 0.45%, but the prevalence may be higher as post-mortem studies suggest it affects about 1.2% of the general population<sup>3,4</sup>.

The traditional management of obstructive salivary disorders (sialadenectomy, duct dilatation and dissection, and

sialodochoplasty) has been replaced by minimally-invasive gland-preserving techniques since the observation by van den Akker and Busemann-Sokole<sup>5</sup> that salivary gland function completely recovers after stone removal. These techniques include shock-wave lithotripsy, sialendoscopy, interventional radiology and endoscopically assisted trans-oral and cervical stone retrieval, which may be used individually or combined, reduce the need for gland removal and its unpleasant complications and loss of function, and assure complete clinical recovery in more than 80% of patients<sup>6</sup>.

Shock-wave lithotripsy was one of the first to be introduced, and is probably the most standardised of the newer

techniques. Extra-corporeal shock-wave lithotripsy (ESWL) has been successfully used to treat salivary stones in a way that is similar to that used in urology and gastroenterology since the late 1980s. Shock-wave lithotripsy fragments salivary stones into smaller pieces using shock-waves generated by the change in impedance at the stone/water interface, which induces a compressive wave that spreads through the stone and an expansive wave that pits and cavitates it, thus making it more easily cleared from the salivary duct system spontaneously after sialogogue-induced salivation, or during endoscopic procedures. The shock waves may be produced extra-corporeally by piezoelectric and electromagnetic techniques, or intra-corporeally by using electro-hydraulic, pneumatic, or laser sources during interventional sialendoscopy<sup>7-15</sup>.

ESWL has many advantages (it is easy to perform, repeatable, safe, generally well-tolerated, and can be carried out on an outpatient basis without anaesthesia), but its main limitation is that the stones often cannot be completely cleared by salivary flow, and small residual fragments remaining inside the ductal system may cause recurrences. It is therefore better if any ESWL treatment is followed by sialendoscopy in order to remove all of the remnants. Other disadvantages are that it is time-consuming (it generally requires repeated 30-minute sessions at intervals of a few weeks) and is not currently approved by the US Food and Drug Administration. For these reasons, together with the cost of the equipment and its maintenance, and the rapid development of advanced interventional sialendoscopic procedures using optical miniaturisation and micro-instruments, fewer centres are now offering ESWL, which is being gradually replaced by endoscopically assisted intra-corporeal techniques for stones which are endoscopically accessible.

### Extracorporeal shockwave lithotripsy (ESWL)

ESWL was first successfully practised for the treatment of sialolithiasis in humans in 1989 by Iro<sup>16</sup> who used a device designed for renal stones after obtaining encouraging results in animal and *in vitro* studies. The dedicated instruments that have been designed since then exploit the mechanical damage to stones caused by external shock-waves generated by electromagnetic or piezoelectric sources and uninterruptedly propagated to the stone/tissue interface. At the anterior edge of the stone, some of the shock-waves are reflected and create a compressive force, and some penetrate the stone to its posterior border where they generate further compressive and tensile forces. When these forces exceed the tensile strength of the stone, it fragments but, as the forces are only generated at its anterior and posterior borders (not inside it), repeated applications are required to reach the stone's inner core. The most frequently used source of ESWL is electromagnetic (Fig. 1): an electrical impulse propagated from a

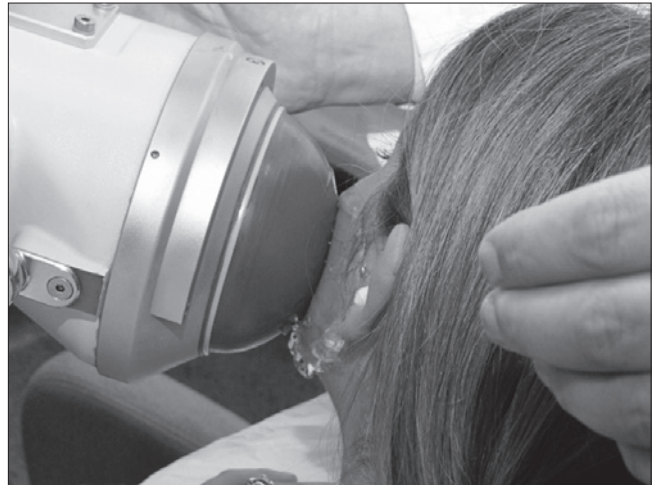

Fig. 1. Extracorporeal lithotripsy of a parotid stone.

generator to a flat coil induces a galvanic change in a nearby metal membrane, and the shock wave propagates into a water coupling medium. When a piezoelectric source is used, a pulse generator produces a high-frequency, high-voltage impulse that simultaneously stimulates all of the ceramic elements making up the piezoelectric acoustic radiator; this leads to their sudden expansion, with the generation of shock waves and their transmission through the water coupling medium.

Ultrasounds are used to focus the shock wave on the stone and continuously monitor the degree of stone fragmentation during each therapeutic session to avoid lesions to the surrounding tissues. It has also recently been suggested that a more advanced contrast-enhanced ultrasonographic diagnostic evaluation could be useful to monitor the degree of glandular vascularisation, which may indicate the presence of chronic inflammation related to sialolithiasis, and therefore be an independent and quantitative marker of the effect of treatment<sup>17</sup>.

As the minimum size of the electromagnetic focus is 2.4 mm, only stones larger than 2.4 mm in diameter are amenable to electromagnetic ESWL treatment, which generally uses a pulse frequency of 0.5-2 Hz during each session. However, although all stones with a diameter of > 2.4 mm that can be ultrasonographically detected could theoretically be managed by electromagnetic ESWL<sup>18</sup>, relative contraindications include the presence of a complete distal duct stenosis and pregnancy, the only absolute contraindication is after implantation of a cardiac pacemaker<sup>18,19</sup>. Furthermore, in the case of an endoscopically accessible proximal location or a mobile, non-embedded intraductal stone, preferable procedures are interventional sialendoscopy or endoscopically video-assisted transoral or transcutaneous stone retrieval<sup>20-24</sup>. In the event of acute sialadenitis or any other acute inflammatory process of the head and neck region, treatment should be postponed<sup>18,20</sup>. Although it is sometimes difficult to make direct com-

**Table I.** Results of electromagnetic and piezoelectric extra-corporeal shock wave lithotripsy (ESWL) in the main published studies.

|                                       | Reference                            | Site           | Success (%)  |
|---------------------------------------|--------------------------------------|----------------|--------------|
| ELECTRO-MAGNETIC ESWL                 | Wehrmann et al., 1994 <sup>8</sup>   | P+SM           | 38/73 (52)   |
|                                       | Kater et al., 1994 <sup>25</sup>     | P              | 14/29 (48)   |
|                                       |                                      | SM             | 26/75 (35)   |
|                                       |                                      | All            | 40/104 (38)  |
|                                       | Ottaviani et al., 1996 <sup>9</sup>  | P              | 9/16 (56)    |
|                                       |                                      | SM             | 15/36 (42)   |
|                                       |                                      | All            | 24/52 (46)   |
|                                       | Ottaviani et al., 1996 <sup>18</sup> | P              | 14/24 (58)   |
|                                       |                                      | SM             | 23/56 (41)   |
|                                       |                                      | All            | 37/80 (46)   |
|                                       | Escudier et al., 2003 <sup>10</sup>  | P              | 13/32 (40)   |
|                                       |                                      | SM             | 27/84 (32)   |
|                                       |                                      | All            | 40/122 (33)  |
|                                       | Capaccio et al., 2004 <sup>26</sup>  | P              | 61/88 (69)   |
|                                       |                                      | SM             | 84/234 (36)  |
|                                       |                                      | All            | 145/322 (45) |
|                                       | McGurk et al., 2005 <sup>27</sup>    | P              | 42/88 (48)   |
|                                       |                                      | SM             | 42/130 (32)  |
| All                                   |                                      | 84/218 (38)    |              |
| Eggers and Chilla, 2005 <sup>20</sup> | P                                    | 15/22 (68)     |              |
|                                       | SM                                   | 6/16 (37)      |              |
|                                       | All                                  | 21/38 (55)     |              |
| Schmitz et al., 2008 <sup>28</sup>    | P                                    | 18/59 (39)     |              |
|                                       | SM                                   | 33/126 (26)    |              |
|                                       | All                                  | 51/167 (30)    |              |
| Escudier et al., 2010 <sup>29</sup>   | P                                    | 39/64 (61)     |              |
|                                       | SM                                   | 28/78 (36)     |              |
|                                       | All                                  | 67/147 (47)    |              |
| Guerre and Katz, 2011 <sup>30</sup>   | P+SM                                 | 1056/1571 (67) |              |
| PIEZO-ELECTRIC ESWL                   | Iro et al., 1992 <sup>31</sup>       | P              | 13/16 (81)   |
|                                       |                                      | SM             | 14/35 (40)   |
|                                       |                                      | All            | 27/51 (53)   |
|                                       | Aidan et al., 1996 <sup>32</sup>     | P              | 1/3 (33)     |
|                                       |                                      | SM             | 4/12 (33)    |
|                                       |                                      | All            | 5/15 (33)    |
|                                       | Iro et al., 1998 <sup>33</sup>       | P              | 38/76 (50)   |
|                                       | Kulkens et al., 2001 <sup>34</sup>   | P              | 26/42 (62)   |
|                                       | Zenk et al., 2004 <sup>35</sup>      | SM             | 58/197 (29)  |

P: parotid; SM: submandibular.

parisons of published studies because of the different outcomes considered (e.g. symptomatic recovery, ultrasonographic stone clearance or detection of stone fragments no larger than 2 mm), when evaluated as the rate of complete stone clearance, the effectiveness of electromagnetic ESWL is 26-69% and that of piezoelectric ESWL is 29-81% (Table I)<sup>8-10 18 19 25-35</sup>; the success rate is higher in the case of parotid gland stones (electromagnetic ESWL 39-69% vs 26-42%; piezoelectric ESWL 33-81% vs. 29-40%) (Table I)<sup>8-10 18 19 25-35</sup>.

Iro et al. first reported successful fragmentation of a pa-

rotid stone<sup>16</sup> in 1992<sup>31</sup>. In 1998, a prospective trial in 76 patients with parotid stones revealed complete success (stone- and complaint-free state) in 50%, partial success in 25% (complaint-free with residual fragments) and marked improvement of symptoms in 17%<sup>33</sup>. Compared to this, worse long-term results after treatment of 191 patients with submandibular stones were reported in 2004, showing complete success in 35%, partial success in 15% (complaint-free with residual fragments)<sup>35</sup>.

In the experience of the University of Milan of about 420 patients treated since 1993, complete submandibular gland stone clearance (defined as the ultrasonographic absence of any residual stone fragment) has been achieved in 28.4% of cases with a distal location, and 48.9% of cases with a hilo-parenchymal location; the corresponding figures for the parotid gland are 70.6% and 66.7%. Ultrasonographic evidence of residual stone fragments smaller than 2 mm was observed in 25.9% of cases of distal and 27.0% of hilo-parenchymal submandibular gland stones, and in, respectively, 25.9% and 25.5% of parenchymal parotid gland stones; residual stone fragments larger than 2 mm were ultrasonographically detected in 25.2% and 44.6% of the submandibular gland stones, and 3.5% and 7.8% of the parotid gland stones<sup>36</sup>. Sialadenectomy was performed in 3.1% of patients (all with submandibular gland stones), and recurrences in the treated gland was observed in only four patients (all of whom achieved complete ultrasonographic stone clearance). Moreover, univariate and multivariate analyses of the findings relating to 322 of the 420 patients after a median follow-up period of 58 months revealed a favourable outcome in patients with parotid gland stones in any location, those with intraductal submandibular gland stones, and stones with a diameter of < 7 mm; in patients aged < 46 years; and in those receiving fewer than 2000 shock waves<sup>26</sup>. Other studies evaluating the factors influencing ESWL outcomes have confirmed that the site (parotid gland) and size of the stones are the main predictors of clearance<sup>29</sup>: the smaller the stone, the greater the probability of cure. The site-dependent cure rate may be related to anatomic conditions (i.e. the regular and relatively horizontal course of Stensen's duct), the constitution of the saliva (i.e. the predominantly serous saliva produced by the parotid gland) and practical questions such as the ease with which parotid stones can be identified and targeted ultrasonographically<sup>6</sup>. With regards to stone size, it can be speculated that smaller stones are not generally embedded within the parenchyma or ductal system because they have not had the time to produce tight adherence and can be eliminated more easily.

In the case of partial stone clearance (i.e. the stone is broken sufficiently to allow saliva to pass, but some fragments remain within the ductal system), the power of the shock waves is also important for the outcome of submandibular

gland stones. Moreover, it is not clear whether their composition affects the success of ESWL (some stones may be more resistant to shock waves than others) or whether incomplete clearance is due to the dynamics of duct salivary flow<sup>29</sup>.

Taken together, our results indicate that patients with parotid gland stones in any location, or peri-hilar or intraparenchymal submandibular gland stones of < 7 mm, may be elective candidates for ESWL.

In terms of safety, only minor, transient and self-resolving side effects have been described, including pain over the treated area (15-100%), glandular swelling (2-35%), ductal bleeding (17-71%) and cutaneous petechiae (6-55%). There have only been rare reports of acute sialadenitis (2-6%), temporary hearing impairment (2-3%), temporary tinnitus (1-2%) and loss of tooth fillings (1%)<sup>8-10 26 28 31 33 35</sup>.

### Endoscopically controlled intra-corporeal lithotripsy

The introduction of interventional sialendoscopy has revolutionised the management of sialolithiasis, leading to generally positive results in submandibular gland stones of < 4 mm and parotid gland stones of < 3 mm<sup>1</sup>. However, stones of > 4 mm and stones embedded deeply in the smallest intra-glandular ductal divisions may be treated using endoscopically controlled intra-corporeal lithotripsy.

Intra-corporeal lithotripsy exploits the shock waves generated by a lithotripsy probe that is inserted into the salivary duct system under endoscopic guidance, and directly reaches the stone's surface<sup>37</sup>. Shock wave sources include laser beams, pneumatic devices and electro-hydraulic or electrokinetic probes.

However, electro-hydraulic lithotripsy, electrokinetic lithotripsy and pneumatic lithotripsy are all modifications of kinetic or ballistic lithotripsy, and therefore associated with the potential disadvantages of mechanical tissue trauma (e.g. duct perforation) or the propulsion of stones into the proximal/intra-parenchymal duct system or paraductal tissue<sup>12 38-40</sup>.

In all forms of intra-corporeal lithotripsy, the effectiveness and duration of treatment depends first on the endoscopic accessibility, second on the size, shape and location of the stone and third on the anatomic relationships within the salivary duct system<sup>20 41 42</sup>. Regarding submandibular stones located near the mylohyoid bend, transoral duct surgery or ESWL are valid treatment alternatives and the use of intraductal lithotripsy must be weighed in every individual case or can be applied in combination with these<sup>20 41 43</sup>.

#### *Intra-corporeal electro-hydraulic lithotripsy*

Intra-corporeal electro-hydraulic lithotripsy (EHL) involves a very fast electrical discharge at the tip of a probe that provokes a local extension of plasma which, together

with the subsequent collapse of a cavitation bubble, creates abrupt micro-shock waves that indirectly lead to stone fragmentation when combined with a high-speed micro-water jet. However, although the fragmentation is sufficient, the method has the significant disadvantage that it traumatically lacerates tissue in *in vitro* experiments and animal tests, as well as during its clinical application. The high risk of iatrogenic ductal injury and the relative ineffectiveness of the procedure at reduced voltages has led to it being gradually abandoned<sup>39 44</sup>, and it is longer considered a method of choice.

The published clinical results relate to only a few patients and, as the majority of articles provide no detailed data concerning procedures, success rates or side effects, it is difficult to judge the effect/risk ratio of the technique<sup>1 11 13 45-50</sup>. It was first used in 1993 by Konigsberger, who placed a flexible endoscope and a probe supplying shock waves (Calcutript<sup>TM</sup>, Storz, Tuttlingen, Germany) 1 mm in front of the Wharton's duct stones of 29 patients (no information is given about the glands)<sup>11</sup>. Complete fragmentation was achieved in 66% of cases, but there are no numbers concerning stone/complaint-free rates. The glands were preserved in 79.3% of cases, but nothing was said about side effects. Nakyama et al.<sup>48</sup> treated a submandibular gland stone using intraductal EHL (Autolith<sup>TM</sup>, Northgate Technology, Scottsdale Court Elgin, IL, USA) and reported complete fragmentation and complete success.

#### *Intra-corporeal electrokinetic lithotripsy*

The principle underlying electrokinetic lithotripsy (EKL) is the generation of kinetic impulses by means of high-power electrical and magnetic fields that produce electromagnetic energy. The energy is transmitted to a probe that generates shock waves and impulses that are directed towards the surface of a stone.

Modayil et al.<sup>38</sup> used EKL (EKL Compact<sup>TM</sup>, Olympus, Tokyo, Japan) in one case, and obtained complete fragmentation; the patient was reported to be complaint-free. However, a significant disadvantage of EKL is that it is noisy, which has negative effects on the auditory system when applied to the head and neck region. Consequently, although EKL is effective in the case of nephrolithiasis<sup>40</sup>, techniques such as laser or pneumatic lithotripsy are currently preferred in the case of sialolithiasis.

#### *Intra-corporeal pneumatic lithotripsy*

Pneumatic lithotripsy (PL) is mainly based on releasing pneumatic energy from CO<sub>2</sub> gas, and transmitting it to a probe that directs kinetic energy to the surface of a stone. Direct contact with the stone is required to cause fragmentation. The gas can be released from a central connecting system or a cartridge (which allows greater mobility, better handling and independence from infrastructure).

The use of the technique to treat sialolithiasis was first

tested in the 1990s, but not under direct endoscopic control because no suitable mini-sialendoscopes, probes, or micro-instruments were available. The results of *in vitro* and *in vivo* trials showed that PL can be effective in treating salivary gland stones, but the observation of tissue damage due to the propulsion of fragments into the duct wall and a tendency to penetrate the surrounding tissue meant that the technique was not widely accepted at the time<sup>12</sup>.

In order to allow direct endoscopic control, it was necessary to use rigid endoscopes with a diameter of > 2 mm (which made it difficult to insert and/or manoeuvre them within the duct system); if smaller endoscopes were used, the probe could not fit in any of the working channels but had to be inserted parallel to the endoscope, which hindered effective interventional therapy. Only two later publications describe the use of PL in a few patients. Arzoz et al.<sup>13</sup> treated nine of 18 patients (Lithoclast™, EMS Swiss, Nyon, Switzerland), but did not specify the glands and, although the overall success and gland preservation rates were, respectively, 80% and 89%, they did not provide any specific data concerning the effectiveness of PL. Serbetci et al.<sup>49</sup> described treatment of two patients (no glands were specified) with Calcusplit™ (Storz, Tuttlingen, Germany); complete fragmentation and a stone-free state was achieved in one (success rate 50%).

A new, small and lightweight hand-held PL device (StoneBreaker™, Cook Medical, Bloomington, USA) became available at the end of October 2014. It has an integrated gas cartridge that makes it independent of immobile gas sources, and the pneumatic energy released by a trigger mechanism can be transmitted to the surface of a stone under direct endoscopic control by means of an exchangeable nitinol probe with a diameter of 0.56 mm (small enough to fit into the working channel) although, like all of the other methods of intraductal fragmentation, it depends on the accessibility of the stone (Fig. 2).

Koch et al. published the first description of the use of this device in the only paper that reports the results of the PL treatment of salivary stones<sup>51</sup>. They treated 49 stones (19 submandibular gland and 23 parotid gland stones) in 44

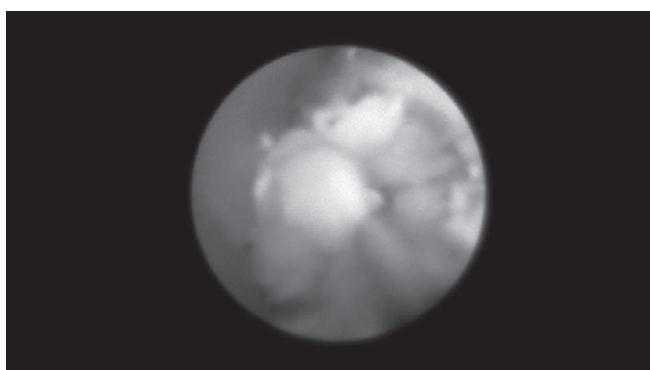
patients: 40 patients had one stone, three had two stones and one had three stones. Complete fragmentation was achieved in 98% of cases (96% of the submandibular gland stones and 100% of the parotid gland stones), and 98% of patients became stone free (100% of those with submandibular gland stones and 95% of those with parotid gland stones). All of the patients retained their glands and became complaint free. Complete success was achieved in 98% of cases (100% of the submandibular gland stones and 95% of the parotid gland stones), although five patients (11.4%) required additional treatment to achieve successful therapy: transoral duct surgery of submandibular gland stones in two cases, and ESWL in three (one submandibular and two parotid gland stones). PL seems to be indicated in the case of impacted/immobile post-hilar submandibular gland stones that are not indicated for extended transoral duct surgery. PL may be indicated in all parotid gland stones that can be accessed with a sialendoscope<sup>20 51</sup>.

Like all of the other forms of intra-corporeal lithotripsy, the effectiveness and duration of treatment depend on the size, shape and location of the stone, and the anatomic relationships of the salivary duct system<sup>20 41 42</sup>.

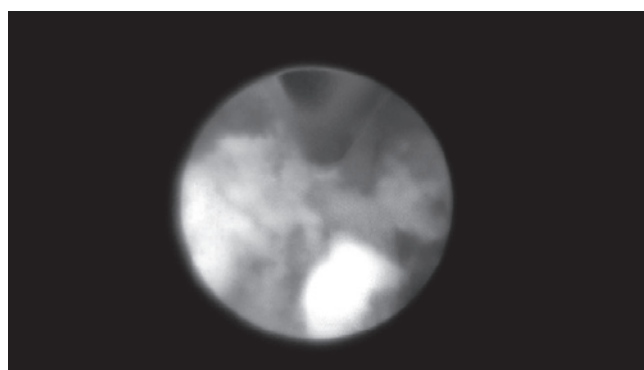
#### *Intra-corporeal laser lithotripsy*

Endoscopically controlled intra-corporeal laser lithotripsy is based on the principle that the absorption of laser pulses causes the formation of a rapidly expanding cavity of ions and electrons on the stone surface leading to high-pressure shock waves that fragment the stone. As energy absorption is material-dependent and human stones generally absorb wavelengths of 300-800 nm, moderate energy corresponding to about 20-100 mJ is generally needed to break down the stone. However, only 60% of the shock waves actually penetrate the stone, whereas about 40% are reflected from its surface and may cause thermal events<sup>52</sup> leading to ductal wall perforation, tissue damage and coagulation.

Endoscopically controlled laser lithotripsy has become a routine procedure for the fragmentation of urinary stones, and has also been used to treat sialolithiasis with positive preliminary results<sup>43 53-55</sup> (Fig. 3). It was first used to treat



**Fig. 2.** Intracorporeal pneumatic lithotripsy of a parotid stone.



**Fig. 3.** Intracorporeal laser lithotripsy of a submandibular stone.

salivary stones in 1990, when Gundlach reported 92% of stone clearance using a pulsed excimer laser<sup>55</sup>. Subsequently, Marchal and Raif & Nahlieli et al.<sup>56,57</sup> showed that holmium and erbium laser lithotripsy improved the overall rate of successful removal of complicated stones from 35% to 70% and, since then, various laser systems have been designed that use gas (e.g. excimer), liquid (e.g. dye) or solid substances (e.g. alexandrite, neodymium:yttrium-aluminum-garnet [YAG], holmium:YAG, erbium:YAG, thulium:YAG) as amplification media. However, there is a relative paucity of publications on these techniques.

The results of holmium:YAG and pulsed dye intra-corporeal laser lithotripsy have been reported in limited case series<sup>14,58</sup>: the former is associated with a high risk of soft tissue damage due to energy absorption by surrounding tissue and a thermal effect; the latter is more manageable, but very expensive<sup>52</sup>.

In the literature, the reported success rates after laser lithotripsy range from 40 to 90%<sup>58</sup>.

As shown in Table II, according to the results from recent studies the rate of successful stone extraction ranges from 81% to 100%<sup>16,43,53-55,57,59</sup>; failures are mainly due to invisible stones in stenotic or tortuous ducts<sup>59</sup>. Some recent publications reported success rates of more than 80%, most often after application of Holmium-YAG-lasera and this type of laser was positively rated in terms of its properties of fragmentation.<sup>43,53,54,60,61</sup> It is not yet known whether salivary stone composition may affect outcomes, but some experimental studies using *in vitro* models have shown that a Ho:YAG laser seems to be effective in disintegrating stones regardless of the physical and radiological characteristics<sup>62</sup>. Together with the results after clinical use of this type of laser published in recent studies and taking into account the cost-effectiveness of the method, a holmium:YAG laser seems to be the favorable alternative if laser lithotripsy is intended.

On the basis of this experience, it has been suggested that endoscopically controlled intra-corporeal laser lithotripsy could be used to remove moderately sized stones (< 7-10 mm) located within the gland itself or in the parotid duct.

The main risks of endoscopically controlled laser lithotripsy are thermal injuries to the surrounding soft tissue, vessels and nerves, and ductal wall perforation, which may occur in up to 13% of cases<sup>59</sup>. The former can be avoided by means of careful irrigation, which is also useful for stone removal; however, it is necessary to remember that strong irrigation may predispose to the development of oedema of the oral floor of the mouth and the gland tissue.

Because of the long duration of the procedure and the need for repeated passages, papilla stenosis is also possible, warranting papillotomy in a substantial proportion of the submandibular cases.

Endoscopically controlled intra-corporeal laser lithotripsy is a time-consuming procedure, particularly in the case of multiple stones, because there is a learning curve for sialendoscopy and laser lithotripsy, and the time required directly correlates with the size of the stone<sup>48</sup>.

## Conclusions

Interventional sialendoscopy is currently considered the method of first choice. Mobile stones with a size of 3-5 mm can be retrieved (primarily by means of a basket or forceps) with success rates of more than 80% if the indication is appropriate<sup>56,58,63</sup>. The literature suggests that primary endoscopically controlled stone extraction without prior fragmentation is only possible in 15-20% of stones, and more than 80% require fragmentation because of their size, impaction and location, or need to be treated by transoral duct surgery or combined approaches<sup>6,20,24,33,58,64</sup>.

Various methods of endoscopically-assisted intra-ductal fragmentation of salivary stones have been proposed in the literature with success rates of more than 80%<sup>1,11,13,15,38,44-51,53-61,65</sup>. Currently, laser and pneumatic lithotripsy are most often used and many experiences have been reported after application of a holmium:YAG laser<sup>13,15,43,45-47,49,51,53-61,65</sup>. For the 10-20% of stones that cannot be accessed using a sialendoscope or any other surgical method, ESWL is the treatment of choice and

**Table II.** Results of endoscopically controlled intra-corporeal laser lithotripsy in the main published studies.

| Reference                                | Laser type     | Site | Success (%) |
|--|----------------|------|-------------|
| Gundlach et al., 1990 <sup>55</sup>      | Pulsed excimer | SM   | 11/12 (92)  |
| Ito et al., 1996 <sup>15</sup>           | Pulsed dye     | SM   | 15/15 (100) |
| Raif et al., 2006 <sup>57</sup>          | Erbium:YAG     | SM+P | 15/18 (83)  |
| Durbec et al., 2012 <sup>59</sup>        | Thulium:YAG    | P    | 37/40 (92)  |
|  |                | SM   | 22/23 (96)  |
|  |                | All  | 59/63 (94)  |
| Martellucci et al., 2013 <sup>53</sup>   | Holmium:YAG    | SM   | 13/16 (81)  |
| Phillips and Withrow, 2014 <sup>43</sup> | Holmium:YAG    | SM+P | 13/16 (81)  |
| Sionis et al., 2014 <sup>54</sup>        | Holmium:YAG    | SM+P | 14/15 (93)  |

P: parotid; SM: submandibular.

**Table III.** Results of pneumatic lithotripsy at the University of Erlangen<sup>51</sup>.

| Parameter Mean ± SEM                                   | Total glands<br>(Patients n = 44,<br>Stones n = 49) | Submandibular<br>gland<br>(Patients n = 25,<br>Stones n = 26) | Parotid<br>gland<br>(Patients n = 19,<br>Stones n = 23) | Mann-<br>Whitney-U-<br>test |
|--|---|---|---|-----------------------------|
| Size of stone (mm)                                     | 6.75 ± 0.37   | 6.38 ± 0.32   | 7.17 ± 0.71   | n.s.                        |
| Number of<br>lithotripsies/stone (n)                   | 1.09 ± 0.07   | 1.09 ± 0.10   | 1.08 ± 0.11   | n.s.                        |
| Number of<br>shock waves/stone (n)                     | 83.43 ± 14.93                                       | 102.27 ± 22.62  | 62.13 ± 18.54   | p = 0.05                    |
| Duration of lithotripsy/stone (min.)                   | 50.51 ± 6.04  | 64.57 ± 9.11  | 34.61 ± 6.43  | p = 0.0001                  |
| Number of stones with<br>complete fragmentation (n, %) | 48/49 (97.9%)                                       | 25/26 (96%)   | 23/23 (100%)  | n.s.                        |
| Number of patients<br>stone-free (n, %)                | 43/44 (97.7%)                                       | 25/25 (100%)  | 18/19 (94.7%)   | n.s.                        |
| Number of patients<br>complaint-free (n, %)            | 44/44 (100%)  | 25/25 (100%)  | 19/19 (100%)  | n.s.                        |

can be successful in up to 80% of cases, particularly under ultrasound guidance<sup>6 23 25 30-36 41 57 65</sup>. It should finally be mentioned that a combination of extra-corporeal and intra-ductal fragmentation may further increase success rates<sup>20 23 64 65</sup>. If treatment is performed according to proven treatment algorithms, which is the case in most acknowledged salivary gland centres, the gland resection rate is clearly below 3-5%.

## References

- Marchal F, Dulguerov P, Becker M, et al. *Specificity for parotid sialendoscopy*. Laryngoscope 2001;111:264-71.
- Epker BN. *Obstructive and inflammatory diseases of the major salivary glands*. Oral Surg Oral Med Oral Pathol 1972;33:2-27.
- Rauch S, Gorlin RJ. *Diseases of the salivary glands*. In: Gorlin RJ, Goldman HM, editors. *Thoma's Oral Pathology*. 6<sup>th</sup> edition, vol 2. St Louis: Mosby; 1970. p. 997-1003.
- Brown AL, Shepherd D, Buckenham TM. *Per oral balloon sialoplasty: results in the treatment of salivary duct stenosis*. Cardiovasc Intervent Radiol 1997;20:337-42.
- Van den Akker HP, Busemann-Sokole E. *Submandibular gland function following transoral sialolithectomy*. Oral Surg Oral Med Oral Pathol 1983;56:351-6.
- Iro H, Zenk J, Escudier MP, et al. *Outcome of minimally invasive management of salivary calculi in 4,691 patients*. Laryngoscope 2009;119:263-8.
- Iro H, Schneider T, Nitsche N, et al. *Extracorporeal piezoelectric lithotripsy of salivary calculi: initial clinical experiences*. HNO 1990;38:251-5.
- Wehrmann T, Kater W, Marlinghaus EH, et al. *Shock wave treatment of salivary duct stones: substantial progress with a minilithotripter*. Clin Invest 1994;72:604-8.
- Ottaviani F, Capaccio P, Campi M, et al. *Extracorporeal electromagnetic shock-wave lithotripsy for salivary gland stones*. Laryngoscope 1996;106:761-4.
- Escudier MP, Brown JE, Drage NA, et al. *Extracorporeal shockwave lithotripsy in the management of salivary calculi*. Br J Surg 2003;90:482-5.
- Konigsberger R, Freyh J, Goetz A, et al. *Endoscopically-controlled electrohydraulic intracorporeal shock wave lithotripsy (EISL) of salivary stones*. J Otolaryngol 1993;22:12-3.
- Iro H, Benzel W, Gode U, et al. *Pneumatic intracorporeal lithotripsy of salivary stones: an in vitro and in vivo animal investigation*. HNO 1995;43:172-6.
- Arzoz E, Santiago A, Esnal F, et al. *Endoscopic intracorporeal lithotripsy for sialolithiasis*. J Oral Maxillofac Surg 1996;54:847-50.
- McGurk M, Prince MJ, Jang ZX, et al. *Laser lithotripsy: a preliminary study on its application for sialolithiasis*. Br J Oral Maxillofac Surg 1994;32:218-21.
- Ito H, Baba S. *Pulsed dye laser lithotripsy of submandibular gland salivary calculus*. J Laryngol Otol 1996;110:218-21.
- Iro H, Nitsche N, Schneider TH, et al. *Extracorporeal shock-wave lithotripsy of salivary gland stones*. Lancet 1989;2:115.
- Siedek V, Clevert DA, Rytvina M, et al. *Contrast-enhanced ultrasound for monitoring effects of extracorporeal shock wave sialolithotripsy in sialolithiasis*. Laryngoscope 2012;122:1301-5.
- Ottaviani F, Capaccio P, Rivolta R, et al. *Salivary gland stones: US evaluation in shock wave lithotripsy*. Radiology 1997;204:437-41.
- Eggers G, Chilla R. *Ultrasound guided lithotripsy of salivary calculi using an electromagnetic lithotripter*. J Oral Maxillofac Surg 2005;34:890-4.
- Koch M, Zenk J, Iro H. *Algorithms for treatment of salivary gland obstructions*. Otolaryngol Clin North Am 2009;42:1173-92.
- Makdissi J, Escudier MP, Brown JE, et al. *Glandular function after intraoral removal of salivary calculi from the hilum of the submandibular gland*. Br J Oral Maxillofac Surg 2004;42:538-41.
- McGurk M, Makdissi J, Brown JE. *Intra-oral removal of stones from the hilum of the submandibular gland: report of technique and morbidity*. Int J Oral Maxillofac Surg 2004;33:683-6.



- 23 Zenk J, Koch M, Klintworth N, et al. *Sialendoscopy in the diagnosis and treatment of sialolithiasis: a study on more than 1000 patients*. Otolaryngol Head Neck Surg 2012;147:858-63.
- 24 Witt RL, Iro H, Koch M, McGurk M, et al. *Minimally invasive options for salivary calculi*. Laryngoscope 2012;122:1306-11.
- 25 Kater W, Meyer WW, Wehrmann T, et al. *Efficacy, risks, and limits of extracorporeal shock wave lithotripsy for salivary gland stones*. J Endourol 1994;8:21-4.
- 26 Capaccio P, Ottaviani F, Manzo R, et al. *Extracorporeal lithotripsy for salivary calculi: a long-term clinical experience*. Laryngoscope 2004;114:1069-1073.
- 27 McGurk M, Escudier MP, Brown JE. *Modern management of salivary calculi*. Br J Surg 2005;92:107-12.
- 28 Schmitz S, Zengel P, Alvir I. *Long-term evaluation of extracorporeal shock-wave lithotripsy in the treatment of salivary stones*. J Laryngol Otol 2008;122:165-71.
- 29 Escudier MP, Brown JE, Putcha V, et al. *Factors influencing the outcome of extracorporeal shock wave lithotripsy in the management of salivary calculi*. Laryngoscope 2010;120:1545-9.
- 30 Guerre A, Katz P. *Extracorporeal shockwave lithotripsy (ESWL) for salivary gland stones: a retrospective study of 1571 patients*. Rev Stomatol Chir Maxillofac 2011;112:75-9.
- 31 Iro H, Schneider HT, Fodra C, et al. *Shockwave lithotripsy of salivary duct stones*. Lancet 1992; 339:1333-6.
- 32 Aidan P, De Kerviler E, LeDuc A, et al. *Treatment of salivary stones by extracorporeal lithotripsy*. Am J Otolaryngol 1996;17:246-50.
- 33 Iro H, Zenk J, Waldfahrer F, et al. *Extracorporeal shock wave lithotripsy of parotid stones. Results of a prospective clinical trial*. Ann Otol Rhinol Laryngol 1998;107:860-4.
- 34 Kulkens C, Quetz JU, Lippert BM. *Ultrasound-guided piezoelectric extracorporeal shock wave lithotripsy of parotid gland calculi*. J Clin Ultrasound 2001;29:389-94.
- 35 Zenk J, Bozzato A, Winter M, et al. *Extracorporeal shock-wave lithotripsy of submandibular stones: evaluation after 10 years*. Ann Otol Rhinol Laryngol 2004;113:378-83.
- 36 Capaccio P, Torretta S, Pignataro L. *Extracorporeal lithotripsy techniques for salivary stones*. Otolaryngologic Clin North Am 2009;42:1139-59.
- 37 Nahlieli O, Baruchin A. *Endoscopic technique for the diagnosis and treatment of obstructive salivary gland diseases*. J Oral Maxillofac Surg 1999;57:1394-401.
- 38 Modayil PC, Jacob V, Manjaly G, et al. *Intracorporeal electrokinetic lithotripsy: an advancement in minimally invasive management of parotid duct calculus*. J Laryngol Otol 2008;122:428-31.
- 39 Iro H, Zenk J, Hosemann WG, et al. *Electrohydraulic intracorporeal lithotripsy of salivary calculi. In vitro and animal experiment studies*. HNO 1993;41:389-95.
- 40 Keeley FX, Jr., Pillai M, Smith G, et al. *Electrokinetic lithotripsy: safety, efficacy and limitations of a new form of ballistic lithotripsy*. BJU International 1999;84:261-3.
- 41 Capaccio P, Torretta S, Ottaviani F, et al. *Modern management of obstructive salivary diseases*. Acta Otolaryngol Ital 2007;27:161-72.
- 42 Luers JC, Grosheva M, Stenner M, et al. *Sialoendoscopy: prognostic factors for endoscopic removal of salivary stones*. Arch Otolaryngol Head Neck Surg 2011;137: 325-9.
- 43 Phillips J, Withrow K. *Outcomes of holmium laser-assisted lithotripsy with sialendoscopy in treatment of sialolithiasis*. Otolaryngol Head Neck Surg 2014;150:962-7.
- 44 Bayar N, Kaymaz FF, Apan A, et al. *Effects of electrohydraulic extracorporeal shock wave lithotripsy on submandibular gland in the rat: electron microscopic evaluation*. Int J Ped Otolaryngol 2002;63:223-33.
- 45 Marchal F, Dulguerov P, Becker M, et al. *Submandibular diagnostic and interventional sialendoscopy: new procedure for ductal disorders*. Ann Otol Rhinol Laryngol 2002;111:27-35.
- 46 Papadaki ME, McCain JP, Kim K, et al. *Interventional sialoendoscopy: early clinical results*. J Oral Maxillofac Surg 2008;66:954-62.
- 47 Pace CG, Hwang KG, Papadaki M, et al. *Interventional sialoendoscopy for treatment of obstructive sialadenitis*. J Otol Maxillofac Surg 2014;72:2157-66.
- 48 Nakayama E, Okamura K, Mitsuyasu T, et al. *A newly developed interventional sialendoscope for a completely nonsurgical sialolithectomy using intracorporeal electrohydraulic lithotripsy*. J Oral Maxillofac Surg 2007;65:1402-5.
- 49 Serbetci E, Sengor GA. *Sialendoscopy: experience with the first 60 glands in Turkey and a literature review*. Ann Otol Rhinol Laryngol; 119:155-64.
- 50 Nahlieli O, Shacham R, Bar T, et al. *Endoscopic mechanical retrieval of sialoliths*. Oral Surg Oral Med Oral Pathol Oral Radiol Endod 2003;95:396-402.
- 51 Koch M, Mantsopoulos K, Schapher M, et al. *Intraductal pneumatic lithotripsy for salivary stones with the StoneBreaker: Preliminary experience*. Laryngoscope 2016;126:1545-50.
- 52 Mulvaney WP, Beck CW. *The laser beam in urology*. J Urol 1968;99:112-5.
- 53 Martellucci S, Pagliuca G, de Vincentiis M, et al. *Ho:Yag laser for sialolithiasis of Wharton's duct*. Otolaryngol Head Neck Surg 2013;148:770-4.
- 54 Sionis S, Caria RA, Trucas M, et al. *Sialoendoscopy with and without holmium:YAG laser-assisted lithotripsy in the management of obstructive sialadenitis of major salivary glands*. Br J Oral Maxillofac Surg 2014;52:58-62.
- 55 Gundlach P, Scherer H, Hopf J, et al. *Endoscopic-controlled laser lithotripsy of salivary calculi: in vitro studies and initial clinical use*. HNO 1990;38:247-50.
- 56 Marchal F, Becker M, Dulguerov PO, et al. *Interventional sialendoscopy*. Laryngoscope 2000;110:318-20.
- 57 Raif J, Vardi M, Nahlieli O, et al. *An Er:YAG laser endoscopic fiber delivery system for lithotripsy of salivary stones*. Lasers Surg Med 2006;38:580-7.
- 58 Marchal F, Dulguerov P. *Sialolithiasis management: the state of art*. Arch Otolaryngol Head Neck Surg 2003;129:951-6.
- 59 Durbec M, Dinkel E, Vigier S, et al. *Thulium-YAG laser sialendoscopy for parotid and submandibular sialolithiasis*. Lasers Surg Med 2012;44:783-6.
- 60 Sun YT, Lee KS, Hung SH, et al. *Sialendoscopy with holmium:YAG laser treatment for multiple large sialolithi-*

- ases of the Wharton duct: a case report and literature review.* J Oral Maxillofac Surg 2014;72:2491-6.
- <sup>61</sup> Su CH, Lee KS, Tseng TM, et al. *Endoscopic holmium:YAG laser-assisted lithotripsy: a preliminary report.* B-Ent 2015;11:57-61.
- <sup>62</sup> Schrötzlmair F, Müller M, Pongratz T, et al. *Laser lithotripsy of salivary stones: correlation with physical and radiological parameters.* Lasers Surg Med 2015;47:342-9.
- <sup>63</sup> Koch M, Zenk J, Iro H. *Diagnostic and interventional sialoscopy in obstructive diseases of the salivary glands.* HNO 2008;56:139-44.
- <sup>64</sup> Nahlieli O, Shacham R, Zaguri A. *Combined external lithotripsy and endoscopic techniques for advanced sialolithiasis cases.* J Oral Maxillofac Surg 2010;68:347-53.
- <sup>65</sup> Katz P. *New techniques for the treatment of salivary lithiasis: sialoendoscopy and extracorporeal lithotripsy: 1773 cases.* Ann Otolaryngol Chir Cervicofac 2004;121:123-32.

Received: September 15, 2016 - Accepted: December 12, 2016

# Sialendoscope-assisted transoral removal of hilo-parenchymal sub-mandibular stones: surgical results and subjective scores

## *L'asportazione transorale scialoendoscopico-assistita dei calcoli ilo-parenchimali sottomandibolari: risultati chirurgici e soggettivi*

P. CAPACCIO<sup>1,2</sup>, M. GAFFURI<sup>1</sup>, V. ROSSI<sup>1,2</sup>, L. PIGNATARO<sup>1,3</sup>

<sup>1</sup> Department of Otolaryngology and Head and Neck Surgery, Fondazione IRCCS Ca' Granda Ospedale Maggiore Policlinico, Milan, Italy; <sup>2</sup> Department of Biomedical, Surgical, Dental Sciences; <sup>3</sup> Department of Clinical Sciences and Community Health, University of Milan, Italy

### SUMMARY

It has been suggested that a conservative trans-oral approach to proximal and hilo-parenchymal submandibular stones (HPSMS) is a valid alternative to the more frequently used sialadenectomy. The aim of this study was to evaluate the surgical, ultrasonographic and patients' subjective outcomes of results of the trans-oral removal of HPSMS. Between January 2003 and September 2015, sialendoscope-assisted trans-oral surgery was used to remove symptomatic, large (> 7 mm), fixed and palpable HPSMS from 479 patients under general anaesthesia. All patients were followed clinically and ultrasonographically to investigate symptom relief and recurrence of stones, and were telephonically interviewed to assess saliva-related subjective outcomes with a questionnaire. Stones were successfully removed from 472 patients (98.5%); the seven failures (1.5%) concerned pure parenchymal stones. One year after the procedure, 408 patients (85.1%) were symptom free, 59 (12.3%) had recurrent obstructive symptoms and 12 (2.6%) had recurrent infections. Of the 54 patients who developed a recurrent stone (11.2%), 52 underwent a second procedure: 29 interventional sialendoscopies, two sialendoscope-assisted intra-corporeal pneumatic lithotripsy, eight secondary transoral surgery to remove residual stones, six a cycle of extra-corporeal lithotripsy and seven sub-mandibular sialadenectomy. Most patients (75.2%) reported mild surgery-related pain. The symptoms of 454 patients (94.8%) improved after adjunctive treatment and, at the end of follow-up, the affected gland was preserved in 98.5% of patients. A sialendoscope-assisted trans-oral removal of large HPSMS is a safe, effective, conservative surgical procedure, and functional preservation of the main duct and parenchyma of the obstructed gland allows sialendoscopic access through the natural ostium in case of recurrence. Combining a trans-oral approach with other minimally invasive, conservative procedures ensures symptomatic relief and salivary duct system clearance in the majority of patients.

**KEY WORDS:** Submandibular stones • Transoral surgery • Sialendoscopy • Submandibular sialadenectomy • Hyloparenchymal stones

### RIASSUNTO

*Come si evince dall'analisi della letteratura, l'approccio transorale ai calcoli prossimali e ilo-parenchimali della ghiandola sottomandibolare rappresenta una valida alternativa alla scialoadenectomia tradizionale. Lo scopo di questo studio è quello di valutare i risultati chirurgici, ecografici e soggettivi di questa tecnica conservativa. Tra Gennaio 2003 e Settembre 2015 sono stati trattati con l'approccio transorale scialoendoscopico-assistito 479 pazienti affetti da calcoli ilo-parenchimali sottomandibolari palpabili, non mobili, di dimensioni superiori ai 7 mm. Tutti i pazienti sono stati sottoposti ad un follow-up clinico, ecografico e ad una valutazione soggettiva dell'outcome chirurgico per mezzo di un apposito questionario somministrato attraverso un'intervista telefonica. Il successo chirurgico definito come completa asportazione del calcolo ilo-parenchimale è stato ottenuto in 472 pazienti (98.5%); in sette casi (1.5%) si è verificato un insuccesso chirurgico, riguardante esclusivamente calcoli parenchimali puri. Un anno dopo l'intervento chirurgico, 408 pazienti (85.1%) non riferivano più sintomi ostruttivi, 59 pazienti (12.3%) riferivano sintomi ostruttivi ricorrenti e 12 (2.6%) infezioni ricorrenti. Dei 54 pazienti (11.2%) affetti da litiasi sottomandibolare ricorrente, 52 sono stati sottoposti ad una seconda procedura terapeutica, nello specifico in 29 casi a scialoendoscopia, in 2 casi a litotrissia pneumatica intracorporea, in 8 casi a chirurgia transorale, in 6 casi ad un ciclo di litotrissia extracorporea, in 7 casi a scialoadenectomia sottomandibolare. La maggior parte dei pazienti (75.2%) ha riferito un dolore post-chirurgico di grado lieve. Al termine del follow-up, i sintomi riferiti da 454 pazienti (94.8%) erano migliorati dopo il secondo trattamento e la ghiandola sottomandibolare affetta era stata preservata nel 98.5% dei casi. La chirurgia transorale scialoendoscopico-assistita dei calcoli ilo-parenchimali della ghiandola sottomandibolare rappresenta un'opzione terapeutica sicura, efficace e conservativa e la preservazione del dotto e del parenchima ghiandolare permette di esplorare il sistema duttale attraverso l'ostio naturale in caso di ricorrenza della patologia. L'utilizzo combinato dell'approccio transorale e delle altre tecniche mini-invasive permette di trattare con successo la maggior parte dei pazienti affetti da litiasi ilo-parenchimale sottomandibolare.*

**PAROLE CHIAVE:** Calcoli sottomandibolari • Chirurgia transorale • Scialoendoscopia • Scialoadenectomia sottomandibolare • Calcoli ilo-parenchimali

## Introduction

Sialolithiasis accounts for about 50% of benign obstructive salivary gland diseases<sup>1</sup>, the annual symptomatic incidence of which has recently been estimated to be 1/10-30,000 subjects<sup>2</sup>.

The submandibular glands (SMGs) are the most frequently affected (80-90%)<sup>3</sup> because of the narrow opening of Wharton's duct, its ascendant course and length, and the mainly mucous composition of saliva<sup>4</sup>, and the most frequent locations of SMG stones are the distal tract of the duct and hilum (pure intraparenchymal stones account for < 10%)<sup>5</sup>. Typical symptoms are recurrent swelling and pain at mealtimes. In many cases, careful palpation of the oral floor allows the exact position of a stone to be detected, and diagnosis can be confirmed radiologically by ultrasonography (US)<sup>6</sup>, conventional radiography, computed tomography (CT) and/or cone beam tomography (CBCT)<sup>7</sup>.

Despite its known risks<sup>8</sup>, sialadenectomy is still the most widely used procedure to treat proximal and HPSMS<sup>9</sup>, but a conservative approach has emerged as a valid alternative<sup>10,11</sup>. It has been shown that trans-oral removal of large (> 7 mm) and deeply located submandibular stones<sup>10,11</sup>, the spread of which has been favoured by the development of interventional sialendoscopy, is safe and effective<sup>11</sup>, and highly successful in terms of stone removal and symptom relief<sup>6,11</sup>. A sialendoscope-assisted procedure is useful because the brightness can help in detecting any residual intraparenchymal stones after removal of the main HPSMS<sup>12</sup>, thus ensuring the complete clearance of the ductal system and eliminating symptoms of mealtime syndrome. On the basis of our previous findings<sup>11</sup>, it can be expected that only a small percentage of patients experience (often asymptomatic) stone recurrence, especially those previously treated by extra-corporeal shock wave lithotripsy (ESWL) in whom the parenchymal spread of micro-debris may not be detected by US or during surgical exploration through the oral hilo-parenchymal opening of the submandibular gland<sup>13,14</sup>.

As a surgical procedure needs to be assessed on the basis of objective surgical and subjective patient perceived results measured using validated questionnaires<sup>15</sup>, the aim of this study was to assess the surgical, US and subjective outcomes in a large series of patients who underwent trans-oral removal of a large HPSMS and who were followed in the long term.

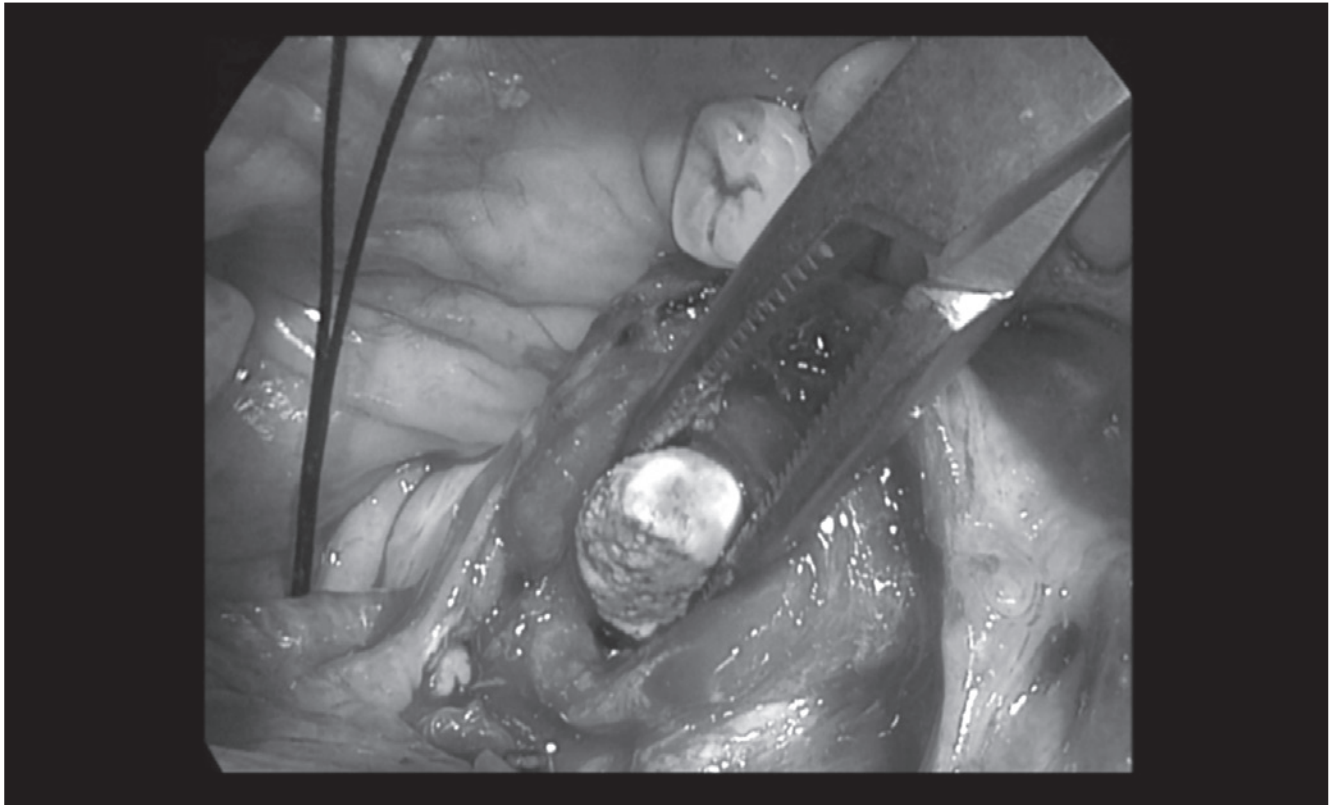
## Materials and methods

Between January 2003 and September 2015, 479 patients (235 females) with a mean age of 46 years (range 19-81) underwent sialendoscope-assisted trans-oral surgical removal of symptomatic, large (> 7 mm), fixed and palpable HPSMS at the Department of Otolaryngology and Head

and Neck Surgery of Fondazione IRCCS Ca' Granda Policlinico in Milan, 14 of whom had been previously and unsuccessfully treated by ESWL. All patients underwent US and Doppler US assessments (Hitachi H21, 7.5 MHz, Hitachi High Technology Corporation Ltd., Tokyo, Japan) and clinical evaluation to establish the size of the stone (minimum diameter 7 mm) and its location, which was clinically defined as hilar when at least two margins were detectable during bimanual palpation of the oral floor, hilo-parenchymal when only the distal margin was detectable during palpation and the remaining margins were covered by glandular tissue, and intra-parenchymal when completely covered by glandular tissue<sup>20</sup>. Exclusion criteria were an inability to open the mouth sufficiently and presence of non-palpable stones.

### *Surgical procedure*

The procedure was performed under general anaesthesia with headlight illumination and loupe magnification. With the mouth held open by a small gag, the tongue was retracted antero-medially, and the floor of the mouth was infiltrated by 5 mL of mepivacaine 25 mg/mL + adrenaline 5 µg/mL just below the oral mucosa. The duct was identified and cannulated using a salivary probe (Bowman probes, Karl Storz, Tuttlingen, Germany). An oblique incision was made near the papillary region of Wharton's duct, along the floor of the mouth toward the second molar. Once the mucosa was parted, the loose areolar tissue was dissected (first by means of sharp-tipped, and then with smooth-tipped scissors) medially to the internal edge of the sublingual gland, which was rotated laterally to expose Wharton's duct. The horseshoe-shaped lingual nerve is easily identified running obliquely from the tongue, passing under the duct, and then ascending medially through the tail of the sublingual gland over Wharton's duct to run below the constrictor muscles to the infra-temporal fossa. The lingual nerve was mobilised from the duct and retracted medially to visualise the stone in the gland hilum, which was moved upward to the submandibular gland area by external finger pressure. An incision was made over the calculus, and the stone was delivered using a micro- or Freer elevator (Martin, Tuttlingen, Germany); submandibulotomy was performed in the case of intraparenchymal stones (Fig. 1). The cavity was then irrigated with saline to clear any debris and a haemostatic and anti-microbial fibrillar surgical net (Tabotamp, Johnson & Johnson Medical Limited, Gargrave, Skipton, UK) was positioned over the hilar opening to avoid the risk of stricture or stenosis. Finally, the wound was irrigated with antibiotic solution (rifampicin), and the oral floor was sutured using resorbable stitches (3.0 Vicryl). In the case of ostial stenosis, the distal third of the duct can be rehabilitated by making an axial incision and inserting a 6F polymeric salivary stent (Optimed, Ettlingen, Germany) or a 14-20 G Venflon tube (Artsana, Grandate, Italy)



**Fig. 1.** Release of a hilo-parenchymal submandibular stone during sialendoscope-assisted transoral surgery.

attached to the oral floor with a resorbable suture, which are usually removed after two weeks.

Sialendoscopy (0.8-1.1 mm, Erlangen sialoendoscopes, Karl Storz Co., GmbH, Tuttlingen, Germany) is used to better locate the stone in the hilo-parenchymal, or to check for any residual intra-parenchymal stones or debris through the incision.

All patients received antibiotic therapy (amoxicillin and clavulanic acid) for one week after the procedure; steroids were also administered in the case of oral floor oedema.

#### *Post-operative follow-up*

Patients were clinically re-examined after one week, one month and one year to evaluate the course of wound healing and recovery of clear secretory flow from the papilla after gland massage, and any early or late post-operative complications were assessed. They were also offered US examination one year after the procedure to check the echogenicity of the glandular parenchyma and ascertain any ductal system dilation or residual stones.

All patients were telephoned to ask for saliva-related subjective outcomes using a questionnaire created to measure trans-oral surgical outcomes on the basis of the proposal of Gillespie et al.<sup>15</sup> They were asked to describe any improvement in symptoms and to grade surgery-related pain with a 0-10 visual analogue scale (VAS, in which 0 = no pain, and 10 = maximum pain). In the case of residual symptoms, the

patients were asked about any further treatments (antibiotics or surgery) and grade the average pain felt using the same scale. Finally, they were asked if they would repeat and recommend trans-oral surgery to other patients.

## **Results**

The US-measured size of stones ranged from seven to 26 mm (mean 10, median 9 mm). The stones were located in the right SMG in 223 patients (46.5%), the left SMG in 244 patients (51%), and bilaterally in 12 patients (2.5%); 233 patients (48.7%) had hilar stones, 188 (39.3%) hilo-parenchymal stones and 58 (12%) intra-parenchymal stones. The stones were successfully removed from 472 patients (98.5%); the seven failures (1.5%) concerned pure parenchymal stones that could not be detached from the gland tissue despite the parenchymal incision (Table I). Only 44 patients (9.2%) underwent a sialendoscope-assisted procedure to locate an intra-parenchymal stone more precisely through the papillary ostium, (n = 18) or check for any residual parenchymal stones through the hilar opening (n = 26). No intra-operative complications were encountered.

Early sequelae were observed in 365 patients (76.1%) (Table II). These consisted of transient gland swelling (n = 125), variable swelling and oedema of the mouth floor (n = 122), tingling of the tip of the tongue (n = 108)

**Table I.** Demographic and clinical characteristics of patients undergoing the sialendoscope-assisted trans-oral surgical removal of hilo-parenchymal stones.

|                                      | n   | %    |
|--------------------------------------|-----|------|
| <b>Gender</b>                        |     |      |
| Male                                 | 244 | 50.9 |
| Female                               | 235 | 49.1 |
| <b>Previous treatments</b>           |     |      |
| None                                 | 465 | 97.1 |
| Shock wave lithotripsy               | 14  | 2.9  |
| <b>Side</b>                          |     |      |
| Right                                | 223 | 46.5 |
| Left                                 | 244 | 51   |
| Bilateral                            | 12  | 2.5  |
| <b>Site</b>                          |     |      |
| Hilar                                | 233 | 48.7 |
| Hilo-parenchymal                     | 188 | 39.3 |
| Intraparenchymal                     | 58  | 12   |
| <b>Intra-operative complications</b> |     |      |
| Yes                                  | 0   | 0    |
| No                                   | 479 | 100  |
| <b>Surgical results</b>              |     |      |
| Success                              | 472 | 98.5 |
| Failure                              | 7   | 1.5  |

**Table II.** Follow-up of patients undergoing conservative transoral surgery.

| <b>Early sequelae</b>             | n   | %    |
|-----------------------------------|-----|------|
| None                              | 114 | 23.9 |
| Swelling only                     | 125 | 26.1 |
| Swelling and oedema               | 122 | 25.4 |
| Tingling                          | 108 | 22.5 |
| Lingual nerve injury (transient)  | 10  | 2.1  |
| <b>Late complications</b>         |     |      |
| None                              | 452 | 94.4 |
| Oral mycosis                      | 0   | 0    |
| Tingling                          | 3   | 0.6  |
| Ranula                            | 0   | 0    |
| Hilar stenosis                    | 24  | 5    |
| Lingual nerve injury (persistent) | 0   | 0    |
| <b>Follow-up results</b>          |     |      |
| No residual stones at US          | 425 | 88.7 |
| Residual stones at US             | 54  | 11.3 |
| <b>Subjective evaluation</b>      |     |      |
| No symptoms                       | 408 | 85.1 |
| Recurrent obstructive symptoms    | 59  | 12.3 |
| Recurrent infections              | 12  | 2.6  |
| <b>Post-surgery treatments</b>    |     |      |
| Interventional sialendoscopy      | 31  | 43.7 |
| Other transoral removal           | 8   | 11.3 |
| Sialoadenectomy                   | 7   | 9.8  |
| ESWL                              | 6   | 8.6  |
| None                              | 19  | 26.6 |

and transient lingual nerve injury (n = 10). Only 27 patients (5.6%) experienced late complications: persistent tingling of the tip of the tongue (n = 3) and recurrent sialadenitis due to partial hilar stenoses revealed by US (n = 24). None of the patients experienced permanent lingual nerve injury.

All patients were clinically followed at one and 12 months after the surgical procedure: 408 (85.1%) were symptom free, 59 (12.3%) had recurrent obstructive symptoms and 12 (2.6%) had recurrent infections. US examination at one year showed that parenchymal echogenicity and vascularisation had normalised in most patients, but 54 (11.2%) had developed a subsequent stone (diameter 2-6 mm). The size of the gland was normal in 32 patients, increased in 13 and decreased in 9 patients; no ductal dilation was observed in 40 patients, whereas six showed mild hilar dilation and eight dilation within the ductal system. Of the 71 patients with recurrent obstructive symptoms or infections, 29 underwent secondary interventional sialendoscopy, two sialendoscopy-assisted pneumatic intracorporeal lithotripsy; eight a secondary trans-oral procedure to remove residual stones, six a cycle of extra-corporeal lithotripsy, and seven submandibular sialadenectomy. The remaining 19 did not undergo any further procedure.

Trans-oral surgery led to resolution of symptoms (defined as the absence of any residual episodes of painful salivary gland swelling) in 408 patients (85.1%) (Table III). Most patients (75.2%) reported mild surgery-related pain (VAS scores 1-5), but 24.8% experienced moderate pain (VAS scores 6-10); during the course of follow-up, 71 patients (14.9%) experienced recurrent swelling and moderate pain, with 29 (40.5%) recording a mean VAS score of 8: further treatments consisted of medical therapy alone in 25 patients (35.2%), and repeat surgery in 46 (64.8%). Symptoms improved after adjunctive treatment in 454 patients (94.8%) and, at the end of follow-up, the affected gland was intact in 98.5% of cases. The vast majority of patients (99.6%) said they would repeat and recommend sialendoscope-assisted trans-oral treatment.

## Discussion

A trans-oral approach has recently been proposed as a gland-preserving alternative to sialadenectomy for deep and parenchymal stones<sup>4,6</sup>. The main limitations of previously published studies are that many also included stones located in the main submandibular duct, very few describe long-term surgical results and none considered patients' subjective perceptions or QoL factors. A further curiosity is that a combined sialendoscopy and trans-oral procedure has been advocated, although it is difficult to understand how sialendoscopy can influence the result of trans-oral stone removal.

We describe the objective and subjective outcomes of conservative sialendoscopy-assisted transoral surgery for

**Table III.** Patient's subjective findings after surgery for hilo-parenchymal submandibular stones.

|   | n   | %    |
|---|-----|------|
| <b>Symptoms resolved after first treatment</b>                | 408 | 85.1 |
| <b>Pain secondary to trans-oral surgery (1-10)</b>            |     |      |
| 1   | 3   | 0.6  |
| 2   | 56  | 11.8 |
| 3   | 75  | 15.7 |
| 4   | 114 | 23.7 |
| 5   | 112 | 23.4 |
| 6   | 63  | 13.2 |
| 7   | 44  | 9.1  |
| 8   | 12  | 2.5  |
| 9   | 0   | 0    |
| 10  | 0   | 0    |
| <b>Residual symptoms - recurrent swelling and pain (5-10)</b> | 71  | 14.9 |
| 5   | 5   | 7.6  |
| 6   | 17  | 24.1 |
| 7   | 18  | 25.3 |
| 8   | 29  | 40.5 |
| 9   | 2   | 2.5  |
| 10  | 0   | 0    |
| <b>Further treatment required</b>                             | 71  | 14.9 |
| Antibiotics   | 25  | 35.2 |
| Surgery   | 46  | 64.8 |
| <b>Improved symptoms after multiple treatments</b>            |     |      |
| Yes   | 454 | 94.8 |
| No  | 25  | 5.2  |
| <b>Intact gland</b>   |     |      |
| Yes   | 472 | 98.5 |
| No  | 7   | 1.5  |
| <b>Would repeat treatment</b>                                 |     |      |
| Yes   | 477 | 99.6 |
| No  | 2   | 0.4  |
| <b>Would recommend treatment</b>                              |     |      |
| Yes   | 477 | 99.6 |
| No  | 2   | 0.4  |

large, palpable submandibular stones in a large series of 479 patients. The stones, which were all clinically and ultrasonographically classified as intra-parenchymal, were successfully retrieved from all but seven patients, in whom the failure was due to the fact that the stone could not be separated from the gland tissue despite the use of dedicated elevators. This good result is in line with our initial experience<sup>1</sup> and what has been reported by other authors<sup>4 6 16</sup>, and demonstrate that the procedure is effective in removing deep submandibular stones. Most of these can be removed without using a sialendoscope but, in 9% of cases, the bright guidance of the sialendoscopic

unit facilitated the search for residual parenchymal microliths that had cracked during removal of the main stone or migrated backwards to the peri-hilar region.

On the basis of our data, the technique can be considered safe as only a small number of patients experienced what were only mild untoward effects, such as tingling of the tip of the tongue or the persistence of recurrent sialadenitis due to a US-revealed hilar stenosis.

During follow-up, 85.1% of patients were considered asymptomatic although US allowed the discovery of a number of residual stones in 11.2% of them, 52 of whom were able to undergo a secondary procedure that was made possible by preservation of the entire ductal system. Thirty-one underwent interventional sialendoscopy (including two who underwent sialendoscope-assisted pneumatic intracorporeal lithotripsy); eight underwent a second trans-oral procedure to remove residual stones; and six underwent a cycle of extra-corporeal lithotripsy. Traditional sialadenectomy was required in only seven patients with undetachable parenchymal stones; as failure is a possible event in the case of deep intra-glandular stones, informed double consent to concomitant sialadenectomy should be considered before surgery.

We have previously found<sup>12</sup> that recurrences mainly occur in the first 12 post-procedural months due to the persistence of micro-debris in the gland parenchyma that cannot be detected by US, something that is more frequently observed in patients who have previously undergone shock wave lithotripsy<sup>17 18</sup>. Consequently, extra-corporeal lithotripsy should be used in combination with trans-oral surgery only as salvage therapy after surgery and not before. A new intra-corporeal lithotripter was successfully used in our patients with residual fragments after surgery. This new technique, which has recently been described by Koch et al.<sup>19</sup>, seems to work well and may well become an alternative to trans-oral surgery in selected patients in the future. Multiple microliths are frequently encountered near the main stone during diagnostic work-up, but cannot be visualised by US even by an experienced radiologist. The risk of undiagnosed stones that may otherwise be left in the salivary duct system during surgery (especially in the case of a secondary approach) could possibly be reduced by combining US and cone beam 3D CT, as is currently done in the case of many ENT disorders<sup>20</sup>.

Post-operative US showed that the ductal and parenchymal characteristics of most patients normalised which, together with the significant reduction in the number of episodes of sialadenitis and the subjective perceptions reported by patients, confirms that obstructive sialadenitis is reversible<sup>17</sup>.

## Conclusions

Sialendoscope-assisted trans-oral removal of large (> 7 mm) hilo-parenchymal submandibular stones is a

safe and effective conservative surgical procedure. It preserves the main submandibular duct and allows the stone to be removed through a minimal incision in the hilo-parenchymal region, thus ensuring functional preservation of the obstructed gland and allowing sialendoscopic access through the natural ostium in the case of recurrence. At the same time, a multimodal approach combining all minimally invasive and conservative procedures (such as extra- and intra-corporeal lithotripsy and interventional sialendoscopy) can be planned to provide symptomatic relief and clearance of the salivary duct system. Pre-operative clinical and US evaluation is always advisable to locate the stone precisely and minimise the risk of failure, especially in the case of pure intra-parenchymal stones. Particular attention should be paid to initial experiences with the newly available system of sialendoscope-assisted pneumatic lithotripsy as this will probably reduce the number of patients undergoing trans-oral surgery for large stones. Although it cannot be defined as minimally invasive, most patients would be prepared to repeat the procedure and recommend it to others as it avoids the risks of traditional invasive external surgery.

## References

- 1 Capaccio P, Torretta S, Ottaviani F, et al. *Modern management of obstructive salivary diseases*. Acta Otorhinolaryngol Ital 2007;27:161-72.
- 2 Sigismund PE, Zenk J, Koch M, et al. *Nearly 3,000 salivary stones: some clinical and epidemiologic aspects*. Laryngoscope 2015;125:1879-82.
- 3 Gillespie MB, Koch M, Iro H, et al. *Endoscopic-assisted gland-preserving therapy for chronic sialadenitis: a German and US comparison*. Arch Otolaryngol Head Neck Surg 2011;137:903-8.
- 4 Rauch S, Gorlin RJ. *Diseases of the salivary glands*. In: Gorlin RJ, Goldman HM, editors. *Thoma's Oral Pathology*. Sixth edition. St Louis: Mosby; 1970. p. 997-1003.
- 5 Zenk J, Constantinidis J, Al-Kadah B, et al. *Transoral removal of submandibular stones*. Arch Otolaryngol Head Neck Surg 2001;127:432-6.
- 6 Cho W, Lim D, Park H. *Transoral sonographic diagnosis of submandibular duct calculi*. J Clin Ultrasound 2014;42:125-128.
- 7 Abdel-Wahed N, Amer ME, Abo-Taleb NS. *Assessment of the role of cone beam computed sialography in diagnosing salivary gland lesions*. Imaging Sci Dent 2013;43:17-23.
- 8 Milton CM, Thomas BM, Bickerton RC. *Morbidity study of submandibular gland excision*. Ann R Coll Surg Engl 1986;68:148-50.
- 9 Hald J, Andreassen UK. *Submandibular gland excision: short- and long-term complications*. ORL J Otorhinolaryngol Relat Spec 1994;56:87-91.
- 10 Marchal F. *A combined endoscopic and external approach for extraction of large stones with preservation of parotid and submandibular glands*. Laryngoscope 2007;117:373-7.
- 11 Walvekar RR, Bomeli SR, Carrau RL, et al. *Combined approach technique for the management of large salivary stones*. Laryngoscope 2009;119:1125-9.
- 12 Capaccio P, Clemente IA, McGurk M, et al. *Transoral removal of hiloparenchymal submandibular calculi: a long-term clinical experience*. Eur Arch Otorhinolaryngol 2011;268:1081-6.
- 13 Xiao JQ, Sun HJ, Qiao QH, et al. *Evaluation of sialendoscopy-assisted treatment of submandibular gland stones*. J Oral Maxillofac Surg 2017;75:309-316.
- 14 Guerre A, Katz P. *Extracorporeal shockwave lithotripsy (ESWL) for salivary gland stones: a retrospective study of 1571 patients*. Rev Stomatol Chir Maxillofac 2011;112:75-9.
- 15 Gillespie MB, O'Connell BP, Rawl JW, et al. *Clinical and quality-of-life outcomes following gland-preserving surgery for chronic sialadenitis*. Laryngoscope 2015;125:1340-4.
- 16 Luers JC, Grosheva M, Stenner M, et al. *Sialoendoscopy: prognostic factors for endoscopic removal of salivary stones*. Arch Otolaryngol Head Neck Surg 2011;137:325-9.
- 17 Ottaviani F, Capaccio P, Campi M, et al. *Extracorporeal electromagnetic shock-wave lithotripsy for salivary gland stones*. Laryngoscope 1996;106:761-4.
- 18 Iro H, Zenk J, Waldfahrer F, et al. *Extracorporeal shock wave lithotripsy of parotid stones: results of a prospective clinical trial*. Ann Otol Rhinol Laryngol 1998;107:860-4.
- 19 Koch M, Mantsopoulos K, Schapher M, et al. *Intraductal pneumatic lithotripsy for salivary stones with the StoneBreaker: preliminary experience*. Laryngoscope 2016;126:1545-50.
- 20 Kroll T, May A, Wittekindt C, et al. *Cone beam computed tomography (CBCT) sialography - an adjunct to salivary gland ultrasonography in the evaluation of recurrent salivary gland swelling*. Oral Surg Oral Med Oral Pathol Oral Radiol 2015;120:771-5.

Received: September 15, 2016 - Accepted: December 12, 2016

Address for correspondence: Pasquale Capaccio, Department of Biomedical, Surgical and Dental Sciences, Fondazione I.R.C.C.S. Policlinico, Mangiagalli e Regina Elena, University of Milan, via F. Sforza 35, 20122 Milano, Italy. Tel. +39 02 50320245. Fax +39 02 50320248. E-mail: pasquale.capaccio@unimi.it



# Sialendoscopy-assisted transfacial removal of parotid calculi

## *L'asportazione transfacciale scialoendoscopico-assistita dei calcoli parotidei*

A.J. HILLS<sup>1</sup>, A.M. HOLDEN<sup>2</sup>, M. McGURK<sup>3</sup>

<sup>1</sup> Department of Oral and Maxillofacial Surgery, William Harvey Hospital, Ashford, Kent, UK; <sup>2</sup> Department of Oral and Maxillofacial Surgery, Gloucestershire Royal Hospital, Gloucestershire, UK; <sup>3</sup> Department of Oral and Maxillofacial Surgery, Guy's Hospital, London, UK

### SUMMARY

Superficial parotidectomy has significant morbidity, and minimally invasive techniques have therefore been developed, including those involving sialendoscopy, to remove sialoliths and preserve the gland along with its function. The size, mobility and location of the sialolith, alongside the presence of strictures, all dictate management. We outline basic treatment paradigms and describe two sialoendoscopy-assisted surgical procedures developed for treating stones, one intraoral and one extraoral.

KEY WORDS: Sialolith • Sialendoscopy • Masseter • Stensen's duct • Parotid

### RIASSUNTO

*La diffusione delle tecniche minimamente invasive per il trattamento dei calcoli salivari, quali la scialoendoscopia, ha permesso di ottenere un maggior tasso di preservazione della funzionalità ghiandolare, evitando le significative morbidità notoriamente associate alla parotidectomia superficiale. La scelta terapeutica è condizionata dalla dimensione, mobilità e posizione del calcolo così come dalla presenza di stenosi duttali. Verranno descritti i principi terapeutici inerenti la patologia litiasica, nonché due tecniche scialoendoscopico-assistite di rimozione dei calcoli salivari: la prima per via intra-orale, la seconda per via extra-orale.*

PAROLE CHIAVE: Calcoli salivari • Scialoendoscopia • Massetere • Dotto di Stenone • Parotide

Acta Otorhinolaryngol Ital 2017;37:128-131

## Introduction

The foremost inflammatory disorder of the major salivary glands is obstructive sialadenitis, of which the most common cause is sialolithiasis<sup>1</sup>. The incidence of symptomatic salivary calculi is approximately 59 cases per million per annum<sup>2</sup>, with a clinical prevalence of 0.45%<sup>3</sup>. Of these, parotid stones account for approximately 5-10%<sup>4,5</sup>. Patients with blocked ducts can develop obstructive sialadenitis, presenting with “meal-time syndrome,” a recurrent painful peri-prandial swelling of the affected gland which is frequently associated with fever and purulent discharge from the papilla as a result of superimposed bacterial infections<sup>6,7</sup>. Parotid sialoliths in the duct proximal to the anterior masseteric boarder have traditionally been treated with superficial parotidectomy, which has significant morbidity. The primary concern is damage to the facial nerve, with up 16%-38% of patients experiencing temporary weakness, and approximately 9% having some degree of permanent weakness<sup>8,9</sup>. Minimally invasive techniques have therefore been developed, including those involving sialendoscopy, to remove sialoliths and preserve the gland along with its function. Micro-endoscopy has been used in

various guises for the management of salivary gland disease since 1991<sup>10</sup>. Its ability to directly visualise the duct has aided therapeutic interventions and offered additional diagnostic benefits by enabling direct visual assessment of the ductal lining. This facilitates the identification of obstructions not readily identifiable on radiology, such as radiolucent sialoliths, polyps, stenosis and mucous plugs.

## Anatomy

The parotid glands lie in the preauricular region with the bulk of the gland overlying the masseter. The gland extends from the zygomatic process and mastoid process, and wraps around the posterior and inferior borders of the mandible. They are the largest of the salivary glands, measuring approximately 46 x 37 mm, being longer in their cranio-caudal axis<sup>11</sup>. The facial nerve transverses through the parotid gland, the plane of which divides it into superficial and deep parotid lobes, the superficial lobe being the larger accounting for two-thirds of the gland. Stensen's duct drains the parotid and is approximately 7 cm long, following a line drawn from the tragus to the midpoint of the upper lip. After the duct forms in the body

of the gland, it exits through the hilum, bending acutely to pass medially into the tail of the parotid. As the duct exits the tail then the buccal branch of the facial nerve runs both parallel and in close proximity to it for approximately 2.5 cm, with the nerve laying inferiorly in 75% of cases, but crossing to lie superiorly in up to 25%<sup>12,13</sup>. Both duct and nerve travel along the superficial surface of the masseter muscle before at its front edge the duct takes a right-angle turn medially to penetrate the buccinator and oral mucosa, exiting opposite the maxillary second molar intraorally. The nerve continues anteriorly towards the orbicularis oris muscle. The diameter of Stensen's duct varies along its length, ranging between 1.4 mm and 0.5 mm depending on the site (proximal = 1.4; middle = 1.2; distal = 1.4; ostium = 0.5)<sup>14</sup>. The narrow middle portion can be explained by the course of the duct through the buccinator muscle and in part helps explain the frequency of stone impaction in this region. Approximately 20% of these symptomatic parotid sialoliths are located within Stensen's duct<sup>15,16</sup>, and a number of larger stones (4-7mm) can travel distally to lie near the punctum. Due to the tortuous nature of the ducts stones collect at three distinct regions where the duct changes direction, the masseteric edge (23%), preauricular region (42%) and the hilum (35%)<sup>17</sup>.

## Investigation

The mainstay of investigation is ultrasound, which can also visualise strictures if a duct is dilated with a sialogogue such as a vitamin C tablet prior to imaging. If a clear distinction is required, then formal sialogram is preferable. Small stones close to the ostium may, however, be best demonstrated by soft tissue dental X-ray. CT scans have too many radio-opaque artifacts to be reliable and MRI sialography, though accurate, seems extravagant when the vast majority of information can be gained by US and endoscopy.

## Treatment paradigms

The size, mobility and location of the sialolith, alongside the presence of strictures, all dictate management<sup>18</sup>. Of these, stone size is all-important (Fig. 1). Those up to 4 mm can be drawn down and removed by basket if in a suitable position. However, some small stones may not be in the main duct but a sub-duct, which can have restricted access. One must bear this in mind when using sialendoscopy and radiological approaches as injudicious lavage may inadvertently wash stones back into these sub-ducts making them irretrievable by these methods. Moderately sized stones 5-8 mm in diameter can potentially be targeted by lithotripsy. Until recently only the extra corporeal shock wave lithotripsy (ECSWL) was available. This was expensive and only a few machines were active in Europe, and therefore the treatment was not available to the aver-

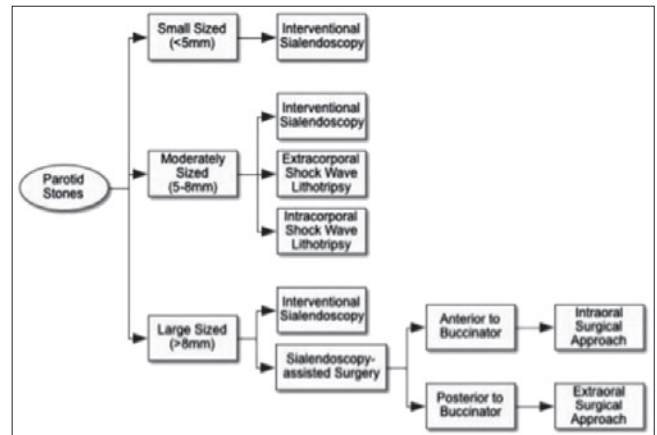


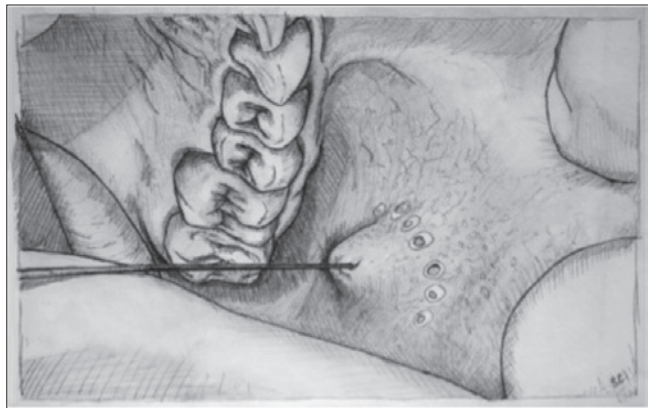
Fig. 1. Treatment paradigms.

age patient. A new intra-corporeal device is now available that is both affordable and effective. Most stones up to about 8 mm can now be targeted, with good results in selected cases (> 70% cure). Stones larger than 8 mm that are in the descending portion of the duct or locked behind strictures fall to the realm of sialendoscopy-assisted surgery. The latter is important as the presence of a stricture distal from the stone prevents fragments moving downstream, and if surgery is deployed can lead to sialoceles. If extremely committed, one can try to dilate strictures and then pull stones through this segment, but this requires dedication, perseverance and patience, qualities few surgeons possess. The fundamental principal that has evolved through experience is that the punctum should not be violated, except very superficially, to release a stone that is already projecting from the orifice. Such an incision is not associated with stricture, but further dissection and incision of the punctum towards the buccinator muscle leads to a troublesome stricture. If a stone has to be retrieved through surgery, then there is a therapeutic divide based on anatomical position. This is due to the masseteric bend to the ostium that prevents stones anterior to it from being accessed from a pre-auricular method, and stones near the hilum similarly being blocked from an intraoral approach. Two sialoendoscopy-assisted surgical procedures have been developed for stones at these differing sites. The anterior boarder of the masseter delineates the posterior limit for an intraoral approach, more proximal to which an extraoral approach is used. Both are usually performed as a day case under general anaesthetic.

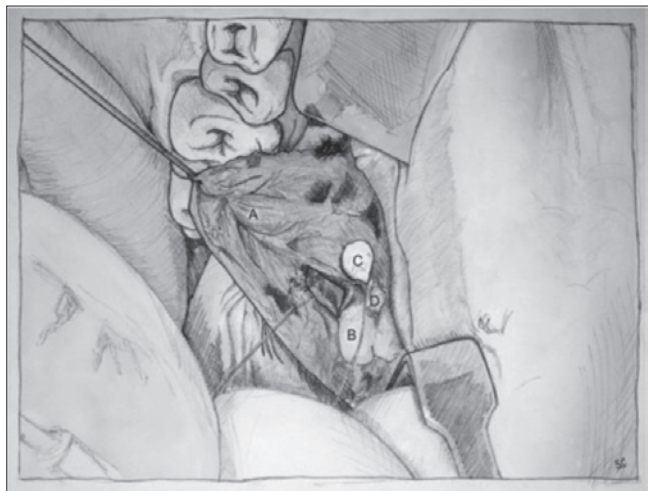## Intraoral approach to parotid stones

A minimally invasive transoral approach is used where the stone sits between the ostium and the anterior boarder of the masseter muscle. The endoscope is introduced to the duct and a semilunar incision is made through the mucosa 1 cm anterior to the parotid punctum, enabling

lateral dissection between the buccal mucosa and buccinator muscle (Fig. 2). The duct, once cannulated by the endoscope, can be identified by palpation or the light at the tip of the scope and traced back as far as the anterior aspect of the masseter muscle. The duct is then carefully skeletonised by blunt dissection on either side of the duct. The latter comes into view as the soft issues around it are parted. Once the stone is located a longitudinal incision is made over the stone to deliver it (Fig. 3). Next, the endoscope is advanced to ensure no additional stones are present in the duct system. The gland is irrigated with normal saline before the small incision is closed with 6.0 vicryl rapide. The duct is ideally closed with the endoscope or lacrimal dilator lying within the lumen to ensure the lumen remains patent. The semilunar incision is closed with interrupted absorbable sutures. The advantage of this approach is that any leakage of saliva from the surgical



**Fig. 2.** Cautery marking the semilunar incision site on buccal mucosa approximately 1 cm anterior to the opening of the duct. The basket can be used to provide gentle traction.



**Fig. 3.** Reflection of the mucosal flap with buccinator muscle lying medial (A) and buccal fat pad lateral (B) revealing the skeletonised duct with sialolith visible (C). Note the sutures used to both define the duct and provide traction to aid recannulation upon the sialolith's removal (D).

site does not collect in the wound forming a sialocele, but empties spontaneously into the oral cavity. This situation is very uncommon. The procedure is associated with minimal side effects.

### Extraoral approach to parotid stones

A stone that lies in the immediate preauricular area is first located with a salivary endoscope to confirm its position and is marked on the skin surface as a surgical guide. A Redon or modified Blair incision is then used to reflect the preauricular skin incision and expose the parotid fascia. The buccal branch of the facial nerve is quite superficial and usually comes into view once the parotid fascia is divided over the duct. A retrograde dissection along the buccal nerve shows that it passes superficial to the descending limb of the parotid duct and as this branch of the facial nerve is traced back towards the main trunk (the main trunk is never exposed or visualised) it helps to define the anatomy of the descending duct. The sialendoscope is then introduced into the duct and passed along the lumen until the stone is seen. Once the stone is found the light source to the endoscope is turned to maximum and the glow from the tip guides the surgeon on to the parotid duct. The duct is skeletonised at this location and once the stone is palpated a small longitudinal incision over its surface ensures its release. The endoscope is withdrawn from the mouth and inserted through the preauricular skin incision to inspect the descending portion of the duct to make sure no secondary stones are present. The duct is then irrigated before closing the incision in the wall with 6.0, the capsule with 4.0 vicryl rapide and the skin is closed as per the surgeon's preference. Patients are discharged with a pressure dressing and a 1-week course of antibiotics. The technique builds on that developed by Baumrath et al<sup>19</sup> where the stones were first localised through plain radiographs and high-resolution ultrasound, before a horizontal skin incision was made directly over the calculus to deliver the stone. This technique was limited to larger, more superficial stones, towards the anterior border of the masseter muscle. The down side is that it frequently leaves an obvious scar on the cheek.

### Complications

Over the last 9 years (2005-2014), 115 patients have been treated with 130 stones using the endoscopic assisted technique, with a successful stone retrieval rate of 98% (85% extraoral: 15% intraoral). Of these, 51% had undergone failed attempts at retrieval using conventional methods prior to using these techniques. Post-operative complications occurred in 23% (25 extraoral, 1 intraoral) cases, these included sialocele (14 cases), pre-auricular sensory deficit (7 cases), transient facial nerve weakness (5 cases), post-operative infection (5 cases) and fistula

formation (2 cases). These post-operative complications were most commonly seen with the extraoral approach and were in keeping with the nature of the approach with dissection into the parotid. No complication was troublesome. Sialoceles all responded within 10 days to hyoscine tablets, intermittent aspiration and pressure dressing. The cause was a stricture downstream from the incision in the duct, these should be dilated prior to closing the duct incision. Altered sensation always occurs when lifting the pre-auricular skin and resolves slowly over time. The transient weakness was to the muscles of the upper lip due to tension on the buccal nerve. The two fistulae were a variation on the sialocele and were treated in the same way.

### Long-term results

The endoscope-assisted technique has a high success rate (97%)<sup>17</sup>. Late results were assessed by a postal survey at a mean of 44 months postsurgery confirmed the value of the technique with 89% of patients completely asymptomatic, 7% had a degree of residual meal time syndrome and only 4% had further incidences of sialadenitis. Significantly, no patient had persistent facial weakness or had gone on to require a parotidectomy.

### Conclusions

Sialoendoscopically-assisted retrieval of parotid stones through an intraoral or extraoral approach is a practical option for the management of larger or impact stones that are not amenable to other endoluminal treatments. They have a high incidence of successful stone retrieval and a low occurrence of long-term complications whilst avoiding the need for parotidectomy with associated morbidity.

### Acknowledgements

Medical illustrations by Dr Simran Chana.

### References

- 1 McGurk M, Combes J. *Endoscopic-assisted management of parotid stones. Controversies in the management of salivary gland disease*. 2<sup>nd</sup> ed. Oxford: Oxford University Press; 2013. p. 307.
- 2 Escudier MP, McGurk M. *Symptomatic sialadenitis and sialolithiasis in the English population, an estimate of the cost of hospital treatment*. Br Dent J 1999;186:463-6.
- 3 McGurk M, Escudier MP, Brown JE. *Modern management of salivary calculi*. Br J Surg 2005;92:107-12.
- 4 Hupp JR, Ellis E, Tucker MR. *Contemporary oral and maxillofacial surgery*. 5<sup>th</sup> ed. St. Louis, Mo.: Mosby Elsevier; 2008. p. 407-409.
- 5 Capaccio P, Gaffuri M, Pignataro L. *Sialendoscopy-assisted transfacial surgical removal of parotid stones*. J Craniomaxillofac Surg 2014;42:1964-9.
- 6 Escudier MP. *The current status and possible future for lithotripsy of salivary calculi*. In: Pregrel M, editor. *Atlas of oral and maxillofacial surgery clinics of North America*. Philadelphia, PA: Saunders; 1998. p. 117-132.
- 7 Capaccio P, Torretta S, Ottaviani F, et al. *Modern management of obstructive salivary diseases*. Acta Otorhinolaryngol Ital 2007;27:161-72.
- 8 Owen ER, Banerjee AK, Kissin M, et al. *Complications of parotid surgery: the need for selectivity*. Br J Surg 1989;76:1034-5.
- 9 Mra Z, Komisar A, Blaugrund SM. *Functional facial nerve weakness after surgery for benign parotid tumours: a multivariate statistical analysis*. Head Neck 1993;15:147-52.
- 10 Katz PH. *Endoscopy of the salivary glands [in French]*. Ann Radiol (Paris) 1991;34:110-3.
- 11 Dost P. *Ultrasonographic biometry in normal salivary glands*. Eur Arch Otorhinolaryngol 1997;254(Suppl 1):S18-9.
- 12 Pogrel MA, Schmidt B, Ammar A. *The relationship of the buccal branch of the facial nerve to the parotid duct*. J Oral Maxillofac Surg 1996;54:71-3.
- 13 Son ET, Choi HJ, Nam DH, et al. *Analysis of anatomical relationship between Stensen's duct and buccal branch of facial nerve*. Arch Craniofac Surg 2013;14:102-6.
- 14 Zenk J, Hosemann WG, Iro H. *Diameters of the main excretory ducts of the adult human submandibular and parotid gland: a histologic study*. Oral Surg Oral Med Oral Pathol Oral Radiol Endod 1998;85:576-80.
- 15 Iro H, Zenk J, Waldfahner F, et al. *Extracorporeal shock wave lithotripsy of parotid stones: results of a prospective clinical trial*. Ann Otol Rhinol Laryngol 1998;107:860-4.
- 16 Zenk J, Koch M, Klintworth N, et al. *Sialendoscopy in the diagnosis and treatment of sialolithiasis: a study on more than 1000 patients*. Otolaryngol Head Neck Surg 2012;147:858-63.
- 17 Samani M, Hills AJ, Holden AM, et al. *Minimally-invasive surgery in the management of symptomatic parotid stones*. Br J Oral Maxillofac Surg 2016;54:438-42.
- 18 Capaccio P, Gaffuri M, Pignataro L. *Sialendoscopy-assisted transfacial surgical removal of parotid stones*. J Craniomaxillofac Surg 2014;42:1964-9.
- 19 Baurmarsh H, Dechiara SC. *Extraoral parotid sialolithotomy*. J Oral Maxillofac Surg 1991;46:127-32.

Received: September 15, 2016 - Accepted: December 12, 2016

Address for correspondence: M. McGurk, Department of Oral and Maxillofacial Surgery, Guy's Hospital, London, SE1 9RT. Tel. 02 0 7188 4349. E-mail: mark.mcgurk@kcl.ac.uk

# Salivary duct stenosis: diagnosis and treatment

## *Stenosi duttali salivari: diagnosi e terapia*

M. KOCH, H. IRO

Department of Otorhinolaryngology, Head and Neck Surgery, Friedrich Alexander University of Erlangen, Nuremberg, Germany

### SUMMARY

The management of stenoses of the major salivary glands had undergone a significant change during the last 15-20 years. Accurate diagnosis forms the basis of adapted minimal invasive therapy. Conventional sialography and MR-sialography are useful examination tools, and ultrasound seems to be a first-line investigational tool if salivary duct stenosis is suspected as cause of gland obstruction. Sialendoscopy is the best choice to establish final diagnosis and characterise the stenosis in order to plan accurate treatment. In all major salivary glands, inflammatory stenosis can be distinguished from fibrotic stenosis. In the parotid duct system, an additional stenosis associated with various abnormalities of the duct system has been reported. Conservative therapy is not sufficient in the majority of cases. The development of a minimally invasive treatment regime, in which sialendoscopy plays a major role, has made the preservation of the gland and its function possible in over 90% of cases. Ductal incision procedures are the most important measure in submandibular duct stenoses, but sialendoscopy becomes more important in the more centrally located stenoses. Sialendoscopic controlled opening and dilation is the dominating method in parotid duct stenoses. In 10-15% of cases, success can be achieved after a combined treatment regime had been applied. This review article aims to give an overview on the epidemiology, diagnostics and current state of the art of the treatment of salivary duct stenoses.

**KEY WORDS:** Salivary duct stenosis • Treatment • Sialendoscopy • Minimal invasive • Gland preservation

### RIASSUNTO

*La gestione delle stenosi delle ghiandole salivari maggiori ha subito un cambiamento significativo nel corso degli ultimi 15-20 anni. L'elemento fondamentale che sta alla base di una scelta terapeutica minimamente invasiva è rappresentato da un'accurata diagnosi. La scialografia convenzionale e la scialo-RM possono essere utili strumenti per la diagnosi delle stenosi salivari, senza dimenticare il ruolo basilare e centrale dell'ecografia qualora si sospetti che un processo stenotico a carico dei dotti salivari sia la causa dell'ostruzione. Tuttavia, ad oggi, la scialoendoscopia rappresenta la scelta diagnostica migliore, permettendo una corretta pianificazione terapeutica attraverso una quanto più precisa caratterizzazione della stenosi. Sia a livello sottomandibolare che parotideo è possibile distinguere le stenosi infiammatorie da quelle secondarie a processi fibrotici e, inoltre, a carico dei dotti salivari parotidei è stata descritta una stenosi associata a varie anomalie del sistema duttale. Nella maggior parte dei casi la sola terapia conservativa non è sufficiente per la risoluzione della sintomatologia ostruttiva, tuttavia lo sviluppo di trattamenti minimamente invasivi, prima fra tutte la scialoendoscopia, ha permesso di ottenere un tasso di conservazione della funzione ghiandolare di oltre il 90% dei casi. Se a livello sottomandibolare la principale misura terapeutica nella gestione delle stenosi del dotto ghiandolare rimane l'incisione duttale (eccezion fatta per il crescente ruolo della scialoendoscopia nelle stenosi centrali), viceversa a livello del dotto parotideo la stenosi viene preminentemente gestita mediante la scialoendoscopia. Va comunque sottolineato che nel 10-15% dei casi il successo terapeutico viene ottenuto attraverso un trattamento di tipo combinato. La seguente review si propone di fornire una panoramica circa l'epidemiologia, la diagnostica e l'attuale stato dell'arte del trattamento delle stenosi salivari.*

**PAROLE CHIAVE:** Stenosi duttali salivari • Terapia • Scialoendoscopia • Minimamente invasiva • Preservazione della funzione ghiandolare

Acta Otorhinolaryngol Ital 2017;37:132-141

## Introduction

The symptoms of obstructive diseases of the salivary glands consist of recurrent painful swelling of the major salivary glands, especially after food intake. This often leads to a marked reduction of the patient's quality of life. Salivary duct stenoses are a relatively rare pathological condition and are often diagnosed in specialised centres. The management of these conditions has changed dramatically during the last 10–20 years. This article aims to provide an overview of recent developments in this field.

## Epidemiology and diagnosis

Salivary duct stenoses are the second most frequent cause of obstructions in the salivary glands, representing 15–25% of cases in the parotid gland and 5-10% of all obstructions of the submandibular gland<sup>1-7</sup>. Up to 50% in cases of unclear gland swelling and up to 85% in cases of obstruction are not caused by sialolithiasis<sup>3-5 8 9</sup>. Around 70-75% of stenoses are located in the parotid and 25-30% in the submandibular duct system<sup>4 5</sup>. Stenoses are associated with sialolithiasis in over 15% of cases in the parotid gland and in 2-5% of cases in the submandibular

gland<sup>3-5,9-11</sup>. Typically, stenoses in both glands are associated with chronic inflammatory changes in the ductal system and parenchyma. Reduced salivary flow, ascending duct infection and the formation of mucous or fibrinous plaques and strictures or stenoses are the consequence<sup>17 10 12-17</sup>.

Particularly in the submandibular gland, the clinical picture of chronic recurrent inflammation is poorly defined. After sialendoscopy examinations in 467 glands, Yu et al. found that stenosis was the cause in 6% of cases<sup>6</sup>. Koch et al. and Kopec et al. investigated possible causes and/or associated diseases in Wharton's duct stenosis. Allergy (up to 26.8%), autoimmune diseases (up to 16.7%), status after irradiation (5.1%), fibrosis due to a dental prosthesis (1.4%) and other rare diseases (0.7%) were described. Sialolithiasis was associated with the stenosis in up to 16.7% of cases. Status after prior surgery (with or without sialolithiasis) was noted in up to 13.8% of cases<sup>10 14</sup>.

Chronic (recurrent) parotitis may be a major cause of stenoses of Stensen's duct<sup>7 12 17 18</sup>. After analysing sialendoscopy examinations in 85 glands, Chuangqi et al. found that stenosis was the main cause of obstruction in 75% of cases<sup>8</sup>. Accompanying conditions/diseases that have been described include allergic, granulomatous and autoimmune conditions, status after radiation therapy, presence of a ductal system with anatomic variations/abnormalities, situation after trauma, disturbances of the cranio-mandibular system, and, rarely, chronic juvenile parotitis or IgG4-associated disease<sup>12-15 19-21</sup>. Some authors have reported isolated obstructive gland disease characterised by fibrinous plaques and marked eosinophilic reaction without allergic or autoimmune disease<sup>3 20 22</sup>. According to Koch et al. and Kopec et al., possible associations of stenosis with conditions and/or diseases are allergic diseases (up to 29.6%), autoimmune diseases (up to 18.5%), status after irradiation (up to 3.7%) and bruxism or craniomandibular disorders (up to 5.2%). Sialolithiasis and status after stone treatment was associated with stenoses in more than 20% of cases. In 5.2-12.9% of cases, prior surgery of the gland or the duct system was reported<sup>13 14</sup>.

## Diagnosis and classification

Ultrasound, magnetic resonance (MR) sialography, and conventional sialography are the imaging tools most often used for diagnosis, and can all contribute to more precise characterisation of stenoses<sup>3 4 23 24</sup>.

Strictures of the efferent ducts are diagnosed with high sensitivity with sialography using contrast medium indicating filling defects or loss of contrast in the ductal system<sup>4</sup>. Due to the use of contrast medium and application of irradiation, sialography is not first choice.

MR sialography is an alternative method of imaging stenoses that does not require the use of contrast media. Stimulation with citric acid can enhance duct obstruction and indicate the state of gland function<sup>23-26</sup>.

Ultrasound provides an overview of the entire ductal system. In both duct systems, a hypoechoic band is seen as evidence of dilation of the ductal system. The accuracy of can be significantly improved by stimulating glandular secretion using vitamin C administration, allowing approximate localisation of the stenosis<sup>3 5 13 27</sup>.

Through sialendoscopy direct visualisation of the ductal system is possible, allowing establishment of the diagnosis and precise characterisation of the stenosis<sup>1 3 5 11 13 20 21 28</sup>. Qi et al. have described inflammatory changes in the duct wall that may represent a possible precursor stage to stenosis and plaques or "fibre-like substances", which are also suspected to be obstructive factors<sup>20</sup>. In general in all major salivary glands, stenosis characterised by inflammatory changes can be distinguished from fibrotic stenosis<sup>5 10 11 13 20 21</sup>.

Several publications have presented various classifications of ductal stenoses. Ngu et al. analysed the numbers and locations of salivary duct stenoses in more than 1300 sialography examinations<sup>4</sup>. In 33.3% multiple and in 7% bilateral stenoses were observed. Wharton's duct strictures were found most often in the posterior third including the hilar region (68.2%), in Stensen's duct the middle third (39.6%) and the proximal third (37.8%) were most often involved<sup>4</sup>.

No sialendoscopy-based classification had been published concerning stenoses of submandibular duct stenoses. In one report by our own research group these stenoses were described more detailed<sup>10</sup>.

After sialendoscopy in 153 Wharton's duct stenoses reported by Koch et al., fibrous stenoses were present in 87.3%; 62.7% were at the papilla or in the distal duct, but only 18.3% in the proximal segment including the hilar or posthilar area, and 7.8% showed a diffuse extension pattern. Bilateral stenoses and multiple stenoses were found in 8.6% and 3%, respectively<sup>10</sup>. Similar results were reported by others<sup>14</sup>. Compared to the publication of Ngu et al.<sup>4</sup>, the distribution of locations was reversed. Multiple stenoses were observed more frequently in this study (48.5% vs. 3%), but no bilateral stenoses were encountered, compared to 8.6% in the study by Koch et al.<sup>4 10</sup>. Previous surgery in the area of the ductal system may have contributed to these differences.

Several sialendoscopy-based classifications of stenoses of the parotid duct system have been published by Marchal et al.<sup>29</sup> and our own research group<sup>11 21</sup>. Marchal et al. proposed a classification based on lithiasis, stenosis and dilation ("LSD" classification), which takes into account the site, number and severity of stenoses. However, the study does not offer any patient numbers to substantiate this<sup>29</sup>. Koch et al. published a first classification describing all changes in the ductal system that were visible with the sialendoscope in 111 stenoses<sup>21</sup>, which was extended and specified in a subsequent publication including 550 stenoses<sup>11</sup>. Different sialendoscopes were used to clas-

sify the stenoses in accordance with various criteria: the location of the stenosis in the ductal system, length of the stenosis, grade of luminal narrowing, number, site and laterality and tissue quality within the stenotic area. Depending on the appearance of the tissue in the stenotic region, three main types were distinguished. Type 1 stenosis was characterised by inflammatory changes in the stenotic area (8.9%), type 2 stenoses were associated with an abnormal duct system that showed circular or web-like changes and megaduct (19.5%) and type 3 stenoses were characterised by purely fibrotic reactions, with diffuse involvement of the duct wall (71.6%). Multiple stenoses were found in 2.8% and bilateral stenoses in 11.9% of cases. Two-thirds were located in the distal or middle duct system. Over 95% were middle two high-grade stenoses. Nearly 80% were short, but 8.9% were diffuse. Kopec et al. published similar results after analysing 27 stenoses<sup>14</sup>. Type 1 stenoses differed significantly from type 3 stenoses, with lower grades. Type 3 stenoses showed significantly higher grades of luminal narrowing than the other two types. Type 2 stenoses were significantly shorter in comparison with the other two types. Multiple stenoses were observed significantly more often in type 2 than in type 3 stenoses<sup>11,21</sup>. Type 1 stenosis may be a precursor form of type 3 stenosis that can be diagnosed simultaneously in the same ductal system<sup>11</sup>. By contrast, type 2 stenoses occur in obviously variant ductal systems that usually have – in addition to a variable number of stenoses – typical abnormalities (webs/encroachments, duct bending/kinks, megaduct with very thin duct wall) along the entire length. However, most of these webs or encroachments do not form a relevant stenosis, although they may appear as strictures/stenoses on radiological examinations (e.g., sialography). These results appear to indicate that type 2 stenosis is completely different in comparison with the other types and has a different, but not fully understood, underlying pathogenesis. A few publications have described similar situations when reporting patients presenting with “sialectasis” or “sialoceles” of the parotid duct<sup>30-36</sup>.

## Treatment

In general, symptom-free stenoses and stenoses associated with recognisable atrophy of the gland require no treatment, or only exclusively conservative treatment. This includes gland massage, anti-inflammatory treatment and antibiotic treatment if necessary. Treatment provided for salivary duct stenoses has changed dramatically during the last 20 years. The development of minimally invasive treatment regimens has led to a significant reduction in the rate of gland resection. In the era before minimally invasive therapy, the failure rate after conservative treatment was nearly 50%, and gland resection was the next step in many of these cases<sup>12,18</sup>. This changed after the develop-

ment of minimally invasive treatment options, involving various methods of transoral ductal surgery, radiologically-guided methods and sialendoscopy-guided therapy. However, it should be emphasised that one of the essential prerequisites for any successful treatment, independently of the method chosen, appears to be an adequate gland function. If an impaired gland is not recovering, the use of almost any approach may not be successful<sup>37-40</sup>.

### *Sialography-guided balloon dilation*

In the early years after sialendoscopy was introduced into clinical medicine, sialography-guided balloon dilation was carried out, with substantial success rates<sup>41,42</sup>. Although (partial or complete) opening of duct stenoses was regularly reported in more than 80% of cases, no detailed information regarding follow-up (state of complaints, gland preservation rate) was provided in most reports<sup>41,43,48</sup>. Drage et al. described 36 cases after sialographically-guided therapy (the glands were not specified). It was possible to dilate the stenoses in 92% of cases, and post-interventional sialographic control showed complete opening in 82% and partial opening in 14% of cases. Follow-up sialography after various time intervals showed complete opening in 48%, partial opening in 5% and an unchanged situation (recurrent stenosis) in 33% of cases with follow-up. No complaints and partially improved symptoms were noted in 48% each<sup>47</sup>. Salerno et al. reported on nine cases (seven parotid, two submandibular glands). Moderate to good opening was possible in 88.9% of cases (six parotid, two submandibular glands). A completely symptom-free state was achieved in 77.8% (five parotid and two submandibular glands)<sup>48</sup>. A summary of the results is shown in Table I. Although acceptable results were achieved with sialography-guided balloon dilation, it has the disadvantage that it only allows indirect visualisation of the stenosis, involves radiation exposure and is associated with a risk of reaction to contrast media. In view of the opportunities provided by sialendoscopy-guided therapy, sialographic controlled treatment currently does not appear to be the treatment of choice. The present review therefore focuses on sialendoscopy-guided therapy.

### *Sialendoscopy-guided therapy of minimally invasive treatment regime: general aspects and the role of adjuvant and medical treatment*

Regular/daily gland massage with sialogogues and repeated irrigation with cortisone are among the basic measures in the treatment sequence and aftercare. If primary therapy was carried out using sialendoscopy-guided measures, then irrigation with intraductal cortisone was often included<sup>1,3,9,13,14,38,40,49-57</sup>. A recent prospective pilot study by Capaccio et al. confirmed the value of intraductal cortisone administration. The outcomes for patients were compared 6 months after (interventional) sialendoscopy,

**Table I.** Results in the literature after minimally invasive, sialographic-controlled treatment of salivary duct stenoses.

| Author (year)           | Glands total (n) | SMG (n) | PG (n) | Partial success of procedure (% glands) | Complete success of procedures (% glands) | Improve of symptoms (% patients) | Recurrent or persistent complaints (% patients) | Preservation of gland (%)        |
|-------------------------|------------------|---------|--------|---|---|----------------------------------|---|----------------------------------|
| Buckenham et al. (1992) | 1                | n.n.    | 1      | ----                                    | 100                                       | n.n.                             | n.n.  | n.n.                             |
| (1993)                  | 3                |         | 3      | ----                                    | 100                                       | n.n.                             | n.n.  | n.n.                             |
| Roberts et al. (1995)   | 3                | ----    | 3      | ----                                    | 100                                       | 100                              | 33.3  | n.n.                             |
| Brown et al. (1997)     | 30               | 6       | 24     | ----                                    | Total 86.7<br>SMG 50<br>PG 96             | Total 77<br>SMG 33.3<br>PG 57    | Total 30<br>SMG 66.7<br>PG 21.7                 | Total 93.3<br>SMG 33.3<br>PG 100 |
| Waldmann et al. (1998)  | 1                | ----    | 1      | ----                                    | 100                                       | 100                              | 100   | 100                              |
| Drage et al. (2002)     | 36               | n.n.    | n.n.   | 14                                      | 82  | 96                               | 52  | n.n.                             |
| Brown et al. (2006)     | 125              | n.n.    | n.n.   | 9.6                                     | 71.5                                      | n.n.                             | n.n.  | n.n.                             |
| Salerno et al. (2007)   | 9                | 2       | 7      | Total 55.5<br>SMG 50<br>PG 57.2         | Total 33.3<br>SMG 50<br>PG 28.6           | Total 77.8<br>SMG 50<br>GP 85.7  | Total 22.2<br>SMG 50<br>GP 14.3                 | n.n.                             |

Legend: SMG: submandibular gland, PG: parotid gland

with or without intraductal cortisone treatment in cases of unclear obstruction, including cases with stenosis. It was found that patients who received intraductal cortisone had a significantly better outcome in comparison with patients who did not have additional treatment. The authors concluded that “sialendoscopy with intraductal steroid irrigation was more effective than interventional sialendoscopy alone in the medium term”<sup>57</sup>.

Most of the publications on this topic describe the results after treatment for stenosis in a few patients, but without any distinction between glands. Detailed data on the nature of the stenosis, success rates of the procedures and follow-up findings are not provided, and no information about symptoms or gland resection status is offered. Irrigation with cortisone is reported in nearly all publications; the instruments used are the sialendoscope itself, microdrills, baskets, various dilators, graspers and balloons. Stents were implanted in 10-100% of cases described<sup>1 9 14 49 53 54 56 58</sup>.

#### *Sialendoscopy-guided therapy and minimally invasive treatment regimen in Wharton's duct stenoses*

Treatment for submandibular stenoses has so far only been described in very few studies. Treatment procedures described included limited and extensive ductal incision procedures and interventional sialendoscopy<sup>3 5 10 42 50 59-62</sup>. Nonspecific data and/or a lack of data in most publications make precise analysis and assessment of the value of sialendoscopy-guided therapy difficult. Overall success rates of the procedures were in the range of 80-100%; complete resolution of symptoms was achieved in 50-80% and gland preservation in 90-100% of cases<sup>1 5 9 10 14 49 53 54 56 58</sup>.

Nahlieli et al. were the first to report on the treatment of stenoses in 11 submandibular glands, with results that were not specific for submandibular glands. Balloons were used for dilation in 80% of cases, blunt obturators/

dilators in 12% and stents in 100%. Eighty per cent of patients became symptom-free, symptoms improved in 16% and gland preservation was achieved in 96%<sup>1</sup>.

Comprehensive, multimodal treatment in 153 of these stenoses has been reported in detail by Koch et al.<sup>10</sup>. Transoral duct surgery was successful in 58.1% of cases, and this proved to be the most important treatment modality in this gland. The prerequisite for ductal incision is that marsupialisation of the duct and creation of a neo-ostium is possible. Marsupialisation appears to be particularly important, as gland function is often compromised. These procedures may extend beyond the hilum to submandibulotomy as described in the treatment of sialolithiasis<sup>50 63 64</sup>. Interventional sialendoscopy was carried out successfully in 26.8% of cases, particularly in proximal or more central posthilar stenoses. Irrigation with cortisone alone was sufficient in 12.4%. Overall, 93% of patients who underwent endoscopic treatment also became free of symptoms, and sialendoscopy-based techniques played a decisive role in the treatment in 39.2% of cases. The value of intraductal endoscopy-guided treatment increased from the distal to the proximal duct system, but was limited in diffuse stenosis. The gland preservation rate was 97.8%. After a mean follow-up period of more than 4 years, 3% of patients with preserved glands had relevant persistent symptoms<sup>10</sup>. In summary, the location of the stenosis is one of the most important factors for decision-making on how to treat Wharton's duct stenosis. In view of the accessibility of the submandibular duct system, various methods of transoral duct incision appear to be indicated for stenoses from the papilla to the hilum. In stenosis of the proximal ductal system and hilar region, sialendoscopy-guided opening and dilation appear to be a good treatment option to extended transoral duct slitting. Particularly in the hilar and posthilar area, and also sometimes in localised stenoses of the intraparenchymal ductal system, sialen-



doscopy provides unique direct visualisation of a segment of the ductal system that cannot be adequately visualised with other methods.

A treatment algorithm describing all gland-preserving treatment modalities has been published (Fig. 1) <sup>50</sup>.

*Sialendoscopy-guided therapy and minimally invasive treatment regimen Stensen's duct stenoses*

Parotid duct stenoses are difficult to treat. Before the minimally invasive era, stenoses could not be clearly defined, and treatment for this condition was often carried out with a diagnosis of "chronic parotitis". Numerous reports on the treatment of chronic parotitis were published and the results were reported to be unsatisfactory in the majority of cases <sup>12 18 65</sup>. Systemic anti-inflammatory treatment, which consists of administration of antibiotics and especially hydrocortisone, is the established first-line therapy <sup>12 65 66</sup>. Local treatment, such as irrigation of the duct with contrast medium or saline solution and intraductal application of medicaments was also reported <sup>67-69</sup>. This form of treatment does not lead to cure and is not successful in up to 40-50% of cases, making further therapy necessary <sup>12 18 65</sup>. More invasive methods used are various surgical procedures in the distal duct system, such as (extended) papillotomy, distal duct incision, sialodochoplasty with duct reinsertion or duct ligation. High failure rates, ranging from 50% to 70%, have been described <sup>12 18 65 70-72</sup>. Consequently, up to the early 2000s, parotidectomy was still thought to be unavoidable in the course of the disease in over 40% of cases <sup>12 65 66 73-77</sup>. The introduction of sialendoscopy made it possible to diagnose parotid duct stenosis in cases with chronic parotitis. Few publications dealing with sialendoscopy-based treatment reporting data concerning short to medium-term

follow-up periods have been reported. Most of the studies only include relatively few patients, and glands are not differentiated. In addition, detailed data regarding the nature of the stenosis, the success rates of the procedures and follow-up data specific for the gland are not provided. The success rates of procedures were over 80-100%, with complete success reported in 70-90% and gland preservation in 90-100% <sup>1 3 9 13 14 38 49 51-56 78</sup>.

Nahlieli et al. first published results on treatment of 25 stenoses, 14 of which were parotid stenosis, but the glands were not differentiated regarding treatment results (details see above and Table II) <sup>1</sup>.

Ardekian et al. treated 87 parotid duct stenoses. Irrigation with cortisone and application of hydrostatic pressure were performed in all cases. The stenoses were opened and dilated with sialo-balloons, and forced manipulation using a microdrill was described in very difficult cases. Stents were implanted in nine cases, and administration of cortisone and antibiotics (penicillin) in the ductal system was also performed. The results showed that the procedure was successful in 81.7% of glands, and failures were noted in 4.6% of cases <sup>51</sup>.

Vashishta and Gillespie treated a total of 51 patients with unclear swelling of the major salivary glands (but the glands are not specified). Ninety-two per cent of the patients (47/51) had stenoses (59%) or strictures (33%). Microdrills and dilators were used in 78%, stent implantation was performed in 10% and botulinum toxin was injected in 8%. No specific data were provided about the success rate after sialendoscopy for stenoses. Overall, 61% of patients became completely symptom-free and 27% experienced improvement. Gland resection was performed in 4.2% <sup>9</sup>.

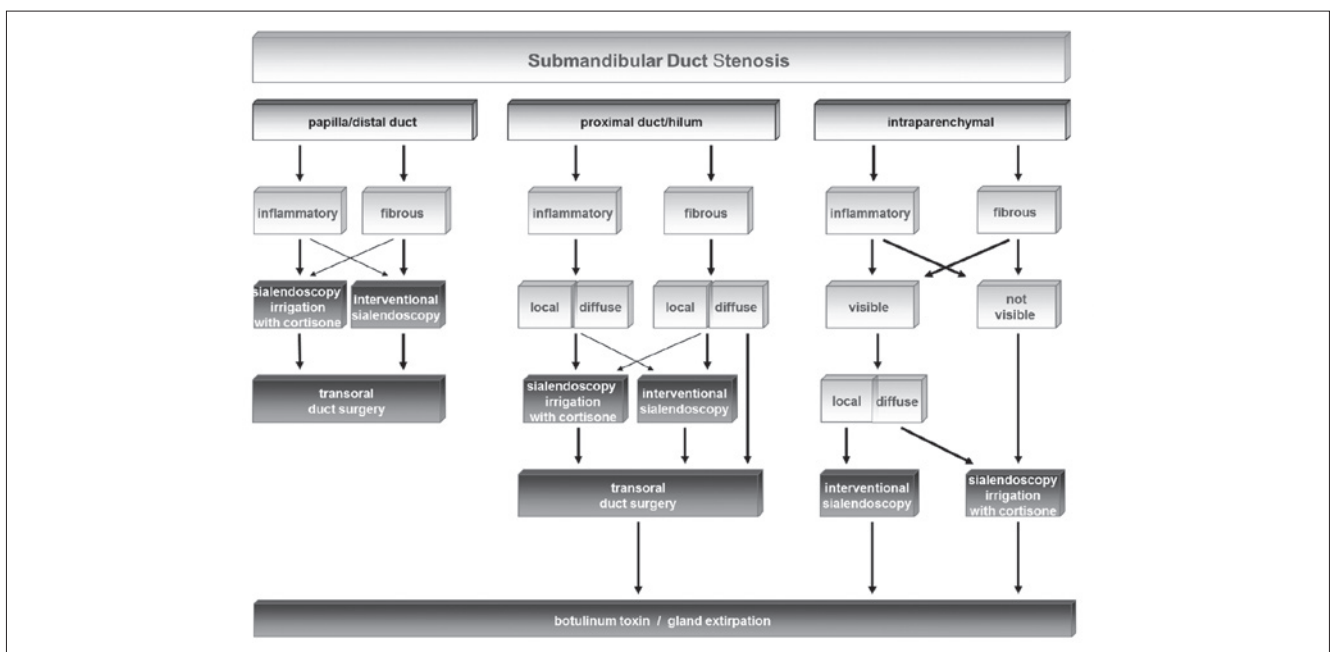


Fig. 1. Treatment algorithm for stenoses in Wharton's duct system (from Koch et al., 2009 <sup>50</sup>, mod.).

After reporting on the preliminary results in 39 patients<sup>13</sup>, Koch et al. presented another study on 93 patients with 111 stenoses in 99 glands, also taking into account the differences observed in parotid duct stenoses<sup>52</sup>. Interventional sialendoscopy proved to be the most important treatment modality, with successful results in 59.2% of cases. Irrigation with cortisone and application of hydrostatic pressure was the only treatment administered in 21.5% of patients. Transoral duct surgery had to be performed in combination with sialendoscopy in 8.6% of patients. Marked differences were noted when treatments for the different types of stenosis were analysed. With type 1 stenoses, irrigation with cortisone was performed in 66.7% of cases and was sufficient in 60%; interventional sialendoscopy was performed in 33.3% and was successful in 26.7% of the stenoses. In type 2 stenoses, irrigation with cortisone was successful in all 47.1% cases in which it was attempted; interventional sialendoscopy was carried out in 52.9% of cases and was successful in 47.1%. In type 3, stenoses irrigation with cortisone was sufficient in only 4.9% of the cases, but interventional sialendoscopy was performed in 77.1% and was successful in 70.5% of stenoses. In these stenoses, a combination with transoral duct surgery was necessary in 18% and successful in 72.3% of these. Stent implantation was required in 63.6% of these cases, leading to a substantial reduction in the risk of recurrent stenosis, with better results than those published in the literature<sup>1 12 65 70 72 75</sup>. In 95.1% of type 3 stenoses, minimally invasive surgical measures had to be performed. Altogether, dilation of the stenoses using interventional sialendoscopy was successful in 88.2% of all cases in which it was attempted, and stents were placed in 8.6%. Gland preservation was achieved in 96.8%. After nearly 2.5 years of follow-up, improvement or freedom from symptoms was achieved in

92.3% of patients with preserved glands. The hypothesis that type 1 stenosis is a precursor form of type 3 stenosis and is thus “non-fibrous” or “nonfixed” – so that it may be reversible after treatment using anti-inflammatory and non-interventional measures – may explain the fact that any “fixed” fibrous type 3 stenosis is much more likely to require more invasive treatment measures. The specific characteristics of type 2 stenoses (> 95% short, nearly 70% low-grade) may explain why they can be treated in a more conservative and non-invasive manner in nearly half of cases. Irrigation and gland massage may be sufficient to wash out obstructing plaques. This may be particularly important in view of the weak excretory function in these ducts. If dilation with interventional sialendoscopy is necessary, stent implantation may be part of treatment<sup>11 52</sup>. A review of the literature shows that some authors have reported on the treatment of stenoses with sialiectasis in the ductal system that appear to show similarities to the type 2 stenoses described by our own group. If treatment was prescribed, it consisted of various methods of transoral duct surgery including duct ligation<sup>30-36</sup>.

Combined endoscopic and transcutaneous surgery, if necessary with duct reconstruction using a vein patch or replacement with a vein graft, has been described in a few publications. This surgery was performed in single cases in all reports. The results in terms of preservation of the gland and gland function have not been sufficient to recommend the procedure<sup>37-39</sup> as part of a standard therapy regime, but it may be a treatment option to avoid gland resection in single cases.

The only study that has reported the results after long-term follow-up was published by Koch et al.<sup>40</sup>. Reassessment was possible in 88.2% of previously treated patients<sup>52</sup> after an average follow-up period of 98 months. Gland preser-

**Table II.** Results in the literature after treatment of salivary duct stenoses with a minimally invasive, sialendoscopy-dominated therapy regime.

| Author (year)           | Glands total (n) | SMG (n) | PG (n) | Success of procedures (% glands)    | Improve of symptoms (% patients)                     | Persistent complaints (% patients) | Preservation of gland (%)             |
|-------------------------|------------------|---------|--------|-------------------------------------|--|------------------------------------|---------------------------------------|
| Nahlieli et al. (2001)  | 25               | 11      | 14     | Total 80<br>SMG n.n.<br>PG n.n.     | Total 96<br>SMG n.n.<br>PG n.n.                      | Total 20<br>SMG n.n.<br>PG n.n.    | Total 96<br>SMG n.n.<br>PG n.n.       |
| Koch et al. (2008)      | 45               | -----   | 45     | 91.1                                | 92.3   | 7.7                                | 93.7                                  |
| Papadaki et al. (2008)  | 18               | n.n.    | n.n.   | 100                                 | n.n.   | n.n.                               | 100                                   |
| Ardekian et al. (2008)  | 87               | -----   | 87     | 81.7                                | n.n.   | n.n.                               | n.n.                                  |
| Maresh et al. (2011)    | 8                | 4       | 4      | Total 90<br>SMG 100<br>PG 100       | Total 75<br>SMG n.n.<br>PG n.n.                      | Total 25<br>SMG n.n.<br>PG n.n.    | Total 100<br>SMG n.n.<br>PG n.n.      |
| Koch et al. (2011)      | 153              | 153     | -----  | 94.8                                | 94.8   | 5.2                                | 97.8                                  |
| Koch et al. (2012)      | 99               | -----   | 99     | 89.9                                | 96.8   | 10.7                               | 96.8                                  |
| Kopec et al. (2012)     | 59               | 24      | 35     | Total 92<br><br>SMG n.n.<br>PG n.n. | Total 92 (signifikant 78)<br><br>SMG n.n.<br>PG n.n. | n.n.<br><br>n.n.<br>n.n.           | Total 98.3<br><br>SMG n.n.<br>PG n.n. |
| Vashishta et al. (2013) | 47               | n.n.    | n.n.   | n.n.                                | Total 88   | Total 39                           | Total 95.8                            |
| Ryan et al. (2014)      | 1                | -----   | 1      | 100                                 | 100  | -----                              | 100                                   |

Legend: SMG: submandibular gland, PG: parotid gland

vation was noted in all 82 of these patients. Patients were evaluated using a questionnaire; 50% reported swelling and 20% pain. However, the level of symptoms was low, 23.5 on a visual analogue scale (VAS) of 1-100, and scores for pain were also low (1.38 on a VAS from 1 to 10). No differences were noted in relation to the different types of stenoses. A significant decrease in symptoms after treatment in comparison with the pretreatment state and a significant increase in the perceived quality of life related to the salivary glands were reported by the patients using a VAS from 1 to 100, independently of the type of stenosis. The treatment was very well accepted by patients<sup>40</sup>. A comprehensive treatment algorithm was also published for Stensen's duct stenosis (Fig. 2)<sup>50</sup>.

*Treatment failure*

If all procedures fail, ablation of gland function by surgical and chemical means may be indicated. Botulinum toxin has been successfully injected into the gland for patients with various disturbances of salivary flow. In patients with therapy-resistant ductal stenosis, repeat injection of Botulinum toxin into the gland parenchyma may arrest symptoms<sup>79-81</sup>. Duct ligation has reported to be unsuccessful in not more than 50% of cases and is therefore not a preferred procedure<sup>12 18 37 65 70 71 82-84</sup>.

A recent publication on 69 patients who had therapy resistant stenosis (in both glands, although the glands were not differentiated) were treated by administering alfuzosin (at 2.5 mg/day per os) for 3–24 months. They noted "significant improvement" in 80% of patients, but no further details or side effects are described in the report, nor is any information provided about the state of the gland<sup>85</sup>.

Overall, the results in the literature show that the best success rates are achieved not with a single therapeutic modality, but rather with a combination of various treatment options. This is reflected in the comprehensive treatment algorithms published (Figs. 1, 2)<sup>50</sup>.

*Meta-analyses and patient acceptance of minimal sialendoscopy-guided treatment regimens*

Several meta-analyses and reviews have been published that generally confirm the effectiveness of sialendoscopy-guided therapy in obstructive salivary gland diseases, but do not include any specific analyses of the management of stenoses<sup>86 87</sup>. Patient satisfaction after sialendoscopy-guided treatment for obstructive salivary gland diseases has also been investigated by a few research groups. The only publication describing patient acceptance after treatment for salivary duct stenoses was mentioned earlier<sup>40</sup>. Several authors assessed patient satisfaction after sialendoscopic controlled therapy of obstructive sialadenitis, not exclusively including patients with duct stenosis<sup>53 55 56 88</sup>. Kroll et al., using the Short Form 36 (SF-36) questionnaire, found a high level of patient satisfaction<sup>53</sup>. Gillespie et al. using a salivary-specific standardised questionnaire (modified OHIP-14 scores) observed that the scores after treatment of cases not caused by sialolithiasis improved, but significantly less than the scores after treatment for sialolithiasis, with significantly less improvement in salivary gland-related quality of life scores<sup>55</sup>. Similar results were obtained by Aubin-Pouliot et al., who used a questionnaire designed to obtain a chronic obstructive sialadenitis score (COSS). The results showed that symptoms decreased significantly after sialendoscopy-assisted

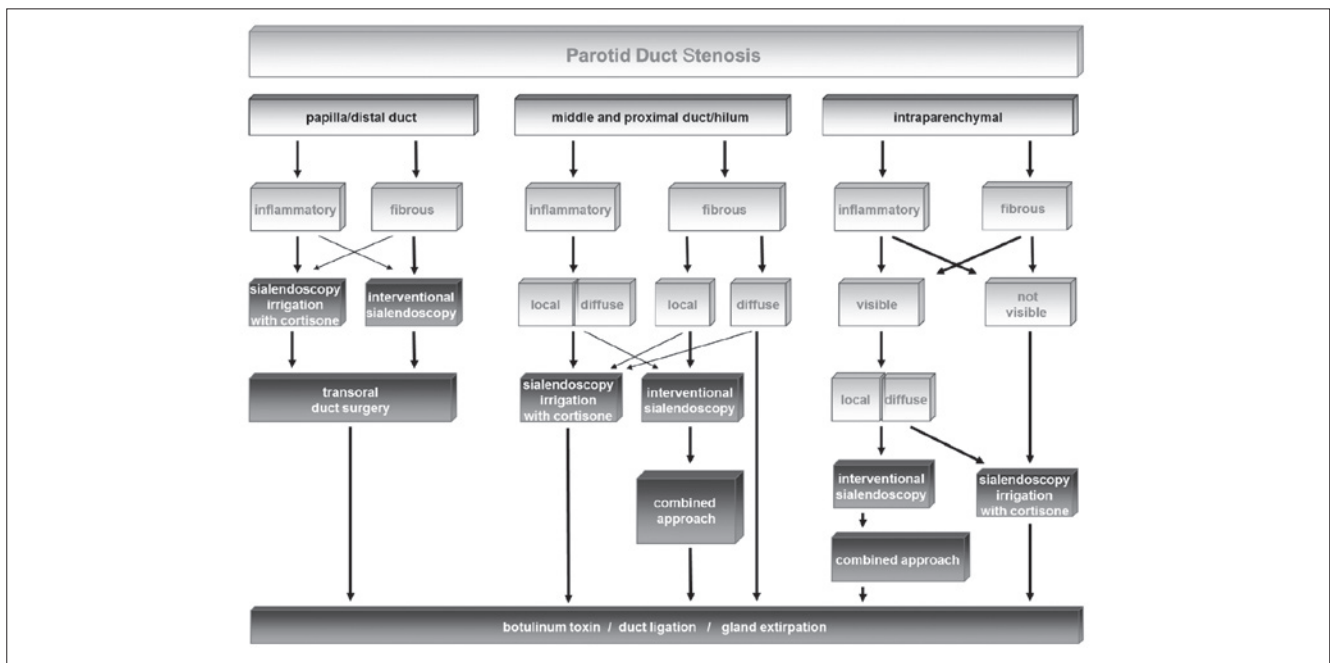


Fig. 2. Treatment algorithm for stenoses of Stensen's duct system (from Koch et al., 2009<sup>50</sup>, mod.).

salivary duct surgery (in submandibular glands more than in parotid glands). Overall, the scores improved less after treatment for sialadenitis not caused by sialolithiasis in comparison with sialolithiasis-caused sialadenitis<sup>56</sup>. These results suggest that successful treatment for patients with gland obstruction that is not caused by sialolithiasis – or at least achieving a balanced situation during the longer-term follow-up – continues to be a challenge.

## Conclusions

Ultrasound and sialendoscopy play an extremely important role in the diagnosis and treatment of salivary duct stenoses. They allow rapid, low-cost diagnosis with simultaneous planning and implementation of treatment. In general, the quality of the tissue in the stenotic region is important for deciding which treatment may be appropriate. In sialendoscopy-based treatment strategies in patients with an intact, unincised ductal system, intraductal cortisone instillation appears to have a positive effect on inflammatory and fibrotic processes. Inflammatory stenoses can often be treated by irrigation with cortisone, whereas fibrous stenoses require additional surgical treatment in the majority of cases. However, a wide range of procedures are needed to maximise the number of successful treatments. These include different methods of transoral ductal surgery in both glands.

In the submandibular duct, the location and extent of the stenosis play a very important part in the choice of treatment modality. Due to the area's good accessibility, transoral ductal surgery is the most important method. The more central the location of the stenosis, however, the more important interventional sialendoscopy becomes.

In parotid duct stenoses, the concept that there are different types of stenosis in the duct has been confirmed by an extended analysis. Clear and significant differences between these types are evident. While inflammatory stenosis may be a precursor form of fibrotic stenosis, stenosis associated with webs and megaduct appears to be a completely separate type. Interventional sialendoscopy being the treatment of first choice, these significant differences between the various types of stenosis appear to support the use of different treatment strategies.

The development of minimally invasive treatment protocols and treatment algorithms (Figs. 1, 2) has made it possible to permanently relieve symptoms, with minimal morbidity, while preserving the function of the salivary glands. This is accompanied by a high level of patient acceptance for these treatment strategies. Removal of the gland is the last choice if relevant symptoms are present and the gland parenchyma is not showing a tendency to atrophy.

## References

- Nahlieli O, Shacham R, Yoffe B, et al. *Diagnosis and treatment of strictures and kinks in salivary gland ducts*. J Oral Maxillofac Surg 2001;59:484-90.
- Marchal F, Dulguerov P, Becker M, et al. *Submandibular diagnostic and interventional sialendoscopy: new procedure for ductal disorders*. Ann Otol Rhinol Laryngol 2002;111:27-35.
- Koch M, Zenk J, Bozzato A, et al. *Sialoscopy in cases of unclear swelling of the major salivary glands*. Otolaryngol Head Neck Surg 2005;133:863-8.
- Ngu RK, Brown JE, Whaites EJ, et al. *Salivary duct strictures: nature and incidence in benign salivary obstruction*. Dentomaxillofac Radiol 2007;36:63-7.
- Koch M, Zenk J, Iro H. *Diagnostic and interventional sialoscopy in obstructive diseases of the salivary glands*. HNO 2008;56:139-44.
- Yu C, Yang C, Zheng L, et al. *Endoscopic observation and strategic management of obstructive submandibular sialadenitis*. J Oral Maxillofac Surg 2010;68:1770-5.
- Lee LI, Pawar RR, Whitley S, et al. *Incidence of different causes of benign obstruction of the salivary glands: retrospective analysis of 493 cases using fluoroscopy and digital subtraction sialography*. Br J Oral Maxillofac Surg 2015;53:54-7.
- Chuangqi Y, Chi Y, Lingyan Z. *Sialendoscopic findings in patients with obstructive sialadenitis: long-term experience*. Br J Oral Maxillofac Surg 2013;51:337-41.
- Vashishta R, Gillespie MB. *Salivary endoscopy for idiopathic chronic sialadenitis*. Laryngoscope 2013;123:3016-20.
- Koch M, Iro H, Kunzel J, et al. *Diagnosis and gland-preserving minimally invasive therapy for wharton's duct stenoses*. Laryngoscope 2012; 122: 552-8
- Koch M, Iro H. *Extended and treatment-oriented classification of parotid duct stenosis*. Laryngoscope 2017;127:366-71.
- Baurmash HD. *Chronic recurrent parotitis: a closer look at its origin, diagnosis, and management*. J Oral Maxillofac Surg 2004;62:1010-8.
- Koch M, Iro H, Zenk J. *Role of sialoscopy in the treatment of Stensen's duct strictures*. Ann Otol Rhinol Laryngol 2008;117:271-8.
- Kopec T, Szyfter W, Wierzbicka M, et al. *Stenoses of the salivary ducts-sialendoscopy based diagnosis and treatment*. Br J Oral Maxillofac Surg 2013;51:e174-7.
- Gallo A, Benazzo M, Capaccio P, et al. *Sialoendoscopy: state of the art, challenges and further perspectives*. Round Table, 101<sup>st</sup> SIO National Congress, Catania 2014. Acta Otorhinolaryngol Ital 2015;35:217-33.
- Reddy R, White DR, Gillespie MB. *Obstructive parotitis secondary to an acute masseteric bend*. ORL J Otorhinolaryngol Relat Spec 2012;74:12-5.
- Harrison JD. *Causes, natural history, and incidence of salivary stones and obstructions*. Otolaryngol Clin North Am 2009;42:927-47.
- Wang S, Marchal F, Zou Z, et al. *Classification and management of chronic sialadenitis of the parotid gland*. J Oral Rehabil 2009;36:2-8.
- Newkirk KA, Ringel MD, Wartofsky L, et al. *The role of radioactive iodine in salivary gland dysfunction*. Ear Nose Throat J 2000;79:460-8.
- Qi S, Liu X, Wang S. *Sialoendoscopic and irrigation findings in chronic obstructive parotitis*. Laryngoscope 2005;115:541-5.
- Koch M, Iro H, Zenk J. *Sialendoscopy-based diagnosis*

- and classification of parotid duct stenoses. *Laryngoscope* 2009;119:1696-703.
- 22 Chikamatsu K, Shino M, Fukuda Y, et al. *Recurring bilateral parotid gland swelling: two cases of sialodochitis fibrinosa*. *J Laryngol Otol* 2006;120:330-3.
  - 23 Capaccio P, Cuccarini V, Ottaviani F, et al. *Comparative ultrasonographic, magnetic resonance sialographic, and videoendoscopic assessment of salivary duct disorders*. *Ann Otol Rhinol Laryngol* 2008;117:245-52.
  - 24 Zenk J, Iro H, Klintworth N, et al. *Diagnostic imaging in sialadenitis*. *Oral Maxillofac Surg Clin North Am* 2009;21:275-92.
  - 25 Tanaka T, Ono K, Ansai T, et al. *Dynamic magnetic resonance sialography for patients with xerostomia*. *Oral Surg Oral Med Oral Pathol Oral Radiol Endod* 2008;106:115-23.
  - 26 Gadodia A, Seith A, Sharma R, et al. *Magnetic resonance sialography using CISS and HASTE sequences in inflammatory salivary gland diseases: comparison with digital sialography*. *Acta Radiol* 2010;51:156-63.
  - 27 Bozzato A, Hertel V, Bumm K, et al. *Salivary simulation with ascorbic acid enhances sonographic diagnosis of obstructive sialadenitis*. *J Clin Ultrasound* 2009;37:329-32.
  - 28 Yuasa K, Nakhyama E, Ban S, et al. *Submandibular gland duct endoscopy. Diagnostic value for salivary duct disorders in comparison to conventional radiography, sialography, and ultrasonography*. *Oral Surg Oral Med Oral Pathol Oral Radiol Endod* 1997;84:578-81.
  - 29 Marchal F, Chossegros C, Faure F, et al. *Salivary stones and stenosis. A comprehensive classification*. *Rev Stomatol Chir Maxillofac* 2008;109:233-6.
  - 30 Christensen DR, Mashberg A, Turk MH. *Correction of extreme dilatation of Stensen's duct resulting from chronic partial obstruction*. *J Oral Surg* 1973;31:136-8.
  - 31 Iqbal SM, Singh RR, Dewangan GL. *Sialoceles of Stensen's duct (a case report)*. *J Laryngol Otol* 1986;100:363-5.
  - 32 Laudenbach P, Fain J, Canet E. *[Duct cysts of the parotid. Complications of dilated Stensen's duct]*. *Rev Stomatol Chir Maxillofac* 1990;91 Suppl 1:78-81.
  - 33 Mandel L. *The grossly dilated Stensen's duct: case reports*. *J Oral Maxillofac Surg* 2007;65:2089-94.
  - 34 Baurmash HD. *Sialectasis of Stensen's duct with an extraoral swelling: a case report with surgical management*. *J Oral Maxillofac Surg* 2007;65:140-3.
  - 35 Yoon YH, Rha KS, Choi JW, et al. *Sialectasis of Stensen's duct: an unusual case of recurrent cheek swelling*. *Eur Arch Otorhinolaryngol* 2009;266:573-6.
  - 36 Lohia S, Joshi AS. *Idiopathic sialectasis of the Stensen's duct treated with marsupialisation*. *BMJ Case Rep* 2013;2013.
  - 37 McGurk M, MacBean AD, Fan KF, et al. *Endoscopically assisted operative retrieval of parotid stones*. *Br J Oral Maxillofac Surg* 2006;44:157-60.
  - 38 Marchal F. *A combined endoscopic and external approach for extraction of large stones with preservation of parotid and submandibular glands*. *Laryngoscope* 2007;117:373-7.
  - 39 Koch M, Iro H, Zenk J. *Combined endoscopic-transcutaneous surgery in parotid gland sialolithiasis and other ductal diseases: reporting medium- to long-term objective and patients' subjective outcomes*. *Eur Arch Otorhinolaryngol* 2013;270:1933-40.
  - 40 Koch M, Kunzel J, Iro H, et al. *Long-term results and subjective outcome after gland-preserving treatment in parotid duct stenosis*. *Laryngoscope* 2014;124:1813-8.
  - 41 Brown JE. *Interventional sialography and minimally invasive techniques in benign salivary gland obstruction*. *Semin Ultrasound CT MR* 2006;27:465-75.
  - 42 McGurk M, Escudier MP, Thomas BL, et al. *A revolution in the management of obstructive salivary gland disease*. *Dent Update* 2006;33:28-30 33-6.
  - 43 Buckenham T, Guest P. *Interventional sialography using digital imaging*. *Australas Radiol* 1993;37:76-9.
  - 44 Roberts DN, Juman S, Hall JR, et al. *Parotid duct stenosis: interventional radiology to the rescue*. *Ann R Coll Surg Engl* 1995;77:444-6.
  - 45 Brown AL, Shepherd D, Buckenham TM. *Per oral balloon sialoplasty: results in the treatment of salivary duct stenosis*. *Cardiovasc Intervent Radiol* 1997;20:337-42.
  - 46 Waldman DL, Westesson PL, Hengerer AS. *Balloon dilation of parotid duct stenosis*. *J Vasc Interv Radiol* 1998;9:167-8.
  - 47 Drage NA, Brown JE, Escudier MP, et al. *Balloon dilatation of salivary duct strictures: report on 36 treated glands*. *Cardiovasc Intervent Radiol* 2002;25:356-9.
  - 48 Salerno S, Lo Casto A, Comparetto A, et al. *Sialodochoplasty in the treatment of salivary-duct stricture in chronic sialoadenitis: technique and results*. *Radiol Med* 2007;112:138-44.
  - 49 Papadaki ME, McCain JP, Kim K, et al. *Interventional sialoendoscopy: early clinical results*. *J Oral Maxillofac Surg* 2008;66:954-62.
  - 50 Koch M, Zenk J, Iro H. *Algorithms for treatment of salivary gland obstructions*. *Otolaryngol Clin North Am* 2009;42:1173-92.
  - 51 Ardekian L, Shamir D, Trabelsi M, et al. *Chronic obstructive parotitis due to strictures of Stensen's duct - our treatment experience with sialoendoscopy*. *J Oral Maxillofac Surg* 2010;68:83-7.
  - 52 Koch M, Iro H, Klintworth N, et al. *Results of minimally invasive gland-preserving treatment in different types of parotid duct stenosis*. *Arch Otolaryngol Head Neck Surg* 2012;138:804-10.
  - 53 Kroll T, Finkensieper M, Sharma SJ, et al. *Short-term outcome and patient satisfaction after sialendoscopy*. *Eur Arch Otorhinolaryngol* 2013;270:2939-45.
  - 54 Pace CG, Hwang KG, Papadaki ME, et al. *Sialadenitis without sialolithiasis treated by sialendoscopy*. *J Oral Maxillofac Surg* 2015;73:1748-52.
  - 55 Gillespie MB, O'Connell BP, Rawl JW, et al. *Clinical and quality-of-life outcomes following gland-preserving surgery for chronic sialadenitis*. *Laryngoscope* 2015;125:1340-4.
  - 56 Aubin-Pouliot A, Delagnes EA, Chang JL, et al. *Sialendoscopy-assisted surgery and the chronic obstructive sialadenitis symptoms questionnaire: a prospective study*. *Laryngoscope* 2016;126:1343-8.
  - 57 Capaccio P, Torretta S, Di Pasquale D, et al. *The role of interventional sialendoscopy and intraductal steroid therapy in patients with recurrent sine causa sialadenitis: a prospective cross-sectional study*. *Clin Otolaryngol* 2017;42:148-55.
  - 58 Maresh A, Kutler DI, Kacker A. *Sialoendoscopy in the diag-*

- nosis and management of obstructive sialadenitis*. Laryngoscope 2011;121:495-500.
- <sup>59</sup> Labrunie G, Lair J, Touzet C. [Bypass whartonostomy (author's transl)]. Rev Stomatol Chir Maxillofac 1981;82:70-5.
- <sup>60</sup> Rontal M, Rontal E. *The use of sialodochoplasty in the treatment of benign inflammatory obstructive submandibular gland disease*. Laryngoscope 1987;97:1417-21.
- <sup>61</sup> Karas ND. *Surgery of the salivary ducts*. Atlas Oral Maxillofac Surg Clin North Am 1998;6:99-116.
- <sup>62</sup> Mandel L, Kaynar A. *Surgical bypass of submandibular duct stricture*. Oral Surg Oral Med Oral Pathol Oral Radiol Endod 1999;88:532-3.
- <sup>63</sup> Zenk J, Constantinidis J, Al-Kadah B, et al. *Transoral removal of submandibular stones*. Arch Otolaryngol Head Neck Surg 2001;127:432-6.
- <sup>64</sup> McGurk M. *Surgical release of a stone from the hilum of the submandibular gland: a technique note*. Int J Oral Maxillofac Surg 2005;34:208-10.
- <sup>65</sup> Motamed M, Laugharne D, Bradley PJ. *Management of chronic parotitis: a review*. J Laryngol Otol 2003;117:521-6.
- <sup>66</sup> Nahlieli O, Bar T, Shacham R, et al. *Management of chronic recurrent parotitis: current therapy*. J Oral Maxillofac Surg 2004;62:1150-5.
- <sup>67</sup> Galili D, Marmary Y. *Juvenile recurrent parotitis: clinicoradiologic follow-up study and the beneficial effect of sialography*. Oral Surg Oral Med Oral Pathol 1986;61:550-6.
- <sup>68</sup> Bowling DM, Ferry G, Rauch SD, et al. *Intraductal tetracycline therapy for the treatment of chronic recurrent parotitis*. Ear Nose Throat J 1994;73:262-74.
- <sup>69</sup> Antoniadis D, Harrison JD, Epivatianos A, et al. *Treatment of chronic sialadenitis by intraductal penicillin or saline*. J Oral Maxillofac Surg 2004;62:431-4.
- <sup>70</sup> Munzel M, Meister P. [On the ligation of Stenon's duct in chronic-recurrent parotitis (author's transl)]. Laryngologie Rhinologie Otologie 1977;56:902-6.
- <sup>71</sup> Nichols RD. *Surgical treatment of chronic suppurative parotitis*. A critical review. Laryngoscope 1977;87:2066-81.
- <sup>72</sup> Cohen D, Gatt N, Olschwang D, et al. *Surgery for prolonged parotid duct obstruction: a case report*. Otolaryngol Head Neck Surg 2003;128:753-4.
- <sup>73</sup> O'Brien CJ, Murrant NJ. *Surgical management of chronic parotitis*. Head Neck 1993;15:445-9.
- <sup>74</sup> Sadeghi N, Black MJ, Frenkiel S. *Parotidectomy for the treatment of chronic recurrent parotitis*. J Otolaryngol 1996;25:305-7.
- <sup>75</sup> Moody AB, Avery CM, Walsh S, et al. *Surgical management of chronic parotid disease*. Br J Oral Maxillofac Surg 2000;38:620-22.
- <sup>76</sup> Amin MA, Bailey BM, Patel SR. *Clinical and radiological evidence to support superficial parotidectomy as the treatment of choice for chronic parotid sialadenitis: a retrospective study*. Br J Oral Maxillofac Surg 2001;39:348-52.
- <sup>77</sup> Patel RS, Low TH, Gao K, et al. *Clinical outcome after surgery for 75 patients with parotid sialadenitis*. Laryngoscope 2007;117:644-7.
- <sup>78</sup> Ryan WR, Chang JL, Eisele DW. *Surgeon-performed ultrasound and transfacial sialoendoscopy for complete parotid duct stenosis*. Laryngoscope 2014;124:418-20.
- <sup>79</sup> Ellies M, Gottstein U, Rohrbach-Volland S, et al. *Reduction of salivary flow with botulinum toxin: extended report on 33 patients with drooling, salivary fistulas, and sialadenitis*. Laryngoscope 2004;114:1856-60.
- <sup>80</sup> Capaccio P, Torretta S, Osio M, et al. *Botulinum toxin therapy: a tempting tool in the management of salivary secretory disorders*. Am J Otolaryngol 2008;29:333-8.
- <sup>81</sup> Kruegel J, Winterhoff J, Koehler S, et al. *Botulinum toxin: A noninvasive option for the symptomatic treatment of salivary gland stenosis - a case report*. Head Neck 2010;32:959-63.
- <sup>82</sup> Diamant H. *Ligation of the parotid duct in chronic recurrent parotitis*. Acta Otolaryngol 1958;49:375-80.
- <sup>83</sup> Morgan WR. *Parotid duct ligation and tympanic neurectomy in chronic recurrent parotiditis*. Arch Otolaryngol 1973;98:179-82.
- <sup>84</sup> Harrison JD, Fouad HM, Garrett JR. *The effects of ductal obstruction on the acinar cells of the parotid of cat*. Arch Oral Biol 2000;45:945-9.
- <sup>85</sup> Guerre A, Hartl DM, Katz P. [Alpha-1-blockers (alfuzosin) for obstructive salivary gland diseases]. Rev Stomatol Chir Maxillofac 2010;111:135-9.
- <sup>86</sup> Strychowsky JE, Sommer DD, Gupta MK, et al. *Sialendoscopy for the management of obstructive salivary gland disease: a systematic review and meta-analysis*. Arch Otolaryngol Head Neck Surg 2012;138:541-7.
- <sup>87</sup> Atienza G, Lopez-Cedrun JL. *Management of obstructive salivary disorders by sialendoscopy: a systematic review*. Br J Oral Maxillofac Surg 2015;53:507-19.
- <sup>88</sup> Meier BA, Holst R, Schousboe LP. *Patient-perceived benefit of sialendoscopy as measured by the Glasgow Benefit Inventory*. Laryngoscope 2015;125:1874-8.

Received: September 15, 2016 - Accepted: December 12, 2016

Address for correspondence: Michael Koch, Department of Otorhinolaryngology, Head and Neck Surgery Friedrich Alexander University of Erlangen-Nuremberg, Waldstrasse 1 D-91054 Erlangen, Germany. Tel. +49 9131 85 43839. Fax +49 9131 85 33833. E-mail: Michael.Koch@uk-erlangen.de

# Complications of traditional and modern therapeutic salivary approaches

## *Complicanze degli approcci terapeutici tradizionali e moderni alle ghiandole salivari*

O. NAHLIELI

Oral and Maxillofacial Surgery Department Barzilai Medical Center, Ashkelon, Israel. Affiliated to the Faculty of Medicine, Ben Gurion University of the Negev, Beer Sheva, Israel

### SUMMARY

The morbidity following traditional surgery of the salivary glands is well documented and includes postsurgical complications such as the Frey's syndrome, complete or partial facial nerve damage, facial scarring, greater auricular nerve numbness, sialocoeles and salivary fistula. The avulsion of the salivary duct, secondary strictures, gland swelling, salivary fistulas and perforations (false rout), traumatic ranulas, and the lingual nerve paraesthesia are the main endoscopy-related complications. In general, the rate of postsurgical complications after modern advanced minimally invasive surgical interventions is significantly lower compared with traditional surgery of the salivary glands. However, such comparisons cannot be performed because up-to-date traditional and minimally invasive surgical techniques are applied to different salivary disorders. Combinations of various minimally invasive techniques are also possible. There is no clear borderline between "traditional" and "modern" surgery of the salivary glands. It is appropriate to write about gradual replacement of old techniques with newer ones, and this process has no traffic lights.

KEY WORDS: Complications • Minimally invasive surgery • Salivary glands

### RIASSUNTO

*Le complicanze dopo chirurgia tradizionale delle ghiandole salivari sono notoriamente documentate in letteratura e comprendono: la sindrome di Frey, la paralisi parziale o completa del nervo facciale, le lesioni del nervo grande auricolare, lo scialocele, la fistola salivare e gli esiti cicatriziali a livello della cute del volto. Per contro, le principali complicanze secondarie ai trattamenti endoscopici risultano essere l'avulsione del dotto salivare, le stenosi secondarie, la tumefazione ghiandolare, le fistole salivari, le perforazioni da falsa strada, le ranule post-traumatiche e le parestesie del nervo linguale. In generale, le moderne tecniche di chirurgia minimamente invasiva mostrano un tasso di complicanze post-operatorie significativamente inferiore rispetto alla chirurgia tradizionale delle ghiandole salivari. Tuttavia, un confronto tra le due strategie chirurgiche non può svolgersi correttamente perché esse sono applicate a diversi ambiti patologici. La combinazione di più tecniche di chirurgia minimamente invasiva rende sfumata la linea di confine tra chirurgia "tradizionale" e "moderna", risultando utile e necessaria una più dettagliata descrizione del progressivo abbandono delle tecniche tradizionali a favore delle nuove.*

PAROLE CHIAVE: *Complicanze • Chirurgia minimamente invasiva • Ghiandole salivari*

Acta Otorhinolaryngol Ital 2017;37:142-147

## Introduction

The removal of the salivary gland (parotidectomy, submandibular sialadenectomy, sublingual sialadenectomy) for benign or malignant tumour as well as non-neoplastic disease was a common procedure in the previous century. The morbidity following such traditional surgery is well documented and includes postsurgical complications such as postoperative partial or complete facial nerve damage, Frey's syndrome, facial scarring, greater auricular nerve numbness, sialocoeles, and salivary fistula. Taking both medical necessity and aesthetic sentiments into consideration, the need for minimally invasive approaches to the diseases of the salivary glands was well understood. A minimally invasive approach, however, is limited to non-neoplastic diseases,

mainly sialolithiasis and ductal obstructions. A method for salivary gland calculus disintegration by shock waves was proposed already in the 1980s<sup>1,2</sup>. Shock waves produced by a Dornier lithotripter are able to destruct large salivary stones, but no practitioner can be sure that all the fragments will be washed out from the gland by saliva.

Therefore, an endoscopic technique was attempted. This approach was developed in the 1990s parallel to further improvements in lithotripsy<sup>3-6</sup>. Sialoendoscopes with stone-extraction baskets or forceps and balloon catheters were developed for therapeutic purposes. While tumours of the salivary glands are not to be treated by minimally invasive surgery, obstructive sialadenitis, with or without sialolithiasis, strictures and kinks, is treatable by minimally invasive techniques. Therefore, the traditional surgical

and the minimally invasive surgical approaches currently coexist. It might be easy to compare rates of postsurgical complications after these two types of operations, but there are at least two obstacles for such an analysis. First, today sialadenectomy and minimally invasive surgery are applied to different diseases of the glands. Most cases with sialolithiasis and ductal obstructions are treated by minimally invasive means, while tumours of the parotid submandibular or sublingual gland will be managed with various types of sialadenectomy. Second, both surgical approaches partially overlap and in some cases “video-assisted” or “endoscopically-assisted” traditional surgery is currently applied. Minimally invasive approaches, or “less aggressive surgery”, for traditional parotidectomy suggest selective superficial lobe parotidectomy instead of superficial lobectomy. Combinations of various minimally invasive techniques are also possible. There is no clear borderline between “traditional” and “modern” surgery of the salivary glands. It is thus appropriate to write about gradual replacement of the old techniques with the new ones, and this process has no traffic lights.

All current surgical approaches to the salivary gland diseases can be classified in the following way:

- standard traditional surgery (i.e. parotidectomy, sialadenectomy);
- less aggressive traditional surgery (i.e. partial parotidectomy, extracapsular dissection);
- video-assisted/endoscopically assisted traditional surgery;
- transoral/intraoral surgical approaches;
- endoscopically assisted transoral/intraoral surgical approaches;
- the extracorporeal shock-wave lithotripsy (ESWL);
- a combination of ESWL with a sialoendoscopic approach;
- direct sialoendoscopic removal of stones via salivary ducts and/or endoscopic assistance techniques.

Postsurgical complication therefore can be classified into:

- surgical complications;
- endoscopy-related complications;
- ESWL-related complications.

## Surgical complications of traditional surgery

**Parotidectomy.** Article titles such as “Parotidectomy: surgery in evolution” or “Evolution and changing trends in surgery for benign parotid tumours” clearly indicates the current situation in the salivary surgery and its gradual movement towards minimally invasive techniques<sup>7,8</sup>. Yet, benign and malignant tumours are to be operated traditionally. Such traditional surgical approaches include partial superficial parotidectomy, superficial parotidectomy with preparation of the facial nerve and total parotidectomy with or without preservation of the facial nerve (radical parotidectomy). Attempts

to perform selective deep-lobe parotidectomy with preservation of the superficial lobe in benign cases were made in the 1990s<sup>9,10</sup>. It was demonstrated, however, that temporary facial nerve dysfunction had a significantly higher incidence if tumours were located in the deep lobe of the gland<sup>11</sup>. At the same time, selective deep lobe parotidectomy preserves the function of the gland<sup>12</sup>. The rates of postsurgical complications in the 2000s-2010s after total, selected superficial parotidectomy, or deep lobe parotidectomy are presented in the Table I. In general, these rates are acceptable. In the 1980s, for example, the rate of temporary facial damage of 28% was considered low<sup>27</sup>, while today such a rate is considered as high. We can trace some decline in the rates of complications compared to the results of the 1980s<sup>27-30</sup>, but in general this decline is not very impressive. Frey’s syndrome (symptomatic gustatory sweating and inflammation of the skin over the site of the parotidectomy) and the facial nerve involvement remain the main unsolved problems, especially in total/radical cases.

I will not discuss the extracapsular dissection complication rate versus traditional superficial parotidectomy approach in this review article, because this technique needs special attention and will be discussed separately in a special article in this salivary disorders issue.

**Submandibular sialadenectomy, sublingual sialadenectomy.** Submandibular gland excision is traditionally performed using a transcervical approach. In addition to tumours, failure to remove submandibular calculi via minimal invasive methods may also require sialadenectomy. Swelling in the floor of the mouth (ranula, plunging ranula) can occur after submandibular sialadenectomy and may require removal of the sublingual gland as well<sup>31</sup>. Currently, even a transcervical approach to the submandibular gland can be endoscopically-assisted<sup>32</sup>. Submandibular

**Table I.** Rates of postsurgical complications in current literature in cases of total parotidectomy<sup>7-9 11 13-15 17-21 23 25</sup>, superficial/partial parotidectomy<sup>11 13 15-20 22 23 25</sup>, and selected deep lobe parotidectomy<sup>10-12 23 24 26</sup>.

| Complications                       | Total excision | Deep lobe excision | Superficial excision |
|-------------------------------------|----------------|--------------------|----------------------|
| Temporary facial weakness           | 41.7%-9%       | 26%-7%             | 20%-9%               |
| Permanent facial weakness           | 9%-0%          | 7%-0%              | 7%-0%                |
| Post-operative hematoma             | 7%-0%          | 3%-0%              | 3.2%-0%              |
| Frey’s syndrome                     | 25%-1%         | 0%                 | 17%-1%               |
| Salivary fistula                    | 11%-0%         | Not reported       | 1.7%                 |
| Sialocele                           | 16%-0%         | 1%-0%              | 26%-0%               |
| Infection                           | 1.5%-0%        | 1%-0%              | 1%-0%                |
| Sensory deficit                     | 20%-0%         | 2%-0%              | 3%-0%                |
| Seroma                              | 3%-0%          | Not reported       | Not reported         |
| Keloid formation                    | 1%-0%          | Not reported       | Not reported         |
| Greater auricular nerve anaesthesia | 10.4%-0%       | Not reported       | 5%-0%                |



gland excision in malignant cases is followed by subsequent neck dissection or the elective neck dissection because cancers in the submandibular gland are generally more aggressive than the same histologic types in the parotid gland<sup>33,34</sup>. Neck dissection has its own postsurgical complications.

In cases that involve submandibular gland excision, the majority of complications arise because of mistakes in identification of the lingual nerve, the marginal mandibular nerve, and the submandibular duct (rare)<sup>35</sup>. Injuries of the marginal mandibular branch of the facial nerve is the most frequent postsurgical complication that can end with permanent paresis or paralysis in 1-7% of cases, and lingual nerve injury is the second most frequent nerve damage with a 0.5-4.4% risk of paralysis<sup>35-39</sup>. This complication may occur because of adhesion or partial adhesion between Wharton's duct and the lingual nerve. If a transoral surgical approach is chosen, specific complications might include oedema at the mouth base, lingual ecchymosis and postoperative temporary abnormal tongue sensation<sup>40</sup>.

Xerostomia and decreased salivary flow in a resting position is a specific long term complication after submandibular sialadenectomy because the submandibular glands are responsible for 70% of resting salivary flow. Up to 22% of operated patients can be affected with it<sup>37</sup>. Other complications might include a heterotrophic scar, keloid formation, Frey's syndrome (rare in submandibular cases), and injuries to the submandibular duct, ranula and intraoperative bleeding<sup>41</sup>. The damage to the hypoglossal nerve or to the cervical branch of the facial nerve are possible but very rare<sup>35,42</sup>.

Calculi, ranulas and malignant sublingual gland neoplasms are rare. In cases with cancer, wide tumour-free surgical margin excision is the treatment of choice and the above mentioned nerves can be damaged<sup>43</sup>. Injuries of Wharton's duct are also possible, but in general the rate of complications is somewhat lower than in cases of submandibular surgery<sup>41,44</sup>. Xerostomia and Frey's syndrome are not observed.

Transoral/intraoral surgical approaches with or without endoscopic assistance are mainly used for removal of salivary stones located in the ducts including giant sialoliths<sup>45</sup>. However, this technique can be applied for removal of hiloparenchymal submandibular calculi as well<sup>46</sup>. In general, authors indicate a very low rate of complications (3%-0%), such as functional disorder of the marginal mandibular, hypoglossal and lingual nerves, or wound haematoma formation<sup>45-48</sup>. It should be remembered that these results are mostly limited to cases of sialolithiasis.

## Endoscopy-related complications

While endoscopic and endoscopy-assisted surgeries can have general postsurgical complications such as infection or haematoma<sup>49</sup>, endoscopic interventions may produce several specific complications<sup>50</sup>. A combined or endoscopy-assisted surgical technique is usually applied for removing large sialoliths from the salivary glands or after

failure of a pure endoscopic approach. The only contraindication for the endoscopic intervention is acute sialadenitis. The authors agree that most of the sialendoscopy complications are minor, yet some require specific attention<sup>49-52</sup>. Endoscopy-related complications are different origin in comparison with the above described traditional surgery complications, and direct comparison of risks is difficult. While most complications of radical surgery are neurological, these types of complications are minimal when sialendoscopy is used. Facial palsy/paralysis or Frey's syndrome never occur<sup>51,53,54</sup>. Lingual nerve paraesthesia might occur if the submandibular gland is involved, but the risk of complication is minimal (< 0.7%)<sup>54,55</sup>.

Major endoscopy-related complications are defined as iatrogenic insults directly responsible for additional procedures<sup>56,57</sup>. The generally accepted definition for minor complications indicate them as events leading to either failure of the procedure, a second surgical procedure, a change in the surgical plan, or deviation from the planned course of events as a result of the procedure itself. Following these definitions, the major complications occur in only 2-3% of cases, and the minor complications occur in 19-23%<sup>50-58</sup>. The avulsion of the salivary duct, secondary strictures, gland swelling, salivary fistulas and perforations (false rout), traumatic ranulas, and lingual nerve paraesthesia are the main endoscopy-related complications.

*Avulsion of the duct* occurs during the removal of a calculus. The surgeon fixes a calculus in the wire basket and then tries to remove it from the duct. If traction efforts are excessive, avulsion can occur. This complication is rare, but is possible if the operation is performed by inexperienced surgeon.

*Secondary, or postoperative, strictures* of the salivary duct are the main complication following sialendoscopic procedures<sup>51-54,59</sup>. The risk for such a complication remains after each operative endoscopic surgery, but does not exceed 2-2.45%<sup>53,59,60</sup>. Strictures can be identified in both parotid and submandibular cases by continuous swelling of the gland following stone extraction without any evidence of additional or stone particle intraductally, and absence of saliva or reduced saliva secretion from the orifice of the affected gland. Most postoperative strictures are located near the orifice region, and successful dilation is possible in the majority of cases<sup>53-55,60</sup>.

*The perforation* (false rout) of the salivary duct occurs either near the orifice of the duct due to separation of the ductal wall from the oral mucosa or during sialendoscopic mechanical procedures intraductally like stone removal and stricture dilation<sup>59-61</sup>. The endoscopic identification of this pathology is possible, but ductal structures of the lumen can be overlooked. Another sign is the excessive swelling in the region of the perforation due to the leakage of the irrigation solution to surrounding tissue.

Post-operative *gland swelling* occurs when the main goal of the minimally invasive surgery was achieved, i.e. the gland was preserved. Excessive swelling following si-

alendoscopy usually occurs because of the obstruction of the main salivary duct, perforation of the duct, or excessive irrigation<sup>53 54 59</sup>. Such gland swelling usually resolves in approximately 24-48 hours<sup>54 58 62</sup>. While generally not hazardous, this complication may cause airway compromise after submandibular surgery<sup>63</sup>. Therefore, if bilateral submandibular intervention is planned, a surgeon should examine the gland and oral cavity after operating the first gland and determine whether it is safe to proceed with the second gland.

*Ranula* formation is a well documented outcome of surgical procedures in the floor of the mouth. Formation of ranula can occur in patients following submandibular sialendoscopy<sup>55 60 64 65</sup>. In submandibular or sublingual endoscopic surgery, the risk is 1-2.45%<sup>64-66</sup>. The formation of ranula is proportional to the extent of the procedure and patients who underwent endoscopic assisted intervention like stretching procedure have a reasonable risk for this complication. Ranula is easily identified by swelling, mostly blue, in the floor of the oral cavity. Successful marsupialisation occurs in majority of cases.

*Lingual nerve paraesthesia* is a rare complication of sialendoscopy of the submandibular gland (0.7%-0.4%)<sup>52 61</sup>. It can happen mainly in an endoscopic assisted procedure - the stretching technique. During a pure intraductal endoscopic procedure, it can happen only due to perforation of the salivary duct. Usually, the lesion is identified by nerve assessment. Changing paraesthesia into anaesthesia is even rarer. If the nerve is damaged, steroid treatment should be administered immediately after correct diagnosis. The currently analysed cases show that the risk of this complication exists when the stones are located in the posterior third of the main duct<sup>52 61</sup>.

Salivary fistulas, sialoceles, minor ductal tears, minor haemorrhage and acute masseteric bend, while reported, should be considered as extremely rare complications<sup>52 61 67 68</sup>. Large or recalcitrant parotid stones can leave a persistent stone fragment or produce obstructive symptoms due to a fibrous stricture that is also very rare. The rates of the postsurgical endoscopy-related complications are presented in Table II.

### Complications of the extracorporeal shock-wave lithotripsy

ESWL delivers 1000-1500 shock waves per session. External lithotripsy is applied with low energy levels up to 130 atm. The lithotripter generates enough power to produce a cavitation effect. The shock waves disconnect the salivary stone from the ductal wall, reduce the volume of the stone and can crush the stone. Due to the low energy levels of the shockwaves, the procedure is not painful and does not require anaesthesia. No specific ESWL-related side effects have been reported<sup>2 6 54 70-73</sup>.

Sonographic/ultrasonic lithotripsy, however, should be distinguished from laser lithotripsy of salivary stones.

**Table II.** Rates of the postsurgical endoscopy-related complications in the current literature<sup>49-68</sup>.

| Complication ↓/<br>gland →    | Parotid | Submandibular | Sublingual   |
|-------------------------------|---------|---------------|--------------|
| Strictures                    | 4%-2%   | 1%-2%         | -            |
| Ranula                        | -       | 1.68%         | 0.5%         |
| Lingual nerve<br>paresthesia  | -       | 0.5%-1%       | 0.5%         |
| Avulsion of the duct          | 0.5%    | 0.5%          | -            |
| Gland swelling<br>(temporary) | 5%-10%  | 7%-12%        | Not reported |
| Perforation of the<br>duct    | 0.5%    | 0.5%          | -            |

Subsequent fragmentation of salivary stones can be performed with a Ho:YAG laser or Er:YAG laser in a near-contact manner, but for this technique damage of salivary duct mucosa, ductal stenosis and salivary fistula are reported as rare complications (less than 2%)<sup>74-76</sup>. A newly approved pneumatic lithotripter is still under investigation. An intraparenchymal repulsion of a residual fragment of a stone has been reported as a complication<sup>77</sup>. The main problem with the ESWL is not the rate of specific complications, but its inability to fragment all stones and remove all the fragments from the ducts. Total elimination of the stone by lithotripsy alone can be achieved in 30-50% of cases<sup>2 6 54 70 71 78</sup>. The success of the technique is more impressive when ESWL is combined with sialoendoscopic intervention<sup>78</sup>.

### Conclusions

In general, the rate of postsurgical complications after modern advanced minimally invasive surgical interventions is significantly lower compared to traditional surgery of the salivary glands. However, such a comparison cannot be performed because up-to-date traditional and minimally invasive surgical techniques are currently applied to different salivary disorders.

### References

- Marmary Y. A novel and non-invasive method for the removal of salivary gland stones. *Int J Oral Maxillofac Surg* 1986;15:585-7.
- Iro H, Benzel W, Zenk J, et al. Minimally invasive treatment of sialolithiasis using extracorporeal shock waves. *HNO* 1993;41:311-6.
- Katz P. Endoscopy of the salivary glands. *Ann Radiol (Paris)* 1991;34:110-3.
- Katz P. New treatment method for salivary lithiasis. *Rev Laryngol Otol Rhinol (Bord)* 1993;114:379-82.
- Nahlieli O, Neder A, Baruchin AM. Salivary gland endoscopy: a new technique for diagnosis and treatment of sialolithiasis. *J Oral Maxillofac Surg* 1994;52:1240-2.
- Iro H, Zenk J, Waldfahrer F, et al. Extracorporeal shock wave

- lithotripsy of parotid stones. Results of a prospective clinical trial.* Ann Otol Rhinol Laryngol 1998;107:860-4.
- 7 Eviston TJ, Yabe TE, Gupta R, et al. *Parotidectomy: surgery in evolution.* ANZ J Surg 2016;86:193-9.
  - 8 Mantsopoulos K, Koch M, Klintworth N, et al. *Evolution and changing trends in surgery for benign parotid tumors.* Laryngoscope 2015;125:122-7
  - 9 Leverstein H, Van der Wal JE, Tiwari RM, et al. *Results of the surgical management and histopathological evaluation of 88 parotid gland Warthin's tumours.* Clin Otolaryngol Allied Sci 1997;22:500-3.
  - 10 Hussain A, Murray DP. *Preservation of the superficial lobe for deep-lobe parotid tumors: a better aesthetic outcome.* Ear Nose Throat J 2005;84:518,520-2,524.
  - 11 Ikoma R, Ishitoya J, Sakuma Y, et al. *Temporary facial nerve dysfunction after parotidectomy correlates with tumor location.* Auris Nasus Larynx 2014;41:479-84.
  - 12 Colella G, Giudice A, Rambaldi P, et al. *Parotid function after selective deep lobe parotidectomy.* Br J Oral Maxillofac Surg 2007;45:108-11.
  - 13 Thahim K, Udaipurwala IH, Kaleem M. *Clinical manifestations, treatment outcome and post-operative complications of parotid gland tumours - an experience of 20 cases.* J Pak Med Assoc 2013;63:1472-5.
  - 14 Thom JJ, Moore EJ, Price DL, et al. *The role of total parotidectomy for metastatic cutaneous squamous cell carcinoma and malignant melanoma.* JAMA Otolaryngol Head Neck Surg 2014;140:548-54.
  - 15 Kim BD, Lim S, Wood J, et al. *Predictors of adverse events after parotidectomy: a review of 2919 cases.* Ann Otol Rhinol Laryngol 2015;124:35-44.
  - 16 Plaza G, Amarillo E, Hernández-García E, et al. *The role of partial parotidectomy for benign parotid tumors: a case-control study.* Acta Otolaryngol 2015;135:718-21.
  - 17 El Fol HA, Beheiri MJ, Zaqri WA. *Comparison of the effect of total conservative parotidectomy versus superficial parotidectomy in management of benign parotid gland tumor: A systematic review.* J Craniomaxillofac Surg 2015. pii: S1010-5182(15)00012-8.
  - 18 Derin S, Erdogan S, Almac A, et al. *Parotid gland tumours in Turkish population: analysis of 165 patients.* Asian Pac J Cancer Prev 2015;16:3539-42.
  - 19 Maahs GS, Oppermann Pde O, Maahs LG, et al. *Parotid gland tumors: a retrospective study of 154 patients.* Braz J Otorhinolaryngol 2015;81:301-6.
  - 20 Achour I, Chakroun A, Ben Rhaïem Z, et al. *Surgery of pleomorphic adenoma of the parotid gland.* Rev Stomatol Chir Maxillofac Chir Orale 2015;116:129-31.
  - 21 Renkonen S, Sayed F, Keski-Säntti H, et al. *Reconstruction of facial nerve after radical parotidectomy.* Acta Otolaryngol.2015;135:1065-9.
  - 22 Yuen AP. *Small access postaural parotidectomy: an analysis of techniques, feasibility and safety.* Eur Arch Otorhinolaryngol 2016;273:1879-83.
  - 23 Vaiman M, Jabarin B, Abuita R. *Methylene blue staining in the parotid surgery: Randomized trial, 144 patients.* Am J Otolaryngol 2016;37:22-6.
  - 24 Vaiman M, Abuita R, Jabarin B. *Selective deep lobe parotid surgery for benign tumors.* Acta Otolaryngol 2015;135:1319-22.
  - 25 Correia-Sá IB, Correia-Sá M, Costa-Ferreira P, et al. *Eleven years of parotid gland surgery in a plastic and reconstructive department.* J Craniofac Surg 2016;27:e26-33.
  - 26 Olsen KD, Moore EJ. *Deep lobe parotidectomy: clinical rationale in the management of primary and metastatic cancer.* Eur Arch Otorhinolaryngol 2014; 271:1181-5.
  - 27 Brusati R, Bozzetti A, Chiapasco M. *Facial nerve and parotid surgery.* J Craniomaxillofac Surg 1987;15:278-80.
  - 28 Singleton GT, Cassisi NJ. *Frey's syndrome: incidence related to skin flap thickness in parotidectomy.* Laryngoscope 1980;90(10 Pt 1):1636-9.
  - 29 Martis C. *Parotid benign tumors: comments on surgical treatment of 263 cases.* Int J Oral Surg 1983;12:211-20.
  - 30 Powell ME, Clairmont AA. *Complications of parotidectomy.* South Med J 1983;76:1109-12.
  - 31 O'Regan B, Mather CI. *Ipsilateral removal of sublingual gland after excision of submandibular gland for benign disease: 10-year prospective study and comprehensive review 1978-2008.* Br J Oral Maxillofac Surg 2011;49:186-9.
  - 32 Hamza Y, Khalil R. *Video-assisted submandibular resection: two-step technique.* Surg Endosc 2009;23:2785-9.
  - 33 Silver NL, Chinn SB, Bradley PJ, et al. *Surgery for malignant submandibular gland neoplasms.* Adv Otorhinolaryngol 2016;78:104-12.
  - 34 Nobis CP, Rohleder NH, Wolff KD, et al. *Head and neck salivary gland carcinomas - elective neck dissection, yes or no?* J Oral Maxillofac Surg 2014;72:205-10.
  - 35 Nocon CC, Cohen MA, Langerman AJ. *Quality of neck dissection operative reports.* Am J Otolaryngol 2016;37:330-3.
  - 36 de Carvalho AS, Dedivitis RA, de Castro MA, et al. *Submandibular gland excision.* Rev Col Bras Cir 2015;42:14-7.
  - 37 Springborg LK, Møller MN. *Submandibular gland excision: long-term clinical outcome in 139 patients operated in a single institution.* Eur Arch Otorhinolaryngol 2013;270:1441-6.
  - 38 Delsing CP, Cillessen E, Scheffer A, et al. *Bilateral submandibular gland excision for drooling: our experience in twenty-six children and adolescents.* Clin Otolaryngol 2015;40:285-90.
  - 39 Preuss SF, Klusmann JP, Wittekindt C, et al. *Submandibular gland excision: 15 years of experience.* J Oral Maxillofac Surg 2007;65:953-7.
  - 40 Akbay E, Cevik C, Arli C. *Perioperative difficulties and early postoperative complications of transoral approach in mouth base surgery.* J Craniofac Surg 2014;25:e143-8.
  - 41 Zhao GR, Ji P, Zhao HW, et al. *Modified L-shaped surgical approach to excision of the sublingual gland.* Br J Oral Maxillofac Surg 2015;53:725-9.
  - 42 Righini CA, Petrossi J, Reyt E, et al. *An original submandibular approach technique sparing the cervical branch of the facial nerve.* Eur Ann Otorhinolaryngol Head Neck Dis 2014;131:143-6.
  - 43 Bradley PJ, Ferris RL. *Surgery for malignant sublingual and minor salivary gland neoplasms.* Adv Otorhinolaryngol 2016;78:113-9.
  - 44 Chakravarti A, Gupta R, Garg S, et al. *Bilateral submandibular duct transposition with sublingual gland excision*

- for cerebral palsy children with drooling. *Indian J Pediatr* 2014;81:623-4.
- 45 Boffano P, Gallesio C. *Surgical treatment of a giant sialolith of the Wharton duct.* *J Craniofac Surg* 2010;21:134-5.
- 46 Capaccio P, Clemente IA, McGurk M, et al. *Transoral removal of hiloparenchymal submandibular calculi: a long-term clinical experience.* *Eur Arch Otorhinolaryngol* 2011;268:1081-6.
- 47 Komatsuzaki Y, Ochi K, Sugiura N, et al. *Video-assisted submandibular sialadenectomy using an ultrasonic scalpel.* *Auris Nasus Larynx* 2003;30(Suppl):S75-8.
- 48 Combes J, Karavidas K, McGurk M. *Intraoral removal of proximal submandibular stones - an alternative to sialadenectomy?* *Int J Oral Maxillofac Surg* 2009;38:813-6.
- 49 Parente Arias PL, Fernández Fernández MM, Varela Vázquez P, et al. *Minimally invasive video-assisted submandibular sialadenectomy: surgical technique and results from two institutions.* *Surg Endosc* 2016;30:3314-20.
- 50 Pitak-Arnop P, Pausch NC, Dhanuthai K, et al. *Endoscope-assisted submandibular sialadenectomy: a review of outcomes, complications, and ethical concerns.* *Eplasty* 2010;10:e36.
- 51 Lari N, Chossegros C, Thiery G, et al. *Sialendoscopy of the salivary glands.* *Rev Stomatol Chir Maxillofac* 2008;109:167-71.
- 52 Strychowsky JE, Sommer DD, Gupta MK, et al. *Sialendoscopy for the management of obstructive salivary gland disease: a systematic review and meta-analysis.* *Arch Otolaryngol Head Neck Surg* 2012;138:541-7.
- 53 Marchal F, Becker M, Dulguerov P, et al. *Interventional sialendoscopy.* *Laryngoscope* 2000;110:318-320.
- 54 Nahlieli O. *Advanced sialoendoscopy techniques, rare findings, and complications.* *Otolaryngol Clin North Am* 2009;42:1053-72.
- 55 Iro H, Zenk J, Escudier MP, Nahlieli O, et al. *Outcome of minimally invasive management of salivary calculi in 4,691 patients.* *Laryngoscope* 2009;119:263-8.
- 56 Bowen MA, Tauzin M, Kluka EA, et al. *Diagnostic and interventional sialendoscopy: a preliminary experience.* *Laryngoscope* 2010;121:299-303.
- 57 Walvekar RR, Razfar A, Carrau RL, et al. *Sialendoscopy and associated complications: a preliminary experience.* *Laryngoscope* 2008;118:776-9.
- 58 Nahlieli O, Nakar LH, Nazarian Y, et al. *Sialoendoscopy: a new approach to salivary gland obstructive pathology.* *J Am Dent Assoc* 2006;137:1394-400.
- 59 Marchal F, Chossegros C, Faure F, et al. *Salivary stones and stenosis. A comprehensive classification.* *Rev Stomatol Chir Maxillofac* 2008;109:233-6.
- 60 Nahlieli O, Bar T, Shacham R, et al. *Management of chronic recurrent parotitis: current therapy.* *J Oral Maxillofac Surg* 2004;62:1150-5.
- 61 Atienza G, López-Cedrún JL. *Management of obstructive salivary disorders by sialendoscopy: a systematic review.* *Br J Oral Maxillofac Surg* 2015;53:507-19.
- 62 Kroll T, Finkensieper M, Sharma SJ, et al. *Short-term outcome and patient satisfaction after sialendoscopy.* *Eur Arch Otorhinolaryngol* 2013;270:2939-45.
- 63 Iwai T, Matsui Y, Yamagishi M, et al. *Simple technique for dilatation of the papilla in sialoendoscopy.* *J Oral Maxillofac Surg* 2009;67:681-2.
- 64 Nahlieli O, Droma EB, Eliav E, et al. *Salivary gland injury subsequent to implant surgery.* *Int J Oral Maxillofac Implants* 2008;23:556-60.
- 65 Mandel L. *Plunging ranula following placement of mandibular implants: case report.* *J Oral Maxillofac Surg* 2008;66:1743-7.
- 66 Harrison JD, Kim A, Al-Ali S, et al. *Postmortem investigation of mylohyoid hiatus and hernia: aetiological factors of plunging ranula.* *Clin Anat* 2013;26:693-9.
- 67 Gary C, Kluka EA, Schaitkin B, et al. *Interventional sialendoscopy for treatment of juvenile recurrent parotitis.* *J Indian Assoc Pediatr Surg* 2011;16:132-6.
- 68 Al-Abri R, Marchal F. *New era of endoscopic approach for sialolithiasis: sialendoscopy.* *Sultan Qaboos Univ Med J* 2010;10:382-7.
- 69 Karavidas K, Nahlieli O, Fritsch M, et al. *Minimal surgery for parotid stones: a 7-year endoscopic experience.* *Int J Oral Maxillofac Surg* 2010;39:1-4.
- 70 Zenk J, Koch M, Iro H. *Extracorporeal and intracorporeal lithotripsy of salivary gland stones: basic investigations.* *Otolaryngol Clin North Am* 2009;42:1115-37.
- 71 Zenk J, Koch M, Mantsopoulos K, et al. *The significance of extracorporeal shock wave lithotripsy in sialolithiasis therapy.* *HNO* 2013;61:306-11.
- 72 Abdusalamov MR, Afanas'ev VV, Gamataev II. *Shockwave lithotripsy in sialolithiasis patients.* *Stomatologiya (Mosk)* 2014;93:31-2.
- 73 Desmots F, Chossegros C, Salles F, et al. *Lithotripsy for salivary stones with prospective US assessment on our first 25 consecutive patients.* *J Craniomaxillofac Surg* 2014;42:577-82.
- 74 Raif J, Vardi M, Nahlieli O, et al. *An Er:YAG laser endoscopic fiber delivery system for lithotripsy of salivary stones.* *Lasers Surg Med* 2006;38:580-7.
- 75 Schrötzmair F, Müller M, Pongratz T, et al. *Laser lithotripsy of salivary stones: Correlation with physical and radiological parameters.* *Lasers Surg Med* 2015;47:342-9.
- 76 Martellucci S, Pagliuca G, de Vincentiis M, et al. *Ho:Yag laser for sialolithiasis of Wharton's duct.* *Otolaryngol Head Neck Surg* 2013;148:770-4.
- 77 Koch M, Mantsopoulos K, Schapher M, et al. *Intraductal pneumatic lithotripsy for salivary stones with the StoneBreaker: Preliminary experience.* *Laryngoscope* 2016;126:1545-50.
- 78 Nahlieli O, Shacham R, Zaguri A. *Combined external lithotripsy and endoscopic techniques for advanced sialolithiasis cases.* *J Oral Maxillofac Surg* 2010;68:347-53.

Received: September 15, 2016 - Accepted: December 12, 2016

Address for correspondence: Oded Nahlieli, Department of Oral and Maxillofacial Surgery Barzilai Medical Center Ashkelon, 78306, Israel. E-mail: nahlieli@yahoo.com

# Sialendoscopic management of autoimmune sialadenitis: a review of literature

## *Trattamento scialendoscopico delle scialoadeniti autoimmuni: revisione della letteratura*

A. GALLO<sup>1</sup>, S. MARTELLUCCI<sup>1</sup>, M. FUSCONI<sup>2</sup>, G. PAGLIUCA<sup>1</sup>, A. GRECO<sup>2</sup>, A. DE VIRGILIO<sup>2</sup>, M. DE VINCENZI<sup>2</sup>

<sup>1</sup> Department of Surgical Biotechnologies and Science, ENT Section "Sapienza" University of Rome, Italy;

<sup>2</sup> Department of Sensorial Organs, ENT Section "Sapienza" University of Rome, Italy

### SUMMARY

Autoimmune diseases of major salivary glands include Sjögren's syndrome and a complex of disorders classified as immunoglobulin G4-related diseases. These pathologies are characterised by an autoimmune reaction mediated by T-helper lymphocytes that targets the ducts of exocrine glands in Sjögren's syndrome and glandular parenchyma in immunoglobulin G4-related diseases. Immunoglobulin G4-related diseases represent recently introduced multi-organ diseases that also involve the salivary glands. However, the morbid conditions once known as Mikulicz's disease and Kuttner's tumour were recently considered as two variants of immunoglobulin G4-related diseases affecting the major salivary glands (immunoglobulin G4-related sialadenitis). This review briefly summarises the pathogenesis and clinical features of autoimmune diseases of the major salivary glands, focusing on the diagnostic and therapeutic role of sialendoscopy.

**KEY WORDS:** Kuttner Tumour • Mikulicz's Disease • IgG4 related diseases • IgG4 related sialadenitis • Sjögren's syndrome • Ductal stenosis • Sialoendoscopy

### RIASSUNTO

*Le patologie autoimmuni delle ghiandole salivari maggiori comprendono la sindrome di Sjögren e l'insieme di condizioni morbose raccolte sotto il nome di patologie IgG4-correlate. Tanto la sindrome di Sjögren quanto le patologie IgG4-correlate sono caratterizzate da una reazione autoimmune mediata dai linfociti T-Helper il cui bersaglio è rappresentato dai dotti delle ghiandole esocrine nella sindrome di Sjögren e dal parenchima ghiandolare nelle malattie IgG4-correlate. Queste ultime, di introduzione relativamente recente, coinvolgono solitamente molti organi tra cui le ghiandole salivari. Negli ultimi anni patologie un tempo note come malattia di Mikulicz e tumore di Kuttner sono state classificate come le patologie IgG4-correlate limitate alle ghiandole salivari maggiori e denominate scialoadeniti IgG4-correlate. Questa breve revisione riassume la patogenesi e le principali caratteristiche cliniche delle ghiandole salivari maggiori sottolineando il potenziale ruolo diagnostico e terapeutico delle scialoendoscopia.*

**PAROLE CHIAVE:** Tumore di Kuttner • Malattia di Mikulicz • Patologie IgG4-Correlate • Scialoadeniti IgG4-Correlate • Sindrome di Sjögren • Stenosi Duttale • Scialoendoscopia

Acta Otorhinolaryngol Ital 2017;37:148-154

## Introduction

Salivary gland diseases include neoplasms and non-neoplastic disorders such as viral parotitis, sialolithiasis and chronic non-lithiasic sialadenitis. Autoimmune diseases are responsible for a small share of chronic, non-lithiasic inflammatory disorders of major salivary glands. In these conditions, the parenchyma of salivary glands, salivary ducts, or both represent the target of an attack carried out by the immune system against its own tissues, through autoantibodies and T cells. Sjögren's syndrome (SS) and immunoglobulin G4-related diseases (IgG4-RD) are the main chronic autoimmune sialadenitis<sup>1,2</sup>.

SS attacks the exocrine glands, specifically the salivary and lacrimal tissue, and CD4+ lymphocytes play the main role in the autoimmune process. IgG4-RD are newly described fibro-inflammatory conditions that often present as nodular

lesions that can affect nearly every organ system<sup>1</sup>. In IgG4-RD, the target of the autoimmune attack is the connective tissue and the inflammatory cell infiltration is composed of IgG4-positive plasma cells, CD4+ and CD8+ T cells. In recent years, both Mikulicz's disease (MD) and the so-called Kuttner's tumour (KT) were classified in the group of IgG4-RD and considered as variations of IgG4 RD affecting salivary tissue (IgG4-related sialadenitis or IgG4-RS)<sup>3</sup>.

The aim of this review is summarise the characteristics of the autoimmune diseases that affect the salivary glands, analysing the potential role of sialendoscopic techniques in the diagnosis and treatment of these conditions.

## Sjögren's syndrome (SS)

SS may be defined as a chronic autoimmune inflammatory exocrinopathy affecting the salivary and lacrimal glands.

The dysfunction of exocrine glands is usually accompanied by a multitude of extraglandular manifestations<sup>4</sup>. SS may occur as primary or secondary form. Primary SS, with or without extraglandular involvement, occurs in the absence of another underlying rheumatic disorder, whereas secondary SS is associated with another autoimmune disease, such as systemic lupus erythematosus, rheumatoid arthritis, or scleroderma. Given the overlap of SS with many other rheumatic disorders, it is sometimes difficult to determine whether a clinical manifestation is solely a consequence of SS or is due to one of its overlapping disorders. These primary and secondary types occur with similar frequency, but sicca complex symptoms seem to be more severe in primary form<sup>5,6</sup>.

Primary SS is an autoimmune disorder characterised by lymphocytic infiltrates with destruction of exocrine glands and systemic production of autoantibodies against ribonucleoprotein particles SS-A/Ro and SS-B/La. The infiltrating cells (T- and B-cells, dendritic cells) interfere with salivary production at several points, starting a vicious circle and causing the salivary glands to become sites of chronic inflammation<sup>4</sup>.

Despite extensive studies, the underlying cause of SS and its pathogenesis remains controversial. It is thought that environmental factors can trigger inflammation in individuals with a genetic predisposition, configuring a multifactorial disease<sup>7</sup>.

Primary SS is strongly associated with HLA-DR3 and the linked genes B8, and DQ2, and C4A null gene. Within the primary SS group, those with anti-La represent a subset that show an even more striking association with HLA 3. This suggests that the anti-La-positive patients with SS may be the most homogeneous subgroup, both clinically and immunogenetically. Anti-Ro is associated with DR2 and the linked DQ1 gene, as well as with DR3, and this may reflect the wider diagnostic associations of this antibody. Rheumatoid arthritis with secondary SS is associated with DR4 rather than DR3<sup>8-11</sup>.

Viruses are viable candidates as environmental triggers, although no single virus has been implicated and the triggering mechanisms is still unknown. Epstein-Barr virus, HTLV-1, human herpesvirus 6, HIV, hepatitis C virus and cytomegalovirus may have a role and clinical manifestations of sicca syndrome are frequently seen in patients infected with HIV, HTLV-1, and hepatitis C<sup>12-14</sup>. Damage and/or cell death due to viral infection may provide triggering antigens to toll-like receptors in or on dendritic or epithelial cells, which, by recognising pathogen-associated patterns, are activated and begin producing cytokines, chemokines and adhesion molecules. As T and B lymphocytes migrate into the gland, they themselves become activated by dendritic and epithelial cells, thereafter acting as antigen-presenting cells. Expressed antigens include SSA/Ro, SSB/La, alpha-fodrin and beta-fodrin, and cholinergic muscarinic receptors. Dendritic cell triggering by immune

complexes formed from SSA-anti-SSA (or other immune complexes) may propagate the ongoing innate and acquired immune activation<sup>11-15</sup>.

SS is one of the most common autoimmune rheumatic diseases with a prevalence around 1% according to the revised American-European Consensus Group (AECG) criteria<sup>16</sup>. There is general agreement that it is a disease of middle-aged or elderly women (mean age of onset 45–55 years, male/female ratio 1:9)<sup>4,11</sup>.

Clinically, most individuals with SS present with sicca symptoms (xerophthalmia and xerostomia), that are expression of chronic exocrinopathy. The lack of saliva in the mouth and the absence of a normal 'pool' of saliva underneath the tongue causes an increase in the rate of caries and may promote oral candidosis. In more severe cases, the tongue is atrophic, fissured or even ulcerated. Parotid glands are frequently swollen. Exocrine glands other than the salivary and lacrimal glands may be affected. Dry skin and dry hair are symptoms frequently elicited on direct questioning. About 30% of patients have diminished vaginal secretions and may present with dyspareunia. Involvement of the gastrointestinal tract leads to reflux oesophagitis or gastritis owing to a lack of protective mucus secretion is also possible<sup>4,7,11</sup>.

SS is a systemic disease. About 70% of patients complain of fatigue that may be misdiagnosed whereas arthritis, with characteristics similar to those seen in rheumatoid arthritis, occurs in about 30% of subjects<sup>11</sup>. The renal features of SS include interstitial nephritis, leading to renal tubular acidosis, and membranous glomerulonephritis due to circulating immune complex disease (more common in the secondary SS). The incidence of significant renal disease of around 5%, but subclinical renal features of disease rises to around 30%<sup>17</sup>. Interstitial pneumonitis determined by an interstitial infiltrate of lymphocytes around the bronchioles may cause function abnormalities found in approximately 25% of patients with SS<sup>18</sup>. Although vasculopathies such as Raynaud's phenomenon and congenital heart block are also frequently observed, these disorders assume minor clinical significance<sup>11</sup>. Conversely, neurological involvement is quite rare (1%), but may manifest as multiple sclerosis-like syndrome<sup>19</sup>. Finally, it has long been known that patients with primary SS have a 44-fold increased risk of mucosa-associated lymphoid tissue (MALT) type B cell lymphoma<sup>20</sup>.

A number of classification criteria for SS were designed, primarily for clinical research studies, but are also used to guide clinical diagnoses. The revised AECG criteria for classification of Sjögren's syndrome<sup>16</sup>, summarised in Table I, were proposed in 2002 and are the most commonly used criteria for diagnosis of SS. A new set of classification criteria has been developed by the Sjögren's International Collaborative Clinical Alliance (SICCA) investigators and accepted as a provisional criteria set by the American College of Rheumatology (ACR) in 2012<sup>21</sup>.

Diagnostic workup in the suspicion of SS usually include

**Table I.** American–European Consensus Group Classification criteria for Sjögren's syndrome. Diagnosis of primary Sjögren's syndrome requires four of six criteria; in addition, either criterion number 5 or criterion number 6 must be included. Sjögren's syndrome can be diagnosed in patients who have no sicca symptoms if three of the four objective criteria are fulfilled. Secondary Sjögren's syndrome is diagnosed when, in the presence of a connective-tissue disease, symptoms of oral or ocular dryness exist in addition to criterion 3, 4, or 5.

|   |  |
|---|--|
| 1. <b>Ocular symptoms</b>   | Dry eyes for more than 3 months<br>Foreign-body sensation<br>Use of tear substitutes more than 3 times daily   |
| 2. <b>Oral symptoms</b>   | Feeling of dry mouth<br>Recurrently swollen salivary glands<br>Frequent use of liquids to aid swallowing   |
| 3. <b>Ocular signs</b>  | Schirmer test performed without anesthesia (< 5 mm in 5 min)<br>Positive vital dye staining results  |
| 4. <b>Oral signs</b>  | Abnormal salivary scintigraphy findings<br>Abnormal parotid sialography findings<br>Abnormal sialometry findings (unstimulated salivary flow < 1.5 mL in 15 min) |
| 5. <b>Positive minor salivary gland biopsy findings (focus score <math>\geq 1</math>)</b> |  |
| 6. <b>Positive anti-SSA or anti-SSB antibody results</b>                                  |  |

**Exclusions:** any patient with past head and neck radiation treatment, hepatitis C infection, acquired immunodeficiency disease (AIDS), pre-existing lymphoma, sarcoidosis, graft versus host disease, use of anticholinergic drugs.

the blood tests listed in the revised AECG criteria. Furthermore, patients with SS frequently present leucopenia, thrombocytopenia, high ESR and anti-nuclear antibodies. The classical histological feature of SS at minor salivary gland biopsy is of at least one 'focus' of 50 or more (predominantly CD4+) T lymphocytes per high-powered field clustered around a salivary duct (periductal focal lymphocytic infiltrates). Histology reports sometimes describe a generalised scattering of inflammatory cells across the gland usually described as a 'chronic sialadenitis'. The report may conclude that this is 'compatible with SS'. In fact, chronic sialadenitis can be found in normal individuals and this should be classed as a negative biopsy<sup>1471116</sup>. AECG criteria order to objectively assess xerophthalmia through simple, economic tests such as Rose Bengal staining and the Schirmer test, which can be used to strongly support or refute the suspicion of SS<sup>22</sup>. Conversely, the tests recommended to objectify the signs of xerostomia, except for the poor standardised sialometry, are particularly expensive (salivary scintigraphy) and not very specific (sialography) imaging techniques. Sialographic changes in parotid glands affected by SS were accurately described and, with regards to chronic sialadenitis, classified into punctate, globular, cavitory and destructive sialectasia of the acinar and ductal system. These four sialectasic changes are thought to represent increasing glandular damage caused by an autoimmune reaction<sup>23</sup>. Sialendoscopy, according to AECG criteria, is not listed as a recommended examination to assess salivary gland involvement in SS. The reason for this exclusion is probably due to historical reasons: the revised AECG criteria, in fact, date to 2002 whereas sialendoscopy still represents a relatively new procedure. However, this technique allows endoscopic transluminal visualisation of major salivary glands and offers a mechanism for diagnosing and treating both inflammatory and obstructive pathologies related

to the ductal system, and thus like sialography potentially adequate to recognise the ductal abnormalities accompanying SS<sup>24</sup>.

In the literature, there is little experience about the role of sialendoscopy in SS. Some authors report the presence of hyperaemia at the level of main and the second-order salivary ducts, with evidence of a vascular pattern demonstrating perivascular inflammation and congestion<sup>25</sup>. It is possible that this endoscopic appearance, also observed in recurrent parotitis, could characterise the initial phases of SS, whereas the pale, little vascularised appearance of the ductal wall expresses the subsequent progression of the disease, in which parenchymal tissue is replaced by fibrosis<sup>2425</sup>. Obstructive mucous plugs are frequently observed in the ductal tree. The presence of these obstructions causes saliva stagnation and inflammation upstream of the obstruction, which is probably responsible for the occasional parotid swelling and pain<sup>2526</sup>. However, stricture formation was found to be the major cause of ductal obstruction by other authors. Jager, et al. and De Luca, et al. reported the presence of stricture in the majority of salivary glands affected by SS explored in their study<sup>2728</sup>. Microlithiasis, related to the subsequent inflammatory episodes<sup>29</sup>, is observed mainly in the advanced stages of the disease in which the fibrous replaced and subverted the entire gland. Our research group is currently investigating a possible role of sialendoscopy in diagnosis of SS by analysing the expression of IL-17 and IL-23 in saliva and ductal lavage collected during the surgical procedure. The therapy for SS is based on drugs aimed to modulate the autoimmune response. Traditional immunomodulatory drugs such as low-dose steroids, methotrexate, ciclosporin and azathioprine show no benefit, while there is some evidence to support the use of hydroxychloroquine sulphate, although there is no evidence of a direct effect on salivary or lacrimal flow<sup>630-32</sup>. Thus, although biologic

agents represent promising treatments<sup>33-35</sup>, the current management of xerostomia and xerophthalmia is still based on topical treatments (tear and saliva substitutes)<sup>36</sup> and sialogogues such as pilocarpine and cevimeline<sup>37-39</sup>.

During sialendoscopy, a semi-rigid miniaturised endoscope is inserted into the salivary duct after dilating the papilla and driven in the ductal system under constant irrigation<sup>40</sup>. Sterile saline solution is the fluid of choice for the irrigation of salivary ducts, but corticosteroid solutions can also be used<sup>24 40-42</sup>. Thus, a diagnostic procedure alone causes relevant dilation of the entire ductal system. On the other hand, the use of interventional sialendoscope with working channels allows the concomitant treatment of strictures, mucus plugs and sialoliths, contributing to alleviate complaints in patients affected by inflammatory disease<sup>24 43-45</sup>. Recent clinical experience suggested that sialendoscopy may alleviate the oral symptoms of SS by restoring salivary function<sup>25-28</sup>. Jager, et al. conducted a randomised study of 20 patients with SS oral symptoms who were randomly assigned to the nonintervention control group or to the sialendoscopy group. In patients undergoing sialendoscopy, unstimulated and stimulated saliva flow, Clinical Oral Dryness Score, Xerostomia Inventory Score, and EULAR Sjogren's Syndrome Patient Reported Index score showed a significant improvement of symptoms at 1 and 8 weeks after the procedure<sup>27</sup>. Although a positive effect of sialendoscopy on xerostomia cannot be assessed with a few, small case series, these promising results suggest that sialendoscopy could be a viable technique to treat obstructive salivary gland diseases related to SS that is refractory to conventional management.

### **IgG4-related sialadenitis (IgG4-RS)**

IgG4-RD are newly described fibro-inflammatory conditions that often presents as tumefactive lesions affecting several districts. Hamano, et al. first recognised IgG4-RD in 2001, after a connection between elevated serum IgG4 levels and inflammatory mass lesions in the pancreas causing autoimmune pancreatitis<sup>46</sup>. However, an initial consensus statement regarding diagnosis of IgG4-RD was reached only in 2011 during the first international symposium for IgG4-RD<sup>47</sup>.

The head and neck region is the second most common site for presentation of IgG4-RD after the pancreas and some pseudotumoural diseases of unknown pathogenesis, including MD and KT, have been attributed to IgG4-RD during the last 10 years<sup>48-55</sup>. Identification of IgG4-positive plasma cells in both KT and MD propelled renewed interest in these diseases, and fueled re-analyses of the classification of inflamed salivary glands<sup>56</sup>.

The exact aetiology of IgG4-RS is unknown and no known role of the IgG4 molecule has been identified. IgG4 itself normally represents the smallest fraction of IgG subclasses (< 5%). It has an amino acid variance in the

hinge region allowing it to split and randomly combine with other half molecules, creating asymmetric bispecific antibodies with two different antigen-binding sites. For this special feature, IgG4 scarcely forms immune complexes, binds Fc-receptors and complements component with low affinity. Thus, its ability to initiate immune responses is limited<sup>2 3</sup>.

It is postulated that the inflammatory and fibrotic processes that drive IgG4-RS are propagated by a combination of T helper (Th) 2 cells and regulatory T cells (Treg cells). This is contrary to most autoimmune disorders where polarised Th1 and/or Th17 subsets are responsible for the inflammatory process<sup>2 3 47</sup>.

Clinical data on IgG4-RS are increasingly reported. Currently, it is believed that this condition preferentially affects middle-aged males presenting with persistent parotid and/or submandibular gland swelling, unilaterally or bilaterally.

The disorder that was identified by Kuttner in 1896<sup>57</sup> commonly involves one or both submandibular glands, clinically presenting as hard tumour-like masses with tendency to nodular swelling that can be confounded with malignant forms. The disease is often associated with microlithiasis. Histological sections reveal preservation of the lobular architecture, marked lymphoplasmacytic inflammation, large irregular lymphoid follicles with expanded germinal centers and acinar atrophy without prominent lymphoepithelial lesions. Characteristically, prominent cellular interlobular fibrosis due to activated fibroblasts and infiltration of lymphocytes and IgG4-positive-stained plasma cells is observed. Eosinophil infiltration and obliterative phlebitis are frequent<sup>56</sup>.

MD, first described in 1888<sup>58</sup>, refers to idiopathic, bilateral, painless, symmetrical and persistent swelling of the lacrimal, parotid and submandibular glands. Because MD and primary-SS are histologically similar, MD has long been considered as a subtype of SS. Upon haematoxylin-eosin staining, lacrimal or salivary gland specimens from MD showed severe mononuclear cell infiltration and lymphoid follicles around the ductal and acinar cells. The infiltration of numerous IgG4-positive plasmacytes near acinar and ductal cells and around lymphoid follicles allows differentiating MD from SS<sup>51</sup>. Therefore, the presence of IgG4-positive plasmacytes in the inflammatory infiltration suggests that MD and KT are only two different phenotypes of IgG4-RS. A comparison between clinical and histological features of the two phenotypes of IgG4-RS and SS is summarised in Table II.

Clinically, xerostomia is inconstant in IgG4-RS, involving approximately 30% of patients. Autoimmune pancreatitis, sclerosing cholangitis and asthma are frequently associated conditions (15-30%). Lacrimal gland involvement, as well as sinonasal disorders and cervical lymphadenopathy (70%), are frequent coexisting conditions<sup>3</sup>.

Imaging studies of salivary glands show a pattern of non-specific features in MD phenotype of IgG4-RS. On US



**Table II.** Comparison between SS and IgG4-RS.

| Features     |                           | SS   | IgG4-RS  |   |
|--------------|---------------------------|--|--|---|
|              |                           |  | MD phenotype   | KT phenotype  |
| Clinical     | Gender (female:male)      | 9:1  | 1:2.5  |   |
|              | Glands involvement        | Both parotids and submaxillary glands                          | Both parotids and submaxillary glands                          | submaxillary glands   |
|              | Bilateral/unilateral      | Bilateral  | Bilateral  | Often unilateral  |
|              | Appearance                | Usually transient swelling                                     | Persistent symmetrical swelling                                | Persistent nodular swelling   |
|              | Salivary impairment       | Severe   |  | Mild  |
|              | Response to steroids      | Limited  |  | Good  |
| Histological | Fibrosis                  | Inconstant, mild   | Constant, intense  |   |
|              | Obliterative phlebitis    | Absent   | frequent   |   |
|              | IgG4+ plasmacytes         | Absent   | >30–50 hpf   |   |
| Serological  | Serum IgG4 levels         | Normal   | High   |   |
|              | Serum IgE levels          | Normal   | High   |   |
|              | Anti-Ro(SSA)/Anti-La(SSB) | High rate  | Absent   |   |
|              |                           |  |  |   |
| Imaging      | Ultrasound                | Inhomogeneity hypoechoic areas and hyperechoic lines and spots | Inhomogeneity hypoechoic areas and hyperechoic lines and spots | Nodular, smooth contour mass with hypoechoic foci scattered against a heterogeneous background. |

examination of the affected glands, hypoechoic areas with hyperechoic lines creating a reticular pattern that is a common finding in patients affected by SS. On the contrary, a nodular pattern with duct enlargement and micro-lithiasis is often observed in the disorder once known as KT. Computerised tomography and magnetic resonance imaging have lower diagnostic accuracy compared to ultrasonography<sup>2,3,51-56</sup>.

Biopsy of the affected gland is necessary to formulate a diagnosis of IgG4-RS, although lip biopsy has been proposed as an alternative technique<sup>59</sup>. There are three main histopathological hallmarks for IgG4-RD: infiltrates of IgG4+ plasmacytes, intense fibrosis and obliterative phlebitis. However, the exact histological findings vary greatly depending on the tissue affected and clinical presentation. Currently, histologic diagnosis of IgG4-RD is based primarily on IgG4 positive to IgG containing cell ratio and, secondarily, on the number of IgG4 positive cells per high power field. A ratio of IgG4 to IgG that is higher than 50% and the confirmation of at least 30 IgG4-positive cells per high-power field are considered to be highly suggestive of IgG4-RD<sup>60</sup>.

Laboratory tests on blood can confirm the diagnosis. Patients affected by IgG4-RD show significantly higher total IgG, IgG2, IgG4 and IgE. In addition, eosinophil counts are usually increased and hypocomplementaemia is frequent. In particular, elevated serum IgG4, even if neither present in all patients with histologically proven IgG4-RD nor specific for it, can be a supplementary tool in the diagnosis of IgG4-RD<sup>61</sup>. Serum IgG4 concentration > 135 mg/dl<sup>-1</sup> have been defined as a threshold value for diagnosis<sup>61</sup>. Furthermore, it was observed that IgG4 serum con-

centration correlates with reduction of saliva production and glandular fibrosis, suggesting that IgG4 concentration in serum can represent a useful marker to follow the evolution of the disease and efficacy of treatment<sup>56</sup>.

In the literature, there are very few publications focusing on medical treatment of IgG4-RS, although all authors indicate systemic steroid therapy as first-line treatment and prednisone represents the most used drug. In the past decades, in fact, the good responsiveness to steroids was considered a distinctive clinical feature of MD compared to SS<sup>51</sup>.

Steroid therapy, weighted according to the activity of the disease and body mass, is usually long-term and the initial dose is gradually tapered after 2-4 weeks of starting therapy. Long-term glucocorticoid treatment seems to significantly improve symptoms related to reduced salivary secretion conferring, according to some studies, recovery of histological abnormalities. Some authors have emphasised the role of early steroid therapy to improve outcomes in patients with IgG4-RS. Salivary secretion rate, indeed, seems to decrease with histological changes related to a delayed intervention<sup>62</sup>. Conversely, the role of other immunosuppressive agents such as azathioprine, methotrexate, or mycophenolate mofetil is still controversial and understudied.

To the best of our knowledge, there are no reports about sialendoscopy performed in patients affected by IgG4 related sialadenitis. However, we believe that this technique will be useful in the management of patients suffering from IgG4-RD. Although it is unlikely that this method can replace the role of the biopsy for diagnostic purposes, sialendoscopy is a potential tool in the treatment of sialadenitis. Endoscopic techniques, in fact, as is the case

in other chronic sialadenitis, could eliminate microlithiasis and debris thorough rinsing or using microforceps and basket, also allowing the treatment of eventual ductal stenosis using hydrostatic pressure or high-pressure balloons. Furthermore, the intraductal administration of anti-inflammatory drugs, while poorly studied at present, may be an alternative to systemic steroids in the future.

## Conclusions

The role of sialendoscopy in the treatment of autoimmune chronic sialadenitis is currently understudied, mainly due to the recent worldwide diffusion of this technique.

The outcomes of a few preliminary trials, however, are particularly encouraging and deserve to be verified in randomised controlled trials with a larger sample and longer follow-up period.

The discussion between otolaryngologists and rheumatologists should also be more incisive so that sialendoscopy and sialography can be considered as useful techniques for diagnosis and staging of autoimmune diseases of the salivary glands. Furthermore, rheumatologists should consider a minimally invasive technique such as interventional sialendoscopy for management of patients suffering from autoimmune diseases of the major salivary glands who do not derive benefit from conventional therapies.

## References

- Campos J, Hillen MR, Barone F. *Salivary gland pathology in Sjögren's syndrome*. *Rheum Dis Clin North Am* 2016;42:473-83.
- Fragoulis GE, Zampeli E, Moutsopoulos HM. *IgG4-related sialadenitis and Sjögren's syndrome*. *Oral Dis* 2017;23:152-156.
- Mulholland GB, Jeffery CC, Satija P, et al. *Immunoglobulin G4-related diseases in the head and neck: a systematic review*. *J Otolaryngol Head Neck Surg* 2015 20;44:24.
- Fox RI. *Sjögren's syndrome*. *Lancet* 2005;366:321-31.
- Ng WF, Bowman SJ. *Primary Sjogren's syndrome: too dry and too tired*. *Rheumatology* 2010;49:844-53.
- Saraux A, Pers JO, Devauchelle-Pensec V. *Treatment of primary Sjögren syndrome*. *Nat Rev Rheumatol* 2016;12:456-71.
- Reksten TR, Jonsson MV. *Sjögren's syndrome: an update on epidemiology and current insights on pathophysiology*. *Oral Maxillofac Surg Clin North Am* 2014;26:1-12.
- Cruz-Tapias P, Rojas-Villarraga A, Maier-Moore S, et al. *HLA and Sjögren's syndrome susceptibility. A meta-analysis of worldwide studies*. *Autoimmun Rev* 2012;11:281-7.
- Ferro F, Vagelli R, Bruni C, et al. *One year in review 2016: Sjögren's syndrome*. *Clin Exp Rheumatol* 2016;34:161-71.
- Gottenberg JE, Busson M, Loiseau P, et al. *In primary Sjögren's syndrome, HLA class II is associated exclusively with autoantibody production and spreading of the autoimmune response*. *Arthritis Rheum* 2003 48:2240-5.
- Venables PJ. *Sjögren's syndrome*. *Best Pract Res Clin Rheumatol* 2004;18:313-29.
- Lucchesi D, Pitzalis C, Bombardieri M. *EBV and other viruses as triggers of tertiary lymphoid structures in primary Sjögren's syndrome*. *Expert Rev Clin Immunol* 2014;10:445-55.
- Sipsas NV, Gamaletsou MN, Moutsopoulos HM. *Is Sjögren's syndrome a retroviral disease?* *Arthritis Res Ther* 2011;13:212.
- Brodziak A, Ziółko E, Muc-Wierzgoń M, et al. *The role of human endogenous retroviruses in the pathogenesis of autoimmune diseases*. *Med Sci Monit* 2012;18:RA80-8.
- Fayyaz A, Kurien BT, Scofield RH. *Autoantibodies in Sjögren's Syndrome*. *Rheum Dis Clin North Am* 2016;42:419-34.
- Vitali C, Bombardieri S, Jonsson R, et al. *Classification criteria for Sjogren's syndrome: a revised version of the European criteria published by the American European consensus group*. *Ann Rheum Dis* 2002;61:554e8.
- Bossini N, Savoldi S, Franceschini F, et al. *Clinical and morphological features of kidney involvement in primary Sjogren's syndrome*. *Nephrol Dial Transplant* 2001;16:2328-36.
- Davidson BK, Kelly CA, Griffiths ID. *Ten year follow up of pulmonary function in patients with primary Sjogren's syndrome*. *Ann Rheum Dis* 2000;59:709-12.
- Vincent TL, Richardson MP, Mackworth-Young CG, et al. *Sjogren's syndrome-associated myelopathy: response to immunosuppressive treatment*. *Am J Med* 2003;114:145-8.
- Kassan SS, Thomas TL, Montsopoulos HM, et al. *Increased risk of lymphoma in sicca syndrome*. *Ann Intern Med* 1978; 89:888-92.
- Shiboski SC, Shiboski CH, Criswell L, et al. *Sjögren's International Collaborative Clinical Alliance (SICCA) Research Groups. American College of Rheumatology classification criteria for Sjögren's syndrome: a data-driven, expert consensus approach in the Sjögren's International Collaborative Clinical Alliance cohort*. *Arthritis Care Res (Hoboken)* 2012;64:475-87.
- Alves M, Reinach PS, Paula JS, et al. *Comparison of diagnostic tests in distinct well-defined conditions related to dry eye disease*. *PLoS One* 2014;9:e97921.
- Dijkstra PF. *Classification and differential diagnosis of sialographic characteristics in Sjögren syndrome*. *Semin Arthritis Rheum* 1980;10:10-7.
- Gallo A, Benazzo M, Capaccio P, et al. *Sialoendoscopy: state of the art, challenges and further perspectives*. Round Table, 101<sup>st</sup> SIO National Congress, Catania 2014. *Acta Otorhinolaryngol Ital* 2015;35:217-33.
- Shacham R, Puterman MB, Ohana N, et al. *Endoscopic treatment of salivary glands affected by autoimmune diseases*. *J Oral Maxillofac Surg* 2011;69:476-81.
- Pace CG, Hwang K-G, Papadaki M, et al. *Interventional sialoendoscopy for treatment of obstructive sialadenitis*. *J Oral Maxillofac Surg* 2014;72:2157.
- Jager DJ, Karagozoglu KH, Maarse F, et al. *Sialendoscopy of salivary glands affected by Sjögren syndrome: a randomized controlled pilot study*. *J Oral Maxillofac Surg* 2016;74:1167-74.
- De Luca R, Trodella M, Vicidomini A, et al. *Endoscopic management of salivary gland obstructive diseases in patients with Sjogren's syndrome*. *J Craniomaxillofac Surg* 2015;43:1643-9.

- 29 Fusconi M, Petrozza V, Schippa S, et al. *Bacterial biofilm in salivary gland stones: cause or consequence?* Otolaryngol Head Neck Surg 2016;154:449-53.
- 30 Price EJ, Rigby SP, Clancy U, et al. *A double blind placebo controlled trial of azathioprine in the treatment of primary Sjogren's syndrome.* J Rheumatol 1998;25:896-9.
- 31 Fox RI, Dixon R, Guarrasi V, et al. *Treatment of primary Sjogren's syndrome with hydroxychloroquine; a retrospective, open-label study.* Lupus 1996;5:31-6.
- 32 Kruize AA, Hene RJ, Kallenberg CG, et al. *Hydroxychloroquine treatment for primary Sjogren's syndrome; a two year, double blind cross over trial.* Ann Rheum Dis 1993;52:60-4.
- 33 Steinfeld SD, Demols P, Appelboom T. *Infliximab in primary Sjogren's syndrome: one-year followup.* Arthritis Rheum 2002;46:3301-3.
- 34 Somer BG, Tsai DE, Downs L, et al. *American College of Rheumatology ad hoc Committee on Immunologic Testing Guidelines. Improvement in Sjogren's syndrome following therapy with rituximab for marginal zone lymphoma.* Arthritis Rheum 2003;49:394-8.
- 35 Dass S, Bowman SJ, Vital EM, et al. *Safety and efficacy of Rituximab in Sjogren's syndrome: results of a randomized, placebo controlled trial.* Ann Rheum Dis 2007;66:70.
- 36 Ramos-Casals M, Brito-Zerón P, Sisó-Almirall A, et al. *Topical and systemic medications for the treatment of primary Sjögren's syndrome.* Nat Rev Rheumatol 2012;8:399-411.
- 37 Berk L. *Systemic pilocarpine for treatment of xerostomia.* Expert Opin Drug Metab Toxicol 2008;4:1333-40.
- 38 Noaiseh G, Baker JF, Vivino FB. *Comparison of the discontinuation rates and side-effect profiles of pilocarpine and cevimeline for xerostomia in primary Sjögren's syndrome.* Clin Exp Rheumatol 2014;32:575-7.
- 39 Fife RS, Chase WF, Dore RK, et al. *Cevimeline for the treatment of xerostomia in patients with Sjogren syndrome: a randomized trial.* Arch Intern Med 2002;162:1293-300.
- 40 Turner MD. *Sialoendoscopy and salivary gland sparing surgery.* Oral Maxillofac Surg Clin North Am 2009;21:323-9.
- 41 Martellucci S, Pagliuca G, de Vincentiis M, et al. *Ho:Yag laser for sialolithiasis of Wharton's duct.* Otolaryngol Head Neck Surg 2013;148:770-4.
- 42 Gallo A, Capaccio P, Benazzo M, et al. *Outcomes of interventional sialoendoscopy for obstructive salivary gland disorders: an italian multicentre study.* Acta Otorhinolaryngol Ital 2016:479-85.
- 43 Marchal F, Becker M, Dulguerov P, et al. *Interventional sialoendoscopy.* Laryngoscope 2015;125:2427-9.
- 44 Maresh A, Kutler DI, Kacker A. *Sialoendoscopy in the diagnosis and management of obstructive sialadenitis.* Laryngoscope 2011;121:495-500.
- 45 Chuangqi Y, Chi Y, Lingyan Z. *Sialendoscopic findings in patients with obstructive sialadenitis: long-term experience.* Br J Oral Maxillofac Surg 2013;51:337-41.
- 46 Hamano H, Kawa S, Horiuchi A. *High serum IgG4 concentrations in patients with sclerosing pancreatitis.* N Engl J Med 2001;344:732-8.
- 47 Deshpande V, Zen Y, Chan JK. *Consensus statement on the pathology of IgG4-related disease.* Mod Pathol 2012;25:1181-92.
- 48 Yamamoto M, Takahashi H, Sugai S, et al. *Clinical and pathological characteristics of Mikulicz's disease (IgG4-related plasmacytic exocrinopathy).* Autoimmun Rev 2005;4:195-200.
- 49 Kitagawa S, Zen Y, Harada K, et al. *Abundant IgG4-positive plasma cell infiltration characterizes chronic sclerosing sialadenitis (Küttner's tumor).* Am J Surg Pathol 2005;29:783-91.
- 50 Kamisawa T, Nakajima H, Egawa N, et al. *IgG4-related sclerosing disease incorporating sclerosing pancreatitis, cholangitis, sialadenitis and retroperitoneal fibrosis with lymphadenopathy.* Pancreatol 2006;6:132-7.
- 51 Yamamoto M, Takahashi H, Ohara M, et al. *A new conceptualization for Mikulicz's disease as an IgG4-related plasmacytic disease.* Mod Rheumatol 2006;16:335-40.
- 52 Takano K, Yamamoto M, Takahashi H, et al. *Clinicopathologic similarities between Mikulicz disease and Küttner tumor.* Am J Otolaryngol 2010;31:429-34.
- 53 Geyer JT, Ferry JA, Harris NL, et al. *Chronic sclerosing sialadenitis (Küttner tumor) is an IgG4-associated disease.* Am J Surg Pathol 2010;34:202-10.
- 54 Himi T, Takano K, Yamamoto M, et al. *A novel concept of Mikulicz's disease as IgG4-related disease.* Auris Nasus Larynx 2012;39:9-17.
- 55 Geyer JT, Deshpande V. *IgG4-associated sialadenitis.* Curr Opin Rheumatol 2011;23:95-101.
- 56 Li W, Chen Y, Sun ZP, et al. *Clinicopathological characteristics of immunoglobulin G4-related sialadenitis.* Arthritis Res Ther 2015;17:186.
- 57 Küttner H. *Über entzündliche Tumoren der Submandillarspeicheldrüse.* Bruns Bieter Klin Chir 1896;15:815-34.
- 58 Mikulicz J. *Über eine eigenartige symmetrische Erkrankung der Thränen- und Mundspeicheldrüsen.* Stuttgart: Beitr. z. Chir. Festschr. f. Theodor Billroth; 1892. p. 610-630.
- 59 Baer AN, Gourin CG, Westra WH, Cox D, et al. *Sjögren's International Collaborative Alliance. Rare diagnosis of IgG4-related systemic disease by lip biopsy in an international Sjögren syndrome registry.* Oral Surg Oral Med Oral Pathol Oral Radiol 2013;115:e34-9.
- 60 Stone JH, Zen Y, Deshpande V. *IgG4-related disease.* N Engl J Med 2012;366:539-51.
- 61 Moriyama M, Tanaka A, Maehara T, et al. *T helper subsets in Sjogren's syndrome and IgG4-related dacryoadenitis and sialoadenitis: a critical review.* J Autoimmun 2014;51:81-8.
- 62 Shimizu Y, Yamamoto M, Naishiro Y, et al. *Necessity of early intervention for IgG4-related disease-delayed treatment induces fibrosis progression.* Rheumatology 2013;52:679-83.

Received: September 15, 2016 - Accepted: December 12, 2016

# Interventional sialendoscopy for radioiodine-induced sialadenitis: quo vadis?

## *La scialoendoscopia interventistica per le scialoadeniti radioiodio-indotte: quo vadis?*

P. CANZI<sup>1</sup>, S. CACCIOLA<sup>1</sup>, P. CAPACCIO<sup>2,3</sup>, F. PAGELLA<sup>1</sup>, A. OCCHINI<sup>1</sup>, L. PIGNATARO<sup>2,4</sup>, M. BENAZZO<sup>1</sup>

<sup>1</sup> Department of Otorhinolaryngology, University of Pavia, IRCCS Policlinico "San Matteo" Foundation, Pavia, Italy; <sup>2</sup> Department of Otolaryngology and Head and Neck Surgery, Fondazione IRCCS Ca' Granda Ospedale Maggiore Policlinico, Milan, Italy; <sup>3</sup> Department of Biomedical, Surgical and Dental Sciences; <sup>4</sup> Department of Clinical Sciences and Community Health, Università degli Studi di Milano, Milan, Italy

### SUMMARY

Salivary gland toxicity is a common adverse effect of radioactive iodine (<sup>131</sup>I) for the treatment of thyroid cancers with a prevalence ranging from 2% to 67% of the <sup>131</sup>I exposed population. Recently, sialendoscopy has been introduced as an attractive diagnostic and therapeutic tool for management of patients with radioiodine-induced sialadenitis that is unresponsive to standard medical treatments. The objective of the current review was to assess the impact of this procedure on outcomes in patients suffering from radioiodine sialadenitis. Overall, eight studies were included and 122 patients underwent 264 sialendoscopic procedures. Duct stenosis and mucous plugs were observed in 85.7% of endoscopic findings, supporting the role of ductal obstruction in the pathophysiology of radioiodine sialadenitis. In total, 89.3% of patients experienced complete or partial resolution of sialadenitis recurrences without any major adverse events, and parotidectomy was advocated in only 1 case. However, outcomes mainly concerned subjective reports and only two clinical experiences evaluated objective measurement with dissimilar results. Limited to few studies, xerostomia and obstructive symptoms responded differently after sialendoscopy. The optimal timing of salivary gland videoendoscopy needs to be further analysed in order to define the best management of radioiodine-induced obstructive sialadenitis.

KEY WORDS: Sialadenitis • Radioiodine • Sialendoscopy • Salivary glands • Endoscopy

### RIASSUNTO

*La tossicità delle ghiandole salivari rappresenta un noto effetto indesiderato dello iodio radioattivo (<sup>131</sup>I) utilizzato per il trattamento di neoplasie tiroidee, con una prevalenza che varia dal 2% al 67% della popolazione esposta. Recentemente, la scialoendoscopia è stata introdotta come un interessante strumento diagnostico e terapeutico per la gestione dei pazienti affetti da scialoadenite radioiodio-indotta non responsiva ai trattamenti medici standard. L'obiettivo della presente revisione è stato valutare l'influenza di questa procedura sulla storia clinica di pazienti affetti da scialoadenite conseguente a trattamento con radioiodio. Complessivamente, la revisione ha incluso 8 studi, 122 pazienti e 264 scialoendoscopie. Le stenosi duttali ed i tappi mucosi hanno rappresentato l'85.7% dei reperti endoscopici, sostenendo il ruolo dell'ostruzione duttale nella fisiopatologia della scialoadenite da radioiodio. Circa l'89.3% dei pazienti riportarono una risoluzione parziale o completa degli episodi di scialoadenite ricorrente, senza complicanze post-operatorie maggiori. Un solo caso è stato sottoposto a parotidectomia per fallimento del trattamento scialoendoscopico e persistenza dei sintomi. Tuttavia, i risultati della letteratura riguardarono principalmente valutazioni soggettive e solamente in due esperienze cliniche furono prese in considerazione misure oggettive con risultati discordanti. La xerostomia fu analizzata in pochi studi, con benefici differenti rispetto ai sintomi ostruttivi. La tempistica ideale per la videoendoscopia delle ghiandole salivari necessita di ulteriori analisi, al fine di definire la miglior gestione delle scialoadeniti ostruttive radioiodio-indotte.*

PAROLE CHIAVE: Scialoadenite • Radioiodio • Scialoendoscopia • Ghiandole salivari • Endoscopia

Acta Otorhinolaryngol Ital 2017;37:155-159

## Introduction

Salivary gland toxicity after radioiodine therapy is a widely documented adverse effect of radioactive iodine (<sup>131</sup>I) in the treatment of differentiated thyroid cancers <sup>1</sup>. Swelling, pain and xerostomia, usually bilateral, are present in 2% to 67% of the <sup>131</sup>I exposed population <sup>2</sup>. Epidemiological data are still unclear because many factors can influence post-radioiodine salivary dysfunction: dose and timing of

administered <sup>131</sup>I, previous history of salivary gland disorders as well as other causes of xerostomia or increased <sup>131</sup>I retention <sup>2,3</sup>. Salivary gland injuries can be quantified by technetium scintigraphy, but the total cumulative <sup>131</sup>I dose may not strictly relate with clinical manifestations <sup>4,5</sup>. Clinical onset may occur early (within 48 hours) or late (3-6 months) after irradiation. Radiation damage to the salivary glands results from their selective ability

of uptake and concentrate iodine as high as 7-700 times plasma levels, probably through a sodium/potassium/chloride cotransporter<sup>6-9</sup>. Furthermore, <sup>131</sup>I induced harmful effects appear to be related to increased permeability of the gland vascular endothelium leading to leakage of plasma proteins and electrolytes. Adverse events include parenchymal injuries and salivary duct obstructions that trigger an inflammatory vicious circle able to amplify <sup>131</sup>I uptake. More frequently involved, serous glands express a greater ability to concentrate iodine in comparison with mucous ones. Prevention and management of radioiodine-induced sialadenitis are widely debated in literature, and contradictory data are available concerning the adoption of sialagogues and anti-inflammatory drugs to avoid recurrences<sup>2</sup>. Proper patient education, hydration with salivary gland massage and antibiotic administration in case of suppurative evolution represent the standard management of sialadenitis with estimated benefit in about 70% of cases<sup>10,11</sup>. In 2006, for the first time, 15 patients suffering from sialadenitis secondary to <sup>131</sup>I underwent sialendoscopy with advantages in all cases following a single procedure only, under local anaesthesia<sup>12</sup>. The promising results of this inedited therapeutic option, led to new international experiences that have not been compared or analysed. The aim of the present study was to carry out a comprehensive review of salivary gland videoendoscopy applied to radioiodine-induced sialadenitis, in order to assess the impact of this procedure on outcomes.

## Materials and methods

A systematic literature search was conducted using electronic databases (Medline, Embase, Scopus). The research strategy was performed combining intervention-specific terms (“sialoendoscopy”, “sialendoscopy”, “endoscopy”) with disease-specific terms (“radioiodine-induced sialadenitis”, “radioiodine sialoadenitis”, “radioiodine”, “<sup>131</sup>I”). Levels of evidence were assigned according to the Oxford

Centre for Evidence based Medicine<sup>13</sup>. Inclusion criteria for published studies where the following: (1) randomised controlled trial, prospective and retrospective studies; (2) evaluation and description of sialendoscopic outcomes in patients suffering from typical <sup>131</sup>I-induced sialadenitis, such as swelling, pain and xerostomia. Review articles, case reports, abstracts without a full text, letters and editorials were excluded, as well as non-English publications. The primary endpoint of this review was to evaluate the success rate of interventional sialendoscopy assessed as a reduction (“improved” patients) and/or resolution (“cured” patients) of salivary gland painful swellings. Secondary endpoints were: sialendoscopic findings, pre- and postoperative assessment of salivary gland function (by scintigraphy), pre- and postoperative evaluation of xerostomia, postoperative morbidity defined as all complications following sialendoscopy, percentage of gland excision after sialendoscopy. The last search was conducted on 30<sup>th</sup> September 2016.

## Results

Eight studies satisfied the inclusion criteria: levels of evidence ranged between 3 and 4 in all studies (Table I). All enrolled patients complained of two or more recurrent events of sialadenitis after radioiodine therapy. In seven studies, all patients were submitted to interventional sialendoscopy only after conservative medical treatment failures. The median time from radioiodine treatment to sialendoscopy was 11 months, ranging from 4.5<sup>11</sup> to 16<sup>10</sup> months (Table II). Interestingly, only in Wu et al.<sup>17</sup>, enrolled patients had never attempted conservative treatments before sialendoscopy. All authors, except Nahlieli et al.<sup>12</sup>, reported the mean dose of radioiodine, which ranged from 107 mCi<sup>16</sup> to 250 mCi<sup>10</sup>, with a mean cumulative radioiodine dose of 163.7 mCi. When reported, 74.7% received a single radioiodine treatment, and the remaining 25.3% underwent multiple treatments. The overall population was composed of 122

**Table I.** Clinical studies.

| Author, year                 | No. of patients | No. of sialendoscopies | Sialendoscope; size   | Mean follow-up | Level of evidence |
|------------------------------|-----------------|------------------------|---|----------------|-------------------|
| Nahlieli, 2006 <sup>12</sup> | 15              | 15                     | NA; 1.3 mm  | NA             | 4                 |
| Kim, 2007 <sup>11</sup>      | 6               | 6                      | NA; NA  | NA             | 4                 |
| Bomeli, 2009 <sup>14</sup>   | 12              | 32                     | Marchal sialendoscope (Karl Storz, Tuttlingen, Germany); 1.3 mm | NA             | 4                 |
| Prendes, 2012 <sup>10</sup>  | 11              | 29                     | Marchal sialendoscope (Karl Storz, Tuttlingen, Germany); 1.3 mm | 14.4 months    | 4                 |
| De Luca, 2014 <sup>15</sup>  | 30              | 80                     | NA; NA  | NA             | 4                 |
| Bhayani, 2015 <sup>16</sup>  | 26              | 68                     | Karl Storz sialendoscope (El Segundo, CA); NA                   | 23.4 months    | 4                 |
| Wu, 2015 <sup>17</sup>       | 12              | 19                     | PolyDiagnost sialendoscope (Hallbergmoos, Germany); NA          | NA             | 4                 |
| Kim, 2016 <sup>18</sup>      | 10              | 15                     | Karl Storz sialendoscope (Tuttlingen, Germany); 1.1 mm          | 5 months       | 3                 |

NA: data not available

**Table II.** Demographic and clinical data.

| Patients                                    |                    |
|---|--------------------|
| Number of patients                          | 122                |
| Sex   |                    |
| Male  | 13.8%              |
| Female                                      | 86.2%              |
| Mean age                                    | 45.9 years         |
| Histology*                                  |                    |
| Papillary thyroid carcinoma                 | 79.8%              |
| Follicular thyroid carcinoma                | 14.4%              |
| Other histologies                           | 5.8%               |
| Cumulative radioiodine dose (mCi)           |                    |
| Mean dose (min-max)                         | 163.7 (107-250)    |
| Salivary glands submitted to sialendoscopy* |                    |
| Parotid gland                               | 75.7%              |
| Submandibular gland                         | 24.3%              |
| Main sialendoscopic findings *              |                    |
| Stenosis                                    | 46.3%              |
| Mucous plugs                                | 39.4%              |
| Sialodochitis                               | 14.3%              |
| Sialendoscopy                               |                    |
| No. of primary treatments performed (%)     | 240 (90.9%)        |
| No. of secondary treatments performed (%)   | 24 (9.1%)          |
| Time from radioiodine to sialendoscopy      |                    |
| Median time (range), months                 | 11 (4.5-16) months |

\* Absolute value not available for incomplete data

patients (13.8% males, 86.2% females), mean age 45.9 years, with greater involvement of parotid glands (75.7%) submitted to sialendoscopy compared to submandibular glands (24.3%). In 79.8% of patients, <sup>131</sup>I had been given for papillary thyroid carcinoma, in 14.4% for follicular thyroid carcinoma and in the remaining 5.8% for other histologies. Overall, 240 sialendoscopies in 122 patients were carried out as primary treatment, consequently it may be assumed that multiple glands were often submitted simultaneously to interventional sialendoscopy in the same patient. The type of anaesthesia was specified in 4 studies: Nahlieli et al. <sup>12</sup> and De Luca et al. <sup>15</sup> performed all the procedures under local anaesthesia; Prendes et al. <sup>10</sup> and Bhayani et al. <sup>16</sup> opted for general anaesthesia. Only Prendes et al. <sup>10</sup> reported one case of unsuccessful cannulation of the duct. When reported, stenosis was the most relevant endoscopic finding (46.3%) followed by fibrinous debris/mucous plugs and sialodochitis in 39.4% and 14.3% of patients respectively. No studies reported the type of stenosis according to Koch classification <sup>19</sup>. All therapeutic procedures comprised irrigation with isotonic saline solution plus steroids (of different types according to each study), with the exception of the Wu et al. series <sup>17</sup>, in which sterile saline solution was mixed with gentamicin. In all cases, stenosis management required

**Table III.** Therapeutic success after interventional sialendoscopy.

| Therapeutic Success*                    |                   |
|---|-------------------|
| <b>Complete therapeutic success (%)</b> | <b>40 (33.1%)</b> |
| After primary procedure (%)             | 40 (100%)         |
| After secondary procedures (%)          | 0                 |
| <b>Partial therapeutic success (%)</b>  | <b>68 (56.2%)</b> |
| After primary procedure (%)             | 64 (94.1%)        |
| After secondary procedures (%)          | 4 (5.9%)          |
| <b>Unsuccessful treatment (%)</b>       | <b>13 (10.7%)</b> |
| <b>TOTAL (%)**</b>                      | <b>121 (100%)</b> |

\*Therapeutic success was referred to the number of patients

\*\*Total number of patients was 121 because 1 patient was lost to follow-up

multiple techniques involving instrumental and hydraulic ductal dilation. Balloon dilation, as well as salivary stent positioning, were performed when needed, but no detailed data about the number of cases was available. No clinical study reported the frequency of sialadenitis before and after sialendoscopy, even though a high success rate (89.3%) was documented in all clinical trials with a complete resolution of symptoms in 33.1% of the overall population and partial improvement in 56.2% (Table III). When successfully performed (108 patients), sialendoscopy was effective as primary treatment in 104 patients (96.3%) and as a further therapeutic option in only 4 patients (3.7%). In 10.7% of cases, salivary gland endoscopy did not provide an advantages for sialadenitis recurrence. One case of parotidectomy was carried out, with an overall percentage of gland excision of 0.8%<sup>10</sup>. Only Kim <sup>18</sup> et al. and Wu et al. <sup>17</sup> analysed the functional outcome of sialendoscopy by salivary gland scintigraphy. In the first study <sup>18</sup>, pre- and post-sialendoscopy outcomes did not differ in uptake ratio, maximum accumulation and secretion by salivary gland scintigraphy. Differently, in Wu et al. <sup>17</sup> the scintigraphy results showed a statistically significant higher uptake ratio and excretion fraction after interventional sialendoscopy. Concerning xerostomia, only Bhayani et al. <sup>16</sup> and Kim et al. <sup>18</sup> quantitatively assessed saliva production and evaluated dry mouth symptoms with a standard quality of life xerostomia questionnaire. Bhayani et al. <sup>16</sup> observed a partial or complete relief of xerostomia symptoms in 77.3% of patients and sialometric data revealed a statistically significant difference in saliva production at 6 months following sialendoscopy for unstimulated salivary flow. In Kim et al. <sup>18</sup>, xerostomia-related symptom scores after sialendoscopy did not differ significantly in comparison with pre-endoscopic scores and there were no statistically significant differences between pre- and post-sialendoscopy stimulated salivary flow rate. No major adverse events were documented in any study.

## Discussion

In 1805, Philipp Bozzini announced in a daily German newspaper the development of a novel device that some years later was considered the progenitor of current endoscopes: the Lichtleiter or “Light Conductor”<sup>20</sup>. Since then, the evolution of endoscope-assisted techniques has revolutionised the concept of surgery introducing a new era of minimally-invasive medicine. This change of perspective was made possible by continuous progress in medical knowledge and technology with a positive influence in many fields of healthcare. From its first documentation in early 1990s<sup>21,22</sup>, salivary gland videoendoscopy or sialendoscopy was largely applied in diagnosis and treatment of sialolithiasis and salivary duct stenosis with significant results<sup>23-25</sup>. The potential implications of this innovative tool were noted by the increasing number of published studies, as well as by the further applications in patients suffering from obstructive salivary gland disorders<sup>26,27</sup>. Radioiodine-induced sialadenitis represents one of the latest employments of sialendoscopy: even if many authors have advocated its usefulness, debate is still open on the real effectiveness of this procedure and a comprehensive review had never been performed. According to our literature analysis, 122 patients underwent 240 sialendoscopic procedures as primary treatment, followed by 24 secondary sialendoscopies. The vast majority of patients were women (86.2%) probably due to the epidemiological distribution of thyroid carcinomas susceptible to radioiodine therapy. The parotid gland was most frequently affected according with the higher concentration of serous acini as well as a lower clearance rate of salivary flow in comparison with submandibular gland<sup>28,29</sup>. Duct stenosis and mucous plugs were observed in 85.7% of endoscopic findings, supporting the role of ductal obstruction in the pathophysiology of radioiodine sialadenitis. In all, 89.3% of patients experienced a complete or partial resolution of sialadenitis recurrences and parotidectomy was advocated only in 1 case<sup>10</sup>. Mean follow-up period was specified in only three studies (Table I). In all studies, with the exception of Wu et al.<sup>17</sup>, interventional sialendoscopy was performed in case of medical treatment failure and after a median time of 11 months from <sup>131</sup>I therapy, both indicating the chronicity of the disease prior to sialendoscopy.

Despite the encouraging results, some critical considerations are necessary. The success rate was the result of different therapeutic strategies considering the type of steroid irrigation, the use of hydraulic, instrument and/or balloon dilation, the adoption of salivary stents, the ductal injection of antibiotics and the specific timing of sialendoscopic procedures. Moreover, the relief of painful swellings was mainly limited to subjective reports of symptomatic improvement, lacking a detailed description of the frequency of recurrence and a validated objective measurement.

Only two studies quantitatively assessed salivary gland

function by salivary scintigraphy, with contradictory results. According to Kim et al.<sup>18</sup>, there were no significant differences in functional outcomes between pre- and post-operative sialendoscopy, even if obstructive symptoms were always improved. Wu et al. reported improved salivary gland scintigraphy scores in 78.9% of glands in line with better symptomatic results<sup>17</sup>. Interestingly, the two studies mostly differed in the time to treatment (mean 13 months versus “early treatment” not further specified), in the mean cumulative <sup>131</sup>I dose (more than 150 mCi versus 125 mCi), in the type of ductal stenosis regarding site, number and severity (not comparable due to the lack of data) and finally in study design (prospective versus retrospective). Subjective and objective assessment of xerostomia was limited to few patients in two clinical studies, with dissimilar results. Bhayani et al.<sup>16</sup> documented symptomatic and sialometric benefits after sialendoscopy, differently from Kim et al.<sup>18</sup> in which xerostomia and obstructive symptoms responded differently after sialendoscopy. The safety of sialendoscopy was supported by all studies with no major adverse events documented.

## Conclusions

Recently, sialendoscopy has been advocated as an attractive diagnostic and therapeutic choice in patients with radioiodine-induced sialadenitis who are unresponsive to medical treatments. Eight international experiences have reported promising results with improvement of painful swellings in 89.3% of the cases and no major adverse events. However, small population sizes, the absence of randomised studies and heterogeneous follow-up times as well as different interventional sialendoscopic strategies strongly weaken the overall level of evidence. Furthermore, objective outcomes are limited to few studies with different methods of study and dissimilar results. Optimal timing of salivary gland videoendoscopy needs to be further analysed to define the best management strategy of radioiodine-induced obstructive sialadenitis.

## References

- 1 Lee SL. *Complications of radioactive iodine treatment of thyroid carcinoma*. J Natl Compr Canc Netw 2010;8:1277-86.
- 2 Van Nostrand D. *Sialoadenitis secondary to <sup>131</sup>I therapy for well-differentiated thyroid cancer*. Oral Dis 2011;17:154-61.
- 3 Mandel SJ, Mandel L. *Radioactive iodine and the salivary glands*. Thyroid 2003;13:265-71.
- 4 Hyer S, Kong A, Pratt B et al. *Salivary gland toxicity after radioiodine therapy for thyroid cancer*. Clin Oncol (R Coll Radiol) 2007;19:83-6.
- 5 Caglar M, Tuncel M, Alpar R. *Scintigraphic evaluation of salivary gland dysfunction in patients with thyroid cancer after radioiodine treatment*. Clin Nucl Med 2002;27:767-71.
- 6 Freinkel N, Ingbar SH. *Concentration gradients for inorgan-*

- ic I131 and chloride in mixed human saliva. *J Clin Invest* 1953;32:1077-84.
- 7 Myant NB. *Iodine metabolism of salivary glands*. *Ann N Y Acad Sci* 1960;85:208-14.
  - 8 Rice DH. *Advances in diagnosis and management of salivary gland diseases*. *West J Med* 1984;140:238-49.
  - 9 Schiff L, Stevens CD, Molle WE, et al. *Gastric (and salivary) excretion of radioiodine in man (preliminary report)*. *J Natl Cancer Inst* 1947;7:349-54.
  - 10 Prendes BL, Orloff LA, Eisele DW. *Therapeutic sialendoscopy for the management of radioiodine sialadenitis*. *Arch Otolaryngol Head Neck Surg* 2012;138:15-9.
  - 11 Kim JW, Han GS, Lee SH, et al. *Sialoendoscopic treatment for radioiodine induced sialadenitis*. *Laryngoscope* 2007;117:133-6.
  - 12 Nahlieli O, Nazarian Y. *Sialadenitis following radioiodine therapy - a new diagnostic and treatment modality*. *Oral Dis* 2006;12:476-9.
  - 13 Phillips B, Ball C. *Levels of Evidence and Grades of Recommendation*. Oxford: Oxford Centre for Evidence-Based Medicine; 2001.
  - 14 Bomeli SR, Schaitkin B, Carrau RL, et al. *Interventional sialendoscopy for treatment of radioiodine-induced sialadenitis*. *Laryngoscope* 2009;119:864-7.
  - 15 De Luca R, Vicidomini A, Trodella M et al. *Sialoendoscopy: a viable treatment for I(131) induced sialoadenitis*. *Br J Oral Maxillofac Surg* 2014;52:641-6.
  - 16 Bhayani MK, Acharya V, Kongkiatkamon S, et al. *Sialendoscopy for patients with radioiodine-induced sialadenitis and xerostomia*. *Thyroid* 2015;25:834-8.
  - 17 Wu CB, Xi H, Zhou Q, et al. *Sialendoscopy-assisted treatment for radioiodine-induced sialadenitis*. *J Oral Maxillofac Surg* 2015;73:475-81.
  - 18 Kim YM, Choi JS, Hong SB, et al. *Salivary gland function after sialendoscopy for treatment of chronic radioiodine-induced sialadenitis*. *Head Neck* 2016;38:51-8.
  - 19 Koch M, Iro H, Zenk J. *Sialendoscopy-based diagnosis and classification of parotid duct stenoses*. *Laryngoscope* 2009;119:1696-703.
  - 20 Morgenstern L. *The 200<sup>th</sup> anniversary of the first endoscope: Philipp Bozzini (1773-1809)*. *Surg Innov* 2005;12:105-6.
  - 21 Katz P. *New method of examination of the salivary glands: the fiberscope*. *Inf Dent* 1990;72:785-6.
  - 22 Königsberger R, Feyh J, Goetz A, et al. *Endoscopic controlled laser lithotripsy in the treatment of sialolithiasis*. *Laryngorhinootologie* 1990;69:322-3.
  - 23 Gallo A, Capaccio P, Benazzo M, et al. *Outcomes of interventional sialendoscopy for obstructive salivary gland disorders: an Italian multicentre study*. *Acta Otorhinolaryngol Ital* 2016;36:479-85.
  - 24 Capaccio P, Torretta S, Ottaviani F, et al. *Modern management of obstructive salivary diseases*. *Acta Otorhinolaryngol Ital* 2007;27:161-72.
  - 25 Strychowsky JE, Sommer DD, Gupta MK, et al. *Sialendoscopy for the management of obstructive salivary gland disease: a systematic review and meta-analysis*. *Arch Otolaryngol Head Neck Surg* 2012;138:541-7;
  - 26 Gallo A, Benazzo M, Capaccio P, et al. *Sialoendoscopy: state of the art, challenges and further perspectives*. Round Table, 101<sup>st</sup> SIO National Congress, Catania 2014. *Acta Otorhinolaryngol Ital* 2015;35:217-33.
  - 27 Canzi P, Occhini A, Pagella F, et al. *Sialendoscopy in juvenile recurrent parotitis: a review of the literature*. *Acta Otorhinolaryngol Ital* 2013;33:367-73.
  - 28 Jeong SY, Kim HW, Lee SW, et al. *Salivary gland function 5 years after radioactive iodine ablation in patients with differentiated thyroid cancer: direct comparison of pre- and postablation scintigraphies and their relation to xerostomia symptoms*. *Thyroid* 2013;23:609-16.
  - 29 La Perle KM, Kim DC, Hall NC, et al. *Modulation of sodium/iodide symporter expression in the salivary gland*. *Thyroid* 2013;23:1029-36.

Received: September 15, 2016 - Accepted: December 12, 2016

Address for correspondence: Pietro Canzi, Department of Otorhinolaryngology, IRCCS Policlinico San Matteo Foundation and University of Pavia, viale Camillo Golgi 19, 27100, Pavia, Italy. Fax +39 0382 528184. E-mail: [pietro.canzi@unipv.it](mailto:pietro.canzi@unipv.it)



# Modern management of paediatric obstructive salivary disorders: long-term clinical experience

## *La gestione moderna dei disordini ostruttivi salivari in età pediatrica: esperienza clinica a lungo termine*

P. CAPACCIO<sup>1,2\*</sup>, P. CANZI<sup>3\*</sup>, M. GAFFURI<sup>1</sup>, A. OCCHINI<sup>3</sup>, M. BENAZZO<sup>3</sup>, F. OTTAVIANI<sup>4</sup>, L. PIGNATARO<sup>1,5</sup>

<sup>1</sup> Department of Otolaryngology and Head and Neck Surgery, Fondazione IRCCS Ca' Granda Ospedale Maggiore Policlinico, Milan, Italy; <sup>2</sup> Department of Biomedical, Surgical and Dental Sciences, Università degli Studi di Milano, Milan, Italy; <sup>3</sup> Department of Otorhinolaryngology, University of Pavia, IRCCS Policlinico San Matteo Foundation, Pavia, Italy; <sup>4</sup> Department of Clinical Sciences and Community Health, Università degli Studi di Milano Ospedale Fatebenefratelli San Giuseppe, Milano; <sup>5</sup> Department of Clinical Sciences and Community Health, Università degli Studi di Milano, Milan, Italy

\*These authors contributed equally to this article.

### SUMMARY

Recent technological improvements in head and neck field have changed diagnostic and therapeutic strategies for salivary disorders. Diagnosis is now based on colour Doppler ultrasonography (US), magnetic resonance (MR) sialography and cone beam 3D computed tomography (CT), and extra- and intracorporeal lithotripsy, interventional sialendoscopy and sialendoscopy-assisted surgery are used as minimally invasive, conservative procedures for functional preservation of the affected gland. We evaluated the results of our long-term experience in the management of paediatric obstructive salivary disorders. The study involved a consecutive series of 66 children (38 females) whose obstructive salivary symptoms caused by juvenile recurrent parotitis (JRP) (n = 32), stones (n = 20), ranula (n = 9) and ductal stenosis (n = 5). 45 patients underwent interventional sialendoscopy for JRP, stones and stenoses, 12 a cycle of extracorporeal shockwave lithotripsy (ESWL), three sialendoscopy-assisted transoral surgery, one drainage, six marsupialisation, and two suturing of a ranula. Three children underwent combined ESWL and interventional sialendoscopy, and seven a secondary procedure. An overall successful result was obtained in 90.9% of cases. None of the patients underwent traditional invasive sialadenectomy notwithstanding persistence of mild obstructive symptoms in six patients. No major complications were observed. Using a diagnostic work-up based on colour Doppler US, MR sialography and cone beam 3D TC, children with obstructive salivary disorders can be effectively treated in a modern minimally-invasive manner by extracorporeal and intracorporeal lithotripsy, interventional sialendoscopy and sialendoscopy-assisted transoral surgery; this approach guarantees a successful result in most patients, thus avoiding the need for invasive sialadenectomy while functionally preserving the gland.

**KEYWORDS:** Salivary calculi • Ranula • Juvenile recurrent parotitis • Salivary duct stenosis • Paediatric age • Sialendoscopy • Ultrasonography • Extracorporeal lithotripsy • Intracorporeal lithotripsy • Sialendoscopy-assisted transoral surgery

### RIASSUNTO

*I disordini ostruttivi salivari sono infrequenti nell'età pediatrica. I recenti progressi tecnologici nel distretto della testa e del collo hanno modificato la strategia diagnostica e terapeutica dei disordini salivari. La diagnosi è oggi basata sull'eco color Doppler, sulla scialo-RMN, sulla cone beam 3D TC, mentre la litotrissia extracorporea ed intracorporea, la scialoendoscopia interventistica, la chirurgia scialoendoscopico-assistita, sono attualmente utilizzati come procedure conservative e mininvasive per la preservazione funzionale della ghiandola affetta. Abbiamo analizzato i risultati dell'esperienza clinica a lungo termine nel trattamento dei disordini ostruttivi dell'età pediatrica. Un gruppo consecutivo di 66 pazienti pediatrici (38 femmine) con sintomi salivari ostruttivi causati da parotite ricorrente pediatrica (32 pazienti), calcoli (20), stenosi duttali (5), e ranule (9) è stato incluso nello studio. 45 pazienti sono stati sottoposti a scialoendoscopia interventistica per parotite ricorrente, calcoli e stenosi, 12 pazienti sono stati sottoposti ad un ciclo di litotrissia extracorporea (ESWL), tre pazienti a chirurgia transorale scialoendoscopico-assistita, un paziente a drenaggio, sei a marsupializzazione e due a sutura della ranula. Nel 90,9% è stato raggiunto un risultato favorevole. L'approccio combinato di litotrissia salivare extracorporea e di scialoendoscopia interventistica è stato utilizzato in tre pazienti ed una procedura secondaria è stata eseguita in sette pazienti. Nessun paziente è stato sottoposto a scialoadenectomia nonostante la persistenza di modesti sintomi ostruttivi in sei pazienti. Non è stata osservata alcuna complicanza maggiore. Adottando un adeguato iter diagnostico mediante eco color Doppler delle ghiandole salivari, scialo-RMN e cone beam 3D TC, i pazienti pediatrici con disordini ostruttivi salivari possono essere efficacemente trattati con un approccio moderno mini-invasivo mediante tecniche di litotrissia extracorporea ed intracorporea, scialoendoscopia interventistica, e chirurgia transorale scialoendoscopico-assistita; questo approccio garantisce un risultato favorevole nella maggior parte dei pazienti evitando così il ricorso alla scialoadenectomia invasiva e mantenendo così la preservazione funzionale della ghiandola coinvolta.*

**PAROLE CHIAVE:** Calcoli salivari • Ranula • Parotite ricorrente pediatrica • Stenosi duttale • Litotrissia salivare extracorporea • Litotrissia intracorporea • Ecografia • Chirurgia transorale

## Introduction

Salivary gland disorders other than infectious conditions are less frequent in children than in adults, and neoplastic lesions are rare. The most frequent clinical manifestations are inflammatory events, which occur in about 10% of all salivary gland disorders<sup>1,2</sup>. The wide range of factors involved in paediatric salivary gland disorders makes clinical management of childhood and adolescent salivary gland swelling challenging. Over the last 20 years or so, healthcare technological research has opened up new diagnostic and therapeutic perspectives. Recent radiological approaches have replaced conventional sialography for morphological investigation of the salivary gland duct system, and introduced more precise and non-invasive alternatives. The use of modern colour Doppler ultrasonography (US) allows a detailed assessment of salivary vascular anatomy and flow velocity<sup>2</sup>. Magnetic resonance (MR) sialography is a non-ionising, non-allergenic means of exploring salivary gland ducts that uses a natural contrast medium (saliva) and does not require duct cannulation<sup>3</sup>, and cone beam computed tomography (CBCT) has been proposed as a cheaper alternative to traditional CT that reduces the amount of radiation exposure, especially in paediatric patients<sup>4</sup>. First described in the 1990s, sialendoscopy<sup>5,6</sup> is increasingly used because the advantage of seeing inside the duct system allows both diagnostic and therapeutic procedures. Historical treatments such as partial or complete gland removal are being progressively abandoned in favour of minimally invasive approaches, which currently represent the new medical standard of care and have a considerable impact on paediatric patients. Nevertheless, there is still a relative paucity of published data concerning recurrent inflammatory disorders of the salivary glands in children<sup>7,8,9,10-13</sup>, and so the aim of this study was to analyse our 20-year experience of paediatric salivary obstructive disorders and their minimally invasive management.

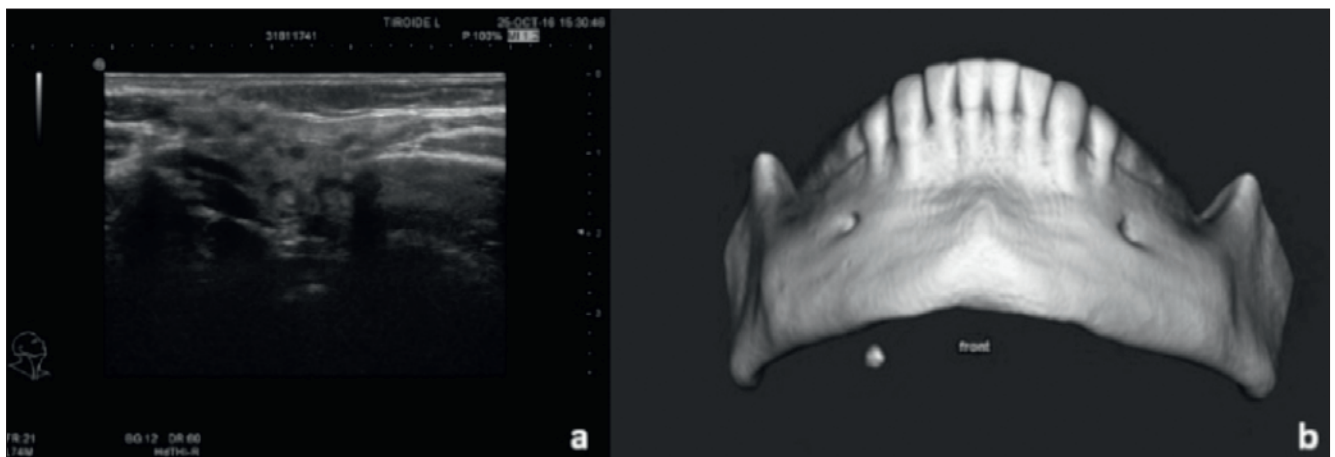
## Materials and methods

Between March 1994 and December 2015, 66 children with obstructive salivary gland or oral floor swelling (38 girls; mean age 7.9 years, range 1-16) were treated at the Departments of Otolaryngology and Head and Neck Surgery of Fondazione IRCCS Ca' Granda Policlinico of Milan and Fondazione IRCCS Policlinico San Matteo of Pavia. All patients had experienced at least one episode of parotid, submandibular or sublingual swelling. All patients underwent a complete ENT clinical examination, including inspection and palpation of the oral floor and major salivary glands, and high-resolution US and Doppler US assessments (Hitachi H21, 7.5 MHz, Hitachi High Technology Corporation Ltd., Tokyo, Japan) (Fig. 1a); further investigations included MR sialography and CBCT (Fig. 1b) when necessary. Subsequently, various therapeutic options were adopted on the basis the clinical and radiological findings.

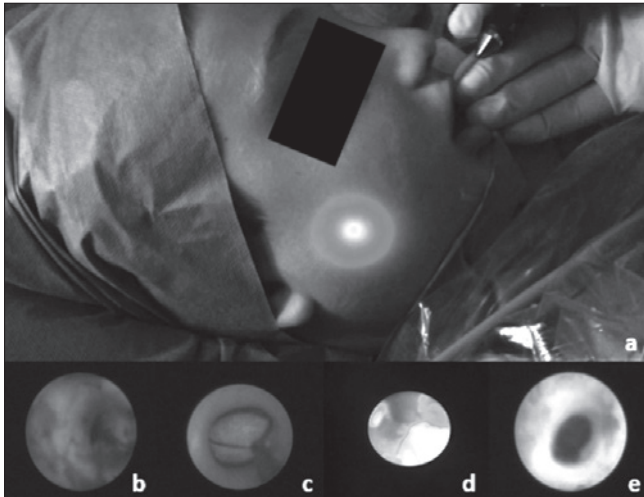
### *Therapeutic options*

#### *Diagnostic and interventional sialendoscopy*

Sialendoscopy was performed under general anaesthesia with the patients in a half-seated position, with the head on a headrest turned towards the surgeon and mouth held open by a small gag. Endoscopic exploration of the ductal system of the affected gland was performed using semi-rigid salivary sialendoscopes (Fig. 2a) with outer diameters of 0.8-1.1 mm (Nahlieli and Erlangen sialendoscopes, Karl Storz®, Tuttlingen, Germany). Insertion through the salivary duct was preceded by appropriate dilation with standard salivary probes and conical dilators (Bowman probes 0000-6, Karl Storz®, Tuttlingen, Germany) and, when necessary, minimal papillotomy or limited minimal sialodochotomy. A sialendoscopic diagnosis of lithiasis was made by directly visualising the duct stone, and a diagnosis of duct stenosis was based on the grading system of Koch et



**Fig. 1.** High-resolution US of a patient affected by JRP, showing typical hypoechoic areas and heterogeneous echoes (a); 3D-CBCT image showing a right submandibular stone in a 15-year-old boy.



**Fig. 2.** Endoscopic exploration of the ductal system of a right parotid gland by means of a semi-rigid sialendoscope (a); sialodochitis of the Stensen's duct (b); a stone trapped in a basket wire (c); intraductal fragmentation of a stone by means of holmium:YAG laser lithotripter (the red light of the laser is visible at the centre of the picture) (d); endoscopic image of a salivary duct stenosis (e).

al.<sup>14</sup> Additional sialendoscopic findings were represented by sialodochitis (Fig. 2b), mucous plugs and other duct anomalies. When necessary, interventional sialendoscopy was performed during the same procedure. Parotid or submandibular stones of < 3 mm were extracted using customised wire baskets (Fig. 2c) (Karl Storz®, Tuttlingen, Germany; NCircle, Cook Medical Inc®, Bloomington, IN, USA; Boston Scientific®, Marlborough, MA, USA), forceps (Karl Storz®, Tuttlingen, Germany), balloons (Karl Storz®, Tuttlingen, Germany), or a manual drill (Karl Storz®, Tuttlingen, Germany). An intraductal holmium:YAG laser lithotripter (Lumenis®, Dreieich, Germany) carried by a semi-flexible fibre (diameter 200 or 365 µm, with a power of 2.5-3.5 W, a rate of 5 Hz/sec, and energy of 0.5-0.7 J) was used to fragment stones of ≥ 3 mm in diameter before extraction (Fig. 2d). Duct stenoses (Fig. 2e) were dilated by simple irrigation, balloon dilation and/or endoscopic stent positioning (venous catheter, Venflon, Artsana, Grandate, Italy; salivary polymeric stent, Optimed®, Ettlingen, Germany). At the end of the procedure the duct was washed with 2 mL of a betamethasone solution, corresponding to two vials of 4 mg/1 mL each. All patients received one-shot antibiotic therapy (amoxicillin and clavulanic acid) during the surgical procedure.

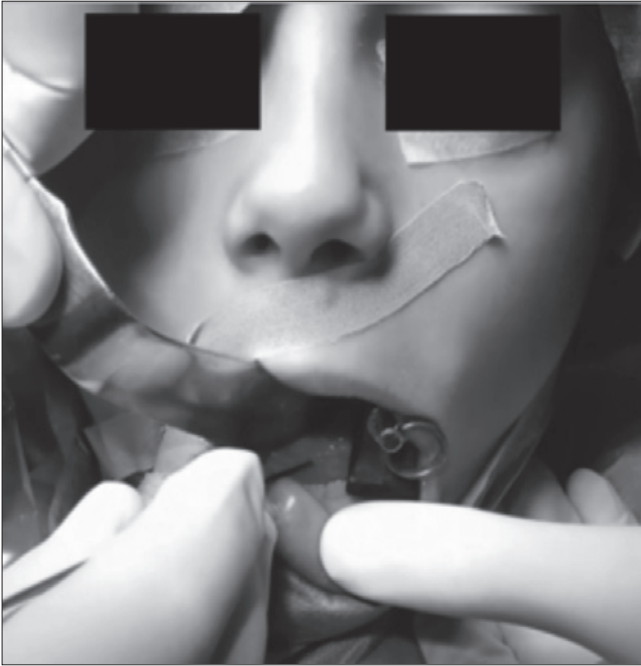#### *Extracorporeal shockwave lithotripsy (ESWL)*

Children with single or multiple parotid or submandibular calculi with a main diameter of 3-7 mm underwent a cycle of electromagnetic ESWL. A dedicated lithotripter with a mobile arm (Minilith SL -1, Storz Medical, Kreuzlingen, Switzerland) was used for treatment of salivary calculi. With the patient seated on a dentist's chair in a supine

semi-reclined position, the ultrasound-guided shockwave generated by a small-diameter, cylindric, electromagnetic source was focused on the salivary stone using a parabolic reflector within the cushion. The 2.4 mm size of the shockwave focus allows the treatment of stones with diameters of ≥ 2.4 mm. The pulse frequency of the wave may vary from 0.5 to 2 Hz, and no more than 4000 shockwaves may be administered per session. Continuous sonographic monitoring allows direct visualisation of the degree of fragmentation during treatment, and avoids lesions to the surrounding tissues. A typical session of ESWL for sialolithiasis lasts approximately 30 min (median duration 29 min; range 20-37 min), and the treatment is repeated weekly.

#### *Sialendoscopy-assisted transoral surgery for discrete and large submandibular stones of the main duct and hiloparenchymal region*

Single or multiple palpable stones in the main duct and hiloparenchymal submandibular region were sometimes removed using a sialendoscopy-assisted oral procedure with headlight illumination and the patient under general anaesthesia. The mouth was held open by a small gag, the tongue was retracted and the oral floor was infiltrated with 5 mL of mepivacaine 25 mg/ml + adrenaline 5 µg/ml. After dilating the duct with lacrimal probes (Fig. 3), a semi-rigid sialendoscope was inserted into the ductal system to localise the stone. A retropapillar incision was made over the oral floor mucosa, the tissue was bluntly dissected using sharp-tipped scissors and the duct was isolated from the surrounding tissues up to the second molar (the safe zone above the lingual nerve). The lingual nerve was identified running obliquely from the tongue, beneath the duct to the submandibular ganglion laterally, and then ascending medially over the submandibular duct as this enters the gland. The submandibular gland was identified by means of external digital pressure from the submandibular region. The duct was stretched using a fine haemostat swab and a minimal incision of the duct or the hiloparenchymal area was made over the stone, which was subsequently removed by means of a dedicated Freer elevator (Martin, Tuttlingen, Germany). The duct was then irrigated with normal saline to clean the hilar region and remove stone debris and, when possible, the ductal system was explored endoscopically to check for residual stones. In order to avoid the risk of post-operative duct stenosis a 14-20 G Venflon tube (Artsana, Grandate, Italy) was usually positioned through the papilla to stent the duct, and secured to the oral floor mucosa by means of a resorbable suture. Finally, the incision was closed using fine resorbable sutures (6.0 Vicryl) after positioning a fibrillar haemostatic net (Tabotamp, Johnson & Johnson Medical Limited, Gargrave, Skipton, UK) in order to avoid the risk of stricture or stenosis. The oral floor was then sutured using resorbable stitches (3.0 Vicryl).



**Fig. 3.** To perform a sialendoscopy-assisted oral procedure, the mouth is held open by a small gag and the tongue retracted; the first surgical step is to dilate the duct with lacrimal probes.

#### *Oral surgery for sublingual ranulas*

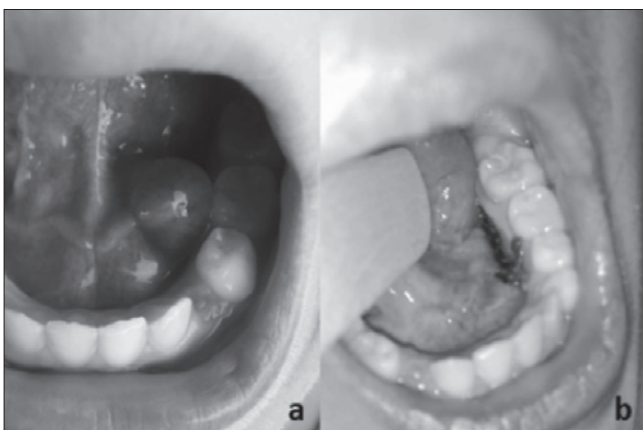Oral floor ranulas (Fig. 4a) were treated by various surgical procedures, mainly consisting of drainage, marsupialisation and suturing.

#### *Drainage*

With the patient under local anaesthesia, saliva was aspirated using a wide-bore needle to completely decompress the ranula, or the oral floor was incised using a size 11 scalpel.

#### *Traditional and modified marsupialisation*

Marsupialisation involved excising the ranula roof and suturing the lesion edges to the oral mucosa to maintain



**Fig. 4.** a left oral floor ranula in a female child (a); sutures in place 1 month after surgery, with no recurrence detectable (b).

communication with the oral cavity; in the case of modified marsupialisation, suturing the ranula edges to the oral mucosa preceded the excision of the roof of the lesion<sup>15</sup>. To avoid the resealing of the edge of the wound and subsequent recurrence, modified nasal packing (Mero-cel) was left over the floor of the lesion and sutured to the oral mucosa for three days.

#### *Suturing*

This technique has recently been described by Goodson et al.<sup>16</sup>. Two or three interrupted 3-0 gauge silk sutures are placed through the edge of the sublingual gland around the origin of the ranula. The leaking salivary unit is caught within the sutures and strangulated. The sutures help to decompress the ranula and cause fibrosis and scarring of the sublingual gland at the site of the salivary leak. To improve the process of scarring and fibrosis, we modified McGurk's technique by using two additional silk sutures placed positioned perpendicularly to the others to create loose rings that favour saliva leakage from the pseudocyst, prevent puffiness of the cavity and aid the scarring process (Fig. 4b). The sutures do not always need to be removed as they often come away during the healing process.

#### *Post-operative follow-up*

All patients received antibiotic prophylaxis (combined amoxicillin sodium and clavulanic acid 50 mg/kg/day for seven days) and, when necessary, steroids (betamethasone 0.2 mg/kg/day) to reduce oedema of the mouth floor. The children who underwent oral surgery for stones or ranulas followed a cold semi-solid diet for the first week. All patients were clinically followed up after one week, and then minimally after one, six and 12 months. Therapeutic success was considered complete when the cause of the obstruction was completely removed or the patient was free of symptoms, and partial when the cause of the obstruction was not completely removed (e.g. residual stones of < 2 mm) or when the number of episodes of sialadenitis was reduced. The procedure was considered unsuccessful when the cause of obstruction was not removed or there was no change in the symptom-related condition of the patient. In the case of recurrent symptoms, a US evaluation was made six months after the procedure.

## **Results**

Of the 66 patients analysed, 32 (48.5%) suffered from juvenile recurrent parotitis (JRP), 25 (37.9%) from recurrent obstructive sialadenitis and nine (13.6%) from oral floor ranulas (Table I). Baseline data and detailed outcomes are summarised in Tables II-V. The minimally invasive management of paediatric obstructive sialadenitis had a complete therapeutic effect on 90.9% of the glands. No temporary or persistent untoward effect was observed. None of the patients underwent invasive pa-

**Table I.** Paediatric recurrent sialadenitis, case series (1994-2015).

| Pathology                              | Number of patients |
|--|--------------------|
| JRP                                    | 32                 |
| Oral floor ranula                      | 9                  |
| Parotid obstructive sialadenitis       | 9                  |
| Submandibular obstructive sialadenitis | 16                 |
| <b>Total</b>                           | <b>66</b>          |

**Table II.** JRP series.

|   | n         |
|---|-----------|
| <b>Number of patients</b>                                   | <b>32</b> |
| Male  | 13        |
| Female  | 19        |
| <b>Age (years)</b>  |           |
| Mean  | 7.2       |
| Median  | 6         |
| Range   | 1 to 16   |
| <b>Side</b>   |           |
| Right   | 13        |
| Left  | 9         |
| Bilateral   | 10        |
| <b>No. of recurrences/year before sialendoscopy</b>         |           |
| Mean  | 4.6       |
| Median  | 4         |
| Range   | 2 to 10   |
| <b>No. of sialendoscopies</b>                               | 42        |
| <b>Follow-up (months)</b>                                   |           |
| Mean  | 23        |
| Range   | 6 to 55   |
| <b>No. of patients with recurrences after sialendoscopy</b> | 7         |
| <b>Secondary SE procedures</b>                              | 3         |
| Medical therapies   | 4         |

rotid or submandibular sialadenectomy. The results of each group of obstructive salivary gland disorders are discussed below.

#### *Juvenile recurrent parotitis (JRP) (Table II)*

Thirty-two patients with JRP were enrolled, making JRP the main cause of recurrent sialadenitis in our series. The patients were predominantly female (59.4%) and had a mean age of 7.2 years at the time of presentation. Approximately one-third (10/32) complained of bilateral involvement and recurrent parotitis before sialendoscopy occurred up to 10 times per year (mean 4.6 times). Diagnosis of JRP was based on clinical and imaging findings. In all cases, US scans detected typical multiple hypo-echoic areas corresponding to duct dilation, and identified hyperplastic cells around the ducts. Colour Doppler US

showed reactive intraparenchymal lymph nodes and gland hyper or hypo-vascularisation depending on whether JRP was in an acute or quiescent phase.

Forty-two sialendoscopies were carried out under general anaesthesia, 10 of which were performed bilaterally during the same procedure. The secondary salivary ducts were explored in all cases, and third order branching was investigated in 40% of procedures. The most frequent endoscopic finding was a white wall appearance; main duct strictures (Koch's type I) and dilation were identified in all of the glands, and mucous plugs in 60% of the ducts. Interventional sialendoscopy involved irrigating the ductal system with saline solution and steroids.

At the time of follow-up, 25 patients were free from symptoms with no episodes of recurrence, and seven patients experienced symptom recurrence, three of whom underwent secondary sialendoscopies with positive therapeutic effects and one was cured with medical therapy.

#### *Paediatric oral floor ranula (Table III)*

Six female and three male children had simple oral floor ranulas with a mean size of 1.3 cm; the right side was most frequently involved. The minimally invasive surgi-

**Table III.** Paediatric oral floor ranulas.

|  | n        |
|--|----------|
| <b>Number of patients</b>                      | 9        |
| Male   | 3        |
| Female   | 6        |
| <b>Age (years)</b>                             |          |
| Mean   | 6.9      |
| Range  | 5 to 13  |
| <b>Side</b>                                    |          |
| Right  | 7        |
| Left   | 2        |
| Bilateral                                      | 0        |
| <b>Size (cm)</b>                               |          |
| Mean   | 1.3      |
| Range  | 0.8 to 2 |
| <b>Treatment</b>                               |          |
| Drainage                                       | 1        |
| Marsupialisation                               | 6        |
| Suture   | 2        |
| <b>Follow-up (months)</b>                      |          |
| Mean   | 11       |
| Range  | 4 to 16  |
| <b>No. of recurrences after 1st treatment</b>  | 2        |
| <b>Secondary procedures</b>                    | 2        |
| Patients still symptomatic after 2nd treatment | 1        |

cal treatments used were marsupialisation (six patients), suturing (two patients) and drainage (one patient). An immediate recurrence was observed in two of the six patients who underwent drainage followed by traditional and modified marsupialisation (2/6; 33%); there were no recurrences in patients who underwent the suturing technique. A secondary procedure was performed in recurred patients; one patient is still symptomatic.

#### *Recurrent obstructive sialadenitis (Tables IV-V)*

The 25 treated patients showed a significant prevalence of submandibular over parotid involvement (64% vs 36%). There were no substantial differences in gender or side. Mean age at the time of enrolment was 8.9 years, and the symptoms had lasted for more than six months. Sialolithiasis was the most frequent cause of obstruction (20/25, 80%) of both parotid (7/9) and submandibular glands (13/16), and the mean stone size was 4.5 mm.

ESWL was the primary treatment in 60% of cases (12/20); the stone-free rate after extracorporeal lithotripsy was 75% (9/12), and combined sialendoscopic stone removal was required in 25% of cases (3/12) because of residual symptomatic stone fragments. Thirteen interventional sialendoscopies were carried out, being the primary treatment in the case of eight duct stones and five duct stenoses. Among the patients with duct anomalies, one was a newborn infant with bilateral atresia of the papilla, which was treated by surgically incising the final tract of the submandibular duct followed by a sialendoscopic exploration of the duct system. Laser lithotripsy was performed in one eight years-old patient with a 2 mm stone located in a secondary intraparenchymal branch of the duct system. Treatment failures (i.e. persistent salivary symptoms) were observed in two patients, one with a submandibular duct stenosis and the other with a parenchymal parotid stone.

## Discussion

Twentieth century medical science has led to major advances in our knowledge of pathophysiology and the minimally invasive management of diseases. In the case of salivary gland disorders, modern approaches have proved to be effective in adults<sup>3 17-19</sup>, but there is relatively little published information concerning children<sup>7-13</sup>. We herein describe our 20-year experience of treating 66 paediatric patients with recurrent salivary obstructive disorders; to the best of our knowledge, this is the largest series of paediatric patients described in this field. All patients were treated using minimally invasive strategies, which were successful in 90.9% of cases; none of the patients required salivary gland removal. In all cases, we were able to enter the duct system using the latest generation of miniaturised sialendoscopes, and no adverse events were encountered.

In line with previous reports<sup>20</sup>, the most common cause of recurrent paediatric sialadenitis in our experience was JRP.

**Table IV.** Paediatric parotid obstructive sialadenitis

|  | n       |
|--|---------|
| <b>Number of patients</b>                      | 9       |
| Male   | 5       |
| Female   | 4       |
| <b>Age (years)</b>                             |         |
| Mean   | 9.2     |
| Range  | 5 to 13 |
| <b>Side</b>                                    |         |
| Right  | 6       |
| Left   | 3       |
| Bilateral                                      | 0       |
| <b>Pathology</b>                               |         |
| Sialolithiasis                                 | 7       |
| <i>Size of the stone (mm)</i>                  |         |
| Mean   | 4.97    |
| Range  | 2 to 7  |
| Duct stenosis                                  | 2       |
| <i>Type*</i>                                   |         |
| I  | 2       |
| II   | 0       |
| III  | 0       |
| <b>Duration of symptoms (months)</b>           |         |
| Mean   | 8.2     |
| Range  | 1 to 30 |
| <b>Primary Treatment</b>                       |         |
| ESWL   | 5       |
| Interventional sialendoscopy                   | 4       |
| <b>Results of ESWL</b>                         |         |
| No. of patients stone free after ESWL          | 3       |
| Residual fragments < 2 mm                      | 2       |
| Symptomatic                                    | 2       |
| Asymptomatic                                   | 0       |
| <b>Results of sialendoscopy</b>                |         |
| No. of patients stone free after sialendoscopy | 1       |
| Residual stones                                | 1       |
| Recurrent duct stenosis                        | 0       |
| <b>Follow-up (months)</b>                      |         |
| Mean   | 12      |
| Range  | 6 to 14 |
| <b>Further treatments</b>                      |         |
| Interventional sialendoscopy following ESWL    | 2       |
| Residual stones after 2nd sialendoscopy        | 0       |
| ESWL following failure sialendoscopy           | 1       |

\* Classification of duct stenosis according to Koch et al.<sup>14</sup>

Some studies have suggested that the pathophysiology of JRP is immune-mediated<sup>21 22</sup>, and our colour Doppler US findings of reactive lymphatic tissue in all 42 glands seem to support this hypothesis, which is further supported by the therapeutic effect of steroid injections during operative sialendoscopy<sup>21 22</sup>. In line with previous reports<sup>23-25</sup>, sialen-

**Table V.** Paediatric submandibular obstructive sialadenitis

|   | n       |
|---|---------|
| <b>Number of patients</b>                         | 16      |
| Male  | 7       |
| Female  | 9       |
| <b>Age (years)</b>                                |         |
| Mean  | 8.6     |
| Range   | 5 to 15 |
| <b>Side</b>                                       |         |
| Right   | 7       |
| Left  | 9       |
| Bilateral   | 0       |
| <b>Pathology</b>                                  |         |
| Sialolithiasis                                    | 13      |
| <i>Size of the stone (mm)</i>                     |         |
| Mean  | 4.1     |
| Range   | 1 to 7  |
| Duct stenosis                                     | 3       |
| <i>Type (*)</i>                                   |         |
| I   | 2       |
| II  | 1       |
| III   | 0       |
| <b>Duration of symptoms (months)</b>              |         |
| Mean  | 6.5     |
| Range   | 1 to 13 |
| <b>Primary Treatment</b>                          |         |
| ESWL  | 7       |
| Sialendoscopy-assisted procedures                 | 9       |
| <i>Interventional SE</i>                          | 6       |
| <i>SE Endoral procedures</i>                      | 2       |
| <i>SE Transoral procedures</i>                    | 1       |
| <b>Results of ESWL</b>                            |         |
| No. of patients stone free after ESWL             | 5       |
| <i>Residual fragments &lt; 2 mm</i>               | 2       |
| Symptomatic                                       | 1       |
| Asymptomatic                                      | 1       |
| <b>Results of sialendoscopic-assisted surgery</b> |         |
| No. of patients stone free after sialendoscopy    | 5       |
| Residual stones                                   | 0       |
| Recurrent duct stenosis                           | 1       |
| <b>Follow-up (months)</b>                         |         |
| Mean  | 11      |
| Range   | 6 to 15 |
| <b>Further treatments</b>                         |         |
| Interventional sialendoscopy following ESWL       | 1       |
| Residual stones after 2nd sialendoscopy           | 0       |
| ESWL following failure sialendoscopy              | 0       |

\* Classification of duct stenosis according to Koch et al.<sup>14</sup>

doscopy proved to be remarkably beneficial as it reduced the mean frequency of JRP attacks from 4.6 to 0.5 per year, thus giving patients a better quality of life until puberty.

Childhood sialolithiasis is quite rare, accounting for about 3-5% of all salivary stones<sup>7,26</sup>. In our 20 cases, the modern methods of ESWL and sialendoscopy alone or combined with a transoral surgical approach led to complete clinical control in 95% of patients, although the combination of two techniques (ESWL and sialendoscopy) and the repetition of a transoral removal of a parenchymal stone was necessary in four cases. Stone lithotripsy was required to treat 65% of stones (13/20): 12 patients underwent ESWL and one patient sialendoscopy-assisted laser lithotripsy. ESWL was mainly used during the first 10 years of our experience<sup>27</sup>, but the advent of sialendoscopy in 2001 allowed us to treat some patients with residual stone fragments after lithotripsy. Current technology is evolving towards intracorporeal laser or pneumatic fibre lithotripsy techniques, but only a few studies of intraductal laser and pneumatic lithotripsy have been published<sup>7,28,29</sup> and no final conclusion can be drawn, especially in the case of children.

The optimal management of oral floor ranula is still controversial<sup>30-35</sup>, and our experience reflects the evolution of various approaches. Traditional treatments include sclerotherapy, the removal of the cystic wall between the ranula and the sublingual gland, and drainage and marsupialisation of the ranula<sup>30-35</sup>. None of our patients underwent salivary gland and ranula excision but, as expected, ranula drainage was followed by immediate recurrence, and the rate of recurrence was 33% after marsupialisation; modified marsupialisation with cavity packing and the suture technique seemed to work better. The low rate of recurrence justifies the use of a minimally invasive alternative to invasive sublingual sialadenectomy in this population<sup>30-35</sup>.

## Conclusions

Paediatric obstructive salivary disorders are not common and their treatment is made challenging by a number of factors: the patients' age, the large number of causes, and the limited data available in the literature. However, recent developments in our understanding of the pathophysiological mechanisms of salivary gland disorders have positively influenced the progress of minimally invasive treatments. In our experience, a modern diagnostic and therapeutic approach using extracorporeal and intracorporeal lithotripsy, interventional sialendoscopy and sialendoscopy-assisted transoral surgery was successful in most cases, thus avoiding the need for invasive sialadenectomy. Future innovations in minimally invasive technologies will guarantee the functional preservation of the affected gland in all paediatric patients.

## References

- Jabbour N, Tibesar R, Lander T, et al. *Sialendoscopy in children*. Int J Pediatr Otorhinolaryngol 2010;74:347-50.

- <sup>2</sup> Iro H, Zenk J. *Salivary gland diseases in children*. GMS Curr Top Otorhinolaryngol Head Neck Surg 2014;1;13:Doc06.
- <sup>3</sup> Capaccio P, Torretta S, Ottaviani F, et al. *Modern management of obstructive salivary diseases*. Acta Otorhinolaryngol Ital 2007;27:161-72.
- <sup>4</sup> Kroll B, May A, Wittekindt C, et al. *Cone beam computed tomography (CBCT) sialography: an adjunct to salivary gland ultrasonography in the evaluation of recurrent salivary gland swelling*. Oral Surg Oral Med Oral Pathol Oral Radiol 2015;120:771-5.
- <sup>5</sup> Katz P. *New method of examination of the salivary glands: the fiberscope*. Inf Dent 1990;72:785-6.
- <sup>6</sup> Königsberger R, Feyh J, Goetz A, et al. *Endoscopically controlled laser lithotripsy in the treatment of sialolithiasis*. Laryngorhinootologie 1990;69:322-3.
- <sup>7</sup> Faure F, Querin S, Dulguerov P, et al. *Pediatric salivary gland obstructive swelling: sialendoscopic approach*. Laryngoscope 2007;117:1364-7.
- <sup>8</sup> Martins-Carvalho C, Plouin-Gaudon I, Quenin S, et al. *Pediatric sialendoscopy: a 5-year experience at a single institution*. Arch Otolaryngol Head Neck Surg 2010;136:33-6.
- <sup>9</sup> Haberal I, Gocmen H, Samim E. *Surgical management of pediatric ranula*. Int J Pediatr Otorhinolaryngol 2004;68:161-3.
- <sup>10</sup> Su CH, Lee KS, Hsu JH, et al. *Pediatric sialendoscopy in Asians: A preliminary report*. J Pediatr Surg 2016;51:1684-7.
- <sup>11</sup> Semensohn R, Spektor Z, Kay DJ, et al. *Pediatric sialendoscopy: initial experience in a pediatric otolaryngology group practice*. Laryngoscope 2015;125:480-4.
- <sup>12</sup> Hackett AM, Baranano CF, Reed M, et al. *Sialoendoscopy for the treatment of pediatric salivary gland disorders*. Arch Otolaryngol Head Neck Surg 2012;138:912-5.
- <sup>13</sup> Jabbour N, Tibesar R, Lander T, et al. *Sialendoscopy in children*. Int J Pediatr Otorhinolaryngol 2010;74:347-50.
- <sup>14</sup> Koch M, Iro H, Zenk J. *Sialendoscopy-based diagnosis and classification of parotid duct stenoses*. Laryngoscope 2009;119:1696-703.
- <sup>15</sup> Zhi K, Gao L, Ren W. *What is new in management of pediatric ranula?* Curr Opin Otolaryngol Head Neck Surg 2014;22:525-9.
- <sup>16</sup> Goodson AM, Payne KF, George K, et al. *Minimally invasive treatment of oral ranulae: adaption to an old technique*. Br J Oral Maxillofac Surg 2015;53:332-5.
- <sup>17</sup> Strychowsky JE, Sommer DD, Gupta MK, et al. *Sialendoscopy for the management of obstructive salivary gland disease: a systematic review and meta-analysis*. Arch Otolaryngol Head Neck Surg 2012;138:541-7.
- <sup>18</sup> Gallo A, Benazzo M, Capaccio P et al. *Sialoendoscopy: state of the art, challenges and further perspectives*. Round Table, 101<sup>st</sup> SIO National Congress, Catania 2014. Acta Otorhinolaryngol Ital 2015;35:217-33.
- <sup>19</sup> Capaccio P, Torretta S, Pignataro L. *The role of adenectomy for salivary gland obstructions in the era of sialendoscopy and lithotripsy*. Otolaryngol Clin North Am 2009;42:1161-71.
- <sup>20</sup> Francis CL, Larsen CG. *Pediatric sialadenitis*. Otolaryngol Clin North Am 2014;47:763-78.
- <sup>21</sup> Ussmuller J, Donath K. *Clinical, histopathologic and immunohistochemical studies of chronic sialectatic parotitis in childhood and adolescence*. Klin Padiatr 1999;211:165-71.
- <sup>22</sup> Shkalim V, Monselise Y, Mosseri R, et al. *Recurrent parotitis in selective IgA deficiency*. Pediatr Allergy Immunol 2004;15:281-3.
- <sup>23</sup> Canzi P, Occhini A, Pagella F, et al. *Sialendoscopy in juvenile recurrent parotitis: a review of the literature*. Acta Otorhinolaryngol Ital 2013;33:367-73.
- <sup>24</sup> Ramakrishna J, Strychowsky J, Gupta M, et al. *Sialendoscopy for the management of juvenile recurrent parotitis: a systematic review and meta-analysis*. Laryngoscope 2015;125:1472-9.
- <sup>25</sup> Capaccio P, Sigismund PE, Luca N, et al. *Modern management of juvenile recurrent parotitis*. J Laryngol Otol 2012;126:1254-60.
- <sup>26</sup> Ogden MA, Rosbe KW, Chang JL. *Pediatric sialendoscopy indications and outcomes*. Curr Opin Otolaryngol Head Neck Surg 2016;24:529-35.
- <sup>27</sup> Ottaviani F, Marchisio P, Arisi E, et al. *Extracorporeal shock-wave lithotripsy for salivary calculi in pediatric patients*. Acta Otolaryngol. 2001;121:873-6.
- <sup>28</sup> Sionis S, Caria RA, Trucas M, et al. *Sialoendoscopy with and without holmium: YAG laser-assisted lithotripsy in the management of obstructive sialadenitis of major salivary glands*. Br J Oral Maxillofac Surg 2014;52:58-62.
- <sup>29</sup> Koch M, Mantsopoulos K, Schapher M, et al. *Intraductal pneumatic lithotripsy for salivary stones with the StoneBreaker: preliminary experience*. Laryngoscope 2016;126:1545-50.
- <sup>30</sup> Harrison JD. *Modern management and pathophysiology of ranula: literature review*. Head Neck 2010;32:1310-20.
- <sup>31</sup> Patel MR, Deal AM, Shockley WW. *Oral and plunging ranulas: What is the most effective treatment?* Laryngoscope 2009;119:1501-9.
- <sup>32</sup> Sandrini FA, Sant'ana-Filho M, Rados PV. *Ranula management: suggested modifications in the micro-marsupialization technique*. J Oral Maxillofac Surg 2007;65:1436-8.
- <sup>33</sup> Mortellaro C, Dall'Oca S, Lucchina AG, et al. *Sublingual ranula: a closer look to its surgical management*. J Craniofac Surg 2008;19:286-90.
- <sup>34</sup> Hills A, Holden A, McGurk M. *Evolution of the management of ranulas: change in a single surgeon's practice 2001-14*. Br J Oral Maxillofac Surg 2016;54:992-96.
- <sup>35</sup> Sigismund PE, Bozzato A, Schumann M, et al. *Management of ranula: 9 years' clinical experience in pediatric and adult patients*. J Oral Maxillofac Surg 2013;71:538-44.

Received: September 15, 2016 - Accepted: December 12, 2016

Address for correspondence: Pietro Canzi, Department of Otorhinolaryngology, IRCCS Policlinico San Matteo Foundation and University of Pavia, viale Camillo Golgi, 19, 27100, Pavia, Italy. Fax +39 0382528184. E-mail: pietro.canzi@unipv.it



# Botulinum toxin therapy: functional silencing of salivary disorders

## *Terapia con tossina botulinica: silenziamento funzionale dei disordini salivari*

A. LOVATO<sup>1</sup>, D.A. RESTIVO<sup>2</sup>, G. OTTAVIANO<sup>3</sup>, G. MARIONI<sup>3</sup>, R. MARCHESE-RAGONA<sup>3</sup>

<sup>1</sup> Department of Neuroscience DNS, University of Padova, Audiology Unit at Treviso Hospital, Treviso, Italy;

<sup>2</sup> Department of Internal Medicine, Neurologic Unit, Nuovo "Garibaldi" Hospital, Catania, Italy; <sup>3</sup> Otolaryngology Section, Department of Neuroscience DNS, University of Padova, Italy

### SUMMARY

Botulinum toxin (BTX) is a neurotoxic protein produced by *Clostridium botulinum*, an anaerobic bacterium. BTX therapy is a safe and effective treatment when used for functional silencing of the salivary glands in disorders such as sialoceles and salivary fistulae that may have a post-traumatic or post-operative origin. BTX injections can be considered in sialoceles and salivary fistulae after the failure of or together with conservative treatments (e.g. antibiotics, pressure dressings, or serial aspirations). BTX treatment has a promising role in chronic sialadenitis. BTX therapy is highly successful in the treatment of gustatory sweating (Frey's syndrome), and could be considered the gold standard treatment for this neurological disorder.

KEY WORDS: Botulinum toxin • Sialocele • Salivary fistula • Chronic sialadenitis • Frey's syndrome

### RIASSUNTO

*La tossina botulinica è una neurotossina prodotta dal batterio anaerobio Clostridium botulinum. L'iniezione di tossina botulinica è un trattamento sicuro ed efficace quando viene usata per inibire la funzione delle ghiandole salivari in patologie come gli sialoceli o le fistole salivari di origine post-traumatica o iatrogena. Negli sialoceli e fistole salivari, il trattamento con tossina botulinica può essere preso in considerazione anche dopo il fallimento o in aggiunta ai trattamenti conservativi non chirurgici. La terapia con tossina botulinica si sta dimostrando promettente anche nel trattamento della scialoadenite cronica. La tossina botulinica ha un elevato tasso di risoluzione nella Sindrome di Frey ed è considerata il gold standard nel trattamento di questo disturbo neurologico.*

PAROLE CHIAVE: Tossina botulinica • Sialocele • Fistola salivare • Scialoadenite cronica • Sindrome di Frey

Acta Otorhinolaryngol Ital 2017;37:168-171

## Introduction

Botulinum toxin (BTX) is produced by *Clostridium botulinum*, an anaerobic bacterium. The bacterium produces seven serological types of toxins (A, B, C1, D, E, F and G) as a complex mixture of neurotoxic polypeptides and nontoxic protein components<sup>1</sup>. BTX type A (BTX-A) and B (BTX-B) are commercialised and available for medical use<sup>2</sup>.

The application by injection of BTX on salivary glands was first proposed in 1997 as treatment for sialorrhoea<sup>3</sup>, and in 1999 we proposed BTX injection in parotid sialoceles<sup>4</sup>. The toxin is able to depress secretory activity of the salivary glands reducing saliva production. At neuromuscular junctions, BTX inhibits presynaptic acetylcholine release by interfering with the neuroexocytosis process, and causes flaccid muscle paralysis<sup>5</sup>. With the same mechanism, BTX on salivary glands acts on the cholinergic nerve terminals (parasympathetic nerve terminals), and produces a local chemical blocking and loss of neuronal activity<sup>3</sup>.

The localised cholinergic block achieved by BTX injection inhibits salivary flow and allows healing of salivary disorders. BTX therapy has been effectively used in various salivary disorders, such as salivary fistulae after sialadenectomy<sup>6,7</sup>, post-traumatic and iatrogenic salivary sialoceles<sup>8-10</sup> and chronic sialadenitis<sup>11</sup>. BTX has also been successfully used to treat auriculo-temporal (or Frey's) syndrome<sup>12,13</sup>, as it reduced the skin area affected by gustatory sweating by inhibiting the sweat glands abnormally re-innervated after parotidectomy by the cholinergic pathway<sup>14</sup>.

In the present paper, we critically review the current indications and treatment modalities for BTX therapy in salivary gland disorders (and in Frey's syndrome).

## Salivary fistula and sialoceles

Parotid fistula is a chronic wound of the gland or its duct through which saliva is discharged<sup>15</sup>. Sialoceles are a collection or retention of saliva in the gland soft tissue.

Salivary fistulae and sialoceles may occur after penetrating injuries of the salivary glands (in peacetime practice mainly due to shattered glass in road accidents), or as a complication of partial parotidectomy<sup>16</sup>. Parotid fistula has also been reported after rhytidectomy, mastoidectomy, dental extraction, temporomandibular joint surgery and mandibular osteotomy<sup>7</sup>; submandibular sialocele can be due to sialoadenectomy<sup>9</sup>. According to our experience with post-operative parotid fistula<sup>7</sup>, after an initial (4 to 8 postoperative days) swelling beneath the wound in the area overlying the parotid, an efflux of clear fluid from the wound occurs. The flow through the fistula increases during meals, particularly during mastication. In dubious cases, analysis of the fluid can confirm parotid secretion because of its high amylase content<sup>7</sup>.

Sialocele and salivary fistula, especially when post-traumatic, can be managed by conservative non-operative treatment that includes antibiotics, pressure dressings and serial aspirations<sup>17</sup>. With conventional management techniques, it is very difficult to abolish salivary flow and resolving these salivary disorders may take time, involving a lengthy hospital stay and considerable discomfort. Wax and Tarshis<sup>15</sup> successfully treated 14 cases of post-parotidectomy fistula with pressure dressing; 9 cases healed after 2 to 9 days, whereas the others needed 10 to 36 days of treatment (average period 21 days). Systemic anticholinergic drugs (which may temporarily lead to a reduction in salivary secretion) may be associated, but they often cause distressing side effects<sup>18</sup>, including dryness of the mouth, blurred vision, urine retention, photophobia, tachycardia, palpitation and anhidrosis with heat intolerance<sup>19</sup>. In the treatment of parotid fistulae, the several therapies that have been described (i.e. pressure dressing, systemic anticholinergic drugs, suction drain insertion, tympanic neurectomy with or without chorda tympani section, surgery and use of 2-octyl cyanoacrylate in persistent cases) frequently show disappointing outcomes<sup>20,21</sup>. Considering parotidectomy completion, post-operative fibrosis makes it difficult to dissect the tissue plane with frequent permanent facial paralysis<sup>22</sup>.

In order to avoid surgical management, BTX therapy could be used to obtain a temporary functional silencing of the salivary glands and to allow sialocele and fistula healing<sup>11</sup>. Lim and Choi<sup>23</sup> successfully treated a parotid salivary fistula with one BTX injection as the only primary therapy without pressure dressing. BTX treatment has proven successful for the treatment of salivary fistula and sialocele, either post-traumatic or post-operative<sup>6-11 16 17 19 23-25</sup>. Capaccio et al.<sup>24</sup> reported the treatment by BTX of 3 patients with salivary fistula and 5 with sialocele: complete clinical recovery was observed in all but one patients. Furthermore, the authors focused on the need for a combination of traditional percutaneous aspiration of extravasated fluid and BTX injection to avoid invasive sialadenectomy<sup>24</sup>, as also proposed by

other authors<sup>16</sup>. Laskawi and colleagues<sup>25</sup> reviewed their experience with BTX treatment in 12 post-parotidectomy salivary fistulae; they reported 90% of successful fistula closures if early treatment (within 6 weeks after development of the fistula) was performed. Considering the results of our clinical experience with post-operative fistula (16 cases to date), we suggested early BTX treatment to avoid the epithelial coating of the fistulous tract<sup>7</sup>.

### Chronic sialadenitis

BTX was used for the first time for the treatment of 2 cases of chronic sialadenitis by Ellies et al.<sup>11</sup>. They suggested that a temporary silencing of the gland might promote the regeneration of the gland tissue, avoiding gland excision, which is often necessary in recurrent chronic sialadenitis<sup>11</sup>. Treatment with BTX in chronic sialadenitis due to Stensen's duct strictures was effective in reduction of recurrent parotitis<sup>24</sup> and gland swelling<sup>26</sup>. Traditional treatment options for parotid duct strictures included conservative methods, such as antibiotics, analgesics, or self-massage of the gland<sup>27</sup>. As second-line therapy, minimally invasive sialendoscopic dilation of the duct has to be considered<sup>26</sup>, using BTX therapy only in persistent cases after sialendoscopy. Recently, BTX was also used in two cases of Sjögren's syndrome-associated recurrent parotitis with good outcomes<sup>28,29</sup>. For these salivary gland disorders, it appears that BTX injections at regular intervals are needed (every 3-4 months), as temporary silencing of the glands would not be sufficient<sup>29</sup>.

### Frey's syndrome

A quite frequent and well-described complication of parotidectomy is gustatory sweating or Frey's syndrome. The pathogenesis is based on the aberrant regeneration of sectioned parasympathetic secretomotor fibres of the auriculo-temporal nerve with inappropriate innervation of the cutaneous facial sweat glands that are normally innervated by sympathetic cholinergic fibres<sup>30</sup>. As a consequence, Frey's syndrome is a disorder characterised by unilateral sweating and flushing of the facial skin in the area of the parotid gland occurring during meals that usually becomes evident 1-12 months after surgery<sup>30</sup>. According to a survey of post-parotidectomy patients, the incidence of Frey's syndrome was 23%, while it was observed in 62% of cases using Minor's starch-iodine test<sup>31</sup>. The Minor test is usually used to identify and mark the margins of the area involved by gustatory sweating. Systemic or topical application of various anticholinergic agents (scopolamine, glycopyrrolate, diphemnanil-methylsulfate) and surgical treatment (including cervical sympathectomy, tympanic neurectomy, sternocleidomastoid transfer and dermis-fat grafts and the use of various materials, as interpositional barriers) have been proven

unsuccessful for Frey's syndrome<sup>32</sup>. On the contrary, good results have been obtained by local injection of BTX, as the neurotoxin inhibits pre-synaptic acetylcholine release, reducing eccrine glands secretions and sweating<sup>32</sup>. The gustatory sweating usually ceased in the treated area within 48-72 hours after the first BTX injection.

Treatment with BTX in Frey's syndrome reduces hyperhidrosis and facial gustatory flushing, as described by Tugnoli et colleagues<sup>33</sup>. A recent systematic meta-analysis by Xie et al.<sup>34</sup> on the effectiveness of BTX-A therapy for Frey's syndrome reported an effective rate of more than 98%<sup>34</sup>. In 2001, Tugnoli et al. described the treatment of Frey's syndrome with BTX type F (BTX-F) in a patient with immuno-resistance to BTX-A<sup>35</sup>. BTX was also effective in diabetic autonomic gustatory sweating; in 2002 Restivo et al. treated with success 14 diabetic subjects with gustatory sweating<sup>36</sup>. We can currently state that BTX injections is the gold standard treatment for Frey's syndrome.

## Discussion

BTX has proven to be efficient in the treatment of salivary disorders such as sialoceles<sup>24</sup> and salivary fistula<sup>25</sup>. Furthermore, BTX may have an emergent role in the treatment of chronic sialadenitis<sup>29</sup>. BTX injections are effective in most of the patients with Frey's syndrome<sup>34</sup>. The majority of authors used BTX-A for salivary gland disorders<sup>24 25 37</sup> and gustatory sweating<sup>31</sup>, even if the use of BTX-B<sup>16</sup> and BTX-F<sup>35</sup> has been described in salivary gland disease.

The dose of BTX-A injected in the parotid gland, to treat sialoceles and salivary fistulae, varied in different studies from 10 to 60 mouse units (MU)<sup>7 11 24</sup>. Capaccio et al.<sup>24</sup> used 25 to 60 MU per treatment fractionated into 4 doses as the parotid was divided into anterior, posterior, upper, and lower quadrants. In their case series, the authors treated drooling, salivary fistulae, sialoceles and recurrent parotitis, without giving precise indications regarding the doses used in the different entities<sup>24</sup>. Treating post-parotidectomy salivary fistulae, we had complete healing of all the fistulae using a single lower dose (10 to 20 MU) fractionated in 3 doses (two for the superior and one for the inferior lobe)<sup>7</sup>. For post-parotidectomy fistulae, Laskawi et al.<sup>25</sup> reported a total dose of BTX-A between 10 and 40 U, depending on the size of the remaining glandular compartment. The injections were performed into the gland at two to three sites; three patients got two injections because of persistent leakage of saliva after the first injection<sup>25</sup>. In Frey's syndrome, the area identified by the Minor test is divided into 1 or 1.5 cm squares, and 2 MU of BTX-A are injected, subcutaneously, into each square to achieve a diffuse, homogeneous effect<sup>24 32</sup>.

In cases of parotid salivary fistulae, we injected BTX under electromyographic (EMG) control on an ambulatory

basis with little discomfort. We used a tuberculin syringe with a 27-gauge monopolar Teflon-coated hollow EMG recording needle connected to an EMG recorder for the injection. To prevent the masseter and pterygoideus muscles from improperly weakening with the needle in place, patients were instructed to open and close their mouths, and the EMG signals were observed<sup>7 38</sup>. Other authors used ultrasonographic-assisted intraparenchymal infiltration<sup>11 24 25</sup>. Both techniques were effective and with few reported mild complications, such as transitory paresis of the lower branch of the facial nerve<sup>11</sup> and change of saliva thickness<sup>38</sup>. Injections for Frey's syndrome should also be considered safe as only transient paresis of the orbicularis oris, in very few cases, has been reported<sup>32</sup>.

In view of the effectiveness and the absence of significant side effects in treatment of parotid fistula and sialoceles, BTX therapy may be indicated as a precautionary treatment both in partial parotidectomies and in the management of deep facial wounds that affect the parotid gland<sup>7</sup>. Recently, to avoid the onset of salivary complications, the use of BTX has been proposed after facial transplantation<sup>39</sup>.

## Conclusions

BTX injection is a safe and effective treatment when used for functional silencing of the salivary glands in disorders such as sialoceles and salivary fistulae, and also shows a promising role in chronic sialadenitis therapy. BTX therapy is highly successful in the treatment of gustatory sweating (Frey's syndrome), and could be considered the gold standard treatment for this post-parotidectomy complication.

## References

- 1 Tsui JK. *Botulinum toxin as a therapeutic agent*. Pharmacol Ther 1996;72:13-24.
- 2 Oliveira JB, Evêncio-Neto J, Baratella-Evêncio L. *Histological and immunohistochemical findings of the action of botulinum toxin in salivary gland: systematic review*. Braz J Biol 2016. [Epub ahead of print]
- 3 Bushara KO. *Sialorrhea in amyotrophic lateral sclerosis: a hypothesis of a new treatment - botulinum toxin A injections of the parotid glands*. Med Hypotheses 1997;48:337-9.
- 4 Marchese-Ragona R, Blotta P, Pastore A, et al. *Management of parotid sialocele with botulinum toxin*. Laryngoscope 1999;109:1344-6.
- 5 Sollner T, Bennett MK, Whiteheart S, et al. *A protein assembly-disassembly pathway in vitro that may correspond to sequential steps of synaptic vesicle docking, activation, and fusion*. Cell 1993;75:409-18.
- 6 Marchese-Ragona R, Galzignato PF, Marioni G, et al. *Endoscopic diagnosis of rhino-parotid fistula and successful treatment with botulinum toxin*. Laryngoscope 2005;115:2062-4.
- 7 Marchese-Ragona R, Marioni G, Restivo AD, et al. *The role of botulinum toxin in postparotidectomy fistula treatment. A technical note*. Am J Otolaryngol 2006;27:221-4.

- <sup>8</sup> Capaccio P, Paglia M, Minorati D, et al. *Diagnosis and therapeutic management of iatrogenic parotid sialocele*. Ann Otol Rhinol Laryngol 2004;113:562-4.
- <sup>9</sup> Capaccio P, Cuccarini V, Benicchio V, et al. *Treatment of iatrogenic submandibular sialocele with botulinum toxin. Case report*. Br J Oral Maxillofac Surg 2007;45:415-7.
- <sup>10</sup> Arnaud S, Batifor D, Goudot P, et al. *Nonsurgical management of traumatic injuries of the parotid gland and duct using type A botulinum toxin*. Plast Reconstr Surg 2006;117:2426-30.
- <sup>11</sup> Ellies M, Gottstein U, Rohrbach-Volland S, et al. *Reduction of salivary flow with botulinum toxin: extended report on 33 patients with drooling, salivary fistulas, and sialadenitis*. Laryngoscope 2004;114:1856-60.
- <sup>12</sup> Laskawi R, Drobik C, Schonebeck C. *Up-to-date report of botulinum toxin type A treatment in patients with gustatory sweating (Frey's syndrome)*. Laryngoscope 1998;108:381-4.
- <sup>13</sup> Restivo DA, Lanza S, Patti F, et al. *Improvement of diabetic autonomic gustatory sweating by botulinum toxin type A*. Neurology 2002;59:1971-3.
- <sup>14</sup> Drummond P. *Mechanism of gustatory flushing in Frey's syndrome*. Clin Auton Res 2002;12:144-6.
- <sup>15</sup> Wax M, Tarshis L. *Post-parotidectomy fistula*. J Otolaryngol 1991;20:10-3.
- <sup>16</sup> Pantel M, Volk GF, Guntinas-Lichius O, Wittekindt C. *Botulinum toxin type b for the treatment of a sialocele after parotidectomy*. Head Neck 2013;35:E11-2.
- <sup>17</sup> Gordin EA, Daniero JJ, Krein H, et al. *Parotid gland trauma*. Facial Plast Surg 2010;26:504-10.
- <sup>18</sup> Spinell C, Ricci E, Berti P, et al. *Postoperative salivary fistula: therapeutic action of octreotide*. Surgery 1995;117:117-8.
- <sup>19</sup> Landau R, Stewart M. *Conservative management of post-traumatic parotid fistulae and sialoceles: a prospective study*. Br J Surg 1985;72:42-4.
- <sup>20</sup> Mandour MA, El-Sheikh MM, El-Garem F. *Tympanic neurectomy for parotid fistula*. Arch Otolaryngol 1976;102:327-9.
- <sup>21</sup> Schindel J, Markowicz H, Levie B. *Combined surgical-radiological treatment of parotid gland fistulae*. J Laryngol Otol 1968;82:867-70.
- <sup>22</sup> Ananthakrishnan N, Parkash S. *Parotid fistulas: a review*. Br J Surg 1982;69:641-3.
- <sup>23</sup> Lim YC, Choi EC. *Treatment of an acute salivary fistula after parotid surgery: botulinum toxin type A injection as primary treatment*. Eur Arch Otorhinolaryngol 2008;265:243-5.
- <sup>24</sup> Capaccio P, Torretta S, Osio M, et al. *Botulinum toxin therapy: a tempting tool in the management of salivary secretory disorders*. Am J Otolaryngol 2008;29:333-8.
- <sup>25</sup> Laskawi R, Winterhoff J, Köhler S, et al. *Botulinum toxin treatment of salivary fistulas following parotidectomy: follow-up results*. Oral Maxillofac Surg 2013;17:281-5.
- <sup>26</sup> Kruegel J, Winterhoff J, Koehler S, et al. *Botulinum toxin: A noninvasive option for the symptomatic treatment of salivary gland stenosis - a case report*. Head Neck 2010;32:959-63.
- <sup>27</sup> Nahlieli O, Bar T, Shacham R, et al. *Management of chronic recurrent parotitis: current therapy*. J Oral Maxillofac Surg 2004;62:1150-5.
- <sup>28</sup> Daniel SJ, Diamond M. *Botulinum toxin injection: a novel treatment for recurrent cystic parotitis Sjögren syndrome*. Otolaryngol Head Neck Surg 2011;145:180-1.
- <sup>29</sup> O'Neil LM, Palme CE, Riffat F, et al. *Botulinum toxin for the management of Sjögren syndrome-associated recurrent parotitis*. J Oral Maxillofac Surg 2016; 74:2428-2430.
- <sup>30</sup> Singh N, Kohli M, Kohli H. *Innovative technique to reduce incidence of Frey's syndrome after parotid surgery*. Am Surg 2011;77:351-4.
- <sup>31</sup> Neumann A, Rosenberger D, Vorsprach O, et al. *The incidence of Frey syndrome following parotidectomy: results of a survey and follow-up*. HNO 2011;59:173-8.
- <sup>32</sup> Marchese-Ragona R, De Filippis C, Marioni G, et al. *Treatment of complications of parotid gland surgery*. Acta Otorhinolaryngol Ital 2005;25:174-8.
- <sup>33</sup> Tugnoli V, Marchese Ragona R, Eleopra R, et al. *The role of gustatory flushing in Frey's syndrome and its treatment with botulinum toxin type A*. Clin Auton Res 2002;12:174-8.
- <sup>34</sup> Xie S, Wang K, Xu T, et al. *Efficacy and safety of botulinum toxin type A for treatment of Frey's syndrome: evidence from 22 published articles*. Cancer Med 2015;4:1639-50.
- <sup>35</sup> Tugnoli V, Marchese Ragona R, Eleopra R, et al. *Treatment of Frey syndrome with botulinum toxin type F*. Arch Otolaryngol Head Neck Surg 2001;127:339-40.
- <sup>36</sup> Restivo DA, Lanza S, Patti F, et al. *Improvement of diabetic autonomic gustatory sweating by botulinum toxin type A*. Neurology 2002;59:1971-3.
- <sup>37</sup> Staffieri A, Marchese Ragona R, de Filippis C, et al. *Management of parotid fistulae and sialoceles with botulinum toxin*. Otolaryngol Head Neck Surg 1999;121:P240-1.
- <sup>38</sup> Marchese Ragona R, de Filippis C, Staffieri A, et al. *Parotid fistula: treatment with botulinum toxin*. Plastic Reconst Surg 2001;107:886-7.
- <sup>39</sup> Frautschi R, Rampazzo A, Bernard S, et al. *Management of the salivary glands and facial nerve in face transplantation*. Plast Reconstr Surg 2016;137:1887-97.

Received: September 15, 2016 - Accepted: December 12, 2016

Address for correspondence: Rosario Marchese Ragona, Otolaryngology Section, Department of Neuroscience DNS, University of Padova, via Giustiniani 2, 35128 Padova, Italy. Tel. +39 049 8211993. Fax +39 049 8211994. E-mail: rosario.marcheseragona@unipd.it