

ACTA

Otorhinolaryngologica Italica

*Official Journal of the Italian Society of Otorhinolaryngology
Head and Neck Surgery*

Organo Ufficiale della Società Italiana di Otorinolaringologia
e Chirurgia Cervico-Facciale

Volume 36

5

October 2016

Review

Childhood neurofibromatosis type 2 (NF2) and related disorders:
from bench to bedside and biologically targeted therapies

Head and neck

Lipofilling as refinement procedure in maxillo-mandibular malformations

Salvage total laryngectomy after conservation laryngeal surgery for recurrent
laryngeal squamous cell carcinoma

Paediatric otorhinolaryngology

Advanced oxidation protein product levels as a marker of oxidative stress
in paediatric patients with chronic tonsillitis

Oral pathology

Association between oral habits, mouth breathing and malocclusion

Phoniatory

Comparison between videofluoroscopy, fiberoptic endoscopy and scintigraphy
for diagnosis of oro-pharyngeal dysphagia

Laryngology

Open partial horizontal laryngectomies: is it time to adopt a modular form
of consent for the intervention?

Otology

Surgical treatment of sporadic vestibular schwannoma
in a series of 1006 patients

Audiology

Severe to profound deafness may be associated with MYH9-related disease:
report of 4 patients

Vestibology

A connection between neurovascular conflicts within the cerebellopontine angle
and vestibular neuritis, a case controlled cohort study

Case series and reports

Cochlear implantation in delayed sudden hearing loss after conservative
vestibular schwannoma surgery

Anterior laryngofissure approach in type III laryngotracheal cleft: a case report

PACINI
EDITORE
MEDICINA

www.actaitalica.it



ACTA

Otorhinolaryngologica Italica

Official Journal of the Italian Society of Otorhinolaryngology - Head and Neck Surgery
Organo Ufficiale della Società Italiana di Otorinolaringologia e Chirurgia Cervico-Facciale

Former Editors-in-Chief: C. Calearo[†], E. de Campora, A. Staffieri, M. Piemonte, F. Chiesa

Editorial Board

Editor-in-Chief:

G. Paludetti

President of S.I.O.:

C.A. Leone

Former Presidents of S.I.O.

and Editors-in-Chief:

I. De Vincentiis, D. Felisati, L. Coppo,

G. Zaoli, P. Miani, G. Motta,

L. Marcucci, A. Ottaviani,

P. Puxeddu, M. Maurizi, G. Sperati,

D. Passali, E. de Campora, A. Sartoris,

P. Laudadio, M. De Benedetto,

S. Conticello, D. Casolino,

A. Rinaldi Ceroni, M. Piemonte,

A. Staffieri, F. Chiesa, R. Fiorella,

A. Camaioni, A. Serra, G. Spriano,

R. Filippo

Editorial Staff

Editor-in-Chief:

G. Paludetti

Deputy Editor:

J. Galli

Associate Editors:

G. Almadori, F. Ottaviani

Editorial Coordinator:

E. De Corso

Editorial Assistant:

P. Moore

Treasurer:

L. de Campora

Italian Scientific Board

L. Bellussi, G. Danesi, C. Grandi,

A. Martini, L. Pignataro, F. Raso,

R. Speciale, I. Tasca

International Scientific Board

J. Betka, P. Clement, M. Halmagyi,

L.P. Kowalski, M. Pais Clemente,

J. Shah, H. Stammberger, R. Laszig,

G. O'Donoghue, R.J. Salvi, R. Leemans,

M. Remacle, F. Marshal, H.P. Zenner,

B. Scola Yurrita, R.W. Gilbert

Editorial Office

Editor-in-Chief:

G. Paludetti

Department of Head and Neck Surgery -

Otorhinolaryngology

Catholic University of the Sacred Heart

"A. Gemelli" Hospital

L.go F. Vito, 1 - 00168 Rome, Italy

Tel. +39 06 30154439

Fax + 39 06 3051194

actaitalicaorl@rm.unicatt.it

Editorial Coordinator:

E. De Corso

eugenio.decorso@policlinicogemelli.it

Editorial Secretariat:

G. Di Cintio

dicintiojohn@gmail.com

Argomenti di Acta

Otorhinolaryngologica Italica

Editor-in-Chief: G. Paludetti

Editorial Coordinator: M.R. Marchese

raffaellamarchese@gmail.com

© Copyright 2016 by

Società Italiana di Otorinolaringologia

e Chirurgia Cervico-Facciale

Via Luigi Pigorini, 6/3

00162 Rome, Italy

Publisher

Pacini Editore Srl

Via Gherardesca, 1

56121 Pisa, Italy

Tel. +39 050 313011

Fax +39 050 3130300

info@pacinieditore.it

www.pacinimedica.it

Acta Otorhinolaryngologica Italica is cited

in Index Medicus, MEDLINE, PubMed

Central, Science Citation Index Expanded,

Scopus, DOAJ, Open-J Gate, Free Medical

Journals, Index Copernicus, Socolar

Journal Citation Reports:

Impact Factor 1.531

Acta Otorhinolaryngologica Italica is

available on Google Scholar



Contents

Review

- Childhood neurofibromatosis type 2 (NF2) and related disorders: from bench to bedside and biologically targeted therapies
Neurofibromatosi tipo 2 (NF2) e sindromi correlate in età infantile: dalla biologia molecolare alla pratica clinica e nuove terapie con farmaci biologici
M. Ruggieri, A.D. Praticò, A. Serra, L. Maiolino, S. Cocuzza, P. Di Mauro, L. Licciardello, P. Milone, G. Privitera, G. Belfiore, M. Di Pietro, F. Di Raimondo, A. Romano, A. Chiarenza, M. Muglia, A. Polizzi, D.G. Evans. pag. 345

Head and neck

- Lipofilling as refinement procedure in maxillo-mandibular malformations
Il lipofilling come procedura ancillare nelle malformazioni maxillo-mandibolari
D. Cervelli, G. Gasparini, A. Moro, S. Pelo, E. Foresta, F. Grussu, G. D'Amato, P. De Angelis, G. Saponaro » 368

- Salvage total laryngectomy after conservation laryngeal surgery for recurrent laryngeal squamous cell carcinoma
Laringectomia totale di salvataggio nel trattamento delle recidive di carcinoma squamocellulare laringeo dopo terapia chirurgica conservativa
A. De Virgilio, A. Greco, F. Bussu, A. Gallo, D. Rosati, S.-H. Kim, C.-C. Wang, M. Conte, G. Pagliuca, M. De Vincentiis. » 373

Paediatric otorhinolaryngology

- Advanced oxidation protein product levels as a marker of oxidative stress in paediatric patients with chronic tonsillitis
Ruolo dei prodotti avanzati di ossidazione proteica come marker di stress ossidativo nei pazienti pediatrici affetti da tonsillite cronica
I. Ozbay, C. Kucur, F.E. Koçak, B. Savran, F. Oghan. » 381

Oral pathology

- Association between oral habits, mouth breathing and malocclusion
Associazione fra abitudini viziate, respirazione orale e malocclusione
C. Grippaudo, E.G. Paolantonio, G. Antonini, R. Saulle, G. La Torre, R. Deli » 386

Phoniatry

- Comparison between videofluoroscopy, fiberoptic endoscopy and scintigraphy for diagnosis of oro-pharyngeal dysphagia
Confronto tra videofluoroscopia, endoscopia a fibre ottiche e scintigrafia per la diagnosi di disfagia oro-faringea
B. Fattori, P. Giusti, V. Mancini, M. Grosso, M.R. Barillari, L. Bastiani, S. Molinaro, A. Nacci » 395

Laryngology

- Open partial horizontal laryngectomies: is it time to adopt a modular form of consent for the intervention?
Laringectomie parziali orizzontali: è tempo di adottare un form modulare di consenso all'intervento?
L. Giordano, D. Di Santo, E. Crosetti, A. Bertolin, G. Rizzotto, G. Succo, M. Bussi » 403

Otology

- Surgical treatment of sporadic vestibular schwannoma in a series of 1006 patients
Trattamento chirurgico degli schwannomi vestibolari: risultati su una serie di 1006 pazienti
Z. Zhang, Y. Nguyen, D. De Seta, F.Y. Russo, A. Rey, M. Kalamarides, O. Sterkers, D. Bernardeschi » 408

Audiology

- Severe to profound deafness may be associated with MYH9-related disease: report of 4 patients
La sordità da severa a profonda può essere associata alla malattia MYH9-correlata: report di 4 pazienti
P. Canzi, A. Pecci, M. Manfrin, E. Rebecchi, C. Zaninetti, V. Bozzi, M. Benazzo » 415

Vestibology

- A connection between neurovascular conflicts within the cerebellopontine angle and vestibular neuritis, a case controlled cohort study
Relazione fra conflitti neurovascolari a livello dell'angolo pontocerebellare e neurite vestibolare, uno studio di coorte caso-controllo
B. Loader, I. Linauer, S. Korkesch, I. Krammer-Effenberger, V. Zielinski, N. Schibany, A. Kaider, E. Vyskocil, D. Tscholakoff, P. Franz » 421

Case series and reports

- Cochlear implantation in delayed sudden hearing loss after conservative vestibular schwannoma surgery
Impianto cocleare in ipoacusia improvvisa ritardata dopo chirurgia conservativa per neurinoma dell'acustico
F. Dagna, A. Murri, R. Albera, D. Cuda » 428

- Anterior laryngofissure approach in type III laryngotracheal cleft: a case report
Laringofissura anteriore nel cleft laringotracheale di tipo III: caso clinico
A.E. Arslankoylu, M. Unal, N. Kuyucu, O. Ismi » 431

- Calendar of events - Italian and International Meetings and Courses » 435**

REVIEW

Childhood neurofibromatosis type 2 (NF2) and related disorders: from bench to bedside and biologically targeted therapies

Neurofibromatosi tipo 2 (NF2) e sindromi correlate in età infantile: dalla biologia molecolare alla pratica clinica e nuove terapie con farmaci biologici

M. RUGGIERI¹, A.D. PRATICÒ^{1,2}, A. SERRA³, L. MAIOLINO³, S. COCUZZA³, P. DI MAURO³, L. LICCIARDELLO³, P. MILONE⁴, G. PRIVITERA⁴, G. BELFIORE⁵, M. DI PIETRO⁶, F. DI RAIMONDO⁷, A. ROMANO⁷, A. CHIARENZA⁷, M. MUGLIA⁸, A. POLIZZI^{9,10}, D.G. EVANS¹¹

¹ Unit of Rare Diseases of the Nervous System in Childhood, Department of Clinical and Experimental Medicine, Section of Pediatrics and Child Neuropsychiatry, University of Catania, Italy; ² Department of Biomedical and Biotechnological Sciences, University of Catania, Italy; ³ Department of Medical and Surgical Sciences and Advanced Technologies "G. Ingrassia", Institute of Otorhinolaryngology, University of Catania, Italy; ⁴ Department of Medical and Surgical Sciences and Advanced Technologies "G. Ingrassia", Institute of Radiology, University of Catania, Italy; ⁵ Unit of Paediatric Radiology, AOU "Policlinico-Vittorio Emanuele", Catania, Italy; ⁶ Department of Medical and Surgical Sciences and Advanced Technologies "G. Ingrassia", Institute of Ophthalmology, University of Catania, Italy; ⁷ Division of Hematology, AOU "Policlinico-Vittorio Emanuele", University of Catania, Italy; ⁸ Unit of Genetics, Institute of Neurological Sciences, National Research Council, Piano Lago di Mangone, Italy; ⁹ National Centre for Rare Disease, Istituto Superiore di Sanità, Rome, Italy; ¹⁰ Institute of Neurological Sciences, National Research Council, Catania, Italy; ¹¹ Genomic Medicine, University of Manchester, Manchester Academic Health Science Centre, Institute of Human Development, Central Manchester NHS Foundation Trust, Manchester Royal Infirmary, Manchester, UK

SUMMARY

Neurofibromatosis type 2 [NF2; MIM # 101000] is an autosomal dominant disorder characterised by the occurrence of vestibular schwannomas (VSs), schwannomas of other cranial, spinal and cutaneous nerves, cranial and spinal meningiomas and/or other central nervous system (CNS) tumours (e.g., ependymomas, astrocytomas). Additional features include early onset cataracts, optic nerve sheath meningiomas, retinal hamartomas, dermal schwannomas (i.e., NF2-plaques), and (few) café-au-lait spots. Clinically, NF2 children fall into two main groups: (1) congenital NF2 - with bilateral VSs detected as early as the first days to months of life, which can be stable/asymptomatic for one-two decades and suddenly progress; and (2) severe pre-pubertal (Wishart type) NF2- with multiple (and rapidly progressive) CNS tumours other-than-VS, which usually present first, years before VSs [vs. the classical adult (Gardner type) NF2, with bilateral VSs presenting in young adulthood, sometimes as the only disease feature]. Some individuals can develop unilateral VS associated with ipsilateral meningiomas or multiple schwannomas localised to one part of the peripheral nervous system [i.e., mosaic NF2] or multiple non-VS, non-intradermal cranial, spinal and peripheral schwannomas (histologically proven) [schwannomatosis]. NF2 is caused by mutations in the NF2 gene at chromosome 22q12.1, which encodes for a protein called merlin or schwannomin, most similar to the extrin-readixin-moesin (ERM) proteins; mosaicNF2 is due to mosaic phenomena for the NF2 gene, whilst schwannomatosis is caused by coupled germ-line and mosaic mutations either in the SMARCB1 gene [SWNTS1; MIM # 162091] or the LZTR1 gene [SWNTS2; MIM # 615670] both falling within the 22q region and the NF2 gene. Data driven from in vitro and animal studies on the merlin pathway [e.g., post-translational and upstream/downstream regulation] allowed biologically targeted treatment strategies [e.g., Lapatinib, Erlotinib, Bevacizumab] aimed to multiple tumour shrinkage and/or regression and tumour arrest of progression with functional improvement.

KEY WORDS: Paediatric NF2 • Congenital NF2 • Childhood NF2 • Early onset NF2 • Mosaic NF2 • Schwannomatosis • Merlin

RIASSUNTO

La neurofibromatosi tipo 2 [NF2] è una malattia genetica a trasmissione autosomica dominante [MIM # 101000]. Clinicamente è caratterizzata da: (1) schwannomi bilaterali del (VIII) nervo acustico/vestibolare; (2) cataratta giovanile o amartomi retinici; (3) schwannomi a carico dei nervi periferici e dei nervi cranici; (4) tumori multipli del sistema nervoso centrale (es., meningiomi, astrocitomi, ependimomi); (5) lesioni cutanee: (a) placche NF2 (schwannomi cutanei); (b) (poche) macchie caffelatte; (6) "malformazioni dello sviluppo corticale cerebrale". La prevalenza della (forma sintomatica di) NF2 nella popolazione generale è di 1 su 100.000-200.000 individui con un'incidenza di 1 su 33.000 nati. La forma classica a esordio nel giovane adulto è conosciuta come forma di Gardner, (esordio intorno ai 20-30 anni d'età) con manifestazioni legate agli schwannomi bilaterali del nervo acustico/vestibolare (diminuzione/perdita progressiva dell'udito, tinnito, vertigini) e/o più raramente con manifestazioni da (altri) tumori del sistema nervoso centrale e/o periferico. In età pediatrica il fenotipo è diverso (forma di Wishart): per primi compaiono abitualmente i tumori del sistema nervoso centrale in assenza di schwannomi vestibolari; si possono avere macchie caffelatte e placche NF2 e solo dopo anni i tumori del nervo cranico VIII e di altri nervi cranici. Il quadro è più grave. Esiste anche una forma "congenita" ad esordio nei primi giorni/mesi di vita, con schwannomi vestibolari di piccole dimensioni (stabili nel tempo: anche per anni/decenni ma con improvvisa e rapida pro-

gressione) e numerose placche NF2; in questa forma le altre manifestazioni (es. meningiomi, altri tumori, altri schwannomi) sono spesso più gravi e progressive delle altre forme. Il gene responsabile della NF2 è localizzato sul cromosoma 22q12.1. Il prodotto genico della NF2 è conosciuto con il nome di schwannomina o merlina [dalla famiglia di proteine 4.1 del tipo moesina-ezrina-radixina/ERM alla quale appartiene il gene della NF2] e ha funzioni di regolazione della crescita e del rimodellamento cellulare (soppressione della crescita cellulare e della tumorigenesi). Alcune persone possono presentare tutte le (o parte delle) manifestazioni della NF2 in un emilato o in segmenti corporei circoscritti [NF2 a mosaico]. Altre persone presentano schwannomi (confermati istologicamente) dei nervi periferici (non intradermici) e/o delle radici gangliari in assenza di tumori del nervo vestibolare (o di altri nervi cranici: anche se in alcuni casi vi possono essere anche tumori unilaterali o bilaterali del nervo acustico/vestibolare e/o dei nervi cranici misti) o di altri segni diagnostici per la NF2 [Schwannomatosi, SWNTS]. L'esordio in questa forma è intorno ai 30 anni d'età (sono conosciuti casi in età pediatrica) con tumori in svariate sedi (abituamente tronco e arti). Si conoscono due forme principali: (1) SWNTS1 [MIM # 162091] causata da alterazioni del gene SMARCB1 [regolatore della cromatina actina-dipendente associato alla matrice e correlato alle proteina SWI/SBF, sub-famiglia B, membro di tipo 1; MIM # 601607], sul cromosoma 22q11.23 (posizione centromerica rispetto al gene della NF2); (2) SWNTS2 [MIM # 615670] causata da alterazioni del gene LZTR1 [regolatore della trascrizione di tipo 1 legato alla Leucina; MIM # 600574], cromosoma 22q11.21 (posizione centromerica rispetto al gene SMARCB1) che codifica per una proteina, membro della super-famiglia BTB-kelch. Il meccanismo molecolare della Schwannomatosi comprende: (1) mutazione germinale del gene SMARCB1 o del gene LZTR1; (2) ampia delezione all'interno del cromosoma 22 (con perdita del gene NF2 e dell'allele intatto SMARCB1 o LZTR1); e (3) mutazione somatica dell'allele intatto del gene NF2 [meccanismo conosciuto come "four hits": "Quadrupla alterazione" (su entrambi gli alleli dei due geni SWNTS/NF2), con tre passaggi consecutivi]. Negli ultimi anni, accanto alle tradizionali terapie chirurgiche e/o radioterapiche sono stati anche impiegati diversi farmaci "biologici" (es., Lapatinib e Bevacizumab) con effetti di riduzione/arresto della crescita dei tipici tumori NF2.

PAROLE CHIAVE: NF2 pediatrica • NF2 ad esordio precoce • NF2 a mosaico • NF2 Congenita • Schwannomatosi • Merlina

Acta Otorhinolaryngol Ital 2016;36:345-367

Introduction

Neurofibromatosis type 2 [NF2; MIM # 101000]¹⁻⁴, previously known as bilateral acoustic neurofibromatosis [BANF] or central neurofibromatosis⁵⁻⁸, is an autosomal dominant disorder caused by mutations in the NF2 gene [MIM # 607379]^{9,10}, encoding neurofibromin-2 or schwannomin [SCH], which is also called merlin [moesin-ezrin-radixin-like (ERM) protein], on chromosome 22q12.2¹¹. Clinically, NF2 is characterised by the development of vestibular schwannomas (VSs), schwannomas of other cranial, spinal and cutaneous nerves, cranial and spinal meningiomas and/or other central nervous system (CNS) tumours including ependymomas and low grade astrocytomas¹²⁻¹⁵. A variety of ocular abnormalities are also common, such as early onset cataracts (usually asymptomatic), optic nerve sheath meningiomas, retinal and/or pigment epithelial hamartomas and epithelial retinal membranes¹⁶. Skin abnormalities include flat dermal (NF2-plaques) and spherical/ovoid subcutaneous nodular schwannomas¹⁷. Less than 1% of NF2 patients have ≥ 6 café-au-lait (CAL) spots^{1-4,17}. Clinically, affected individuals fall into two main groups^{18,19}: (1) (Mild) Gardner type NF2^{6,7}, with bilateral VSs presenting in adulthood (mean age 22 to 27 years), often as the only feature¹⁹; (2) (Severe) Wishart type NF2⁵, with multiple (and rapidly progressive) CNS tumours other-than-VS which may present first, years before VSs²⁰⁻³³. The latter group also tends to have more marked skin and eye involvement^{1-4,20-33}. There is nonetheless substantial variation and patients may not fit neatly into one category. A third group, known as congenital NF2³⁴, has been also recorded with bilateral VSs detected as early as the first days to months of life, which can be stable (and asymptomatic) for one to nearly two decades and thereafter sud-

denly progress: this form may be associated with (reversible) NF2 plaques in atypical locations (e.g., face, hands and feet) and other CNS tumours (e.g., meningiomas, ependymomas)³⁴.

Some individuals may also have NF2-related tumours localised to one part of the nervous system: e.g., a unilateral vestibular schwannoma with ipsilateral meningiomas or multiple schwannomas in one part of the peripheral nervous system (mosaic NF2): these phenotypes are caused by true somatic mutations of the NF2 gene³⁵⁻⁵⁰.

Some other individuals develop multiple non-vestibular, non-intradermal cranial, spinal and peripheral [histologically proven] schwannomas and are usually referred as having schwannomatosis [SWNTS]⁵¹⁻⁵⁹: two major clinical/molecular forms have been characterised so far, caused by mutation either in the SMARCB1 gene [SWNTS1: MIM # 162091] located at 22q11.23⁶⁰⁻⁶² or in the LZTR1 gene [SWNTS2: MIM # 615670] located at 22q11.21⁶³⁻⁶⁵.

Clinically overlapping features, between classical NF2 and alternate forms of NF2 [i.e., mosaic NF2 and schwannomatosis], are increasingly recorded^{38,40,43-47,50,58} and only sometimes sorted out by means of molecular analysis⁶⁶. Unilateral VSs (without NF2-related features) are relatively common in the general population [7% of all primary CNS tumours] as well as the occurrence of multiple meningiomas [including familial multiple meningiomas]. For all the above reasons and considerations, multiple sets of diagnostic criteria have been developed over the years for NF2 and its alternate/related forms^{44,46,55,57-59,67-72}. However, even individuals with bilateral VS especially late in life can have developed these by chance rather than having NF2⁵⁰.

Clinical manifestations and natural history in the paediatric age

Patterns of initial presentations

The pattern(s) of presentation (and the natural history) of NF2 in childhood, are very protean and differ from adulthood in many respects¹⁹⁻³³. In addition, children with NF2 whose onset is at or before puberty usually present differently from adolescents^{28 32 34}. The most common initial symptoms in adult onset NF2 are usually attributed to eight cranial nerve dysfunction and include hearing loss, tinnitus, or balance dysfunction^{1-4 12-14 73}. Conversely, in the pre-pubertal NF2 age group subtle skin tumours, small posterior capsular or cortical edge cataracts or neurological signs (see below) secondary to other-than-VSs cranial nerve(s) involvement and/or brainstem or spinal cord compression are more common and manifest long before dysfunction of cranial nerve VIII¹⁹⁻³⁴. A reversal pattern is encountered in the congenital form of NF2 (see below)³⁴, whose first nervous system manifestation of the disease is the presence of small (i.e., less than 1 cm) bilateral VS, recorded (incidentally) as early as the first months or days (Zampino G., personal observation) of life.

Skin manifestations

The initial clinical presentation of some NF2 children is when they manifest with few CAL spots (larger than in NF1, with more irregular margins and paler colour) (Fig. 1), and/or peripheral nerve tumours (Fig. 2) and are initially diagnosed as having either NF1 or sporadic benign neurofibromas or schwannomas, the revision of the diagnosis only occurring when the tumours are removed for histology showing a schwannoma not a neurofibroma or when other tumours become symptomatic or other NF2 features manifest^{19 23 28 32 34}. Some of the cutaneous and

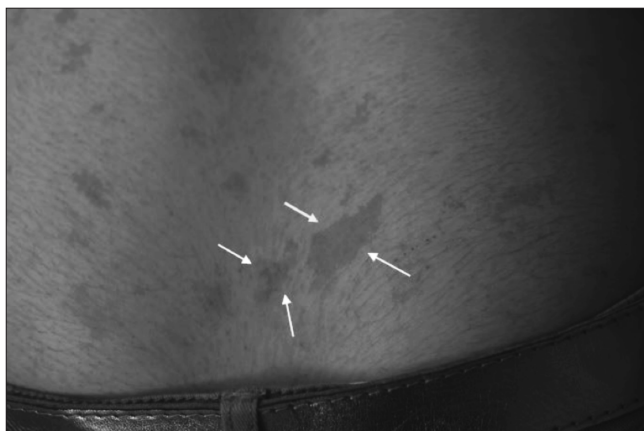

Fig. 1. Close view up of the skin of a child with NF2 showing multiple café-au-lait spots of different size and shape (the largest are indicated by white arrows): note the paler brownish colour and the irregular size and margins.

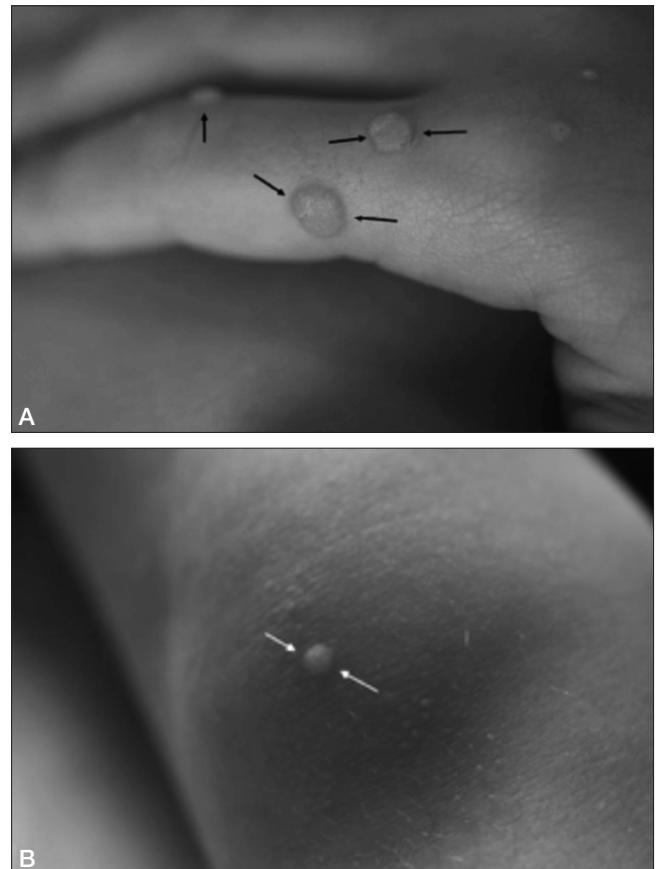


Fig. 2. Close view up of the skin of a toddler with "congenital" onset NF2 showing classical NF2 plaques (in atypical locations) over (A) the fingers (black arrows) and (B) the knee (white arrows).

nodular schwannomas are difficult to distinguish from neurofibromas from a clinical point of view. The only exception are the NF2-plaques which are schwannomas histologically and have a distinctive appearance as discrete, well-circumscribed, slightly raised pigmented cutaneous lesions (Fig. 2) often containing excess hair and usually less than 2 cm in diameter^{28 34}. Another important aspect is that the NF2-plaques, in this young age group, are usually and typically (mostly) localised in the upper and lower limbs (and the hands, feet and the face in the congenital forms) (Fig. 2 A-B)^{23 28 34}, differently from what is recorded in adult onset NF2 where the plaques are prevalently located in the trunk^{1-4 12-14}.

Ophthalmologic manifestations

Cataract is usually recorded in about 40% of NF2 children and is most commonly of the juvenile posterior sub-capsular or cortical types (Fig. 3a). A further 25% of cases may have retinal hamartomas. Overall, cataract and/or retinal changes are recorded in 40% to over 70% in the paediatric NF2 series so far reported^{19 23 28 30 32}. Notably, Evans et al.²³ recorded lower overall figures (3.3%) for cataract in their NF2 children, but these had not undergone systematic ophthalmological examination. In all the

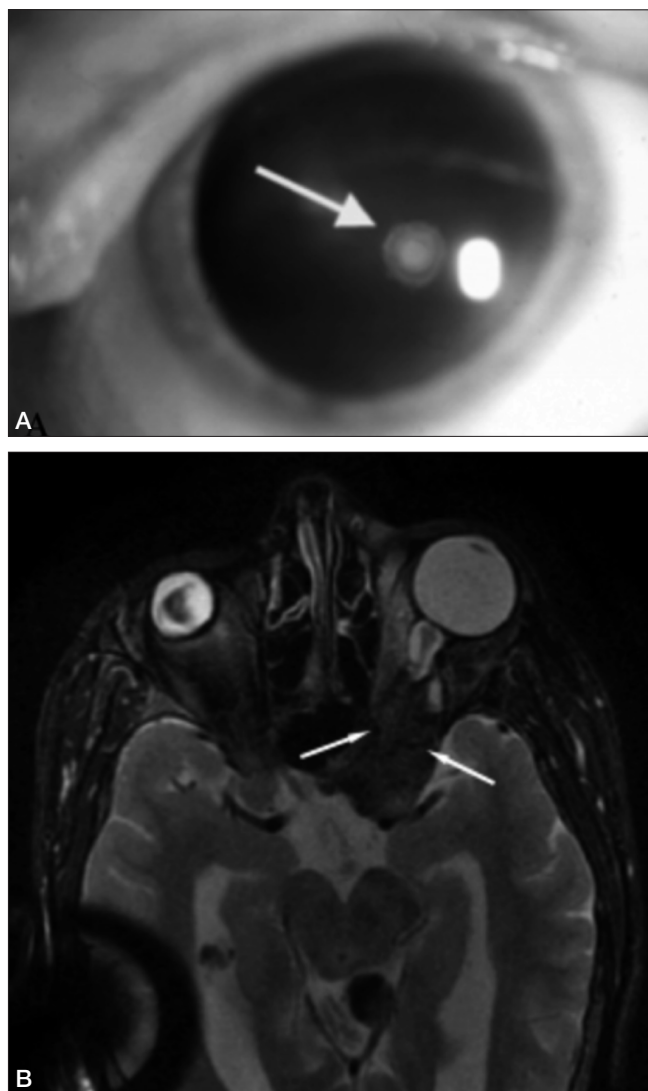


Fig. 3. (A) Magnified view of the eye in an NF2 child showing subcapsular lens opacities (white arrow); and (B) Axial T2-weighted magnetic resonance image of the brain in a child with “congenital” NF2 showing a hypointense area (white arrows) in the intra-orbital region (“intra-orbital meningioma”).

large NF2 series, lens opacities have usually been asymptomatic but when they are large can affect visual acuity in approximately 20% of NF2 patients^{19,33}. In childhood NF2 lens opacities can be detected by chance very early in life but often are thought to be sporadic and the children being discharged with follow-up^{19,24,26-28}. When the same patients later develop hearing or neurological signs, whose association with cataracts should have alerted for NF2, diagnosis was suspected²⁸.

A significant number of NF2 children may have idiopathic strabismus or amblyopia before the development of other neurological symptoms that prompt the diagnosis of NF2^{23,26-28}. Childhood onset strabismus and amblyopia have been frequently reported in adults with NF2^{1-4,12-14}. Even though either sign has been regarded as non specific²⁰ we recorded both signs in children who later on in their

NF2 course were shown at neuroimaging to have intraorbital or retro-orbital meningiomas (Fig. 3b) or schwannomas of the third, fourth, sixth and seventh cranial nerves or tumours in the brainstem.

Otolaryngology manifestations

Few NF2 children develop pure hearing or balance dysfunction as the first feature of their disease¹⁹⁻³³.

It must be noted that, in contrast to isolated unilateral VS, the NF2-associated VSs tend to cause symptoms at younger ages; in addition to that, NF2-associated VSs have larger size and a multilobulated macroscopic (Figs. 4a-b) and microscopic appearance when compared with their sporadic counterpart^{23,28} and on MRI are clearly multifocal on both branches of the vestibular nerves almost invariably including the 7th nerve branches and/or invading the internal auditory canal (Fig. 4c)⁷¹.

Some otolaryngology features can be caused by (other-than-eight) cranial nerve(s) involvement (Fig. 5) and/or to brain meningiomas (Fig. 6)^{23-26,28}.

Neurological phenotype

Neurological manifestations are dictated by the presence, localisation and extension of the lesions in the cranial and/or spinal regions and in the major cranial and/or peripheral nerve trunks: because of their initial, other-than-VSs, involvement most children with NF2 at onset may have isolated or multiple (other-than-eight nerve) cranial nerve deficits, neurological dysfunction related to intracranial, brainstem and/or spinal masses (most often meningiomas, schwannomas and ependymomas), including sensory and/or motor deficits, seizures and/or visual field defects, and peripheral neuropathy (with muscle wasting) secondary to schwannomas.

There are neither intellectual impairment nor learning difficulties.

Central nervous system imaging, which in NF2 must include full brain and spinal MRI, usually assess the tumour burden and its progression over time. In almost all children with the Wishart type NF2^{24-26,28} and in all children with congenital type NF2³⁴ we also recorded high signal lesions in the cortical or periventricular regions resembling those of cortical dysplasia or cortical alterations of the polymicrogyria type. These hyperintensities (which do not enhance after gadolinium administration) have been so far attributed either to meningoangiomas or to hamartomatous tissue; the “pure” cortical dysplasia is often associated with other brain anomalies (e.g., colpocephaly). Interestingly, these cortical abnormalities do not behave as true masses or classical dysplasia being asymptomatic initially: however, after puberty we recorded generalised tonic-clonic seizures [easily treatable with classical anti-convulsants (e.g., valproic acid)] in most of these children with cortical abnormalities^{28,34}.

The brainstem and/or the spine are usually involved by in-

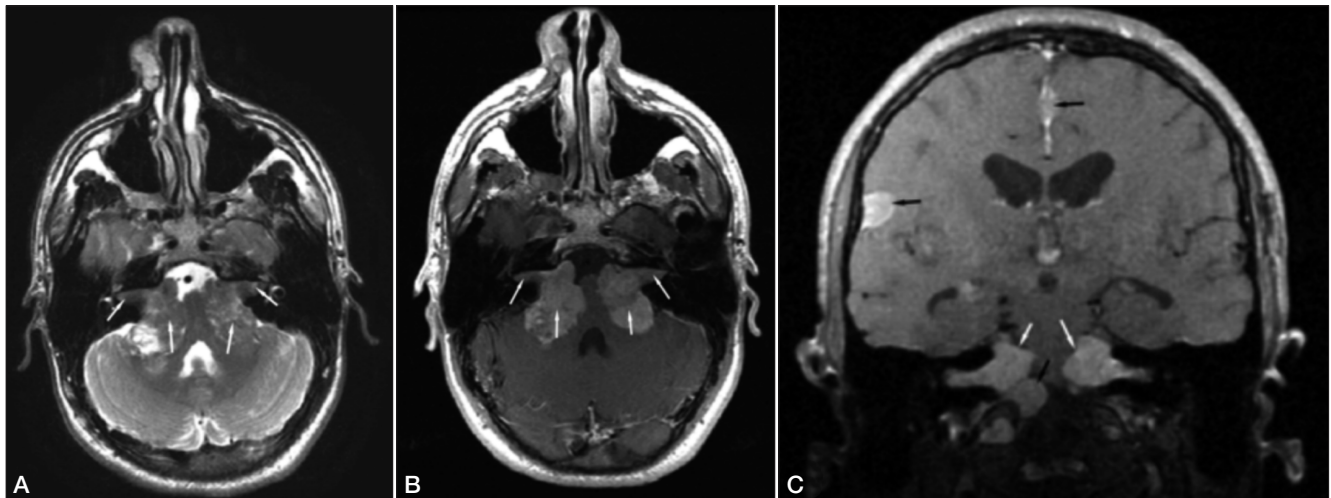


Fig. 4. Axial T2-weighted (A) and T1-weighted contrast enhanced (gadolinium) (B) magnetic resonance images of the brain in an adolescent with Nf2 showing bilateral schwannomas (as hypointense lesions: white arrows) with intracanalicular extension (outer white arrows); (C) Coronal T1-weighted contrast enhanced (gadolinium) magnetic resonance image of the brain in a child with NF2 showing bilateral schwannomas (as hyperintense lesions: white arrows) and multiple meningiomas (black arrows).

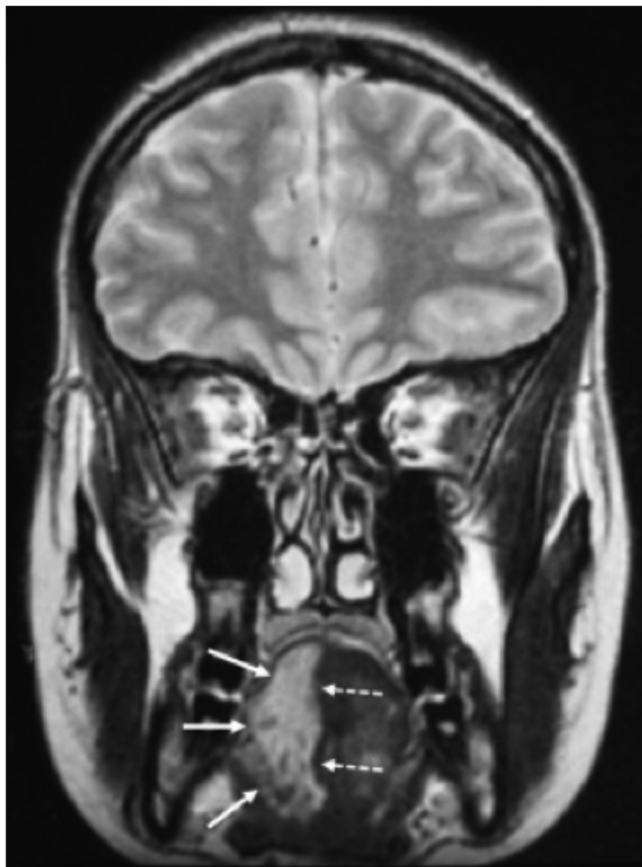


Fig. 5. Coronal T2-weighted magnetic resonance image of the brain showing a hyperintense aspect of the right hemi-tongue (seen in the left side of the Fig.: white arrows), which is atrophic because of a schwannoma of the 12th cranial nerve (note the normal aspect of the contralateral tongue delineated by the dashed white arrows).

trinsic tumours (e.g., ependymomas, astrocytomas) (Fig. 7), intradural meningiomas (Fig. 8a), and/or by peripheral schwannomas affecting the paravertebral ganglia and/or extending into the extra- or intradural spaces (Fig. 8b).

Peripheral nervous system imaging reveals solitary or (more often) multiple schwannomas affecting, with variable extension, multiple nerves or multiple (major) nerve trunks and/or the paravertebral ganglia²⁰⁻³³. MRI is essential for initial diagnosis and differential diagnosis with NF1 and related forms, mosaic/segmental NF2 and schwannomatosis (see below).

Peripheral (axonal/demyelinating) neuropathy (confirmed by neurophysiology testing and without MRI evidence of underlying tumours) and monomelic atrophy (with wasting of a single limb) are frequently recorded (but often under-recognised) irrespective of age in children (and adults) with NF2 [symmetric and/or asymmetric distal sensorimotor neuropathy ranging from mild to severe degrees]²⁰⁻³³: this neuropathy is thought to arise from neurofibromatous changes in peripheral nerves.

Congenital NF2

This form is characterised by the occurrence of^{20 23 27 34}: (1) small (< 1 cm), bilateral vestibular schwannomas (VSs) detected (as an incidental finding) at MRI by the first months of life (Fig. 9a) [or at birth: Zampino G., et al. at the Department of Paediatrics of the Catholic University of Rome, Italy, 2015; personal observation] that are asymptomatic for 10 to 15 years, with usually sudden and rapid (< 12 months) progression; (2) devel-

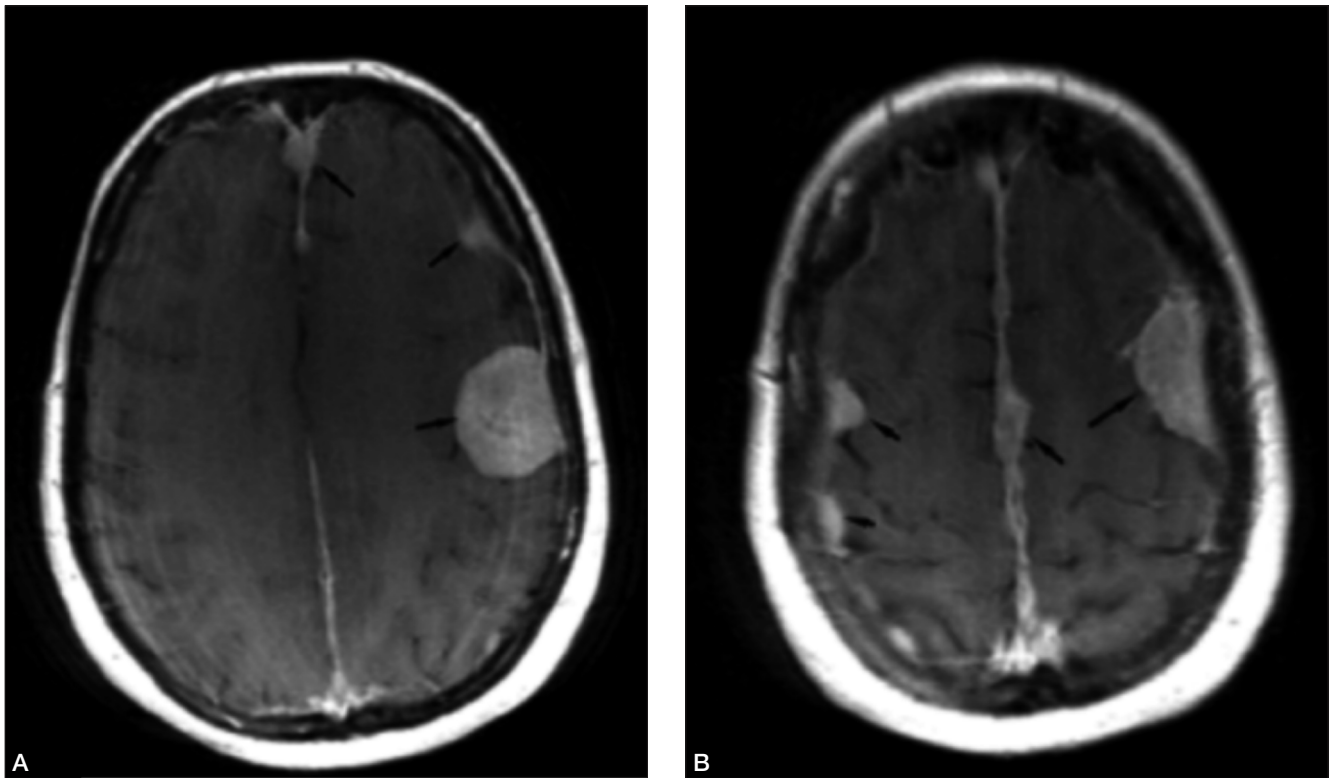


Fig. 6. Axial T1-weighted contrast enhanced (gadolinium) (A-B) magnetic resonance images of the brain showing multiple meningiomas as hyperintense lesions (“meningiomatosis”).

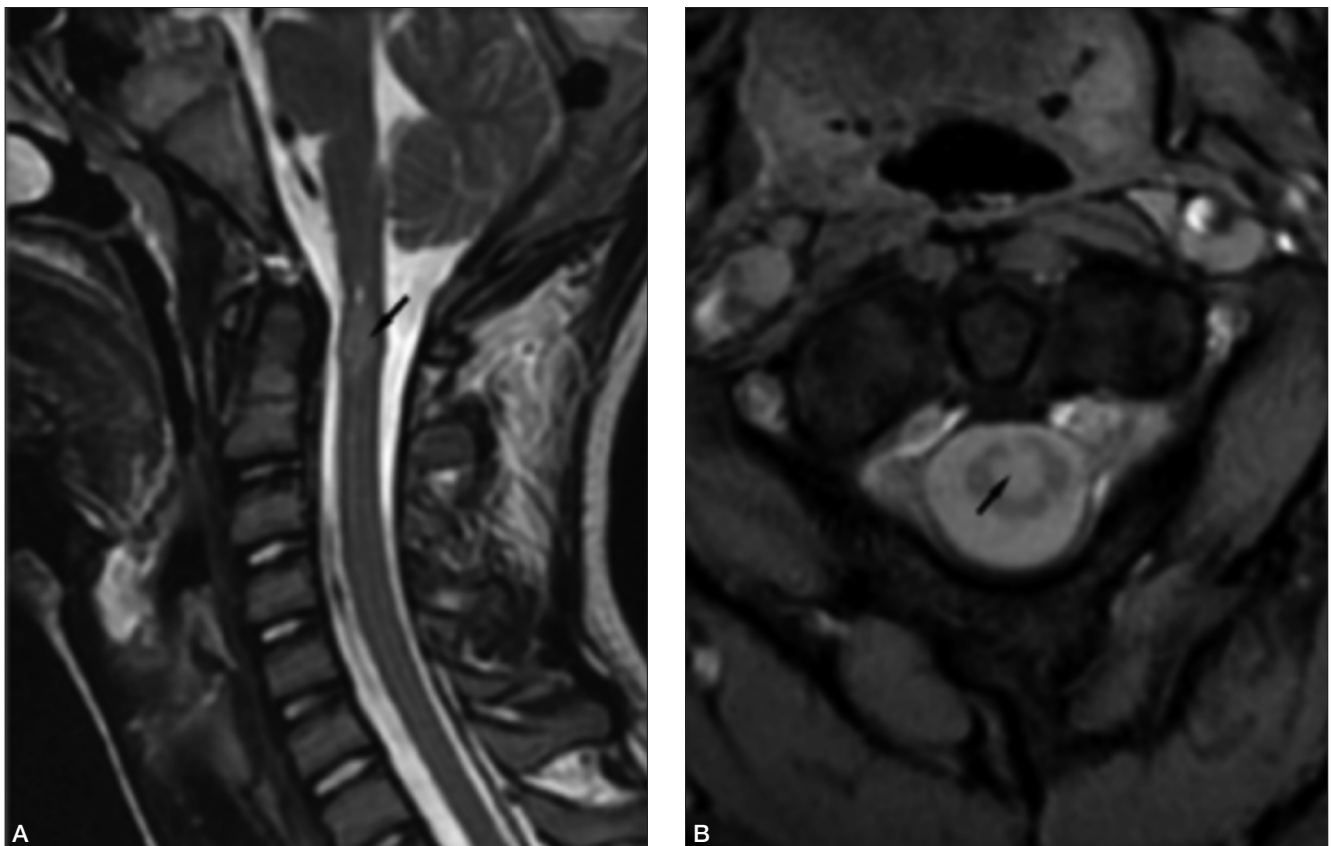


Fig. 7. Sagittal (A) and axial (B) T2-weighted magnetic resonance images of the spinal cord in a child with NF2 showing round hyperintense lesions of the cervical cord at the C1 level (intraspinal ependymoma).

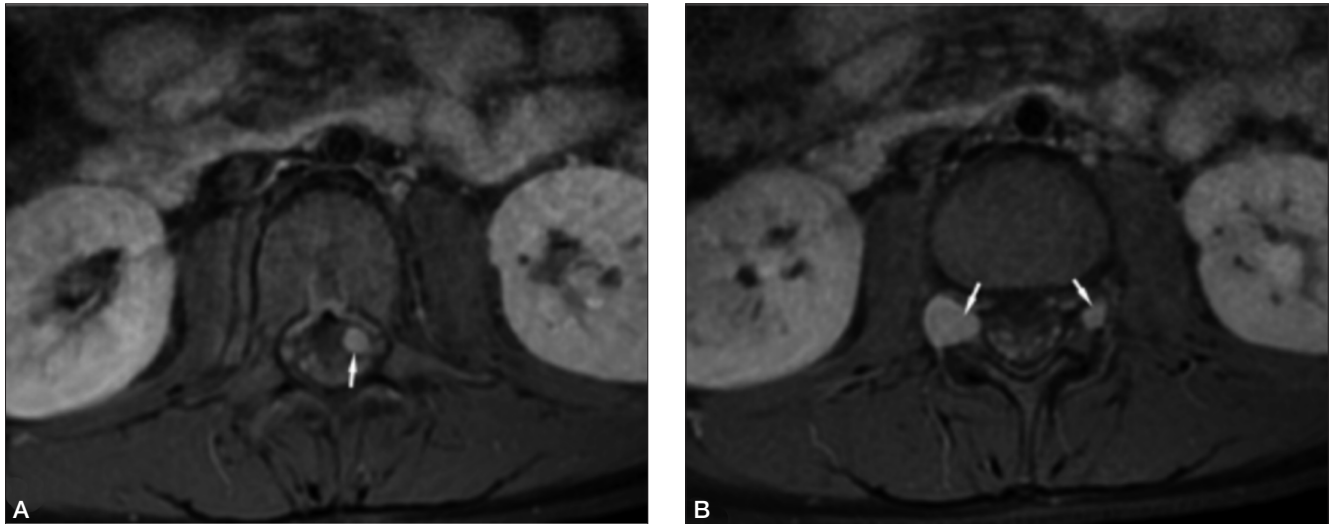


Fig. 8. Axial T1-weighted contrast enhanced (gadolinium) (A-B) magnetic resonance images of the spinal cord in an adolescent with NF2, showing (A) an intradural meningioma (white arrow) and (B) two schwannomas of the spinal nerves (white arrows).

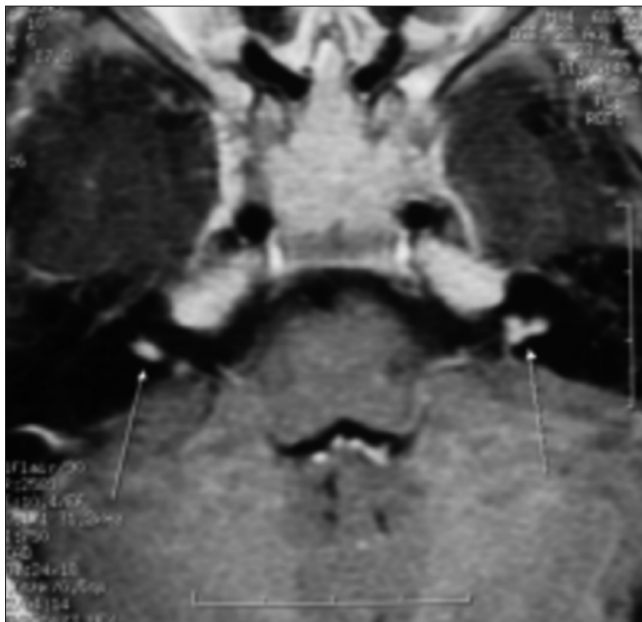


Fig. 9. Axial T1-weighted magnetic resonance image of the brain in a child with a congenital form of NF2 obtained at age 4 months showing bilateral vestibular schwannomas (case 1, ref. 34).

opment of large numbers of skin NF2 plaques mainly in atypical locations (i.e., face, hands and knees) (Fig. 2), which reverted to normal skin appearance at the time of VSs progression in the series so far reported³⁴; (3) lens opacities (Fig. 1) and NF2 retinal changes detected as early as the first months of life; (4) cortical malformations and/or diffuse (asymptomatic) high signal lesions at brain MRI in the periventricular regions; and (5) unaffected first-degree relatives who do not harbour NF2 gene abnormalities.

Pathophysiology: NF2 gene and merlin/schwannomin

NF2 gene

NF2 is caused by mutations in the NF2 gene at chromosome 22q12.1, which encodes for a protein called merlin or schwannomin, most similar to the exrin-radixin-moesin (ERM) proteins (Fig. 10)⁹⁻¹¹: these are membrane-cytoskeleton scaffolding proteins (i.e., linking actin filaments to cell membrane or membrane glycoproteins), which act as critical regulators of contact-dependent inhibition of proliferation and function at the interface between cell-to-cell adhesion, transmembrane signalling, and the actin cytoskeleton, thus contributing to maintain normal cytoskeletal organisation, to modulate cellular motility, attachment, remodelling and spreading and to regulate growth (tumour suppression function)⁷⁴.

Merlin structure and conformation

Merlin isoforms. The NF2 gene encodes two merlin isoforms⁷⁵: (1) the longer, dominant isoform 1 (merlin-1 or merlin), a 595-residue protein, which presents an extended carboxy-terminal tail that is encoded by exon 17; and (2) the merlin isoform 2 (merlin-2), which contains an alternatively spliced exon 16 which ends in a stop codon, encoding 11 unique residues following amino acid 579 (as compared to Merlin-1)⁷⁶. Merlin-2 lacks the carboxy-terminal residues required for intra-molecular binding between the amino-terminal FERM domain and the carboxy-terminal hydrophilic tail, possibly leading to a constitutively open conformation (Fig. 10). In vitro and in vivo studies have demonstrated that merlin-2 inhibits cell proliferation and attenuates the downstream mitogenic signalling to the same extent of its isoform merlin-1 (thus, apparently irrespective of the open vs. closed state)⁷⁷.

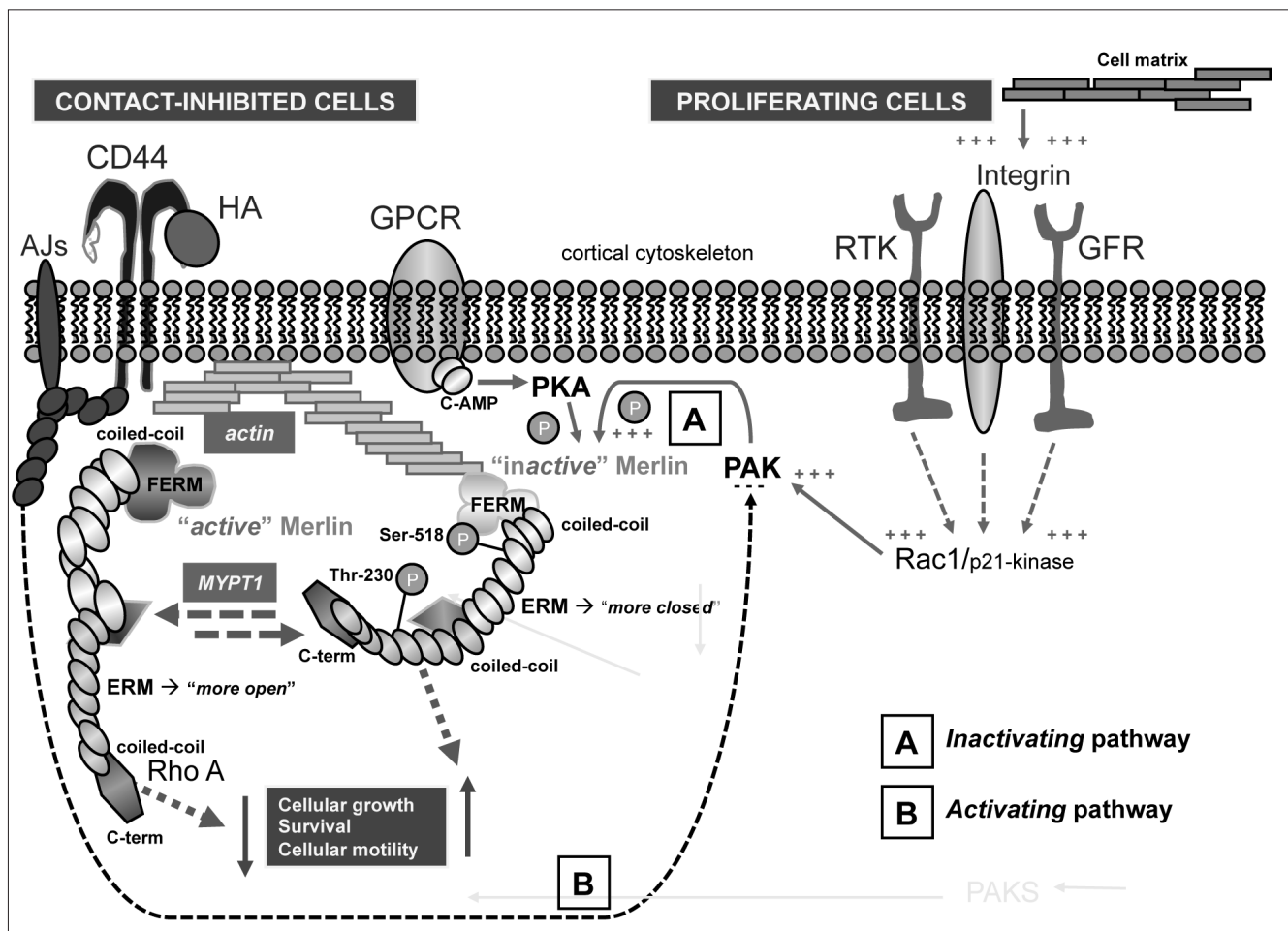


Fig. 10. Merlin-signalling pathway - In more recent years, several lines of evidence have suggested that Merlin exists in multiple states, which vary from “fully open” to “fully closed” [including “more closed” and “more open” states (see text for further explanation)]. In its “more closed” frame **Merlin** is hyperphosphorylated (has many “P” groups) and connected to cytoskeletal actin (because of an increase in intra-molecular bounds - secondary to the increased “P” groups - which contribute to fold the protein structure) (**inactive Merlin**): thus, the *mitogen-signalling* pathway [activated via the PAK and PKA pathways], is active and increases the cellular proliferative phenomena; in its “more open” frame **Merlin** is dephosphorylated (has less “P” groups) and is disconnected from actin (**active Merlin**): thus, the *mitogen-signalling* pathway, is inactive and decreases cellular growth, survival and cellular motility. In *proliferating cells*: (a) interactions between the extracellular matrix and the GFR/RTK/integrin proteins (and their membrane receptors) trigger the Rac1/PAK pathway; and (b) interactions between the GPCR receptors and c-AMP trigger the PKA pathway, both activating in turn the structural changes of Merlin [i.e., phosphorylation, increase in intra-cellular bounds and protein folding], which switches to a “more closed” (inactive) state [**A: inactivating pathway**]. In *contact-inhibited cells*, different phosphatases (mediated by the adhesion junctions’ molecules and by HA bounds to CD44 receptors), via activation of the MYPT1 dephosphorylation and inhibition of the PAK/PAK pathway, dephosphorylate Merlin (→ switching to active form), which in turn leads to decreased cellular growth [**B: activating pathway**]. AJs = adhesion junction proteins; c-AMP = cyclic AMP; CD44 = antigen CD44; C-term = carboxy-terminal hydrophilic tail of the Merlin protein; coiled-coil = a structural motif (part) of the Merlin protein in which alpha-helices are coiled together like the strands of a rope; ERM = Ezrin-radixin-moesin proteins; FERM = (F)-Four-point-one (4.1) protein-ERM domain of the Merlin protein (amino-terminal); GFR = growth factor receptor; GPCR = G-protein-coupled receptor; HA = hyaluronic acid; MYPT1 = myosin phosphatase target, subunit 1; P = phosphorylation groups; PAK = serine/threonine p21-activated kinase; PKA = protein kinase A enzyme; Rac1 = Rho family small GTP binding proteins; Rho = RAS homologue gene family; RTK = receptor tyrosine kinase; Ser-518 = Serine-518; Thr-230 = Threonine 230; + + + = stimulation; - - - = inhibition (from Ruggieri et al., 2015³⁵ and Ruggieri et al., 2015³⁶, adapted and modified).

Merlin properties. The similarities of merlin to its familial group of ERM proteins are responsible for its cytoskeletal-binding properties: e.g., merlin links the cytoskeleton to the cell membrane either directly (through integral membrane proteins) or indirectly (through membrane-associated proteins)⁷⁸.

Merlin domains. Merlin is divided into three structurally

distinct regions: (1) an amino-terminal FERM (Four-point-one, ezrin, radixin, and moesin) domain; (2) a α -helical coiled-coil domain; and (3) a carboxy-terminal hydrophilic tail. The FERM domain shares 65% sequence identity with canonical ERMs, but, differently from the other ERM proteins, merlin lacks the actin-binding site in the C-terminal domain, which is highly conserved in the

other ERMs protein providing these proteins with their function at the cortical cytoskeleton⁷⁹. In merlin, the binding site of actin is located in the glutathione S-transferase N-terminal domain.

“Closed” (active) vs. “open” inactive forms. Merlin switches from a closed state to an open state by phosphorylation at serine 518 (Fig. 10)⁸⁰. In the past decades, the evidence that Merlin-2 -which lacks the carboxy-terminal domain, thus lacking the possibility to reach a “closed” state - failed to exert tumour suppression activity and/or contact inhibition, led researchers to state that “active” merlin functioned in a closed conformation caused by the dephosphorylation at Serine-518, while the open form [i.e., the solely form thought to be reached by merlin-2] was “inactive” and phosphorylated.

“More closed” (inactive) vs. “more open” (active) forms. In more recent years, the above (simplified) interpretation was questioned and several lines of evidence now suggest that merlin exists in multiple states, which vary from “fully open” to “fully closed”. In addition to that, it was demonstrated^{79,81} that merlin-2 is able to suppress growth in mammalian cell lines, suggesting that the interdomain binding is dispensable for Merlin’s adhesion signalling: the phosphorylated merlin [merlin-2] displays higher interdomain binding and therefore it is able to inhibit cell growth (even) in its open state. Furthermore, it has been observed that a stably closed merlin mutant does not suppress cell growth, whereas merlin-2 and the S-518 phospho-deficient mutant, which are defective in interdomain binding and therefore more open, can suppress cellular growth in the same way as it does the wild-type merlin. It is now accepted that the “more open” forms (Fig. 10B) of merlin are more active as anti-oncogenic proteins, while the “more closed” forms (Fig. 10A) lacks this function.

FERM domain. Recent genetic evidence has suggested that a crucial role in Merlin’s anti-tumour efficacy is played by the FERM domain, and in particular by the “Blue-box motif” within the subdomain F2, correspondent to the residues 177-183 in human merlin. In this respect, it is now well known that patients with truncating mutations show a more severe clinical picture, with a higher tumour burden. However, it must be said also that missense mutations involving residues 177-183 in the F2 domain can lead to more severe forms of NF2. Substitution of F2 domain with that of ERM protein Ezrin abolishes Merlin’s anti-oncogenic activity, while substitutions of F1 or F3 domains does not affect cell proliferation^{81,82}. In contrast, mutations involving the coiled-coil region or the carboxy-terminal tail have rarely been observed in NF2 patients, thus demonstrating the crucial role of FERM domain in the pathogenesis of the disease⁸³. It is presumable, that the α -helical domain and the C-terminus function in maintaining merlin in its inactive conformation during the normal biological cellular growth and could contribute to contact inhibition.

Post-translational regulation of Merlin

Merlin’s function is mediated by different signalling pathways within the cell, which have been extensively characterised⁸⁴.

Inactivating pathways. In proliferating cells, integrin-mediated anchorage to the cell matrix and stimulation of receptor tyrosine kinases (RTKs) activate Rac [Rac1/p21-kinase], in turn activating PAK and leading to phosphorylation of merlin at serine 518 (Fig. 10B). Serine 518 phosphorylation increases the interdomain binding between Merlin’s carboxy-terminus and FERM domain, maintaining merlin in a “more closed”, inactive form: the inactivation is probably due to (a) masking of protein-interacting domains on FERM domain, which are necessary for downstream signalling or (b) occlusion of a presumable nuclear localization signal⁸⁵. Merlin is inactivated mostly via the PAK/Rac pathway, which is initiated by RTK and Integrin receptors in the cell wall. The activation of PAK leads to the phosphorylation of Merlin in position 518 and the latter may be necessary for subsequent phosphorylation of other sites. Moreover, also protein kinase A enzymes can independently phosphorylate Merlin at serines 518 and 10⁸⁶: this could be particularly relevant in Schwann cells, which are sensitive to the cyclic AMP-PKA signalling axis⁸⁷. Protein kinase B, also named AKT, can induce phosphorylation at threonine 230 and serine 315, causing decreased interdomain binding, and the interaction with Phosphoinositide and PIKE-L⁸⁸. Loss of PTEN function (related to an increased oncogenic risk) which results in increased PI3K-AKT activity can induce further merlin inactivation⁷⁷.

Activating pathways. In contact-inhibited cells, dephosphorylated merlin accumulates (Fig. 10B) as a result of intercellular adhesions, which lead to PAK inhibition^{82,84}. Different phosphatases may contribute in dephosphorylating merlin, regulating its activity, but the key role is played by cadherins and CD44 receptors, which activate merlin through its dephosphorylation by myosin phosphatase targeting subunit 1 (MYPT1)⁸⁹. It has been showed that the protein kinase CPI-17 (c-potentiated phosphatase inhibitor 17 kDa weighed) inhibits MYPT1 and causes a reduced activation of merlin⁹⁰. By contrast, cadherins cause loss of function of PAK protein, thus inhibiting the inactivation of Merlin.

Merlin downstream

Effects mediated by Merlin in the membrane organisation of proteins include cell-to-cell adhesion, cytoskeletal architecture, interaction with cytosolic proteins and regulation of diverse downstream pathways, including nuclear and hippo pathway regulation.

Merlin-2, via the GTPase Rho/RhoKinase signalling network, promotes phosphorylation of neurofilaments that are neuron-specific intermediate filaments essential for axon structure and caliber⁸².

Merlin-1 interacts with membrane associated proteins

where it regulates the formation of membrane domain, with a function of contact inhibition, by interacting with several proteins localised in the plasma membrane, including other ERMs, the intracellular domain of CD44, α -catenin and angiomin.

The interactions with α -catenin have been demonstrated in keratinocytes and skin epithelium: Merlin promotes the binding of β -catenin and Par3, needed for the maturation of adherence junctions, and with 14-3-3 protein, which sequesters phosphorylated YAP, suppressing YAP-mediated transcription. β -catenin also interacts with APC tumour suppressor, enhancing its activity⁹¹. The interaction with angiomin regulates contact inhibition and tumour suppression through Patj, Pals1 and Mupp1 proteins by suppressing the Rac-PAK signalling. It is important to underline that both inactive and active forms of merlin interact with angiomin, independently from growth suppressive stimuli⁹². Other interactions of merlin occur with cholesterol-dependent membrane domains as a result of phosphoinositide binding, or directly with cytoplasm proteins to control cytoskeletal dynamics, vesicular transport and microtubule stabilisation, which could function in promoting the transport of anti-mitogenic biomolecules or regulating the availability of growth factors in the cytoplasm⁹³⁻⁹⁶.

In the nucleus, dephosphorylated Merlin inhibits the pro-oncogenic CRL4^{DCAF1} E3 ubiquitin ligase, even if Merlin lacks a canonical nuclear localisation sequence. It is presumable that Merlin interacts with the nucleus through a motif in the C-terminus promoting nuclear export by the CRM1-exportin pathway, or by FERM domain residues necessary for nuclear translocation⁸⁵.

The reduction of functions of CRL4 is mediated by interactions of merlin with DCAF1 (DDB1 and Cul4-associated factor 1), a substrate recognition component of the CRL4^{DCAF1} complex, essential for epigenetic modifications that regulate DNA methylation and therefore gene transcription, in particular during embryogenesis and tumorigenesis⁹⁷. Merlin's FERM domain binds one of the carboxy-terminal acidic tail of DCAF1, directly competing with CRL4 or causing structural changes, inhibiting its binding with CRL4⁸⁵.

A further role of Merlin is in the Hippo pathway, which is a potent regulator of organ size in the whole animal kingdom. Disruption of this pathway causes organ overgrowth and tumorigenesis, through an overexpression of YAP and TAZ transcriptional coactivator, which lead to increased transcription of genes that drive proliferation, evasion of apoptosis and stemness⁹⁸⁻⁹⁹. It has recently been shown that merlin can interact with Kibra to activate the Hippo kinase cascade, maybe through interactions and modulation of angiomin in the tight junctions. Interestingly, angiomin directly binds YAP and TAZ and retains them at the cortex.¹⁰⁰ Moreover, Merlin's inhibition of CRL4^{DCAF1} ligase causes a reduced inhibition of the Lats kinases, restrict YAP signalling¹⁰¹.

The interplay of pathways

In summary, Merlin regulates proliferation acting via some cascades, which include Hippo/Mst and Warts/Lats proteins which in turn regulate the Yorkie/Yap complex on one side, and on the (RTK) Ras GAP/Raf proteins [which regulate the MEK/ERK pathway] and the PI3K/AKT proteins [which regulate the mTOR pathway] (Figs. 10, 11)⁷⁴⁻⁸¹⁻⁸⁴.

Despite the common action on Ras/MEK/ERK and PI3K/AKT/mTOR pathways, schwannomin does not interfere with learning and memory formation as it does neurofibromin (i.e., the affected protein in NF1) and the NF2 neurological phenotype seems, apparently, solely secondary to tumour formation and progression.

For the four-hit, three-steps model of tumorigenesis explaining the schwannomatosis phenotypes see below (under schwannomatosis) (Fig. 12).

Genotype-phenotype correlations

Germline mutations occur throughout the first 15 exons but not in exons 16 and 17 of NF2⁴⁹. The predominant mutations are nonsense mutations at CpG islands but all forms of NF2 mutation occur including large multiexon and whole gene deletions. There is a relatively strong genotype phenotype correlation both with type and position of NF2 germline mutation¹⁰²⁻¹⁰⁶.

Individuals with truncating mutations (nonsense/frameshift) have earlier onset of symptoms, more meningiomas and spinal tumours and die younger. Truncating mutations in exon 1 and 14/15 cause milder disease. Splice site mutations are milder than truncating mutations and there is also a positional effect with early mutations being more severe. Large deletions/duplications are intermediate with missense mutations being associated with the mildest form¹⁰⁴⁻¹⁰⁶⁻¹⁰⁷.

Alternate/related forms of Neurofibromatosis 2

Mosaic NF2

Some individuals may have a unilateral eighth-nerve schwannoma associated to ipsilateral meningiomas [i.e., unilateral NF2 involvement of the CNS] or multiple schwannomas localised to one part of the peripheral nervous system³⁵⁻⁵⁰ (the latter going into the differential diagnosis with schwannomatosis: see below)⁶⁶. As somatic mosaicism for the NF2 gene is the causative phenomenon they are also referred to as having mosaic NF2⁴⁴.

Schwannomatosis

Schwannomatosis [SWNTS] is characterised by the development of multiple non-vestibular, non-intradermal cranial, spinal and peripheral schwannomas [histologically proven]⁵¹⁻⁵⁹. Other NF2 features such as cataracts and ependymoma are absent, but meningiomas may occur with SMARCB1 mutations¹⁰⁸, even though these are not

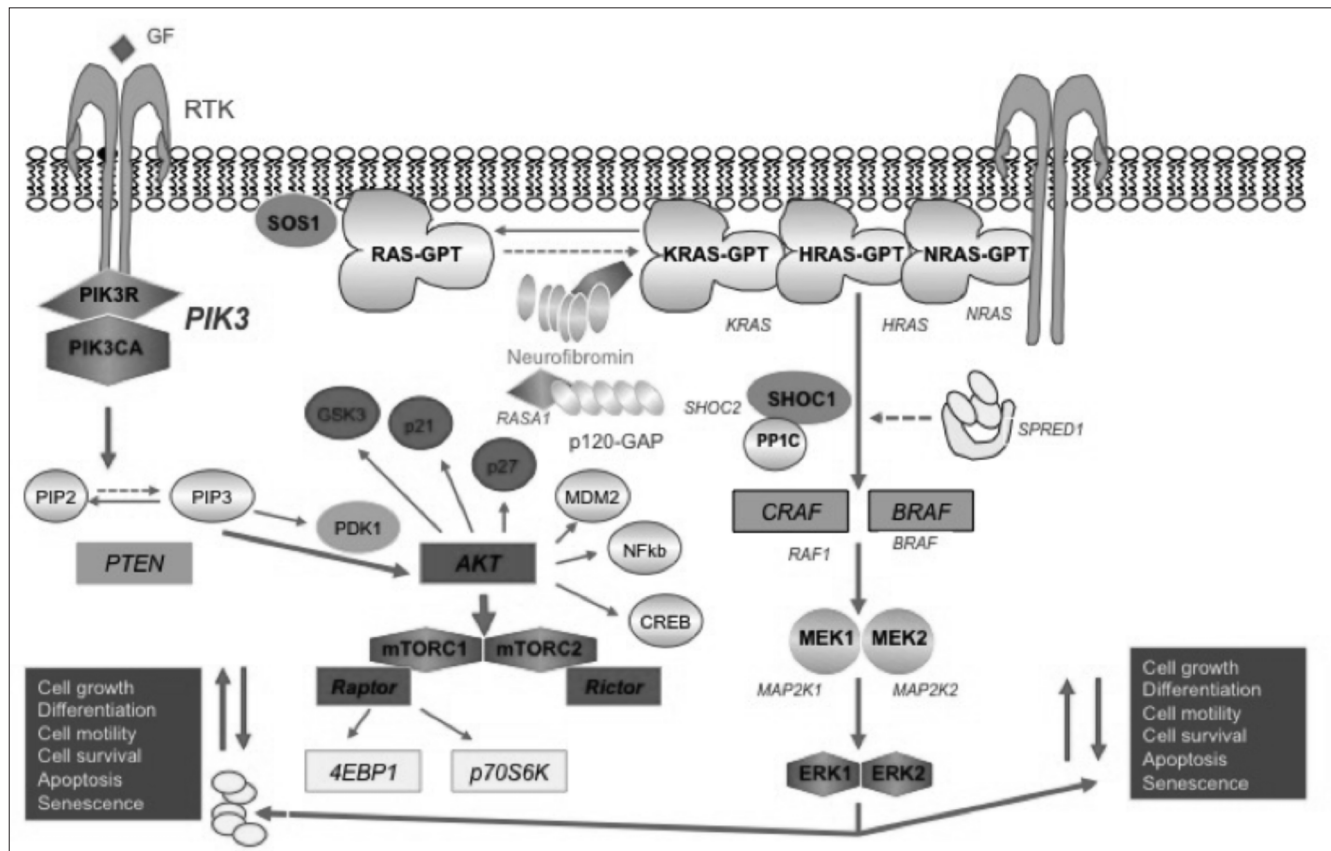


Fig. 11. Diagram showing the PIK3/AKT/MAPK signalling pathway (see text for explanation): AKT, AK (Akr mouse) strain transforming; BRAF, B-raf (rapidly accelerated fibrosarcoma); CRAF, C-raf (rapidly accelerated fibrosarcoma); CREB, cAMP response element-binding protein; 4EBP1, Eukaryotic translation initiation factor 4E-binding protein 1; ERK1, extracellular signal regulated kinase 1; ERK2, extracellular signal regulated kinase 2; GSK3, glycogen synthase kinase 3; HRAS, Harvey rat sarcoma viral (V-ras) oncogene homolog; HRAS-GTP, Harvey rat sarcoma viral (V-ras) oncogene homolog glucose triphosphate; KRAS, Kirsten rat sarcoma viral (V-ras) oncogene homolog; KRAS-GTP, Kirsten rat sarcoma viral (V-ras) oncogene homolog glucose triphosphate; GF, growth factor; MAP2K1, mitogen activated protein 2 kinase 1; MAP2K2, mitogen activated protein 2 kinase 2; MDM2, mouse double minute 2 homolog; MEK1, MAPK-extracellular kinase 1; MEK2, MAPK-extracellular kinase 2; mTORC1, mammalian target of rapamycin complex-1; mTORC2, mammalian target of rapamycin complex-2; NFκB, nuclear factor kappa-light-chain-enhancer of activated B cells; NRAS, Neuroblastoma rat sarcoma viral (V-ras) oncogene homolog; NRAS-GTP, Neuroblastoma rat sarcoma viral (V-ras) oncogene homolog glucose triphosphate; p70S6K, protein 70 serine/threonine 6 kinase; p120-GAP, p120-GTPase activating protein; PDK1, Phosphoinositide dependent kinase 1; PIK3, phosphatidylinositol-3-kinase; PIK3CA, phosphatidylinositol-3-kinase catalytic a subunit; PIK3R, phosphatidylinositol-3-kinase regulatory subunit; PIP2, phosphatidylinositol bi-phosphate; PIP3, phosphatidylinositol tri-phosphate; PP1C, protein phosphatase 1 catalytic subunit C; PTEN, phosphatase and tensin homolog; RAF, rapidly accelerated fibrosarcoma protein; Raptor, regulatory associated protein of mTOR; RAS-GTP, rat sarcoma viral (V-ras) oncogene homolog glucose triphosphate; RASA1, rat sarcoma viral (V-ras) oncogene homolog GTPase activating protein 1; Rictor, rapamycin insensitive companion of mTOR; RTK, tyrosine kinase receptor; SHOC1, suppressor of *C. elegans* homolog 1 protein; SHOC2, suppressor of *C. elegans* homolog 2 protein; SOS1, son of Sevenless 1 homolog; SPRED, Sprouty-related EVH1 domain-containing protein 1 (from Ruggieri et al., 2015³⁶, adapted and modified).

a prominent feature: SMARCB1 mutations are not a common cause of multiple meningiomas¹⁰⁹.

Two major clinical/molecular forms have been characterised so far⁵⁹⁻⁶⁶: (1) SWNTS1 [MIM # 162091]⁶⁰⁻⁶² caused by constitutional (germ-line) inactivating mutations of the SMARCB1 gene [SWI/SBF-related matrix-associated actin-dependent regulator of chromatin, subfamily B, member 1; MIM # 601607] located 6 Mb centromeric to the NF2 gene at 22q11.23, which encodes a SWI/SNF ATP-dependent nuclear chromatin remodelling protein, which is part of a complex that: (a) relieves repressive chromatin

structures, allowing the transcriptional machinery to access its targets more effectively; (b) also binds to and enhances the DNA joining activity of HIV-1 integrase [SWI/SNF is a tumour suppressor implicated also in the genesis of malignant rhabdoid tumours]. The SWNTS1 phenotype includes families with multiple schwannomas and multiple extra-axial/extra-medullary meningiomas (and also a unilateral vestibular schwannoma)⁵⁸; and (2) SWNTS2 [MIM # 615670]⁶³⁻⁶⁵ caused by constitutional/germ-line inactivating mutations of the LZTR1 gene [Leucine zipper-like transcriptional regulator 1; MIM # 600574],

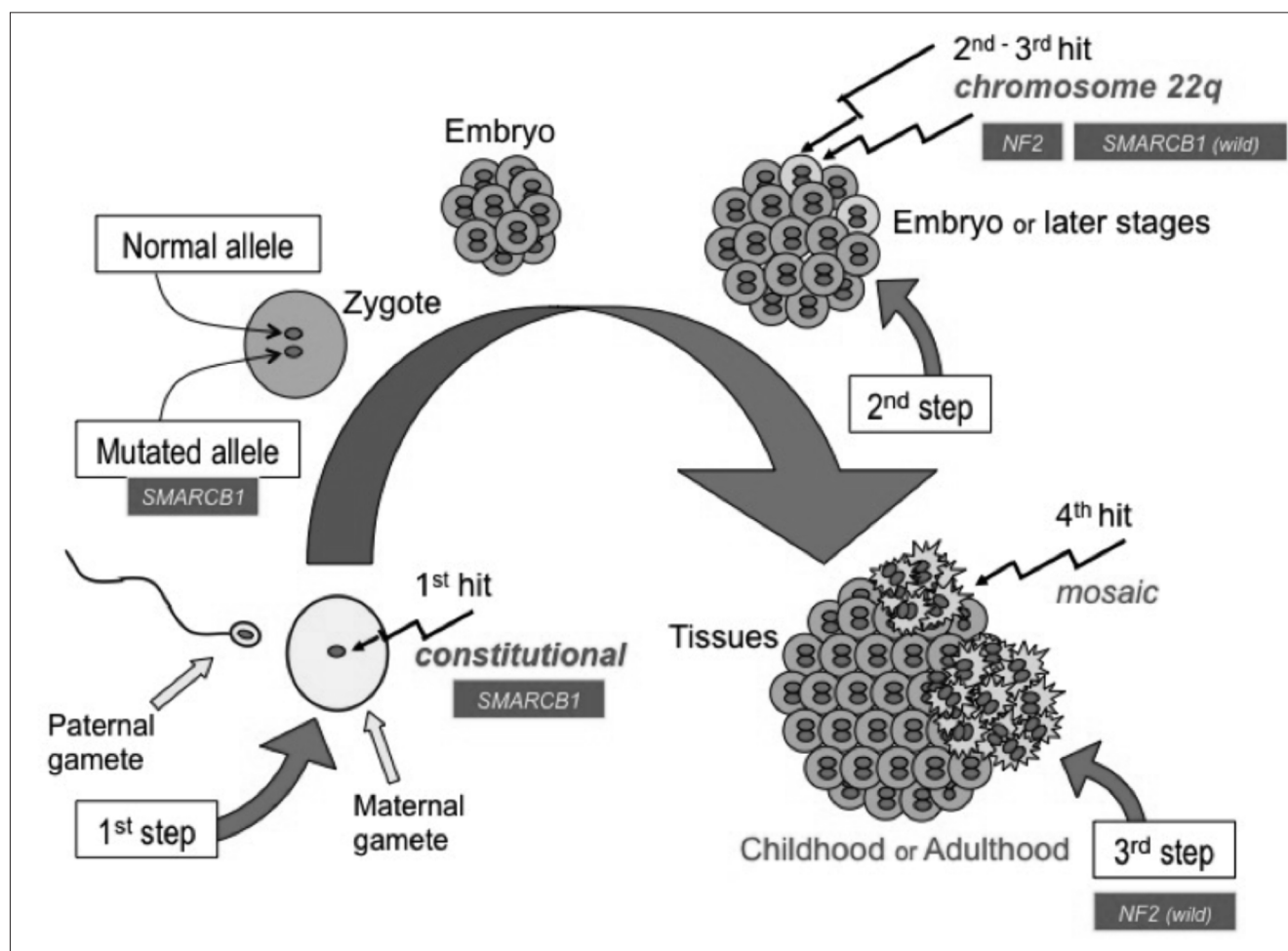


Fig. 12. The four hits-three steps model of tumorigenesis in schwannomatosis [in the Fig. the SMARCB1 gene is represented, but the model is alike for the LZTR1 gene]: (1) during the first step the constitutive SMARCB1 gene is inactivated (1st hit); (2) in addition to the constitutional SMARCB1 mutation, a second step consists in the loss of chromosome 22q, or a segment of it, involving the two loci [i.e., the wild-type SMARCB1 gene and the constitutional NF2 gene] (2nd and 3rd hits); followed (3) by a somatic mutation of the remaining wild-type NF2 allele that constitutes the third step (4th hit) giving rise to the local growth of the schwannoma (from Ruggieri et al., 2015³⁶, adapted and modified).

centromeric to the SMARCB1 gene at 22q11.21, which encodes a member of the BTB-kelch superfamily: it localises exclusively to the Golgi network where it may help stabilize the Golgi complex. The SWNTS2 phenotype is characterised by a later onset of disease (i.e., 20-60 years) and schwannomas affecting various body regions including extremities, spinal cord, chest wall and subcutaneous regions. To complicate matters, vestibular schwannomas do occur at a low frequency in individuals with LZTR1 mutations⁶⁵.

Mosaic NF2 and schwannomatosis

As stated above, schwannomatosis is partially explained by mutations in the SMARCB1 gene. Approximately 10-15% of patients with schwannomatosis have a family history, while the remaining 85-90% have sporadic disease. About 40-50% of familial schwannomatosis, and less than 10% of sporadic patients, have an identifiable SMARCB1

mutation⁶⁰⁻⁶². The other gene, LZTR1, has been recently reported to be mutated in ~80% of schwannomatosis patients negative for SMARCB1 mutation with evidence of a four hit mechanism⁶³. However, further research has shown that a substantial portion of schwannomatosis remains unexplained by LZTR1⁶⁴⁻⁶⁵. Schwannomas from SMARCB1 positive patients follow a four-hit, three-step model of tumorigenesis (Fig. 12) in which both alleles of SMARCB1 and NF2 genes are inactivated in the tumour⁶⁰⁻⁶⁶. In addition to the constitutive SMARCB1 mutation, a second step consists in the loss of chromosome 22q, or a segment of it, involving the two loci, followed by a somatic mutation of the remaining wild-type NF2 allele that constitutes the third step and the four hit. The four-hit, three-step model is also present in schwannomas from LZTR1 patients, involving LZTR1 and NF2 genes. There is a phenotypic overlap among patients that are mosaic NF2 and patients with sporadic schwannomatosis, consisting of the presence of

multiple non-vestibular nerve schwannomas. The sensitivity of blood genetic analysis is challenged in these situations and the histopathological features of schwannomas in either condition (i.e., NF2, schwannomatosis and mosaic NF2) are very similar. Recently⁶⁶, an adult patient with only multiple schwannomas in a single body segment (i.e., her leg) - thus, entirely fulfilling the diagnostic criteria for schwannomatosis - was demonstrated to harbour a double hit inactivation of the NF2 gene in two different schwannomas of the same body segment, demonstrating to be a true mosaic NF2 patient.

Diagnosis

Clinical criteria for the diagnosis of NF2 were first formulated at the National Institutes of Health (NIH) Consensus Conference on NF1 and NF2 in 1987⁶⁷ and revised in 1990⁶⁸. These criteria emphasised the presence of bilateral VSs in a high percentage of NF2 patients (Table I). Alternatively, patients could qualify for a diagnosis of NF2 with a family history of NF2 and either unilateral VS or any two other tumours typically associated with NF2 (Table I). Under NIH criteria, however, patients without bilateral VSs or a family history of NF2 cannot qualify for a diagnosis of

NF2. This was (and still is) particularly relevant for childhood NF2 whose initial presentation, and part of its natural history, progress without eight-nerve dysfunction and often lack affected members in the family tree.

Revised criteria were proposed by the Manchester group in 1992⁶⁹ and by the National Neurofibromatosis Foundation (NNFF) in 1997 (Table I)⁷⁰. The goal of these revisions was to improve the sensitivity for patients with features associated with NF2 but who did not reach formal NIH criteria. None of these criteria, however, can distinguish perfectly unaffected adults and children from those with NF2 and each has its strengths and weaknesses. Unfortunately, mutational analysis cannot replace clinical criteria for diagnosis of NF2 since a causative mutation cannot be identified still in a high percentage of affected NF2 children. The diagnostic work-up is further complicated by the occurrence of alternate forms within the spectrum of NF2: i.e., mosaic NF2, schwannomatosis and multiple meningiomas, even though either form is rare in the paediatric age.

Baser et al.^{71,72} attempted to encompass all the above problems by empirically developing and testing an improved set of diagnostic criteria⁷² that uses current understanding

Table I. Previous sets of diagnostic criteria for NF2.

NIH Criteria [1987] ⁶⁷	NIH Criteria [1991] ⁶⁸	Manchester Criteria [1992] ⁶⁹	NNFF Criteria [1997] ⁷⁰
<i>Patients who meet either condition A or B have NF2</i>	<i>Patients who meet either condition A or B have NF2</i>	<i>Patients who meet either condition A, condition B, condition C, or condition D have NF2</i>	<i>Patients who meet either condition A or B have NF2</i>
A. Bilateral vestibular schwannoma	A. Bilateral vestibular schwannoma	A. Bilateral vestibular schwannoma	A. Bilateral vestibular schwannoma
B. 1 st degree family relative with NF2 and either unilateral VS or any two of: neurofibroma, meningioma, glioma, schwannoma, or juvenile posterior subcapsular lens opacity	B. 1 st degree family relative with NF2 and either unilateral VS or any one of: neurofibroma, meningioma, glioma, schwannoma, or juvenile posterior subcapsular lens opacity	B. 1 st degree family relative with NF2 and either unilateral VS or any two of: neurofibroma, meningioma, glioma, schwannoma, or juvenile posterior subcapsular lens opacity C. Unilateral VS and any two of: neurofibroma, meningioma, glioma, schwannoma, or juvenile posterior subcapsular lens opacity D. Multiple meningiomas (≥ 2) and unilateral VS or any two of: neurofibroma, glioma, schwannoma, cataract	B. 1 st degree family relative with NF2 and either unilateral VS at < 30 years of age or any two of: meningioma, schwannoma, glioma, juvenile lens opacity (posterior subcortical cataract or cortical cataract)
Presumptive or probable NF2			<i>Patients who meet either condition C or D have probable NF2</i> C. Unilateral VS < 30 years of age and at least one of: meningioma, schwannoma, glioma, juvenile lens opacity D. Multiple meningiomas and either unilateral VS < 30 years of age or at least one of: schwannoma, glioma, juvenile lens opacity

Table II. The Baser criteria for diagnosis of NF2 [2011] ^{71 72}.

Feature	If present at or < age 30 years	If present > age 30 years
First-degree relative with NF2 diagnosed by these criteria	2	2
Unilateral vestibular schwannoma	2	1 ^a
Second vestibular schwannoma	4	3 ^a
One meningioma	2	1
Second meningioma (no additional points for > than 2 meningiomas)	2	1
Cutaneous schwannomas (one or more)	2	1
Cranial nerve tumour (excluding vestibular schwannoma) (one or more)	2	1
Mononeuropathy	2	1
Cataract (one or more)	2	0

The patient is given points as shown in the table.

^aPoints are not given for unilateral or second vestibular schwannoma if age at diagnosis is more than 70 yr.

• A diagnosis of definite NF2 is established if the total number of points is 6 or more.

• A diagnosis of definite NF2 is established if a constitutional pathogenic NF2 mutation is found on mutation testing.

• If no constitutional pathogenic NF2 mutation is found on mutation testing:

- A diagnosis of **mosaic NF2** is established if mosaicism for a pathogenic NF2 mutation is found in the blood or no detectable pathogenic NF2 mutation is found in the blood but the same pathogenic NF2 mutation is found in two separate NF2-associated tumours.

- Otherwise, a temporary diagnosis of **possible NF2** is made, pending further clarification. Clarification may occur if the patient is established to have a different condition (e.g., schwannomatosis or multiple meningiomas) by standard diagnostic criteria or if evolution of the patient's disease over time permits establishing a diagnosis of definite NF2 or mosaic NF2 according to the criteria given above.

of the natural history and genetic characteristics of NF2 to increase sensitivity while maintaining very high specificity (Table II): these criteria currently permit early diagnosis in a greater proportion of patients with NF2 than previous sets of diagnostic criteria ⁷².

Initial evaluation

Initial evaluation of children who have or are at risk for NF2 should include testing to confirm a diagnosis and to identify potential problems ¹⁹⁻³³.

A medical history should include questions about focal neurologic symptoms, skin tumours and/or cutaneous spots, seizures, headache, and visual symptoms as well as auditory and vestibular function. A family history should explore unexplained neurological and audiology symptoms in all first-degree relatives.

MRI scan of the brain should include gadolinium and include axial and coronal thin cuts (1-3 mm) through the brainstem to identify VSs ^{23 28 34}. MRI scan of the cervical spine should be performed given the predilection of ependymomas for this site and of meningiomas and/or schwannomas for the paravertebral regions ^{28 34}. Some clinicians recommend imaging of the thoracic and lumbar spine whereas others reserve these exams for patients with neurologic symptoms referable to these locations ^{2-4 19 28}.

Ophthalmologic examination serves to identify characteristic lesions such as lens opacities, retinal hamartomas, or epiretinal membranes ^{19 23 26 28}.

A complete neurological examination serves as a baseline for future comparison and may assist in the selection of sites within the nervous system that require further imaging studies.

Audiology (including pure tone threshold and word

recognition) and brainstem auditory evoked responses (BAER) document eighth cranial nerve dysfunction related to VSs and set a baseline for future comparisons. Abnormalities of pure tone thresholds are present in 90% of patients between 10 and 72 years with NF2. Word recognition serves as a measure of functional hearing. BAERs are a more sensitive measure of auditory function and is abnormal in 100% of patients with symptomatic VSs. In cases where the diagnosis is uncertain, biopsy of any skin lesion and review of any pathologic material may be helpful.

Follow-up

After initial diagnosis, children should be seen relatively frequently (every 3-6 months) until the growth rate and biologic behaviour of tumours is determined (this holds especially true in congenital NF2). Consultation with an experienced surgeon after initial diagnosis is often helpful for pre-symptomatic patients (i.e., those with adequate hearing) to discuss the feasibility of hearing-sparing surgery (see below). Most patients without acute problems can be followed on a 6-month to an annual basis. Evaluation at these visits should include complete neurological examination, MRI scan of the brain and spinal cord with thin cuts through the brainstem, MRI scans of symptomatic lesions outside the brain if present, audiology, and BAER. Ophthalmologic evaluation should be performed in selected patients with visual impairment or facial weakness. Yearly audiology serves to document changes in pure tone threshold and word recognition. This information can be helpful in planning early surgical intervention for VSs and in counselling patients about possible deafness. Changes in BAERs may precede hearing loss. The

frequency with which routine spinal imaging is obtained varies among clinics, but is clearly indicated in patients with new or progressive symptoms referable to the spinal cord. We prefer to obtain it at every MRI follow-up, unless there is no evidence of spinal tumours on first scan. In adulthood less frequent screening on a 3-5 yearly basis is warranted.

Classical management of childhood NF2

The approach to management of NF2-associated tumours has been always different from that of their sporadic counterparts. Because children (but also adults) with NF2 develop multiple cranial, spinal and peripheral nerve tumours, surgical removal of every lesion is not possible or advisable. Instead, the primary goal has been (and still is) to preserve function and to minimize quality of life.

Currently, despite frequent functional impairment, surgical removal remains the standard therapy for VSs (and for non-VSs nervous system tumours): indeed, patients undergoing surgery for VSs often experience iatrogenic hearing loss in the treated ear requiring rehabilitation through the use of a cochlear implant or an auditory brainstem implant (ABI). As an alternative or in addition to tumour removal, stereotactic irradiation and/or chemotherapy can be used to delay tumour progression, but it is thought to increase the risk for secondary malignancies in these patients. Moreover, radiation therapy frequently accelerates loss of hearing. Complete surgical resection is curative, but the timing for tumour removal is controversial, with a complex risk-benefit ratio, between risks of surgery and tumour's natural history.

Until the last decade, the above strategies were the sole therapeutic options for NF2-related vestibular schwannomas, and more in general for NF2-associated tumours: more recent biologically targeted therapies (see below) employing molecules driven from the increased knowledge of the molecular pathways involved in the pathogenesis of NF2 have been successfully employed in adult and paediatric patients with NF2. As these newer therapeutic options have been employed only very recently and in a limited number of NF2 children and are still under study here below, we will review the classical management options still employed worldwide.

Surgical strategies. The tumour load in childhood NF2 series^{6 14 15 20} is usually extensive and involves the skin, brain and spine.

Few NF2 children undergo resection of dermal tumours because of cosmetic burden^{23 28 34}; this is in line with the patterns of growth of peripheral schwannomas, which rarely are disfiguring at this young ages^{6 15 20}. Interestingly, resection of typical NF2-plaques is being asked for diagnostic clarification as in the paediatric population VSs are not apparent until older ages²⁸.

Surgery is clearly indicated for NF2 children with significant brainstem or spinal cord compression or with ob-

structive hydrocephalus. In patients with little or no neurological dysfunction related to their tumours, watchful waiting may allow children to retain neurological function for many years. For this reason, timing of intervention is often a difficult decision for patients and physicians.

A great number of NF2 children imaged have usually one or more extradural spinal masses compatible with schwannomas or meningiomas. Despite this extensive load of spinal nerve sheath tumours only rarely at these young ages these tumours indent the cord itself and require surgical removal because of progressive spinal cord impairment. Resection is usually successful in the majority of NF2 children with spinal tumours (usually ependymomas) without need of repeated neurosurgical intervention or regrowth^{23 28-30}. Conversely, pontine (and bulbar) tumours (usually, ependymomas and astrocytomas) most often need repeated partial resection with severe sequelae. According to our experience, the tumour burden in this location is high and changes the course of disease. As a general rule, indications for resection include rapid tumour growth and worsening neurologic symptoms. In contrast to what occur with brainstem tumours in NF1 (which are low grade astrocytomas, are often asymptomatic and have an indolent course with later tumour regression) these tumours' location in NF2 is associated with higher-grade histology, relentlessly progressive course and often a fatal outcome. However, the mere presence of an asymptomatic ependymoma should prompt a watch and wait policy as many remain indolent.

The decision to operate early on vestibular schwannomas or wait until symptoms or complete deafness ensue is difficult. Recent consensus proposed surgical resection of the largest tumours (> 3 cm in diameter) permitting facial nerve preservation and brainstem protection^{23 28}. There is no consensus for the management of VS less than 3 cm in diameter. Unresectable tumours and hearing impairment following surgery justify the introduction of new effective and safe therapies (see below). Surgical extirpation of VSs is usually accomplished using middle cranial fossa, posterior sub-occipital, and trans-labyrinthine approaches. The goal of pre-symptomatic surgery is retention of hearing with a minimum of post-operative complications such as facial weakness or dysphagia. In patients with a documented change in hearing, bony decompression of the internal auditory canal through a middle cranial fossa can stabilize hearing for a period of time. Pre-operative tumour size as an indicator of outcome in VSs surgery is still debated. A sub-occipital approach for small tumours can result in hearing preservation although precise numbers using this technique have not been published. Alternatively, a trans-labyrinthine approach with placement of an auditory brainstem implant (ABI) can provide auditory sensations in some patients. Children opting for this approach should be counselled that about 10% of patients do not receive auditory sensations, that ABI's do not provide

normal sound quality, that processor optimisation requires regular follow-up, and that maximal benefit is often not achieved for many years¹¹⁰. For most patients with ABI's, the primary benefit occurs when the implant is used in conjunction with lip reading. At the present time, little information is available about the efficacy of hearing sparing surgery in paediatric NF2 patients but outcomes appear to be inferior to that for adults.¹¹¹ A further option is cochlear nerve preserving surgery when the tumour is small via the translabarynthine approach and insertion of a cochlear implant that produces far superior results to ABI¹¹².

The decision to proceed with hearing-sparing surgery must be individualised for each patient. Options include observation without surgical intervention and hearing-sparing surgery; stereotactic radiation has not yielded comparable results for preservation of hearing (see below). For those with tumours that are multilobulated or greater than 1.5 cm in greatest dimension, the risk of peri-operative complications (including hearing loss and cranial nerve dysfunction) likely outweighs the potential benefits. In these patients, tumour resection should be deferred until another indication for surgery such as increased intracranial pressure, impending hydrocephalus, or new neurologic symptoms develops.

Indications for surgical resection of other (non-VSs) cranial nerve schwannomas are less well defined. In general, schwannomas of other cranial nerves are slow growing and produce few symptoms. Surgical resection in these patients should be reserved for those with unacceptable neurologic symptoms or rapid tumour growth.

Radiation therapy. Radiation is often used as adjuvant therapy for treatment of sporadic brain tumours. Treatment outcomes for (paediatric and adult) patients with NF2-related VSs are worse than for patients with sporadic tumours. In early studies of stereotactic radiosurgery, 18-20 Gy were delivered to tumours. Local control was achieved in 90% of patients but no serviceable hearing was preserved in patients with serviceable hearing pre-operatively. For this reason, the dose of radiation to the tumour margin was reduced to 12-16 Gy. Using modern regimens, treatment with stereotactic radiosurgery results in tumour control in 98% of patients with NF2 with preservation of useful hearing in 40-67%. Decreased facial and trigeminal function occurs in 5-16% and 10% of patients, respectively. The risk of deafness in patients with serviceable hearing pre-operatively is about 20%. More recently, fractionated stereotactic radiotherapy has been advocated to minimise the risk of hearing loss. The actuarial 5-year local control rate using this technique is 93% and the hearing-preservation rate is 64%. The use of radiation therapy for benign tumours in NF2 children must nonetheless be used with caution because of the greater risk of future tumour induction and malignant transformation⁸².

The role of adjuvant radiation in other tumours such as meningiomas and ependymomas is not established, but

the majority of these tumours demonstrate benign histology and can be controlled surgically. No case series have been published on treatment of NF2-related meningiomas. In general, treatment of sporadic tumours with stereotactic radiosurgery results in local control in 90-95% of cases. Peritumoural cerebral oedema develops in up to 25% of patients, but symptoms referable to cerebral oedema develop in less than 10% of patients.

Most clinicians prefer surgical extirpation of tumours when possible and reserve radiation treatment for tumours that are not surgically accessible. This practice is based on the experience that radiation therapy makes subsequent resection of VSs and function of ABI's more difficult. In addition, there are anecdotal reports of malignant transformation of NF2-associated schwannomas after radiation treatment and indirect evidence of increased numbers of malignancy in NF2 patients who have received radiation.

Chemotherapy. At the present time, there is no effective chemotherapy for treatment of NF2-related tumours. Sporadic meningiomas represent the best-studied tumour at the present time. Typically, patients with refractory or non-surgical tumours have been included in chemotherapy trials. Although some initial reports suggested efficacy of hydroxyurea in treating meningiomas, more recent reports do not support this view. Furthermore, there seems to be little role for use of tamoxifen or temozolomide for recurrent tumours. No trials of chemotherapy for treatment of vestibular schwannomas or ependymomas have been reported. Gene therapy remains a potential option for the future as injection of oncolytic recombinant herpes virus into schwannomas in mice results in significant tumour shrinkage.

NF2 patients who are managed at multidisciplinary specialty treatment centres have a significantly lower risk of mortality than those who are treated at non-specialty centres with higher rates of favourable outcome in VSs surgery and lower rates of serious complications with increasing surgical experience²⁷.

Genetic counselling. Individuals at risk for NF2 need genetic counselling and pre-symptomatic testing. Clinically, a normal MR image at 16 or 18 years reduces the chances of having inherited NF2. A normal MRI at 30 years makes inheritance very unlikely, except in late-onset families, and may justify cessation of formal screening¹¹³. Notably, most of our NF2 cases were sporadic and the earlier the onset of NF2 the lower the risk for siblings and parents.

As clinical and radiological screening cannot reassure at-risk individuals that they have not inherited the condition until 30 years of age, molecular genetic testing for NF2 has had a major impact on clinical practice²⁵. Constitutional mutation testing for NF2 is now available worldwide and mutations are found in about half the sporadic individuals tested but over 90% of families with vertical transmission⁴⁵. Identified mutations can be used for a pre-symptomatic testing and the latter is warranted even in children.

Biologically targeted pharmacological strategies in childhood NF2

Recently, following the studies on merlin pathway(s), different pharmacological strategies have been developed, in order to obtain tumour volumetric shrinkage and/or arrest of progression of tumours including a reduction in time to progression¹¹⁴. Given the complexity of the Merlin's pathway(s), different targets have been proposed¹¹⁵⁻¹²¹.

Antagonists of the ErbB family. Lapatinib, an antagonists of the Her1-2 members of the ErbB family of tyrosine kinase receptors, was clinically tested in NF2-patients, with volumetric regression of VSs and improvement of hearing, in 4 of 17 patients treated¹²²; however, patients

treated with another inhibitor of ErbB tyrosine kinase receptors, Erlotinib, did not experience tumour regression, even if in 27% of the cases there was a stabilisation of the disease¹²³.

Inhibitors of the mTOR pathway. The attempt to use mTOR pathway inhibition (i.e., Everolimus) did not yield appreciable results, with no patients (out of 9 enrolled) showing a volumetric response of the schwannomas, nor clear evidence of a stabilization of the disease¹²⁴.

Inhibitors of IGF1 receptor/PDGF/Akt/MEK. In vitro studies on the employment of different potential drugs have shown appreciable results, in particular with picropodophyllin, an anti-IGF1 receptor¹²⁵, OSU-03012, an Akt inhibitor¹²⁶, and nilotinib, a C-kit cascade inhibitor¹²⁷.

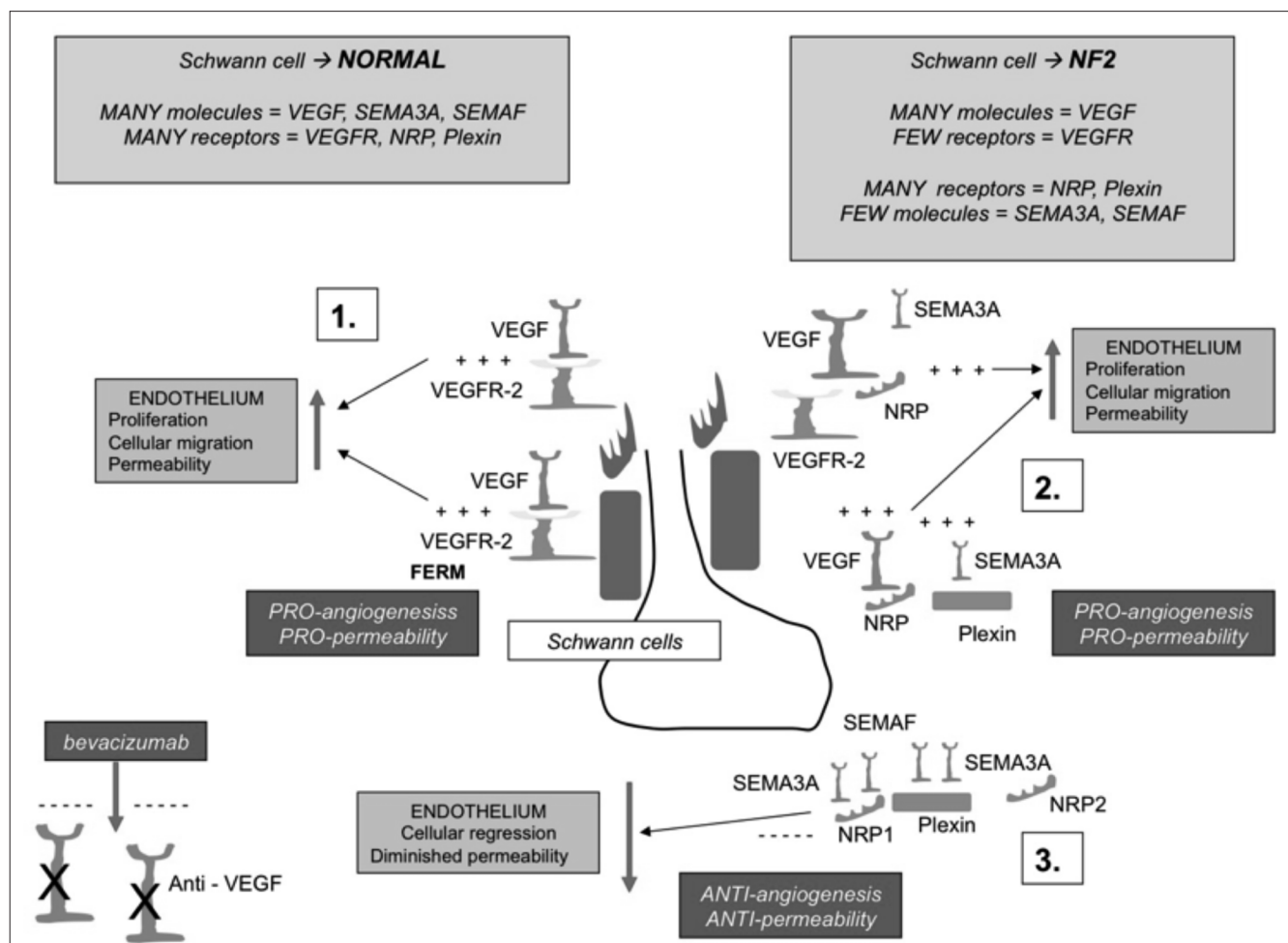


Fig. 13. VEGF/VEGFR signalling pathway in normal vs. NF2 Schwann cells [Avastin]: in normal Schwann cells VEGF (vascular endothelial growth factor), SEMA3A (semaphorin 3 A) and SEMAF (semaphorin F) molecules and VEGFR (VEGF receptors), NRP (neuropilin) and Plexin receptors are normally expressed; in NF2 Schwann cells VEGF are normally expressed vs. lower expressed VEGFR; in addition to that, in NF2 Schwann cells NRP and Plexin receptors are normally expressed vs. lower expressed SEMA3A and SEMAF molecules (see boxes). VEGF typically binds to VEGFR2 [Panel 1] inducing endothelial proliferation, migration and permeability; VEGF can also compete with SEMA3A to bind to Neuropilin (NRP) receptors directly or can form a bridge between VEGFR2 and NRP potentiating its signalling via VEGFR2 [Panel 2]; SEMA3A and SEMAF bind NRP1 and NRP2, respectively, to induce endothelial cell regression and diminished permeability [Panel 3]. Thus, Avastin [an anti-VEGF antibody], when administered in NF2 patients acts not only via VEGFR inhibition (as VEGFR are lower expressed in NF2 Schwann cells) but also because it displaces VEGF from binding to NRP and Plexin receptor, thus allowing SEMA3A and SEMAF to bind to these receptors inducing endothelial cell regression and diminished permeability [see Panel 3 (from Ruggieri et al., 2015³⁵ and Ruggieri et al., 2015³⁶, adapted and modified).

Table III. NF2 patients treated with bevacizumab in the literature (from Ruggieri et al., 2015³⁵ and Ruggieri et al., 2015³⁶, adapted and modified).

Author	Year	Total no.	Average age [Current]	Age range (years)	Sex	Median duration of Treatment	Hearing Response	Radiologic Response	Side effects
Plotkin et al	2009 & 2012	31	26	12-73	14 M 17 F	14 months	90% had stable or improved hearing after 1 year of treatment and 61% at 3 years	17/31 (55%) reduction in size of VS; 10/31 stable disease (32%). [87% of patients had stable or decreased tumour size after 1 year of treatment and 54% at 3 years]	50% menorrhagia and Irregular menstruation; 35% proteinuria and hypertension; 26% epistaxis; 23% fatigue and hyponatremia
Mautner et al	2010	2	31	23-39	2 M	1 year	1/2 improvement	2/2 volumetric reduction	Patient 1: slightly fatigue and epistaxis; Patient 2 hypertension
Eminowicz et al	2012	2	34	31-37	1 M 1 F	Case 1 18 weeks; Case 2 > 16 weeks	2/2 improvement	2/2 volumetric reduction	NR
Riina et al [Intra-arterial infusion]	2012	3	39.7	31-56	2 M 1 F	1 day	NA	Patient 1: Reduction 11 and 19% of VSs; Patient 2: stable disease; Patient 3: stable disease	None
Subbiah et al [Total 6 patients; 4 treated with BEV]	2012	4	30	16-41	2 M 2 F	(4-10+ months)	3/4 stable disease; 1/4 improvement	3/4 stable disease; 1/4 33% tumour shrinkage	2/4 proteinuria and hyperlipidemia
Hawasli et al [Total 10 patients; 5 affected by NF2 and treated with BEV]	2013	5	22,8	14-38	NR	11 months	2/5 stable disease; 3/5 improvement	4/5 stable; 1/5 volumetric reduction	2/5 hypertensions; 1/5 epistaxis; 1/5 weight loss; 1/5 abdominal pain and diarrhea; 1/5 chest pain
Nunes et al [Meningiomas; Same patients of Plotkin 2012]	2013	15	29.5	16-63	7 M 8 F	18 months	NA	29% (14/48 meningiomas); volumetric radiographic response; median time to progression was 15 months. Median duration of response was 3.7 months	4 grade 3 adverse events (hypertension, elevated liver enzymes, menorrhagia, irregular menses) and 2 grade 4 events (delayed wound healing)
Alanin et al	2014	12	34	23-78	5 M 7 F	22 months (range 7-34)	5/12 subjective benefit; 3/12 objective benefit	6/12 radiologic response	92% fatigue; 71% oligomenorrhea; 67% proteinuria; 33% hypertension; 17% epistaxis; one patient presented cerebral haemorrhage (fatal event)
Farschtschi et al [reduced dosage; 5 to 2.5 mg]	2015	3	28.3	22-38	2 M 1 F	66-76 months	3/3 hearing improvement	3/3 radiologic response	Hypertension 3/3; proteinuria 2/3; The side effects ceased after treatment reduction to 2.5 mg/g
Hochart et al	2015	7	15	11.4-18.8	3 M 4 F	11.3 months (range 3.2-55.6)	3/7 stable; 3/7 Non eligible; 1/7 improvement	3/7 shrinkage; 2/7 Reduction of growth rate; 1/7 stable disease	1/7 severe hypertension and proteinuria; 1/7 osteomyelitis; 1/7 epistaxis; 1/7 inter-mensual bleeding; 1/7 malaise
Morris KA et al	2016	61	25	10-57	36 M 25 F	23 months (range 3-53)	Hearing stabilisation or improvement in 86%	Partial volumetric tumour response (all tumours) was in 39% and stabilisation in 51%	Hypertension in 30% and proteinuria in 16%. 12/61 treatment breaks.

Legend: BEV = Bevacizumab; NR = Not reported; NA = Not available; VS = Vestibular schwannoma

Imatinib, a PDGF inhibitor¹²⁸, has also been employed in a NF2 patient¹²⁹. Even if preliminary results were appreciable, the treatment was suspended after only 4 months for severe adverse reactions, including headache, vomiting, abdominal pain and increased unsteadiness. Sorafenib, which acts by inhibiting C-kit, PDGF and MEK1-2 system, was employed in a single patient and afterward suspended because of the appearance of a rash¹³⁰.

Anti-VEGF antibodies. Bevacizumab, a monoclonal antibody directed against anti-vascular endothelial growth factor (VEGF) has shown the most promising results in terms of tumour volume shrinkage, stabilisation of the disease and hearing improvement, since its first employment by Plotkin et al, at the dose of 5 mg/kg/biweekly (Fig. 13)¹³¹. Even if associated with different side effects (including haemorrhage, delayed wound healing, proteinuria and hypertension)¹³² it is by and large extremely well tolerated in NF2 patients¹³³. Bevacizumab has demonstrated its efficacy in the treatment of VSs^{129 131 134}, with a stable or improved hearing in 90% of patients after 1 year and 61% after 3 years¹³⁵; a stable or decreased tumour volume was observed in 88% of patients after 1 year of treatment and in 54% at 3 years. The same usefulness was not demonstrated in the meningiomas of the same cohort of NF2 patients^{135 136}: a volumetric response was observed in 29% and the median duration of the response was 3.7 months and a median time to progression of 15 months. Among the 10 patients affected by non-malignant brain tumours and treated with anti-VEGF therapy enrolled by Hawasli et al.¹³⁶, six were affected by NF2: 5 were treated with bevacizumab, and one with pazopanib, a pleiotropic tyrosine kinase receptor inhibitor, which inhibits also the angiogenesis. All the six NF2 patients showed benefits from anti-VEGF, while among the non-NF2 patients, two (affected by recurrent meningiomas) continued to present tumour growth after VEGF therapy.

Subbiah et al.¹²⁹ demonstrated the utility of a combined treatment with bevacizumab and temsirolimus, an mTOR inhibitor, in two patients: one of them had a 33% volumetric response in size, while the other presented a stable disease.

A radiological response was observed in 7 of 18 tumours (39%) of the 12 patients enrolled by Alanin et al.¹³⁷, with a continued response (for more than 2 months) in 6/18 (33%). Three patients (25%) showed an objective hearing improvement and five (41.7%) reported subjective benefit in neurological symptoms, including improved hearing.

Anti-VEGF in the paediatric age (Table III) (Fig. 13). Among the seven children and teenagers affected by NF2 (median age 15 years) treated by Hochart et al.¹³⁸, one showed a tumour regression of more than 20%, two a tumour shrinkage between 5 and 19% and the other four showed a decreased tumour growth. A hearing benefit was showed in 1 out of 4 patients eligible for audiometric evaluation, while the others presented a stable disease¹³⁸. Severe adverse (hypertension and osteitis) events were registered

in two patients, who had to discontinue treatment; another patient needed a reduction of the doses after recurrent episodes of epistaxis, while another experienced a grade 2 inter-menstrual bleeding. Six children with NF2 with 8 evaluable VS had significantly poorer responses to bevacizumab than 51 adults in a large multi-institution study¹³³. Other smaller groups of NF2-related tumours have been treated with bevacizumab. These studies have demonstrated that a reduced dose bevacizumab treatment to 2.5 mg bi- or tri-weekly, also if prolonged for 66-76 months, could still provide a clinically stable, radiographic and audiology sustained response¹³⁹, that tumour shrinkage can be more than 40%¹⁴⁰, and that bevacizumab can also be effective in patients previously unsuccessfully treated with gamma knife radiotherapy¹⁴¹. Moreover, a super-selective intra-arterial cerebral infusion of bevacizumab was reported in 3 patients has showed a likely efficacy, with one patient presenting a decreased tumour volume and two showing a stable disease¹⁴².

Mortality in NF2 and in NF2 children

Overall, patients with NF2 have diminished lifespan compared to non-affected family members^{106 107 143} with overall 5-, 10-, and 20-years survival rates after diagnosis of 85%, 67% and 38%, respectively¹³⁷. Early age at diagnosis and the presence of intracranial meningiomas are usually associated with increased mortality, and having a mosaic, rather than non-mosaic, NF2 mutation is associated with reduced mortality¹⁰⁶. The most frequent causes of death include tumour burden, peri-operative complications, and malignancy from NF2-related tumour^{28 107 143}. A decreased risk of mortality is associated with treatment at a specialty medical centre and with splice-site or missense mutations vs. truncating mutations [patients with splice-site mutations in exons 6-15 have lower mortality than patients with splice-site mutations in exons 1-5]. Notably, the overall mortality of children and adults with NF2 diagnosed in more recent decades is lower than that of patients diagnosed earlier^{28 106}.

References

- Huson SM, Hughes RAC. *The Neurofibromatoses*. A Pathogenetic and Clinical Overview. London: Churchill Livingstone, 1994.
- Evans DG. *Neurofibromatosis type 2 (NF2): a clinical and molecular review*. Orphanet J Rare Dis 2009;4:16.
- Asthagiri AR, Parry DM, Butman JA, et al. *Neurofibromatosis type 2*. Lancet 2009;373:1974-86.
- Evans DG. *Neurofibromatosis 2 Bilateral acoustic neurofibromatosis, central neurofibromatosis, NF2, neurofibromatosis type II*. Genet Med 2009;11:599-610.
- Wishart JH. *Case of tumours in the skull, dura mater, and brain*. Edinburgh Med Surg J 1822;18:393-7.
- Gardner WJ, Frazier CH. *Hereditary bilateral acoustic tumors*. J Hered 1933;22:7-8.

- 7 Gardner WJ, Turner O. *Bilateral acoustic neurofibromas: further clinical and pathologic data on hereditary deafness and Recklinghausen's disease.* Arch Neurol Psychiatr 1940;44:76-99.
- 8 Young DF, Eldridge R, Gardner WJ. *Bilateral acoustic neuroma in a large kindred.* JAMA 1970;214:347-53.
- 9 Seizinger BR, Martuza RL, Gusella JF. *Loss of genes on chromosome 22 in tumorigenesis of human acoustic neuroma.* Nature 1986;322:644-7.
- 10 Rouleau GA, Merel P, Lutchman M, et al. *Alteration in a new gene encoding a putative membrane-organizing protein causes neurofibromatosis type 2.* Nature 1993;363:515-21.
- 11 Trofatter JA, MacCollin MM, Rutter JL, et al. *A novel moesin-, ezrin-, radixin-like gene is a candidate for the neurofibromatosis 2 tumor suppressor.* Cell 1993;72:791-800.
- 12 Evans DG, Huson SM, Donnai D, et al. *A genetic study of type 2 neurofibromatosis in the United Kingdom. I. Prevalence, mutation rate, fitness, and confirmation of maternal transmission effect on severity.* J Med Genet 1992;29:841-6.
- 13 Evans DG, Huson SM, Donnai D, et al. *A genetic study of type 2 neurofibromatosis in the United Kingdom. II. Guidelines for genetic counselling.* J Med Genet 1992;29:847-52.
- 14 Parry DM, Eldridge R, Kaiser-Kupfer MI, et al. *Neurofibromatosis type 2 (NF2): Clinical characteristics of 63 affected individuals and clinical evidence for heterogeneity.* Am J Med Genet 1994;52:450-61.
- 15 Mautner VF, Baser ME, Takkar SD, et al. *Vestibular schwannoma growth in patients with neurofibromatosis type 2: a longitudinal study.* J Neurosurg 2002;96:223-28.
- 16 Ragge NK, Baser ME, Riccardi VM, et al. *The ocular presentation of neurofibromatosis 2.* Eye (Lond) 1997;11:12-8.
- 17 Mautner VF, Lindenau M, Baser ME, et al. *Skin abnormalities in neurofibromatosis type 2.* Arch Dermatol 1997;133:1539-43.
- 18 Eldridge R, Parry DM, Kaiser-Kupfer MI. *Neurofibromatosis 2 (NF2): clinical heterogeneity and natural history based on 39 individuals in 9 families and 16 sporadic cases.* Am J Hum Genet 1991;49:A133.
- 19 Ruggieri M. *The different forms of neurofibromatosis.* Child's Nerv Syst 1999;15:295-308.
- 20 Mautner VF, Tatagiba M, Guthoff R, et al. *Neurofibromatosis type 2 in the paediatric age group.* Neurosurgery 1993;33:92-6.
- 21 MacCollin M, Bove C, Kluwe L et al. *The natural history of neurofibromatosis 2 in 31 affected children.* Ann Neurol 1996;44:A576.
- 22 MacCollin M, Mautner VF. *The diagnosis and management of neurofibromatosis type 2 in childhood.* Semin Pediatr Neurol 1998;5:243-52.
- 23 Evans DGR, Birch JM, Ramsden RT. *Paediatric presentation of type 2 neurofibromatosis.* Arch Dis Child 1999;81:496-9.
- 24 Ruggieri M, Huson SM. *Clinical presentations of neurofibromatosis type 2 in childhood.* Eur J Pediatr Neurol 1999;3:A66.
- 25 Huson SM, Ruggieri M. *The various presentations of neurofibromatosis type 2 (NF2) in childhood.* J Med Genet 1999;36:S6926.
- 26 Ruggieri M, Polizzi A, Rampello L, et al. *Neurofibromatosis type 2 (NF2) in childhood.* NeurolSci 2000;21:356.
- 27 Nunes F, MacCollin M. *Neurofibromatosis type 1 in the pediatric population.* J Child Neurol 2002;18:718-724.
- 28 Ruggieri M, Iannetti P, Polizzi A, et al. *Earliest clinical manifestations and natural history of neurofibromatosis type 2 (NF2) in childhood: a study of 24 patients.* Neuropediatrics 2005;36:21-34.
- 29 Rushing EJ, Olsen C, Mena H, et al. *Central nervous system meningiomas in the first two decades of life: a clinicopathological analysis of 87 patients.* J Neurosurg 2005;103:489-95.
- 30 Bosch MM, Boltshauser E, Harpes P, et al. *Ophthalmologic findings and long-term course in patients with neurofibromatosis type 2.* Am J Ophthalmol 2006;141:1068-77.
- 31 Pascual-Castroviejo I, Pascual-Pascual SI, Viaño J. *Neurofibromatosis type 2. A study of 7 patients.* Neurologia 2009;24:457-61.
- 32 Matsuo M, Ohno K, Ohtsuka F. *Characterization of early onset neurofibromatosis type 2.* Brain Dev 2014;36:148-52.
- 33 Choi JW, Lee JY, Phi JH, et al. *Clinical course of vestibular schwannoma in pediatric neurofibromatosis Type 2.* J Neurosurg Pediatr 2014;13:650-7.
- 34 Ruggieri M, Gabriele AL, Polizzi A, et al. *Natural history of neurofibromatosis type 2 with onset before the age of 1 year.* Neurogenetics 2013;14:89-98.
- 35 Ruggieri M, Praticò AD, Evans DG. *Diagnosis, management, and new therapeutic options in childhood neurofibromatosis type 2 and related forms.* Semin Pediatr Neurol 2015;22:240-58.
- 36 Ruggieri M, Praticò AD, Muglia M, et al. *Biochemical insights into Merlin/NF2 pathophysiology and biologically targeted therapies in childhood NF2 and related forms.* J Ped Biochem 2015;5:120-30.
- 37 MacCollin M, Ramesh V, Jacoby LB, et al. *Mutational analysis of patients with neurofibromatosis 2.* Am J Hum Genet 1994;55:314-20.
- 38 Kluwe L, Mautner VF. *A missense mutation in the NF2 gene results in moderate and mild clinical phenotypes of neurofibromatosis type 2.* Hum Genet 1996;97:224-7.
- 39 Kluwe L, Mautner VF. *Mosaicism in sporadic neurofibromatosis 2 patients.* Hum Mol Genet 1998;7:2051-5.
- 40 Evans DG, Wallace AJ, Wu CL, et al. *Somatic mosaicism: a common cause of classic disease in tumor-prone syndromes? Lessons from type 2 neurofibromatosis.* Am J Hum Genet 1998;63:727-76.
- 41 Ruggieri M, Huson SM. *The neurofibromatoses. An overview.* NeurolSci 1999;20:89-108.
- 42 Ruggieri M, Polizzi A. *Segmental neurofibromatosis.* J Neurosurg 2000;93:530-32.
- 43 Ruggieri M. *Mosaic (segmental) neurofibromatosis type 1 (NF1) and type 2 (NF2) – no longer neurofibromatosis type 5.* Am J Med Genet 2001;101:178-80.
- 44 Ruggieri M, Huson S. *The clinical and diagnostic implications of mosaicism in the neurofibromatosis.* Neurology 2001;56:1433-43.
- 45 Kluwe L, Mautner V, Heinrich B, et al. *Molecular study of frequency of mosaicism in neurofibromatosis 2 patients with bilateral vestibular schwannomas.* J Med Genet 2003;40:109-14.
- 46 Evans DG, Ramsden RT, Shenton A, et al. *Mosaicism in neurofibromatosis type 2: an update of risk based on uni/bilat-*

- erality of vestibular schwannoma at presentation and sensitive mutation analysis including multiple ligation-dependent probe amplification. *J Med Genet* 2007;44:424-28.
- 47 Evans DG, Ramsden RT, Shenton A et al. *What are the implications in individuals with unilateral vestibular schwannoma and other neurogenic tumors?* *J Neurosurg* 2008;108:92-6.
- 48 Evans DG, Wallace A. *An update on age related mosaic and offspring risk in neurofibromatosis 2 (NF2).* *J Med Genet* 2009;46:792.
- 49 Evans DG, Bowers N, Huson SM, et al. *Mutation type and position varies between mosaic and inherited NF2 and correlates with disease severity.* *Clin Genet* 2013;83:594-95.
- 50 Evans DG, Freeman S, Gokhale C, et al. *Bilateral vestibular schwannomas in older patients: NF2 or chance?* *J Med Genet* 2015;52:422-24.
- 51 Ruggieri M, Praticò AD. *Mosaic neurocutaneous disorders and their causes.* *Semin Pediatr Neurol* 2015;22:207-33.
- 52 Niimura M. *Neurofibromatosis.* *Rinsho Derma* 1973;15:653-63.
- 53 Jacoby LB, Jones D, Davis K, et al. *Molecular analysis of the NF2 tumor-suppressor gene in schwannomatosis.* *Am J Hum Genet* 1997;61:1293-302.
- 54 Antinheimo J, Sankila R, Carpen O, et al. *Population-based analysis of sporadic and type 2 neurofibromatosis-associated meningiomas and schwannomas.* *Neurology* 2000;54:71-6.
- 55 MacCollin M, Chiocca EA, Evans DG, et al. *Diagnostic criteria for schwannomatosis.* *Neurology* 2005;64:1838-45.
- 56 MacCollin M, Woodfin W, Kronn D, et al. *Schwannomatosis: a clinical and pathologic study.* *Neurology* 1996;46:1072-9.
- 57 Baser ME, Friedman JM, Evans DG. *Increasing the specificity of diagnostic criteria for schwannomatosis.* *Neurology* 2006;66:730-2.
- 58 Smith MJ, Kulkarni A, Rustad C, et al. *Vestibular schwannomas occur in schwannomatosis and should not be considered an exclusion criterion for clinical diagnosis.* *Am J Med Genet A* 2012;158A:215-9.
- 59 Plotkin SR, Blakeley JO, Evans DG, et al. *Update from the 2011 International Schwannomatosis Workshop: from genetics to diagnostic criteria.* *Am J Med Genet A* 2013;161A:405-16.
- 60 Hulsebos TJ, Plomp AS, Wolterman RA, et al. *Germline mutation of INI1/SMARCB1 in familial schwannomatosis.* *Am J Hum Genet* 2007;80:805-10.
- 61 Sestini R, Bacci C, Provenzano A, et al. *Evidence of a four-hit mechanism involving SMARCB1 and NF2 in schwannomatosis-associated schwannomas.* *Hum Mutat* 2008;29:227-31.
- 62 Hadfield KD, Newman WG, Bowers NL, et al. *Molecular characterisation of SMARCB1 and NF2 in familial and sporadic schwannomatosis.* *J Med Genet* 2008;45:332-39.
- 63 Piotrowski A, Xie J, Liu YF, et al. *Germline loss-of-function mutations in LZTR1 predispose to an inherited disorder of multiple schwannomas.* *Nat Genet* 2014;46:182-7.
- 64 Paganini I, Chang VY, Capone GL, et al. *Expanding the mutational spectrum of LZTR1 in schwannomatosis.* *Eur J Hum Genet* 2015;23:963-8.
- 65 Smith MJ, Isidor B, Beetz C, et al. *Mutations in LZTR1 add to the complex heterogeneity of schwannomatosis.* *Neurology* 2015;84:141-7.
- 66 Castellanos E, Bielsa I, Carrato C, et al. *Segmental neurofibromatosis type 2: discriminating two hit from four hit in a patient presenting multiple schwannomas confined to one limb.* *MC Med Genomics* 2015;8:2.
- 67 National Institutes of Health Consensus Development Conference Statement. *Neurofibromatosis.* *Arch Neurol* 1988;45:575-8.
- 68 Mulvihill JJ, Parry DM, Sherman JL, et al. *NIH conference. Neurofibromatosis 1 (Recklinghausen disease) and neurofibromatosis 2 (bilateral acoustic neurofibromatosis). An update.* *Ann Intern Med* 1990;113:39-52.
- 69 Evans DG, Huson SM, Donnai D, et al. *A clinical study of type 2 neurofibromatosis.* *Q J Med J* 1992;304:603-18.
- 70 Gutmann DH, Aylsworth A, Carey JC, et al. *The diagnostic evaluation and multidisciplinary management of neurofibromatosis 1 and neurofibromatosis 2.* *JAMA* 1997;278:51-3.
- 71 Baser ME, Friedman JM, Wallace AJ, et al. *Evaluation of clinical diagnostic criteria for neurofibromatosis 2.* *Neurology* 2002;59:1759-65.
- 72 Baser ME, Friedman JM, Joe H, et al. *Empirical development of improved diagnostic criteria for neurofibromatosis 2.* *Genet Med* 2011;13:576-81.
- 73 Stivaros SM, Stemmer-Rachamimov AO, Alston R, et al. *Multiple synchronous sites of origin of vestibular schwannomas in neurofibromatosis Type 2.* *J Med Genet* 2015;52:557-62.
- 74 Curto M, McClatchey A. *Nf2/Merlin: a coordinator of receptor signalling and intercellular contact.* *Brit J Cancer* 2008;98:256-62.
- 75 Cheng JQ, Lee WC, Klein MA, et al. *Frequent mutations of NF2 and allelic loss from chromosome band 22q12 in malignant mesothelioma: evidence for a two-hit mechanism of NF2 inactivation.* *Genes Chromosomes Cancer* 1999;24:238-42.
- 76 Bianchi AB, Hara T, Ramesh V, et al. *Mutations in transcript isoforms of the neurofibromatosis 2 gene in multiple human tumour types.* *Nat Genet* 1994;6:185-92.
- 77 Sher I, Hanemann CO, Karplus PA, et al. *The tumor suppressor merlin controls growth in its open state, and phosphorylation converts it to a less-active more-closed state.* *Dev Cell* 2012;22:703-5.
- 78 Schroeder RD, Angelo LS, Kurzrock R. *NF2/merlin in hereditary neurofibromatosis 2 versus cancer: biologic mechanisms and clinical associations.* *Oncotarget* 2014;5:67-77
- 79 McClatchey AI, Fehon RG. *Merlin and the ERM proteins-regulators of receptor distribution and signaling at the cell cortex.* *Trends Cell Biol* 2009;19:198-206.
- 80 Surace EI, Haipek CA, Gutmann DH. *Effect of merlin phosphorylation on neurofibromatosis 2 (NF2) gene function.* *Oncogene* 2004;23:580-7.
- 81 Lallemand D, Saint-Amaux AL, Giovannini M. *Tumor-suppression functions of merlin are independent of its role as an organizer of the actin cytoskeleton in Schwann cells.* *J Cell Sci* 2009;122:4141-9.
- 82 Cooper J, Giancotti FG. *Molecular insights into NF2/Merlin tumor suppressor function.* *FEBS Lett* 2014;588:2743-52.
- 83 Ahronowitz I, Xin W, Kiely R, et al. *Mutational spectrum of the NF2 gene: a meta-analysis of 12 years of research and diagnostic laboratory findings.* *Hum Mutat* 2007; 28:1-12.
- 84 de Vries M, van der Mey AG, Hogendoorn PC. *Tumor biology of vestibular schwannoma: a review of experimental*

- data on the determinants of tumor genesis and growth characteristics. *OtolNeurotol* 2015;36:1128-36.
- ⁸⁵ Li W, You L, Cooper J, et al. *Merlin/NF2 suppresses tumorigenesis by inhibiting the E3 ubiquitin ligase CRL4(DCAF1) in the nucleus.* *Cell* 2010;140:477-90.
- ⁸⁶ Alftan K, Heiska L, Grönholm M, et al. *Cyclic AMP-dependent protein kinase phosphorylates merlin at serine 518 independently of p21-activated kinase and promotes merlin-ezrinheterodimerization.* *J Biol Chem* 2004;279:18559-66.
- ⁸⁷ Kim HA, DeClue JE, Ratner N. *cAMP-dependent protein kinase A is required for Schwann cell growth: interactions between the cAMP and neuregulin/tyrosine kinase pathways.* *J Neurosci Res* 1997;49:236-47.
- ⁸⁸ Rong R, Tang X, Gutmann DH, Ye K. *Neurofibromatosis 2 (NF2) tumor suppressor merlin inhibits phosphatidylinositol 3-kinase through binding to PIKE-L.* *Proc Natl Acad Sci U S A* 2004;101:18200-5.
- ⁸⁹ Rong R, Surace EI, Haipek CA, et al. *Serine 518 phosphorylation modulates merlin intramolecular association and binding to critical effectors important for NF2 growth suppression.* *Oncogene* 2004;23:8447-54.
- ⁹⁰ Jin H, Sperka T, Herrlich P, Morrison H. *Tumorigenic transformation by CPI-17 through inhibition of a merlin phosphatase.* *Nature* 2006;442:576-9.
- ⁹¹ Lallemand D, Curto M, Saotome I, et al. *NF2 deficiency promotes tumorigenesis and metastasis by destabilizing adherens junctions.* *Genes Dev* 2003;17:1090-100.
- ⁹² Yi C, Troutman S, Fera D, et al. *A tight junction-associated Merlin-angiotonin complex mediates Merlin's regulation of mitogenic signaling and tumor suppressive functions.* *Cancer Cell* 2011;19:527-40.
- ⁹³ Stickney JT, Bacon WC, Rojas M, et al. *Activation of the tumor suppressor merlin modulates its interaction with lipid rafts.* *Cancer Res* 2004;64:2717-24.
- ⁹⁴ Mani T, Hennigan RF, Foster LA, et al. *FERM domain phosphoinositide binding targets merlin to the membrane and is essential for its growth-suppressive function.* *Mol Cell Biol* 2011;31:1983-96.
- ⁹⁵ Brault E, Gautreau A, Lamarine M, et al. *Normal membrane localization and actin association of the NF2 tumor suppressor protein are dependent on folding of its N-terminal domain.* *J Cell Sci* 2001;114:1901-12.
- ⁹⁶ Hennigan RF, Moon CA, Parysek LM, et al. *The NF2 tumor suppressor regulates microtubule-based vesicle trafficking via a novel Rac, MLK and p38(SAPK) pathway.* *Oncogene* 2013;32:1135-43.
- ⁹⁷ Yu C, Zhang YL, Pan WW, et al. *CRL4 complex regulates mammalian oocyte survival and reprogramming by activation of TET proteins.* *Science* 2013;342:1518-21.
- ⁹⁸ Pan D. *The hippo signaling pathway in development and cancer.* *Dev Cell.* 2010;19:491-505.
- ⁹⁹ Johnson R, Halder G. *The two faces of Hippo: targeting the Hippo pathway for regenerative medicine and cancer treatment.* *Nat Rev Drug Discov* 2014;13:63-79.
- ¹⁰⁰ Chan SW, Lim CJ, Chong YF, et al. *Hippo pathway-independent restriction of TAZ and YAP by angiotonin.* *J Biol Chem* 2011;286:7018-26.
- ¹⁰¹ Li Y, Zhou H, Li F, et al. *Angiotonin binding-induced activation of Merlin/NF2 in the Hippo pathway.* *Cell Res* 2015;25:801-17.
- ¹⁰² Selvanathan SK, Shenton A, Ferner R, et al. *Further Genotype-phenotype correlations in neurofibromatosis type 2.* *Clin Genet* 2010;77:163-70.
- ¹⁰³ Smith MJ, Higgs JE, Bowers NL, et al. *Cranial meningiomas in 411 neurofibromatosis type 2 (NF2) patients with proven gene mutations: clear positional effect of mutations, but absence of female severity effect on age at onset.* *J Med Genet* 2011;48:261-5.
- ¹⁰⁴ Evans DGR, Trueman L, Wallace A, et al. *Genotype phenotype correlations in NF2: evidence for more severe disease associated with truncating mutations.* *J Med Genet* 1998;35:450-5.
- ¹⁰⁵ Baser ME, Kuramoto L, Woods R, et al. *The location of constitutional neurofibromatosis 2 (NF2) splice-site mutations is associated with the severity of NF2.* *J Med Genet* 2005;42:540-6.
- ¹⁰⁶ Hexter A, Jones A, Joe H, et al. *English Specialist NF2 Research Group, Friedman JM, Evans DG. Clinical and molecular predictors of mortality in neurofibromatosis 2: a UK national analysis of 1192 patients.* *J Med Genet* 2015;52:699-75.
- ¹⁰⁷ Baser ME, Friedman JM, Aeschliman D, et al. *Predictors of the risk of mortality in neurofibromatosis 2.* *Am J Hum Genet* 2002;71:715-23.
- ¹⁰⁸ van den Munckhof P, Christiaans I, et al. *Germline SMARCB1 mutation predisposes to multiple meningiomas and schwannomas with preferential location of cranial meningiomas at the falx cerebri.* *Neurogenetics* 2012;13:1-7.
- ¹⁰⁹ Hadfield KD, Smith MJ, Trump D, et al. *SMARCB1 mutations are not a common cause of multiple meningiomas.* *J Med Genet* 2010;47:567-8.
- ¹¹⁰ Otto SR, Brackmann DE, Hitselberger WE, et al. *Multichannel auditory brainstem implant: update on performance in 61 patients.* *J Neurosurg* 2002;96:1063-71.
- ¹¹¹ Nunes F, MacCollin M. *Neurofibromatosis 2 in the pediatric population.* *J Child Neurol* 2003;18:718-24.
- ¹¹² Lloyd SK, Glynn FJ, Rutherford SA, et al. *Ipsilateral cochlear implantation after cochlear nerve preserving vestibular schwannoma surgery in patients with neurofibromatosis type 2.* *Otol Neurotol* 2014;35:43-51.
- ¹¹³ Evans DG, Raymond F, Barwell J, et al. *Genetic testing and screening of individuals at risk of NF2.* *Clin Genet* 2012;82:416-24.
- ¹¹⁴ Gutmann DH, Blakeley JO, Korf BR, et al. *Optimizing biologically targeted clinical trials for neurofibromatosis.* *Expert Opin Investig Drugs* 2013;22:443-62.
- ¹¹⁵ Lim SH, Ardern-Holmes S, McCowage G, et al. *Systemic therapy in neurofibromatosis type 2.* *Cancer Treat Rev* 2014;40:857-61.
- ¹¹⁶ Trovato A, Siracusa R, Di Paola R, et al. *Redox modulation of cellular stress response and lipoxin A4 expression by Hericium Erinaceus in rat brain: relevance to Alzheimer's disease pathogenesis.* *Immun Ageing* 2016;13:23.
- ¹¹⁷ Matin N, Tabatabaie O, Falsaperla R, et al. *Efficacy and safety of omalizumab in paediatric age: an update of literature data.* *J Biol Regul Homeost Agents* 2016;30:579-84.
- ¹¹⁸ Dattilo S, Mancuso C, Koverech G, et al. *Heat shock proteins*

- and hormesis in the diagnosis and treatment of neurodegenerative diseases. *Immun Ageing* 2015;12:20.
- ¹¹⁹ Serra A, Di Mauro P, Andaloro C, et al. *A selective mutism arising from first language attrition, successfully treated with paroxetine-cbt combination treatment.* *Psychiatry Investig* 2015;12:569-72.
- ¹²⁰ Vitaliti G, Tabatabaie O, Matin N, et al. *The usefulness of immunotherapy in pediatric neurodegenerative disorders: a systematic review of literature data.* *Hum Vaccin Immunother* 2015;11:2749-63.
- ¹²¹ Serra A, DI Mauro P, Cocuzza S, et al. *Audiological findings in a case of cerebellar angioreticuloma.* *Acta Otorhinolaryngol Ital* 2015;35:212-4.
- ¹²² Karajannis MA, Legault G, Hagiwara M, et al. *Phase II trial of lapatinib in adult and pediatric patients with neurofibromatosis type 2 and progressive vestibular schwannomas.* *Neuro Oncol* 2012;14:1163-70.
- ¹²³ Plotkin SR, Halpin C, McKenna MJ, et al. *Erlotinib for progressive vestibular schwannoma in neurofibromatosis 2 patients.* *Otol Neurotol* 2010;31:1135-43.
- ¹²⁴ Karajannis MA, Legault G, Hagiwara M, et al. *Phase II study of everolimus in children and adults with neurofibromatosis type 2 and progressive vestibular schwannomas.* *Neuro Oncol* 2014;16:292-97.
- ¹²⁵ Ammoun S, Hanemann CO. *Emerging therapeutic targets in schwannomas and other merlin-deficient tumors.* *Nat Rev Neurol* 2011;7:392-9.
- ¹²⁶ Lee TX, Packer MD, Huang J, et al. *Growth inhibitory and anti-tumour activities of OSU-03012, a novel PDK-1 inhibitor, on vestibular schwannoma and malignant schwannoma cells.* *Eur J Cancer* 2009;45:1709-20.
- ¹²⁷ Ammoun S, Schmid MC, Triner J, et al. *Nilotinib alone or in combination with selumetinib is a drug candidate for neurofibromatosis type 2.* *Neuro Oncol* 2011;13:759-66.
- ¹²⁸ Mukherjee J, Kamnasaran D, Balasubramaniam A, et al. *Human schwannomas express activated platelet-derived growth factor receptors and c-kit and are growth inhibited by Gleevec (ImatinibMesylate).* *Cancer Res* 2009;69:5099-107.
- ¹²⁹ Subbiah V, Slopis J, Hong DS, et al. *Treatment of patients with advanced neurofibromatosis type 2 with novel molecularly targeted therapies: from bench to bedside.* *J Clin Oncol* 2012;30:e64-8.
- ¹³⁰ Lim S, de Souza P. *Imatinib in neurofibromatosis type 2.* *BMJ Case Rep* 2013. pii: bcr2013010274.
- ¹³¹ Plotkin SR, Stemmer-Rachamimov AO, Barker FG 2nd, et al. *Hearing improvement after bevacizumab in patients with neurofibromatosis type 2.* *N Engl J Med* 2009;361:358-67.
- ¹³² Kamba T, McDonald DM. *Mechanisms of adverse effects of anti-VEGF therapy for cancer.* *Br J Cancer* 2007;96:1788-95.
- ¹³³ Morris KA, Golding JF, Axon PR, et al. The UK NF2 Research group, Evans DG, McCabe MG, Parry A. *Bevacizumab in Neurofibromatosis type 2 (NF2) related vestibular schwannomas: a nationally coordinated approach to delivery and prospective evaluation.* *Neuro-Oncology Practice* 2016;0:1-9. doi:10.1093/nop/npv06 [in press].
- ¹³⁴ Plotkin SR, Merker VL, Halpin C, et al. *Bevacizumab for progressive vestibular schwannoma in neurofibromatosis type 2: a retrospective review of 31 patients.* *Otol Neurotol* 2012;33:1046-52.
- ¹³⁵ Nunes FP, Merker VL, Jennings D, et al. *Bevacizumab treatment for meningiomas in NF2: a retrospective analysis of 15 patients.* *PLoS One* 2013;8:e59941.
- ¹³⁶ Hawasli AH, Rubin JB, Tran DDet al. *Antiangiogenic agents for nonmalignant brain tumors.* *J Neurol Surg B Skull Base* 2013;74:136-41.
- ¹³⁷ Alanin MC, Klausen C, Caye-Thomasen P, et al. *The effect of bevacizumab on vestibular schwannoma tumour size and hearing in patients with neurofibromatosis type 2.* *Eur Arch Otorhinolaryngol* 2015;272:3627-33.
- ¹³⁸ Hochart A, Gaillard V, Baroncini M, et al. *Bevacizumab decreases vestibular schwannomas growth rate in children and teenagers with neurofibromatosis type 2.* *J Neurooncol* 2015;124:229-36.
- ¹³⁹ Farschtschi S, Kollmann P, Dalchow C, et al. *Reduced dosage of bevacizumab in treatment of vestibular schwannomas in patients with neurofibromatosis type 2.* *Eur Arch Otorhinolaryngol* 2015;272:3857-60.
- ¹⁴⁰ Mautner VF, Nguyen R, Kutta H, et al. *Bevacizumab induces regression of vestibular schwannomas in patients with neurofibromatosis type 2.* *Neuro Oncol* 2010;12:14-8.
- ¹⁴¹ Eminowicz GK, Raman R, Conibear J, et al. *Bevacizumab treatment for vestibular schwannomas in neurofibromatosis type two: report of two cases, including responses after prior gamma knife and vascular endothelial growth factor inhibition therapy.* *J Laryngol Otol* 2012;126:79-82.
- ¹⁴² Riina HA, Burkhardt JK, Santillan A, et al. *Short-term clinico-radiographic response to super-selective intra-arterial cerebral infusion of Bevacizumab for the treatment of vestibular schwannomas in Neurofibromatosis type 2.* *Interv Neuroradiol* 2012;18:127-32.
- ¹⁴³ Otsuka G, Saito K, Nagatani T, et al. *Age at symptom onset and long-term survival in patients with neurofibromatosis Type 2.* *J Neurosurg* 2003;99:480-3.

Received: February 10, 2016 - Accepted: April 29, 2016

Address for correspondence: Martino Ruggieri, Unit of Rare Diseases of the Nervous System in Childhood, Department of Clinical and Experimental Medicine Section of Pediatrics and Child Neuropsychiatry, A.O.U. "Policlinico-Vittorio Emanuele" University of Catania via S. Sofia 78, 95124 Catania. Tel. +39 095 3781281. Fax +39 095 7466385. E-mail: m.ruggieri@unict.it

HEAD AND NECK

Lipofilling as refinement procedure in maxillo-mandibular malformations

Il lipofilling come procedura ancillare nelle malformazioni maxillo-mandibolari

D. CERVELLI¹, G. GASPARINI¹, A. MORO¹, S. PELO¹, E. FORESTA¹, F. GRUSSU², G. D'AMATO¹, P. DE ANGELIS¹, G. SAPONARO¹

¹ Maxillo-Facial Surgery Unit, Complesso Integrato Columbus, Università Cattolica del Sacro Cuore, Rome, Italy;

² Plastic Surgery Unit, Policlinico Universitario "A. Gemelli", Università Cattolica del Sacro Cuore, Rome, Italy

SUMMARY

Maxillo-mandibular asymmetry has numerous aetiologies: congenital, traumatic, iatrogenic and post-oncologic. Patients with congenital dentofacial malformations are generally submitted to orthognathic surgery and/or additional procedures (genioplasty, alloplastic implants) with satisfactory results. However, despite achieving skeletal symmetry, noticeable facial asymmetry may persist. This study was performed in 45 patients (29 women and 16 men) operated between December 2012 and June 2014. All patients were affected by maxilla-mandibular asymmetry and underwent orthognathic surgery for hard tissue correction of the deformity. Residual facial alterations were then treated with lipofilling refinement procedure. In all cases good integration of the grafted fat was observed in the recipient sites. Retrospective analysis of photographic documentation showed progressive volumetric decrease for up to approximately 6 months after surgery; after that graft volume remained relatively stable. There were no significant surgical complications, either from the fat harvest site or the reconstructed site. Mild oedema and bruising were frequent during the first post-operative week. No haematomas, infections, vascular or nervous injuries were recorded. Twenty-four patients felt the need to have a second procedure. A second fat transfer was performed in 22 cases, and a third in 2 (total of 69 procedures). Based on the observations of our study, fat grafting is a simple, effective and reproducible technique, with a high satisfaction rate and few disadvantages or complications. We demonstrated that the success of lipofilling is dependent on the treated aesthetic subunits of the face. The malar and lateral cheek regions seem to be highly favourable for fat grafting, unlike the upper and lower lips subunits. Composite procedures using orthognathic surgery and autologous fat provide the surgeon with an additional, more customizable option for patients with maxillo-mandibular malformations.

KEY WORDS: Maxillo-mandibular asymmetry • Lipofilling • Orthognathic surgery

RIASSUNTO

Le asimmetrie maxillo-mandibolari riconoscono numerose eziologie: congenita, traumatica, iatrogena e post resezione oncologica. I pazienti affetti da malformazioni congenite vengono generalmente sottoposti a chirurgia ortognatica con o senza procedure aggiuntive (genioplastica, impianti alloplastici) con risultati soddisfacenti. Tuttavia, nonostante il raggiungimento della simmetria scheletrica può esistere una asimmetria residua più o meno evidente. Lo studio presentato è stato effettuato su 45 pazienti (29 femmine e 16 maschi), trattati chirurgicamente tra Dicembre 2012 e Giugno 2014. Tutti i pazienti erano affetti da asimmetria maxillo-mandibolare e sono stati sottoposti a chirurgia ortognatica per la correzione ossea della deformità. Le alterazioni residue sono state trattate con lipofilling. In tutti i casi si è osservato un buon attecchimento del grasso a livello del sito ricevente. L'analisi retrospettiva della documentazione fotografica ha dimostrato un progressivo decremento dei volumi raggiunti in seguito al trattamento con lipofilling fino a sei mesi dalla procedura, dopodiché i volumi sono rimasti invariati. Non sono state riportate complicanze significative sia a livello del sito donatore sia del ricevente. Un lieve edema ecchimotico è stato osservato frequentemente nella prima settimana post-operatoria, non sono stati riportati casi di ematoma, infezioni, danni nervosi o vascolari. 24 pazienti hanno avuto necessità di ulteriori applicazioni, una seconda applicazione si è resa necessaria in 22 pazienti ed una terza in 2 pazienti. (totale di 69 procedure). Sulla base dei risultati di questo studio la metodica del lipofilling si è dimostrata semplice, efficace e facilmente riproducibile, mostrando un alto indice di soddisfazione da parte dei pazienti e una scarsa incidenza di svantaggi e complicanze. Abbiamo inoltre dimostrato come il successo del riempimento con grasso autologo sia dipendente dalla subunità del viso che viene trattata. Le regioni malare e della guancia hanno mostrato i migliori risultati mentre le subunità corrispondenti al labbro inferiore e superiore hanno mostrato uno scarso attecchimento del grasso innestato, con una conseguente maggiore perdita di volume. In conclusione si può dire che le procedure composite, che prevedono l'utilizzo congiunto della correzione chirurgica delle basi scheletriche e un successivo ritocco per mezzo di innesto di grasso autologo, costituiscono una opzione addizionale e personalizzabile per i pazienti affetti da malformazioni maxillo-mandibolari.

PAROLE CHIAVE: Asimmetrie maxillo-Mandibolari • Lipofilling • Chirurgia ortognatica

Acta Otorhinolaryngol Ital 2016;36:368-372

Introduction

Maxillo-mandibular asymmetry has numerous aetiologies: congenital, traumatic, iatrogenic and post-oncologic. Patients with congenital dentofacial malformations are generally submitted to orthognathic surgery and/or additional procedures (genioplasty, alloplastic implants) with satisfactory results. However, despite achieving skeletal symmetry, noticeable facial asymmetry may persist. This problem is the result of the asymmetrical growth of the overlying soft tissue or the effect of its accommodation after skeletal movements. Although skeletal symmetry is present, the changes of the soft tissue envelope frequently give the face a hard, more angular appearance and/or a visible asymmetry to the normal side, that compromises the final result.

The transfer of autologous fat has been performed as whole grafts since the 1890s¹ and as injectable grafts since the 1920s². However, it is only within the last 20 years that the popularity of autologous fat graft for facial recontouring has increased within the plastic and maxillo-facial surgery community. The wide experience recently gained with the clinical use of autologous fat transfer for facial soft tissue augmentation suggests that this procedure is the best presently available. In many ways fat is the closest we have to an ideal filler: it is readily available and inexpensive to harvest, it is autologous and therefore lacks a host immune response, it is safe and noncarcinogenic and it is acquired with a minimally invasive procedure³.

Despite the clinical optimism associated with autologous fat graft, there remains an uncertainty among practitioners regarding the viability of transferred fat⁴. Several methods have been suggested to improve graft survival and volume prediction: "nontraumatic" blunt cannula technique, centrifugation and immediate injection of small amounts in multiple passes^{5,6}. The addition of growth factors or washing may be less meaningful⁷. In spite of these variable techniques for harvesting and engraftment, physician and patient satisfaction with the results of the procedure remains high, particularly in the short term⁸.

The aim of this retrospective study was to evaluate and optimise the role of fat grafting as adjunct refinement procedure in management of patients with maxillo-mandibular malformations.

Materials and methods

The study was performed on 45 patients (29 women and 16 men) operated between December 2012 and June 2014. The study was approved by the appropriate institutional review boards. Inclusion criterion was the presence of maxillo-mandibular asymmetry in patients already submitted to orthognathic surgery and/or to additional aesthetic procedures such as genioplasty or alloplastic implant placement. Excluded were patients with previous fa-

cial soft tissue surgery or those who refused to participate in the study. Each subject was fully informed about the aim of the study and about the possibility that fat grafting might have to be repeated, if necessary. Informed consent was obtained at study entry. Each patient was examined preoperatively to precisely evaluate and mark any area to be treated. Preoperative and post-operative photographs were systematically obtained.

Fat harvest, preparation and reinjection were performed in a standardised fashion in accordance with Coleman's recommendations⁹ by the same plastic surgeon. Fat was harvested from the abdominal wall or inner knees using manual suction with a 10 cc syringe and a 3 mm blunt cannula. Centrifugation was carried out at 3000 rpm for 3 min. After that, the blood/tumescent fraction was drained and the oil was removed. The resulting purified fat layer was used for grafting the maxillo-mandibular region following the principles of structural fat grafting. Multiple access sites and a fan-like pattern technique using 1.4 mm and 1.8 mm blunt cannulas were used to transfer small aliquots of fat into various depths of the soft tissue (from the dermis to the muscular fascia or muscle). A three-dimensional network of tunnels was created to improve the contact between the graft and the local adipose tissue, in order to maximise its harvest. The quantity of transplanted adipose tissue was determined by attempting to obtain symmetry with the contralateral side with 30% overcorrection. Overcorrection was performed with the realisation that there will be some loss of volume over time. Postoperatively, patients were asked to come back for follow-up at weeks 2 and 4 and at months 3, 6 and 12. At each follow-up visit, surgical complications were documented and patients were photographed. Position, facial expression, focal distance and camera settings were standardised. They were also asked to rate their overall satisfaction with the post-surgical facial appearance on a five-point scale (1: poor, 2: fair, 3: good, 4: very good, 5: excellent). This scale has been utilised in and validated by several prior studies¹⁰⁻¹².

Results

The average age of the 45 patients enrolled in the study was 29.5 years at the time of surgery. The average post-operative follow-up time was 9.7 months (range 1 to 18 months). Indications for grafts included maxillo-mandibular asymmetries after correction of congenital dentofacial malformations. Patient demographics, grafted areas, post-operative follow-up time and number of procedures are listed in Table I.

Due to its ease of access and availability, the most common donor site used was the abdominal wall (51 procedures), followed by the inner knees (18 procedures).

In all cases good integration of the grafted fat was observed in the recipient sites (Figs. 1-3). Retrospective

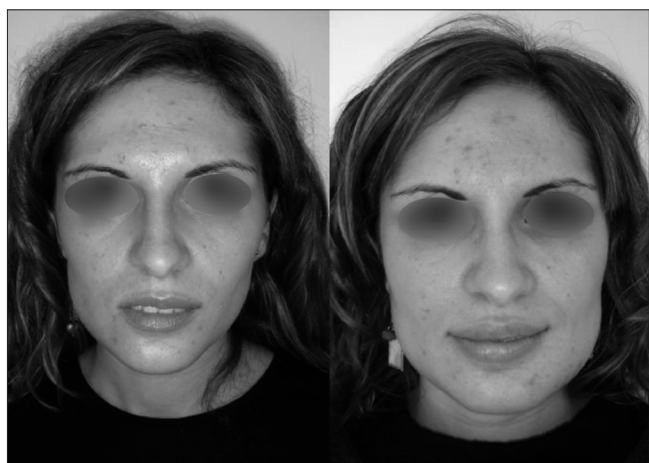

Fig. 1. A 29-year-old woman with facial asymmetry after orthognathic surgery (Patient no. 25). Postsurgical aspect after two structural grafting procedures (follow-up time: 10 months). 15 ml and 11 ml of fat tissue were grafted in the left chin, lateral cheek region and in the right upper and lower lips. Note the improvement of facial symmetry.

analysis of photographic documentation showed progressive volumetric decrease for up to approximately 6 months after surgery; after that graft volume remained relatively stable.

There were no significant surgical complications, either from the fat harvest site or the reconstructed site. Mild oedema and bruising were frequent during the first post-operative week. No haematomas, infections, vascular or nervous injuries were recorded.

Twenty-four patients felt the need to have a second procedure. A second fat transfer was performed in 22 patients, and a third in 2 (total of 69 procedures).

Analysis of patient satisfaction after the last follow-up visit clearly demonstrated better results in the malar (mean satisfaction score [MSS]: 4.5) and lateral cheek regions (MSS: 4.2). Less satisfactory results were obtained in the chin (MSS: 3.4), nasolabial region (MSS: 3.1) and marionette folds (MSS: 2.8). The least satisfactory results were achieved in the upper (MSS: 2) and lower (MSS: 1.9) lip subunits. Satisfaction ratings for each subunit of the maxillo-mandibular region are presented in Table II.

Discussion

In facial reconstructive surgery, it is generally assumed that functional disorders should be corrected primarily. If a bone deformation is present, bone repair should be considered first. Facial volume deficiency may be corrected at a second stage. Orthognathic surgery includes all surgical procedures used to surgically treat patients affected by jaw discrepancies. The aim is to align the bony jaws into a favourable position for mastication, deglutition, respiration, and also to achieve a more desirable appearance, returning the patient to more appropriate facial proportions.

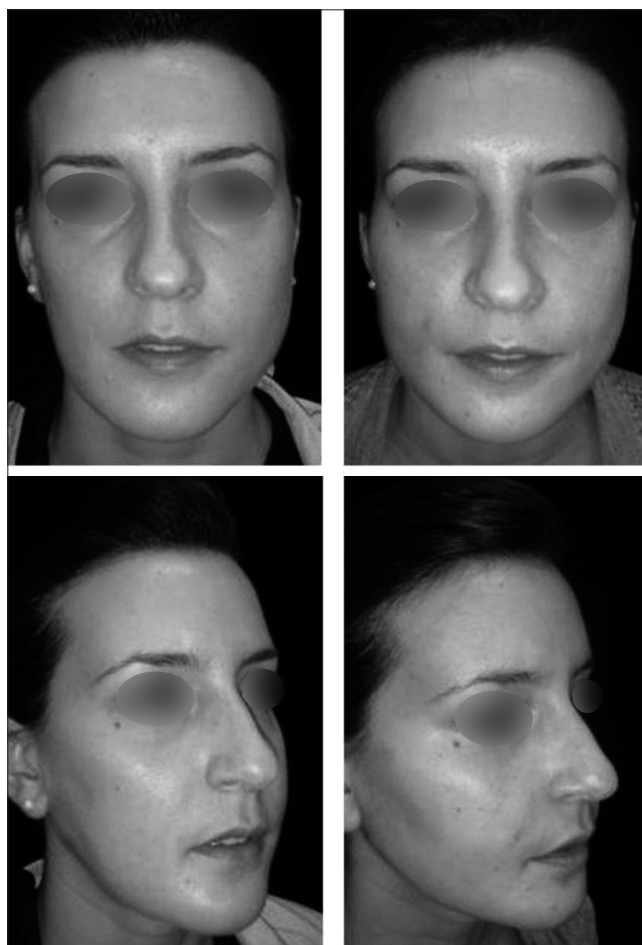

Fig. 2. (Front and lateral view). A 23-year-old woman affected by maxillo-mandibular asymmetry after orthognathic surgery (Patient no. 14). Postsurgical aspect after frontal only one structural grafting procedure (follow-up time: 13 months). 25 ml of purified fat tissue were grafted in the right malar, lateral cheek region and mandibular angle. Note the dramatic and lasting improvement of facial symmetry.

Surgical procedures involve mobilisation of the bony jaws and their repositioning according to an accurate pre-surgical planning. Fixation is usually performed with plates and screws. The results are encouraging, but complications may be possible. Loss of sensitivity in the territories innervated by the third branch of the trigeminal nerve, malocclusion relapse, temporomandibular joint disorders, or foreign body reaction to internal rigid fixation means are the most frequent complications in orthognathic surgery. Despite the aim to recreate an appropriate facial eurhythmia, this kind of surgery may leave other cosmetic issues unaddressed, especially those related to soft tissue imbalance. Surgical options for correction include hard tissue augmentation (genioplasty, bone remodelling, autologous grafts and alloplastic materials), soft tissue augmentation (fillers, lipofilling), reduction (liposuction), cosmetic lip procedures, rhinoplasty. These procedures are preferentially performed at a later date after soft tissue

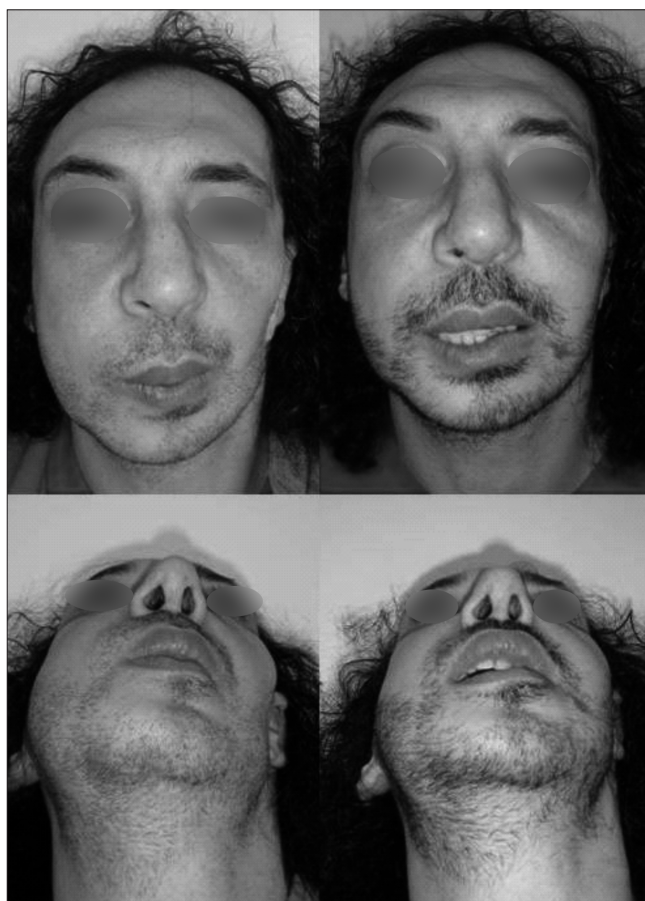

Fig. 3. (Front and inferior view). A 40-year-old man affected by Treacher-Collins syndrome with a severe facial asymmetry even after orthognathic surgery (Patient no. 40). Postsurgical aspect after two structural grafting procedures (follow-up time: 3 months). 20 ml and 14 ml of purified fat tissue were grafted in the left lateral cheek region, chin and nasolabial folds. Even if the post-operative result is still not satisfying, facial symmetry is improved.

oedema from orthognathic surgery has stopped, in order to achieve a more predictable outcome.

In clinical practice, procedures designed to augment soft tissues are the most commonly performed after orthognathic surgery, and fat grafting seems to be a reliable option as suggested by recent reports¹³ and by the results of our study. The authors believe that autologous fat can produce a more natural result for correction of maxillo-mandibular asymmetry. It allows the surgeon the opportunity to sequentially fine-tune and refine the final contours and volume of the soft tissue envelope, resulting in improved facial symmetry. Furthermore, improvement of skin quality of the treated region is generally observed a few months after fat grafting. We know that the face can be divided into well-defined aesthetic regions. However, these aesthetic regions can be further divided into well-accepted smaller subunits¹⁴. Numerous studies have evaluated adipocyte survival in fat grafting, but few have the clinical results according to the treated facial sub-

nits. In our study, we were able to analyse the success of lipofilling in relation to the different subunits of the maxillo-mandibular region. The most satisfactory results in our study were obtained in the malar and lateral cheek regions, followed by the chin, nasolabial and marionette folds, while the poorest results were achieved in the upper and lower lip subunits.

Levels of satisfaction and percentage of results were rated as “very good” and “good” and seem to correlate with the results of Mojallal et al.¹³ and Fulton et al.^{15 16} Similar outcomes were reported by Bertossi et al.¹⁷ in some facial recipient sites, but with the best results achieved in the lips and nasolabial folds. Similarly, Colic et al.¹⁸ found a resorption rate at 2 years in the perioral region of only 20%, emphasising the importance of intramuscular fat injection. The results of our study are different. In our hands, the perioral region is an area that is difficult to correct, because of high mobility, which reduces graft taking. An overcorrection and multiple procedures are frequently necessary and intramuscular injection does not seem to prevent a high resorption rate. This is particularly true for the upper and lower lip subunits. Even with multiple fat injection procedures, our results in the chin and marionette folds are quite satisfactory, according to Fulton et al.^{15 16} Differently, Eremia and Newman¹⁹ in a large series reported excellent results at 3 months, but the correction obtained was completely lost within 8 to 9 months, and repeated injections could not stabilise the results. Why are results in some anatomical regions better than in others, as shown in our study? There are no scientifically based answers, but only hypotheses which are still waiting to be experimentally confirmed. The most common hypotheses found in the literature concerns the degree of vascularisation and mobility of the recipient site and the quality of the donor-site (fibrosis, ischaemic changes, other morbidities, etc.). The studies by Mojallal et al.²⁰ in the field of tissue engineering are of interest. Those authors stated that fat graft survival depends basically on three factors: mature adipocyte survival, differentiation of adipose-derived stem cells (preadipocytes) in mature adipocytes and the presence of extracellular matrix, absolutely necessary for the two previously mentioned factors. Adipose tissue stem cells are pluripotent and various connective tissue lines derive from them. In the authors’ opinion, results are better in areas where fat tissue can be found naturally. The recipient fat tissue represents a scaffold that provides the substances to convert preadipocytes to mature adipocytes and not to other types of cells. Obviously this cannot be the case within the muscle or in contact with the fascia. This hypothesis justifies the results of our study as the best outcomes were obtained in the facial subunits where the fat was more represented (malar and lateral cheek). Another study performed by Rohrich et al. on cadavers demonstrates that subcutaneous fat of the face is partitioned into discrete anatomic compartments and that facial aging is,

in part, characterised by how these compartments change with age, which might also be involved in some compartments retaining fat grafts better than others²⁰.

In our series, a second fat transfer was performed in 22 patients, and a third in 2 cases. A further procedure was performed when the patient and surgeon considered the achieved result insufficient, in case of undercorrection of the defect. The reason for undercorrection could be underestimation of the required volume, high resorption of the grafted fat, or inadequate recipient site²¹.

Overcorrection is less common. As removal of fat without damaging the adjacent tissues is difficult, localised injection of fat should be avoided and regular distribution should be performed. In our study, no patients complained of overcorrection of the defect.

Irregularities can be observed when fat is injected too superficially or in an area with thin skin. They can be very disappointing, especially for female patients. In our series this complication was uncommon, concerning mainly the lips and mandibular profile.

The subjective evaluations of the results (preoperative and postoperative photographs) is the main limitation of this study. Despite this, our perception of the results seems to be in close relation with the level of satisfaction of patients, making the accuracy of the evaluation method relatively high.

Conclusions

Based on the observations of our study, fat grafting is a simple, effective and reproducible technique, with a high satisfaction rate and few disadvantages or complications. We demonstrated that the success of lipofilling is dependent on the treated aesthetic subunits of the face. The malar and lateral cheek regions seem to be highly favourable for fat grafting, unlike the upper and lower lips subunits. Composite procedures using orthognathic surgery and autologous fat provide the surgeon with an additional, more customisable option for patients with maxillo-mandibular malformations.

References

- 1 Neuber F. *Fettransplantation*. Zentrabl Chir 1893;22:66.
- 2 Miller CG. *Cannula implants and review of implantation techniques in esthetic surgery*. Chicago: Oak Press 1926.
- 3 Kaminer MS, Omura NE. *Autologous fat transplantation*. Arch Dermatol 2001;137:812.
- 4 Calabria R. *Fat grafting: fact or fiction?* Aesthetic Surg 2005;25:55.
- 5 Coleman SR. *Structural fat grafts: the ideal filler?* Clin Plast Surg 2001;28:111-9.
- 6 Coleman SR. *Facial recontouring with lipostructure*. Clin Plast Surg 1997;24:347-67.
- 7 Kaufman MR, Miller TA, Huang C, et al. *Autologous fat transfer for facial recontouring: is there science behind the art?* Plast Reconstr Surg 2007;119:2287-96.
- 8 Kaufman MR, Bradley JP, Dickinson Bm, et al. *Autologous fat transfer national consensus survey: trends in techniques for harvest, preparation, application and perception of short- and long-term results*. Plast Reconstr Surg 2007;119:323-31.
- 9 Coleman SR. *Structural fat grafting: more than a permanent filler*. Plast Reconstr Surg 2006;118:108S-20S.
- 10 Pereira LH, Sterodimas A. *Composite body contouring*. Aesthet Plast Surg. 2009;33:616-624.
- 11 Citarella FR, Sterodimas A, Condé-Green A. *Endoscopically assisted limited-incision rhytidectomy: a 10 years prospective study*. J Plast Reconstr Aesthet Surg 2010;63:1842-8.
- 12 Pereira LH, Sterodimas A. *Transaxillary breast augmentation: a prospective comparison of subglandular, subfacial and submuscular implant insertion*. Aesthet Plast Surg 2009;33:752-9.
- 13 Mojallal A, Shipkov C, Braye F, et al. *Influence of the recipient site on the outcomes of fat grafting in facial reconstructive surgery*. Plast Reconstr Surg 2009;124:471-83.
- 14 McCarthy J. *Introduction to plastic surgery*. In: McCarthy J, ed. *Plastic Surgery*. Philadelphia: Saunders 1990.
- 15 Fulton JE, Parastouk N. *Fat grafting*. Dermatol Clin 2001;19:523-30.
- 16 Fulton JE, Suarez M, Silverton K, et al. *Small volume fat transfer*. Dermatol Surg 1998;24:857-65.
- 17 Bertossi D, Kharouf S, D'Agostino A, et al. *Facial localized cosmetic filling by multiple injections of fat stored at -30 degrees C: techniques, clinical follow-up of 99 patients and histological examination of 10 patients*. Ann Chir Plast Esthet 2000;45:548-555.
- 18 Colic MM. *Lip and perioral enhancement by direct intramuscular fat autografting*. Aesthetic Plast Surg 1999;23:36-40.
- 19 Eremia S, Newman N. *Long-term follow-up after autologous fat grafting: analysis of results from 116 patients follow at least 12 months after receiving the last of minimum of two treatments*. Dermatol Surg 2000;26:1150-8.
- 20 Rohrich RJ, Pessa JE. *The fat compartments of the face: anatomy and clinical implications for cosmetic surgery*. Plast Reconstr Surg 2007;119:2219-27; discussion 2228-31.
- 21 Mazzola RF, Cantarella G, Torretta S, et al. *Autologous fat injection to face and neck: from soft tissue augmentation to regenerative medicine*. Acta Otorhinolaryngol Ital 2011;31:59-69.

Received: October 7, 2015 - Accepted: March 26, 2016

Address for correspondence: Gianmarco Saponaro Maxillo-Facial Surgery Unit, Complesso Integrato Columbus, Università Cattolica del Sacro Cuore, via Giuseppe Moscati 31, 00168 Rome, Italy. Email: gianmarco.saponaro@gmail.com

HEAD AND NECK

Salvage total laryngectomy after conservation laryngeal surgery for recurrent laryngeal squamous cell carcinoma

Laringectomia totale di salvataggio nel trattamento delle recidive di carcinoma squamocellulare laringeo dopo terapia chirurgica conservativa

A. DE VIRGILIO^{1,2}, A. GRECO¹, F. BUSSU³, A. GALLO⁴, D. ROSATI¹, S.-H. KIM⁵, C.-C. WANG⁶, M. CONTE¹, G. PAGLIUCA⁴, M. DE VINCENZI¹

¹ Department of Sensory Organs, ENT Section, "Sapienza" University of Rome, Italy; ² Department of Otolaryngology-Head and Neck Surgery, Regina Elena National Cancer Institute, Rome, Italy; ³ Institute of Otorhinolaryngology, Università Cattolica del Sacro Cuore, Policlinico Agostino Gemelli, Rome, Italy; ⁴ Department of Surgical Biotechnologies and Science, ENT Section, "Sapienza" University of Rome, Italy; ⁵ Department of Otorhinolaryngology, Yonsei University College of Medicine, Seoul, Korea; ⁶ Department of Otolaryngology, Taichung Veterans General Hospital, Taichung City, Taiwan.

SUMMARY

The aim of the present study was to evaluate the oncological efficacy of salvage total laryngectomy in patients who had previously undergone supracricoid partial laryngectomy or transoral laser microsurgery for treatment of laryngeal squamous cell carcinoma. We retrospectively reviewed the medical, surgical and pathological records of 35 patients who underwent salvage total laryngectomy after recurrence of laryngeal cancer (following supracricoid partial laryngectomy or transoral laser microsurgery). Kaplan-Meier survival curves as well as univariate and multivariate analyses of prognostic factors were performed. No statistically significant differences were seen comparing the supracricoid partial laryngectomy group with the transoral laser microsurgery group for overall survival and disease-specific survival at 3 years (OS = 38% vs. 52%, $p = 0.16$; DSS = 40% vs. 61%, $p = 0.057$) or locoregional control at 2 years (LRC = 40% vs. 54%, $p = 0.056$). A trend indicating worse survival and locoregional control for supracricoid partial laryngectomy patients emerged. Preservation of the osteocartilaginous frame in transoral laser microsurgery could hypothetically result in better salvageability of anterior recurrences with extralaryngeal spread.

KEY WORDS: Carcinoma • Larynx • Salvage total laryngectomy • Supracricoid laryngectomy • Transoral laser microsurgery

RIASSUNTO

Lo scopo del presente studio è stato quello di valutare l'efficacia oncologica della laringectomia totale di salvataggio in pazienti precedentemente sottoposti a laringectomia subtotale open o microchirurgia laser transorale affetti da carcinoma squamocellulare laringeo. Abbiamo analizzato retrospettivamente le informazioni cliniche, chirurgiche e patologiche di 35 pazienti sottoposti a laringectomia totale di salvataggio dopo recidiva di carcinoma laringeo (laringectomia subtotale open o transorale). Le informazioni sono state analizzate tramite l'utilizzo delle curve di Kaplan-Meier nonché tramite l'analisi univariata e multivariata dei fattori prognostici. Non sono emerse differenze statisticamente significative nel confronto tra il gruppo di pazienti precedentemente sottoposti a laringectomia subtotale ed il gruppo sottoposto a microchirurgia laser transorale sia in termini di overall survival (OS) e disease specific survival (DSS) a 3 anni (OS = 38% vs 52%, $p = 0,16$; DSS = 40% vs 61%, $p = 0,057$) che di controllo locoregionale (LRC) a 2 anni (LRC = 40% vs 54%, $p = 0,056$). È stata tuttavia messa in evidenza una tendenza che indica una sopravvivenza e controllo locoregionale peggiore nei pazienti sottoposti a laringectomia subtotale. La conservazione dello scheletro osteocartilagineo della microchirurgia laser transorale si traduce ipoteticamente in una maggiore probabilità di salvataggio delle recidive anteriori con diffusione extralaringea.

PAROLE CHIAVE: Carcinoma • Laringe • Laringectomia totale di salvataggio • Laringectomia sopracricoidale • Microchirurgia laser transorale

Acta Otorhinolaryngol Ital 2016;36:373-380

Introduction

Supracricoid partial laryngectomy (SPL) and transoral laser microsurgery (TLM) are conservative surgical techniques performed for treatment of laryngeal squamous

cell carcinoma (LSCC) allowing for effective preservation of laryngeal function with excellent oncological results^{1,2}.

SPL is an 'open' technique that involves the opening of the laryngeal box, removal of the thyroid cartilage, false

cords, true vocal cords, epiglottis (or part of it) and, when necessary, one arytenoid. At the end of the procedure, a pexy between the cricoid cartilage and the hyoid bone is performed^{1,3}. TLM is an endoscopic technique through which the LSSC is removed, generally without violating cartilage structures. The procedure does not involve the creation of communications between the laryngeal box and laterocervical spaces^{2,4}. SPL and TLM pose important decisional problems in cases of suspected local recurrence with anterior extralaryngeal extension.

In general, the anterior extralaryngeal spread of a relapsing LSCC can occur in supraglottic primary (mainly through the thyrohyoid membrane) and glottic primary cases (through the thyrohyoid and cricothyroid membranes or directly through the thyroid cartilage)^{5,6}. The latter rarely occurs. However, the potential for tumour extralaryngeal spread increases in anterior relapsing lesions previously treated with conservative surgical techniques, such as supracricoid partial laryngectomy (SPL) or transoral laser microsurgery (TLM). In these cases, the complete absence of the thyroid cartilage (in the case of SPL) or of the internal perichondrium (in the case of TLM) may facilitate anterior extralaryngeal spread⁷. In the majority of cases it is possible to classify LSSC anterior relapse into 3 categories:

1. local recurrent tumour inside the neolarynx;
2. extra-laryngeal only pattern: no tumour inside the neolarynx, fully extra-laryngeal recurrence;
3. undetermined recurrence pattern.

The treatment of recurrent LSCC with suspected anterior extralaryngeal extension in the absence of direct invasion of vital structures is surgical. In most cases, an extended total laryngectomy is required that includes not only the removal of the larynx in its entirety, but also prelaryngeal muscles, thyroid gland, and when necessary, a portion of the overlying skin⁸. The aim of the present study was to evaluate the oncological efficacy of salvage total laryngectomy (STL) in recurrent LSCC with anterior extralaryngeal invasion in patients who had previously undergone to SPL or TLM.

Materials and methods

We retrospectively reviewed the medical, surgical and pathological records of 43 patients who underwent STL between March 1990 and December 2014 at Policlinico Umberto I, 'Sapienza' University of Rome for LSCC with anterior extralaryngeal invasion (rcT4a) at first diagnosis or recurrence after conservative surgical treatment with SPL or TLS. Patient characteristics, including age, gender and KPS at diagnosis, were recorded.

Inclusion and exclusion criteria

We identified 2 patient groups: patients primarily treated with SPL and those primarily treated with TLM. Patients

who were ineligible for treatment with a radical intent and/or with known distant metastases, patients who did not undergo follow-up and those affected by non-squamous histologies were excluded. Patients with an extralaryngeal spreading pattern without clinical evidence of intralaryngeal cancer were excluded as well. Based on inclusion and exclusion criteria, 35 patients were enrolled: 16 patients underwent primary SPL before STL (Group 1) and 19 underwent primary TLM before STL (Group 2). The Institutional Review Board of the Policlinico Umberto I Hospital, Rome, Italy approved the study.

Treatment and indications. In the group of patients who were primarily treated with TLM, the main treatment was endoscopic laser cordectomy (i.e., type II, III, IV, or V) in glottic cases or endoscopic laser horizontal supraglottic laryngectomy associated with mono or bilateral neck dissection in the supraglottic cases (level II-IV + Delphian node in N0 cases; I-VI in N+ cases). In the group of patients who were primarily treated with SPL, the primary treatment was cricothyroidopexy or a cricothyroid-epiglottopexy associated with mono or bilateral neck dissection (level II-IV + Delphian node in N0 cases; I-VI in N+ cases). Cricothyroidopexy was the preferred treatment in cases of anterior commissure involvement. All patients participating in the study underwent STL for anterior LSCC recurrences with suspected extralaryngeal spread.

Salvage total laryngectomy (STL)

When cervical skin removal is planned (according to the clinical status of the tumour), the skin area that is to be removed is outlined. Immediately after the incision of the skin, frozen sections are obtained to determine whether the skin is affected by subcutaneous neoplastic lymphangitis. The incision is continued at full thickness without dissecting the cutaneous, subcutaneous, fascial and muscular planes overlying the laryngeal lodge. When skin removal was not considered, a subplatysmal U-shaped cervical flap was elevated. The upper resection boundaries include the hyoid bone, whereas the lower margins may include, when necessary, the entire thyroid gland and two or more tracheal rings, depending on the subglottic extension of the tumour. Hypopharynx defects are restored as in conventional total laryngectomy, whereas the anterior defect involving skin, fascia and muscle is restored using a pectoralis major myo-cutaneous flap. The lower margin of the myocutaneous flap is sutured to the upper rim of the first remaining tracheal ring. A wide stoma is then created.

Neck dissection and adjuvant treatment

The cN0 patients underwent elective selective neck dissection unless they had already been dissected in a previous surgery, with removal of levels II to IV, according to the main international guidelines. A comprehensive neck dissection was performed for clinically-positive nodal disease. Adjuvant radiotherapy was performed in pN0-N1

cases. Adjuvant chemoradiation was performed (considering the patient's performance status) in high risk patients: extracapsular spread, positive margins, intravascular invasion, perineural invasion, pN2-N3 patients.

Outcome analysis. The follow-up was calculated from the date of the STL. The endpoints included overall survival (OS), disease-specific survival (DSS) and loco-regional control (LRC). Statistical analysis was performed using SPSS for Windows version 15.0. Survival curves were plotted using the Kaplan–Meier method. Univariate and multivariate analyses were performed using the Cox proportional hazards model. A survival comparison was performed using a log-rank test, and p values < 0.05 were considered to be statistically significant.

Results

Age distribution was not significantly different between the two groups. Demographics and stage distribution are reported in Table I. When comparing staging (T and N for primary and recurrent LSCC) and subsites for primary LSCC, no significant differences were found between the groups. The median follow-up in our population was 31 months; therefore, 3-year survival rates are given. The median age of the entire group was 63 years (range 36-74 years). Among recurrences, the median time from primary treatment to first recurrence was 9 months for the SPL group and 13 months for the TLM group, with a mean of 11.5 and 14 months, respectively (p = 0.12).

A submucosal recurrent pattern was observed in 29 patients (83%, 12 SPL group, 17 TLM group), while an undetermined spreading pattern was observed in 6 patients (17%, 4 SPL group and 2 TLM group, Table I). Median time from primary treatment to first recurrence was 8 months in the submucosal recurrent pattern (29 patients) and 14 months for the undetermined recurrence pattern (6 patients), with a mean of 7.83 and 14 months, respectively (p < 0.001).

A nasogastric feeding tube was placed before the STL in all cases. Early and late sequelae and functional results, as well as the requirement for further adjuvant treatment, are summarised in Table II. We were unable to administer the recommended adjuvant treatment for comorbidities or low compliance in the post-operative period for 2 patients who underwent STL after SPL and 3 patients who underwent STL after TLM.

Pathologic stage. Pre-operative (STL) clinical staging was confirmed by histologic analysis in the majority of cases. In 3 cases, which were clinically classified as T4a, the pathologic staging changed to T3 (3 TLM groups). In 4 cases, which were clinically classified as N+, the pathologic staging changed to N0 (2 SPL groups, 2 TLM groups). The margins on the definitive specimen were positive in 3 cases (2 SPL groups, 1 TLM group, Table I). However, no significant differences emerged when com-

Table I. Patient characteristics and treatment modalities.

Characteristic	STL after SPL (16)	STL after TLM (19)
Age		
Median	64	59
Range	39-73	36-74
Sex N (%)		
Male	15 (94)	17 (89)
Female	1 (6)	2 (11)
Disease-free interval (months)		
Median	9	13
Range	3-27	5-35
Site of primary N (%)		
Supraglottis	10 (63)	5 (26)
Glottis	6 (37)	14 (74)
pT stage N (%)		
T1	4 (25)	5 (26)
T2	12 (75)	14 (74)
T3	-	-
T4a	-	-
pN stage N(%)		
N0	14 (87)	18 (95)
N1	2 (13)	1 (5)
N2A	-	-
N2B	-	-
rT stage (on the pathology specimen) N (%)		
T3	-	3 (16)
T4a	16 (100)	16 (84)
rN stage (on the pathology specimen) N (%)		
N0	8 (50)	12 (63)
N1	4 (25)	4 (21)
N2A	2 (13)	1 (5)
N2B	1 (6)	2 (11)
N2C	1 (6)	-
Spreading pattern N (%)		
Submucosal	12 (75)	17 (89)
Undetermined	4 (25)	2 (11)
Skin removal N (%)		
Yes	8 (50)	7 (37)
No	8 (50)	12 (63)
Skin involvement N (%)		
Positive	4 (50)	4 (57)
Negative	4 (50)	3 (43)
Resection margins after SL N (%)		
Positive	2 (13)	1 (5)
Negative	14 (87)	18 (95)

STL: salvage total laryngectomy; SPL: supracricoid partial laryngectomy; TLM: transoral laser microsurgery. pT: primary tumour T stage; pN: primary tumour N stage; rT: recurrent tumour T stage; rN: recurrent tumour N stage.

paring the two groups according to pathologic staging and margin status.

Survival analysis and loco-regional control. Calculated from the date of STL, overall OS in the entire group was

Table II. Early and late sequelae, adjuvant/salvage treatment and functional endpoints.

	STL after SPL (N=16) n (%)	STL after TLM (N=19) n (%)
Early reconstructive procedures		
Myocutaneous pectoralis major flap	15 (94)	15 (79)
Myofascial pectoralis major flap	1 (6)	4 (21)
Early sequelae (within 60 days) N		
Neck bleeding	3 (19)	2 (11)
Wound infection	1 (6)	-
Salivary fistula	3 (19)	2 (11)
Dysphagia	5 (31)	4 (21)
Persistent pain	2 (13)	-
Late sequelae (after 60 days)		
Pain	4 (25)	3 (16)
Neck fibrosis	6 (38)	5 (23)
Dysphagia	4 (25)	4 (21)
Further treatments for cancer		
Adjuvant radiotherapy	3 (19)	3 (16)
Adjuvant radiochemotherapy	11 (69)	13 (68)
Feeding/nasogastric tube		
Median removal time in days (range)	14 (8-51)	15 (12-42)
Permanent (PEG)	4 (25)	4 (21)

STL: salvage total laryngectomy; SPL: supracricoid partial laryngectomy; TLM: transoral laser microsurgery.

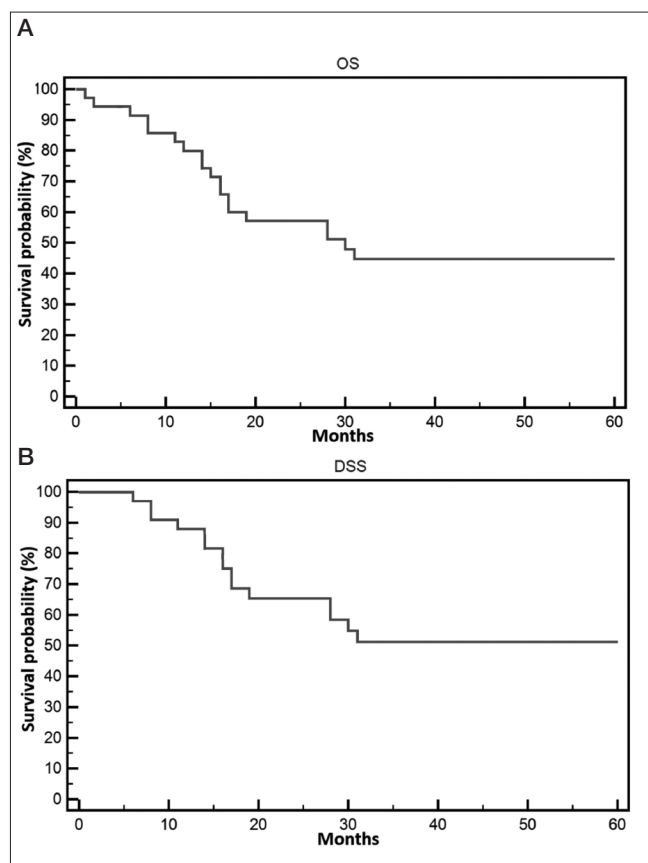


Fig. 1. Overall (a) and disease-specific (b) survival rates.

45% at 3 years; the DSS was 51% at 3 years (Fig. 1 a-b). No significant differences emerged comparing SPL vs. TLM for OS and DSS. However, a trend showing a worse survival was seen in SPL cases (3-year OS = 38% vs. 52%, $p = 0.16$; HR, 1.84, 95% CI, 0.72-4.66; 3-year-DSS = 40% vs. 61%, $p = 0.057$; HR, 2.57, 95% CI, 0.90-7.34, Fig. 2 a-b). This trend was confirmed if we consider locoregional control (LRC) as the endpoint. In fact, the SPL group showed worse LRC than the TLM group (3-year LRC = 40% vs. 54%, $p = 0.056$; HR, 2.44, 95% CI, 0.91-6.53) (Fig. 3).

Comparing the SPL and TLM groups using Cox univariate and multivariate regression analyses, we found no significant associations between clinical parameters (i.e., age, gender, time to first recurrence, cT, rT, nodal involvement at diagnosis and at recurrence, primary site, primary treatment, and margin status after STL) with DSS rates (Table III).

Discussion

STL is an aggressive surgical technique characterised by removing the larynx/neo-larynx in addition to prelaryngeal soft tissue, strap muscles and, when subcutaneous lymphangitis is suspected, a skin area overlying the larynx (wide field laryngectomy)⁷⁻⁹. Because the surgical removal is large, the surgical defect must be filled. There-

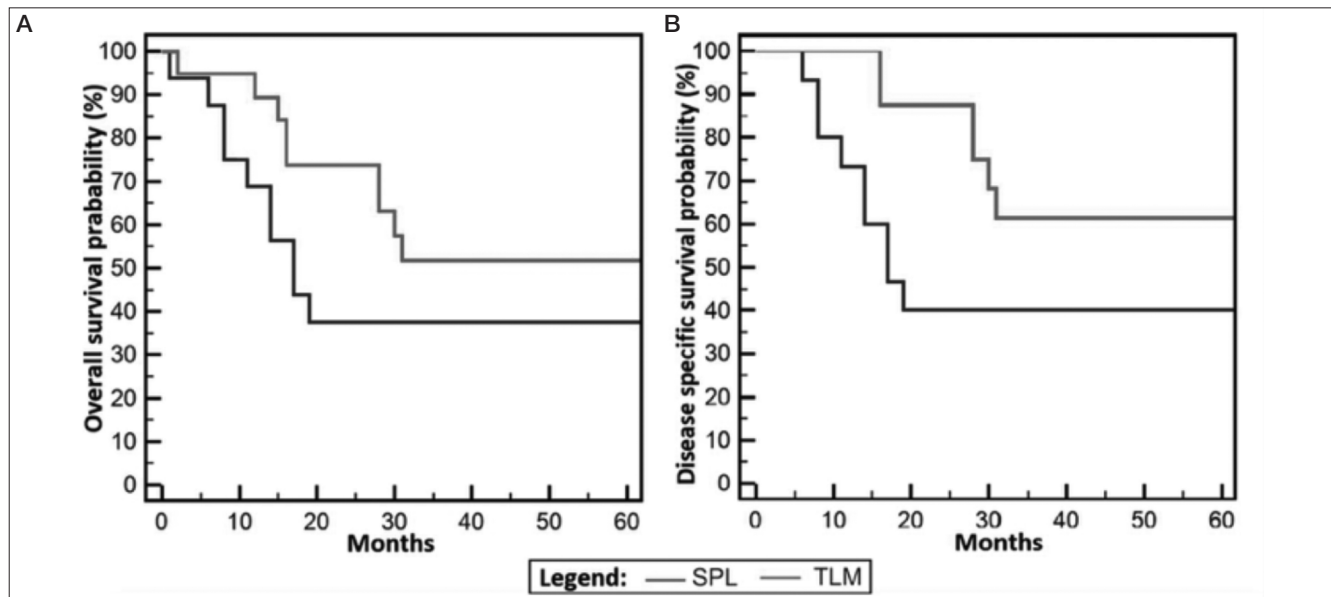


Fig. 2. Comparison between salvage wide field laryngectomy after supracricoid partial laryngectomy group (SPL) and salvage wide field laryngectomy after transoral laser microsurgery group (TLM) for overall (A) and disease-specific (B) survival.

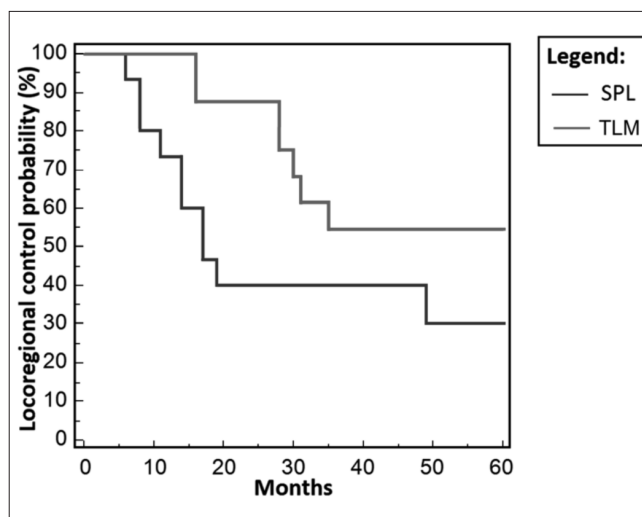


Fig. 3. Comparison between salvage wide field laryngectomy after supracricoid partial laryngectomy group (SPL) and salvage wide field laryngectomy after transoral laser microsurgery group (TLM) for locoregional control.

fore, in our centre, we prefer to use a pedicled myocutaneous or myofascial pectoralis major flap, which reliably provides an adequate amount of well-vascularised tissue and is particularly useful in patients who have previously undergone surgery and are candidates for adjuvant radio and/or chemotherapy¹⁰. Furthermore, the pectoralis major flap has been demonstrated by several reports to significantly reduce local complications such as salivary fistula¹¹. In our study, the pectoralis major flap was used for reconstruction purposes in all cases.

In this study, we investigated the results of STL in LSCC recurrences after SPL or TLM. To our knowledge, no

similar studies evaluating a large series of STL have been previously published in the international literature. OS and DSS, post-operative morbidity, and mortality appear to be acceptable, especially considering the fact that we included only recurrent cases that by definition are characterised by poor survival¹².

We divided patients into two groups according to the primary tumour treatment: SPL or TLM. This allowed comparison of oncological data for salvage surgery following widely differing surgical techniques. Indeed, SPL is an 'open' procedure that involves the opening of the laryngeal box, removal of the thyroid cartilage, false cords, true vocal cords, epiglottis (or part of it) and, when necessary, one arytenoid. Furthermore, a pexy between the cricoid cartilage and the hyoid bone is performed¹³. TLM is an endoscopic technique that does not violate the laryngeal osteocartilaginous frame and the procedure does not involve communications between the laryngeal box and laterocervical spaces²⁴. In our opinion, the main advantage of SPL is the oncological radicality in LSCC with suspected or minimal cartilage invasion¹³. Indeed, the oncological radicality of SPL in selected locally advanced LSCC is increasingly being confirmed in the recent literature¹³⁻¹⁵. The main advantage of TLM seems to be linked to the possibility of treating LSCC without excluding further therapeutic options in cases of new recurrences²¹⁶¹⁷. Furthermore TLM is repeatable in the case of local early recurrence¹⁸.

Comparing the two groups according to OS and DSS, some trends were evident: SPL cases showed worse survival (OS = 38% vs. 52%, DSS = 40% vs. 61%), but there were no statistically significant differences ($p = 0.16$ and 0.057 , respectively). This trend was also confirmed when

Table III. Univariate and multivariate analysis of prognostic covariates for DSS (calculated from the time of salvage).

Characteristic	Univariate Analysis			Multivariate Analysis		
	HR ^a	95% CI ^b	p	HR ^a	95% CI ^b	p
Age						
Over 65 years	1			1		
≤65 years	1.6	0.54 to 4.65	0.39	5.37	0.87 to 33.23	0.07
Sex						
Female	1			1		
Male	1.51	0.34 to 6.68	0.59	3.76	0.38 to 37.28	0.25
Time to first recurrence						
Before 10 months	1			1		
After 10 months	1.14	0.40 to 3.19	0.8	1.58	0.48 to 5.14	0.44
cT						
cT1	1			1		
cT2	1.39	0.39 to 4.88	0.61	5.12	0.61 to 42.88	0.13
rT						
rT3	1			1		
rT4a	2	0.26 to 15.14	0.5	0.25	0.01 to 5.25	0.37
Nodal involvement at first diagnosis						
No	1			1		
Yes	0.65	0.08 to 4.87	0.67	0.51	0.04 to 5.60	0.59
Nodal involvement at recurrence						
No	1			1		
Yes	1.45	0.80 to 2.61	0.22	1.96	0.81 to 4.74	0.13
Primary site						
Glottis	1			1		
Supraglottis	2.43	0.86 to 6.88	0.09	0.88	0.23 to 3.28	0.85
Primary Treatment						
Supracricoid laryngectomy	1			1		
Transoral laser microsurgery	0.383	0.13 to 1.07	0.07	0.23	0.05 to 1.08	0.06
Skin involvement						
positive	1			1		
negative	2.43	0.83 to 7.14	0.10	3.56	0.65 to 19.26	0.14
Salvage resection margins						
Negative	1			1		
Positive	1.92	0.42 to 8.64	0.4	5.92	0.71 to 49.39	0.1

^a Hazard ratio; ^b Confidence interval.

we compared the two groups according to LRC: SPL was related to worse LRC (40% vs. 54%), albeit non-significantly ($p = 0.056$). Furthermore, comparing the SPL and TLM groups using Cox univariate and multivariate regression analyses, we found no significant correlations of clinical parameters with DSS rates (Table III). Although no significant differences emerged, we cannot exclude the possibility that a larger series would have obtained more representative data, which may have yielded statistically significant differences for OS, DSS and LRC. Note that LSCC cases with anterior extralaryngeal extension and candidates for surgery are rare and, in the literature, there are few data concerning the surgical treatment of this peculiar LSCC. Moreover, we should consider that,

although extralaryngeal extension was radiologically strongly suspected in all cases, final pathological staging in TLM group was T3 in 3 cases (16%), while the SPL group included only T4a. Although the difference in staging was not significant, this could represent a potential bias.

The different clinical behaviours observed in the two groups and the better salvageability of TLM can be explained by the characteristics of the primary operation. In recurrences after SPL, the complete absence of thyroid cartilage allows the tumour to spread more directly, faster and (potentially) with no clinical manifestation in the anterior regions of the neck in the absence of a mechanical barrier until extensive anterior involvement occurs.

Conversely, TLM offers the great advantage of leaving the osteocartilaginous laryngeal frame, a valuable tumour spread barrier, largely intact (albeit by resecting the internal perichondrium). Preservation of the osteocartilaginous frame is the main factor underlying the better salvageability of recurrences as well as the better tolerance to adjuvant radiotherapy observed in cases treated endoscopically; this treatment triggered the progressive replacement of traditional open operations with endoscopic laser homologues, such as cordectomy, and (later) horizontal supraglottic laryngectomy^{18 19}. Therefore, the present results indirectly confirm the advantages of TLM in terms of recurrence salvageability.

In our opinion, the above delineated salvageability issues associated with primary SPL should not prevent the use of SPL. In fact, although there are conflicting data on the oncologic efficacy of TLM in the treatment of locally advanced LSCC, there is increasing evidence supporting the use of SPL in the primary treatment of advanced LSCC and as salvage treatment in early recurrent LSCC after radiotherapy with high organ preservation rates and survival^{13 15 20-23}.

Finally, in the majority of cases it is possible to classify LSSC anterior relapse into three categories: 1) local recurrent tumour inside the neolarynx (visible as submucosal recurrence) in continuity with extralaryngeal spread; 2) extra-laryngeal only pattern: no tumour inside the neolarynx, fully extra-laryngeal recurrence. This is probably a regional recurrence due to ECS from Delphian lymph node or level VI nodes; 3) undetermined recurrence pattern: tumour involving and destroying the remnant laryngeal framework with extralaryngeal extension. This is probably related to vascular or lymphatic permeation. We did not include extra-laryngeal only pattern in our study since in our opinion it could not be considered as a pure laryngeal relapse.

We observed that median time from primary treatment to first recurrence was 8 months in the submucosal recurrent pattern (29 patients, 83%) and 14 months for the undetermined recurrence pattern (6 patients, 17%), with a mean of 7.83 and 14 months, respectively ($p < 0.001$). This result should be strongly emphasised since endoscopic early detection of LSCC relapse with undetermined pattern is very difficult and, in our opinion, a higher level of caution in the follow-up is recommended after salvage laryngectomy in SPL patients.

Globally, our results suggest that longer follow-up periods with stricter intervals (2 months for the first 2 years) using different imaging techniques (MRI and PET scan) can be useful in early detection of relapse. Moreover, the routine use of adjuvant chemoradiation (in case of favourable performance status) after STL should be considered in all cases to improve survival. Finally, further research is warranted to confirm our findings and to validate our speculations.

Conclusions

To the best of our knowledge, the present study is the first to investigate the salvageability of recurrent LSCC with anterior suspected extralaryngeal extension after SPL or TLM. Although our results did not reach statistical significance, there was a trend indicating lower survival and locoregional control in patients who had undergone STL for LSCC recurrence after SPL. This was probably due to the complete absence of thyroid cartilage in SPL patients.

References

- Laccourreye H, Laccourreye O, Weinstein G, et al. *Supracricoid laryngectomy with cricothyroidopexy: a partial laryngeal procedure for selected supraglottic and transglottic carcinomas*. *Laryngoscope* 1990;100:735-41.
- Gallo A, de Vincentiis M, Manciooco V, et al. *CO2 laser cordectomy for early-stage glottic carcinoma: a long-term follow-up of 156 cases*. *Laryngoscope* 2002;112:370-4.
- De Vincentiis M, Minni A, Gallo A, et al. *Supracricoid partial laryngectomies: oncologic and functional results*. *Head Neck* 1998;20:504-9.
- Canis M, Martin A, Ihler F, et al. *Results of transoral laser microsurgery for supraglottic carcinoma in 277 patients*. *Eur Arch Otorhinolaryngol* 2013;270:2315-26.
- Lam KH. *Extralaryngeal spread of cancer of the larynx: a study with whole-organ sections*. *Head Neck Surg* 1983;5:410-24.
- Chen SA, Muller S, Chen AY, et al. *Patterns of extralaryngeal spread of laryngeal cancer: thyroid cartilage penetration occurs in a minority of patients with extralaryngeal spread of laryngeal squamous cell cancers*. *Cancer* 2011;117:5047-51.
- Croce A, Moretti A, Bianchedi M, et al. *Widened forward-total laryngectomy ("squared laryngectomy")*. *Hints of surgical techniques and personal experience*. *Acta Otorhinolaryngol Ital* 1995;15:355-60.
- Gallo A, Moi R, Simonelli M, et al. *Salvage resection after previous laryngeal surgery: total laryngectomy with en bloc resection of the overlying cervical skin*. *Arch Otolaryngol Head Neck Surg* 2001;127:786-9.
- Guerrier Y. *Les laryngectomies totales élargies*. In: Guerrier Y. *Traité de technique chirurgicale O.R.L et cervico-faciale*. Vol. 3. Paris: Masson Paris 1987; pp. 331-9.
- Gil Z, Gupta A, Kummer B, et al. *The role of pectoralis major muscle flap in salvage total laryngectomy*. *Arch Otolaryngol Head Neck Surg* 2009;135:1019-23.
- Oosthuizen JC, Leonard DS, Kinsella JB. *The role of pectoralis major myofascial flap in salvage laryngectomy: a single surgeon experience*. *Acta Otolaryngol* 2012;132:1002-5.
- van der Putten L, de Bree R, Kuik DJ, et al. *Salvage laryngectomy: oncological and functional outcome*. *Oral Oncol* 2011;47:296-301.
- De Virgilio A, Fusconi M, Gallo A, et al. *The oncologic radicality of supracricoid partial laryngectomy with cricothyroidopexy in the treatment of advanced N0-N1 laryngeal squamous cell carcinoma*. *Laryngoscope* 2012;122:826-33.
- De Vincentiis M, Minni A, Gallo A. *Supracricoid laryngec-*

- tomy with cricohyoidopexy (CHP) in the treatment of laryngeal cancer: a functional and oncologic experience.* Laryngoscope 1996;106:1108-14.
- ¹⁵ Mercante G, Grammatica A, Battaglia P, et al. *Supracricoid partial laryngectomy in the management of T3 laryngeal cancer.* Otolaryngol Head Neck Surg 2013;149:714-20.
- ¹⁶ Zhang SY, Lu ZM, Luo XN, et al. *Retrospective analysis of prognostic factors in 205 patients with laryngeal squamous cell carcinoma who underwent surgical treatment.* PLoS One 2013;8:e60157.
- ¹⁷ Blanch JL, Vilaseca I, Caballero M, et al. *Outcome of transoral laser microsurgery for T2-T3 tumors growing in the laryngeal anterior commissure.* Head Neck 2011;33:1252-9.
- ¹⁸ Peretti G, Piazza C, Bolzoni A, et al. *Analysis of recurrences in 322 Tis, T1, or T2 glottic carcinomas treated by carbon dioxide laser.* Ann Otol Rhinol Laryngol 2004;113:853-8.
- ¹⁹ Bussu F, Almadori G, De Corso E, et al. *Endoscopic horizontal partial laryngectomy by CO(2) laser in the management of supraglottic squamous cell carcinoma.* Head Neck 2009;31:1196-1206.
- ²⁰ Bussu F, Paludetti G, Almadori G, et al. *Comparison of total laryngectomy with surgical (cricohyoidopexy) and nonsurgical organ-preservation modalities in advanced laryngeal squamous cell carcinomas: a multicenter retrospective analysis.* Head Neck 2013;35:554-61.
- ²¹ de Vincentiis M, De Virgilio A, Bussu F, et al. *Oncological results of the surgical salvage of recurrent laryngeal SCC in a multicentric retrospective series. The emerging role of supracricoid partial laryngectomy.* Head Neck 2015;37:84-91.
- ²² Crosetti E, Garofalo P, Bosio C, et al. *How the operated larynx ages.* Acta Otorhinolaryngol Ital 2014;34:19-28.
- ²³ Russi EG, Sanguineti G, Chiesa F, et al. *Is there a role for postoperative radiotherapy following open partial laryngectomy when prognostic factors on the pathological specimen are unfavourable? A survey of head and neck surgical/radiation oncologists.* Acta Otorhinolaryngol Ital 2013;33:311-9.

Received: June 18, 2015 - Accepted: September 9, 2015

PAEDIATRIC OTORHINOLARYNGOLOGY

Advanced oxidation protein product levels as a marker of oxidative stress in paediatric patients with chronic tonsillitis

Ruolo dei prodotti avanzati di ossidazione proteica come marker di stress ossidativo nei pazienti pediatrici affetti da tonsillite cronica

I. OZBAY^{1,2}, C. KUCUR¹, F.E. KOÇAK³, B. SAVRAN⁴, F. OGHAN¹

¹ Department of ORL, Dumlupınar University, Kutahya, Turkey; ² Department of Otolaryngology-Head and Neck Surgery, "Arthur G. James" Cancer Hospital and "Richard J. Solove" Research Institute, Comprehensive Cancer Center, the Ohio State University Wexner Medical Center, Columbus, Ohio, USA; ³ Department of Biochemistry, Dumlupınar University, Kutahya, Turkey; ⁴ Department of Pediatric Surgery, Dumlupınar University, Kutahya, Turkey

SUMMARY

We aimed to determine whether advanced oxidation protein product (AOPP) levels can serve as a marker of oxidative stress in paediatric patients with chronic tonsillitis. Thirty children with chronic tonsillitis and 30 healthy children (control group) were recruited from the Otorhinolaryngology (ORL) and Paediatric Surgery departments, respectively, of Dumlupınar University Hospital. In the patient group, blood samples were collected before tonsillectomy, and tonsil tissue was sampled during the operation. Blood samples were also obtained from the control subjects. AOPP levels in the serum and tonsil tissue were measured by the spectrophotometric method. Serum AOPP levels were significantly higher in the patient group (13.1 ± 3.3 ng/ml) than in the control group (11.6 ± 2.3 ng/ml; $P < 0.05$). In addition, the mean AOPP level (41.9 ± 13.5 ng/mg protein) in the tonsil tissue in the patient group was significantly higher than the mean serum AOPP levels in the control and patient groups ($P < 0.05$). AOPP levels are elevated in the tonsil tissue and serum of patients with chronic tonsillitis compared to the serum AOPP levels in healthy controls. AOPPs may represent a novel class of pro-inflammatory molecules that are involved in oxidative stress in chronic tonsillitis. AOPPs may be used as a marker of oxidative stress in paediatric patients with chronic tonsillitis.

KEY WORDS: Chronic tonsillitis • Advanced oxidation protein products (AOPPs) • Oxidative stress

RIASSUNTO

L'obiettivo del presente studio è stato determinare se i livelli plasmatici dei prodotti avanzati di ossidazione proteica (AOPP) rappresentino dei marker di stress ossidativo nei pazienti pediatrici affetti da tonsillite cronica. Per lo studio sono stati arruolati, presso i Dipartimenti di Otorinolaringoiatria e Chirurgia pediatrica dell'Ospedale Universitario di Dumlupınar, trenta bambini sani e trenta affetti da tonsillite cronica. Il gruppo dei pazienti affetti da malattia è stato sottoposto a un prelievo ematico preoperatorio e ad una biopsia intraoperatoria del tessuto tonsillare. Il gruppo dei pazienti sani è stato sottoposto unicamente al prelievo ematico. I livelli plasmatici e tissutali degli AOPP sono quindi stati misurati mediante spettrofotometria. I livelli sierici degli AOPP sono risultati essere più elevati nel gruppo dei pazienti affetti da tonsillite cronica ($13,1 \pm 3,3$ ng/ml) rispetto al gruppo di controllo ($11,6 \pm 2,3$ ng/ml; $P < 0,05$). Il livello tissutale medio degli AOPP nei pazienti malati è risultato essere superiore a quello plasmatico medio sia nel gruppo dei pazienti sani che in quello dei pazienti malati ($41,9 \pm 13,5$ ng/mg; $P < 0,05$). I livelli plasmatici e tissutali degli AOPP sono risultati quindi essere più elevati nei pazienti malati rispetto al gruppo di controllo. Gli AOPP potrebbero quindi rappresentare una nuova classe di molecole pro-infiammatorie coinvolte nello stress ossidativo nella tonsillite cronica e potrebbero avere un ruolo come marker di stress ossidativo nei pazienti pediatrici affetti da tale patologia.

PAROLE CHIAVE: Tonsillite cronica • Prodotti avanzati di ossidazione proteica (AOPPs) • Stress ossidativo

Acta Otorhinolaryngol Ital 2016;36:381-385

Introduction

Tonsil tissue that is part of the Waldeyer ring has a lymphoepithelial structure ¹. Chronic tonsillitis commonly occurs in children. It causes recurrent attacks of throat pain, dysphagia, fever and malaise, and also leads to obstructive sleep apnoea syndrome in children. In addition, it disturbs sleep quality and impairs school success ². An-

tibiotics and diverse drug combinations used to treat this disease cause many side effects in children. Furthermore, the medical and surgical treatment of this disease poses an enormous economic burden.

Oxygen deports electrons from other molecules in the cell to create reactive oxygen species (ROS). ROS are controlled by a defence system that relies on the activity of enzymes and non-enzyme substances. An imbalance

between ROS generation and the body's defence system against ROS is termed oxidative stress³. Oxidation products are generated during inflammation and are involved in the tissue injury caused by inflammation. Antioxidants play a role in neutralising oxidation products and limiting tissue injury. Advanced oxidation protein products (AOPPs), a new oxidative stress marker, were first detected in the plasma of uremic patients in 1996⁴. AOPPs are thought to activate mononuclear phagocytes and act as cytokine-like mediators between neutrophils and monocytes⁴. The products of the oxidative modification of proteins are more stable than those of lipids, making AOPPs better marker of oxidative stress⁵. AOPPs are defined as dityrosine-including cross-linked protein products, a description that is significant, as it excludes protein aggregates generated by disulphide bonds created as a result of oxidative stress. Consequently, AOPPs are a good marker of oxidative stress⁶.

Oxidative stress has been linked to chronic tonsillitis^{7,8}. However, no study has yet reported the feasibility of using AOPP levels as a marker of oxidative stress in paediatric patients with chronic tonsillitis. We, therefore, conducted this study to determine whether AOPP concentrations in tonsil tissue and serum are affected by chronic tonsillitis and whether AOPPs play a role in the aetiology of chronic tonsillitis.

Materials and methods

Study design

Our study group consisted of 30 patients who were diagnosed with chronic tonsillitis and scheduled to undergo tonsillectomy in the Department of Otorhinolaryngology (ORL), Dumlupinar University Education and Research Hospital, Kutahya, Turkey. Chronic tonsillitis was diagnosed on the basis of the patient's history and the findings of physical examinations. Chronically inflamed tonsils with white debris arising from the tonsillar crypts and frequent attacks of tonsillitis were considered as indications for tonsillectomy. Patients with chronic tonsillar hypertrophy were included in the study; however, indications such as chronic tonsillitis that did not respond to medical treatment and was associated with persistent sore throat, halitosis or painful cervical adenitis were excluded. In addition, patients with complications were not included in the study. As a control group, 30 healthy individuals with no complaints in the head and neck region and without any infection or other systemic diseases were recruited from the Department of Paediatric Surgery, Dumlupinar University Education and Research Hospital.

Blood and tonsil tissue collection and preparation

Preoperatively in the study group, after overnight fasting, an overall of 10 ml venous blood samples were obtained from each person in addition to the routine preoperative

blood tests immediately before tonsillectomy. In both the patient and control groups, blood samples were collected into evacuated tubes containing a serum separator and clot activator (Vacuette®, Greiner Bio-One, Kremsmunster, Austria). Within 1 h of collection, blood samples were centrifuged at 1500 × g for 15 min to obtain serum samples. After centrifugation, serum samples were stored at -80°C until biochemical analysis. Tonsillectomy was performed under general anaesthesia in all patients. After the tonsillectomy, tonsil tissue samples were immediately rinsed with cold, heparinised, phosphate-buffered saline to remove any red blood cells or clots. Portions of the tonsil samples were placed in Eppendorf tubes and immediately stored at -80°C until biochemical analysis.

Measurement of AOPP levels

Before the measurement of the AOPP levels in the tonsil tissue samples, approximately 10 mg of tonsil tissue was mixed with 100 µl of cold working solution (50 mM phosphate buffer, pH 7.40), and homogenised using a mechanical homogeniser (SpeedMill Plus, Analytik Jena, Germany). The homogenate was then centrifuged at 10,000 × g for 15 min at 4°C, and the resultant supernatant was preserved for biochemical analysis by storing on ice. AOPP levels were measured in tonsil tissue homogenates and serum samples by using commercial enzyme-linked immunosorbent assay kits (Eastbiopharm Co., Ltd., Hangzhou, China) and a microplate reader (BMG Labtech Spectrostar Nano, GmbH, Ortenberg, Germany). Tissue protein concentrations were measured using the Bradford method on a Beckman Coulter AU680 analyser (Beckman Coulter, Miami, FL, USA)¹. AOPP concentrations were expressed as ng/ml for serum samples and ng/ml protein for tonsil tissue samples.

Ethical considerations

The study protocol was approved by the local ethics committee. The parents of all included subjects provided written and oral informed consent, and subjects were enrolled only after their parents had agreed to participate in the study and signed an informed consent form.

Statistical analysis

Statistical analyses were performed using GraphPad Prism version 6.05 (GraphPad Software, Inc., CA, USA). All data sets were tested for normality using Shapiro-Wilk test. Since the values were normally distributed and the sample size was ≥ 30, data were presented as mean ± standard deviation (SD) and parametric statistical tests were used. The comparison of AOPP values between groups were analysed using unpaired t-test. The comparison of AOPP values between serum samples and tonsil tissue samples in patients with chronic tonsillitis were analysed using unpaired t-test. A P value < 0.05 was considered as statistically significant.

Results

The study group consisted of 30 patients (17 males, 13 females, mean age 7.9 ± 3.4) undergoing tonsillectomy who fulfilled the inclusion criteria. The control group consisted of 30 subjects (17 males, 13 females, mean age 7.7 ± 3.2).

When the serum AOPP levels measured in study group and control group were compared, since the 95% confidence interval (CI) did not include zero and the P value was < 0.05 , we concluded that there was a statistically significant difference between the two groups [$t(57) = -1.47$, $P = 0.048$, 95% CI: -2.92 to -0.01]. Our results revealed that serum AOPP levels were higher in study group compared to control group (Table I; Fig. 1).

When serum AOPP levels and tonsil tissue AOPP levels in the study group were compared, significant difference was found between AOPP levels [$t(55) = -28.83$, $P < 0.001$, 95% CI: -33.99 to -23.67]. Tissue AOPP levels were significantly higher in tonsil tissue samples compared to serum samples (Table II; Fig. 2).

Discussion

Chronic tonsillitis is characterised by episodes of local infections with diverse pathogens, which are associated with the activation of lymphoid cells and episodes of excessive hypoxia/reoxygenation⁷. Free oxygen radicals (FORs), which are part of the defence mechanism, are profusely generated by neutrophils, monocytes, eosinophils and macrophages to kill bacteria during tonsillar inflammation^{2,8}. Yılmaz et al.² concluded that tonsillectomy diminishes the total oxidative stress by eliminating a microbial source and thereby strengthens the immune system. FORs negatively impact the immune system by reducing the proliferation capacity of defensive cells through DNA damage and by decreasing the synthesis of some critical factors, which decreases antioxidant levels and thereby increases the susceptibility to upper respiratory tract infections. Cvetkovic et al.⁸ claimed that the antioxidant defence system may help prevent the recurrence of tonsillitis; however, tonsillectomy alone cannot supply this conservation.

Oxidative stress is involved in the pathogenesis of many diseases. Antioxidant therapy, which decreases oxidative stress, is a potential treatment for a number of pathologies. Whether oxidative stress is the reason or the result of disease is unclear. The in vivo quantification of oxidative stress is complicated, and practical and easy methods of measurement are still being developed. During oxidative stress, AOPPs are generated as a result of myeloperoxidase activity against hypochloric acid and chloramines in activated neutrophils; thus, AOPPs are a reliable marker to measure the oxidative modification of proteins⁹. FORs are molecules that contain one or more unpaired electrons,

Table I. Comparison of the levels of advanced oxidation protein products (AOPPs) between chronic tonsillitis patients and control subjects.

AOPP	CT Group (mean \pm SD) N = 30	Control Group (mean \pm SD) N = 30	95% CI	P
Serum (ng/mL)	13.1 ± 3.3	11.6 ± 2.3	-2.92 to -0.01	0.048^*

CT: Chronic tonsillitis, AOPP: Advanced oxidation protein product, SD: Standard deviation, CI: Confidence interval. Data are presented as mean \pm SD for each group. Data were tested using the unpaired t test. A P value of less than 0.05 was considered as statistically significant. Since the 95% CI did not include zero, there was a statistically significant difference between the two groups.

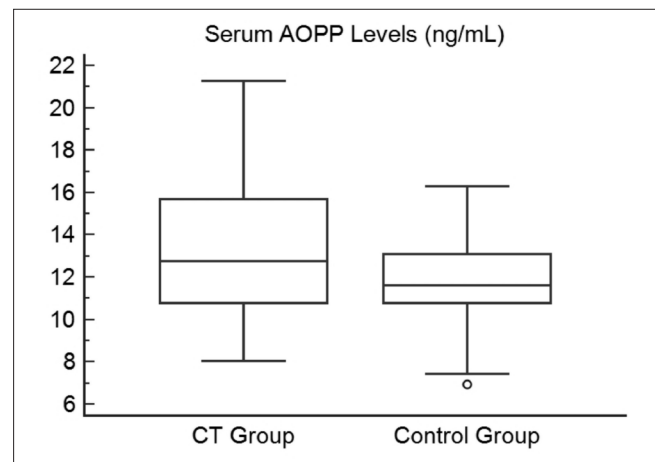


Fig. 1. Comparison of the serum levels of advanced oxidation protein products (AOPPs) between patients with chronic tonsillitis and control subjects.

and can accumulate to high levels in living systems¹⁰. These molecules are very reactive, and in particular, react with lipids, proteins, nucleotides and carbohydrates, causing tissue injury¹¹. Under normal conditions, the potential deleterious effects of free radicals are precluded by antioxidants¹¹, which consist of enzymes such as superoxide dismutase (SOD), glutathione peroxidase, catalase and glucose-6-phosphate dehydrogenase and non-enzymatic factors such as ascorbic acid, α -tocopherol, retinol and β -carotene^{12,13}. Antioxidants within cells, cell membranes and extracellular fluids preclude extreme free radical for-

Table II. Comparison of the levels of advanced oxidation protein products (AOPPs) between serum samples and tonsil tissue samples in patients with chronic tonsillitis.

Serum AOPP (ng/mL) (mean \pm SD) N = 30	Tonsil Tissue AOPP (ng/mg protein) (mean \pm SD) N = 30	95% CI	P
13.1 ± 3.3	41.9 ± 13.5	-33.99 to -23.67	$< 0.001^*$

AOPP: Advanced oxidation protein product, SD: Standard deviation, CI: Confidence interval. Data are presented as mean \pm SD for each group. Data were tested using the unpaired t test. A P value of less than 0.05 was considered as statistically significant. Since the 95% CI did not include zero, there was a statistically significant difference between the two groups.

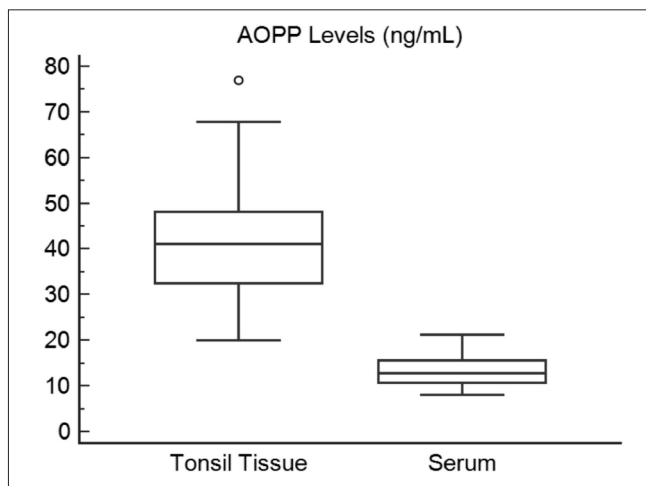


Fig. 2. Comparison of the levels of advanced oxidation protein products (AOPPs) between serum samples and tonsil tissue samples in patients with chronic tonsillitis.

mation and maintain a balance¹². Blood plays an important role in the maintenance of the equilibrium between antioxidants and oxidants, as it facilitates the distribution of antioxidants throughout the body^{10 11}.

During chronic inflammation, the antioxidant level slowly declines until the level of oxidative stress exceeds the capacity of the body to neutralise it. Low antioxidant levels may be the result of chronic illnesses. Free radical-mediated damage to lipids in the membranes of leucocytes augments the permeability of these cells and diminishes their immune function. In addition, DNA damage caused by free radicals inhibits the synthesis of certain important factors by leucocytes and decreases the proliferation capacity of leucocytes. Low antioxidant levels in blood may predispose children to frequent upper respiratory tract infections by adversely affecting their immune system. The discovery of antioxidants and oxidation products in the tonsil tissues of patients with chronic tonsillitis shows that these substances are associated with this disease².

Chronic tonsillitis is a chronic inflammatory illness, and the role of FORs in the pathogenesis of this disease has been reported in diverse studies^{2 14}. Kiroglu et al.¹⁵ reported that the preoperative blood erythrocyte malondialdehyde (MDA), serum MDA, erythrocyte catalase and serum catalase levels and adenoid and tonsil tissue levels of MDA and catalase were higher in chronic adenotonsillitis patients than in children with adenotonsillary hypertrophy. Kaygusuz et al.¹⁶ investigated chronic tonsillitis patients, and found that oxidative stress increased and SOD activity decreased in parallel with an increase in the generation of MDA by lipid peroxidation that resulted in tissue damage. The authors also reported that in the same patient group, oxidative stress declined during the postoperative period together with an increment in SOD activity and a decline in MDA level. Yilmaz et al.² com-

pared the pre-and postoperative (1 month) blood levels of antioxidants (carotene, retinol, lycopene, tocopherol, ascorbic acid, SOD, glutathione peroxidase) and MDA in patients with adenotonsillary disease. They reported that the blood levels of antioxidants increased, while those of the oxidant decreased significantly after operation in patients with adenotonsillary disease. Garca et al.¹⁷ investigated the effects of adenosine deaminase, an enzyme that plays significant roles in the differentiation of lymphoid cells, and oxidative stress in patients with chronic tonsillitis. The authors found that tissue and serum adenosine deaminase activity was elevated in patients with chronic tonsillitis.

AOPP levels have been mentioned as a marker of oxidative stress in the literature concerning the ear, nose and throat region. Balikci et al.¹⁸ investigated AOPP levels in children with chronic otitis media with effusion; they found that AOPP levels were increased in the effusion fluid, but not in the plasma, of these patients. The authors, therefore, concluded that chronic otitis media with effusion was associated with protein oxidation abnormalities. Veyseller et al.¹⁹ reported that AOPPs could be used as markers of oxidative stress during the development of nasal polyposis. Aksoy et al.²⁰ investigated the levels of AOPP as a marker of oxidative stress in patients with allergic rhinitis. They concluded that as a known indicator of protein oxidation, the serum AOPP level could be used as a marker of increased oxidative stress in response to allergen exposure in allergic rhinitis. In the present study, which is the first to investigate the relationship between AOPP levels and chronic tonsillitis, we found that AOPP levels were higher in the tonsil tissue and serum samples obtained from patients with chronic tonsillitis than in serum samples obtained from the control group.

A limitation of our study was not comparing the postoperative serum levels of AOPPs of patients with the control group. Ethical rules limited us to take blood samples from patients postoperatively. This is because we do not routinely take blood samples in every patient in the postoperative period if patients recover well. In addition, because it was not ethically acceptable to generate a control group for tonsillar tissue measurements to statistically compare these values with any corresponding value, and only blood samples were attained from the control group. We hope that this preliminary study will encourage larger studies to be undertaken.

Conclusions

AOPPs may represent a novel class of pro-inflammatory molecules that are involved in oxidative stress in patients with chronic tonsillitis. Examination of the pathophysiological processes associated with AOPPs could deepen our knowledge concerning the relationship between oxidative stress and the course of chronic tonsillitis. AOPPs

may be used as a marker of oxidative stress in paediatric patients with chronic tonsillitis. In addition, AOPPs blood levels as biochemical parameter may have possible role for tonsillectomy indication in paediatric patients with chronic tonsillitis. Further studies are required to elaborate on this relationship.

References

- ¹ Boyaka PN, Wright PF, Marinaro M, et al. *Human nasopharyngeal-associated lymphoreticular tissues*. Am J Pathol 2000;157:2023-35.
- ² Yilmaz T, Kocan EG, Besler HT. *The role of oxidants and antioxidants in chronic tonsillitis and adenoid hypertrophy in children*. Int J Pediatr Otorhinolaryngol 2004;68:1053-8.
- ³ Goodyear-Bruch C, Pierce JD. *Oxidative stress in critically ill patients*. Am J Crit Care 2002;11:543-51.
- ⁴ Witko-Sarsat V, Friendlander M, Capeillere-Blandin C, et al. *Advanced oxidation protein products as a novel marker of oxidative stress in uremia*. Kidney Int 1996; 49:1304-113.
- ⁵ Massy ZA, Nguyen-Khoa T. *Oxidative stress and chronic renal failure: markers and management*. J Nephrol 2002;15:336-41.
- ⁶ Vissers MC, Winterbourn CC. *Oxidative damage to fibronectin I. The effects of the neutrophil myeloperoxidase system and HOCl*. Arch Biochem Biophys 1991;285:53-9.
- ⁷ Kutluhan A, Ugras S, Kiris M, et al. *Differences in clinical and histopathologic features between chronic adenotonsillitis and chronic adenotonsillar hypertrophy*. Kulak Burun Bogaz Ihtis Derg 2003;10:61-7.
- ⁸ Cvetković T, Vlahović P, Todorović M, et al. *Investigation of oxidative stress in patients with chronic tonsillitis*. Auris Nasus Larynx 2009;36:340-4.
- ⁹ Piwowar A, Knapik-Kordecka M, Warwas M. *AOPP and its relations with selected markers of oxidative/antioxidative system in type 2 diabetes mellitus*. Diabetes Res Clin Pract 2007;77:188-92.
- ¹⁰ Halliwell B. *Oxidants and human disease: some new concepts*. FASEB J 1987;1:358-64.
- ¹¹ Halliwell B, Gutteridge JM, Cross CE. *Free radicals, antioxidants and human disease: where are we now? J Lab Clin Med 1992;119:598-620*.
- ¹² Besler ET, Çomoglu S. *Lipoprotein oxidaton, plasma total antioxidant capacity and homocysteine level in patients with multiple sclerosis*. Nutr Neurosci 2003;6:189-96.
- ¹³ Young IS, Woodside JV. *Antioxidants in health and disease*. J Clin Pathol 2001;54:176-86.
- ¹⁴ Dogruer ZN, Unal M, Eskandari G, et al. *Malondialdehyde and antioxidant enzymes in children with obstructive adenotonsillar hypertrophy*. Clin. Biochem 2004;37:718-21.
- ¹⁵ Kiroglu AF, Noyan T, Oger M, et al. *Oxidants and antioxidants in tonsillar and adenoidal tissue in chronic adenotonsillitis and adenotonsillar hypertrophy in children*. Int J Pediatr Otorhinolaryngol. 2006;70:35-8.
- ¹⁶ Kaygusuz I, Ilhan N, Karlidag T, et al. *Free radicals and scavenging enzymes in chronic tonsillitis*. Otolaryngol Head Neck Surg 2003;129:265-8.
- ¹⁷ Garca MF, Demir H, Turan M *Assesment of adenosine deaminase (ADA) activity and oxidative stress in patients with chronic tonsillitis*. Eur Arch Otorhinolaryngol 2014;271:1797-802.
- ¹⁸ Balıkcı HH, Karakas M, Gürdal MM, et al. *Advanced oxidation protein product level in children with chronic otitis media with effusion*. Int J Pediatr Otorhinolaryngol 2014;78:551-3.
- ¹⁹ Veyseller B, Aksoy F, Ertas B, et al. *A new oxidative stress marker in patients with nasal polyposis: advanced oxidation protein products (AOPP)*. B-ENT 2010;6:105-9.
- ²⁰ Aksoy F, Yıldırım YS, Veyseller B, et al. *Serum levels of advanced oxidation protein products in response to allergen exposure in allergic rhinitis*. Ear Nose Throat J 2012;91:32-5.

Received: October 26, 2015 - Accepted: March 26, 2016

Address for correspondence: Isa Ozbay, Department of Otorhinolaryngology, Faculty of Medicine, Dumlupınar University, 43000 Kutahya, Turkey. Tel. +9005059311869. Fax +9002742316673. E-mail: isaobay@yahoo.com

ORAL PATHOLOGY

Association between oral habits, mouth breathing and malocclusion

Associazione fra abitudini viziate, respirazione orale e malocclusione

C. GRIPPAUDO¹, E.G. PAOLANTONIO¹, G. ANTONINI¹, R. SAULLE², G. LA TORRE², R. DELI¹

¹ Catholic University of Sacred Heart, Dental Institute; ² Department of Public Health and Infectious Diseases, Sapienza University of Rome, Italy

SUMMARY

The ratio of bad habits, mouth breathing and malocclusion is an important issue in view of prevention and early treatment of disorders of the craniofacial growth. While bad habits can interfere with the position of the teeth and normal pattern of skeletal growth, on the other hand obstruction of the upper airway, resulting in mouth breathing, changes the pattern of craniofacial growth causing malocclusion. Our cross-sectional study, carried out on 3017 children using the ROMA index, was developed to verify if there was a significant correlation between bad habits/mouth breathing and malocclusion. The results showed that an increase in the degree of the index increases the prevalence of bad habits and mouth breathing, meaning that these factors are associated with more severe malocclusions. Moreover, we found a significant association of bad habits with increased overjet and openbite, while no association was found with crossbite. Additionally, we found that mouth breathing is closely related to increased overjet, reduced overjet, anterior or posterior crossbite, openbite and displacement of contact points. Therefore, it is necessary to intervene early on these aetiological factors of malocclusion to prevent its development or worsening and, if already developed, correct it by early orthodontic treatment to promote eugenic skeletal growth.

KEY WORDS: Oral habits • Mouth breathing • Malocclusion • Occlusal index • ROMA index

RIASSUNTO

Il rapporto fra abitudini viziate, respirazione orale e malocclusione è fondamentale in tema di prevenzione e trattamento precoce dei disturbi della crescita cranio-facciale. Infatti così come le abitudini viziate possono interferire negativamente con la posizione dei denti e con il normale pattern di crescita scheletrica cranio-facciale, così l'ostruzione delle vie aeree superiori, con conseguente respirazione orale, cambia il modello di crescita craniofacciale con sviluppo di malocclusioni da moderate a severe. Questo studio trasversale, effettuato su 3.017 bambini applicando il ROMA index, vuole verificare l'esistenza di una correlazione significativa tra abitudini viziate/respirazione orale e malocclusione. Dai risultati emerge che all'aumentare del grado dell'indice aumenta anche la prevalenza di abitudini viziate e respirazione orale, significando che questi fattori sono associati alle malocclusioni più gravi. Inoltre abbiamo riscontrato un'associazione statisticamente significativa fra abitudini viziate e overjet e openbite aumentati, ma non con il morso inverso. Dal lavoro è emerso che la respirazione orale è strettamente correlata ad overjet aumentato, overjet inverso, morso crociato, openbite e displacement. Riteniamo quindi che abitudini viziate e respirazione orale, rientrando fra i fattori di rischio di malocclusione, vadano intercettati e corretti precocemente per prevenire lo sviluppo di malocclusioni o il peggioramento di quelle preesistenti.

PAROLE CHIAVE: Abitudini viziate • Respirazione orale • Malocclusione • Indici occlusali • ROMA index

Acta Otorhinolaryngol Ital 2016;36:386-394

Introduction

It is still debated whether bad habits and mouth breathing have a role in the aetiopathogenesis of malocclusions. Beyond this controversy, whenever these problems are found in association with malocclusion, it is of considerable importance for prognosis and they must be eliminated in order to ensure a functional environment adequate for physiological growth. If some neuromuscular activities are developed to compensate dentoalveolar or skeletal alterations, others have an aetiological role^{1,2}. Improper oral habits can interfere not only with the position of the teeth, but especially with the normal skeletal growth pattern.

Some studies have shown that many environmental factors cause malocclusion^{3,4}, including eating habits, and especially the current trend in consuming foods of soft consistency with reduction of masticatory forces, non-nutritive sucking, pacifier sucking and finger sucking and early weaning⁵. Pacifier sucking, baby bottle sucking and especially finger sucking frequently causes protrusion of the upper incisors and the premaxilla, atypical swallowing^{6,7}, anterior open bite and posterior crossbite⁸⁻¹⁰. The posterior crossbite is due to a low position of the tongue due to sucking, with lack of thrust of the tongue on the palate and increased activity of the muscles of the cheeks that causes an alteration of muscle pressure on the upper arch¹¹⁻¹².

Regarding the influence of breathing on craniofacial morphology, there are several publications in the literature. Although some authors believe that the change of the normal pattern of dento-skeletal growth is due to genetic and environmental factors¹³, most think instead that the obstruction of upper airways, resulting in mouth breathing, changes the pattern of craniofacial growth¹⁴ with typical facial features and dentition: long face, contraction of the upper dental arch, high arched palate, gummy smile, dental malocclusion both Class II and Class III¹⁵. In mouth breathing, compared to the general population, a higher prevalence of posterior cross bite, of anterior open bite and Class II malocclusion is seen¹⁶.

Furthermore, there are frequent medical and social problems related to tiredness due to lack of sleep, which is interrupted for mouth breathing and frequent sleep apnoea, such as attention deficit disorder (ADD) and hyperactivity¹⁷.

It is therefore appropriate to verify the existence of a significant association between bad habits, mouth breathing and malocclusion and if children with these habits have characteristics of malocclusion worse than those of the general population; when found bad habits and mouth breathing are risk factors for malocclusion that need to be corrected early.

In this study we evaluated the association between bad habits/mouth breathing and malocclusion by application of the ROMA index¹⁸ on a sample of school children already participating in an epidemiological study¹⁹ and on the timing of orthodontic treatment²⁰.

Materials and methods

The ROMA Index - Risk Of Malocclusion Assessment Index - is a tool to assess treatment need in young patients. It was specifically devised for use in examining young patients during the first visit, in an attempt to grade, beside malocclusions, skeletal and functional aspects, which in children are determinants of oro-facial development. It was developed reviewing and modifying the dental and occlusal parameters of DHC of the IOTN²¹ with addition of items relative to skeletal and functional problems, which lack in the IOTN (maxillary hypodevelopment/mandibular hyperdevelopment or increased overjet; maxillary hyperdevelopment/mandibular hypodevelopment or reduced overjet; mandibular hypo- or hyperdivergence; facial or mandibular asymmetries; functional asymmetries; bad habits; mouth breathing).

The ROMA Index (Table I) is intended as a guide to clinical signs of malocclusion in paediatric patients. Depending on how many signs are detected, there is a greater or lesser need for orthodontic intervention. The most severe characteristic is identified for any particular patient during examination, and the patient is then categorised on the

index risk factor scale according to this most severe characteristic. As in the following list, categories are ranked in order of seriousness, thus also indicating the level of urgency with which orthodontic diagnosis/treatment is required:

Grade 1 → Minimum risk

No predisposing conditions to malocclusion are detected. In this case, treatment is unnecessary and it is sufficient to carry out periodic examinations, in order to monitor the normal course of development and to detect possible pathological factors promptly.

Grade 2 → Low risk

This includes easily controlled factors having only limited effects on cranio-facial development. Diagnostic investigations and preventive interventions to promote correct cranio-facial development are planned, but they are delayed until there is a temporal correspondence between the aetiological agent and growth acceleration in the affected region.

Grade 3 → Moderate risk

There are non-severe alterations in dental and/or skeletal relationships, but most tending to persist and sometimes worsen with growth. The timing of intervention is dependent on the patient's age, i.e., on the active growth phases of the affected areas, so as to achieve good treatment response. Orthodontic treatment is combined with orthopaedic-functional therapy to be performed after undertaking appropriate diagnostic investigations.

Grade 4 → High risk

It includes major cranio-facial skeletal malformations and alterations of the occlusion. Alternatively, there can be systemic problems likely to worsen prognosis that justify immediate treatment, independent of the rhythm of growth of the different cranio-facial components. Both orthopaedic therapy and orthodontic interventions are required to correct the problems caused by the malocclusion and hindering harmonious maxillary growth.

Grade 5 → Extreme risk

Diagnosis comprises congenital facial malformations and major systemic malformation syndromes. Treatment, to be performed in collaboration with paediatricians and other specialists (multidisciplinary care), is required as early as possible.

The investigation was planned as a cross-sectional study and the ROMA index (Table I) was used to examine 3017 Italian children. The sample was balanced according to gender, age and geographical origin. It consists of 1375 males (45.6%) and 1642 females (54.4%) aged between 7 and 13 years (Table II). The survey was conducted be-

Table I. ROMA index.

Problems	Items	Grade	
Systemic	Malformation syndromes	5a	
	Congenital malformations	5b	
	Postural or orthopaedic problems	4c	
	Medical or auxological problems	4d	
	Inheritance of malocclusion	4e	
	Facial or mandibular asymmetries	4f	
Cranio-facial	TMJ dysfunctions	4g	
	Sequelae of trauma or surgery of the cranio-facial district	4j	
	Maxillary hypodevelopment or mandibular hyperdevelopment	OVJ ≤ 0	4k
		OVJ > 0	3k
	Maxillary hyperdevelopment or mandibular hypodevelopment	OVJ > 6 mm	4h
		3 mm < OVJ < 6 mm	3h
		0 mm < OVJ < 3 mm	2h
	Mandibular hypo- or hyperdivergence	4i	
	Dental	Caries and early loss of deciduous teeth	3l
		Scissor bite	4m
Anterior or posterior crossbite*		> 2 mm	4n
		> 1 mm	3n
		< 1 mm	2n
Displacement**		> 4 mm	4o
		> 2 mm	3o
		> 1 mm	2o
		> 4 mm	4p
		> 2 mm	3p
		> 1 mm	2p
Hypodontia of permanent teeth		4q	
OVB > 5 mm	3r		
Anomalies of the tooth eruption sequence	2s		
Poor oral hygiene	2t		
Normal mesial or distal occlusion (up to a cuspid)	2u		
Functional	Functional asymmetries	2v	
	Bad habits	2w	
	Mouth breathing	2x	

* one or more teeth.

**displacement of contact points (the maximum distance of the contact points of the most misaligned contiguous teeth).

The index items, identified by a letter, are framed in four categories of problems (systemic, craniofacial, dental, functional) and each item is accompanied by a number which corresponds to the degree of risk. The degree of risk for each patient is given by the worst index item detected.

tween 2008 and 2011 and the children – 1529 (50.7%) from primary schools and 1488 (49.3%) from secondary schools – were examined in their schools, after official approval of the survey by each school principal. Schools belonged to the following Italian regions: Piemonte and Friuli (North), Abruzzo and Lazio (Centre), Puglia and Calabria (South).

The ROMA index was applied by operators who had previously undergone a training period of one month following the instructions of a special manual, in order to apply the index with the same standard of judgment and to minimise errors. In addition, the index has already been

validated and was also verified its intra-examiner and inter-examiner reproducibility¹⁸. To evaluate the reproducibility, the intra-examiner error was calculated on the tables index made by the same operator who examined 20 children twice, one month apart. A second operator independently collected a third table index for each of the 20 children to assess the inter-examiner error. The Kappa values oscillate between 0.643 and 1.00 in relation to intra-operator concordance (0.00 < p < 0.002), and between 0.773 and 1.00 in relation to inter-operator concordance (p = 0 < 0.001): the index is therefore highly reproducible. After calculating the prevalence of malocclusion on the

Table II. Sample distribution.

	Males	Females	Primary school	Secondary school
N	1375	1642	1529	1488
Prevalence (%)	45.6	54.4	50.7	49.3

basis of the degrees of orthodontic risk determined by the index, we evaluated the prevalence with which bad habits (2w) and mouth breathing (2x) are found in association with sex, macroarea, grade of the index, index items (increased overjet, reduced overjet, anterior or posterior crossbite, open bite, displacement), verifying the statistical significance of this association.

Descriptive analyses were performed using frequencies and percentages and frequency tables for categorical variables. For the bivariate analysis chi-square tests were performed to evaluate differences for categorical variables. The level of significance was set at $p \leq 0.05$. Data were analysed with the software SPSS 19.0 for Windows.

Results

Table III shows the results in the total sample and after stratification according to primary and secondary schools. Variables included in the analysis were “bad habits” (2w) and “mouth breathing” (2x) in relation to socio-demographic characteristics (sex and geographical area of origin) and index grades.

There was no statistically significant association between bad habits/mouth breathing and sex, although differences were present for both geographical area and grade of the index. The prevalence of bad habits and mouth breathing was higher in South Italy and with the increase of the degree of the index an increase in the prevalence of 2w and 2x was also seen, meaning that these factors were associated with more severe malocclusions. Grade 5 does not follow the trend for the small sample due to the low prevalence of syndromic diseases in the population.

In Table IV, “bad habits” (2w) and “mouth breathing” (2x) were related to increased overjet (h), reduced overjet (k), crossbite (n), openbite (o), displacement (p). The table shows that 2w and 2x are both closely related with increased overjet and displacement in all age groups. Reduced overjet, openbite and posterior crossbite was significantly associated only with mouth breathing in both the total sample and in the subgroups (primary and secondary schools), except in primary school children with reduced overjet.

Discussion

Bad habits

Many authors have written about the relationship between bad habits and malocclusion. Oral habits are repetitive behaviour in the oral cavity that result in loss of tooth structure and include digit sucking, pacifier sucking, lip suck-

ing and biting, nail-biting, bruxism, self-injurious habits and tongue thrusting²². Their effect is dependent on the nature, onset and duration of habits. Persistent nonnutritive sucking habits may result in long-term problems and can affect the stomatognathic system, leading to an imbalance between external and internal muscle. Tongue thrusting, an abnormal tongue position with deviation from the normal swallowing pattern, and mouth breathing may be associated with anterior open bite, abnormal speech and anterior protrusion of the maxillary incisors²³. It appears that several factors account for the persistence of infantile swallowing patterns and that tongue thrust plays an important role in the aetiology of openbite as well as in the relapse of treated openbite patients^{24,25}. A study conducted by Viggiano concluded that children with non-nutritive sucking activity and accustomed to using a bottle had more than double the risk of posterior crossbite right from the primary dentition⁵. Warren conducted a study to know about the extent to which nonnutritive sucking habits contribute to malocclusion in the mixed dentition. The authors have found that anterior openbite and posterior crossbite were associated with habits of 36 months or more. Sustained pacifier habits, including those of 24 to 47 months, were associated with anterior openbite and Class II molar relationships, while digit habits were associated with anterior openbite when sustained for 60 months or longer²⁶.

The negative influence of bad habits on occlusion originates in childhood. Bottle feeding and nonnutritive sucking habits have been associated with malocclusions starting from the primary dentition^{4,10}. Several authors have pointed out that bottle-fed children have a strong tendency to develop a pacifier-sucking habit²⁷⁻²⁹. Nonnutritive sucking habits are associated with an atypical swallowing pattern, and with tongue thrusting, which may be related to the development of malocclusions such as posterior crossbite^{4,12}.

According reports by other authors, in our study we found a significant association of bad habits with increased overjet and openbite. Otherwise, no association was found with anterior or posterior crossbite. This may be due to the fact that the biological damages caused by bad habits depend on many factors³⁰: age of initiation, duration, intensity and type, and, above all, individual biological and genetic features³¹⁻³³. The early cessation of bad habits leads spontaneously to structural and functional normalisation, especially if the patient has a eugenic growth direction³⁴.

In this regard, Cozza et al. has linked the pattern of vertical growth and non-nutritive sucking habits with trans-

Table III. 2w and 2x in relation to socio-demographic characteristics. P < 0.005 is statistically significant.

Variable	Total sample					Only primary school					Only secondary school							
	2W n. (%)	OR	P	2X n. (%)	OR	P	2W n. (%)	OR	P	2X n. (%)	OR	P	2W n. (%)	OR	P	2X n. (%)	OR	P
SEX																		
Males	211 (7)	1.021 (0.838- 1.245)	0.84	178 (5.9)	0.0847 (0.679- 1.055)	0.076	126 (8.3)	1.172 (0.904- 1.519)	0.128	117 (7.7)	0.0847 (0.679- 1.055)	0.121	85 (5.7)	0.882 (0.648- 1.202)	0.429	61 (4.1)	0.917 (0.643- 1.309)	0.348
Females	257 (8.5)			184 (6.1)			157 (10.3)			110 (7.2)			100 (6.7)			74 (5)		
Total	468 (15.5)			362 (12)			283 (18.5)			227 (14.9)			185 (12.4)			135 (9.1)		
MACROAREA																		
North	158 (5.2)	-	< 0.05*	91 (3)	-	< 0.05*	89 (5.8)	-	0.077	58 (3.8)	-	< 0.05*	69 (4.6)	-	< 0.05*	33 (2.2)	-	< 0.003*
Centre	114 (3.8)			128 (4.2)			87 (5.7)			80 (5.2)			27 (1.8)			48 (3.2)		
South	196 (6.5)			143 (4.7)			107 (7)			89 (5.8)			89 (6)			54 (3.6)		
Total	468 (15.5)			362 (12)			283 (18.5)			227 (14.8)			185 (12.4)			135 (9.1)		
DEGREE INDEX																		
1	0	-	< 0.05*	3 (0.1)	-	< 0.05*	0	-	< 0.05*	3 (0.2)	-	< 0.05*	0	-	< 0.05*	0	-	< 0.05*
2	74 (2.5)			44 (1.5)			37 (2.5)			29 (1.9)			37 (2.5)			15 (1)		
3	170 (5.6)			130 (4.3)			112 (5.6)			77 (5)			58 (3.9)			53 (3.6)		
4	223 (7.4)			183 (6.1)			133 (7.4)			116 (7.6)			90 (6)			67 (4.5)		
5	1 (0)			2 (0.1)			1 (0)			2 (0.1)			0 (0)			0		
Total	468 (15.5)			362 (12)			283 (18.5)			227 (14.8)			185 (12.4)			135 (9.1)		
TOTAL	3014 (100)			3014 (100)			1527 (100)			1527 (100)			1487 (100)			1487 (100)		

verse maxillary deficit³⁵. The authors concluded that if the habit of sucking in mixed dentition is associated with increased vertical dimension it is significantly associated with a transversal maxillary deficit, with narrow diameters of the upper jaw and increased prevalence of posterior crossbite.

Probably, thus, the risk for children with bad habits to develop a crossbite depends on the genetic pattern of growth, so not all individuals who have bad habits have crossbite or will develop crossbite in the future. Is therefore very important to assess the direction of skeletal growth of the patient with bad habits to determine the degree of risk of developing a malocclusion.

Mouth breathing

The presence of obstruction of the airways, especially at the level of the nose and pharynx, forces the patient to breathe through the mouth³⁶. Allergic rhinitis and adenotonsillar hypertrophy are the main cause of airway obstruction. They are usually associated with various symptoms: lack of nasal airflow, sneezing, itching, runny nose clear, but also snoring, possible obstructive sleep apnoea syndrome (OSAS) and increased respiratory infections such as ear infections, sinusitis and tonsillitis^{37 38}. Mouth breathing due to airway obstruction leads postural changes such as lip incompetence, low position of the tongue in the mouth floor and increased vertical facial height for clockwise rotation of the jaw³⁹.

The association between insufficient nasal breathing and dentofacial morphology has been studied extensively and many authors believe that the pattern of craniofacial growth can be affected by unbalanced muscle function typical of mouth breathing^{14 40 41}. Children with mouth breathing have typical facial features: long face, dark circles, narrow nostrils, transverse contraction of the upper jaw, high arched palate and gummy smile associated with malocclusion of class II or, sometimes, class III, with a high prevalence of posterior crossbite and anterior openbite^{15 16 42 43}. Children who mouth breath and who rotate the mandible in a posterior and inferior direction develop a Class II malocclusion and a skeletal Class II profile with increased overjet. In fact, the muscles which depress the jaw to open the mouth exert a backward pressure upon it which displaces the mandible distally and retard its growth. The buccinator muscles are made tense by opening the mouth and tend to exert lingual pressure on the maxillary bicuspid and molars, which do not receive sufficient support from the tongue, so that the palate and the upper dental arch becomes quite narrow. Lip function is abnormal, the lower lip being large and bulbous and the upper lip short and functionless, with often lower lip forced up under the upper incisor, that are further protruded with increased overjet. Bresolin et al. found that mouth breathers had longer faces with a narrower maxilla and retrognathic jaws^{44 45} and Trask found that allergic

children who were mouth breathers had longer and more retrusive faces than nasal breather children⁴⁶.

In the opinion of Rakosi and Schilli, mouth breathing may have a role in the aetiopathogenesis of some forms of Class III malocclusion. Oral breathing children have constantly open jaw and a low posture of the tongue with excessive mandibular growth, with constant distraction of the mandibular condyle from the fossa which may be a growth stimulus⁴⁷. In addition, the lack of thrust of the tongue on the palate and on the upper jaw may cause a sagittal and transverse maxillary skeletal deficit, a Class III malocclusion with reduced or reverse overjet.

Many authors also found that mouth breathers have a high prevalence of narrow dental arches and dental crowding^{15 48}, especially considering the upper arch⁴⁹.

The results of our study agree fully with literature reports: we found that mouth breathing is closely related to increased overjet, reduced overjet, anterior or posterior crossbite, openbite and displacement. Therefore, it is necessary to intervene early on aetiological factors of mouth breathing to prevent the development or worsening of malocclusion and, if already developed, to correct it by early orthodontic treatment to promote eugenic skeletal growth. Early orthodontic treatments in these young patients are needed to modify skeletal malocclusions: more stable results are achievable, less extractions of permanent teeth are needed with increased parental satisfaction and the length of orthodontic treatments in permanent dentition is sensibly reduced with lower risks of enamel decalcifications and gum diseases after treatment⁵⁰⁻⁵².

Conclusions

The scientific community acknowledges that bad habits and oral breathing have a role in the aetiopathogenesis of malocclusions, and their association is confirmed herein. Mouth breathing and bad habits can be considered as risk factors of malocclusion because they change the physiological balance of growth. However, while mouth breathing is always significantly associated with all occlusal problems examined, bad habits have a significant role only in some, probably because of their lower relevance than other factors implicated in the aetiopathogenesis of malocclusions. Thus, we can assume that the "risk of developing malocclusion" related to bad habits would be expressed in individuals more susceptible to genetic causes and unfavourable growth pattern.

Nonetheless, we believe that for these type of problems close collaboration is needed between different specialists (paediatrician, allergist, ENT specialist, orthodontist, speech therapist) and that early orthodontic visits and treatment, when needed in children with bad habits or with allergic rhinitis and/or adeno-tonsillar hypertrophy will allow early detection and timely treatment of dysfunctions and avoid worsening of already established malocclusions.

Table IV. 2w and 2x in relation to increased overjet (h), reduced overjet (k), cross bite (n), displacement (o), openbite (p).

Variable	Total sample						Only primary school						Only secondary school					
	2W n. (%)	OR	P	2X n. (%)	OR	P	2W n. (%)	OR	P	2X n. (%)	OR	P	2W n. (%)	OR	P	2X n. (%)	OR	P
H	2 197 (6.5)	1.589 (1.299- 1.944)	<0.001*	168 (5.6)	1.907 (1.527- 2.382)	<0.001*	127 (8.3)	1.382 (1.064- 1.793)	0.009*	117 (7.7)	1.870 (1.408- 2.484)	< 0.001*	70 (4.7)	1.738 (1.260- 2.398)	< 0.001*	51 (3.4)	1.694 (1.172- 2.448)	0.004*
Total	468 (15.5)			362 (12)			283 (18.5)			227 (14.8)			185 (12.4)			135 (9.1)		
k	3 48 (1.6)	1.186 (.854- 1.648)	0.175	42 (1.4)	1.384 (.976- 1.962)	0.045*	30 (2)	1.212 (.792- 1.856)	0.217	24 (1.6)	1.197 (.753- 1.904)	0.257	18 (1.2)	1.135 (.673- 1.915)	0.359	18 (1.2)	1.688 (.991- 2.875)	0.042*
Total	468 (15.5)			362 (12)			283 (18.5)			227 (14.8)			185 (12.4)			135 (9.1)		
n	2 85 (2.8)	1.008 (.780- 1.302)	0.498	103 (3.4)	1.991 (1.551- 2.557)	<0.001*	52 (3.4)	.920 (.660- 1.281)	0.344	73 (4.8)	2.281 (1.667- 3.121)	< 0.001*	33 (2.2)	1.099 (.734- 1.645)	0.357	30 (2)	1.488 (.967- 2.289)	0.048*
Total	468 (15.5)			362 (12)			283 (18.5)			227 (14.8)			185 (12.4)			135 (9.1)		
o	2 249 (8.3)	1.117 (.917- 1.360)	0.148	214 (7.1)	1.460 (1.168- 1.825)	<0.001*	157 (10.3)	1.169 (.902- 1.515)	0.133	141 (9.2)	1.600 (1.198- 2.137)	0.001*	92 (6.2)	1.015 (.746- 1.382)	0.492	73 (4.9)	1.229 (.862- 1.753)	0.147
Total	468 (15.5)			362 (12)			283 (18.5)			227 (14.8)			185 (12.4)			135 (9.1)		
p	2 70 (2.3)	3.299 (2.421- 4.497)	<0.001*	49 (1.6)	2.614 (1.855- 3.685)	<0.001*	38 (2.5)	3.120 (2.029- 4.798)	<0.001*	24 (1.6)	1.990 (1.226- 3.231)	0.006*	32 (2.2)	3.684 (2.347- 5.782)	< 0.001*	25 (1.7)	3.76 6(2.304- 6.156)	< 0.001*
Total	468 (15.5)			362 (12)			283 (18.5)			227 (14.8)			185 (12.4)			135 (9.1)		

References

- ¹ Linder-Aronson S. *Adenoids: their effects on mode of breathing and nasal air flow and their relationship to characteristics of the facial skeleton and the dentition. A biometric, rhino-manometric and cephalometro-radiographic study on children with and without adenoids.* Acta Otolaryngol Suppl 1970;265:1-132.
- ² Linder-Aronson S. *Orthodontics in the Swedish Public Dental Health System.* Transactions of the European Orthodontic Society 1974, pp. 233-40.
- ³ Brin I, Zwilling-Sellan O, Harari D, et al. *Does a secular trend exist in the distribution of occlusal patterns?* Angle Orthod 1998;68:81-4.
- ⁴ Vázquez-Nava F, Quezada-Castillo JA, Oviedo-Treviño S, et al. *Association between allergic rhinitis, bottle feeding, non-nutritive sucking habits, and malocclusion in the primary dentition.* Arch Dis Child 2006;91:836-40.
- ⁵ Viggiano D, Fasano D, Monaco G et al. *Breast feeding, bottle feeding and non-nutritive sucking; effects on occlusion in deciduous dentition.* Arch Dis Child 2004;89:1121-3.
- ⁶ Larsson E. *Artificial sucking habits: Etiology, prevalence and effect on occlusion.* Int J Orofacial Myology 1994;20:10-21.
- ⁷ Larsson E. *Sucking, chewing and feeding habits and the development of crossbite: A longitudinal study of girls from birth to 3 years of age.* Angle Orthod 2001;71:116-9.
- ⁸ Warren JJ, Bishara SE, Steinbock KL. *Effects of oral habits' duration on dental characteristics in the primary dentition.* J Am Dent Assoc 2001;132:1685-93.
- ⁹ Castelo PM, Gavião MB, Pereira LJ, et al. *Maximal bite force, facial morphology and sucking habits in young children with functional posterior crossbite.* J Appl Oral Sci 2010;18:143-8.
- ¹⁰ Melink S, Vagner MV, Hocevar-Boltezar I, et al. *Posterior crossbite in the deciduous dentition period, its relation with sucking habits, irregular orofacial functions, and otolaryngological findings.* Am J Orthod Dentofacial Orthop 2010;138:32-40.
- ¹¹ Carrascoza KC, Possobon RF, Tomita LM, et al. *Consequences of bottle-feeding to the oral facial development of initially breastfed children.* J Pediatr Rio J 2006;82:395-7.
- ¹² Ovsenik M. *Incorrect orofacial functions until 5 years of age and their association with posterior crossbite.* Am J Orthod Dentofacial Orthop 2009;136:375-81.
- ¹³ Warren DW. *Effect of airway obstruction upon facial growth.* Otolaryngol Clin North Am 1990;23:699-712.
- ¹⁴ Harvold EP, Tomer BS, Vargervik K, et al. *Primate experiments on oral respiration.* Am J Orthod 1981;79:359-72.
- ¹⁵ Harari D, Redlich M, Miri S, et al. *The effect of mouth breathing versus nasal breathing on dentofacial and craniofacial development in orthodontic patients.* Laryngoscope 2010;120:2089-93.
- ¹⁶ Souki BQ, Pimenta GB, Souki MQ et al. *Prevalence of malocclusion among mouth breathing children: do expectations meet reality?* Int J Pediatr Otorhinolaryngol 2009;73:767-73.
- ¹⁷ Jefferson Y. *Mouth breathing: adverse effects on facial growth, health, academics, and behavior.* Gen Dent 2010;58:18-25.
- ¹⁸ Grippaudo C, Paolantonio EG, Deli R, et al. *Validation of the Risk Of Malocclusion Assessment (ROMA) Index.* Eur J Paediatr Dent 2007;8:136-42.
- ¹⁹ Grippaudo C, Pantanali F, Paolantonio EG, et al. *Prevalence of malocclusion in Italian schoolchildren and orthodontic treatment need.* Eur J Paediatr Dent 2013;14:314-8.
- ²⁰ Grippaudo C, Pantanali F, Paolantonio EG, et al. *Orthodontic treatment timing in growing patients.* Eur J Paediatr Dent 2013;14:231-6.
- ²¹ Brook PH, Shaw WC. *The development of an index of orthodontic treatment priority.* Eur J Orthod 1989;11:309-320.
- ²² Garde JB, Suryavanshi RK, Jawale BA et al. *An epidemiological study to know the prevalence of deleterious oral habits among 6 to 12 year old children.* J Int Oral Health 2014;6:39-43.
- ²³ Dean JA, McDonald RE, Avery DA. *Managing the developing occlusion.* St. Louis, Mo: Mosby and Co. 2000, pp. 178-217.
- ²⁴ Graber TM. *The 'three Ms': muscles, malformation, and malocclusion.* Am J Orthod 1963;49:418-50.
- ²⁵ Graber TM, Rakosi T, Petrovic AG. *Dentofacial orthopedics with functional appliances.* 1st Edition. St. Louis, MO: Mosby 1985.
- ²⁶ Warren JJ, Slayton RL, Bishara SE, et al. *Effects of nonnutritive sucking habits on occlusal characteristics in the mixed dentition.* Pediatr Dent 2005;27:445-50.
- ²⁷ Telles FBA, Ferreira RI, Magalhães LNC, et al. *Effect of breast- and bottle-feeding duration on the age of pacifier use persistence.* Braz Oral Res 2009;23:432-8.
- ²⁸ Charchut SW, Allred EN, Needleman HL. *The effects of infant feeding patterns on the occlusion of the primary dentition.* J Dent Child 2003;70:197-203.
- ²⁹ Meyers A, Hertzberg J. *Bottle-feeding and malocclusion: is there an association?* Am J Orthod Dentofacial Orthop 1988;93:149-52.
- ³⁰ Graber TM, Chung DDB, Aoba JT. *Dentofacial orthopedics versus orthodontics.* J Am Dent Assoc 1969;75:1145-66.
- ³¹ Demir A, Uysal T, Basciftci FA et al. *The association of occlusal factors with masticatory muscle tenderness in 10- to 19-year old Turkish subjects.* Angle Orthod 2005;75:40-6.
- ³² Kayukawa H. *Malocclusion and masticatory muscle activity: a comparison of four types of malocclusion.* J Clin Pediatr Dent 1992;16:162-77.
- ³³ Esteves A, Bommarito S. *Evaluation of palatine depth and dimensions of the upper dental arch in patients with malocclusion and different facial types.* Rev Dent Press Orthodon Ortop Facial 2007;12:84-98.
- ³⁴ Levrini A. *Le abitudini viziate.* Quaderni di Odontoiatria Infantile Elsevier vol. 3, 1989.
- ³⁵ Cozza P, Baccetti T, Franchi L et al. *Transverse features of subjects with sucking habits and facial hyperdivergency in the mixed dentition.* Am J Orthod Dentofacial Orthop 2007;132:226-9.
- ³⁶ Valera FC, Travitzki LV, Mattar SE, et al. *Muscular, functional and orthodontic changes in preschool children with enlarged adenoids and tonsils.* J Pediatr Otorhinolaryngol 2003;67:761-70.
- ³⁷ Skoner DP. *Allergic rhinitis: definition, epidemiology,*

- pathophysiology, detection, and diagnosis.* J Allergy Clin Immunol 2001;108:S2-8.
- ³⁸ Bellanti JA, Wallerstedt DB. *Allergic rhinitis update: epidemiology and natural history.* Allergy Asthma Proc 2000;21:367-70.
- ³⁹ Sousa JB, Anselmo-Lima WT, Valera FC et al. *Cephalometric assessment of the mandibular growth pattern in mouth-breathing children.* J Pediatr Otorhinolaryngol 2005;69:311-7.
- ⁴⁰ Solow B, Kreiborhg S. *Soft tissue stretching: a possible control factor in craniofacial morphogenesis.* J Dent Res 1977;505-7.
- ⁴¹ Rubin RM. *Mode of respiration and facial growth.* Am J Orthod 1980;78:504-10.
- ⁴² Mocellin M, Fugmann EA, Gavazzoni FB. *Estudo cefalometrico- radiografico e otorrinolaringologico correlacionado o grau de obstrucao nasal e o padrao de crescimento facial em pacientes nao tratados ortodonticamente.* Rev Bras Otorrinolaringol 2000;66:116-120.
- ⁴³ Reed E, Kiebach TJ, Martin C, et al. *Stability of early class III orthopedic treatment.* Semin Orthod 2014;20:114-27.
- ⁴⁴ Bresolin D, Shapiro PA, Shapiro GG, et al. *Mouth breathing in allergic children: Its relationship to dentofacial development.* Am J Orthod 1983;83:334-34.
- ⁴⁵ Bresolin D, Shapiro GG, Shapiro PA, et al. *Facial characteristics of children who breathe through the mouth.* Pediatrics 1984;73:622-625.
- ⁴⁶ Trask GM, Shapiro GG, Shapiro PA. *The effects of perennial allergic rhinitis on dental and skeletal development: a comparison of sibling pairs.* Am J Orthod Dentofacial Orthop 1987;92:286-293.
- ⁴⁷ Rakosi T, Schilli W. *Class III anomalies: a coordinated approach to skeletal, dental, and soft tissue problems.* J Oral Surg 1981;39:860-70.
- ⁴⁸ Vig KW. *Nasal obstruction and facial growth: the strength of evidence for clinical assumptions.* Am J Orthod Dentofacial Orthop 1998;113:603-11.
- ⁴⁹ Wagaiyu EG, Ashley FP. *Mouth breathing, lip seal and upper lip coverage and their relationship with gingival inflammation in 11-14 year-old schoolchildren.* J Clin Periodontol 1991;18:698-702.
- ⁵⁰ King GJ, Keeling SD, Hocevar RA et al. *The timing of treatment for Class II malocclusions in children: a literature review.* Angle Orthod 1990;60:87-97.
- ⁵¹ Kluemper GT, Beeman CS, Hicks EP. *Early orthodontic treatment: what are the imperatives?* J Am Dent Assoc 2000;131:613-20.
- ⁵² Musich D, Busch MJ. *Early orthodontic treatment: current clinical perspectives.* Alpha Omegan 2007;100:17-24.

Received: July 10, 2015 - Accepted: March 26, 2016

Address for correspondence: Cristina Grippaudo, Catholic University of Sacred Heart, Department of Surgical Sciences for Disorders of the Head and Neck - Institute of Dentistry, "A. Gemelli" Hospital, largo A. Gemelli 1, 00168 Rome, Italy. Tel. +39 06 30154286. E-mail: cristina.grippaudo@unicatt.it

PHONIATRY

Comparison between videofluoroscopy, fiberoptic endoscopy and scintigraphy for diagnosis of oro-pharyngeal dysphagia

Confronto tra videofluoroscopia, endoscopia a fibre ottiche e scintigrafia per la diagnosi di disfagia oro-faringea

B. FATTORI¹, P. GIUSTI², V. MANCINI¹, M. GROSSO³, M.R. BARILLARI⁴, L. BASTIANI⁵, S. MOLINARO⁵, A. NACCI¹

¹ ENT, Audiology and Phoniatric Unit, Department of Neurosciences, University of Pisa, Italy; ² Department of Diagnostic and Interventional Radiology, University of Pisa, Italy; ³ Regional Centre of Nuclear Medicine, Azienda Ospedaliera Universitaria Pisana, Pisa, Italy; ⁴ Audiology and Phoniatric Unit, University of Napoli 2, Italy; ⁵ Institute of Clinical Physiology of the Italian National Research Council (IFC-CNR), Pisa, Italy

SUMMARY

The purpose of this study was to compare videofluoroscopy (VFS), fiberoptic endoscopic evaluation of swallowing (FEES) and oro-pharyngo-oesophageal scintigraphy (OPES) with regards to premature spillage, post-swallowing residue and aspiration to assess the reliability of these tests for detection of oro-pharyngeal dysphagia. Sixty patients affected with dysphagia of various origin were enrolled in the study and submitted to VFS, FEES and OPES using a liquid and semi-solid bolus. As a reference, we used VFS. Both the FEES and the OPES showed good sensitivity with high overall values ($\geq 80\%$ and $\geq 90\%$ respectively). The comparison between FEES vs VFS concerning drop before swallowing showed good specificity (84.4% for semi-solids and 86.7% for liquids). In the case of post-swallowing residue, FEES vs VFS revealed good overall validity (75% for semi-solids) with specificity and sensitivity well balanced for the semi-solids. OPES vs. VFS demonstrated good sensitivity (88.6%) and overall validity (76.7%) for liquids. The analysis of FEES vs. VFS for aspiration showed that the overall validity was low ($\leq 65\%$). On the other hand, OPES demonstrated appreciable overall validity (71.7%). VFS, FEES and OPES are capable of detecting oro-pharyngeal dysphagia. FEES gave significant results in the evaluation of post-swallowing residues.

KEY WORDS: Dysphagia • Videofluoroscopy • Fiberoptic Endoscopic Evaluation of Swallowing • Oro-pharyngo-oesophageal Scintigraphy • Speech-language pathology

RIASSUNTO

L'obiettivo di questo studio era quello di confrontare la Videofluoroscopia (VFS), la valutazione endoscopica a fibre ottiche della deglutizione (FEES) e la scintigrafia oro-faringo-esofagea (OPES) per quanto riguarda la caduta pre-deglutitoria, il ristagno post-deglutitorio e l'aspirazione, al fine di valutare l'attendibilità di questi test nel rilevare la disfagia orofaringea. Sessanta pazienti, affetti da disfagia di varia origine, sono stati arruolati nello studio e sottoposti a VFS, FEES e OPES utilizzando un bolo liquido e uno semi-solido. Abbiamo usato la VFS come esame di riferimento. La FEES e la OPES hanno entrambe mostrato una buona sensibilità, con valori complessivi elevati (rispettivamente $\geq 80\%$ e $\geq 90\%$). Il confronto tra FEES e VFS relativamente alla caduta pre-deglutitoria ha evidenziato una buona specificità (84,4% per i semi-solidi e 86,7% per i liquidi). Nel caso di ristagni post-deglutitori, il confronto tra FEES e VFS ha rivelato una buona validità complessiva (75% per i semi-solidi), con specificità e sensibilità ben equilibrate per i semi-solidi. Il confronto tra OPES e VFS ha dimostrato buona sensibilità (88,6%) e validità complessiva (76,7%) per i liquidi. Il confronto dei dati ottenuti tra FEES e VFS, relativamente all'aspirazione, ha evidenziato una bassa validità complessiva ($\leq 65\%$). D'altra parte, la OPES ha mostrato una validità complessiva apprezzabile (71,7%). VFS, FEES e OPES sono in grado di rilevare la disfagia oro-faringea. La FEES ha fornito risultati significativi nella valutazione dei ristagni post-deglutitori.

PAROLE CHIAVE: *Disfagia • Videofluoroscopia • Valutazione endoscopica a fibre ottiche della deglutizione • Scintigrafia orofaringoesofagea • Foniatria*

Acta Otorhinolaryngol Ital 2016;36:395-402

Introduction

Videofluoroscopy (VFS), fiberoptic endoscopic evaluation of swallowing (FEES) and oro-pharyngo-oesophageal scintigraphy (OPES) are all widely used tools for studying swallowing disorders in the oro-pharyngeal area. While VFS is

still considered by speech-language pathologists to be the gold standard, there are numerous reports in the literature that emphasise the validity of the other two methods¹⁻⁵. Accurate assessment of the oro-pharyngeal phase of swallowing is particularly important since this presents the greatest clinical risk for dysphagic patients: tracheo-bronchial

aspiration. Furthermore, early diagnosis of oro-pharyngeal dysphagia can prevent malnutrition and dehydration in the patient, as well as avoiding significant impairment to the quality of his life. In the literature there are numerous studies that compare the efficacy of the various diagnostic tools for detecting penetration and aspiration⁶⁻¹⁵. Some authors demonstrated a good agreement between VFS and FEES, especially regarding aspiration (82.3-90% agreement); the analysis of FEES vs. VFS showed that the sensitivity of FEES was 88% and specificity was overall lower, but was 92% for detection of aspiration^{11 13 14}. In 2003, Rao et al.¹⁵ studied sensitivity and specificity values for laryngeal penetration, tracheal aspiration and pharyngeal residue for both the VFS and FEES. When the VFS was used as the gold standard, sensitivity of the FEES for laryngeal penetration was 87%, aspiration 96% and pharyngeal residue 68%. Specificity of the FEES for laryngeal penetration and aspiration were both 100%, and pharyngeal residue was 98%. When the FEES was used as the gold standard, sensitivity of the VFS for laryngeal penetration and aspiration were both 100%, and pharyngeal residue was 96%. Specificity of the VFS for laryngeal penetration was 58%, aspiration 63% and pharyngeal residue 78%¹⁵.

There are few data in the literature regarding the OPES. In 2004, Shaw et al.⁵ calculated that the specificity of the OPES retention indices for liquid boluses is 100% in the oral area and 96% in the pharynx, while sensitivity in these areas is low (being 72% and 57%, respectively). More recently, Huang et al.⁹ studied the correlation between OPES and VFS; scintigraphy parameters had good predictive value for VFS findings, with sensitivity, specificity, positive predictive values and negative predictive values between 70% and 95%. OPES had good sensitivity in detecting 91% of aspirations and 81% of penetrations and/or aspirations in VFS, while the specificity was lower⁹.

There are few reports in the literature that take into account other parameters that are equally important for a precise definition of swallowing efficiency and, in particular, the degree of oro-pharyngeal dysphagia^{5 8 9 16-18}. In fact, by assessing the pre-swallowing presence of a bolus in the pharynx, the presence and amount of residue in the hypo-pharyngeal area, we can more accurately estimate the efficacy of this oro-pharyngeal phase and consequently the risks involved in penetration and aspiration, even if these events are not immediate but later in time after the administration of the bolus^{16 19}.

These parameters (premature spillage, post swallowing residue and aspiration) can be assessed with all three of the above-mentioned methods; in this respect, we compared them to see if any one of these methods was better suited for overall clinical evaluation of the oro-pharyngeal phase of swallowing and if there was any correspondence among the various parameters studied with the three tests. In our study, the three methods (VFS, FEES and OPES) were performed on the same day.

Materials and methods

For this study we enrolled 60 dysphagic patients (22 females and 38 males; mean age 63.66 yrs \pm 16.5 SD) who were referred to the unit for dysphagia studies of Pisa University Hospital between January and April 2014. The disorders behind the dysphagia were neurological in 34 (56.7%), post-surgical for head-neck cancer in 15 (25%) gastroenterological with pharyngeal-laryngeal reflux in 7 (11.6%) and pneumological with bronchial-pulmonary disease in 4 (6.7%). The mean onset of the dysphagia was 1.5 years (1.2 SD) prior to the study. All the patients enrolled in the study were collaborative and capable of maintaining good postural alignment. None had undergone any type of speech rehabilitation and none had to use either a NGFT or a PEG. Furthermore, none of the patients referred an allergy to drugs, to suffer from favism or to be pregnant. All patients were submitted to FEES, VFS and OPES performed with both a liquid bolus (5 cc water) and a semi-solid one (5 cc jellied drink, Bevanda Gelificata, Novartis S.A.[®]).

The first test was always performed with the FEES since these were first-time patients in our dysphagia surgery in the ENT, Audiology and Phoniatic Unit. Moreover, the operators who performed and reported the results of the individual tests (FEES, VFS and OPES) were unaware of the results of the other investigations. The parameters we took into account for all three of the tests were: presence of premature spillage, presence and amount of post-swallowing residue in the hypo-pharyngeal area, presence of tracheo-bronchial aspiration (Table I)²⁰⁻²³.

Informed consent was obtained from all participants and the study was approved by the Ethical Research Committee of the University Hospital of Pisa.

Fiberoptic endoscopic evaluation of swallowing (FEES)

FEES is performed with a flexible fiberoptic rhinopharyngolaryngoscope (Olympus ENF-P3) connected to a CCD camera and colour monitor and recorded digitally on a Digital Swallowing Workstation (Kay Pentax Ltd[®], Montvale, NJ, USA). The examination was carried out by two speech-language pathologists and each patient was administered two or more semi-solid (jellied drink, Bevanda Gelificata, Novartis S.A.[®]) or liquid boluses (water marked with methylene blue for easy detection), swallowing 5 cc of each type of bolus. Evaluation of pre-swallowing penetration and aspiration was given Score 0 if it was absent and Score 1 if it was present. The amount of the residue (pooling amount) in the hypopharynx was calculated against the Farneti pooling-score scale^{21 22} (Table I).

Videofluoroscopy (VFS)

The digital fluoroscopy examinations were performed with a Clinodigit Compact Xframe Italray device. The digital images were acquired by filming at a frame rate of

Table I. OPES - VFS - FEES Ratio Score.

	Premature spillage		Aspiration	
ABSENT	0		0	
PRESENT	1		1	
Hypopharyngeal residue	None	Mild	Moderate	Severe
VFS ⁽²⁰⁾	0 ($< 3\%$)	1 (≥ 3 to $< 25\%$)	2 (≥ 25 to $< 55\%$)	3 ($\geq 55\%$)
OPES ⁽²³⁾	0 ($< 5\%$)	1 (≥ 5 to $< 20\%$)	2 (≥ 20 to $< 40\%$)	3 ($\geq 40\%$)
FEES ⁽²¹⁻²²⁾	0	1	2	3

30/sec, which was sufficient for recording the swallowing act. Acquisition resolution was 3001x3001x14 bit.

Digitalised imaging permits the creation of a PACS (picture archiving and communication system), which is a computerised system where the images are uploaded, together with the relative data supplied by the various diagnostic tools available in the hospital, thus allowing the images to be archived and shared. Furthermore, the PACS permits viewing information concerning any previous investigation the patient has been submitted to whenever a new examination has become necessary. Patients are initially positioned in the lateral view, and regions of visualisation include the oral cavity, pharyngeal cavity larynx and cervical oesophagus. The patient is then positioned in the anterior-posterior (i.e. frontal) viewing plane so that judgments may be made regarding symmetry of bolus flow, pharyngeal wall contraction and symmetry of structure and function when viewing bolus flow²⁴. Dynamic recording at a minimum of 30 video frames/sec is essential for detecting the rapid movements and bolus flow events associated with oropharyngeal swallowing. The possibility to perform an accurate evaluation with freeze-frame and slow motion capability must be allowed²⁴. An image is enlarged on the neck region of the patient in an orthostatic latero-lateral position, and the contrast medium is administered. The contrast medium used was Prontobarrio HD (Bracco®): the packaging supplied contains 340 g powder for oral suspension, 98.45% barium sulphate. The powder is diluted in 65 ml of water for the liquid consistency and in 30 ml of water for the semi-solid bolus; for each density, the patient is invited to take three sips of 5 cc.

The fluoroscope is activated at the time of administration of the contrast bolus and is deactivated immediately after the bolus has passed through the upper oesophageal sphincter in order to minimise exposure. The total radiation exposure it is fairly constant and is similar to the amount typically encountered in an upper gastrointestinal series. The examination may be extended depending on nature and severity of the patient's swallowing problem and condition, although the goal of minimising radiation exposure while maximising clinical results is consistently maintained²⁴.

Oro-pharyngo-oesophageal scintigraphy (OPES)

In the OPES investigation, the patient's face is in an 80° oblique projection on front of a single rectangular headed large-field-of-view (LFOV) gamma camera equipped with a low energy-high resolution (LEHR) parallel hole collimator using a 140 KeV ($\pm 10\%$) energy window. Prior to the marked bolus, patients were given 5 cc of the non-marked bolus to allow them to practice taking it before the actual investigation. The patient is administered a single bolus of 5 cc of water marked with 37 MBq (1 mCi) of ^{99m}Tc nanocolloid (Nanocoll-Amersham®, UK). Eight images per sec (0.125 sec/frame) are acquired for one min, by means of dynamic acquisitions (with a 64 x 64 matrix and zoom at 1), including the oral region as far as the epigastric area within the imaging field. The pharyngeal region of interest (ROI) was that between the oral cavity and the external reference corresponding to the pharyngo-oesophageal transition. An external marker was positioned at mandibular angle level and another one at the level of the cricoid²⁵. Two sec after the start, the patient is invited to take the liquid bolus in one swallow. At the end of the test, a static image lasting 60 sec is acquired, with the patient still in the same position, to evaluate any possible tracheo-bronchial aspiration. After an interval of 30 min, the procedure is repeated, but this time with a semi-solid bolus marked with 37 MBq (1 mCi) of ^{99m}Tc nanocolloid. The acquisitions were obtained with the same method as with the liquid bolus.

Statistical analysis

Analyses were carried out with the SPSS statistical package (version 20). Descriptive statistics were performed to describe a sample characteristic (age, gender and the time of onset of dysphagia). Sensitivity, specificity, positive predictive value (PPV), negative predictive value (NPV) and validity, for FEES and OPES, were determined by comparing to the gold standard (VFS), both in the liquid and semi-solid tests. Furthermore, with the same indices (sensitivity, specificity, PPV, NPV and validity), the OPES method was compared to FEES, considering the latter as the gold standard (Table II).

Table II. Results of a diagnostic test presented as a 2x2 table.

Result of diagnostic tests	Results of Gold Standard Test	
	Disease present	Disease absent
Test positive	True positive (a)	False positive (b)
Test negative	False negative (c)	True negative (d)

$Sensitivity = a/a+c$

$Specificity = d/b+d$

$PPV = Sensitivity * \pi / Sensitivity * \pi + (1 - Specificity) * (1 - \pi)$

$NPV = Specificity * (1 - \pi) / Specificity * (1 - \pi) + (1 - Sensitivity) * \pi$

$Validity = (True\ positive + True\ negative) / (True\ positive + True\ negative + False\ positive + False\ negative)$

Results

The first evaluation carried out was to assess the ability of the three tests (VFS; OPES; FEES) to detect the presence of swallowing alterations. As a reference value, we initially used the VFS since this is the gold standard. FEES showed good sensitivity with both semi-solids (85.2%) and liquids (80.4%), and the overall validity of the test was 83.3% and 80%, respectively. OPES also demonstrated good sensitivity with semi-solids (96.3%) and liquids (94.1%), with an overall validity of the test of 93.3% and 90%, respectively (Table III and Table IV).

The comparison between OPES and FEES in the detection of dysphagia gave high sensitivity values (> 97.9%) and a high overall validity (> 83%) for both densities considered.

We then evaluated the parameters of the study on oropharyngeal dysphagia: premature spillage, hypopharyngeal residue and aspiration.

The premature spillage parameter in the case of FEES vs VFS showed good specificity with both semi-solids (84.4%) and liquids (86.7%), but sensitivity values were low (both equal to 60%) and the overall validity of the test was 78.3% in the case of semi-solids and 80% with liquids (Table III and Table IV). OPES showed the highest specificity (95.6% with both semi-solids and liquids) and an overall validity at 81.7% for semi-solids and 85% for liquids, but very low sensitivity values (40% and 53.3%, respectively).

The comparison between OPES and FEES gave a specificity of 86% for liquids and 95.5% for semi-solids, but sensitivity was low (37.5%).

Post-swallowing hypopharyngeal residue. The FEES vs. VFS assessment gave a good overall validity (75%), with the specificity and sensitivity values being well balanced in the case of semi-solids; the overall validity for the liquids was lower (65%). OPES vs. VFS showed a low overall validity in the case of semi-solids (43%), while in the

Table III. The sensitivity, specificity, predictive positive value (PPV), predictive negative value (PNV) and validity in the three tests (VFS; FEES; OPES) with semi-solid boluses.

	Semisolid				
	Sensitivity	Specificity	PPV	NPV	Validity
FEES vs VFS	85.2	66.7	95.8	33.3	83.3
OPES vs VFS	96.3	66.7	96.3	66.7	93.3
OPES vs FEES	97.9	41.7	87.0	83.3	86.7
FEES vs. VFS					
	Sensitivity	Specificity	PPV	NPV	Validity
Premature spillage	60.0	84.4	56.3	86.4	78.3
Hypopharyngeal residue	75.6	73.3	89.5	50.0	75.0
Aspiration	33.3	87.9	69.2	61.7	63.3
OPES vs. VFS					
	Sensitivity	Specificity	PPV	NPV	Validity
Premature spillage	40.0	95.6	75.0	82.7	81.7
Hypopharyngeal residue	33.3	73.3	78.9	26.8	43.3
Aspiration	63.0	78.8	70.8	72.2	71.7
OPES vs. FEES					
	Sensitivity	Specificity	PPV	NPV	Validity
Premature spillage	37.5	95.5	75.0	80.8	80.0
Hypopharyngeal residue	36.8	77.3	73.7	41.5	51.7
Aspiration	76.9	70.2	41.7	91.7	71.7

Table IV. The sensitivity, specificity, predictive positive value (PPV), predictive negative value (PNV) and validity in the three tests (VFS; FEES; OPES) with both liquid boluses.

	Liquid				
	Sensitivity	Specificity	PPV	NPV	Validity
FEES vs VFS	80.4	77.8	95.3	41.2	80.0
OPES vs VFS	94.1	66.7	94.1	66.7	90.0
OPES vs FEES	97.7	47.1	82.4	88.9	83.3
	FEES vs. VFS				
	Sensitivity	Specificity	PPV	NPV	Validity
Premature spillage	60.0	86.7	60.0	86.7	80.0
Hypopharyngeal residue	61.4	75.0	87.1	41.4	65.0
Aspiration	37.0	87.9	71.4	63.0	65.0
	OPES vs. VFS				
	Sensitivity	Specificity	PPV	NPV	Validity
Premature spillage	53.3	95.6	80.0	86.0	85.0
Hypopharyngeal residue	88.6	43.8	81.3	58.3	76.7
Aspiration	51.9	72.7	60.9	64.9	63.3
	OPES vs. FEES				
	Sensitivity	Specificity	PPV	NPV	Validity
Premature spillage	80.0	86.0	53.3	95.6	85.0
Hypopharyngeal residue	96.8	41.4	63.8	92.3	71.7
Aspiration	71.4	71.7	43.5	89.2	71.7

case of liquids the sensitivity was good (88.6%), as was the overall validity (76.7%). The results of the comparison between OPES and FEES were poor, showing that the best results are obtained with the VFS test.

Aspiration. FEES vs. VFS demonstrated a low overall validity of the test both with semi-solids (63.3%) and liquids (65%). In contrast, OPES showed a fairly good overall validity (71.7%), with a balance between sensitivity and specificity values for both the densities tested.

The number and relative percentage of the subjects in the study who were positive (pathological) for premature spillage, hypopharyngeal residue and aspiration in the FEES, VFS and OPES tests with liquid and semi-solid boluses, respectively, are given in Table V.

Discussion

For years, VFS has been considered by speech-language pathologists as the gold standard test for studying oro-pharyngeal dysphagia. Recently, however, its role has been debated, principally because of the introduction of other diagnostic tools for studying swallowing in the clinical field, such as videoendoscopy (FEES) and oro-pharyngo-oesophageal scintigraphy (OPES)^{2 3 5 23-30}. Hence, VFS, FEES and OPES are three important tests for the early detection of dysphagia and all three should be taken into account when oro-pharyngeal dysphagia is suspected and/or when it is necessary to programme strict follow-up^{15 17}. The importance of early diagnosis of dysphagia and the consequent care of the patient is linked with the need to

Table V. The number and relative percentage of the subjects in the study who resulted to be positive (pathological) for premature spillage, hypopharyngeal residue and aspiration in the FEES, VFS and OPES tests with liquid and semi-solid boluses, respectively.

	Liquid		
	FEES	VFS	OPES
Premature spillage	15/60 (25%)	15/60 (25%)	10/60 (16.7%)
Hypopharyngeal residue	31/60 (51.7%)	44/60 (73.3%)	48/60 (80%)
Aspiration	14/60 (23.3%)	27/60 (45%)	23/60 (38.3%)
	Semi-solid		
	FEES	VFS	OPES
Premature spillage	16/60 (26.7%)	15/60 (25%)	8/60 (13.3%)
Hypopharyngeal residue	38/60 (63.3%)	45/60 (75%)	19/60 (31.7%)
Aspiration	13/60 (21.7%)	27/60 (45%)	24/60 (40%)

prevent complications due to malnutrition, dehydration and aspiration pneumonia⁶. Furthermore, oro-pharyngeal dysphagia can drastically alter the patient's quality of life, especially during meals.

There are many reports in the literature that compare FEES with VFS, OPES with VFS and OPES with FEES (both in normal and dysphagic subjects)^{5 8-10 14 16-18 31}. In particular, there is no report in the literature of a study that statistically compares the results obtained from the three examinations performed at the same time (FEES vs. VFS vs. OPES) in the same group of patients, either to achieve a correct diagnosis of oro-pharyngeal dysphagia or to evaluate individual swallowing parameters such as premature spillage of the bolus, post-swallowing residue and tracheo-bronchial aspiration.

In this study, we compared the results obtained with these three diagnostic tools using liquid and semi-solid boluses to assess the reliability of these tests in the detection of oro-pharyngeal dysphagia in patients affected with swallowing disorders of various origins.

The results revealed that both FEES and OPES performed with both of the densities show good sensitivity and overall validity compared to the gold standard (VFS), and that sensitivity and overall validity values were high (97.9% and 86.7%, respectively), demonstrating that these two diagnostic tools (OPES and FEES) are essentially superimposable in the detection of dysphagia. OPES objectively measures and quantifies bolus transit, bolus residues and tracheobronchial aspiration, and allows a simultaneous qualitative analysis of each swallow by means of activity/time curves. Combining OPES systematically with FEES without performing VFS might actually be sufficient in many clinical situations³²⁻³⁵.

Thus, all three of these tests, FEES, VFS and OPES, are capable of supplying an accurate diagnosis of oro-pharyngeal dysphagia.

However, when we take into account the single parameters individually, we notice that in the case of premature spillage, VFS is still the test to be considered the gold standard. FEES was statistically better than OPES because the videoendoscopic evaluation of this parameter is seen directly by the observer and even the penetration of small amounts of liquid or semi-solid boluses is clearly visible. In the OPES test, on the other hand, small quantities of premature spillage can escape the attention of the observer during the evaluation since the main aim is to delineate the regions of interest (ROI). Our results indicate that VFS and FEES are tests to refer to for demonstrating premature spillage, while the OPES is less precise for this parameter. Other authors however have shown a good correlation between OPES and VFS for this parameter⁹.

The evaluation of post-swallowing residue with FEES gave better results than with OPES, because the videoendoscopic method permits a direct view of the hypopharyngeal region and residues are therefore clearly vis-

ible and easily quantified even when they are negligible. However, a report in the literature found that there is a possibility that FEES might over-estimate pharyngeal residue compared to VFS, and this must be taken into account when managing dysphagia patients¹⁶. On the other hand, the scintigraphic examination (OPES) results were less precise than the other two tests in demonstrating and calculating post-swallowing residue. This poor accuracy probably derives from the fact that this test fails to supply anatomical definitions and that it has to construct the regions of interest (ROI) on the images acquired, a factor that makes OPES operator-dependent. In the literature, however, there are some reports of a good correlation between OPES and VFS concerning the post-swallow pharyngeal residue parameter, proving the usefulness of the scintigraphic examination even for this parameter^{5 9 17}, but our data do not agree with these results.

According to the results of our statistical analysis of tracheo-bronchial aspiration, VFS appears to define it very well even if its quantification is nevertheless evaluated well by OPES. Our results are also in agreement with the latest data published in the literature, which indicate the good sensitivity of scintigraphy in detecting penetration and/or aspiration⁹. As far as FEES is concerned, however, the data in the literature point out that videoendoscopic examination of swallowing can over-estimate penetration and aspiration of the bolus, producing important clinical and rehabilitative implications as a consequence¹⁰. Nevertheless, other studies stress that FEES is useful for evaluating episodes of aspiration, since the test is non-invasive and is inexpensive¹⁴. The results of the FEES test in our study on aspiration were less accurate than those obtained with the other two examinations, especially in cases of aspiration of small quantities of bolus.

Conclusions

Our study leads us to conclude that the VFS, FEES and OPES tests are all capable of detecting oro-pharyngeal dysphagia, whichever disorder is at the basis of it. Nevertheless, VFS must still be considered by speech-language pathologists as the gold standard since it supplies values that are more reliable than those obtained with the other two tests, at least as far as the swallowing parameters we took into account are concerned. Furthermore, VFS gives more information about the physiology of pharyngeal phase of swallowing and is particularly useful in cases when the swallowing mechanism is altered during the oral and/or oesophageal phase^{16 31}. FEES gave results that were statistically significant compared to VFS and OPES, particularly in the evaluation of post-swallowing residues in the hypopharyngeal region, residues that become of important predictive value even of the risk of aspiration^{16 17 21} and which we believe to be the most important (together with aspiration) of the three parameters taken into consideration.

In addition, as reported in the literature, FEES has a great advantage over VFS in that it uses real food during the test and allows a better view of the larynx movement¹⁶. Therefore, on the grounds of these considerations and our results, we maintain that FEES should always be considered as a valid test for studying swallowing, particularly since it is able to replace the VFS for investigating oropharyngeal dysphagia, and that it should be performed first of all when it is not possible to use VFS. Other advantages of the FEES test are that it is simple to perform, it is well tolerated by the patient and its use is much more economical than the other two methods³⁶. Moreover, since FEES does not expose the patient to radiation, unlike VFS and OPES, it can be repeated several times even at brief intervals for accurate follow-up of dysphagia, perhaps during rehabilitation with speech therapy³⁷. However, it must be remembered that OPES exposes the patient to very low dosages of radiation and that for this reason it can be used instead of VFS for monitoring swallowing disorders during speech therapy and rehabilitation³⁸⁻³⁹. On the other hand, we believe that OPES is to be considered a more complementary type of test. In this respect, this test in our study was more useful than VFS and FEES for semi-quantitative evaluation of tracheo-bronchial aspiration, permitting us to obtain percentages of aspiration that would have been difficult to quantify with the other methods.

Hence, our study has shown how VFS can be considered as the test of choice for assessing pre-swallowing spillage and tracheo-bronchial inhalation, while FEES is the test of choice for studying residue. If these three parameters are to be evaluated from a semi-quantitative point of view, then OPES can be used together with the other two as a complementary test.

References

- 1 Argon M, Secil Y, Duygun U, et al. *The value of scintigraphy in the evaluation of oropharyngeal dysphagia*. Eur J Nucl Med Mol Image 2004;31:94-8.
- 2 Fattori B, Grosso M, Ursino F, et al. *Clinical applications of oro-pharyngo-oesophageal scintigraphy in the study of dysphagia*. Acta Otorhinolaryngol Ital 2007;27:192-9.
- 3 Hiss SG, Postma GN. *Fiberoptic endoscopic evaluation of swallowing*. Laryngoscope 2003;113:1386-93.
- 4 Leder SB, Murray JT. *Fiberoptic endoscopic evaluation of swallowing*. Phys Med Rehabil Clin N Am 2008;19:787-801.
- 5 Shaw DW, Williams RB, Cook II, et al. *Oropharyngeal scintigraphy: a reliable technique for the quantitative evaluation of oral-pharyngeal swallowing*. Dysphagia 2004;19:36-42.
- 6 Bours GJ, Speyer R, Lemmens J, et al. *Bedside screening tests vs. videofluoroscopy or fiberoptic endoscopic evaluation of swallowing to detect dysphagia in patients with neurological disorders: systematic review*. J Adv Nurs 2009;65:477-93.
- 7 Galli J, Valenza V, Paludetti G, et al. *An oropharyngeal-oesophageal scintigraphic study of deglutition*. Acta Otorhinolaryngol Ital 1996;16:412-9.
- 8 Hamlet SL, Muz J, Patterson R, et al. *Pharyngeal transit time: assessment with videofluoroscopic and scintigraphic techniques*. Dysphagia 1989;4:4-7.
- 9 Huang YH, Chang SC, Kao PF, et al. *The value of pharyngeal scintigraphy in predicting videofluoroscopic findings*. Am J Phys Med Rehabil 2013;92:1075-83.
- 10 Kelly AM, Drinnan MJ, Leslie P. *Assessing penetration and aspiration: how do videofluoroscopy and fiberoptic endoscopic evaluation of swallowing compare?* Laryngoscope 2007;117:1723-7.
- 11 Langmore SE, Schatz K, Olson N. *Endoscopic and videofluoroscopic evaluations of swallowing and aspiration*. Ann Otol Rhinol Laryngol 1991;100:678-81.
- 12 Lim SH, Lieu PK, Phua SY, et al. *Accuracy of bedside clinical methods compared with fiberoptic endoscopic examination of swallowing (FEES) in determining the risk of aspiration in acute stroke patients*. Dysphagia 2001;16:1-6.
- 13 Noordally SO, Sohawon S, De Gieter M, et al. *A study to determine the correlation between clinical, fiber-optic endoscopic evaluation of swallowing and videofluoroscopic evaluations of swallowing after prolonged intubation*. Nutr Clin Pract 2011;26:457-62.
- 14 Périé S, Laccourreye L, Flahault A, et al. *Role of videoendoscopy in assessment of pharyngeal function in oropharyngeal dysphagia: comparison with videofluoroscopy and manometry*. Laryngoscope 1998;108:1712-6.
- 15 Rao N, Brady SL, Chaudhuri G, et al. *Gold-Standard? Analysis of the videofluoroscopic and fiberoptic endoscopic swallow examinations*. J Applied Res 2003;3:89-96.
- 16 Kelly AM, Leslie P, Beale T et al. *Fiberoptic endoscopic evaluation of swallowing and videofluoroscopy: does examination type influence perception of pharyngeal residue severity?* Clin Otolaryngol 2006;31:425-32.
- 17 Logemann JA, Williams RB, Rademaker A, et al. *The relationship between observations and measures of oral and pharyngeal residue from videofluorography and scintigraphy*. Dysphagia 2005;20:226-31.
- 18 Wu CH, Hsiao TY, Chen JC, et al. *Evaluation of swallowing safety with fiberoptic endoscope: comparison with videofluoroscopic technique*. Laryngoscope 1997;107:396-401.
- 19 Rademaker AW, Pauloski BR, Logemann JA, et al. *Oropharyngeal swallow efficiency as a representative measure of swallowing function*. J Speech Hear Res 1994;37(2):314-25.
- 20 Dyer JC, Leslie P, Drinnan MJ. *Objective computer-based assessment of valleculae residue - is it useful?* Dysphagia 2008;23:7-15.
- 21 Farneti D. *Endoscopic scale for evaluation of the severity of dysphagia: preliminary observations*. Rev Laryngol Otol Rhinol (Bord) 2008;129:137-40.
- 22 Farneti D, Fattori B, Nacci A, et al. *The Pooling-score (P-score): inter- and intra-rater reliability in endoscopic assessment of the severity of dysphagia*. Acta Otorhinolaryngol Ital 2014;34:105-10.
- 23 Fattori B, Grosso M, Bongioanni P, et al. *Assessment of swallowing by oropharyngo-oesophageal scintigraphy in patients with amyotrophic lateral sclerosis*. Dysphagia 2006;21:280-6.
- 24 Martin-Harris B, Jones B. *The videofluorographic swallowing study*. Phys Med Rehabil Clin N Am 2008;19:769-85.

- ²⁵ Silva AC, Fabio SR, Dantas RO. *A scintigraphic study of oral, pharyngeal, and esophageal transit in patients with stroke*. *Dysphagia* 2008;23:165-71.
- ²⁶ Aviv JE, Spitzer J, Cohen M, et al. *Laryngeal adductor reflex and pharyngeal squeeze as predictors of laryngeal penetration and aspiration*. *Laryngoscope* 2002;112:338-41.
- ²⁷ Colodny N. *Interjudge and intrajudge reliabilities in fiberoptic endoscopic evaluation of swallowing (FEES) using the penetration-aspiration scale: a replication study*. *Dysphagia* 2002;17:308-15.
- ²⁸ Hamlet S, Choi J, Zormeier M, et al. *Normal adult swallowing of liquid and viscous material: scintigraphic data on bolus transit and oropharyngeal residues*. *Dysphagia* 1996;11:41-7.
- ²⁹ Langmore SE. *Evaluation of oropharyngeal dysphagia: which diagnostic tool is superior?* *Curr Opin Otolaryngol Head Neck Surg* 2003;11:485-9.
- ³⁰ Onofri SM, Cola PC, Berti LC, et al. *Correlation between laryngeal sensitivity and penetration/aspiration after stroke*. *Dysphagia* 2014;29:256-61.
- ³¹ Logemann JA, Rademaker AW, Pauloski BR, et al. *Normal swallowing physiology as viewed by videofluoroscopy and videoendoscopy*. *Folia Phoniater Logop* 1998;50:311-9.
- ³² Valenza V, Galli J, Romano L, et al. *Oro-pharyngo-esophageal scintigraphy in evaluation of swallowing disorders after oral cancer surgery*. *Clin Nucl Med* 2001;26:1054-7.
- ³³ Galli J, Valenza V, Reale F, et al. *Postoperative dysphagia, neurogenic dysphagia: scintigraphic assessment*. *Ann Otol Rhinol Laryngol* 2003;112:20-8.
- ³⁴ Galli J, Volante V, Parrilla C, et al. *Oropharyngoesophageal scintigraphy in the diagnostic algorithm of laryngopharyngeal reflux disease: an useful exam?* *Otolaryngol Head Neck Surg* 2005;132:717-21.
- ³⁵ Parrilla C, Valenza V, Calo' L, et al. *Is it sufficient to quantify aspiration for predicting aspiration pneumonia?* *Clin Nucl Med* 2008;33:236-9.
- ³⁶ Warnecke T, Teismann I, Oelenberg S, et al. *The safety of fiberoptic endoscopic evaluation of swallowing in acute stroke patients*. *Stroke* 2009;40:482-6.
- ³⁷ Logemann JA. *Swallowing disorders*. *Best Pract Res Clin Gastroenterol* 2007;21:563-73.
- ³⁸ Galli J, Valenza V, D'Alatri L, et al. *Scintigraphic monitoring of swallowing rehabilitation after horizontal supraglottic laryngectomy*. *Ann Otol Rhinol Laryngol* 2000;109:787-90.
- ³⁹ Bussu F, Galli J, Valenza V, et al. *Evaluation of swallowing function after supracricoid laryngectomy as a primary or salvage procedure*. *Dysphagia* 2015;30:686-94.

Received: August 29, 2015 - Accepted: June 9, 2016

LARYNGOLOGY

Open partial horizontal laryngectomies: is it time to adopt a modular form of consent for the intervention?

Laringectomie parziali orizzontali: è tempo di adottare un form modulare di consenso all'intervento?

L. GIORDANO¹, D. DI SANTO¹, E. CROSETTI², A. BERTOLIN³, G. RIZZOTTO³, G. SUCCO⁴, M. BUSSI¹

¹ Otolaryngology Service, Head and Neck Department, "San Raffaele" Hospital, "Vita-Salute" University, Milan, Italy;

² Head and Neck Oncology Service, IRCCS FPO Candiolo Cancer Institute Turin, Italy; ³ Otolaryngology Service, Vittorio Veneto Hospital, Treviso, Italy; ⁴ Otolaryngology Service, Oncology Department, "San Luigi Gonzaga" Hospital, University of Turin, Italy

SUMMARY

Nowadays, open partial horizontal laryngectomies (OPHLs) are well-established procedures for treatment of laryngeal cancer. Their uniqueness is the possibility to modulate the intervention intraoperatively, according to eventual tumour extension. An OPHL procedure is not easy to understand: there are several types of procedures and the possibility to modulate the intervention can produce confusion and lack of adherence to the treatment from the patient. Even if the surgery is tailored to a patient's specific lesion, a unified consent form that discloses any possible extensions, including a total laryngectomy, is still needed. We reviewed the English literature on informed consent, and propose comprehensive Information and Consent Forms for OPHLs. The Information Form is intended to answer any possible questions about the procedure, while remaining easy to read and understand for the patient. It includes sections on laryngeal anatomy and physiology, surgical aims and indications, alternatives to surgery, complications, and physiology of the operated larynx. The Consent Form is written in a "modular" way: the surgeon defines the precise extension of the lesion, chooses the best OPHL procedure and highlights all possible expected extensions specific for the patient. Our intention, providing these forms both in Italian and in English, is to optimise communication between the patient and surgeon, improving surgical procedure arrangements and preventing any possible misunderstandings and medico-legal litigation.

KEY WORDS: Open partial horizontal laryngectomies • Informed consent • Modular consent • Larynx cancer Treatment

RIASSUNTO

Al giorno d'oggi le laringectomie parziali orizzontali (OPHLs) rappresentano un'alternativa ben consolidata per il trattamento dei tumori della laringe. La particolarità di questa chirurgia è rappresentata dalla possibilità di modulare, anche intraoperatoriamente, l'intervento sulla base di una eventuale estensione della malattia. Tuttavia una OPHL è una procedura non semplice da comprendere: esistono diversi tipi di intervento e la possibilità di modulazione di quest'ultimo può provocare confusione e perdita di aderenza al piano terapeutico da parte del paziente. Allo stesso tempo, sebbene il tipo di intervento e le possibili estensioni, compresa la laringectomia totale, dipendano strettamente dalla specifica estensione della lesione di ogni paziente, si sente la necessità di poter disporre di un unico modulo di consenso informato, che racchiuda al suo interno ogni possibilità. Dopo una revisione della letteratura riguardo il Consenso Informato, proponiamo una Brochure Informativa ed un unico Modello di Consenso per le OPHLs. La brochure informativa risulta di facile lettura per il paziente, e ha lo scopo di rispondere a qualsiasi dubbio egli abbia sulla procedura. Al suo interno ci sono capitoli riguardanti il sistema delle OPHL con una speciale attenzione sulla modularità dell'intervento, l'anatomia e la fisiologia della laringe, lo scopo, le indicazioni e le alternative alla chirurgia, infine le complicanze e la fisiologia della laringe operata. Il Modello di Consenso è scritto in forma modulare: il chirurgo è chiamato a definire la specifica estensione della malattia, ad indicare il tipo di OPHL prescelto e ha la possibilità di mettere in evidenza le possibili estensioni chirurgiche tipiche di ogni paziente. Il nostro scopo, fornendo questi moduli sia in Italiano che in Inglese, è quello di ottimizzare l'alleanza medico-paziente, raggiungendo il massimo accordo riguardo la procedura e cercando di limitare ogni possibile incomprensione e contenzioso medico-legale.

PAROLE CHIAVE: Laringectomie parziali orizzontali • Consenso informato • Consenso modulare • Trattamento carcinoma della laringe

Acta Otorhinolaryngol Ital 2016;36:403-407

Introduction

Supraglottic, supracricoid, and supratracheal laryngectomies are well accepted surgical procedures for the

treatment of laryngeal cancer that provide excellent oncological and functional results¹⁻⁴. Since many different surgical techniques have been described over the years,

a new classification of these procedures has been recently proposed by the working committee on nomenclature of the European Laryngological Society⁵, based on the craniocaudal extent of laryngeal structures resected. According to the proposed classification system, three types of open partial horizontal laryngectomies (OPHL) have been defined: Type I (supraglottic), Type II (supraccricoid) and Type III (supratracheal). Each type may be extended to adjacent laryngeal and/or pharyngeal sites: OPHL Type I can be extended to one arytenoid, the base of tongue, or to a piriform sinus; OPHL Type II can be extended to one arytenoid; OPHL Type III can be extended to one crico-arytenoid unit. Moreover, OPHL Types II and III are further distinguished by the suffix “a” or “b” depending on the sparing or removal of the suprahyoid epiglottis. This classification reflects the complexity of this surgery and its wide range of variability. Thanks to this classification, all the possible variations, in terms of extent of resection, are now clearly defined.

One of the advantages of OPHLs is the possibility to tailor the procedure to the specific extent of disease. Surgeons can shift from one OPHL Type to another, even intraoperatively, if oncological safety cannot be clearly achieved with the scheduled procedure. On the basis of pathological findings in frozen sections, the procedure can be extended to adjacent sites, according to the classification, or it can shift to another OPHL Type. However, shifting to a different OPHL Type can result in a higher complication rate or longer rehabilitation time. In extreme cases, the procedure can be converted to a total laryngectomy, causing a radical change in the patient’s lifestyle after surgery. Patients must be aware of the possibility and accept this eventuality. When approaching an OPHL, the surgeon should refer to a surgical plan rather than to a single procedure.

The amazing advantage of tailoring the procedure to the extent of disease reveals two essential difficulties: 1) it may be hard for the patient to understand the meaning and the complexity of an OPHL, together with its benefits, risks, potential complications and alternatives; 2) OPHLs lack a unified consent form that includes every possible extension of every possible procedure, including total laryngectomy.

These difficulties can be hard to manage, both for the surgeon and patient. Furthermore, providing appropriate preoperative information to a patient undergoing surgery is dictated by the law and may prevent litigations.

We propose the use of a unified Consent Form (CF), in which the surgeon can specify the predicted OPHL Type and can detail all possible extensions. This CF can be customised to each patient in a “modular” way, exactly as the procedure.

In association with the CF, we propose an Information Form (IF), containing explanations on laryngeal anatomy and physiology, rationale of OPHLs, description of each procedure with all possible extensions, alternatives to sur-

gery, eventual complications and physiology of the operated larynx.

In our opinion, these forms could become a very useful tool for both patients and surgeons in planning surgery and in limiting unpleasant misunderstandings and medico-legal litigations.

Materials and methods

We reviewed the English literature looking for the essential elements of an appropriate informed consent (IC) form. IC is a legal term, defined as “voluntary authorisation, by a patient or research subject, with full comprehension of the risk involved, for diagnostic or investigative procedures, and for medical and surgical treatment” (year introduced: 1973 (1971), http://www.ncbi.nlm.nih.gov/mesh/68007258?ordinalpos=1&itool=EntrezSystem2.PEntrez.Mesh_ResultsPanel.Mesh_RVDocSum). IC is supported by three cornerstones: preconditions, information and consent⁶.

The *preconditions* for IC are competence and voluntariness. A patient is a person with the right of self-determination⁷. They must have the competence to make decisions, and they must express voluntariness, without external influence. The surgeon must be sure of the presence of these preconditions before proposing any surgical procedure.

Information is the second cornerstone. The 1995 WHO Declaration on the Promotion of Patients’ Rights states that the patient has the right to be fully informed about their health status. This includes information about: their condition, proposed medical procedures, potential risks and benefits of each procedure, alternatives to the proposed procedures (including the effects of non-treatment), and about the diagnosis, prognosis and progress of treatment⁸. The surgeon should discuss with the patient a well-defined care plan, and must be sure that they understand the information.

Consent is the registration of the patient’s decision and the authorisation to proceed. Depending on each country’s legislation, consent can be obtained orally or in writing. A consent form should be readable and written at a 12-year-old’s reading level⁹. According to the Constitution of the Italian Republic, art. 32, “no one can be forced to a specific medical treatment, except if this is stated by law”. In Italy, consent to a surgical procedure is obtained verbally; a written form is not mandatory, but is advisable to prove that IC was obtained.

Our intention is to produce a booklet that could respond to all the questions patients have about the surgical procedure. We utilised both our personal experience and literature on indications, surgical techniques, possible extensions, possible alternatives, physiology of the operated larynx and possible complications^{1-4 10-15}. In addition, with the assistance of a forensic scientist, we managed to write a readable and complete CF, in which the surgeon

has the possibility to specify the suggested procedure and to clearly define every eventual extension according to the OPHL classification⁵.

Results

The complete information form and the consent form are available in both english and italian as appendix to the on-line free download PDF version of the manuscript (http://www.actaitalica.it/issues/2016/5-2016/07_GIORDANO.pdf).

Information Form (IF)

The booklet is intended for persons without any medical knowledge. We try to explain medical terms in simple words, and include figures when needed.

The first section deals with laryngeal anatomy and physiology, with a figure to make it easier to understand. Then, the surgical procedures are presented according to the OPHL classification⁵, describing the levels of resection with an image; the aim of surgery is discussed, focusing particularly on oncological safety. The next section is about indications for each type of OPHL. Next, we describe the crucial concept of dynamism present in this type of surgery, presented here as “modular” surgery, followed by a description of all possible variations, including the possibility of shifting to a total laryngectomy. A passage about all possible alternatives to the intervention follows, in which radiation and chemo-radiation therapy are described; this passage includes the possibility of not doing anything. We then describe how the procedure is performed, what the patient should expect after surgery, and how the neo-larynx will work. Finally, all possible complications are disclosed.

Consent Form (CF)

Our intention is to write a CF with the possibility to “modulate” the surgical procedure, depending on intraoperative findings. Multiple choice lists have been included, so that it can be tailored to every possible case.

It begins with an introductory section that must be filled-in with the personal details of the patient and surgeon. The surgeon is called to define the precise dimension of the lesion with the help of a multiple choice list, in which all laryngeal and extra-laryngeal subsites that can be involved are included. Later, the surgeon must choose from a second multiple-choice list, the specific scheduled procedure. A third multiple choice list includes all possible extensions of the procedure according to the OPHL classification⁵: the most likely extensions that could result from intraoperative findings are highlighted. In the final passage, the declaration of the consent to the procedure must be signed by both the patient and the surgeon.

Note that the use of some technical terms is fundamental in the CF: medical terms are essential for the precise defi-

nition of the scheduled surgical procedure and possible expected extensions. The need for medical terms reflects the complexity of the procedure. By using simplified terms, we could lose the accuracy required in a CF.

Discussion

The concept of informed consent has developed over time, since medieval times to the present¹⁶⁻¹⁸. Past juridical sentences on litigations between patients and doctors, together with the memory of what happened during the Second World War in the Nazi concentration camps, have lead the way to the current legislation on informed consent. At present, the three cornerstones of Informed Consent are: preconditions, information and consent⁶.

Preconditions

They express the right of self-determination of the patient, who must decide freely for himself, without any kind of influence. Generally, competence is recognised by the surgeon if communication appears to be “normal”. However, in a review on patient competence, Appelbaum¹⁹ surprisingly found that the number of “incompetent” patients was higher than expected, and that doctors are unable to differentiate between competent and incompetent patients.

OPHLs require a strong alliance between surgeon and patient: during the postoperative period patient collaboration, and firm compliance are essential for rehabilitation. For this reason, psychiatric disorders represent absolute contraindications to OPHLs¹¹.

Information

Communication is fundamental: most legal cases are not due to failures in treatment, but due to failure in communication²⁰. Often informed consent is obtained by residents, who may not exactly know what to tell a patient²¹. A written leaflet, as our IF, would undoubtedly be helpful to inform patients. It is demonstrated that oral information is retained very poorly, and patients tend to forget crucial parts²². Better informed patients will have more realistic expectations, higher satisfaction and demonstrate more treatment cooperation²³.

Information must be as complete as possible. Albera et al.^{24,25} demonstrated that informing the patient not only about the disease, but also about the logical course that leads the doctor to a certain diagnosis and a description of the proposed treatment possibilities, including treatment modalities excluded, is appreciated by more than 90% of patients.

Some patients prefer not being informed about the procedure and completely rely on the surgeon’s decisions²⁶. Even in these cases, a written form provided in advance may be helpful to the patient whether they would need some information.

Furthermore, the IF can be a useful tool to instruct non-medical staff or non-specialised doctors about this procedure.

Consent

A patient that agrees to an OPHL is not accepting a single procedure, but a system of similar procedures strictly related with one another, linked by the common concept of removing a horizontal portion of the larynx, while maintaining the function of at least one crico-arytenoid unit. They must accept the possibility that the procedure may become more extended, implying that the rate of complications may become higher and the time of rehabilitation may become longer. For example, if frozen sections reveal positive margins on the subglottic mucosa during an OPHL Type II, the procedure will be converted to an OPHL Type III, which still provides the same excellent oncological and functional outcomes, but will have a longer hospital stay and rehabilitation time, and a higher rate of immediate and late complications^{2 10 27}. In this CF, the surgeon has the possibility to highlight the most plausible extensions for each patient, if unexpected infiltration of surrounding tissues is discovered during surgery.

OPHLs have some limitations: if the tumour spreads to some particular regions (i.e. the posterior paraglottic space or both the arytenoid cartilages), the procedure can no longer be performed, and must be intraoperatively converted into a total laryngectomy to achieve oncological safety. This will happen only in extreme cases, but the patient must know about this eventuality, because it will produce a significant change in their lifestyle. Even though this possibility can never be completely excluded, only a very limited subset of patients has a concrete risk for this extreme measure; for this reason, this eventuality can be highlighted in our CF. In all cases in which the extent of the tumour determines the indication for a more extreme Type III partial laryngectomy (and this occurs for most tumours with sub-glottic extension or extension towards the posterior commissure), this imposes a serious ethical consideration. In fact, in many specialised centres, these cases are considered to be “amenable with total laryngectomy” and therefore, up-front directed to non-surgical treatment in order to spare the larynx. When discussing a conservative surgical option with the patient, it must be explained clearly that if the resection margins are positive in frozen sections, the option immediately following that is total laryngectomy, thus “jumping” the option of concomitant chemoradiotherapy, which has a degree of recommendation IA.

Our “modular” CF does not limit itself to registration of the patient’s decision and authorisation to proceed: it represents an agreement on a surgical plan that can be tailored to each patient’s specific disease. This agreement will be an insurance for both: the patient, to have the best surgical procedure according to oncological safety, and

the surgeon, to perform an OPHL without any concern of extending the procedure if needed.

It is crucial to remember that the IF does not replace the surgeon’s oral explanations to the patient. The surgeon performing the procedure should first orally discuss matters with the patient, and then provide the IF and the CF. The conversation should be tailored to the patient’s socio-cultural conditions, with appropriate and clear vocabulary, and the patient should be urged to ask for any further information. At the end of the discussion, the IF is provided to the patient, and the CF is completed by the surgeon and subsequently signed by both. This should happen some days before surgery, in order to give the patient enough time to meditate. The patient is asked again for any questions the day before the procedure.

Conclusions

The primary goal of OPHLs is always oncological safety. For this reason, the surgeon must be allowed to extend the procedure as far as needed, according to the possible extensions reported⁵. In this article, we propose the use of a written IF that tries to be as complete and as clear as possible, and a CF that can reproduce the “modular” concept of OPHLs. The patient-surgeon relationship is based on trust: with these forms our intention is to improve the level of patient-surgeon cooperation and to avoid any possible litigation by improving comprehension of the procedure and reaching complete agreement on surgical planning.

References

- 1 Succo G, Bussi M, Presutti L, et al. *Supratracheal laryngectomy: current indications and contraindications*. Acta Otorhinolaryngol Ital 2015;35:146-56.
- 2 Rizzotto G, Crosetti E, Lucioni M, et al. *Subtotal laryngectomy: outcomes of 469 patients and proposal of a comprehensive and simplified classification of surgical procedures*. Eur Arch Otorhinolaryngol 2012;269:1635-46.
- 3 Laccourreye O, Brasnu D, Biacabe B, et al. *Neo-adjuvant chemotherapy and supracricoid partial laryngectomy with cricohyoidopexy for advance endolaryngeal carcinoma classified as T3-T4: 5-year oncologic results*. Head Neck 1998;20:595-9.
- 4 De Vincentiis M, Minni A, Gallo A, et al. *Supracricoid partial laryngectomies: oncologic and functional results*. Head Neck 1998;20:504-9.
- 5 Succo G, Peretti G, Piazza C, et al. *Open partial horizontal laryngectomies: a proposal for classification by the working committee on nomenclature of the European Laryngological Society*. Eur Arch Otorhinolaryngol 2014;271:2489-96.
- 6 Leclercq WKG, Keulers BJ, Scheltinga MRM, et al. *A review of surgical informed consent: past, present, and future. A quest to help patients make better decisions*. World J Surg 2010;34:1406-15.
- 7 Katz J. *Reflections on informed consent: 40 years after its birth*. J Am Coll Surg 1998;186:466-74.

- ⁸ World Health Organization Staff. *Promotion of the rights of patients in Europe*. In: Proceedings of a WHO Consultation 1995.
- ⁹ Paasche-Orlow MK, Taylor HA, Brancati FL. *Readability standards for informed-consent forms as compared with actual readability*. N Engl J Med 2003;348:721-6.
- ¹⁰ Benito J, Holsinger FC, Pérez-Martín A, et al. *Aspiration after supracricoid partial laryngectomy: incidence, risk factors, management, and outcomes*. Head Neck 2011;33:679-85.
- ¹¹ Schindler A, Favero E, Capaccio P, et al. *Supracricoid laryngectomy: age influence on long-term functional results*. Laryngoscope 2009;119:1218-1225.
- ¹² Cunsolo EM. *Anatomy and physiology of the operated larynx*. Acta Otorhinolaryngol Ital 2010;30:238-43.
- ¹³ De Vincentiis M, Minni A, Gallo A. *Supracricoid laryngectomy with cricothyroidopexy (CHP) in the treatment of laryngeal cancer: a functional and oncologic experience*. Laryngoscope 1996;106:1108-14.
- ¹⁴ Rizzotto G, Succo G, Lucioni M, et al. *Subtotal laryngectomy with tracheohyoidopexy: a possible alternative to total laryngectomy*. Laryngoscope 2006;116:1907-17.
- ¹⁵ Crosetti E, Garofalo P, Bosio C et al. *How the operated larynx ages*. Acta Otorhinolaryngol Ital 2014;34:19-28.
- ¹⁶ Ajlouni KM. *History of informed medical consent*. Lancet 1995;346:980.
- ¹⁷ Rothman DJ. *History of informed medical consent*. Lancet 1995;346:1633.
- ¹⁸ Baron JH. *History of informed medical consent*. Lancet 1996;347:410.
- ¹⁹ Appelbaum PS. *Clinical practice. Assessment of patients' competence to consent to treatment*. N Engl J Med 2007;357:1834-1840.
- ²⁰ Armstrong AP, Cole AA, Page RE. *Informed consent: are we doing enough?* Br J Plast Surg 1997;50:637-40.
- ²¹ Angelos P, Darosa DA, Bentram D, et al. *Residents seeking informed consent: are they adequately knowledgeable?* Curr Surg 2002;59:115-8.
- ²² Henney S, Rakhra S. *Patient information in otorhinolaryngology: a prospective audit*. J R Soc Med Sh Rep 2011;2:37.
- ²³ Kessler TM, Nachbur BH, Kessler W. *Patients' perception of preoperative information by interactive computer program – exemplified by cholecystectomy*. Patient Educ Couns 2005;59:135-40.
- ²⁴ Bonziglia S, Albera R, Giordano L, et al. *Informed consent. Proposal of a method for ORL*. Acta Otorhinolaryngol Ital 2000;20:448-55.
- ²⁵ Albera R, Argentero P, Bonziglia S, et al. *Informed consent in ENT. Patient's judgment about a specific consensus form*. Acta Otorhinolaryngol Ital 2005;25:304-11.
- ²⁶ Tan LT, Jenkins H, Roberts-Harry J, et al. *Should patients set the agenda for informed consent? A prospective survey of desire for information and discussion prior to routine cataract surgery*. Ther Clin Risk Manag 2008;4:1119-25.
- ²⁷ Simonelli M, Ruoppolo G, De Vincentiis M et al. *Swallowing ability and chronic aspiration after supracricoid partial laryngectomy*. Otolaryngol Head Neck Surg 2010;142:873-8.

Received: July 17, 2015 - Accepted: June 11, 2016

Address for correspondence: Leone Giordano, Otolaryngology Service, Head and Neck Department, "San Raffaele" Hospital, "Vita-Salute" University, via Olgettina 60, 20123 Milan, Italy. Tel. +39 02 26433525. Fax +39 02 26433508; E-mail:giordano.leone@hsr.it

OTOLOGY

Surgical treatment of sporadic vestibular schwannoma in a series of 1006 patients

Trattamento chirurgico degli schwannomi vestibolari: risultati su una serie di 1006 pazienti

Z. ZHANG^{1,2}, Y. NGUYEN¹, D. DE SETA¹, F.Y. RUSSO¹, A. REY³, M. KALAMARIDES⁴, O. STERKERS¹, D. BERNARDESCHI¹

¹ AP-HP, Pitié-Salpêtrière Hospital, Department of Otolaryngology Auditory Implants and Skull Base Surgery, Paris, France; ² Department of Otolaryngology Head and Neck Surgery, Xinhua Hospital Shanghai Jiaotong University School of Medicine, Shanghai, China; ³ AP-HP, Beaujon Hospital, Department of Neurosurgery, Paris, France; ⁴ AP-HP, Pitié-Salpêtrière Hospital, Department of Neurosurgery, Paris, France

SUMMARY

The management of sporadic vestibular schwannoma (VS) has evolved in the last decades. The aim of this study was to analyse the evolution in surgical outcomes of VSs operated by a neurotological team between 1990 and 2006 by different approaches. A monocentric retrospective review of medical charts of 1006 patients was performed. In order to assess eventual changes and progress, the 17-years period was divided in three periods, each one comprehending 268 VS (1990-1996), 299 VS (1997-2001), and 439 VS (2002-2006). Mean follow-up was 5.9 ± 2.4 years. Overall, complete VS removal was achieved in 99.4% of cases. Mortality rate was 0.3%, meningitis and CSF leaks were observed in 1.2% and 9% of the cases, respectively. CSF leakage decreased from 11.6% to 7.1% between the first and last period ($p < 0.01$) as well as revision surgery from 3.4% to 0.9% ($p < 0.05$). Facial nerve was anatomically preserved in 97.7% of cases. At one year, a good facial nerve function was observed in 85.1% of patients (grade I and II of House-Brackmann grading scale), which ranged between the first and last period from 78.4% to 87.6% ($p < 0.05$). At one year, hearing preservation was obtained in 61.6% of patients, which increased from the first period to the last one from 50.9% to 69.0% ($p < 0.05$) (class A+B+C from the AAO-HNS classification). Useful hearing (class A+B) was observed in 33.5% of cases overall, with 21.8% and 42% in the first and last period, respectively ($p < 0.01$). Surgical outcomes of sporadic vestibular schwannoma have improved concerning facial nerve function outcomes, hearing preservation and cerebrospinal fluid (CSF) leaks, mainly due to the neuro-otological team's experience. Functional results after complete microsurgical removal of large VS depend on experience gained on small VS removal.

KEY WORDS: Facial nerve • Vestibular schwannoma • Translabirinthine • Hearing levels

RIASSUNTO

La gestione dello schwannoma vestibolare (SV) sporadico si è gradualmente evoluta negli ultimi decenni. Lo scopo di questo studio è di analizzare l'evoluzione negli esiti chirurgici dell'exeresi di queste lesioni, realizzata da un team neurotologico tra il 1990 e il 2006, attraverso differenti approcci. È stata eseguita una revisione retrospettiva monocentrica dei dati clinici di 1006 pazienti. Al fine di valutare eventuali modifiche e progressi, il periodo di 17 anni è stato diviso in tre periodi, ciascuno comprendente rispettivamente 268 SV (1990-1996), 299 SV (1997-2001), e 439 SV (2002-2006). Il follow-up medio è stato di $5,9 \pm 2,4$ anni. Complessivamente l'asportazione totale è stata ottenuta nel 99,4% dei casi. Il tasso di mortalità è stato dello 0,3%, la meningite e la perdita di liquido cefalo rachidiano (LCR) sono stati osservati nel 1,2% e il 9% dei casi, rispettivamente. La frequenza della perdita di LCR è diminuita dal 11,6% al 7,1% tra il primo e dell'ultimo periodo ($p < 0,01$) e la revisione chirurgica dal 3,4% al 0,9% ($p < 0,05$). Il nervo facciale è stato anatomicamente conservato nel 97,7% dei casi. Ad un anno, una buona funzione del nervo facciale è stata osservata nel 85,1% dei pazienti (I e II grado House-Brackmann), con una variazione tra il primo e l'ultimo periodo che andava dal 78,4% al 87,6% ($p < 0,05$). Ad un anno post-operatorio la conservazione dell'udito è stata ottenuta nel 61,6% dei pazienti, passando dal 50,9% del primo periodo, al 69,0% del periodo più recente ($p < 0,05$) (classe A + B + C dalla classificazione AAO-HNS). L'udito utile (classe A + B) è stato conservato nel 33,5% dei casi complessivamente, con percentuali comprese tra il 21,8% e 42% nel primo e nell'ultimo periodo rispettivamente ($p < 0,01$). Gli esiti chirurgici dell'asportazione dello schwannoma vestibolare sporadico sono migliorati negli anni per quanto riguarda i risultati funzionali del nervo facciale, la conservazione dell'udito, le perdite di liquido cefalorachidiano, principalmente grazie all'esperienza del team neurotologico. I risultati funzionali dopo la rimozione microchirurgica completa SV di grandi dimensioni dipendono dall'esperienza maturata sulle lesioni di piccole dimensioni.

PAROLE CHIAVE: Nervo facciale • Schwannoma vestibolare • Translabirintico • Udito

Acta Otorhinolaryngol Ital 2016;36:408-414

Introduction

Complete microsurgical excision of sporadic vestibular schwannoma (VS) has been advocated for all tumour sizes, up to the beginning of this century. Because of the development of magnetic resonance imaging (MRI) techniques, which have been easier to obtain, a wait and scan policy was introduced in the early 1990s¹. Since then, the introduction of radiotherapy in stereotaxic conditions, mainly by gamma-knife, invigorates the debate concerning the microsurgical removal of small and middle-sized VS, especially in the elderly when VSs are progressive. Besides, radiosurgery has become more popular as far as the doses have been reduced to limit the toxic effects of radioactive agents on neurological structures, and it has been proposed, in case of large VS, to reduce the posterior fossa extension of the tumour by a partial microsurgical excision before irradiating the remaining tumour².

Nevertheless, recent studies have described advances in surgical techniques and devices, which in association with the improvement of surgeon's experience may have led to a gradually decreasing surgical mortality and morbidity. Hence, the modern surgical goals of sporadic VS have changed to achieve higher complete tumour removal, with higher rates of facial nerve (FN) function and hearing level preservation, lower mortality and neurological morbidity incidence³⁻⁸.

Good postoperative outcomes depend on several factors including tumour size, surgical approaches, intraoperative nerve monitoring, cranial nerve displacement pattern and tumour adherence to neurological structures, in addition to surgical experience⁴⁻¹². However, few authors have reviewed surgical outcomes of large series of more than 500 cases^{4-8,13}. The aim of this study is to report the surgical outcomes in a large series of more than 1000 sporadic VS operated by the same neuro-otological team over a 17-year period.

Materials and methods

A monocentric retrospective review was performed on medical charts of 1006 consecutive patients operated for sporadic VS removal between January 1990 and December 2006. Patients with neurofibromatosis Type II (NF2) were excluded. Data were extracted pertaining to the following variables: patient demographics; tumour localisation; clinical and imaging features; facial nerve function, hearing levels, and details of surgical intervention. Patient demographics are reported in Table I. In order to investigate the changes and eventual progresses of the surgical management during the 17-year period, 3 consecutive periods were explored separately: the earlier period (period 1) between 1990 and 1996, the intermediate period (period 2) between 1997 and 2001 and the last period group (period 3) between 2002 and 2006. Mean follow-up was 5.9 ± 2.4 years.

All surgical procedures were performed by the same neuro-otological team (AR and MK, neurosurgeons; OS otologist) in a tertiary referral centre.

The FN function was assessed using the House-Brackmann (HB) grading system¹⁴. HB grade I or II, grade III or IV, and grade V or VI were defined as good, mild and poor FN function respectively. Intraoperative facial nerve monitoring (NIM and NIM II, Medtronic, Xomed, Jacksonville, FL, USA) was routinely used.

All patients completed a series of audiovestibular assessments including pure tone audiometry, intelligibility scores, auditory brainstem evoked responses and caloric and videonistagmography testing. Hearing level was evaluated using the American Academy of Otolaryngology-Head and Neck surgery (AAO-HNS) guidelines and staged in 4 classes¹⁵. Preservation of hearing was calculated as the sum of class A+B+C and a serviceable hearing as the sum of class A+B. Tumour size measurement was based on the largest extrameatal diameter in the cerebello-pontine angle (CPA) from T1-weighted MRI with gadolinium. The tumours were divided into 4 stages¹⁰⁻¹²: stage I (intracanalicular), stage II (inferior or equal to 15 mm in the CPA), stage 3 (from 16 to 30 mm in the CPA) and stage IV (superior to 30 mm in the CPA).

We analysed functional surgical outcomes among the three groups considering the following variables: completeness of tumour removal, intraoperative FN status, postoperative FN outcomes at one year, hearing preservation, CSF leakages and other complications.

Statistical methods

Data are expressed as mean \pm SD. All data were analysed with the software SPSS 19.0. The χ^2 and Fisher's exact tests were used to compare surgical outcomes and the general characteristics of the three groups. Significance was considered at $p < 0.05$.

Results

Preoperative clinical and radiological data are reported in Table I. No significant difference in demographics was observed among the patients in the three periods. Mean age was 55.6 ± 13.6 years with a sex ratio of 0.88:1. VS was revealed by progressive or a sudden hearing loss in 84.3% or 10.7% of cases, respectively. Vertigo and tinnitus were present in 33.7% and 38.9% of cases, respectively.

Preoperative FN function was normal or subnormal in 98.8% cases. Trigeminal nerve dysfunction was observed in 17% of patients. Pre-operative useful hearing was in 41.7% and dead ear or absence of intelligibility in 35.5%. In the different groups, intracanalicular VS ranged from 7.7% to 9.%, stage 2 VS from 35.4% to 46.2% and large VS (stage 3 and 4) from 44.9 to 54.9%.

The surgical approach was chosen depending on: (i) tumour size, its extension into the CPA anterior to the inter-

Table I. Preoperative clinical and radiological data of patients.

Characteristic	Period 1 1990-1996 n = 268	Period 2 1997-2001 n = 299	Period 3 2002-2006, n = 439	Total 1990-2006 n = 1006
Male	105	151	216	472 (46.9%)
Female	163	148	223	534 (53.1%)
Left side	145	177	320	642 (63.8%)
Right side	123	122	119	364 (36.2%)
Age (yr)	64.2 ± 13.8	57.4 ± 12.4	55.3 ± 13.1	51.3 ± 13.6
Tumour size (mm)	19.0 ± 12.5	16.9 ± 10.8	16.4 ± 11.9	17.2 ± 11.7
Tumour Stage				
1	26 (9.7%)	23 (7.7%)	39 (8.9%)	88 (8.7%)
2	95 (35.4%)	136 (45.5%)	203 (46.2%)	434 (43.1%)
3	91 (34.0%)	97 (32.4%)	110 (25.1%)	298 (29.6%)
4	56 (20.9%)	43 (14.4%)	87 (19.8%)	186 (18.5%)
Trigeminal nerve dysfunction	55 (20.5%)	47 (15.7%)	69 (15.7%)	171 (17.0%)
Facial nerve				
HB I-II	266 (99.3%)	298 (99.7%)	430 (97.9%)	994 (98.8%)
HB III-IV	1 (0.4%)	1 (0.3%)	9 (2.1%)	11 (1.1%)
HB V-VI	1 (0.4%)	-	-	1 (0.1%)
Tinnitus	126 (47.0%)	133 (44.5%)	132 (30.1%)	391 (38.9%)
Vertigo	107 (39.9%)	128 (42.8%)	104 (23.7%)	339 (33.7%)
Otalgia	1 (0.4%)	1 (0.3%)	8 (1.8%)	10 (1.0%)
Hearing loss				
Progressive	223 (83.2%)	247 (82.6%)	378 (86.1%)	848 (84.3%)
Sudden	30 (11.2%)	32 (10.7%)	46 (10.5%)	108 (10.7%)
Class A	54 (20.1%)	68 (22.7%)	72 (16.4%)	194 (19.3%)
Class B	56 (20.9%)	84 (28.1%)	85 (19.4%)	225 (22.4%)
Class C	68 (25.4%)	70 (23.4%)	92 (21.0%)	230 (22.9%)
Class D	90 (33.6%)	77 (25.8%)	190 (43.3%)	357 (35.5%)
Headache	18 (6.7%)	16 (5.4%)	14 (3.2%)	48 (4.8%)
Intracranial hypertension	7 (2.6%)	1 (0.3%)	3 (0.7%)	11 (1.1%)

HB: House-Brackmann facial nerve grading system.

nal auditory meatus (IAM), at the IAM fundus, or intracochlear extension; (ii) ipsilateral and contralateral hearing level; (iii) general status and patients' expectations. Precisely, a translabyrinthine approach (TLa) for stage 3 and 4 VS or stage 1 and 2 VS with class C or D hearing loss; transotic approach (TOa) for stage 3 and 4 VS with extension anterior to the IAM or any stage VS with intracochlear extension; retrosigmoid approach (RSa) for stage 1 and 2 VS with class A or B hearing loss and IAM fundus free of tumour; and middle fossa approach (MFa) for stage 1 VS with class A or B hearing level. The extent of tumour resection was defined accordingly to the Acoustic Neuroma Consensus on System Reporting Results¹⁶.

Table II shows the approaches performed in relation to the size of VS. It appears that in few stages 2 MSa was chosen as well as RSa in few stages 3; TOa was mainly used in stage 4 VS. These approaches were differently used as a function of the period. More TLa and few RSa were performed during the early period as compared to the last one. More TOa and less MFa were performed during the last period.

Intraoperative FN status and postoperative FN function
Anatomical FN integrity was preserved in 983 patients (97.7%). Seven hundred and twenty-four patients (72.0%) completed the postoperative FN function evaluation at 1-year. There were 616 (85.1%), 103 (14.2%) and 5 (0.7%) patients with, respectively, good, medium and poor post-

Table II. Surgical approaches according to tumour stage.

	Tumour stage			
	1 (n = 88)	2 (n = 434)	3 (n = 298)	4 (n = 186)
TLa	27 (30.7%)	242 (55.8%)	259 (86.9%)	120 (64.5%)
TOa	10 (11.4%)	7 (1.6%)	17 (5.7%)	66 (35.5%)
RSa	1 (1.1%)	158 (36.4%)	22 (7.4%)	-
MFa	50 (56.8%)	27 (6.2%)	-	-

TLa: translabyrinthine approach; TOa: transotic approach; RSa: retrosigmoid approach; MFa: middle fossa approach.

Table III. Postoperative facial nerve function at 1 year.

	HB Grade I-II (%)	HB Grade III-IV (%)	HB Grade V-VI (%)
Tumour stage			
1 (n = 60)	55 (91.7)	5 (8.3)	-
2 (n = 333)	287 (86.2)	46 (13.8)	-
3 (n = 192)	163 (84.9)	27 (14.1)	2 (1.0)
4 (n = 139)	111 (79.9)	25 (18.0)	3 (2.2)
Surgical approach			
TLa (n = 456)	400 (87.7)	51 (11.2)	5 (1.1)
TOa (n = 61)	50 (82.0)	11 (18.0)	-
RSa (n = 143)	116 (81.1)	27 (18.9)	-
MFa (n = 64)	50 (78.1)	14 (21.9)	-
Surgical period			
Period 1 (1990-1996, n = 88)	69 (78.4)	18 (20.5)	1 (1.1)
Period 2 (1997-2001, n = 241)	201 (83.4)	38 (15.8)	2 (0.8)
Period 3 (2002-2006, n = 395)	346 (87.6)	47 (11.9)	2 (0.5)

HB: House-Brackmann facial nerve grading system; TLa: translabyrinthine approach; TOa: transotic approach; RSa: retrosigmoid approach; MFa: middle fossa approach.

operative FN function. The good FN function rate was inversely proportional to the tumour size (Table III): 91.7% in stage 1, 86.2% in stage 2, 84.9% in stage 3 and 79.9% in stage 4 (good FN function between stage 1 and 4 had significant different, $p = 0.04$). Good FN function was seen 87.7% of cases in TLa, 82.0% in TOa, 81.1% in RSa and 78.1% in MFa, and it was higher in TLa than that in MFa ($p = 0.048$). Furthermore, the good FN function in period 1 was lower than that in period 3 (78.4% vs 87.6%, $p = 0.02$). Out of 23 FNs interrupted during surgery, 13 (56.5%) were repaired by end-to-end anastomosis and 10 (43.5%) by great auricular nerve graft with fibrin glue¹⁷.

Hearing results

Out of 419 patients with a preoperative hearing level class A, B and C, 245 patients (58.5%) underwent tumour removal via RSa or MFa (Table IV). Overall, the hearing preservation rate was 61.6% (151 patients), and a serviceable hearing level was achieved in 82 patients (33.5%). Both these two rates in group 3 were higher than those in groups 1 and 2 (hearing preservation rate: 69.0% vs 50.9%, $p = 0.028$; serviceable hearing preservation rate: 42.2% vs 21.8%, $p = 0.01$).

Complications

The complications occurred in the present series are reported in Table V. CSF leakage occurred in 91 patients (9.0%), 72 of whom were treated conservatively with pressure dressings and lumbar drainage, and 19 underwent revision surgery. The management of CSF leakage was decided on the base of the cerebrospinal fluid pressure value¹⁸. According to the tumour size classification, the incidence of CSF leakage was 5.0% (4 cases) in stage 1, 7.4% (32 cases) in stage 2, 9.5% (28 cases) in stage 3 and 14.7% (27 cases) in stage 4. According to the surgical approaches, it occurred

Table IV. Hearing results at the last follow-up (n = 245).

Postoperative hearing level	Preoperative hearing level			
	A	B	C	Total (%)
A	30	7	-	37 (15.1)
B	16	27	2	45 (18.4)
C	17	30	22	69 (28.2)
D	50	30	14	94 (38.4)

in 7.9% (51 cases) in TLa, 12.2% (12 cases) in TOa, 10.5% (19 cases) in RSa and 11.7% (9 cases) in MFa.

We used four techniques of wound closure to prevent CSF leakage during the three consecutive periods¹⁹: 1) placement of the fascia graft on the dural defect and afterwards fat tissue placement over the fascia; 2) large musculoperiosteal flap to compress the fascia-fat complex; 3) fat tissue directly placed into the operative cavity without fascia graft, then covered with a musculoperiosteal flap; 4) fat tissue directly placed into the operative cavity and hold in place with a titanium plate fixed to the mastoid bone. The incidence of CSF leakage decreased along the three periods: 11.6%, 9.7% and 7.1% in the early, intermediate and last periods, respectively. Likewise, the incidence of postoperative septic meningitis decreased throughout the different periods: 1.9%, 1.3% and 0.7% in early, intermediate and last periods, respectively.

The mortality rate reported in this series was 0.3% (3 patients). One patient with stage 3 VS deceased of postoperative CPA hematoma. The two other patients presenting a stage 4 VS deceased of postoperative pulmonary embolism and cerebral haemorrhage, respectively.

Twelve patients (1.2%) with a total tumour resection presented a recurrence, detected through the routine annual MRI. The mean interval between surgery and recurrence was 2.8 ± 1.9 years (range 1-6 years). The mean diameter of the

Table V. Postoperative complications (n = 1006).

Complications	Period 1 (1990-1996, n = 268) (%)	Period 2 (1997-2001, n = 299) (%)	Period 3 (2002-2006, n = 439) (%)	Total (1990-2006, n = 1006) (%)
Mortality	1 (0.4)	1 (0.3)	1 (0.2)	3 (0.3)
CPA haematoma	2 (0.7)	2 (0.7)	1 (0.2)	5 (0.5)
Subarachnoid haemorrhage	1 (0.4)	1 (0.3)	-	2 (0.2)
Lateral sinus thrombosis	1 (0.4)	1 (0.3)	1 (0.2)	3 (0.3)
Cerebellar oedema	-	1 (0.3)	1 (0.2)	2 (0.2)
Pulmonary embolism	1 (0.4)	-	1 (0.2)	2 (0.2)
Meningitis	5 (1.9)	4 (1.3)	3 (0.7)	12 (1.2)
Phlebitis	2 (0.7)	4 (1.3)	3 (0.7)	9 (0.9)
CSF leak	31 (11.6)	29 (9.7)	31 (7.1)	91 (9.0)
Revision	9 (3.4)	6 (2.0)	4 (0.9)	19 (1.9)
Conservative treatment	22 (8.2)	23 (7.7)	27 (6.2)	72 (7.2)
Lower cranial nerve palsy	-	1(0.3)	-	1 (0.1)
Subcutaneous abdominal haematoma	9 (3.4)	7 (2.3)	5 (1.1)	21 (2.1)
Recurrence	5 (1.9)	4 (1.3)	3 (0.7)	12 (1.2)

recurrence was 10.4 ± 3.6 (range 5-15 mm). Among these 12 cases, five lesions were stable and continued to be observed, and 7 patients underwent surgical revision by TLa by reason of rapid growth tumour (> 2 mm/year) or aggravating symptoms. There was no evidence of tumour regrowth in the 6 patients who underwent a near total tumour removal.

Discussion

Over the last decades, the incidence of VS has increased to approximately 19 tumours per million per year. Several factors might be the cause of this increase, most important of which is the improvement in diagnostic equipment, i.e., magnetic resonance imaging, in a context of increased life expectation.

Along with the improvement of surgical techniques, the acquiring importance of radiosurgery and the advancement of diagnostic equipment led to a change in the objectives of VS treatment. Modern VS surgery is reaching the goal of preservation of function. Although facial nerve preservation was the major concern in the past decades, currently hearing preservation is the main challenge. To date, the choice of the surgical strategy depends on tumour size, hearing and facial nerve function, patient age and the presence of other disabling symptoms. The challenge and the matter of the actual debate is to achieve major tumour removal, with a minimal impairment of these functions.

The extension of tumour removal is strictly related to tumour size and to the adherence of the tumour to critical neurovascular structures^{5 20-22}. The analysis of the present series shows that over the years advancements such as the electrophysiological monitoring of facial function influenced technical procedures and surgical outcomes. Overall in the present study, total tumour removal was reached in 99.4% of patients, with a higher rate of functional preservation in the last period. Moreover, the remaining 0.6% of patients who underwent a near total removal

was treated during period 3. In these cases (three stages 3 and four stages 4, mean tumour size: 31.2 ± 9.8 mm), the presence of a tumour adherent to CPA structures led the surgeon to choose a conservative technique leaving in place a small residual. However, an average follow up of 5 years demonstrated the stability of the lesions and none of the cases presented a growth of the residual. Therefore, in line with other reports we can state that near total tumour resection might be a safe and effective method for preserving postoperative cranial nerve function without negatively impacting tumour control²³.

FN function

Several prognostic factors influence the postoperative FN function: tumour size, patient age, course of disease, previous treatment, surgical approach, intraoperative four-channel electromyography monitoring, FN displacement pattern, tumour adhesion and heterogeneous or cystic tumours^{4 10 24 25}.

All surgeries were performed using a FN monitoring system. FN anatomical integrity does not necessarily correspond to good FN function. In our series, with 97.7% of FN anatomical integrity, good FN function was achieved only in 85.1% of patients. The good FN function rate varied from 91.7% to 79.9%, and it was inversely proportional to the tumour size. Thus, a larger tumour size implies a worse postoperative functional outcome. Recently, Esquia et al.¹⁰ observed that the FN outcome is influenced by the displacement pattern and adhesion between the tumour and nerves. In addition, Bernat et al.²⁵ defined, as a criteria for good FN prognosis, the use of supramaximal stimulation threshold, that would increase the predictive value of monitoring during VS surgery.

Several authors have reported the results of FN preservation by various surgical approaches²⁶⁻²⁸. Our experience highlights that the choice of the approach has an influence

on functional outcomes. TLa and TOa (applicable to all tumour sizes) lead to an easier identification of the FN, on the other hand, in VS approached by MF the FN preservation rate was lower (78.1%). Finally, the surgeon's experience and postoperative rehabilitation training improved the results (87.6% in last period, 83.4% in intermediate period, and 78.4% in early period) without any change of the mean tumour size ($p > 0.05$).

Hearing preservation

In the literature, data concerning hearing preservation vary from 18% to 96% of success^{1-4,6,26,29,30}. In our series, RSa was used in tumour < 15 mm in CPA with class A or B hearing level and free fundus, while MFa was preferred in intracanalicular tumours with class A or B hearing level. Preserved hearing and serviceable hearing were obtained in 61.6% and 33.5% of patients, respectively. Both of these two rates in period 3 were significantly higher than in the earlier periods (hearing preservation rate: 69.0% vs. 50.9%, $p = 0.028$; serviceable hearing preservation rate: 42.2% vs. 21.8%, $p = 0.010$). As described, the preoperative pure tone average, free IAM fundus and tumour size^{32,33} are predictive factors for hearing preservation, but we believe that surgical experience may be crucial for hearing preservation, and in particular for intraoperative identification and protection of blood vessels and cochlear nerve.

In the last decade (2007-2016), the strategy for hearing preservation in VS removal has seen some changes. More frequently than before, subtotal or partial removal of the tumour via RSa is proposed to patients, even with a class 3 VSs, followed by gamma knife radiotherapy.

Complications

Mortality rates associated with VS removal have been decreasing from 20 to 0% during the past decades, but still remain significantly higher in patients over 70 years³³. Neurovascular disorders, brainstem injury and serious intracranial infections are the major causes of death. In our series, three patients deceased from CPA hematoma, pulmonary embolism and cerebral haemorrhage. All life-threatening complications occurred in patients with VS higher than stage 3.

CSF leakage was the most frequent perioperative complication in our series (9.0%). Our results confirm the relation between CSF leakage and tumour size (14.7% in stage 4, 9.5% in stage 3, 7.4% in stage 2 and 4.5% in stage 1)^{34,35}, which is in contrast to what reported by Stieglitz et al³⁶. However, its incidence is not related with the approach even if the occurrence of CSF leakage in TLa was lower (7.9%) than in the other approaches. Merkus et al.³⁵ reported 0.8% of CSF leakage after TLa during a 15-year period, suggesting some modification of closure techniques. Our incidence of CSF leakage decreased during the three periods (14.2% in early period > 9.0% in intermediate period > 5.9% in last period) demonstrating

that the development of closure technique and surgeon's experience helped to prevent this complication. Out of the four techniques of wound closure, the recent technique with a titanium plate anchored to the mastoid led to the most satisfactory results with a lower incidence of leakage compared to the average in the literature of 6.6% and 15%⁶. Consequently, the meningitis rate was 1.2%, which was lower than other reports (1.5%-2.6%)^{34,36-38}.

The most serious complication in the present series was CPA hematoma. It usually occurs within the first 12 to 24 hours and the key point is the immediate removal and decompression of the CPA hematoma, even without confirmation by CT scan.

Conclusions

Many factors influence the surgical outcomes of sporadic VS. Our experience in a large series of 1006 sporadic VS treated over a 17-year period revealed that good functional outcomes depend on several critical variables, including tumour size, surgical approach, surgeon's experience and development of technique.

Over the years the surgical outcome of sporadic VS has improved, in particular regarding facial nerve function outcomes and cerebrospinal fluid (CSF) leaks, mainly due to the neuro-otological team's experience. The actual challenge is hearing preservation after complete microsurgical removal of large VS, which depends on the experience gained on small VS removal.

References

- Jørgensen BG, Pedersen CB. *Acoustic neuroma. Follow-up of 78 patients.* Clin Otolaryngol Allied Sci 1994;19:478-84.
- Iwai Y, Ishibashi K, Watanabe Y, et al. *Functional preservation after planned partial resection followed by gamma knife radiosurgery for large vestibular schwannomas.* World Neurosurg 2015;84:292-300.
- House WF, Shelton C. *Middle fossa approach for acoustic tumor removal.* 1992. Neurosurg Clin N Am 2008;19:279-88.
- Sterkers JM, Morrison GA, Sterkers O, et al. *Preservation of facial, cochlear, and other nerve functions in acoustic neuroma treatment.* Otolaryngol Head Neck Surg 1994;110:146-55.
- Samii M, Matthies C. *Management of 1000 vestibular schwannomas (acoustic neuromas): surgical management and results with an emphasis on complications and how to avoid them.* Neurosurgery 1997;40:11-21; discussion 21-23.
- Wiet RJ, Mamikoglu B, Odom L, et al. *Long-term results of the first 500 cases of acoustic neuroma surgery.* Otolaryngol Head Neck Surg 2001;124:645-51.
- Ben Ammar M, Piccirillo E, Topsakal V, et al. *Surgical results and technical refinements in translabyrinthine excision of vestibular schwannomas: the Gruppo Otologico experience.* Neurosurgery 2012;70:1481-91; discussion 1491.
- Slattery WH III, Francis S, House KC. *Perioperative morbidity of acoustic neuroma surgery.* Otol Neurotol 2001;22:895-902.

- ⁹ Anderson DE, Leonetti J, Wind JJ, et al. *Resection of large vestibular schwannomas: facial nerve preservation in the context of surgical approach and patient-assessed outcome.* J Neurosurg 2005;102:643-9.
- ¹⁰ Esquia-Medina GN, Grayeli AB, Ferrary E, et al. *Do facial nerve displacement pattern and tumor adhesion influence the facial nerve outcome in vestibular schwannoma surgery?* Otol Neurotol 2009;30:392-7.
- ¹¹ Bozorg Grayeli A, Kalamarides M, Fraysse B, et al. *Comparison between intraoperative observations and electromyographic monitoring data for facial nerve outcome after vestibular schwannoma surgery.* Acta Otolaryngol 2005;125:1069-74.
- ¹² Grayeli AB, Guindi S, Kalamarides M, et al. *Four-channel electromyography of the facial nerve in vestibular schwannoma surgery: sensitivity and prognostic value for short-term facial function outcome.* Otol Neurotol 2005;26:114-20.
- ¹³ Glasscock ME III, Kveton JF, Jackson CG, et al. *A systematic approach to the surgical management of acoustic neuroma.* Laryngoscope 1986;96:1088-94.
- ¹⁴ House JW, Brackmann DE. *Facial nerve grading system.* Otolaryngol Head Neck Surg 1985;93:146-7.
- ¹⁵ *Committee on Hearing and Equilibrium guidelines for the evaluation of hearing preservation in acoustic neuroma (vestibular schwannoma).* American Academy of Otolaryngology-Head and Neck Surgery Foundation, INC. Otolaryngol Head Neck Surg 1995;113:179-80.
- ¹⁶ Kanzaki J, Tos M, Sanna M, et al. *New and modified reporting systems from the consensus meeting on systems for reporting results in vestibular schwannoma.* Otol Neurotol 2003;24:642-8; discussion 648-9.
- ¹⁷ Bozorg Grayeli A, Mosnier I, Julien N, et al. *Long-term functional outcome in facial nerve graft by fibrin glue in the temporal bone and cerebellopontine angle.* Eur Arch Otorhinolaryngol 2005;262:404-7.
- ¹⁸ Kalamarides M, Grayeli AB, Bouccara D, et al. *Opening cerebrospinal fluid pressure guides the management of cerebrospinal fluid leakage after acoustic neuroma surgery.* Otol Neurotol 2004;25:769-72.
- ¹⁹ Wu H, Kalamarides M, Garem HE, et al. *Comparison of different wound closure techniques in translabyrinthine acoustic neuroma surgery.* Skull Base Surg 1999;9:239-42.
- ²⁰ Zhang Z, Wang Z, Huang Q, et al. *Removal of large or giant sporadic vestibular schwannomas via translabyrinthine approach: a report of 115 cases.* ORL J Otorhinolaryngol Relat Spec 2012;74:271-7.
- ²¹ Angeli RD, Piccirillo E, Di Trapani G, et al. *Enlarged translabyrinthine approach with transapical extension in the management of giant vestibular schwannomas: personal experience and review of literature.* Otol Neurotol 2011;32:125-31.
- ²² Brackmann DE, Cullen RD, Fisher LM. *Facial nerve function after translabyrinthine vestibular schwannoma surgery.* Otolaryngol Head Neck Surg 2007;136:773-7.
- ²³ Chen Z, Prasad SC, Di Lella F, et al. *The behavior of residual tumors and facial nerve outcomes after incomplete excision of vestibular schwannomas.* J Neurosurg 2014;120:1278-87.
- ²⁴ Mamikoglu B, Wiet RJ, Esquivel CR. *Translabyrinthine approach for the management of large and giant vestibular schwannomas.* Otol Neurotol 2002;23:224-7.
- ²⁵ Bernat I, Grayeli AB, Esquia G, et al. *Intraoperative electromyography and surgical observations as predictive factors of facial nerve outcome in vestibular schwannoma surgery.* Otol Neurotol 2010;31:306-12.
- ²⁶ Magnan J, Barbieri M, Mora R, et al. *Retrosigmoid approach for small and medium-sized acoustic neuromas.* Otol Neurotol 2002;23:141-5.
- ²⁷ Mangham CA Jr. *Retrosigmoid versus middle fossa surgery for small vestibular schwannomas.* Laryngoscope 2004;114:1455-61.
- ²⁸ Sanna M, Russo A, Taibah A, et al. *Enlarged translabyrinthine approach for the management of large and giant acoustic neuromas: a report of 175 consecutive cases.* Ann Otol Rhinol Laryngol 2004;113:319-28.
- ²⁹ Samii M, Gerganov VM, Samii. *A functional outcome after complete surgical removal of giant vestibular schwannomas.* J Neurosurg 2010;112:860-7.
- ³⁰ Yang J, Grayeli AB, Barylyak R, et al. *Functional outcome of retrosigmoid approach in vestibular schwannoma surgery.* Acta Otolaryngol 2008;128:881-886.
- ³¹ Rohit, Piccirillo E, Jain Y et al. *Preoperative predictive factors for hearing preservation in vestibular schwannoma surgery.* Ann Otol Rhinol Laryngol 2006;115:41-6.
- ³² Goddard JC, Schwartz MS, Friedman RA. *Fundal fluid as a predictor of hearing preservation in the middle cranial fossa approach for vestibular schwannoma.* Otol Neurotol 2010;31:1128-34.
- ³³ McCutcheon BA, Graubeger J, Murphy M, et al. *Is patient age associated with perioperative outcomes following surgical resection of benign cranial nerve neoplasms?* World Neurosurg 2016 Feb 5. S1878-8750(16)00177-7.
- ³⁴ Slattery WH 3rd, Francis S, House KC. *Perioperative morbidity of acoustic neuroma surgery.* Otol Neurotol 2001;22:895-902.
- ³⁵ Merkus P, Taibah A, Sequino G, et al. *Less than 1% cerebrospinal fluid leakage in 1,803 translabyrinthine vestibular schwannoma surgery cases.* Otol Neurotol 2010;31:276-83.
- ³⁶ Stieglitz LH, Wrede KH, Gharabaghi A, et al. *Factors affecting postoperative cerebrospinal fluid leaks after retrosigmoidal craniotomy for vestibular schwannomas.* J Neurosurg 2009;111:874-83.
- ³⁷ Bryce GE, Nedzelski JM, Rowed DW, et al. *Cerebrospinal fluid leaks and meningitis in acoustic neuroma surgery.* Otolaryngol Head Neck Surg 1991;104:81-7.
- ³⁸ Mass SC, Wiet RJ, Dinces E. *Complications of the translabyrinthine approach for the removal of acoustic neuromas.* Arch Otolaryngol Head Neck Surg 1999;125:801-4.

Received: March 23, 2016 - Accepted: June 19, 2016

Address for correspondence: Daniele Bernardeschi, Pitié-Salpêtrière Hospital, Department of Otolaryngology Auditory Implants and Skull Base Surgery. Paris, France. 53-87 bd de l'Hopital 75013 Paris, France. Tel. +33 (0)142163112. Fax +33(0)142163114. E-mail: danielle.bernardeschi@aphp.fr

AUDIOLOGY

Severe to profound deafness may be associated with MYH9-related disease: report of 4 patients

La sordità da severa a profonda può essere associata alla malattia MYH9-correlata: report di 4 pazienti

P. CANZI¹, A. PECCI², M. MANFRIN¹, E. REBECCHI¹, C. ZANINETTI², V. BOZZI², M. BENAZZO¹

¹ Department of Otorhinolaryngology, IRCCS Policlinico San Matteo Foundation and University of Pavia, Italy;

² Department of Internal Medicine, IRCCS Policlinico San Matteo Foundation and University of Pavia, Italy

SUMMARY

MYH9-related disease (MYH9-RD) is a rare genetic syndromic disorder characterised by congenital thrombocytopenia and is associated with the risk of developing progressive sensorineural hearing loss, nephropathy and presenile cataracts during childhood or adult life. All consecutive patients enrolled in the Italian Registry for MYH9-RD with severe to profound deafness were included in a retrospective study. The study population involved 147 Italian patients with MYH9-RD: hearing loss was identified in 52% of cases and only 4 patients (6%) presented severe to profound deafness at a mean age of 33 years. Deafness was associated with mild spontaneous bleeding in all patients and with kidney involvement in 3 cases. Cochlear implantation was carried out in 3 cases with benefit, and no major complications were observed. Diagnosis was performed about 28 years after the first clinical manifestation of MYH9-RD, which was never suspected by an otolaryngologist. The clinical and diagnostic aspects of 4 patients with severe to profound deafness are discussed with a focus on therapeutic implications.

KEY WORDS: MYH9 • Hearing loss • Genetic syndrome

RIASSUNTO

La malattia MYH9-correlata è una rara sindrome genetica caratterizzata da piastrinopenia congenita associata al rischio di sviluppare, durante l'infanzia o l'età adulta, ipoacusia neurosensoriale, nefropatia e cataratta presenile ad andamento evolutivo. Furono inclusi in uno studio retrospettivo tutti i casi con sordità da severa a profonda arruolati consecutivamente nel Registro Italiano dei pazienti affetti da malattia MYH9-correlata. La popolazione esaminata coinvolse 147 pazienti Italiani con malattia MYH9-correlata: l'ipoacusia fu identificata nel 52% dei casi e solo 4 pazienti (6%) presentarono un quadro di sordità da severa a profonda all'età media di 33 anni. In tutti i 4 pazienti, la sordità fu associata ad un lieve sanguinamento spontaneo e in 3 pazienti fu accompagnata da un coinvolgimento renale. L'impianto cocleare fu eseguito in 3 casi, con beneficio, in assenza di complicanze maggiori. La diagnosi di malattia MYH9-correlata fu eseguita circa 28 anni dopo la prima manifestazione clinica della malattia che non fu mai sospettata da un otorinolaringoiatra. Saranno discussi gli aspetti clinici e diagnostici di 4 pazienti con sordità da severa a profonda affetti da malattia MYH9-correlata, focalizzando anche le implicazioni terapeutiche.

PAROLE CHIAVE: MYH9 • Ipoacusia • Sindrome genetica

Acta Otorhinolaryngol Ital 2016;36:415-420

Introduction

Over the last century, research and technology have progressively made advances related to deafness and hearing loss, which still remains the most frequent sensory disability in developed societies¹⁻⁴. About 50% of cases with congenital sensorineural hearing loss can be attributed to a genetic cause, and epidemiological studies estimate that in a considerable proportion of “unknown deafness aetiology”, genetic factors are extremely relevant with both diagnostic and therapeutic implications^{3,5-10}.

MYH9-related disease (MYH9-RD) is a rare autosomal-dominant syndromic disorder deriving from mutations in MYH9, the gene encoding for the heavy chain of non-

muscle myosin IIA (NMMHC-IIA)^{11,12}. NMMHC-IIA is expressed in most cell types and tissues and is involved in several processes requiring force and translocation, thus it is essential during cell motility, cytokinesis and maintenance of cell shape¹³. In the inner ear, NMMHC-IIA is extensively distributed in the sensory hair cells of the organ of Corti, as well as in the spiral ligament, spiral limbus, with only minimal expression within the spiral ganglion. All patients with MYH9-RD present since birth with thrombocytopenia and inclusions of NMMHC-IIA in leukocytes. During infancy or adult life, most MYH9-RD patients develop additional clinical manifestations: sensorineural hearing loss, proteinuric nephropathy often leading to end-stage renal failure, cataracts and/or alterations of

liver enzymes¹⁴⁻¹⁶. Each of these non-congenital manifestations can occur alone or can variably associate with the others¹⁷. MYH9-RD includes four syndromes that have been considered for many years as distinct disorders: May-Hegglin Anomaly, Sebastian syndrome, Fechtner syndrome and Epstein syndrome. After the identification of MYH9 as the gene responsible for all of these syndromes, analyses of large series of patients demonstrated that they actually represent some of the different possible clinical presentations of the same condition, for which the definition of MYH9-RD has been introduced^{14 18 19}. Described in 60% of cases and in 36-71% of pedigrees, hearing loss is the most frequent non-congenital manifestation of MYH9-RD^{20 21}. Hearing impairment is limited to high frequencies at clinical onset and in mild forms, but it progressively involves all frequencies in severe phenotypes. When hearing disability is present since childhood or adolescence, patients usually develop severe to profound deafness within the first decades of life^{17 22 23}.

Nowadays, a simple immunofluorescence assay on peripheral blood slides is available to identify patients with MYH9-RD^{24 25}. When severe to profound deafness occurs, performing a proper etiological diagnosis of deafness may have implications for prognostic assessment, patient counselling and treatment. Given that MYH9 mutations primarily damage hair cells, the finding that most MYH9-RD patients have excellent cochlear implantation (CI) outcomes is consistent with the NMMHC-IIA expression pattern observed in animals²⁶. A correct diagnosis of MYH9-RD may help surgical decision-making due to hearing benefits related to CI in this specific genetic disorder. In 2006, the Italian Registry for MYH9-RD was created and approved by the Institutional review board of the IRCCS Policlinico San Matteo Foundation, Pavia, Italy. The experience from the Italian Registry for MYH9-RD of patients with severe to profound deafness is discussed herein, focusing on clinical and diagnostic aspects.

Materials and methods

All consecutive patients enrolled in the Italian Registry for MYH9-RD with severe to profound deafness were included in this retrospective study. All patients underwent a multidisciplinary assessment comprising haematological, audiological, ophthalmologic and nephrological evaluations. Diagnosis of MYH9-RD was made on the basis of the identification of NMMHC-IIA leukocyte inclusions by immunofluorescence assay on peripheral blood slides and confirmed through the identification of the causative MYH9 mutation by molecular screening²⁴. Basic audiological examination consisted of microscopic ear study, pure-tone audiometry, speech recognition score (SRS) using disyllabic word lists presented in quiet conditions, tympanometry and acoustic reflex tests (if necessary). Pure tone average (PTA) was calculated considering air

conduction thresholds at 0.5-1-2-4 KHz (PTA was higher than 70 dB HL in enrolled patients).

Severity of bleeding was classified according to the WHO bleeding score (BS)¹⁷:

- grade 0 = no bleeding;
- grade 1 = only cutaneous bleeding;
- grade 2 = mild blood loss;
- grade 3 = gross blood loss, requiring transfusion;
- grade 4 = debilitating blood loss, retinal or cerebral associated with fatality.

Results

The study population involved 147 Italian patients with MYH9-RD (mean age at the last evaluation: 36 years, standard deviation: 20). Altogether, 139 subjects underwent complete multidisciplinary evaluation. Hearing impairment was identified in 72 cases (52%). Of these, 7 presented mild hearing loss (10%) and 61 showed moderate hearing impairment (84%). The 4 patients with severe to profound deafness (6%) were included in this study. Hearing loss was initially limited to high frequencies and in more severe forms it involved the middle and the low frequencies. In the 72 patients with hearing impairment, the age at onset was homogeneously distributed along the first to sixth decades. In 3 of the 4 cases with severe to profound deafness, hearing loss developed in childhood or adolescence and became severe by the age of 30 years. The mean age of enrolled subjects was 40 years. Table I provides an overview of the basic clinical features. Of note, three patients had sporadic disease deriving from a de novo mutation localised in the N-terminal head domain of NMMHC-IIA. CI was suggested and performed in three patients; in one case CI was carried out before definitive molecular diagnosis of MYH9-RD. CI selection criteria included mean thresholds between 0.5-1-2 kHz > 75 dB HL with open-set SRS ≤ 50% in the best aided condition without lip reading according to Italian recommendations²⁷. Figure 1 shows pure-tone audiometry before surgery (patients 1, 2 and 3) or during the last follow-up (patient 4). In all cases CI was safe and effective in improving the hearing ability, without any perioperative bleeding complications after prophylactic platelet transfusions²⁶. The CI electrode array was inserted through the round window in all cases. CI outcomes were stable over time. Diagnosis of MYH9-RD was made from 14 to 41 years (mean: 28 years) after the first clinical presentation of disease symptoms. In no patients was clinical suspect raised by an otolaryngologist. The main medical history of each patient is summarised below.

Case 1

The patient was referred at the age of 12 years to a nephrology unit because of proteinuria and mild alteration of kidney function. On the same occasion, thrombocytepe-

nia resulting in easy bruising and menorrhagia was also found. The kidney damage quickly progressed over the following years to end-stage renal disease requiring peritoneal dialysis. At the age of 21, the patient underwent a first kidney transplantation that was rejected; a second kidney transplantation was successfully performed at the age of 25. Diagnosis of MYH9-RD was made at the age of 26 and suspected by a nephrologist. Hearing impairment was referred from the age of 20. The first audiological evaluation performed at 22 years of age showed bilateral moderate symmetrical sensorineural hearing loss with recruitment (Metz test: positive). Hearing loss progressed to severe deafness two years later. The patient received benefit from bilateral hearing aids for about 12 years. At the age of 34 years, the patient no longer received sufficient benefit from hearing aids (Table I) and was successfully submitted to CI (SRS with CI and hearing aid: 100% at 50 dB, SRS with CI and without hearing aid: 100% at 60 dB). Post-CI follow-up was of 7 years. Preoperative temporal bone CT scan and MRI showed no anomalies.

Case 2

The patient was referred to a haematology unit at the age of 4 years because of severe thrombocytopenia and easy bruising. A diagnosis of acquired immune thrombocytopenia was made. The patient was therefore treated with several lines of immunosuppressive therapy without any improvements in platelet count; at the age of 12 splenectomy was performed, without benefit. Hearing loss was referred from the age of 20 and progressed to severe deafness by 32 years. Bilateral hearing aids were first used at 30 years: the first audiological evaluation revealed a moderate bilateral symmetrical sensorineural hearing loss with recruitment (Metz test: positive). At the age of 40 years, the patient developed profound hearing loss, proteinuria and chronic renal failure. A diagnostic hypothesis of MYH9-RD was raised by an internist 36 years after the first clinical presentation. Some months later the patient was submitted to CI with benefit: SRS with and without hearing aid in the non-implanted ear was 90% at 50 dB. Preoperative imaging (CT scan and MRI) revealed no anomalies. Hearing results were stable over time (last follow-up: 6 years). Residual hearing in the non-operated side was not useful despite the best aided conditions: a bilateral sequential CI was proposed, but the patient decided to wait.

Case 3

The patient was first referred at the age of 3 years for thrombocytopenia that was discovered because of prolonged bleeding after tonsillectomy. Hearing loss was noticed at the age 8 when he underwent audiometric evaluation that revealed mild bilateral sensorineural hearing defect. Hearing loss was quite asymmetrical (left ear worse than the right one). Consecutive imaging investiga-

tions (CT and MRI) did not show inner ear malformations or retrocochlear pathologies. The patient experienced progression of hearing loss during the following years; the first use of bilateral hearing aids was reported at 34 years when deafness was already severe. Of note, at 12 years a diagnosis of immune thrombocytopenia was established leading to a series of ineffective immunosuppressive treatments (including splenectomy and chronic immunosuppressive drugs) until the age of 21 when the patient refused any further therapies. CI was carried out in the left ear (worst side) at 43 years, one year before the diagnosis of MYH9-RD that was performed at 44 years by an internist. Bilateral sequential CI was carried out in the right ear two years later (SRS with bilateral CI was of 100% at 50 dB). Post-operative follow-up was for 6 years from the first CI.

Case 4

The patient was referred at the age of 35 for a history of thrombocytopenia, recurrent epistaxis and gum bleeding present from late childhood. A history of hearing impairment was also present from at least 3 years. Family history revealed that his mother also had chronic thrombocytopenia and hearing loss. On these bases, a diagnosis of MYH9-RD was suspected by an internist and successively confirmed (21 years after the onset of MYH9-RD symptoms). Audiometric examination at diagnosis revealed moderate bilateral symmetrical sensorineural deafness requiring bilateral hearing aids. Hearing loss progressed to severe deafness after 6 years and mostly involved medium-high frequencies than lower ones (“ski-slope” hearing loss – Fig. 1). During the last follow-up, hearing evaluation did not require CI according to Italian recommendations²⁷ (Table I). No signs of kidney impairment or cataract were present, whereas chronic elevation of transaminases was found.

Discussion

MYH9-RD is a rare autosomal dominant disorder characterised by congenital thrombocytopenia and characteristic leukocyte inclusions of the mutant protein associated with the risk of developing progressive sensorineural hearing loss, nephropathy, cataracts and/or liver enzyme alterations during childhood or adult life^{12 15}. The spectrum of causative mutations of MYH9-RD consists in at least 45 different mutations that have been identified in more than 300 MYH9-RD unrelated families^{15 17 28 34}. Of note, 35-40% of reported patients have sporadic disease caused by a *de novo* mutational event¹⁵.

In the experience of the Italian Registry for MYH9-RD, 4 patients developed severe to profound deafness at a mean age of 33 years. The disease was inherited with a dominant pattern in only one subject, whereas three patients were sporadic cases. In 3 patients (case 1, 2 and 3),

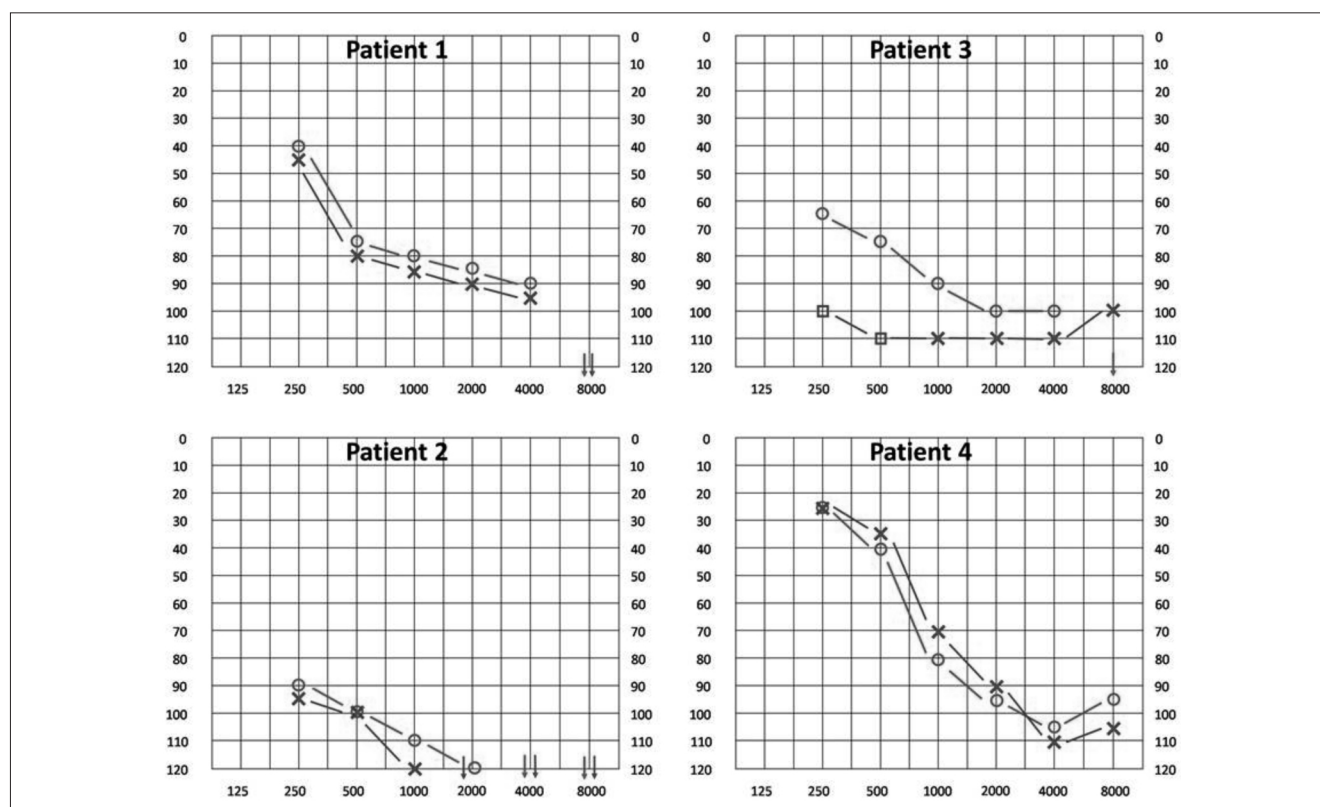


Fig. 1. Pure-tone audiometry before surgery (patients 1, 2 and 3) or during the last follow-up (patient 4).

the NMMHC-IIA mutation involved the N-terminal head domain: according to genotype-phenotype studies, these patients developed severe and early-onset deafness with severe kidney involvement^{17,21}. Mutations in the C-terminal tail domain (case 4) show a low risk of developing severe hearing and kidney impairment: genetic or environmental factors probably interact with the MYH9 mutation leading to profound deafness and renal failure^{17,21}. Deafness was clinically associated with mild spontaneous bleeding (grade 1 or 2 of WHO BS) in all patients and with kidney involvement (one case of kidney transplant) in three cases. Mean age at onset of hearing impairment was 21 years and severe to profound deafness occurred after a mean age of 11.5 years. Diagnosis was reached at a mean age of 36 years with a diagnostic delay of about 28 years after the first clinical manifestation of MYH9-RD. In no patients the clinical suspect was raised by an otolaryngologist, even if patients were submitted to audiological evaluations starting from a mean age of 24 years. Since the identification of the first MYH9 gene mutations, the number of MYH9-RD cases described in literature has greatly increased, particularly in Italy and Japan²⁴. Even though diagnosis of MYH9-RD can be easily confirmed by an immunofluorescence screening test, it is often missed because it is not suspected^{15,24}. Diagnostic difficulties derive from the poor awareness of the disease by physicians because of its rarity, heterogeneous MYH9-RD clinical presentation and the relative high

frequency of sporadic patients who have negative family history. From the otolaryngologist’s point of view, the association of bilateral sensorineural deafness with a personal or familiar history of thrombocytopenia, possibly associated with the other non-haematological manifestations of the disease, represents the key element for raising diagnostic suspicion of MYH9-RD. The literature highlights that 3-7% of patients with severe to profound deafness do not benefit from CI^{8,9}. It has been hypothesised that patients with mutations causing spiral ganglion pathologies may show poor results in comparison with those ones involving hair cells^{10,29}. The effectiveness of CI in MYH9-RD patients is strongly related to the localisation of NMMHC-IIA mutations in the sensory hair cells of the organ of Corti with only minimal involvement of the spiral ganglion²⁶. During the last years, we are witnessing a rapid evolution in genetics with specific implications⁵. “Operate” without a diagnosis of disease may be debatable, and it also means the best management required with medical, legal and ethics implications is largely unknown.

Conclusions

According to the experience of the Italian Registry for MYH9-RD, hearing loss was observed in about half of cases, but severe to profound deafness was found in a limited percentage of subjects. When severe to profound

Table I. Basic clinical features and patients clinical presentation at diagnosis.

Patient /Family	Age/ Gender	Inheritance	NMMHC-IIA mutation (domain)	Bleeding diathesis (BS)	Platelet count (x 10 ⁹ /L)	PTA right/left dB HL (SRS)	Tympanometry and acoustic reflex test	Kidney involvement	Cataract	Liver enzyme alterations
1/1	34/F	Sporadic	p.R702C (HD)	Easy bruising, menorrhagia (2)	14	82/87 dB HL (bilateral SRS < 50%)	Ty A, absent acoustic reflexes	Previous kidney transplantation	No	No
2/2	40/M	Sporadic	p.R702C (HD)	Easy bruising (1)	31	115/120 dB HL (bilateral SRS < 50%)	Ty A, absent acoustic reflexes	Nephrotic range proteinuria, chronic renal failure	No	Yes*
3/3	43/M	Sporadic	p.R702S (HD)	Epistaxis, easy bruising (2) Bleeding after tonsillectomy and tooth extractions (2)	25	91/110 dB HL (bilateral SRS < 50%)	Ty A, absent acoustic reflexes	Proteinuria	No	No
4/4	43/M	Autosomal-dominant	D1447V (TD)	Gingival bleeding (2)	48	80/76 dB HL (bilateral SRS > 50%)	Ty A, absent acoustic reflexes	No	No	Yes

Patient/Family= patient number and belonging family

Age/Gender= age at Italian Registry enrolment/gender.

Inheritance= type of inheritance of the MYH9-RD: sporadic ("de novo" mutation) or autosomal-dominant

NMMHC-IIA mutation (domain)= type of MYH9 gene mutation (domain involved: N-terminal head domain (HD), or C-terminal tail domain (TD))

Bleeding diathesis (BS)= bleeding symptoms (severity of bleeding according to the WHO bleeding score)¹⁷⁾

Platelet count x 10⁹/L = platelet count measured by phase-contrast microscopy

PTA right/left (SRS)= Pure tone average calculated considering air conduction thresholds at 0.5-1-2-4 KHz before CI when performed or during the last follow-up (open-set speech recognition score in the best aided quiet condition without lip reading)

Tympanometry and acoustic reflex test= type of tympanogram according to Jerger's classification, present or absent acoustic reflexes

Kidney involvement= kidney damage developed

Liver enzyme alterations= liver involvement. *Patient with HCV hepatitis

deafness occurred, kidney involvement was present in almost all cases according to the genotype-phenotype correlation. When bilateral sensorineural hearing loss is associated with a personal or family history of thrombocytopenia and/or kidney involvement, MYH9-RD should be suspected.

Acknowledgements

All the authors certify that they receive no financial support or funding for this work. This work was supported in part by a research grant from IRCCS Policlinico San Matteo Foundation to A.P.

References

- Hilgert N, Smith RJ, Van Camp G. *Forty-six genes causing nonsyndromic hearing impairment: which ones should be analyzed in DNA diagnostics.* *Mutat Res* 2009;681:189-96.
- Fortnum HM, Summerfield AQ, Marshall DH. *Prevalence of childhood hearing impairment in the United Kingdom and implications for universal neonatal hearing screening: questionnaire based ascertainment study.* *BMJ* 2001;323:536-40.
- Paludetti G, Conti G, DI Nardo W, et al. *Infant hearing loss: from diagnosis to therapy Official Report of XXI Conference of Italian Society of Pediatric Otorhinolaryngology.* *Acta Otorhinolaryngol Ital* 2012;32:347-70.
- Grasso DL, Hatzopoulos S, Cossu, et al. *Role of the "rooming-in" on efficacy of universal neonatal hearing screening programmes.* *Acta Otorhinolaryngol Ital* 2008;28:243-6.
- Martini A, Calzolari F, Sensi A. *Genetic syndromes involving hearing.* *Int J Pediatr Otorhinolaryngol* 2009;73:S2-12.
- Tekin D, Tutar E, Ozturkmen Akay H, et al. *Comprehensive genetic testing can save lives in hereditary hearing loss.* *Clin Genet* 2015;87:190-1.
- Bitner-Glindzicz M. *Hereditary deafness and phenotyping in humans.* *Br Med Bull* 2002;63:73-94.
- Archbold SM, Nikolopoulos TP, Lloyd-Richmond H. *Long-term use of cochlear implant systems in paediatric recipients and factors contributing to non-use.* *Cochlear Implants Int* 2009;10:25-40.
- Raine CH, Summerfield Q, Strachan DR, et al. *The cost and analysis of nonuse of cochlear implants.* *Otol Neurotol* 2008;29:221-4.
- Eppsteiner RW, Shearer AE, Hildebrand MS, et al. *Prediction of cochlear implant performance by genetic mutation: the spiral ganglion hypothesis.* *Hear Res* 2012;292:51-8.
- Kelley MJ, Jawien W, Ortel TL, et al. *Mutation of MYH9, encoding non-muscle myosin heavy chain A, in May-Hegglin anomaly.* *Nat Genet* 2000;26:106-8.

- ¹² Seri M, Cusano R, Gangarossa S, et al. *Mutations in MYH9 result in the May-Hegglin anomaly, and Fechtner and Sebastian syndromes. The May-Hegglin/Fechtner Syndrome Consortium.* Nat Genet 2000;26:103-5.
- ¹³ Vicente-Manzanares M, Ma X, Adelstein RS, et al. *Non-muscle myosin II takes centre stage in cell adhesion and migration.* Nature 2009;10:778-90.
- ¹⁴ Seri M, Pecci A, Di Bari F, et al. *MYH9-related disease: May-Hegglin anomaly, Sebastian syndrome, Fechtner syndrome, and Epstein syndrome are not distinct entities but represent a variable expression of a single illness.* Medicine (Baltimore) 2003;82:203-15.
- ¹⁵ Balduini CL, Pecci A, Savoia A. *Recent advances in the understanding and management of MYH9-related inherited thrombocytopenias.* Br J Haematol 2011;154:161-74.
- ¹⁶ Pecci A, Biino G, Fierro T, et al. *Italian Registry for MYH9-related diseases: alteration of liver enzymes is a feature of the MYH9-related disease syndrome.* PLoS One 2012;7:e35986.
- ¹⁷ Pecci A, Klersy C, Gresele P, et al. *MYH9-related disease: a novel prognostic model to predict the clinical evolution of the disease based on genotype-phenotype correlations.* Hum Mutat 2014;35:236-47.
- ¹⁸ Althaus K, Greinacher A. *MYH-9 related platelet disorders: strategies for management and diagnosis.* Transfus Med Hemother 2010;37:260-7.
- ¹⁹ Kunishima S, Saito H. *Advances in the understanding of MYH9 disorders.* Curr Opin Hematol 2010;17:405-10.
- ²⁰ Dong F, Li S, Pujol-Moix, et al. *Genotype-phenotype correlation in MYH9-related thrombocytopenia.* British Journal Haematology 2005;130:620-7.
- ²¹ Pecci A, Panza E, Pujol-Moix N, et al. *Position of nonmuscle myosin heavy chain IIA (NMMHC-IIA) mutations predicts the natural history of MYH9-related disease.* Human Mutation 2008;29:409-17.
- ²² Sekine T, Konno M, Sasaki, et al. *Patients with Epstein-Fechtner syndromes owing to MYH9 R702 mutations develop progressive proteinuric renal disease.* Kidney Int 2010;78:207-14.
- ²³ De Rocco D, Zieger B, Platokouki H, et al. *MYH9-related disease: five novel mutations expanding the spectrum of causative mutations and confirming genotype/phenotype correlations.* Eur J Med Genet 2013;56:7-12.
- ²⁴ Savoia A, De Rocco D, Panza E, et al. *Heavy chain myosin 9-related disease (MYH9-RD): neutrophil inclusions of myosin-9 as a pathognomonic sign of the disorder.* Thromb Haemost 2010;103:826-32.
- ²⁵ Kitamura K, Yoshida K, Shiraishi Y, et al. *Normal neutrophil myosin IIA localization in an immunofluorescence analysis can rule out MYH9 disorders.* J Thromb Haemost 2013;11:2071-3.
- ²⁶ Pecci A, Verver EJ, Schlegel N, et al. *Cochlear implantation is safe and effective in patients with MYH9-related disease.* Orphanet J Rare Dis 2014;9:100 doi: 10.1186/1750-1172-9-100.
- ²⁷ Berrettini S, Arslan E, Baggiani A, et al. *Analysis of the impact of professional involvement in evidence generation for the HTA Process, subproject "cochlear implants": methodology, results and recommendations.* Acta Otorhinolaryngol Ital 2011;31:273-80.
- ²⁸ Saposnik B, Binard S, Fenneteau O, et al. *Mutation spectrum and genotype-phenotype correlations in a large French cohort of MYH9-related disorders.* Mol Genet Genomic Med 2014;2:297-312.
- ²⁹ Miyagawa M, Nishio SY, Ikeda T, et al. *Massively parallel DNA sequencing successfully identifies new causative mutations in deafness genes in patients with cochlear implantation and EAS.* PLoS One 2013;8:e75793.

Received: April 28, 2015 - Accepted: April 30, 2016

VESTIBOLOGY

A connection between neurovascular conflicts within the cerebellopontine angle and vestibular neuritis, a case controlled cohort study

Relazione fra conflitti neurovascolari a livello dell'angolo pontocerebellare e neurite vestibolare, uno studio di coorte caso-controllo

B. LOADER¹, I. LINAUER¹, S. KORKESCH¹, I. KRAMMER-EFFENBERGER², V. ZIELINSKI¹, N. SCHIBANY², A. KAIDER³, E. VYSKOCIL⁴, D. TSCHOLAKOFF², P. FRANZ¹

¹ Department of Otorhinolaryngology, Head and Neck Surgery, Rudolfstiftung Tertiary Teaching Hospital, Juchgasse, Vienna, Austria; ² Institute of Diagnostic and Interventional Radiology, Rudolfstiftung Tertiary Teaching Hospital, Juchgasse, Vienna, Austria; ³ Center for Medical Statistics, Informatics and Intelligent Systems, Medical University of Vienna, Spitalgasse, Vienna, Austria; ⁴ Department of Otorhinolaryngology, Head and Neck Surgery, Vienna General Hospital, Medical University of Vienna, Spitalgasse, Vienna, Austria

SUMMARY

This retrospective, observer blinded case-control study aims to compare the prevalence of neurovascular conflicts (NVCs) of the vestibulocochlear nerve and the anterior inferior cerebellar artery (AICA) in patients presenting with clinical signs of acute vestibular neuritis with and without subsequent objective vestibular function loss (VFL). 58 acute cases of clinically suspected acute vestibular neuritis were investigated with same day cranial MRI at a tertiary referral centre and compared to 61 asymptomatic controls. The prevalence of NVCs in cases with objective VFL were also compared to cases without VFL. Radiologists described the NVC as “no contact” (Grade 0), “contact < 2 mm” (Grade 1), “contact > 2 mm” (Grade 2) and “vascular loop presence” (Grade 3) without knowledge of neurotological data. Neurotological data was collected without knowledge of MRI findings. Vestibular function was tested by bithermic caloric irrigation. 26 cases (45%) showed caloric VFL (Group A), whereas 32 (55%) exhibited no VFL (Group B). Group A included 13 cases with NVCs (50%), Group B included 26 NVC cases (82%) ($p = 0.012$) and the control group included 16 individuals (26%) ($p < 0.001$ for comparison of all 3 groups). Group B had a significantly higher NVC-Grading than Group A ($p = 0.009$). There was no statistically significant association between NVCs and either SNHL or tinnitus ($p > 0.05$). Our results suggest that patients presenting with clinical signs of acute vestibular neuritis who show symmetrical caloric vestibular function test results have a significantly higher NVC prevalence in the cerebellopontine angle.

KEY WORDS: Neurovascular conflict • Vestibular neuritis • Vestibular function loss • SNHL • Tinnitus

RIASSUNTO

Il presente studio retrospettivo a singolo cieco si pone come obiettivo quello di valutare in che percentuale di casi di pazienti che si presentano con sintomatologia compatibile con neurite vestibolare acuta, con e senza perdita oggettiva della funzione vestibolare (VFL), sia presente un conflitto neurovascolare fra il nervo vestibolococleare e la arteria cerebellare anteroinferiore (AICA). 58 pazienti con sintomatologia suggestiva per neurite vestibolare acuta, valutati con RMN presso un centro di terzo livello, sono stati confrontati con 61 pazienti asintomatici. I radiologi hanno dato valutato la presenza di conflitto neurovascolare, in assenza di dati clinici, conferendo ai rilievi oggettivi una valutazione in una scala da 0 a 3 a seconda che il contatto fosse: nessuno; inferiore a 2 mm; superiore ai 2 mm; presenza di vascular loop. I reperti neurootologici sono stati quindi raccolti all'oscuro del risultato dell'imaging. La funzione vestibolare è stata testata con prova calorica bitermica. Alla prova calorica 26 casi (45%) hanno mostrato segni oggettivi di deficit vestibolare (Gruppo A), 32 casi (55%) non hanno invece mostrato alcun deficit labirintico (Gruppo B). Il gruppo A ha incluso 13 casi (50%) con evidenza di conflitto neurovascolare (NVC), il gruppo B ha incluso 26 casi con NVC (82%) ($p = 0.012$) mentre i controlli hanno incluso 16 casi con NVC (26%). La differenza fra i tre gruppi ha mostrato significatività statistica ($p < 0.001$). Il Gruppo B ha mostrato un'associazione con un grading di conflitto più elevato rispetto al Gruppo A ($p = 0.009$). La presenza di NVC non ha avuto un'associazione statisticamente significativa né con la presenza di SNHL né con la presenza di acufene ($p > 0.05$). I nostri dati indicano che la presenza di conflitti neurovascolari a livello dell'angolo pontocerebellare è superiore in quei pazienti che in presenza di una sintomatologia compatibile con neurite vestibolare acuta abbiano una funzionalità simmetrica alla prova calorica.

PAROLE CHIAVE: Conflitto neurovascolare • Neurite vestibolare • Deficit vestibolare • SNHL • Acufene

Acta Otorhinolaryngol Ital 2016;36:421-427

Introduction

The phenomenon of neurovascular conflicts (NVCs) and compression syndromes of the head and neck has been controversially discussed for over three decades. Primarily entities such as trigeminal neuralgia and hemifacial spasm have been accepted to have a pathogenetic and clinically relevant connection to a neurovascular conflict¹. In neurotology, a variety of symptom combinations have been studied to analyse the relevance of neurovascular conflicts within the cerebellopontine angle. Primarily, sensorineural hearing loss, tinnitus and recurrent paroxysmal vertigo have been studied. Neurovascular surgical intervention for intractable symptoms, mainly vertigo, have repeatedly been described since 1975^{2,3}. Additionally, Esfahani et al. studied the efficiency of CT-cisternography in the analyses of patients with recurrent vertigo episodes in the late 1980s⁴. With the development of MRI techniques, the focus on vessel loops, neurovascular compression and neurovascular conflicts has intensified⁵⁻⁷. After having been described over 30 years ago, vestibular paroxysmia has subsequently become a well-known differential diagnosis in patients with recurrent paroxysmal vertigo, characterised by short intense recurrent vertigo attacks⁸.

However, it is not yet clear whether NVCs might be connected to acute vestibular neuropathy itself or if NVCs may mimic the clinical signs of acute vestibular neuritis in certain cases. For instance, although suffering from vestibular paroxysmia and responding well to medical treatment, it has been shown that patients suffer from a slow progressive reduction in peripheral vestibular function over time⁹. It has also been shown that a NVC does alter the functionality of the 8th cranial nerve as such and influences the compound action potential in audiometric brainstem response (ABR) studies¹⁰. To the best of our knowledge, it is not yet evident that a NVC might trigger a prolonged and intense vertigo attack such as is seen in acute vestibular neuritis.

Therefore, the present study aimed to scrutinise the prevalence of the neurovascular conflict in patients presenting with clinical signs of acute vestibular neuritis, such as massive primary onset vertigo with a duration of several hours, vomiting and spontaneous horizontal nystagmus, without signs of central nervous system pathology. Our study especially aimed to identify a difference in the frequency of neurovascular contact, and the extent of contact between nerve and blood vessel, in patients with subsequent normal vestibular function compared to those with reduced objective vestibular activity.

Materials and methods

Ethical Considerations

Due to the anonymous and retrospective and completely non-invasive nature of this study, there were no ethical concerns with this study. Where applicable, the

instructions in the Declaration of Helsinki were followed.

Overall, data from 119 MRI patients admitted to our institution for clinically suspected acute vestibular neuritis were retrospectively analysed. 58 patients with clinically suspected vestibular neuritis (acute vertigo, spontaneous nystagmus, nausea, vomiting) and 61 controls (who had presented with tinnitus without vestibular signs) were included in the study.

Firstly, age and sex were noted before results of audiometric and vestibular testing were documented. All patients included had a pathological clinical head thrust test in the plane of the lateral semicircular canal, suggesting superior vestibular neuritis. Further objective vestibular testing was done by binaural caloric water irrigation according to Fitzgerald and Hallpike (44°C and 30°C) 3-5 days after symptom onset before the Jongkees formula was used to determine vestibular loss. Patients with a caloric asymmetry of >30% were grouped as objective VFL. Total bilateral vestibular areflexia was deemed bilateral VFL. Posturography and vestibular evoked myogenic potential testing was not available at our institution during the time frame patients presented to our clinic. Central signs such as ataxia and skew deviation were excluded via neurological consult. All patients underwent pure tone audiometry. No patient with low-frequency hearing loss was included in the study, thereby eliminating Meniere's disease from cohort. Cases with a positive history of Meniere's disease and/or recurrent vertigo attacks were also excluded. Patients with benign paroxysmal positional vertigo were not included. Cases of acoustic neurinoma, cerebellar infarction, multiple sclerosis or other central nervous system pathologies were excluded.

Secondly, radiologists independently re-evaluated all images for the presence of neurovascular contact between the anterior inferior cerebellar artery (AICA) and the vestibulocochlear nerve (VIII). This neurovascular contact was graded as "no contact" (Grade 0), "contact up to 2 mm" (Grade 1), "contact larger than 2 mm" (Grade 2) and "vascular loop presence" (3). The grading system was based on the work of Siricki et al.¹¹

The study was conducted with bilateral observer blinding. In essence, the radiologist did all analyses without knowledge of otologic pathologies, while the otologic findings were also documented without knowledge of radiologic results.

The standard 1.5 TESLA-MRI protocol consisted of T2 turbo spin echo (TSE) transversal with 5 mm section thickness, diffusion weighted imaging transversal (DWI), T2 constructive interference steady state (CISS) transversal with 1 mm section thickness across the cerebellopontine angle and T1 multiplanar reconstruction (MPR) coronal 3 mm sections with contrast.

Statistical analyses

Statistical analyses were independently done by the Centre for Medical Statistics, Informatics and Intelligent Sys-

tems, Medical University of Vienna. Frequencies of binary variables were compared between groups using the Chi-square test. The ordinal scaled grade of neurovascular contact (grades 0 to 3) was compared between groups using the nonparametric Wilcoxon rank sum test (2-group comparisons) and the nonparametric Kruskal-Wallis test (3-group comparisons), respectively. P values < 0.05 were considered as indicating statistical significance. The SAS software (SAS 9.3; 2002-2010, SAS Institute Inc., Cary, NC, USA) was used for statistical calculations.

Results

In total 119 patients were included in the study. 58 patients with clinical signs of vestibular neuritis had an average age of 54.2 years (\pm 14.1 years) with 33 males and 25 females in the cohort, without significant differences between sexes. Of these, 58 cases 26 had objective caloric vestibular loss (Group A), whereas 32 had no objective caloric weakness (Group B). The control group of patients without signs of vestibular neuritis (Group C) had an average age of 55.1 years (\pm 11.2 years) with 24 males and 37 females.

There was no statistically significant correlation between neurovascular conflict and tinnitus or sensorineural hearing loss with no significant differences between the groups ($p > 0.05$).

In cases of suspected vestibular neuritis with pathological caloric irrigation results (Group A, Fig. 1, $n = 26$), neurovascular contact could only be seen in 50% of cases. In

patients presenting with initial clinical signs of acute vestibulopathy, who consequently showed symmetrical caloric results, without objective peripheral vestibular loss (Group B, $n = 32$) a significantly higher presence of neurovascular contact was seen ($n = 26/32 = 82\%$; $p = 0.012$) (Fig. 1).

In Group C (asymptomatic controls), 16/61 cases with NVCs could be identified (26%). When compared to controls (Group C), patients with signs of vestibular neuritis (Group A and B) had significantly more NVCs ($p < 0.001$). When compared separately, a significantly higher prevalence of NVCs could be identified in Group A (with objective loss) than in controls (Group C, $p = 0.039$) (Table I).

Additionally, the grading of the NVC was significantly higher in patients with no objective vestibular loss compared to patients with vestibular loss and controls ($p < 0.001$, Fig. 2). Group A ($n = 26$) showed 13 cases (50%) without NVC, while grade 1 NVC could be identified in 4 (15%), grade 2 in 3 (12%) and grade 3 in 6 (23%) cases. In comparison, patients with acute vestibular clinical signs without objective VFL in Group B exhibited no contact in 4 (13%), grade 1 in 7 (21%), grade 2 in 8 (25%) and grade 3 in 13 (41%) cases. Group C (control group) revealed no contact in 44 (72%), grade 1 in 4 (7%), grade 2 in 9 (15%) and grade 3 in 4 (7%) cases. The absolute number of cases per grade is summarised in Table II. Group B (patients with signs of vestibular neuritis without objective vestibular loss) had significantly higher NVC grading than Group A (patients

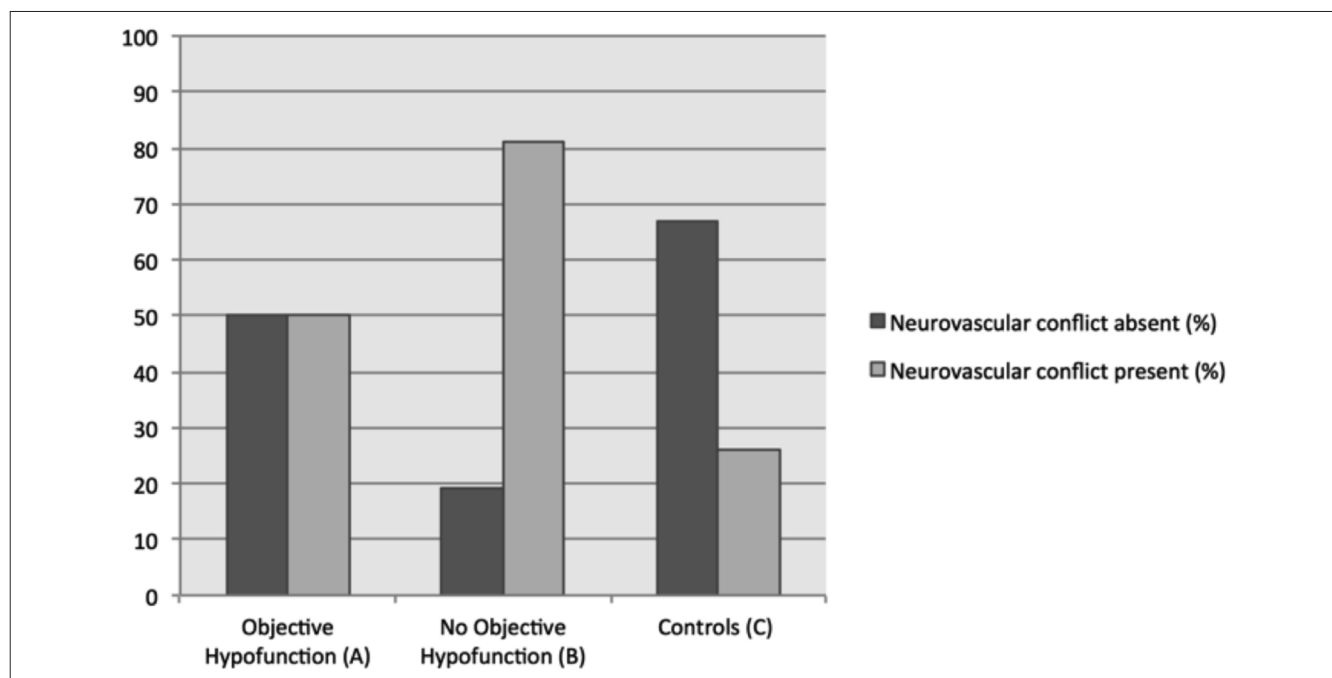


Fig.1. 13 of 26 cases (50%) without caloric vestibular loss (Group A; left) presented NVCs. In Group B, i.e. cases without vestibular loss, a significantly higher amount NVCs could be identified, namely in 26/32 cases (82%) compared to 7 (20%) cases without NVCs ($p = 0.012$) and controls ($p < 0.001$).

Table I. Absolute number of cases analysed. Detailed analyses showed an equal amount of patients with neurovascular conflicts (NVCs) in patients with signs of vestibular neuritis with subsequent objective vestibular loss (Group A). Group B (patients with signs of vestibular neuritis without objective vestibular loss) had significantly more NVC's than controls ($p < 0.001$), as well as significantly more than Group A ($p = 0.012$).

NVC	Group A (n)	Group B (n)	Group C (Controls) (n)	Total (n)
No	13	6	45	64
Yes	13	26	16	55
Total (n)	26	32	61	119

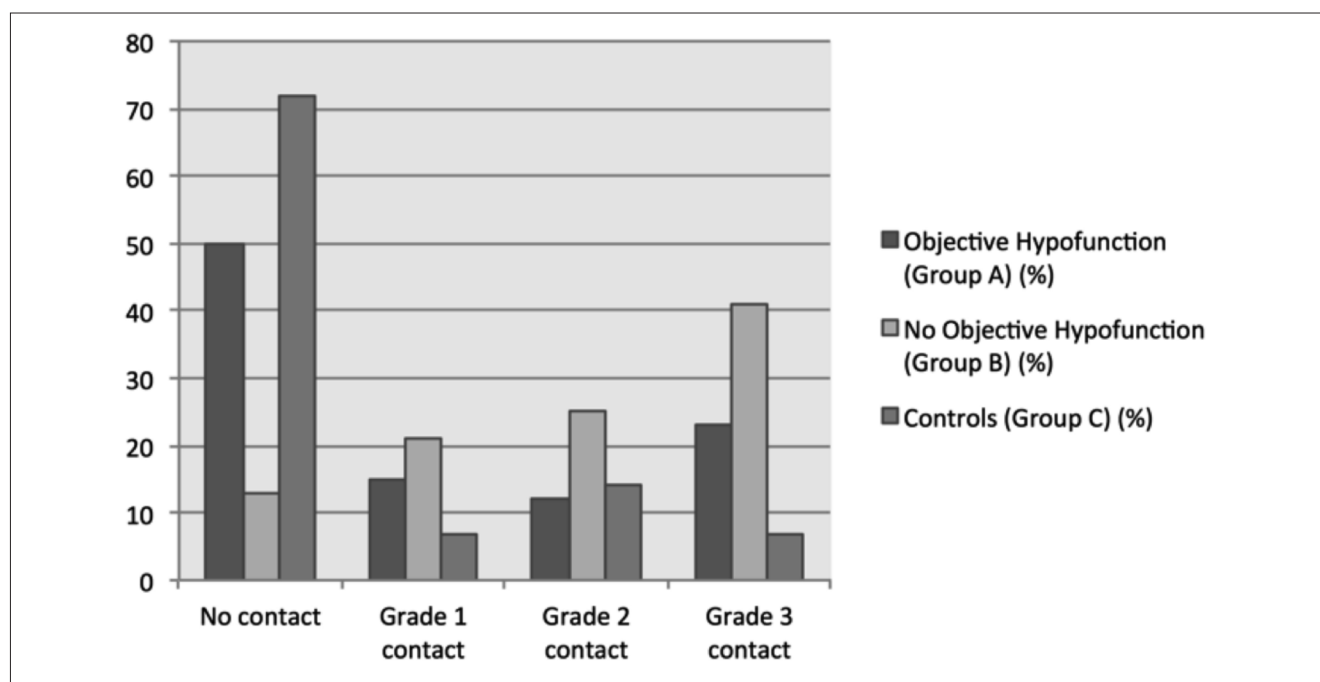


Fig. 2. Distribution of NVC grading depicted as percentage of cases per NVC Grade. In cases with caloric vestibular loss, significantly fewer NVC's could be described ("no contact") and the higher the NVCs grading became, the more cases with normal calorics were identified ($p < 0.0001$).

Table II. Grading of NVCs per group. The grading of groups A and B were significantly higher than the control group C ($p < 0.001$). Group B (patients with signs of vestibular neuritis without objective vestibular loss) had significantly higher NVC grading than Group A (patients with signs of vestibular neuritis with subsequent objective vestibular loss) ($p = 0.009$).

Grade of NVC	Group A (n)	Group B (n)	Group C (n)	Total (n)
0	13	4	44	61
1	4	7	4	15
2	3	8	9	20
3	6	13	4	23
Total (n)	26	32	61	119

with signs of vestibular neuritis with subsequent objective vestibular loss) ($p = 0.009$).

Interestingly, more bilateral NVC's could be identified in group B, while unilateral contact was evenly spread between right and left (Fig. 3). In patients with objective VFL (Group A), the side of the NVC did not correlate significantly with the acute objective vestibular loss.

Discussion

New findings

The present study showed a significantly higher number of NVCs in patients presenting with symptoms of acute peripheral vestibulopathy without objective vestibular function loss (Group B) compared to patients with VFL and controls. Secondly, Group B had a statistically sig-

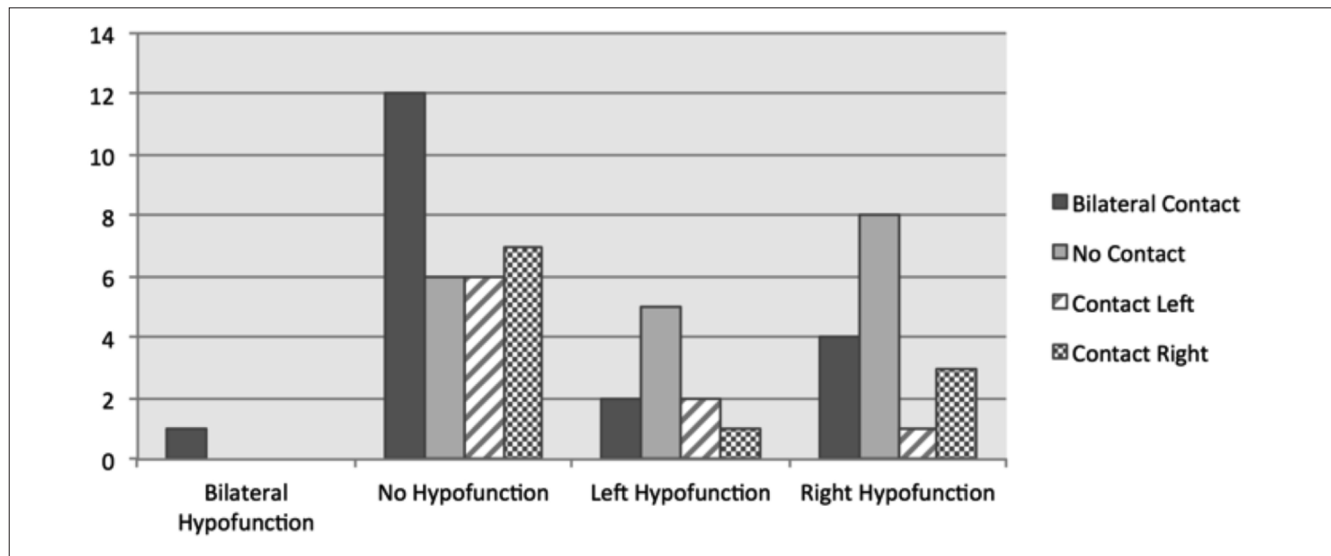


Fig. 3. One case showed bilateral contact and bilateral vestibular loss, whereas in 12 symptomatic cases bilateral NVCs with no vestibular loss could be identified. In addition, noticeably more cases of unilateral hypofunction could be identified in patients without NVC's ("no contact") than patients with objective vestibular loss.

nificantly higher NVC grading than Group A and controls (Fig. 2). Thirdly, a noticeably high ratio of bilateral NVC's could be found in Group B (Fig. 3).

Comparison to previously published data:

It has been reported previously that caloric weakness does not correlate to the severity of subjective symptom perception and symptom intensity in peripheral vestibular disorders¹². This also seems to be a relevant consideration when scrutinising the relevance of vessel loop presence in the inner ear canal. Interestingly, Applebaum et al. described normal calorics in 50% of a small cohort of vessel loop cases (n = 10) with sensorineural hearing loss as identified with CT, where the looping occurred within the auditory canal¹³. A second manuscript by the same research group also identified pathological vestibular function results in a case series of 15 patients, with spontaneous nystagmus in all but one case, without having vertigo as a primary presenting symptom¹⁴. As in our study, the low frequency caloric test was used. In the data presented here, the clinical head thrust test (which is a high frequency test) complemented the caloric findings. In our MRI-based collective, similar results to the first patient collective was found with 50% of vestibular loss patients having NVCs, yet all our cases presented with acute clinical signs of vestibular neuritis such as spontaneous nystagmus, persistent rotatory vertigo of sudden onset and vomiting. Additionally, in this study it was not a prerequisite, as it was in the cited study, that the NVC was located within the internal auditory canal (IAC) but merely in the entry zone of the vestibulocochlear nerve into the cerebellopontine angle. Our findings for vertigo patients seem to be analogous to the findings of van der Steenstraten, who reported

no correlation between the extension of the AICA into the IAC and hearing loss cases¹⁵. This is in turn analogous to the work of Sirickci, who classified NVCs similarly to the grading system used in this study, while adding on a class 4 ("indentation"), which could not be implemented using our methodology¹¹.

It has been accepted that the mere chronic contact between the nerve and blood vessel seems to be vital in the pathogenesis of vestibular paroxysmia. This vertigo entity typically presents with short, sharp spells of vertigo, periodic (but not compulsory) nausea and has a recurrent nature. In up to 60% of paroxysmia cases vertigo spells might be induced by certain head movement⁹. Over time, patients seem to develop a caloric vestibular function loss^{9 14}. Despite evidence of vestibular loss developing over time in patients with vestibular paroxysmia, it is still unclear whether a neurovascular conflict can mimic the acute symptoms of vestibular neuritis. This stands in contrast to vestibular "pseudoneuritis" or acute vestibular syndrome of vascular origin, which can easily be mistaken for acute peripheral vestibulopathy and has been widely accepted as important differential diagnoses to acute vestibular neuropathy¹⁶.

The actual pathogenesis of acute vestibulopathy (i.e. "vestibular neuritis") has to date not been proven beyond a doubt. Among others, strong arguments have been made for the reactivation of herpes simplex virus type 1¹⁷. Recurrence of vestibular neuritis is deemed as rare as 1.9% and mostly occurs contralaterally, although varying numbers and hypotheses on the cause of recurrence have been published^{18 19}. However, objective recovery of vestibular function occurs over months to years and not over days²⁰. In our patient cohort, we identified a remarkably high

number of cases with presenting signs of vestibular pathology, where caloric irrigation values were symmetrical and within the normal range within days (Group B, Fig. 1). With the exclusion of Meniere's disease (through the absence of recurrent attacks in the patient history and no low-frequency hearing loss found in the pure tone audiometry), migraine and other central nervous system pathologies via neurological consult and imaging from Groups A and B, the focus fell on why patients showed non-pathological caloric irrigation results within days of symptom onset. The only remarkable finding in Group B (Fig. 1) was the high prevalence of NVCs within this group ($n = 28 / 32 = 88\%$, Fig. 1). No remarkable findings could be found in the remaining 7 cases of Group B reported herein.

Clinical aspects and hypotheses

Although our data cannot objectively prove beyond a doubt that the neurovascular conflict of the cerebellopontine angle is to blame for the results of the cases of Group B, it does suggest a possible connection between NVCs and acute vestibular system dysfunction. Further study is necessary to prove or disprove the suspicions raised by our patient groups before treatment options similar to

those implemented in vestibular paroxysmia could be explored.

Hypothetically, two pathological mechanisms might be suspected and considered for further study: 1) neuronal excitation due to direct contact between blood vessel and nerve; 2) progressive neuronal damage. On the one hand, the nerve-vessel conflict may stimulate the activity of the vestibular nerve pathologically in analogous fashion to vestibular paroxysmia, albeit with a vertigo attack of longer duration and a greater intensity of the attack as a result. On the other hand, repeated and continual contact of nerve and blood vessel might result in a slow and progressive loss of function until an attack is precipitated. This seems possible (although speculative at best), because it has previously been shown that vestibular paroxysmia patients slowly lose vestibular activity over time⁹. To the best of our knowledge, there have been no reports on AICA – vestibular nerve conflicts resulting in acute vestibular neuritis symptoms to date. Conversely, in cases of bilateral NVC, a combination of excitation and damage might be a relevant factor. However, the data available to us at present does not allow for a conclusive explanation of the pathogenesis and physiological proof behind our observations.

Conclusions

To the best of our knowledge, the clinical data that patients presenting with classical signs of vestibular neuritis, who show normal caloric irrigation results, have a high presence of NVCs between the 8th cranial nerve and the AICA compared to patients with objective vestibular functional loss, is unique.

Acknowledgements

The authors would like to thank Tanja Hojka and Tina Lehner for their logistical assistance.

References

- 1 Jannetta PJ. *Trigeminal neuralgia and hemifacial spasm—etiology and definitive treatment*. *Trans Am Neurol Assoc* 1975;100:89-91.
- 2 Jannetta PJ. *Neurovascular cross-compression in patients with hyperactive dysfunction symptoms of the eighth cranial nerve*. *Surg Forum* 1975;26:467-9.
- 3 Reuter W, Fetter M, Albert FK. *Vestibular paroxysmia. A rare but important differential diagnosis*. *HNO* 2008;56:421-4.
- 4 Esfahani F, Dolan KD. *Air CT cisternography in the diagnosis of vascular loop causing vestibular nerve dysfunction*. *AJNR Am J Neuroradiol* 1989;10:1045-9.
- 5 Papanagiotou P, Grunwald IQ, Politi M, et al. *Vascular anomalies of the cerebellopontine angle*. *Radiologe* 2006;46:216-22.
- 6 Parnes LS, Shimotakahara SG, Pelz D, et al. *Vascular relationships of the vestibulocochlear nerve on magnetic resonance imaging*. *Am J Otol* 1990;11:278-81.

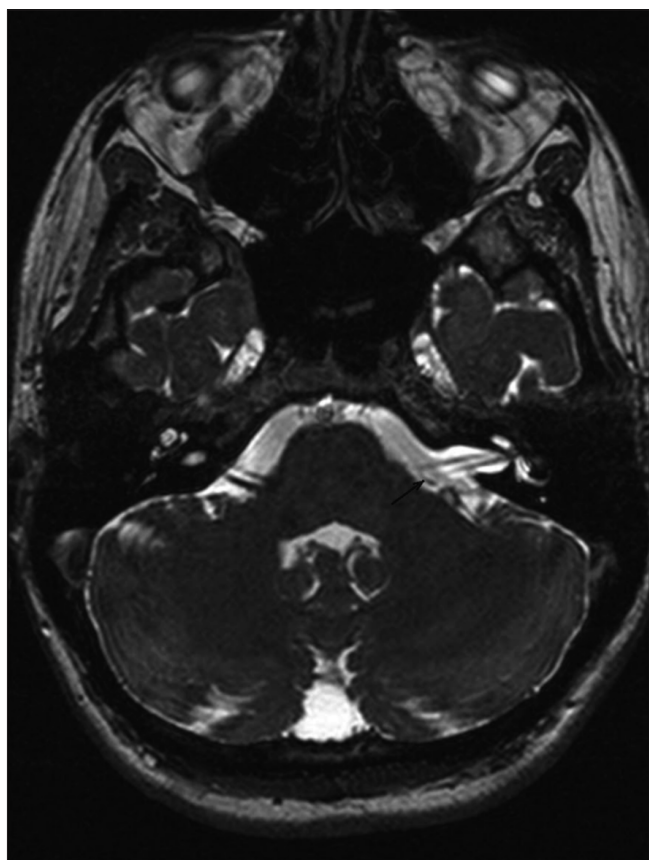


Fig. 4. Vessel loop formation (Grade 3 NVC) on the left in a patient with clinically suspected acute vestibular neuritis without objective caloric weakness. It can be noted that the blood vessel does not enter the internal auditory meatus.

- ⁷ Nowé V, Van de Heyning P, Parizel PM. *MRI in patients with otovestibular complaints of unknown origin*. B-ENT 2007;3:27-35.
- ⁸ Lempert T. *Recurrent spontaneous attacks of dizziness*. Continuum (Minneapolis Minn). 2012;18(5 Neuro-otology):1086-101.
- ⁹ Hüfner K, Barresi D, Glaser M, et al. *Vestibular paroxysmia: diagnostic features and medical treatment*. Neurology 2008;71:1006-14.
- ¹⁰ Ryu H, Yamamoto S, Sugiyama K, et al. *Neurovascular compression syndrome of the eighth cranial nerve. Can the site of compression explain the symptoms?* Acta Neurochir (Wien) 1999;141:495-501.
- ¹¹ Sirikci A, Bayazit Y, Ozer E, et al. *Magnetic resonance imaging based classification of anatomic relationship between the cochleovestibular nerve and anterior inferior cerebellar artery in patients with non-specific neuro-otologic symptoms*. Surg Radiol Anat 2005;27:531-5.
- ¹² Møller MB. *Vascular compression of the eighth cranial nerve as a cause of vertigo*. Keio J Med 1991;40:146-50.
- ¹³ Applebaum EL, Valvasori GE. *Auditory and vestibular system findings in patients with vascular loops in the internal auditory canal*. Ann Otol Rhinol Laryngol Suppl 1984;112:63-70.
- ¹⁴ Applebaum EL, Valvasori G. *Internal auditory canal vascular loops: audiometric and vestibular system findings*. Am J Otol 1985:110-3.
- ¹⁵ van der Steenstraten F, de Ru JA, Witkamp TD. *Is microvascular compression of the vestibulocochlear nerve a cause of unilateral hearing loss?* Ann Otol Rhinol Laryngol 2007;116:248-52.
- ¹⁶ Kim H-A, Lee H. *Recent advances in central acute vestibular syndrome of a vascular cause*. J Neurol Sci 2012;321:17-22.
- ¹⁷ Arbusow V, Strupp M, Wasicky R et al. *Detection of herpes simplex virus type 1 in human vestibular nuclei*. Neurology 2000;55:880-2.
- ¹⁸ Huppert D, Strupp M, Theil Det al. *Low recurrence rate of vestibular neuritis: a long-term follow-up*. Neurology 2006;67:1870-1.
- ¹⁹ van Leeuwen RB, Brintjes TD. *Recurrent vestibulopathy: natural course and prognostic factors*. J Laryngol Otol 2010;124:19-22.
- ²⁰ Silvoniemi P. *Vestibular neuronitis. An otoneurological evaluation*. Acta Otolaryngol Suppl 1988;453:1-72.

Received: July 7, 2015 - Accepted: May 21, 2016

Address for correspondence: Benjamin Loader, Department of Otorhinolaryngology Rudolfstiftung Tertiary Teaching Hospital, Juchgasse 25, A-1030 Vienna, Austria. Tel. +431 71165 4907. E-mail:benjamin.loader@wienkav.at

CASE SERIES AND REPORTS

Cochlear implantation in delayed sudden hearing loss after conservative vestibular schwannoma surgery

Impianto cocleare in ipoacusia improvvisa ritardata dopo chirurgia conservativa per neurinoma dell'acustico

F. DAGNA¹, A. MURRI², R. ALBERA¹, D. CUDA²

¹ Department of Surgical Sciences, University of Torino, Italy; ² Department of Otorhinolaryngology "Guglielmo da Saliceto" Hospital, Piacenza, Italy

SUMMARY

This is a case of successful cochlear implantation in a 50-year-old man who experienced sudden hearing loss and developed ipsilateral severe tinnitus at three years following conservative stage 1 vestibular schwannoma retrosigmoid surgery. After cochlear implantation, tinnitus improved from THI grade 4 to 2. Localisation skills improved. Hearing in noise (S/N + 7 dB) with target signal from the operated side improved from 38 to 100% of correct answers. A significant improvement of spatial and speech items of the "speech, spatial and qualities of sounds" questionnaire was also measured. In conclusion, cochlear implantation is a feasible and effective solution after conservative vestibular schwannoma surgery should delayed hearing loss occur.

KEY WORDS: Cochlear implant • Vestibular schwannoma • Single-sided deafness

RIASSUNTO

Presentiamo un caso di posizionamento di impianto cocleare in un uomo di 50 anni che, dopo aver subito tre anni prima un intervento per via retrosigmoidea per un neurinoma dell'acustico in stadio 1, è stato colpito da ipoacusia improvvisa ipsilaterale sviluppando un intenso acufene. Dopo l'attivazione dell'impianto l'acufene è sceso da un grado 4 ad un grado 2 secondo il THI. Sono migliorate le capacità di localizzazione. L'ascolto nel rumore (S/R + 7 dB) con il segnale proveniente dal lato operato è migliorato da 38 a 100%. Abbiamo inoltre verificato un significativo incremento dei punteggi relativi a spazialità e linguaggio del questionario "Speech, spatial and qualities of sounds". In conclusione l'impianto cocleare è una soluzione praticabile ed efficace in caso di insorgenza di ipoacusia ritardata dopo chirurgia conservativa del neurinoma dell'acustico.

PAROLE CHIAVE: *Impianto cocleare • Neurinoma dell'acustico • Ipoacusia monolaterale*

Acta Otorhinolaryngol Ital 2016;36:428-430

Introduction

Hearing preservation after surgical removal of vestibular schwannoma (VS) has become one of the greatest concerns in this field with many reports advocating very high rates of useful postoperative hearing with both middle cranial fossa (MCF) and retrosigmoid approaches. Recent reviews report that MCF is the best option for hearing conservation with tumours less than 1.5 cm in diameter, while the retrosigmoid corridor would be the best choice for larger tumours¹. The chance of hearing preservation decreases as tumour size increases and this is one of the reasons for offering early surgery according to several groups. Despite all efforts, hearing deterioration after VS surgery still remains an unsolved issue, which can lead to unserviceable hearing²⁻⁴. Even if hearing is well preserved it is not clear if it can deteriorate more quickly in the years

following surgery. From this point of view, there is a lack of studies investigating what happens to postoperative residual hearing and what solutions can be effectively used in case of delayed deterioration.

Case report

We present a 50-year-old male who had undergone surgery for right VS three years before, coming for consultation for sudden sensorineural hearing loss at the same side of the operation. VS removal was carried out by a retrosigmoid approach without any particular complication as stated in the operative report. The VS was intracanalicular (stage I according to Koos' classification) and 9 × 6 × 4 mm in size. There were no facial or cochlear nerve damage as shown by postoperative audiogram (Table I).

Table I. Hearing threshold after vestibular schwannoma (VS) excision and at first consultation.

	Side	125 Hz	250 Hz	0.5 kHz	1 kHz	2 kHz	4 kHz	8 kHz
After VS surgery	L	10	10	10	15	25	75	65
	R	20	20	20	25	35	70	90
At consultation	L	10	10	10	15	25	75	65
	R	/	95	100	105	95	105	/

Table II. Speech perception in noise.

Noise (63 dB)	S/N	Rate pre-op	Rate post-op CI on
Right	+7 dB	38%	100%
Left	+7 dB	74%	80%

After three years of good hearing, he experienced sudden hearing loss, which we ascertained through pure tone audiometry (Table II).

We immediately started intravenous therapy with steroids at a conventional suggested dose and hyperbaric oxygen therapy, without any hearing threshold improvement. The patient also developed severe tinnitus (THI: grade 4).

After thorough evaluation including HRCT scan and MRI showing the presence of the cochlear nerve on that side, without any recurrence of VS and a patent cochlea, we decided to offer cochlear implantation as a solution for his hearing loss and tinnitus.

A Cochlear Nucleus Freedom Contour Advance (Cochlear, Australia) was implanted and activated after 1 month. The cochlear implant restored normal hearing threshold in the deaf ear. The patient improved his localisation skills as reported in Figure 1, which shows azimuth error in degrees in an identification task of the source of target signals randomly delivered through one out of 15 speakers panned from -60° to +60°. His hearing in noise, tested with disyllabic words at 70 dB with S/N + 7 dB, also improved from 38 to 100% of correct answers, when target signals were presented to the implanted ear, and from 74 to 80% when target signals were presented to the contralateral side.

The speech, spatial and qualities of hearing scale also confirmed this data with improvement of spatial and speech items (Fig. 2).

Also his tinnitus dropped from THI grade 4 to 2 with CI on. Tinnitus evolution over time is plotted in Figure 3.

Conclusions

This case shows several interesting aspects dealing with hotly debated topics: hearing preservation and restoration after VS surgery. This case is of particular interest because there are no reports in the literature about hearing restoration with cochlear implant in delayed sudden hearing loss after prior conservative VS surgery.

Hearing preservation in VS surgery is one of the key

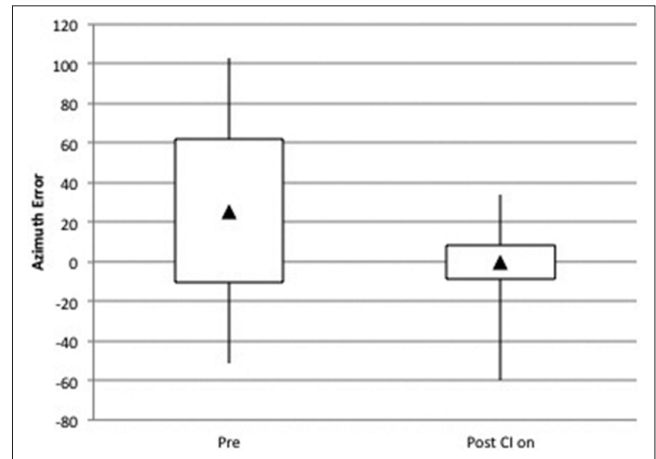


Fig. 1. Azimuth error (°) in localisation test before and after cochlear implantation. Positive values refer to sounds coming from the right and vice-versa. Triangles are median values.

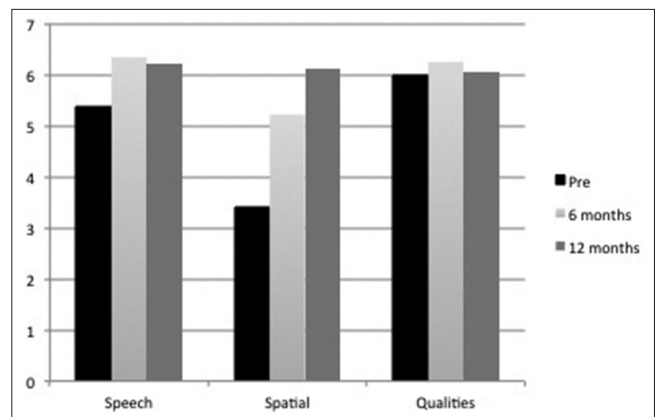


Fig. 2. Results of the “Speech, Spatial and Qualities of hearing” questionnaire over time.

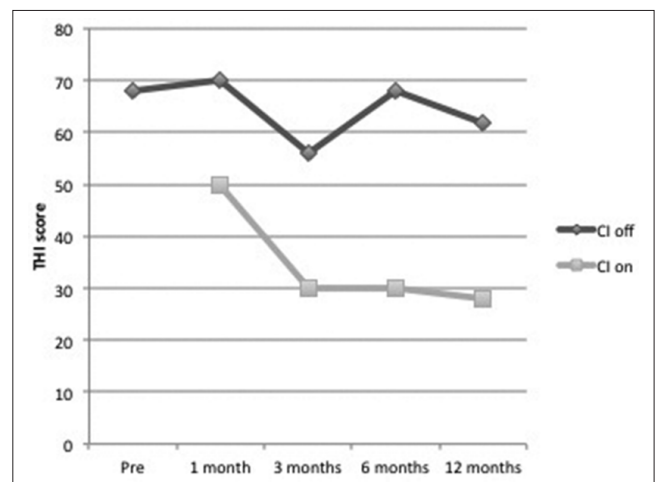


Fig. 3. Tinnitus handicap inventory (THI) score over time.

elements for subsequent hearing restoration². In fact, a cochlear implant can be a valid therapeutic option only if cochlear nerve function is preserved in the first place. There are several reports, which show how cochlear implantation can be an effective solution for hearing restoration in patients with VS either as hearing loss treatment without removing the tumour³ or after VS resection, although they deal with severe bilateral hearing loss patients affected by neurofibromatosis 2 or by sporadic VS in the only hearing ear^{4,5}. The presented case was treated as a single-sided deafness in order to relieve the patient's severe tinnitus and to restore bin-aural hearing. VS surgery does not seem to affect the results of cochlear implantation, which are comparable to "normal" single-sided deafness implanted patients⁶⁻⁸. We cannot understand the aetiology of the subsequent hearing loss, which might be a delayed consequence of the VS surgery itself or not. Whatever the aetiology, it did not affect the retrocochlear auditory pathway. In conclusion, this case shows that in case of conservative VS removal, should a delayed hearing loss occur, it can be managed with cochlear implantation with good, stable and satisfactory results.

References

- ¹ Ansari SF, Terry C, Cohen-Gadol AA. *Surgery for vestibular schwannomas: a systematic review of complications by approach*. Neurosurg Focus 2012;33:E14.
- ² Pai I, Dhar V, Kelleher C, Net al. *Cochlear implantation in patients with vestibular schwannoma: a single United Kingdom center experience*. Laryngoscope 2013;123:2019-23.
- ³ Mukherjee P1, Ramsden JD, Donnelly N, et al. *Cochlear implants to treat deafness caused by vestibular schwannomas*. Otol Neurotol 2013;34:1291-8.
- ⁴ Amodi HA, Makki FM, Cavanagh J, et al. *Cochlear implant rehabilitation for patients with vestibular schwannoma: report of two cases*. Cochlear Implants Int 2012;13:124-7.
- ⁵ Ahsan S, Telischi F, Hodges A, et al. *Cochlear implantation concurrent with translabyrinthine acoustic neuroma resection*. Laryngoscope 2003;113:472-4.
- ⁶ Baguley DM, Atlas MD. *Cochlear implants and tinnitus*. Prog Brain Res 2007;166:347-55.
- ⁷ Baguley. DM. *Cochlear implants in single-sided deafness and tinnitus*. Seminars in Hearing 2010;31:410-3.
- ⁸ Punte AK, Vermeire K, Hofkens A, et al. *Cochlear implantation as a durable tinnitus treatment in single-sided deafness*. Cochlear Implants Int 2011;12(Suppl 1):26-9.

Received: January 2, 2015 - Accepted: March 8, 2015

CASE SERIES AND REPORTS

Anterior laryngofissure approach in type III laryngotracheal cleft: a case report

Laringofissura anteriore nel cleft laringotracheale di tipo III: caso clinico

A.E. ARSLANKOYLU¹, M. UNAL², N. KUYUCU³, O. ISMI⁴

¹ Department of Pediatric Intensive Care, Faculty of Medicine, University of Mersin, Turkey; ² Department of Otorhinolaryngology, Faculty of Medicine, University of Mersin, Turkey; ³ Department of Pediatric Infectious diseases, Faculty of Medicine, University of Mersin, Turkey; ⁴ Department of Otorhinolaryngology, Faculty of Medicine, University of Mersin, Turkey

SUMMARY

Laryngeal and laryngotracheal clefts are rare congenital malformations of the laryngobronchial tree. Their symptoms vary from mild cough to life threatening pulmonary aspiration and cyanosis. Type I and II clefts can be observed without surgical intervention, whereas type III and IV clefts usually require an anterior or lateral cervical approach. We present a case of type III laryngotracheal cleft seen in a 3-month-old male infant who died during revision surgery after an anterior laryngofissure approach. We discuss the difficulties in diagnosis, management and importance of anaesthesia for these rare anomalies in light of the current literature.

KEY WORDS: Larynx • Laryngeal cleft • Laryngotracheal cleft • Laryngofissure • Mortality

RIASSUNTO

I cleft laringei e laringotracheali sono rare malformazioni congenite dell'albero laringo-tracheo-bronchiale. La sintomatologia associata va dalla blanda tosse all'aspirazione e alla cianosi. I cleft di tipo I e II possono essere tenuti sotto osservazione senza intervenire chirurgicamente, mentre i tipi III e IV richiedono un approccio chirurgico anteriore o laterocervicale. Presentiamo il caso di un neonato di 3 mesi affetto da cleft laringotracheale di tipo III, deceduto in corso di revisione chirurgica dopo un approccio in laringofissura anteriore. Nel presente lavoro discutiamo, alla luce della letteratura, le difficoltà diagnostiche, le modalità di trattamento e le tecniche anestesiolgiche relative a questa rara patologia.

PAROLE CHIAVE: Laringe • Cleft laringeo • Cleft laringotracheale • Laringofissura • Mortalità

Acta Otorhinolaryngol Ital 2016;36:431-434

Introduction

Congenital laryngeal anomalies are seen less than 0.5% of the population, and among these laryngeal clefts (LCs) account for 0.3-0.5%. These rare malformations are due to an embryological fusion defect of tracheo-oesophageal septum (TES). Early insult before 25 to 28 days of intrauterine life, which is the critical period for formation of TES, can cause incomplete formation of the septum. Defect in the fusion causes on-going relationship between the gastrointestinal and respiratory systems, which is the main cause of chronic cough or cyanosis during feeding and swallowing ¹.

Since signs, symptoms and treatment options differ according to the severity of LCs, multiple classifications regarding the severity of disease have been proposed; that of Benjamin and Inglis is the simplest and most clinically applicable, which is used by most authors ². Type I is the interarytenoid cleft of soft tissue without involvement of

cricoid cartilage. A type II cleft involves cricoid cartilage without involvement of the inferior lamina. Type III LC involves the entire posterior cricoid lamina with or without involvement of cervical trachea. Type IV is the total TES clefts with involvement of thoracic trachea. Type I is seen most often, while type IV was found in only 3% of cases in the series by Evans et al. ³. The mortality rate is higher than 90% for type IV clefts ¹.

A 3-month-old male infant who died after revision anterior laryngofissure surgery for a type III LC due to anaesthesia complications is presented.

Case

A 3-month-old male infant was hospitalised in Mersin University paediatric intensive care unit due to frequent pulmonary infections after birth and cyanosis attacks after feeding. He was intubated for 7 days when consulted to our otorhinolaryngology department with the complaint

of a decrease in oxygen saturation after feeding with a nasogastric tube. Bedside examination was performed with a laryngeal blade. A posteriorly placed intubation tube was seen near the nasogastric tube. He had no additional illnesses or concomitant congenital malformations. Direct laryngoscopic examination in the operating theatre revealed a type III LC with involvement of the cricoid cartilage and first tracheal ring. A tracheotomy at the third tracheal cartilage was performed for protection and clearance of lower airways. After preparation of general anaesthesia and improvement of general health status and lung parenchyma, the infant underwent intervention for LC repair at the fourth month of life. An anterior laryngofissure approach was planned (Fig. 1). The LC was repaired with sternocleidomastoid muscle flap and three layers of closure (Fig. 2). In the postoperative period, proton pump inhibitor and antibiotic treatment including sulbactam-ampicillin was administered. He was discharged from hospital after recovery on fifth month of life with tracheostomy and nasogastric tube. Three months later, he was re-admitted with complaints of pulmonary infection. On direct laryngoscopic examination there was a cleft at interarytenoid area through the beginning of the cricoid cartilage. After preparation for general anaesthesia following treatment of pulmonary infection, he underwent revision surgery. The anterior laryngofissure approach revealed an approximately 1.5 cm defect at the previous suture line (Fig. 3). A sternocleidomastoid muscle flap and three layers of closure were used to repair the defect. During extubation, a sudden decrease in oxygen saturation to 60% was seen. Aspiration from tracheotomy was performed, and re-intubation and mechanical ventilation were administered by the anaesthesiologist. During aspiration, gastric fluid with saliva was seen although there was nasogastric tube during the surgical procedure. After deterioration of pulse oximetry levels, cardiopulmonary arrest developed. Although resuscitation was administered for one hour by the anaesthesiologist, spontaneous ventilation and cardiac beat could not be achieved and he was regarded dead.

Discussion

Laryngeal clefts are rare malformations and their incidence is challenging to accurately estimate since type I clefts can be asymptomatic or misdiagnosed for years; secondly, submucosal cleft, which is the absence of interarytenoid musculature with presence of the mucosa, can hide physical findings⁴. There is no known prenatal diagnostic tools, and only polyhydramnios can be a non-specific finding that makes diagnosis more difficult¹. Signs and symptoms of LCs differ according to the severity of disease; most are respiratory in nature including chronic cough, aspiration, cyanosis and recurrent pulmonary infection associated with feeding. More serious symptoms such as severe respiratory infection and distress, stridor

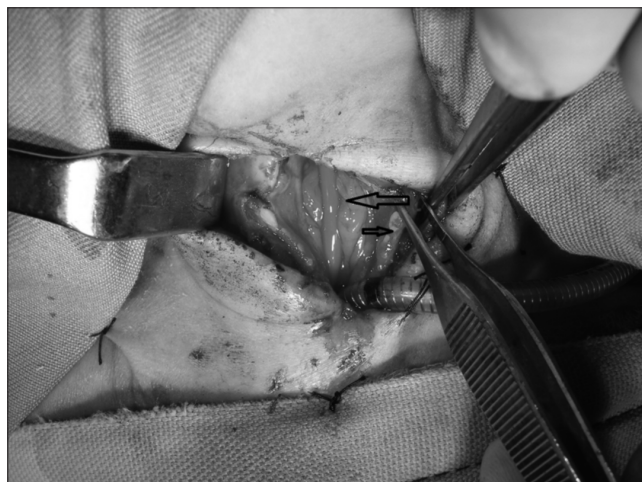

Fig. 1. Perioperative appearance of the patient during laryngofissure approach. The long arrow shows the cleft area with a nasogastric tube behind it. The short arrow shows dissected thyroid cartilage.

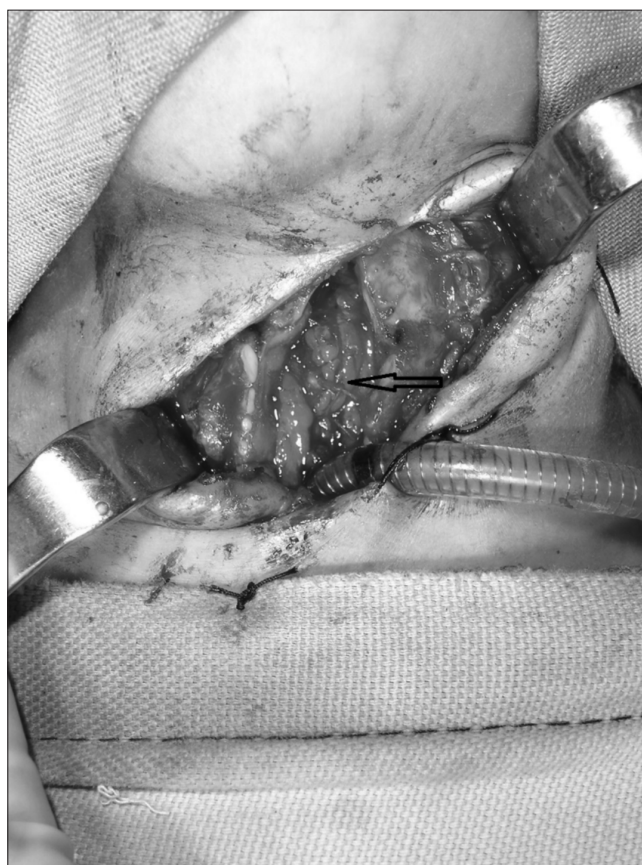

Fig. 2. Postoperative appearance of the patient. The arrow shows the three layer closed cleft area, while the nasogastric tube is behind the surgical wound.

needing hospitalisation and even entubation as in our case are usually seen in type III and IV LCs¹⁴. Rarely, type III LCs can be misdiagnosed as asthmatic attack and treated accordingly with delayed diagnosis⁵. Posterior place-

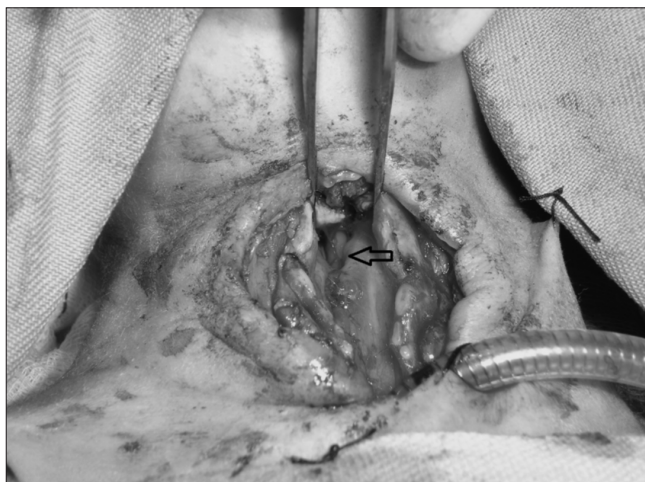


Fig. 3. Re-opened cleft area during revision with a laryngofissure approach. The arrow shows the cleft area with the nasogastric tube behind it.

ment of an endotracheal intubation tube and multiple unsuccessful oesophageal intubations can be seen as in our case ¹.

Although LCs can be seen alone, concomitant multiple congenital malformations may also exist. Opits-Frias syndrome (oculo-genital-laryngeal or G syndrome) with airway cleft, cleft lip, cleft palate, swallowing dysfunction, imperforate anus and hypospadias can be seen in patients with LC. Pallister-Hall syndrome is another syndrome consisting of airway cleft, congenital hypothalamic hamartoblastoma, hypopituitarism, imperforate anus, and postaxial polydactyly that may be present with LC. VATER association (vertebral defects, anal atresia, tracheo-oesophageal fistula, oesophageal atresia, renal dysplasia) also commonly includes LC ⁶. Overall, the most commonly accompanying anomalies are gastrointestinal; oesophageal atresia and tracheo-oesophageal fistula is the most common seen in 20-27% of cases, followed by genitourinary anomalies ¹. In our case there was no accompanying congenital malformation.

Microscopic examination of the larynx under general anaesthesia and palpation of interarytenoid area is the gold standard diagnostic tool for LCs. Barium swallow study and video fluoroscopy may miss aspiration of contrast agent for intermittent aspirating cases ⁶. Functional endoscopic evaluation of swallowing is helpful in diagnosis as it provides the chance of evaluation of anatomic structure during swallowing including vocal cord motion and location of aspiration ⁴. Pneumonia or peribronchial cuffing can be seen as a result of persistent chronic aspiration in chest X-ray ⁴.

Just as symptoms of LCs vary between cases, treatment options also differ according to severity of disease. Observation without surgical treatment can be a suitable

option for type I and II cases with mild symptoms. For medical management, feeding therapy involving thickening of liquids and food consistency can be used. Gastro-oesophageal reflux can be seen with LCs and can cause oedema of mucosa postoperatively. Proton pump inhibitor for prevention is mandatory and endoscopic Nissen fundoplication can be an additional procedure for control of reflux ^{4,7}. In our case, high dose proton pump inhibitor was administered in the perioperative period. For symptomatic cases of type I and II clefts, or unresponsive to medical treatment endoscopic repair, can be considered. Flapping and suturing techniques of interarytenoid area are widely used ⁶. More recently, injection laryngoplasty to the interarytenoid region can be an alternative technique for type I cases ⁸. For type III and IV LCs, open cervical approaches are preferred. A posterior approach is used with a vertical incision along the anterior border of sternocleidomastoid muscle for achieving lateral pharyngotomy after retraction of major vessels. It does not provide visual access as good as that is provided by an anterior approach, and recurrent and superior laryngeal nerves are at great risk for damage. The anterior approach is the most commonly used and safe procedure done via a horizontal incision above the tracheostomy line if present. After retraction of strap muscles, a laryngofissure incision through thyroid cartilage is made. The cleft area can be repaired with interposing grafts such as sternocleidomastoid muscle flaps, pleura, pericardium, strap muscle, periosteum with two or three layers of closing the wound ^{4,6}. We also preferred an anterior cervical approach with laryngofissure incision and sternocleidomastoid muscle flap used as an interposing graft. Tracheotomy is widely used for type III and IV clefts for prevention of lung against aspiration after enteral feeding. Gastrostomy may also be performed for enteral feeding ⁴. We also performed a tracheotomy before an open anterior cervical approach.

Anaesthesia is very critical during surgery for management of LCs. For endoscopic procedures, an endotracheal intubation tube can hinder the surgeon from studying at a well visualised area. Usage of tubeless anaesthesia and insufflation with spontaneous breathing and jet ventilation can be used ⁶. After induction with inhalational agent, maintaining the general anaesthesia with propofol or remifentanyl, without using jet ventilation is also a possible option. In this situation, a modified cut-off endotracheal tube can be used near the laryngoscope blade to support ventilation ⁴. Ferrari et al. recommends tubeless total intravenous anaesthesia (TIVA) with spontaneous ventilation during endolaryngeal management of LCs ⁹. For open procedures, anaesthesia risks are more complicated. LC cases are in children whose lung functions are affected due to chronic aspiration. During reverse anaesthesia, children are prone to aspiration of gastric contents and thick salivary secretions to preoperatively affected pulmonary parenchyma ¹⁰. In the series by Kluger et al.

with 133 cases, five children died postoperatively due to aspiration¹¹. In data in 2011 from United Kingdom, pulmonary aspiration was the most common cause of anaesthesia-related death accounting for 50% of mortality¹². In our case, bronchospasm and sudden deterioration of pulse oximetry was observed during reverse anaesthesia and extubation from tracheotomy. Although a post-mortem study could not be performed, we believe that gastric content and salivary aspiration to previously affected lung parenchyma was the cause.

In conclusion, LCs are rare malformations of the laryngobronchial tree. Some LCs can be life-threatening and early diagnosis is important to protect lung parenchyma from chronic aspiration. Type III and IV cases are prone to open surgical procedures. In the reverse anaesthesia and extubation period, these patients can aspirate secretions to previously diseased pulmonary parenchyma. Frequent aspiration of tracheotomy is important for releasing secretions. Extubation after ensuring that spontaneous ventilation and aspiration reflexes are achieved is critical for prevention of life threatening complications.

References

- ¹ Chitkara AE, Tadros M, Kim J, et al. *Complete laryngotracheoesophageal cleft: complicated management issues*. *Laryngoscope* 2003;113:1314-20.
- ² Benjamin B, Inglis A. *Minor congenital laryngeal clefts: diagnosis and classification*. *Ann Otol Rhinol Laryngol* 1989;98:417-20.
- ³ Evans KL, Courtney-Harris R, Bailey M, et al. *Management of posterior laryngeal and tracheoesophageal clefts*. *Arch Otolaryngol Head Neck Surg* 1995;121:1380-5.
- ⁴ Johnston DR, Watters K, Ferrari LR, et al. *Laryngeal cleft: evaluation and management*. *Int J Pediatr Otorhinolaryngol* 2014;78:905-11.
- ⁵ Parsons DS, Herr T. *Delayed diagnosis of a laryngotracheoesophageal cleft*. *Int J Pediatr Otorhinolaryngol* 1997;39:169-73.
- ⁶ Clark K. *Anterior repair of posterior laryngeal and laryngotracheal clefts*. *Operat Tech Otolaryngol Head Neck Surg* 1999;10:42-52.
- ⁷ Kamata S, Ihara Y, Usui N, et al. *Surgical management for posterior laryngeal cleft developing subglottic airway stenosis*. *J Ped Surg* 2005;40:15-6.
- ⁸ Cohen MS, Zhuang L, Simons JP, et al. *Injection laryngoplasty for type I laryngeal cleft in children*. *Otolaryngol Head Neck Surg* 2011;144:789-93.
- ⁹ Ferrari LR, Zurakowski D, Solari J, et al. *Laryngeal cleft repair: the anesthetic perspective*. *Paediatr Anaesth* 2013;23:334-41.
- ¹⁰ Kelly CJ, Walker RWM. *Perioperative pulmonary aspiration is infrequent and low risk in pediatric anesthetic practice*. *Paediatr Anaesth* 2015;25:36-43.
- ¹¹ Kluger MT, Short TG. *Aspiration during anaesthesia: a review of 133 cases from the Australian anaesthetic incident monitoring study (AIMS)*. *Anaesthesia* 1999;54:19-26.
- ¹² Cook TM, Woodall N, Frerk C: *Fourth National Audit Project. Major complications of airway management in the UK: Results of the fourth national audit project of the Royal college of anaesthetists and the difficult airway society. Part 1: anaesthesia*. *Br J Anaesth* 2011;106:617-31.

Received: March 7, 2015 - Accepted: July 24, 2015

Address for correspondence: Onur Ismi, Mersin University-Otorhinolaryngology department, Mersin Üniversitesi Tıp Fakültesi Hastanesi, Kulak Burun Boğaz A.D Çiftlikköy Kampüsü, Çiftlikköy/Yenişehir, Mersin, Turkey. E-mail: dronurismi@gmail.com, dronurismi@outlook.com

Calendar of events – Italian and International Meetings and Courses

Acta Otorhinolaryngol Ital 2016;36:435-437

Information, following the style of the present list, should be submitted to the Editorial Secretariat of Acta Otorhinolaryngologica Italica (actaitalicaorl@rm.unicatt.it).

In accordance with the Regulations of S.I.O. and Ch.C.-F. (Art. 8) Members of the Society organising Courses, Congresses or other scientific events should inform the Secretary of the Association (A.U.O.R.L., A.O.O.I.) within the deadlines set down in the respective Statutes and Regulations.

OCTOBER-DECEMBER 2016

CORSO PRATICO DI ANATOMIA CHIRURGICA E DISSEZIONE SPERIMENTALE OTOLOGICA 2° LIVELLO - XX EDIZIONE • October 3-7, 2016 • Sanremo (IM) – Italy

President: S. Nosengo – E-mail: franco.cocchini@studiumorl.com – A cura di: A. Tombolini, F. Baricalla – Coordinato da: A. Tombolini – Website: www.studiumorl.com

IFHNOS 2016 • October 5-7, 2016 • Praha – Czech Republic

E-mail: ifhnos2016@guarant.cz – Website: www.ifhnosprague2016.org/

RHINOLOGY & RHYNOALLERGOLOGY INTERNATIONAL CONFERENCE 5th BULGARIAN ITALIAN RHINOLOGY MEETING • October 13-15, 2016 • Senigallia – Italy

Directors: Dilyana Vitcheva, Alessandro Varini, Giuseppe Frau, Alessandro Bucci. Scientific Secretariat: A. Bucci, Finis Africae Country House S.P. Sant' Angelo 155 Senigallia (AN), Italy – Website: www.rhinology.eu. Organizing Secretariat: Events Congress & Communication – Website: www.rhinology.eu

SWISS ENDOSCOPIC EAR SURGERY COURSE (SEES) • October 14-15, 2016 • Bern – Switzerland

E-mail: anschuetz.lukas@gmail.com – Website: http://sees.swiss-meeting.org

6th INTERNATIONAL COURSE ON FUNCTIONAL AND AESTHETIC SURGERY OF THE NOSE – LIVE SURGERY • October 16-19, 2016 • Imola (BO) – Italy

Course Director: Ignazio Tasca – Scientific Secretariat, E.N.T. Department, Imola Hospital, Italy – Tel. +39 0542 662101/293 – Fax +39 0542 662284 – E-mail: i.tasca@ausl.imola.bo.it – Executive Secretariat: A & R Eventi sas di Verlicchi Clara e C., via R. Benassi 28, 40068 San Lazzaro di Savena (BO), Italy – Tel. +39 051 474238 – Fax +39 051 4839525 – E-mail: clara@areventi.it – Website: www.imolarhinoplasty2016.com

4° MASTER DI LARINGOLOGIA ONCOLOGICA • October 17-20, 2016 • Vittorio Veneto – Italy

Scientific Secretariat: A. Bertolin, Ospedale Civile di Vittorio Veneto, Vittorio Veneto, Italy. Organizing Secretariat: Nord Est Congressi – E-mail: mail@nordestcongressi.it – Website: www.nordestcongressi.it

ANZHNCs ANNUAL SCIENTIFIC MEETING AND THE IFHNOS 2016 WORLD TOUR October 25-27, 2016 • The Langham Auckland – New Zealand

E-mail: anzhncs.asm@surgeons.org – Website: www.ifhnosauckland2016.org

15th INTERNATIONAL CONGRESS OF IRANIAN SOCIETY OF OTOLARYNGOLOGY, HEAD AND NECK SURGERY • November 8-11, 2016 • Tehran – Iran

E-mail: mahtab_rabbani@yahoo.com – Website: www.iranent.org/congress/

APPROCCIO PRATICO ALLA VPPB LEZIONI TEORICHE E PRATICHE November 10-12, 2016 • Matera – Italy

Scientific Secretariat: G.A. Liberati, Hotel Del Campo, Matera, Italy. Organizing Secretariat: Prisco Provider Srl – E-mail: info@priscoprovider.it – Website: www.priscoprovider.it

4° CONGRESSO AGGIORNAMENTI IN ORL “ENDORL” • November 12, 2016 • Montegrano (Fermo) – Italy

President: Luigi Fasanella – Scientific Secretariat: Cesare Carlucci – Tel. +39 0733 823030 – E-mail: carlucci7@tin.it

HANDS-ON COURSE ON NEW ENDOSCOPIC APPROACHES TO LATERAL SKUL BASE, INNER EAR AND CEREBELLO-PONTINE ANGLE**November 12-13, 2016 • Verona – Italy and November 14, 2016 • Modena – Italy**

Scientific Secretariat: L. Presutti, D. Marchionni, AOU di Modena Policlinico. Organizing Secretariat: ICLO Srl – E-mail: info@iclo.eu – Website: www.iclo.eu

CORSO DI ANATOMIA CHIRURGICA ENDOSCOPICA DEI SENI PARANASALI E DELLA BASE CRANICA
November 13-15, 2016 • Verona – Italy

Scientific Secretariat: F. Pagella, E. Emanuelli, ICLO San Francesco di Sales Teaching and Research Center di Arezzo (Via A. Einstein, 12). Organizing Secretariat: ICLO Srl – E-mail: info@iclo.eu – Website: www.iclo.eu

MASTER DI DISSEZIONE E CHIRURGIA ENDOSCOPICA DEI SENI PARANASALI E DEL BASICRANIO
November 14-18, 2016 • Milan – Italy

Director: Alberto Dragonetti – E-mail: a.dragonetti@fastwebnet.it

9th INTERNATIONAL SYMPOSIUM ON RECENT ADVANCES IN RHINOSINUSITIS AND NASAL POLYPOSIS (ISRNP 2016) • November 21-23, 2016 • Kuala Lumpur – Malaysia

E-mail: sympo@isrnp2016.net – Website: http://www.isrnp2016.net/

CORSO MICROSCOPICO E VIDEOENDOSCOPICO DI DISSEZIONE SU CADAVERE PROPEDEUTICO ALLA CHIRURGIA OTOLOGICA • November 24-25, 2016 • Milan – Italy

Presidents: Raffaele Pugliese, Alberto Dragonetti – E-mail: corsieconvegni@eurocompany.mi.it

RHINOFORUM 2016 • December 1-3, 2016 • Warsaw – Poland

E-mail: info@forumrynologiczne.pl – Website: http://rhinoforum.pl/en

JANUARY-DECEMBER 2017**CORSO DI DISSEZIONE OTOLOGICA, OTONEUROLOGICA E IMPLANTOLOGIA Uditiva, DISSEZIONE ENDOSCOPICA DELL'ORECCHIO MEDIO E INTERNO • January 10-12, 2017 • Paris – France**

Directors: Olivier Sterkers and Daniele Bernardeschi

12th SURGICAL ANATOMY IN HEAD&NECK CANCERS PROCEDURES • March 1-3, 2017 • Arezzo – Italy

Scientific Secretariat: M. Benazzo, F.G. Chiesa, ICLO San Francesco di Sales Teaching and Research Center di Arezzo (Via A. Einstein, 12). Organizing Secretariat: ICLO Srl – E-mail: info@iclo.eu – Website: www.iclo.eu

9th MILANO MASTERCLASS • March 24-28, 2017 • Milan – Italy

Charimen: Paolo Castelnuovo and Pietro Palma – Website: www.milanomasterclass.it

2nd WORLD CONGRESS ON ENDOSCOPIC EAR SURGERY • April 27-29, 2017 • Bologna – Italy

Chairmen: Livio Presutti, Muaaz Tarabichi, Daniele Marchioni

104° CONGRESSO NAZIONALE SIO – SOCIETA ITALIANA DI OTORINOLARINGOLOGIA E CHIRURGIA CERVICO-FACCIALE • May 24-27, 2017 • Sorrento – Italy

President: Carlo Antonio Leone – Website: www.sioechcf.it

9th INTERNATIONAL BIENNALE MILANO MASTERCLASS – THE NOSE INSIDE OUT
March 24-28, 2017 • Milan – Italy

Scientific Secretariat: P. Castelnuovo, P. Palma – Website: www.milanomasterclass.it. Auditorium "IL SOLE 24 ORE" Via Monte Rosa, 91 - 20149 Milano. Organizing Secretariat: MZ Congressi Srl – E-mail: mima@mzcongressi.com

IFOS PARIS 2017 - ENT WORLD CONGRESS • June 24-28, 2017 • Paris – France

Tel. +33 (0)1 44 64 15 15 – E-mail: contact@ifosparis2017.org – Website: www.ifosparis2017.org

4th CONGRESS OF THE EUROPEAN ORL-HNS • October 19-22, 2017 • Antalya – Turkey

E-mail: dburkaya@topkon.com – Website: www.ceorlhns2017.com

CORSI PRATICI DI VIDEOCHIRURGIA ENDOSCOPICA NASO-SINUALE E DEL BASICRANIO**November 13-17, 2017 • Milan – Italy**

Scientific Secretariat: A. Dragonetti, ASST Grande Ospedale Metropolitano Niguarda, Milan, Italy. Organizing Secretariat: Eurocompany Srl – E-mail: corsieconvegna@eurocompany.mi.it

17th ASEAN ORL HNS CONGRESS • November 16-18, 2017 • Myanmar

E-mail: phillip.samual27@gmail.com

JANUARY-DECEMBER 2018**15th INTERNATIONAL CONFERENCE ON COCHLEAR IMPLANTS AND OTHER IMPLANTABLE AUDITORY TECHNOLOGIES • June 13-16, 2018 • Antwerp – Belgium**

Chairman: Paul Van de Heyning – E-mail: vincent.van.rompaey@uza.be – Website: www.ci2018.org

6th WORLD CONGRESS OF THE INTERNATIONAL FEDERATION OF HEAD AND NECK ONCOLOGIC SOCIETIES • September 1-5, 2018 • Buenos Aires – Argentina

Website: <http://ifhnos2018.org/>

JANUARY-DECEMBER 2019**14th ASIA-OCEANIA ORL-HNS CONGRESS 2019 • January 9-13, 2019 • Hyderabad – India**


E-mail: secretariat@14asiaoceania.com – Website: <http://14asiaoceania.com/>

2016

è online il nuovo sito!

PACINI EDITORE MEDICINA
Leader
nell'editoria
medico scientifica

www.pacinimedicina.it



Contenuti autorevoli
con egida di prestigiose
Società Scientifiche

Ampio archivio per
l'aggiornamento medico:
accesso gratuito



www.facebook.com/pacinimedicina



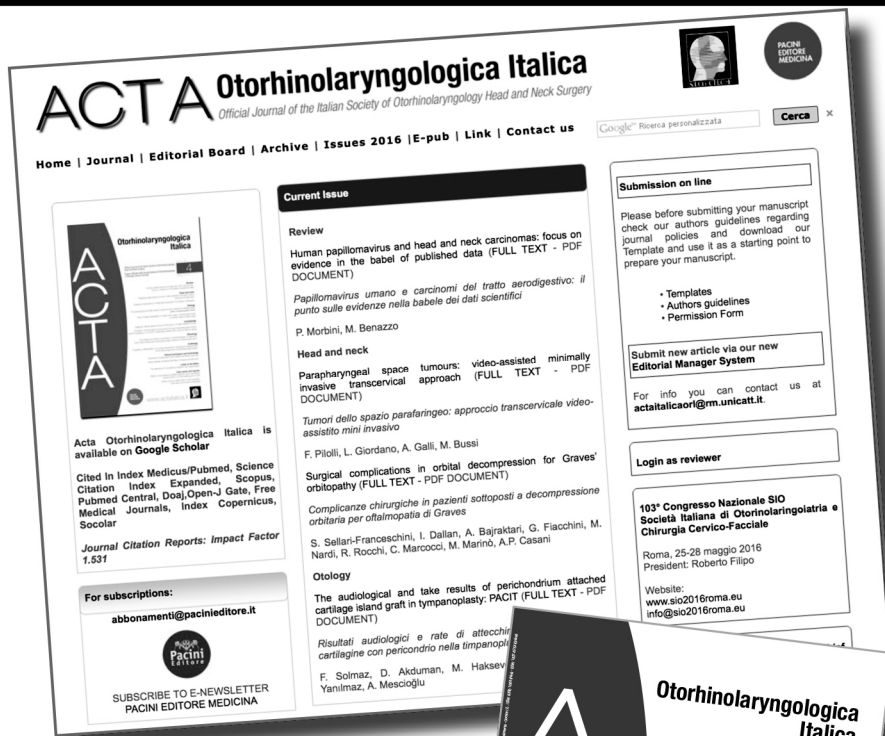**PACINI
EDITORE
MEDICINA**

ACTA Otorhinolaryngologica Italica



Official Journal
of the Italian Society of Otorhinolaryngology Head and Neck Surgery

www.actaitalica.it



Free download

Current Issue

Archive

E-pub

Submission on line

Available on Google Scholar

Cited in Index Medicus,
MEDLINE, PubMed Central,
Science Citation Index
Expanded, Scopus, DOAJ,
Open-J Gate, Free Medical
Journals, Index Copernicus,
Socolar

Journal Citation Reports:
Impact Factor 1.531

Editor-in-Chief: G. Paludetti

Access the site
on your smartphone



www.pacinimedicina.it