

CLINICAL TECHNIQUES AND TECHNOLOGY

Prevention of bisphosphonate-related mandibular fractures

Prevenzione delle fratture mandibolari conseguenti alla necrosi ossea da difosfonati

M. PEDRAZZOLI, L. AUTELITANO, F. BIGLIOLI

Department of Maxillo-facial Surgery, San Paolo Hospital, University of Milan, Italy

SUMMARY

Mandibular fracture is usually the clinical end of bisphosphonate-related osteonecrosis of the jaw. This is a painful complication and patients cannot feed as usual, with a worsening of their quality of life. The goal of treatment in bisphosphonate related osteonecrosis of jaw (BRONJ) patients is to slow progression of bone necrosis. We present a novel technique for treatment of severe mandibular BRONJ in stage 3 patients that present with a high risk to develop fracture, since they have a residual unaffected mandibular bone height less than 6 mm. We treated 10 patients in this clinical situation with an extra-oral application of a reconstructive plate superficial to the platysma, to keep the plate separated from the infected site to avoid contamination and consequent need of removal, followed by an intraoral approach for active curettage of mandibular necrosis. The preservation of blood supply to the mandible and avoidance of direct contact of the infected site with the reconstructive plate are some advantages of this technique. This plate allows enhancement of mandibular strength, allowing proper treatment of the BRONJ site on the oral side without fear of causing a mandibular fracture when the residual mandible is thin. This technical solution guarantees these patients an extended disease-free period since it is effective in preventing mandibular fractures in patients with low mandibular residual height left after the BRONJ onset.

KEY WORDS: Bisphosphonate jaw fracture • Pathologic mandibular fracture • Extra-platysma stabilization • BRONJ Treatment

RIASSUNTO

La frattura della mandibola rappresenta solitamente l'evento finale nei pazienti che presentano una progressione della necrosi ossea derivante dall'impiego dei difosfonati. Si tratta di una grave complicanza molto dolorosa che impedisce ai pazienti di alimentarsi correttamente, essendo pertanto un fattore che peggiora notevolmente la loro qualità di vita. L'obiettivo del trattamento dei pazienti che presentano la necrosi ossea legata ai difosfonati (BRONJ) dovrebbe essere rallentare la progressione della malattia. Presentiamo una soluzione tecnica per il trattamento dei pazienti che presentano necrosi mandibolare in stadio 3 ad alto rischio di sviluppare una frattura, avendo un'altezza mandibolare residua di osso sano inferiore a 6 mm. Il trattamento consiste nel posizionamento di una placca ricostruttiva mandibolare per via extra-orale in un piano superficiale al muscolo platysma per tenere i pezzi di sintesi separati dal sito infettivo e non farli contaminare con conseguente necessità di doverli rimuovere, seguito dal curettage per via endorale della necrosi mandibolare. Il rispetto della vascolarizzazione mandibolare e l'assenza di contatto diretto tra il sito di osteonecrosi e la placca ricostruttiva rappresentano alcuni dei vantaggi di questa metodica. La placca ricostruttiva rinforza la mandibola e consente di aggredire energicamente l'area di necrosi mandibolare, senza esporre il paziente a rischio di frattura iatrogena. Questo garantisce al paziente un rallentamento della progressione della malattia e impedisce la frattura patologica della mandibola, inevitabile epilogo delle necrosi ossee mandibolari.

PAROLE CHIAVE: Frattura mandibolare da difosfonati • Frattura patologica della mandibola • Stabilizzazione extra-platismatica • Trattamento delle necrosi ossee da difosfonati

Acta Otorhinolaryngol Ital 2016;36:317-320

Introduction

Mandibular fracture is usually the clinical end of bisphosphonate-related osteonecrosis of the jaw (BRONJ). This situation is associated with a sudden worsening of patients' quality of life, since they start experiencing pain and cannot eat in a normal fashion. Since at present there is no evidence of an effective medical or surgical therapy to produce complete healing of the necrotic bone, the goal of treatment in BRONJ patients is to slow the progression of bone necrosis. Worsening of the pathology includes

further fistulae formation and mandibular pathologic fracture due to osteolysis extending to the inferior border.

We decided to apply a reconstructive mandibular plate generally used to stabilise BRONJ-related mandibular fractures in patients who have not developed a mandibular fracture, but who are at a high risk of its development. Since there is no literature on this topic, we arbitrarily selected a minimal residual thickness of unaffected mandibular bone of 6 mm (Fig. 1) to apply the plate on an extra-platysmatic dissection plane¹. When the residual height of normal mandibular bone is more than 6 mm, we

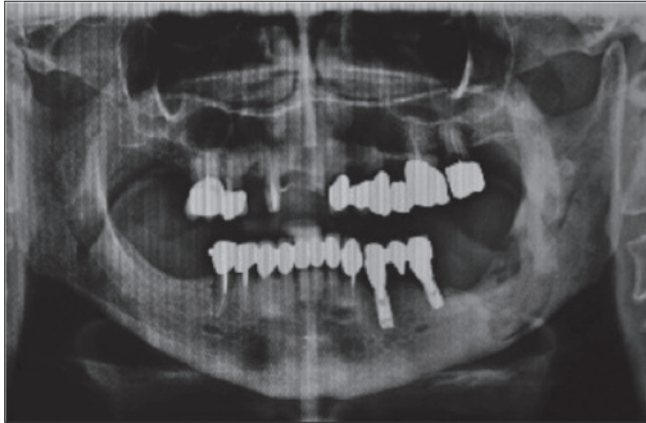


Fig. 1. Panoramic radiograph reveals wide bone destruction in the left mandibular angle, with residual height less than 6 mm.

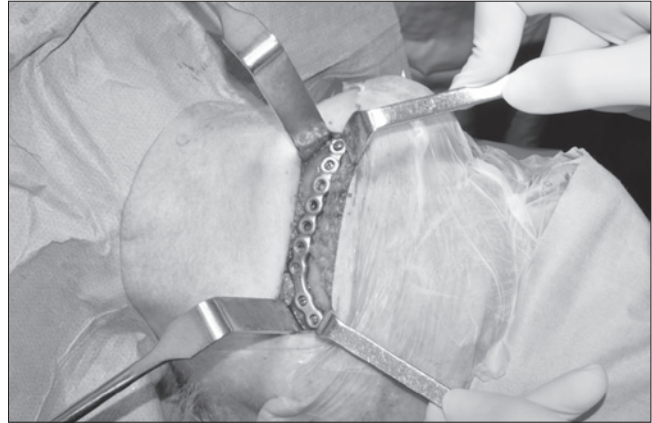


Fig. 2. Intraoperative view: the position of the 2.5 mm plate in the extra-platysmatic plane.

treat patients by simple curettage of the bone necrosis and possible removal of the sequestrum.

The proposed technique consists of the application of a reconstructive plate in a plane superficial to the platysma with an extraoral surgical access followed by an intraoral approach for active curettage of mandibular necrosis and rinsing of the surgical site. The main advantages of this technique are related to the maintenance of the blood supply to the mandible and avoidance of direct contact of the infected site with the reconstructive plate.

The position of this stable plate on a plane superficial to the platysma also allows the proper treatment of the BRONJ site on the oral side, without fear of causing a mandibular fracture due to the surgical curettage, and can allow mandibular resection when clinically needed without loss of occlusion.

Description of clinical technique

A sterile drape is placed over the mouth and face to avoid any direct contamination of the cervical field by the infected bone. After inducing vasoconstriction with 1:200,000 epinephrine into the submandibular region, a 10-cm skin incision is made ~2 cm inferior to the mandibular border, following its profile. The dissection plane is immediately over the platysma muscle, 5 cm in front of and 5 cm behind the site of BRONJ. A 2.5-mm reconstructive locking plate is modelled with the help of a template and then placed superficial to the platysma. Stabilisation is obtained through mono-cortical locking screws placed a few cm from the BRONJ site, under plentiful rinsing solution (Fig. 2). Meticulous haemostasis and the application of an aesthetic suture completes the extra-oral surgical procedure.

The cervical suture is covered by a sterile-drape dressing, and the BRONJ site is accessed through an intraoral approach with minimal to no dissection of the periosteum. Surgery is limited to curettage and rinsing of the residual

bone. Rotating burs are avoided, while piezosurgical instrumentation is preferred. Bony sequestrum is removed when present.

Between 2013 and 2015 we operated on 10 patients affected by BRONJ of the mandible who were at risk to develop a mandibular fracture. Clinical data are shown in Table I.

All patients were discharged after 2 days, with prompt relief of pain and allowance of feeding. We observed no facial nerve lesions. After a mean follow up time of 22.2 months, we saw no infection of plates and all means of fixation are stable at the time of writing. In one patient, after 12 months we observed local progression of disease that was treated by intra-oral curettage without need for plate removal.

Discussion

BRONJ is a clinical situation first reported in the modern era by Marx in 2003². Other authors have observed that a similar disease was described 100 years earlier, in 1899 by Dearden in the *British Medical Journal* in workers in the white phosphorus mines and in match factories; this was known as “Phossy Jaw”. It is possible that long-term exposure to phosphorus in these workers induced the precipitation of bisphosphonates in bone leading to a clinical condition similar to the well-known BRONJ.

The aetiopathological hypothesis of this disease is that bisphosphonates are powerful osteoclast inhibitors, and long-term use can result in suppression of bone turnover with increased trabecular bone density, inducing vascular insufficiency and causing bone necrosis. Moreover, the impaired bone turnover leads to failed removal of old osteocytes. Osteocytes are not immortal cells; thus, when these cells die bone necrosis occurs³.

BRONJ is a clinical situation that is observed increasingly frequently. The effectiveness of bisphosphonates in preventing bone pain and reabsorption in osteoporosis and control-

Table I. Clinical data of patients.

Patient name/gender/age	Residual unaffected mandibular height (mm)	Bisphosphonate means of administration	Disease	Follow-up time (months)
M.E./F/ 65	2	IV	Multiple myeloma	36
B.M./F/56	1	IV	Breast cancer metastasis	26
M.P./M/70	4	IM	Paget	24
L.S./F/72	6	Oral	Osteoporosis	18
G.V./F/78	6	Oral	Osteoporosis	30
A.F./M/72	1	IM	Melanoma metastasis	20
T.A./F/74	3	IM	Breast cancer metastasis	20
L.V./M/77	5	IM	Multiple Myeloma	26
A.P./F/82	4	Oral	Osteoporosis	14
S.S./F/75	3	IM	Osteoporosis	8

ling bone metastasis in the oncologic population leads to the increased use of this therapy. BRONJ is related to both IV and oral administration, the latter being less risky¹.

The clinical presentation of BRONJ patients can differ. Attempting to standardise the management of these patients, the American Association of Oral and Maxillo-facial Surgeons guidelines proposed a modified staging system in 2009⁴:

- At-risk category. Includes asymptomatic patients previously treated with either oral or IV bisphosphonates;
- Stage 0. No clinical evidence of necrotic bone, but non-specific clinical findings and symptoms;
- Stage 1. Exposed necrotic bone, asymptomatic, and with no evidence of infection;
- Stage 2. Exposed and necrotic bone associated with infection as evidenced by pain and erythema in the region of exposed bone with or without purulent drainage;
- Stage 3. Exposed and necrotic bone in patients with pain, infection, and one or more of the following: exposed and necrotic bone extending beyond the region of alveolar bone, resulting in pathologic fracture, extraoral fistula, oro-antral/oro-nasal communication, or osteolysis extending to the inferior border of the mandible or the sinus floor.

In the early stages conservative treatment is usually advised, while in approaching more complex clinical situations, as with stage 2-3 patients, the correct choice is challenging since management is not yet standardised. Surgical debridement/resection, in combination with antibiotic therapy, may offer a long-term palliative and valid solution, but progression to a more complex situation is more likely to occur with time.

In fact, usually the last stage is clinically characterised by pain, swelling, fistulae and finally mandibular fracture. In this situation patients cannot properly eat and, even if the fracture is reduced and stabilised with surgery, the fracture is not likely to heal. On the contrary, the presence of osteosynthesis material over the fracture may sustain a chronic infection.

Kuijpers et al. in 2011⁵ described a unique case of spontaneous healing of a BRONJ-related mandibular fracture in a 74-year-old woman, thus showing the persistent healing potential of bisphosphonate-treated bone, but of course this is not a rule.

Deciding not to treat patients often means sentencing them to a quick decline of their quality of life because of the high degree of pain. In selected cases they can even be treated with free flap reconstruction after mandible resection⁶, but most of these patients are old and in poor general condition, thus their clinical situation cannot be addressed with complex surgical procedures.

Therefore, we decided to stabilise the mandibular bone affected by BRONJ before fracture in those cases in which this clinical evolution is highly predictable, leading to a better clinical situation and preventing painful complications. We arbitrarily decided to apply a mandibular reconstructive plate using the previously described extra-platysma technique¹ when the residual height of the unaffected mandible is no more than 6 mm (Fig. 3). The skin incision in the neck is set 2 cm inferior to the lower mandibular border to improve the aesthetic result. The presence of osteosynthesis material over the platysma and placement of the screws distant from the infected surgical site reduce the risks of maintenance of chronic infection and worsening of osteonecrosis.

This plate is fixed in a plane superficial to the platysma muscle so that surgical dissection is not dangerous for the facial nerve since the marginalis mandibulae branch lies deeper inside. However, placing the screws without direct vision of the nerve branch could lead to nerve injuries. This is rare, and has never occurred in our patients.

This technique is an application of well-known concepts of stabilisation of atrophic jaws, without removal of the periosteal support to the residual stumps; consequently, blood supply to the affected mandible is maintained⁷. That is likely important for spontaneous healing of the necrotic bone and preventing expansion of the osteitis.

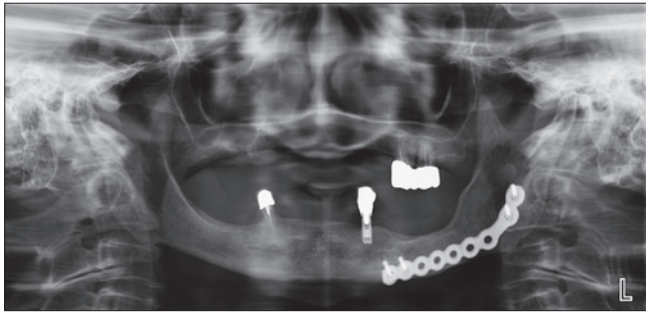


Fig. 3. Postoperative panoramic radiograph (at 24 months) showing the stable position of the reconstructive plate and extraordinary regrowth of mandibular bone.

Use of copious rinsing solution when drilling the screws is also advised to reduce the risk of BRONJ progression. The use of a locking instead of a compressive plate is important to avoid forcing of the weakened mandibular bone, which could lead to a mandibular fracture. The use of monocortical screws is intended to avoid excessive mechanical stress on the bone; the use of bicortical screws could lead to overloading. The oral approach stage of the operation is limited to curettage and rinsing of the surgical site. This is usually performed trying to avoid round burs and using ultrasound surgical devices such as a piezoelectric drill.

The presence of cutaneous fistulae does not represent a barrier to the application of this technique. In fact, in three cases we removed the fistula at the time of neck skin incision, and then closed it with a lower platysma pedicled flap to separate the necrotic site from the dissection plane where the reconstructive plate was going to be positioned. Rapid relief and preservation of normal masticatory function are achieved, and patients usually recover promptly.

The technique is painless, and patients can easily eat and be discharged after a few days, and thus this surgical solution can also be used in patients in poor general clinical conditions.

The suggested technique is easy to apply and in our patients was effective in preventing mandibular fractures in patients with low mandibular residual height after BRONJ onset.

References

- 1 Biglioli F, Pedrazzoli M. *Extra-platysma fixation of bisphosphonate-related mandibular fractures: a suggested technical solution.* Int J Oral Maxillofac Surg 2013;42:611-4.
- 2 Marx RE. *Pamidronate (Aredia) and Zoledronate (Zometa) induced avascular necrosis of the jaws: a growing epidemic.* J Oral Maxillofac Surg 2003;61:1115-8.
- 3 Ruggiero SL. *Emerging concepts in the management and treatment of osteonecrosis of the jaw.* Oral Maxillofac Surg Clin North Am 2013 25:1:11-20.
- 4 Ruggiero SL, Dodson TB, Assael LA, et al. *American Association of Oral and Maxillofacial Surgeons position paper on bisphosphonate-related osteonecrosis of the jaws--2009 update.* J Oral Maxillofac Surg 2009;67(Suppl 5):2-12.
- 5 Kuijpers SC, van Roessel EW, van Merkesteyn JP. *Unusual case of a conservatively treated pathological fracture after sequestrectomy in a patient with long-term oral bisphosphonate use.* J Craniomaxillofac Surg 2011;39:69-72.
- 6 Colletti G, Autelitano L, Rabbiosi D, et al. *Technical refinements in mandibular reconstruction with free fibula flaps: outcome-oriented retrospective review of 99 cases.* Acta Otorhinolaryngol Ital. 2014 Oct;34(5):342-8.
- 7 Ellis E III, Price C. *Treatment protocol for fractures of the atrophic mandible.* J Oral Maxillofac Surg 2008;66:421-35.

Received: November 8, 2015 - Accepted: February 2, 2016