ACTA OTORHINOLARYNGOLOGICA ITALICA 2016;36:310-316; doi: 10.14639/0392-100X-878

Audiology

Possibility of differentiation of cochlear electrodes in radiological measurements of the intracochlear and chorda-facial angle position

Possibilità di differenziazione degli elettrodi cocleari nelle misurazioni radiologiche della posizione intracocleare e dell'angolo cordo-facciale

I. DIOGO, U. WALLICZECK, J. TAUBE, N. FRANKE, A. TEYMOORTASH, J. WERNER, C. GÜLDNER
University Department of ORL, Head and Neck Surgery; UKGM, Marburg, Germany

SUMMARY

Due to an increasing number of cochlear implantations, quality control has become more important. In addition to intraoperative biophysical measurements, radiological imaging is another possibility. An upcoming technique regarding this is Cone Beam CT (CBCT). Sixty-five data sets (35 Nucleus Contour Advance–Cochlear; 30 Flex Soft–MedEl) of postoperative imaging by CBCT (Accu-I-tomo F17, Morita, Kyoto, Japan) underwent further evaluation. Insertion angle, height of the cochlea, distance of the electrode to the medial or lateral wall, angle between chorda tympani and facial nerve and the precise position of the electrode cable in the facial-chordal angle were determined. The typical difference between the perimodiolar and lateral course of the electrodes could also be shown in radiological measurements. This demonstrates the accuracy and advantage of CBCT in visualisation of small structures with fewer metal artifacts. Furthermore, in 75% of patients, the angle of the chorda and facial nerve could be visualised. Significant differences in dependence of the electrode type for the relation of them to the facial nerve could be seen. In conclusion, CBCT achieves reliable visualisation and detailed imaging-based measurements of the intracochlear position of different cochlea electrodes. Additionally, clinically known differences can be reproduced. Even visualisation of the position of the electrode in the chorda-facial angle is possible. Therefore, CBCT is a useful tool in intra- and postoperative control of cochlear implants.

KEY WORDS: Cochlear implant • Cone beam computed tomography • Visualisation of cochlea • Measurement of cochlea • Facial nerve

RIASSUNTO

Con l'incremento del numero di impianti cocleari effettuati, il controllo di qualità è divenuto sempre più importante. Oltre alle misurazioni biofisiche intraoperatorie ci si può avvalere dell'imaging radiologico. Una nuova tecnica utilizzata in questo campo è il Cone Beam CT (CBCT). Nel presente studio sono stati valutati 65 casi (35 Nucleus Contour Advance–Cochlear; 30 Flex Soft–MedEl) studiati mediante CBCT (Accu-I-tomo F17, Morita, Kyoto, Japan). Nello specifico sono stati rilevati: l'angolo di inserzione, l'altezza dell'impianto, la distanza dell'elettrodo dalla parete mediale o laterale, l'angolo tra la corda del timpano e il nervo facciale e la posizione precisa del filo dell'elettrodo nell'angolo cordo-facciale. È stato inoltre possibile valutare la differenza tra il decorso peri-modiolare e laterale degli elettrodi. I dati presentati dimostrano l'accuratezza e il vantaggio della CBCT nella visualizzazione di piccole strutture grazie al ridotto numero di artefatti da indurimento del fascio. Inoltre nel 75% dei pazienti è stato possibile visualizzare l'angolo tra la corda del timpano e il nervo facciale. È stato possibile notare differenze significative fra i vari tipi di elettrodo in funzione del tipo di rapporto con il nervo facciale. In conclusione mediante la CBCT è possibile ottenere una visualizzazione precisa e dettagliate misurazioni della posizione intracocleare dei diversi elettrodi. È persino possibile la corretta valutazione della posizione dell'elettrodo rispetto all'angolo cordo- facciale. La CBCT è quindi, dal nostro punto di vista, un utile strumento per il controllo intra e post-operatorio degli impianti cocleari.

PAROLE CHIAVE: *Impianto cocleare • Cone beam computed tomography • Visualizzazione della coclea • Misurazioni della coclea • Nervo facciale*

Acta Otorhinolaryngol Ital 2016;36:310-316

Introduction

Cochlear implantation is currently the standard in rehabilitation of hereditary or acquired high grade inner ear hearing loss. This results in increasing standardisation and improvement of surgical techniques and technical development of newly dedicated implants. To achieve this and to prevent complications, intra- or postoperative evaluation of the implanted situation is necessary. In addition to biophysical measurements, radiological imaging is the only way to get information about the intracochlear position and the relation of the electrode to anatomic important structures. In the beginning, conventional radiography was used. Today, more information is needed, and thus computed tomography (CT) and cone beam computed tomography (CBCT) are used and recommended by current guidelines [1 2]. Regarding the irradiation, naturally conventional plain radiography has the lowest dose, but in almost the same manner the lowest grade of information. Considering CBCT and CT, the former has about the half to a third of the radiation dose of CT, which is a main advantage particularly in children [3-5].

Imaging methods methods with fewer artifacts are needed, not only to visualise that the electrode is inside the cochlea, but also to present an impression of the detailed intracochlear position and distances to the modiolus or lateral wall. Therefore, CBCT has been introduced into ENT imaging with a special focus on visualisation of middle and inner ear implants [6-8]. Despite some studies that have focused on possibilities [9-12] and limitations [13 14] of this method in comparison to CT, some questions still remain. Can different types of electrodes (modiolar vs. lateral position) also be differentiated not only by impression of the observer, but also reproduced by measurements based on CBCT images? Is it possible to visualise the angle between the chorda tympani and facial nerve and the relation of the electrode/cable to these structures [15]? The current paper aims to answer some of these questions.

Methods

All of our data on patients with a cochlear implant and imaging of their implant by CBCT two typical groups (N = 82) were analysed. Inclusion criteria were: one of the following implant types, existing row data for detailed radiological measurement, low enough artifacts for precise intracochlear measurements and full insertion of the electrode. The first group consisted of patients with a perimodiolar positioned electrode of the cochlea (Contour Advance 512; N = 35). The second group consisted of patients with the lateral wall electrode of MedEl (Flex soft standard electrode; N = 30). All electrodes were inserted through the regular or enlarged round window.

Of the 65 patients, 52% (N = 33) were female and 48% (N = 32%) were male. The mean age at the time of imaging was 51.6 years (range 5 to 88 years). Forty-five percent (N = 29) of the data sets concerned the left ear, whereas 55% (N = 36) were right ears. In three patients, both ears were analysed.

All images were performed on the day of operation or the day after using a CBCT device from Morita (Accu-I-tomo, F17, Kyoto, Japan). The tube current ranged between 84.0 and 90.0 kV. The tube voltage was between 3.0 mA and 8.0 mA. The primary size of the acquired voxels was at 0.08 mm. Imaging analyses and measurements were performed using One Volume Viewer (I-Dixel 2.0, Morita, Kyoto, Japan).

According to a consensus paper, the insertion angle of each single electrode was measured in relation to the entrance of the cochlea (Fig. 1) [16]. In the background of the known difficulties of evaluation in the middle and apical turn and to compare both electrode types, only the first 360° of the cochlea was analyzed.

Based on this reconstructed image, for each single electrode the following parameters were measured. First, the diameter of the cochlea was determined on a line orthogonal to the lateral and medial wall through the electrode. Second, along the same line, the diameter of the electrode, and third the distance of the electrode to the lateral wall (in the case of group 1) or the distance of the electrode to the medial wall (in the case of group 2) were measured (Fig. 2).

Due to the relationship of the electrode and its cable and the facial nerve with the chorda tympani, all 82 patients were reviewed for visibility. Four patients were excluded due to a field of view that was too small. Fourteen pa-

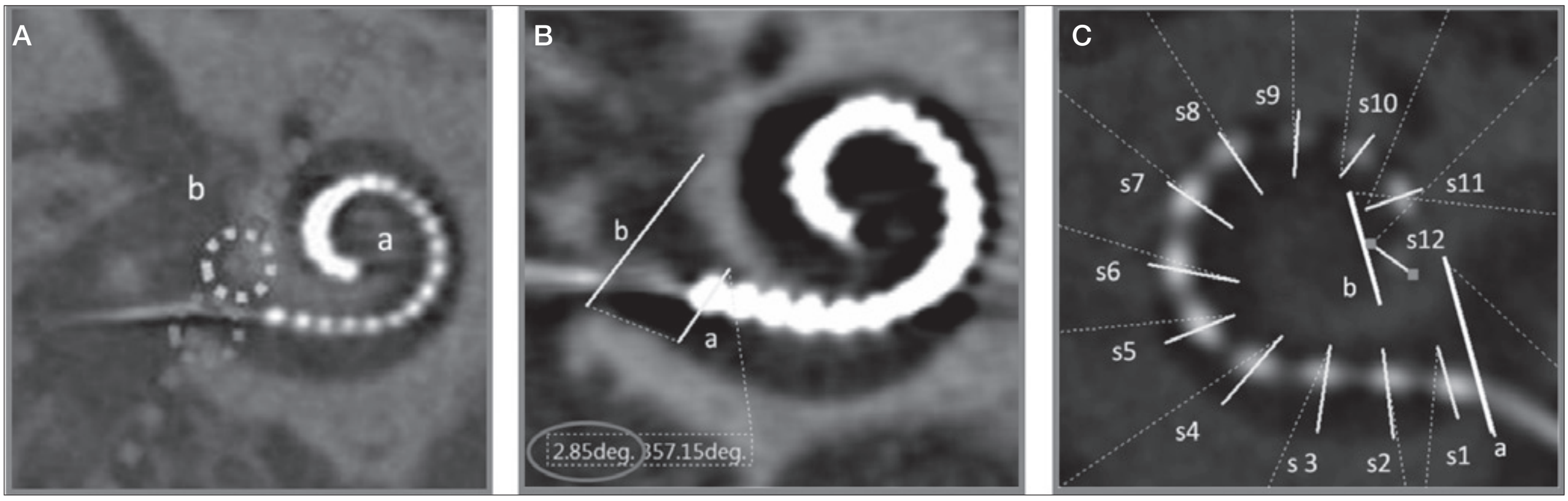

Fig. 1. Visualisation of the way of measurement the insertion angle (in accordance to [16]). The baseline is defined by round window edge and turning point of cochlea to vestibule (A). The angle is measured with a standard tool between the baseline and a line through the single electrode orthogonal to the lateral and medial wall of the cochlea (B). Angle measurements were performed for each single electrode (C).

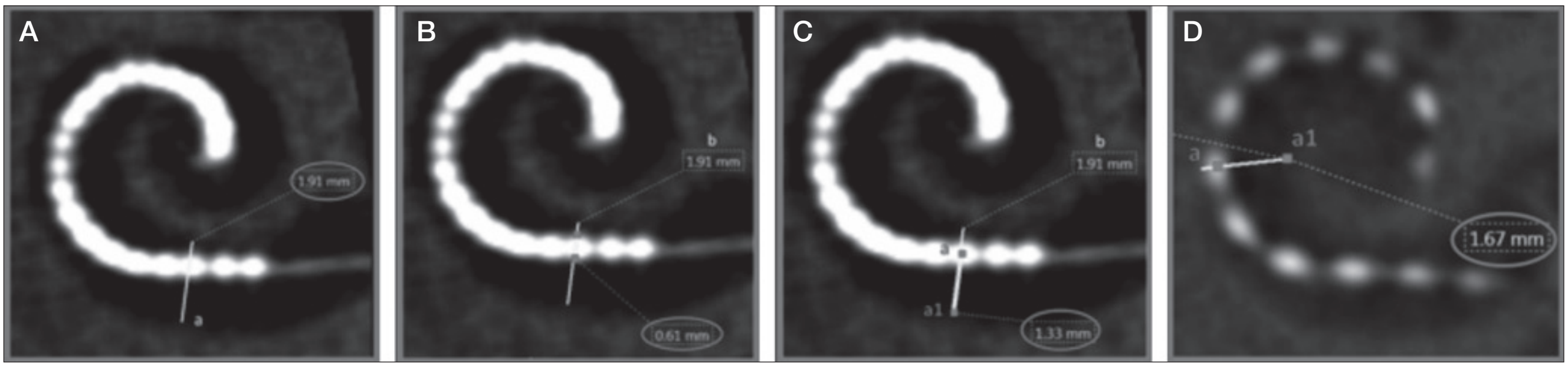

Fig. 2. The diameter of the cochlea (A) and the electrode (B) were measured. In case of perimodiolar electrodes, the distance from lateral wall to electrode (C) and in case of lateral wall electrodes, the distance from medial wall to electrode (D) were determined.

tients had to be excluded due to missing visibility of the chorda tympani, and two more due to too many artifacts. In all, 62 of the 82 (75%) underwent further analysis. A standardised multiplanar reconstruction resulted in a view showing the chorda tympani, facial nerve, horizontal semicircular canal and the cable of the electrode. The angle between the chorda tympani and facial nerve was determined by a standard angle measurement option (Fig. 3). The following measurements were performed on a parallel horizontal line to the semicircular canal at the point of the electrode in the chorda-facial-angle. The diameter of the facial nerve, thickness of the bony coverage in direction to the electrode and distance of the electrode to the bony canal of facial nerve were determined at this point (Fig. 4).

Results

Regarding the group of the Contour Advance electrode, in 9 of 35 patients (26%) all 22 electrodes were in the first 360° of the cochlea. In all patients, the first 18 electrodes could be detected in the first 360°. In the Flex-soft group, the first seven electrodes were within the first 360° in all patients. In all patients of this group, electrodes 10 to 12 were deeper than 360°.

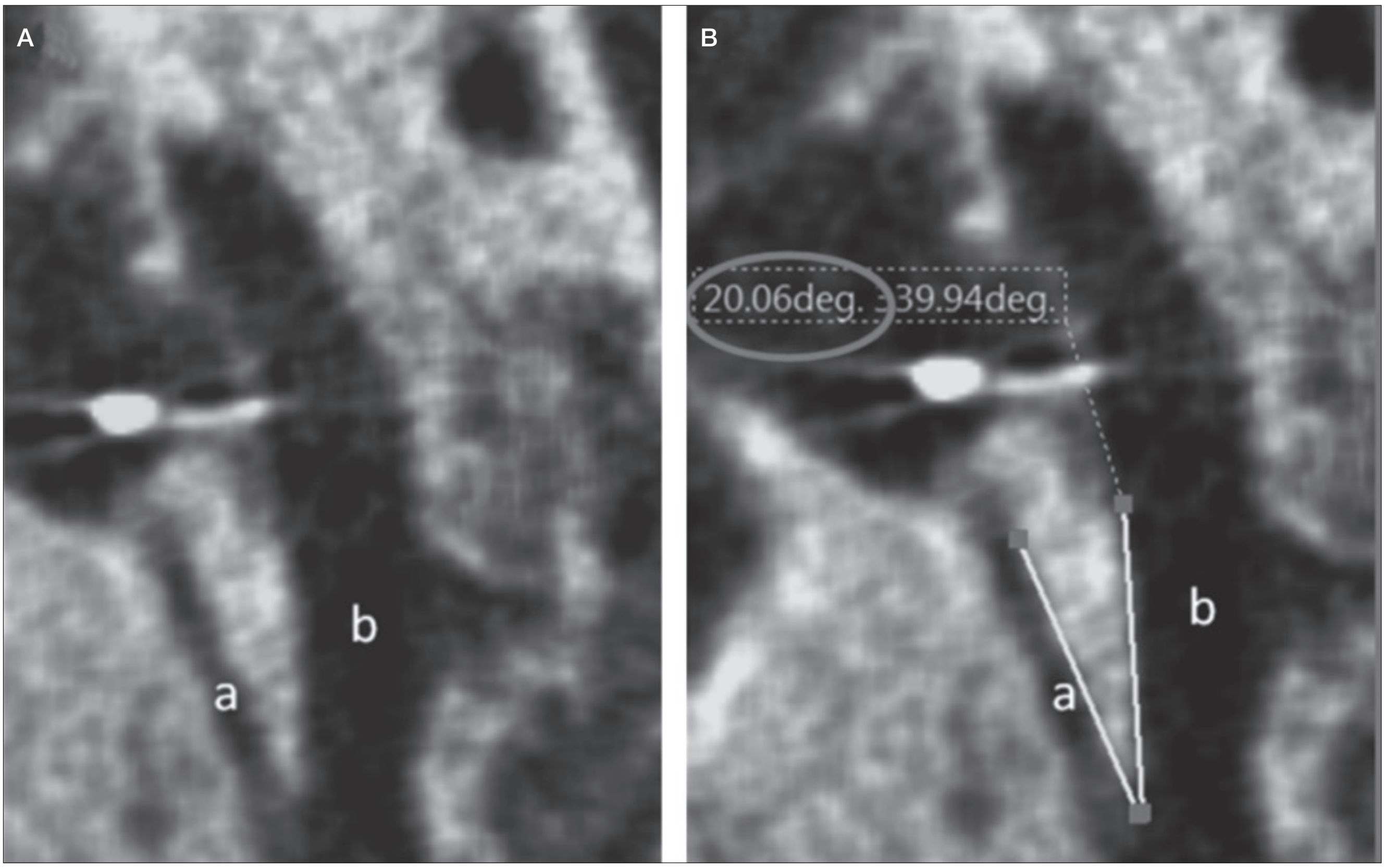

Fig. 3. Typical image of the chorda tympani (a) and the angle to the facial nerve (b) is presented (A). The angle between both structures was measured in each case (B).

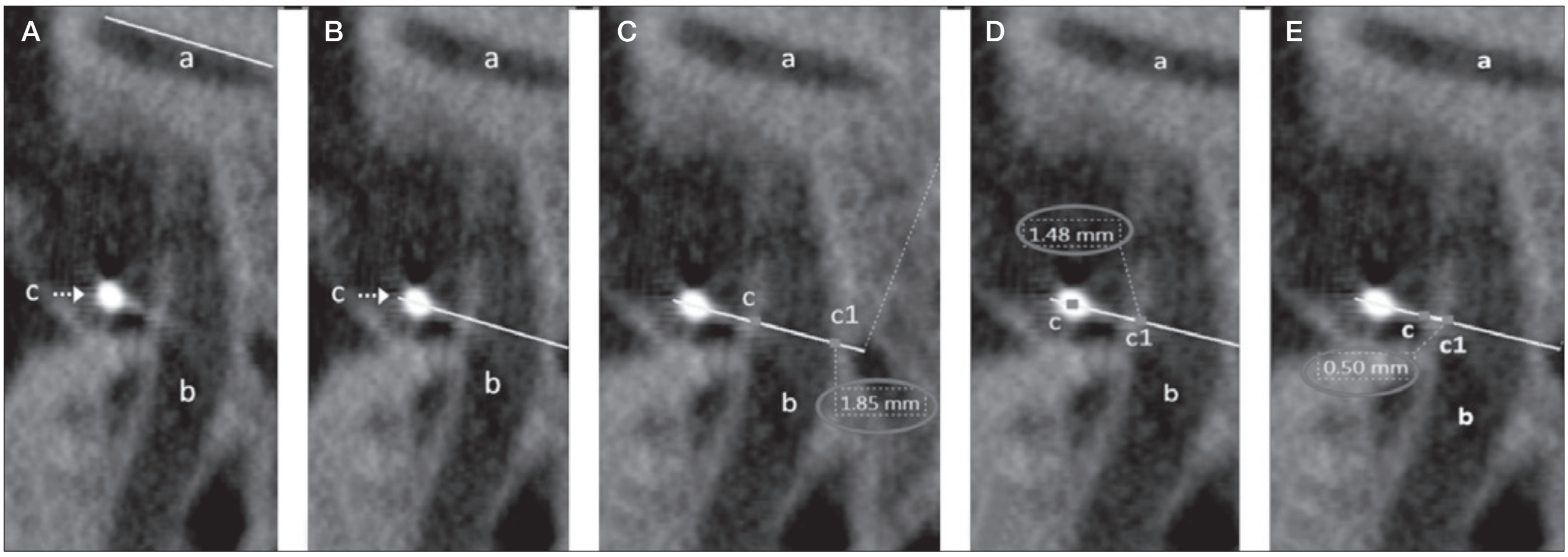

Fig. 4. The distances were measured based on a reference line parallel through the horizontal semicircular canal (A) at the point of the electrode cable (B). The diameter of the facial nerve (C), the distance of the electrode cable to the nerve canal (D) and the bony thickness over the nerve (D) were determined.

The diameter of the cochlea showed a continuously decrease from beginning in direction of apex, whereas a maximum of 2.1 ± 0.43 mm could be seen at the insertion angle between 106° and 120° and a minimum of 1.58 ± 0.3 mm could be detected at the insertion angle between 346° and 360°. No significant differences between groups could be seen (Fig. 5, A). Also, the measurements of the electrode diameter showed the expected decrease from basal to apical (Fig. 5, B).

In the group of Contour Advance electrodes, the mean

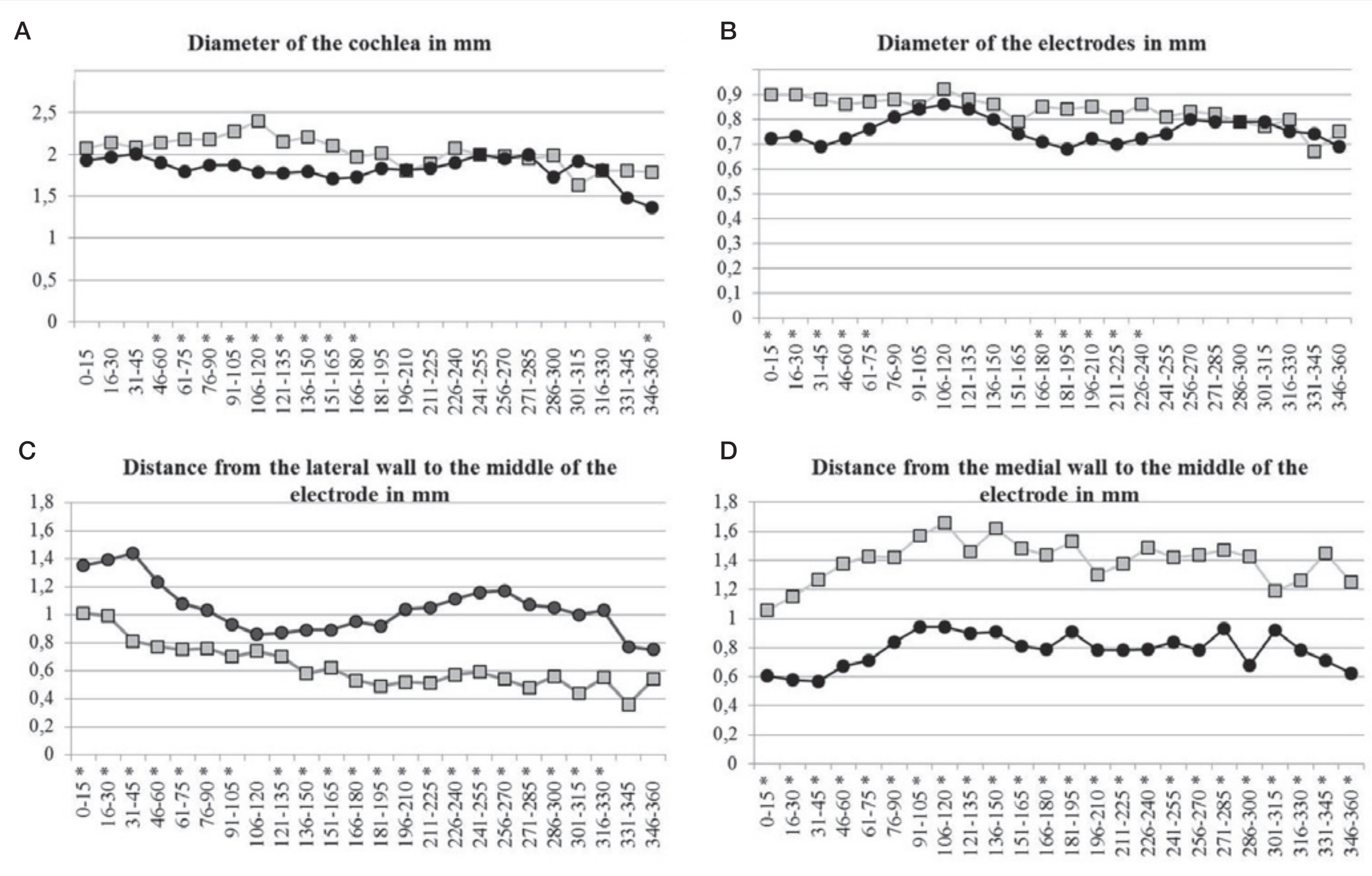

Fig. 5. All graphs show the results for the different measurements and different types of electrodes (grey - Standard flex electrode; black - Contour Advance electrode) in relation to the insertion angle (in 15° groups). All *-marked regions of insertion angle are significant different between both groups ($p < 0.05$). A) Diameter of the cochlea. B) Diameter of the electrode. C) Distance from medial wall to middle of the electrode. D) Distance from the lateral wall to the middle of the electrode.

distance from the electrode to the medial cochlea wall was 0.78 ± 0.12 mm whereas in the Flex-soft group, the mean was at 1.4 ± 0.15 mm. The opposite could be seen in the mean distance of the electrode to the lateral wall (Contour advance group: 1.0 ± 0.18 mm vs. Flex soft group: 0.63 ± 0.16 mm). All differences were significant for the mean and each value of the separate 15°-angle-group ($p < 0.01$). In both measurement curves, a decrease from basal to apical could again be detected (Fig. 5, C and D).

Measurements at the point of chorda-facial-angle are summarised in Table I. The mean angle for all patients between the chorda tympani and facial nerve was 22.6 ± 9.5°. No significant difference could be seen between the groups (group 1: 23.7 ± 9° vs. group 2: 21.2 ±10°; p = 0.61). The diameter of the bony facial nerve canal was 1.8 ± 0.4 mm. Interestingly, a significant difference was found between groups (group 1: 1.7 ± 0.4 mm vs. group 2: 2.0 ± 0.4 mm; p = 0.001). The mean distance from the electrode to the facial nerve was 1.8 ± 0.7 mm. No difference between groups was detected (group 1: 1.7 ± 0.6 mm vs. groups 2: 1.8 ± 0.7 mm; p = 0.41). The mean bony coverage of the facial nerve was 0.8 ± 0.4 mm. Again, no significant difference was seen (group 1: 0.78 ± 0.36 mm vs. group 2: 0.84 ± 0.37 mm; p = 0.35).

Discussion

The number of cochlear implantations has been increasing for many years. This is because of consequent newborn hearing screening programmes and implantation of patients with single sided deafness and residual hearing [17]. For further development of electrodes and improvement of surgical techniques, sufficient postoperative visualisation of the implanted electrode is necessary. Conventional radiography only shows implantation into the cochlea or not, and gives no information about the detailed anatomy and specific intracochlear position. CT is much better, but due to the high range of metal artifacts, the potential of specific analyses is still low [18-20]. CBCT is upcoming technique with high potential for visualisation of bony anatomy and implants due to fewer artifacts in comparison to CT[3]. Several publications have shown its potential in visualisation of cochlear electrodes and its accuracy in comparison to histological examination [11 21-23]. Even in CBCT, metal artifacts exist and result in reduced power of determination in medial and apical turn of the cochlear [13 14]. The next steps of development will be automatic analyses of the images and imaging fusion of pre- and postoperative data [6]. Therefore, precise measurements of the electrode and its intracochlear position are needed. Additionally, measurement-based differentiation of different electrode types is necessary. The current study focused on this topic.

As expected, a decreasing diameter of the cochlea could be detected. This is in accordance with the knowledge based on anatomic studies and shows the accuracy of the performed measurements [24 25]. A relevant inter-individual range of the size of the cochlea exists and leaves open the question of the sense of standardised length of electrodes [24 26]. Variability could be seen in the number of implanted electrodes into the individual cochlea. In the group of Contour Advance electrodes, only 26% (9/35) of all 22 electrodes were within in the basal turn (first 360°) of the cochlea. Based on the different design, all patients with the Flex Soft electrode were inserted deeper than the basal turn. The impact of implantation depth on speech understanding and hearing quality of music is still controversial [27 28]. Particularly with this background, and the focus of inner ear trauma, visualisation of the inner structure of the cochlea before and after implantation remains a focus of research. The current study demonstrates that it is possible to measure the visible and well known differences of the different implant types. Thus, a significant difference in the distances of the electrode to the medial and lateral cochlea wall was found for both groups. A second indicator of accuracy was the determined diameter of the electrode itself, which was in concordance with the information from the manufacturers.

Another frequent problem in cochlear implantation surgery is the relationship to the facial nerve, the chorda tympani and the risk of unexpected postoperative facial nerve stimulation [29]. This might be caused, for example, by extracochlear electrodes, thin bony coverage of facial nerve or direct electric stimulation of the middle ear- or vestibular part of the facial nerve [29]. Because of this problem, the second part of this study analysed the potential of CBCT in visualisation of the chorda-facial angle and relationship to the electrode. Preclinical examinations of temporal bones showed the principal possibility of visualisation of the chorda tympani in CT and CBCT [15 30]. No clinical data based on daily routine imaging data were found in the literature. Therefore, astonishingly, in a fairly high number of patients – 75% (64/82) – the chorda-facial angle could

Table I. Results of measurements at the point of the chorda-facial angle.

	All implants together	Cochlear	MedEl	p-Wert
Chorda-facial angle (°)	22.6 ± 9.5	23.7 ± 9	21.2 ± 10	0.61
Diameter of bony facial nerve canal (mm)	1.8 ± 0.4	1.7 ± 0.4	2.0 ± 0.4	0.001
Distance from electrode to facial nerve canal (mm)	1.8 ± 0.7	1.7 ± 0.7	1.8 ± 0.7	0.41
Thickness of bone above facial nerve (mm)	0.8 ± 0.4	0.78 ± 0.36	0.84 ± 0.37	0.35

be visualised and analysed. The mean angle was 22.6 ± 10° and the distance of the electrode to the bony canal of the facial nerve was about 1.8 mm with a thickness of the bony coverage of about 0.8 mm. The diameter of the facial nerve canal was determined at 1.8 mm and is in principal accordance with other studies [31]. Interestingly, a significant difference in the diameter of facial nerve canal could be detected between groups. We interpret this as a result of different insertion angles of the different types of implants. This might lead to a slightly different position regarding the height of the electrode in the chorda-facial angle, and in conclusion, to a different diameter of the facial nerve canal at the corresponding position. However, this problem should be addressed for detailed analyses in further studies.

Conclusions

CBCT has high potential for visualisation of different types of cochlear implants and achieves a reliable measurement-based analysis of the detailed intracochlear position of the electrode. Furthermore, visualisation and analyses of the chorda-facial angle and its relation to the electrode cable are frequently possible. Therefore, CBCT should be regarded as a useful tool for further radiological/audiological studies.

References

[1] Dammann F, Grees H, Kösling S, et al. *Algorithmen für die Durchführung radiologischer Untersuchungen der Kopf-Hals-Region*. AWMF 2015;039/093.

[2] German Society of Otorhinolaryngology H.a.N.S. *Cochlea-Implantat Versorgung einschließlich zentral-auditorischer Implantate.* AWMF 2012;017-071

[3] Theunisse HJ, Joemai RM, Maal TJ, et al. *Cone-beam CT versus multi-slice CT systems for postoperative imaging of cochlear implantation - a phantom study on image quality and radiation exposure using human temporal bones*. Otol Neurotol 2015;36:592-9.

[4] Stratemann SA, Huang JC, Maki K, et al. *Comparison of cone beam computed tomography imaging with physical measures*. Dentomaxillofac Radiol 2008;37:80-93.

[5] Eggers G, Klein J, Welzel T, et al. *Geometric accuracy of digital volume tomography and conventional computed tomography*. Br J Oral Maxillofac Surg 2008;46:639-44.

[6] Aschendorff A. *Imaging in cochlear implant patients*. Laryngorhinootologie 2011;90(Suppl 1):S16-21.

[7] Güldner C, Heinrichs J, Weiss R, et al. *Prospective evaluation of reliability of cone beam computed tomography in detecting different position of vibroplasty middle ear implants*. Clin Otolaryngol 2013;38:217-24.

[8] Güldner C, Heinrichs J, Weiss R, et al. *Visualisation of the bonebridge by means of CT and CBCT*. Eur J Med Res 2013;18:30.

[9] Zou J, Hannula M, Lehto K, et al. *X-ray microtomographic confirmation of the reliability of CBCT in identifying the scalar location of cochlear implant electrode after round window insertion*. Hear Res 2015;326:59-65.

[10] Zou J, Lahelma J, Koivisto J, et al. *Imaging cochlear implantation with round window insertion in human temporal bones and cochlear morphological variation using high-resolution cone beam CT*. Acta Otolaryngol 2015;135:466-72.

[11] Kurzweg T, Dalchow CV, Bremke M, et al. *The value of digital volume tomography in assessing the position of cochlear implant arrays in temporal bone specimens*. Ear Hear 2011;31:413-9.

[12] Aschendorff A, Kubalek R, Turowski B, et al. *Quality control after cochlear implant surgery by means of rotational tomography*. Otol Neurotol 2005;26:34-7.

[13] Diogo I, Franke N, Steinbach-Hundt S, et al. *Differences of radiological artefacts in cochlear implantation in temporal bone and complete head*. Cochlear Implants Int 2013;15:112-7.

[14] Güldner C, Wiegand S, Weiss R, et al. *Artifacts of the electrode in cochlea implantation and limits in analysis of deep insertion in cone beam tomography (CBT)*. Eur Arch Otorhinolaryngol 2012;269:767-72.

[15] Hiraumi H, Suzuki R, Yamamoto N, et al. *The sensitivity and accuracy of a cone beam CT in detecting the chorda tympani*. Eur Arch Otorhinolaryngol 2016;273:873-7.

[16] Verbist BM, Skinner MW, Cohen LT, et al. *Consensus panel on a cochlear coordinate system applicable in histologic, physiologic, and radiologic studies of the human cochlea*. Otol Neurotol 2010;31:722-30.

[17] Stark T, Helbig S. *Cochleaimplantatversorgung: Indikation im Wandel*. HNO 2011;59:605-14.

[18] Swartz JD, Russell KB, Wolfson RJ, et al. *High resolution computed tomography in evaluation of the temporal bone*. Head Neck Surg 1984;6:921-31.

[19] Lecerf P, Bakhos D, Cottier JP, et al. *Midmodiolar reconstruction as a valuable tool to determine the exact position of the cochlear implant electrode array*. Otol Neurotol 2011;32:1075-81.

[20] Todt I, Rademacher G, Wagner J, et al. *Evaluation of cochlear implant electrode position after a modified round window insertion by means of a 64-multislice CT*. Acta Otolaryngol 2009;129:966-70.

[21] Boyer E, Karkas A, Attye A, et al. *Scalar localization by cone-beam computed tomography of cochlear implant carriers: a comparative study between straight and periomodiolar precurved electrode arrays*. Otol Neurotol 2015;36:422-9.

[22] Xu J, Reh DD, Carey JP, et al. *Technical assessment of a cone-beam CT scanner for otolaryngology imaging: image quality, dose, and technique protocols*. Med Phys 2012;39:4932-42.

[23] Bremke M, Luers JC, Stenner M, et al. *Radiologic examinations in human temporal bone specimens using digital volume tomography and high-resolution computed tomography after implantation of middle ear prosthesis and cochlear implant electrode array*. Otol Neurotol 2013;34:1321-1328

[24] Erixon E, Hogstorp H, Wadin K, et al. *Variational anatomy of the human cochlea: implications for cochlear implantation*. Otol Neurotol 2009;30:14-22.

[25] Dimopoulos P, Muren C. *Anatomic variations of the cochlea and relations to other temporal bone structures*. Acta Radiol 1990;31:439-44.

[26] Avci E, Nauwelaers T, Lenarz T, et al. *Variations in microanatomy of the human cochlea*. J Comp Neurol 2014;522:3245-61.

[27] Hochmair I, Arnold W, Nopp P, et al. *Deep electrode insertion in cochlear implants: apical morphology, electrodes and speech perception results*. Acta Otolaryngol 2003;123:612-7.

[28] Gani M, Valentini G, Sigrist A, et al. *Implications of deep electrode insertion on cochlear implant fitting*. J Assoc Res Otolaryngol 2007;8:69-83.

[29] Ahn JH, Oh SH, Chung JW, et al. *Facial nerve stimulation after cochlear implantation according to types of Nucleus 24-channel electrode arrays*. Acta Otolaryngol 2009;129:588-91.

[30] Erovic BM, Chan HH, Daly MJ, et al. *Intraoperative cone-beam computed tomography and multi-slice computed tomography in temporal bone imaging for surgical treatment*. Otolaryngol Head Neck Surg;150:107-14.

[31] Komori M, Yamada K, Hinohira Y, et al. *Width of the normal facial canal measured by high-resolution cone-beam computed tomography*. Acta Otolaryngol 2013;133:1227-32.

Received: October 10, 2014 - Accepted: February 13, 2016

Address for correspondence: Christian Güldner, University Hospital of Marburg, Department of ENT, Head- and Neck Surgery, Baldingerstraße, 35043 Marburg, Germany. Tel. +49 64215869052. Fax +49 64215866367. E-mail: gueldner@staff.uni-marburg.de