

# Otorhinolaryngologica Italica

Volume 36

2

April 2016

*Official Journal of the Italian Society of Otorhinolaryngology  
Head and Neck Surgery*

Organo Ufficiale della Società Italiana di Otorinolaringologia  
e Chirurgia Cervico-Facciale

## Review

Aspects of cerebral plasticity related to clinical features in acute vestibular neuritis: a "starting point" review from neuroimaging studies

## Head and neck

Intraoperative radiation therapy as adjuvant treatment in locally advanced stage tumours involving the middle ear: a hypothesis-generating retrospective study

Post-operative pain management in head and neck cancer patients: predictive factors and efficacy of therapy

## Rhinology

The effects of inferior turbinoplasty on nasal airflow during cosmetic rhinoplasty

In vivo tissue response and durability of five novel synthetic polymers in a rabbit model

## Skull base

Endoscopic endonasal approach to the craniocervical junction: the importance of anterior C1 arch preservation or its reconstruction

## Audiology

Idiopathic sensorineural hearing loss in the only hearing ear

## Otology

Early and late surgical site infections in ear surgery

Can the learning curve in stapes surgery predict future functional outcome?

## Clinical techniques and technology

Oral cavity reconstruction with the masseter flap

## Case series and reports

Endonasal endoscopic resection of ossifying fibroma involving the ethmoid sinus, orbit and anterior skull base: case report and literature review

Traumatic intra-sphenoidal pseudoaneurysm lodged inside the fractured sphenoidal sinus

# ACTA

PACINI  
EDITORE  
MEDICINA

[www.actaitalica.it](http://www.actaitalica.it)



# ACTA

## Otorhinolaryngologica Italica

*Official Journal of the Italian Society of Otorhinolaryngology - Head and Neck Surgery*  
Organo Ufficiale della Società Italiana di Otorinolaringologia e Chirurgia Cervico-Facciale

Former Editors-in-Chief: C. Calearo†, E. de Campora, A. Staffieri, M. Piemonte, F. Chiesa

### Editorial Board

*Editor-in-Chief:*

G. Paludetti

*President of S.I.O.:*

R. Filipo

*Former Presidents of S.I.O.  
and Editors-in-Chief:*

I. De Vincentiis, D. Felisati, L. Coppo,  
G. Zaoli, P. Miani, G. Motta,  
L. Marcucci, A. Ottaviani,  
P. Puxeddu, M. Maurizi, G. Sperati,  
D. Passali, E. de Campora, A. Sartoris,  
P. Laudadio, M. De Benedetto,  
S. Conticello, D. Casolino,  
A. Rinaldi Ceroni, M. Piemonte,  
A. Staffieri, F. Chiesa, R. Fiorella,  
A. Camaioni, A. Serra, G. Spriano

### Editorial Staff

*Editor-in-Chief:*

G. Paludetti

*Deputy Editor:*

J. Galli

*Associate Editors:*

G. Almadori, F. Ottaviani

*Editorial Coordinator:*

E. De Corso

*Editorial Assistant:*

P. Moore

*Treasurer:*

L. de Campora

### Italian Scientific Board

L. Bellussi, G. Danesi, C. Grandi,

A. Martini, L. Pignataro, F. Raso,

R. Speciale, I. Tasca

### International Scientific Board

J. Betka, P. Clement, M. Halmagyi,

L.P. Kowalski, M. Pais Clemente,

J. Shah, H. Stammberger, R. Laszig,

G. O'Donoghue, R.J. Salvi, R. Leemans,

M. Remacle, F. Marshal, H.P. Zenner,

B. Scola Yurrita, R.W. Gilbert

### Editorial Office

*Editor-in-Chief:*

G. Paludetti

Department of Head and Neck Surgery -  
Otorhinolaryngology

Catholic University of the Sacred Heart

"A. Gemelli" Hospital

L.go F. Vito, 1 - 00168 Rome, Italy

Tel. +39 06 30154439

Fax + 39 06 3051194

actaitalicaorl@rm.unicatt.it

*Editorial Coordinator:*

E. De Corso

eugenio.decorso@policlinicogemelli.it

*Editorial Secretary:*

R. Gallus

gallusroberto@gmail.com

### Argomenti di Acta

**Otorhinolaryngologica Italica**

*Editor-in-Chief:* G. Paludetti

*Editorial Coordinator:* M.R. Marchese  
raffaellamarchese@gmail.com

© Copyright 2016 by

Società Italiana di Otorinolaringologia  
e Chirurgia Cervico-Facciale  
Via Luigi Pigorini, 6/3  
00162 Rome, Italy

### Publisher

Pacini Editore Srl

Via Gherardesca, 1

56121 Pisa, Italy

Tel. +39 050 313011

Fax +39 050 3130300

info@pacineditore.it

www.pacinieditore.it

*Acta Otorhinolaryngologica Italica is cited  
in Index Medicus, MEDLINE, PubMed  
Central, Science Citation Index Expanded,  
Scopus, DOAJ, Open-J Gate, Free Medical  
Journals, Index Copernicus, Socolar*

*Journal Citation Reports:*

*Impact Factor 1.640*

*Acta Otorhinolaryngologica Italica is  
available on Google Scholar*

PACINI  
EDITORE  
MEDICINA

www.actaitalica.it



# Contents

## Review

Aspects of cerebral plasticity related to clinical features in acute vestibular neuritis: a “starting point” review from neuroimaging studies

*La plasticità cerebrale correlata alle caratteristiche cliniche nella neuronite vestibolare acuta: una revisione della letteratura di neuroimaging*

A. Micarelli, A. Chiaravalloti, O. Schillaci, F. Ottaviani, M. Alessandrini . . . . . pag. 75

## Head and neck

Intraoperative radiation therapy as adjuvant treatment in locally advanced stage tumours involving the middle ear: a hypothesis-generating retrospective study

*Radioterapia intraoperatoria nei tumori maligni avanzati estesi all'orecchio medio: valutazione da uno studio retrospettivo*

G. Cristalli, G. Mercante, L. Marucci, A. Soriani, S. Telera, G. Spriano . . . . . » 85

Post-operative pain management in head and neck cancer patients: predictive factors and efficacy of therapy

*Dolore post-operatorio nei pazienti affetti da neoplasia testa-collo: fattori predittivi ed efficacia della terapia*

C. Bianchini, M. Malagò, L. Crema, C. Aimoni, T. Matarazzo, S. Bortolazzi, A. Ciorba, S. Pelucchi, A. Pastore . . . . . » 91

## Rhinology

The effects of inferior turbinoplasty on nasal airflow during cosmetic rhinoplasty

*Gli effetti sul flusso aereo nasale della turbinoplastica inferiore in corso di rinoseptoplastica*

R. Zojaji, M. Keshavarzmanesh, M. Bakhshae, R. Behdani, S. Esmaealzadeh, M. Mazloun Farsi Baf . . . . . » 97

In vivo tissue response and durability of five novel synthetic polymers in a rabbit model

*Biocompatibilità e durata in vivo di cinque nuovi polimeri sintetici testati su coniglio*

E. Sahin, C. Cingi, G. Eskizmir, N. Altintoprak, A. Calli, C. Calli, I. Yilgör, E. Yilgör . . . . . » 101

## Skull base

Endoscopic endonasal approach to the craniocervical junction: the importance of anterior C1 arch preservation or its reconstruction

*Approccio endoscopico endonasale alla giunzione craniocervicale: l'importanza di preservare o ricostruire l'arco anteriore dell'atlante*

M. Re, M. Iacoangeli, L. Di Somma, L. Alvaro, D. Nasi, G. Magliulo, F.M. Gioacchini, D. Fradeani, M. Scerrati . . . . . » 107

## Audiology

Idiopathic sensorineural hearing loss in the only hearing ear

*Ipoacusia neurosensoriale idiopatica nell'unico orecchio udente*

S. Berrettini, A. De Vito, L. Bruschini, S. Fortunato, F. Forli . . . . . » 119

## Otology

Early and late surgical site infections in ear surgery

*Complicanze infettive locali precoci e tardive nella chirurgia otologica*

P.L. Bastier, C. Leroyer, A. Lashéras, A.-M. Rogues, V. Darrouzet, V. Franco-Vidal . . . . . » 127

Can the learning curve in stapes surgery predict future functional outcome?

*L'analisi della curva di apprendimento della chirurgia dell'otosclerosi può aiutare a predire i risultati funzionali?*

B. Sergi, G. Paludetti . . . . . » 135

## Clinical techniques and technology

Oral cavity reconstruction with the masseter flap

*Ricostruzione del cavo orale con lembo massetere*

R. Mahieu, S. Russo, T. Gualtieri, G. Colletti, A. Deganello . . . . . » 139

## Case series and reports

Endonasal endoscopic resection of ossifying fibroma involving the ethmoid sinus, orbit and anterior skull base: case report and literature review

*Resezione endoscopica di un fibroma ossificante interessante il seno etmoidale, l'orbita e il basicranio anteriore: case report e revisione della letteratura*

M. Jurlina, N. Skitarelić, D. Passali, F.M. Passali, R. Mladina . . . . . » 144

Traumatic intra-sphenoidal pseudoaneurysm lodged inside the fractured sphenoidal sinus

*Pseudoaneurisma di origine traumatica localizzato in un seno sfenoidale fratturato*

P. Pelliccia, M. Bartolomeo, G. Iannetti, A. Bonafé, M. Makeieff . . . . . » 149

**Calendar of events - Italian and International Meetings and Courses . . . . . » 153**

Information for authors including editorial standards for the preparation of manuscripts  
available on-line: [www.actaitalica.it](http://www.actaitalica.it)

REVIEW

# Aspects of cerebral plasticity related to clinical features in acute vestibular neuritis: a “starting point” review from neuroimaging studies

## *La plasticità cerebrale correlata alle caratteristiche cliniche nella neuronite vestibolare acuta: una revisione della letteratura di neuroimaging*

A. MICARELLI<sup>1,2</sup>, A. CHIARAVALLOTI<sup>3</sup>, O. SCHILLACI<sup>3,4</sup>, F. OTTAVIANI<sup>1</sup>, M. ALESSANDRINI<sup>1</sup>

<sup>1</sup> Ear-Nose-Throat Unit, “Tor Vergata” University, Rome, Italy; <sup>2</sup> Systems Medicine Department, Neuroscience Unit, “Tor Vergata” University, Rome, Italy; <sup>3</sup> Department of Biomedicine and Prevention, “Tor Vergata” University, Rome, Italy; <sup>4</sup> IRCCS Neuromed, Pozzilli, Italy

### SUMMARY

Vestibular neuritis (VN) is one of the most common causes of vertigo and is characterised by a sudden unilateral vestibular failure (UVF). Many neuroimaging studies in the last 10 years have focused on brain changes related to sudden vestibular deafferentation as in VN. However, most of these studies, also due to different possibilities across diverse centres, were based on different times of first acquisition from the onset of VN symptoms, neuroimaging techniques, statistical analysis and correlation with otoneurological and psychological findings. In the present review, the authors aim to merge together the similarities and discrepancies across various investigations that have employed neuroimaging techniques and group analysis with the purpose of better understanding about how the brain changes and what characteristic clinical features may relate to each other in the acute phase of VN. Six studies that strictly met inclusion criteria were analysed to assess cortical-subcortical correlates of acute clinical features related to VN. The present review clearly reveals that sudden UVF may induce a wide variety of cortical and subcortical responses – with changes in different sensory modules – as a result of acute plasticity in the central nervous system.

KEY WORDS: Vestibular neuritis • Neuroimaging • Cerebral • Group analysis • Vertigo

### RIASSUNTO

*La neuronite vestibolare (NV) rappresenta una delle cause più frequenti di vertigine ed è definita come caratterizzata da una perdita vestibolare monolaterale (UVF) improvvisa. Negli ultimi dieci anni molti studi sono stati condotti al fine di valutare il coinvolgimento cerebrale in corso di deafferentazioni vestibolari improvvise, come quelle in corso di NV. Tuttavia, la maggior parte di essi, anche per le non omogenee possibilità nei vari centri di studio, sono stati eseguiti con diverse tempistiche di acquisizione dall'insorgenza dei sintomi, molteplici tecniche di neuroimmagini, disparate analisi statistiche e correlazioni con i reperti otoneurologici e neuropsicologici. Pertanto nella presente revisione gli autori hanno avuto l'obiettivo di far emergere somiglianze e discrepanze nei lavori che hanno impiegato tecniche di neuroimmagini ed analisi statistica di gruppaggio, con l'intento di approfondire le modalità con cui i cambiamenti cerebrali correlassero con i reperti clinici durante la fase acuta di NV. A tal scopo, sei lavori – selezionati secondo i criteri di inclusione – sono stati analizzati al fine di rivelare quegli aspetti corticali e sottocorticali correlati ai corrispettivi clinici delle fasi acute nella NV. In conclusione la presente revisione mostra chiaramente come una UVF improvvisa sia in grado di generare un'ampia varietà di risposte corticali e sottocorticali – con cambiamenti in differenti moduli sensoriali – come risultato di una plasticità critica del sistema nervoso centrale.*

PAROLE CHIAVE: Neuronite vestibolare • Neuroimmagini • Cerebrale • Analisi di gruppo • Vertigine

Acta Otorhinolaryngol Ital 2016;36:75-84

### Introduction

Vestibular neuritis (VN) is one of the most common causes of vertigo <sup>1</sup>, and is defined as sudden unilateral labyrinthine failure, which is probably due to reactivation of latent herpes simplex virus 1 in the geniculate ganglion <sup>2</sup> or to other infectious diseases of the inner ear. As is known, the characteristic signs and symptoms of VN

include sudden onset of severe rotational vertigo associated with horizontal rotatory peripheral vestibular spontaneous nystagmus toward the unaffected ear, postural imbalance, nausea, vomiting, emotional disturbances and no other neurologic or cochlear symptoms and findings <sup>3</sup>. This symptomatology can be very severe in the first few days (acute VN) due to a sudden loss of environmental landmarks determining cerebral changes <sup>4</sup>.

### *Functional neuronatomy of vestibular networks*

The vestibular system is based on the principle of fusion of bilateral sensors, the input of which is distributed in a bilaterally organised neuronal network<sup>5</sup>. The core circuitry of this network includes ocular motor function that mediates the vestibular-ocular reflex (VOR) and is imbedded in a complex multisensory system containing numerous ascending and descending pathways subserving perceptual, postural and vegetative functions as well as navigation and spatial memory<sup>5</sup>. Thus, vestibular input, which is fed into the VOR structures, is also fed into adjacent but separate fibres for perception and balance control<sup>5</sup>. As ocular motor function consists of a rapid three-neuron arc (for a more comprehensive review: see reference<sup>5</sup>) ascending from both labyrinths – via the vestibular nuclei – to their corresponding pair of extraocular eye muscles (for review see reference<sup>6</sup>), perceptual functions operate via pathways that run through the lateral and ventroposterior lateral thalamus to the multisensory cortical neural network. The latter includes, in the brain of monkey, a number of temporo-parietal cortex areas such as the strongly interconnected area 2v, area 3aV and the parieto-insular vestibular cortex (PIVC), as well as retroinsular areas, superior temporal gyrus, inferior parietal lobule<sup>5 7-11</sup> (Fig. 1). At this level, metabolic studies during irrigation in right- and left-handed human volunteers have shown that the handedness of subjects and the side of the stimulation affect bilateral cortical activation pattern of vestibular areas. In fact, vestibular dominance in the non-dominant hemisphere and stronger activation occurring in the hemisphere ipsilateral to the stimulated ear were found<sup>12</sup>. Interestingly, navigation function seems to be mediated by ‘head direction cells’ in the thalamus (for review see reference<sup>13</sup>) and ‘place cells’ in the hippocampus<sup>14</sup>. Various anatomical connections have been proposed to join the vestibular nuclei to the hippocampus<sup>15 16</sup>. Using functional MRI, Vitte and co-workers<sup>17</sup> demonstrated that vestibular caloric stimulation even activates the hippocampal formation in humans.

The postural control of head and body is mediated via the descending tracts such as the medial vestibulo-spinal tract for head position and the lateral vestibulo-spinal tract for head and body position in space<sup>18</sup>. Finally, vegetative functions are conveyed by pathways from the vestibular nuclei to the locus coeruleus, nucleus of the solitary tract, area postrema and the central nucleus of the amygdale<sup>19</sup> as well as the parabrachial nucleus, infralimbic cortex and hypothalamus<sup>20 21</sup>.

Since neuroimaging protocols are available, many studies in the last 10 years have focused on the cortical and subcortical changes related to sudden vestibular deafferentation as in VN. However, most of these, also due to different possibilities across diverse centers, were based on different times of first acquisition from the onset of VN symptoms, neuroimaging techniques, statistical analysis

and correlation with otoneurological and psychological findings.

The aim of the present review is to merge the similarities and discrepancies across studies that employed neuroimaging techniques with the purpose of better understanding brain changes and characteristic clinical features during the acute phase of VN.

## **Materials and methods**

### *Study selection and inclusion/exclusion criteria*

A thorough analysis on PubMed was searched using the following key words: vestibular neuritis, unilateral vestibular failure (UVF), neuroimaging, magnetic resonance imaging (MRI), positron emission tomography (PET), near infra-red spectroscopy (NIRS), single positron emission computer tomography (SPECT), voxel-based morphometry (VBM), cerebral, cortical, sub-cortical and cerebellum. Only studies written in English were selected. Studies focusing on simultaneous cochleo-vestibular, vestibular surgical de-afferentation and/or bilateral vestibular impairment were excluded as well as those not enrolling acute VN patients and not employing voxel-based analysis. Herein, T1 will be used only to indicate acute phase of VN and T2 only for the delayed phase, even if VN subjects were only studied during the latter.

## **Results**

A preliminary examination of the existing literature highlighted that four major neuroimaging techniques have been employed in the study of acute phase of VN: [18F] fluorodeoxyglucose (FDG) - PET/computer tomography (CT)<sup>4 22 23</sup>, SPECT<sup>24</sup>, VBM<sup>25-27</sup> and functional MRI (fMRI)<sup>28 29</sup>.

According to the above-mentioned criteria, the studies by Alessandrini et al.<sup>24</sup>, Helmchen et al.<sup>26</sup> and Zu Eulenburg et al.<sup>25</sup> were excluded, and the present review included 6 studies.

Moreover, all included studies<sup>4 22 23 27-29</sup> investigated cerebral correlates of acute and delayed phase of VN and in three<sup>4 28 29</sup> acute phase images were compared to both delayed and control groups (CG).

Differences in subjects, time of acquisitions from the VN symptoms onset, neuroimaging technique, statistical analysis and contingent correlations with neuropsychological and otoneurological tests are shown in Table I.

## **Discussion**

### *Cortical correlates of acute and delayed VN phase*

#### *FDG-PET/CT imaging studies*

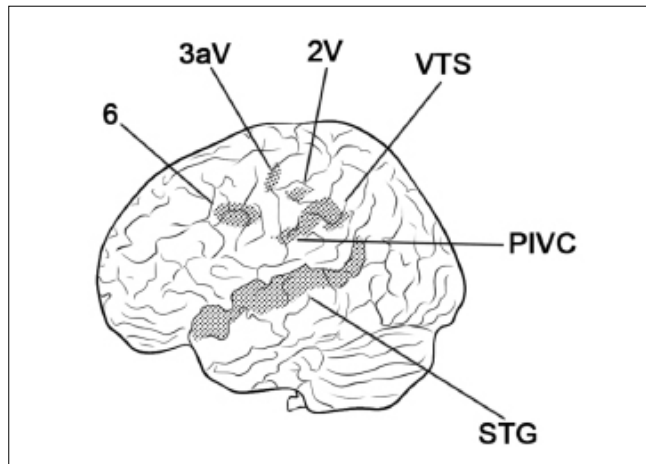
Under physiological conditions, as well as in several diseases affecting the brain, glucose metabolism is tightly connected to neuronal activity. Therefore, changes in neu-

**Table 1.** Systematic analysis of nine studies.

Study	Subjects/ Sample	Side of VN	Neuroimaging technique	T1	T2	Presence of control group	Main Oto-neurological test	Neuropsychological and clinical test	Statistical analysis/images handling	Inclusion
Bense et al. 2004	5 right-handed patients (4 male, 1 female; mean age: 64 years ± 10)	5 right VN	FDG-PET/CT	6.6 days after symptom onset	3 months after symptoms onset	None	DC-EOG, SW, caloric testing	None	SPM99	Yes
Alessandrini et al. 2009	9 right-handed patients (4 male, 5 female; mean age: 51.6 years ± 13.8)	7 left VN; 2 right VN	SPECT	72 hours after symptom onset	1 month after symptoms onset	None	ENG	None	visual evaluation by a well experienced nuclear physician	No
Helmchen et al. 2009	15 right-handed patients (8 males, 7 females; mean age: 49 ± 13.9)	4 left VN; 11 right VN	VBM	None	3 months after symptom onset	15 (8 males, 7 females; mean age: 49 ± 13.7 years)	CVS, SVDS, SW, Caloric testing, DC-EOG	SVDS	VBM toolbox for SPM2	No
Zu Eulenburg et al. 2010	22 right-handed patients (9 females, 13 males; mean age: 56.7 ± 10.4)	10 right VN, 12 left VN	VBM	None	2.5 ± 1.6 years after symptom onset	Not specified in the text	Caloric testing, DC-EOG, HIT, Underberger test, VEMPs, rotatory chair test, SW	VSS, VHQ	VBM toolbox for SPM5	No
Alessandrini et al. 2013	8 right handed patients (five females, 3 males; mean age: 48 ± 7 years)	8 right VN	FDG-PET/CT	48 ± 6 hours symptom onset	1 month after symptom onset	30 (16 female, 14 males; mean age: 49.5 ± 12 years)	DC-EOG	Zung Instrument, depersonalization/depersonalization inventory, Gomez test	SPM2	Yes
Alessandrini et al. 2014	8 right handed patients (5 females, 3 males; mean age 48 ± 7 years)	8 right VN	FDG-PET/CT	48 ± 6 hours symptom onset	1 month after symptom onset	None	DC-EOG, Bucket test	Zung Instrument, depersonalization/depersonalization inventory, Gomez test	AAL	Yes
Hong et al. 2014	9 right-handed patients (6 males, 3 females; mean age: 49.2 ± 18.1 years)	5 right VN; 4 left VN	VBM	72 hours after symptom onset	3 months after symptom onset	None	VNG, Caloric testing, rotatory chair test	K-DHI	VBM toolbox for SPM8	Yes
Helmchen et al. 2013	20 right-handed patients (11 males, 9 females; mean age: 55.1 ± 13.9)	10 right VN; 10 left VN	fMRI	72 hours after symptom onset	96.6 ± 24 days after symptom onset	20 (11 males, 9 females; mean age: 50.2 ± 11.7 years)	DC-EOG, Caloric testing, SW, HIT, static posturography	CVS, SVDS, VADL	SPM8, ICA	Yes
Klingner et al. 2014	14 right-handed patients (6 females, 8 males; mean age: 51.1 ± 10.4 years)	7 right VN, 7 left VN	fMRI	4.9 ± 1.9 days after symptom onset	12 ± 4.6 months after symptom onset	28 age and gender matched controls (12 females, 16 males)	VNG, Caloric testing, Saccadic eye movements, smooth pursuit, optokinetic nystagmus, gaze test	None	SPM8, ICA	Yes

VN, vestibular neuritis; T1, acute phase of VN; T2, delayed phase of VN; FDG-PET/CT, [<sup>18</sup>F] fluorodeoxyglucose – positron emission tomography/computer tomography; SPECT, single positron emission computer tomography; VBM, voxel-based morphometry; fMRI, functional magnetic resonance imaging; DC-EOG, binocular electrooculography; SW, subjective visual vertical; ENG, electronystagmography; CVS, clinical vestibular score; SVDS, subjective vestibular disability score; HIT, head impulse test; VEMPs, vestibular evoked myogenic potentials; VSS, vertigo severity score; VHQ, vertigo handicap questionnaire; K-DHI, Korean version of the dizziness handicap inventory; VNG, videonystagmography; SVDS, self-assessment of vestibular disability; VADL, self-assessment of vestibular disability in daily life; SPM, statistical parametric mapping; AAL, automated anatomical labelling, ICA, independent component analysis.





**Fig. 1.** Schematic drawing of a monkey brain with the neuro-physiologically determined multisensory vestibular areas. PIVC, parieto-insular vestibular cortex; STG, superior temporal gyrus; VTS, visual temporal sylvian area.

ronal activity induced by disease are reflected in alteration of glucose metabolism. FDG is suitable for imaging regional cerebral glucose consumption with PET since it accumulates in brain tissue depending on facilitated transport of glucose and hexokinase-mediated phosphorylation<sup>30</sup>.

In agreement with this assumption, the study of Bense and colleagues<sup>22</sup> on the acute and delayed phases of VN showed that 6 days after onset of VN symptoms unilateral regional cerebral glucose metabolism (rCGM) increases in the left PIVC, contralateral to right-sided vestibular failure. This asymmetry could be explained by assuming that the more dominant ipsilateral right-sided ascending projections to the right insular cortex are depressed by right-sided vestibular neuritis, since there is no tonic endorgan input (decreased resting discharge)<sup>22</sup>. Alternatively, the vestibular tonic imbalance at the vestibular nuclei level (with a higher resting discharge rate of the unaffected left vestibular nuclei complex induced by the acute right-sided vestibular failure) could mimic left-sided vestibular excitation<sup>22</sup>. This supposition is compatible with an activation of pontine and pontomesencephalic brainstem and left vestibular cortex areas, as well as the concurrent deactivation of the visual and somatosensory cortex areas<sup>22</sup>. Conversely, a bilateral rCGM decrease was found during the acute stage of VN in “secondary” multisensory vestibular cortex areas (i.e. superior temporal gyrus, inferior parietal lobule, and precuneus), appointing this metabolic pattern to cortical mechanisms that restore adequate spatial orientation by using the undisturbed visual and somatosensory input<sup>22</sup>. Furthermore, a bilateral rCGM decrease in visual cortex was seen, possibly indicating an effort to reduce sensory conflicts induced by nystagmic movement and a “false” primary vestibular signal<sup>22</sup> (Figs. 2 and 3).

Finally, some parts of “secondary” vestibular cortex ar-

reas appear to be involved in special aspects of vestibular function. In fact, the amount of spontaneous nystagmus during the acute stage of vestibular neuritis correlated positively with the increase of glucose metabolism in part of the vestibular area of the superior temporal gyrus bilaterally (Brodmann Area, BA, 22), as well as in part of an ocular motor area in the right inferior medial frontal gyrus (BA 9/44) that includes the frontal eye field<sup>22</sup>. The index of vestibular failure, measured as the caloric asymmetry between the affected and unaffected ears, was positively correlated with the rCGM in an area in the left inferior parietal lobule (BA 40) known to represent a multisensory vestibular cortex area involved in modulating the gain and time constant of the vestibular ocular reflex<sup>31</sup> (Figs. 2 and 3).

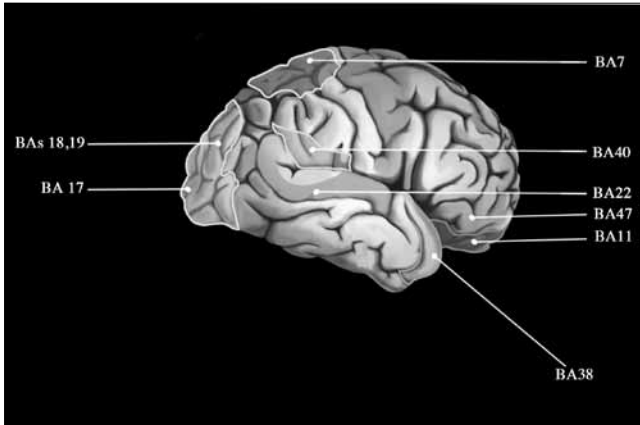
These findings were partially confirmed by another study by Alessandrini and colleagues<sup>4</sup> in which eight right-sided VN patients underwent FDG-PET/CT scan about 48 hours after onset of symptoms. However, rCGM increase in posterior insula was shown only when comparing acute VN subjects with the control group (Figs. 2 and 3).

In both studies, all patients suffered only from right-sided VN; images were realigned, stereotactically normalised into the standard anatomical space of Talairach and Tournoux<sup>32</sup> by linear and nonlinear transformation<sup>33</sup> and smoothed with a three-dimensional Gaussian filter using a 12 mm full-width at half-maximum kernel<sup>4,22</sup>. Thus, coordinates of some regions tend to mainly collimate with minimal differences in anatomical identification as for left posterior insula and right BA 11 (for in-depth analysis see the table in<sup>4</sup> and Tables I and II in<sup>22</sup>).

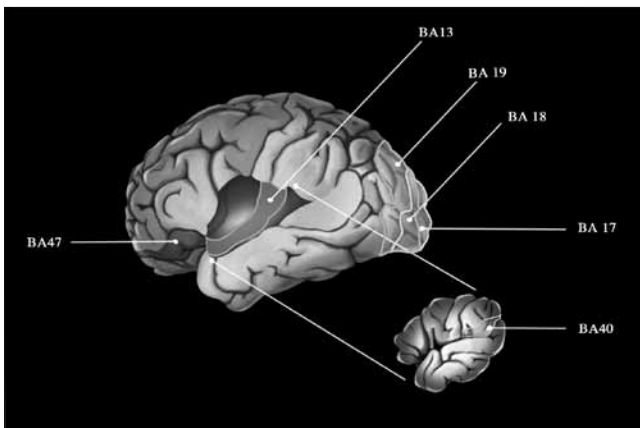
Moreover, the within-subject comparison between T1 and T2 in the study by Alessandrini et al.<sup>4</sup> highlighted for the first time a rCGM increase in the entorhinal cortex (EC; BAs 28/34; Fig. 4) and in the superior temporal gyrus (BA 38) (data also confirmed when contrasting VN subjects with CG) (Fig. 2).

In particular, the authors hypothesised that the EC activation could be ascribed to the physiological role of this region in attempting to reorganise one’s orientation in space, as a response to the unexpected vestibular information alteration impairing one’s orientation in space. This finding seems to be more relevant if coupled with parallel subjective balance impairments score behaviour (see Fig. 3 in reference<sup>4</sup>) at the early phase of vertigo.

In addition, the T1-related rCGM increase in BA38 found in VN patients (Fig. 2) was suggested as a characteristic feature of the early phase of VN that disappears as the acute symptoms fade away. Thus, it was hypothesised that this activation is the cortical representation of the common clinical emotional component related to symptoms of vertigo, supporting this with a parallel increase in the anxiety and depersonalisation/derealisation (DD) during vertigo onset. In agreement with this, the activation of BA38 was found only on the right side aligning with the



**Fig. 2.** 3D rendering of the brain (right hemisphere) showing, respectively, in red boundary line and orange areas the rCGM increase and decrease in T1 vs. T2 in Bense et al. <sup>22</sup>; in blue areas and yellow boundary lines the rCGM increase and decrease in T1 vs. T2 in Alessandrini et al. <sup>4</sup>; in green boundary line and violet area the rCGM increase and decrease in T1 vs. CG in Alessandrini et al. <sup>4</sup>. BA(s), Brodmann area(s).



**Fig. 3.** 3D rendering of the brain (left hemisphere) showing, respectively, in red and orange areas the rCGM increase and decrease in T1 vs. T2 in Bense et al. <sup>22</sup>; in yellow boundary lines the rCGM decrease in T1 vs. T2 in Alessandrini et al. <sup>4</sup>; in green and violet boundary lines the rCGM increase and decrease in T1 vs. CG in Alessandrini et al. <sup>4</sup>. BA(s), Brodmann area(s).

emotional asymmetry theory positing that the right hemisphere may be dominant over the left one in emotional processing <sup>34 35</sup>.

Finally, the authors addressed the positive correlation (see Fig. 4A in the original text) between the hypermetabolism at T1 and the DD score in the cluster comprising the BAs 28/34, BA 38 and inferior-frontal cortices (BAs 11, 25 and 47) as an increase in the perception of depersonalisation symptoms during disease onset. Conversely, the negative correlation (see Fig. 4B in the text) found between DD, balance and anxiety and hypometabolism at T1 suggested that a freezing in the metabolism of visual (BAs 17, 18, 19) and somatosensory (BAs 5, 7) associa-

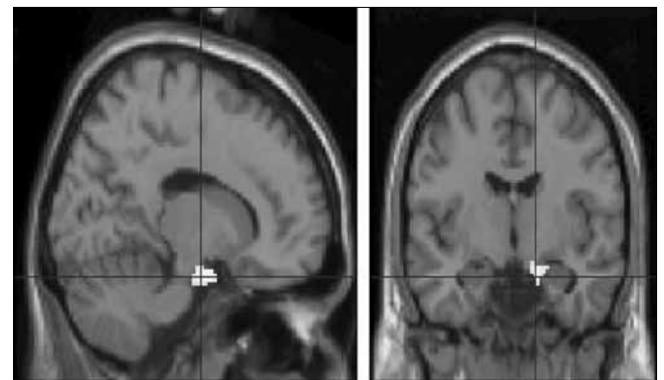
tive cortices could represent an early attempt to reduce the distressing “false” primary vestibular signal <sup>22</sup>, which may be at the neural base of the increase in DD, balance and anxiety scores during disease onset.

Differences in cortical areas and laterality could be probably explained by discrepancies in the acute and delayed time of scanning phases. In fact, first and second acquisitions were set, respectively, at 6.6 days and 3 months in the study by Bense et al. <sup>22</sup> and 48 hours and one month in that by Alessandrini et al. <sup>4</sup>. Furthermore, the different choices in scanning phases gave researchers the chance to: i) better study those brain regions involved in recovery network due to the choice of deferring, in the first study, T2 phase 3 months after symptoms onset and ii) to understand, in the second protocol, those early metabolic changes involved in anxiety processing and body orientation rearrangement by anticipating T1 phase 48 hours after VN onset.

#### *Voxel-based morphometry imaging studies*

VBM is an automated technique that uses statistics to identify differences in brain anatomy between groups of subjects, which in turn can be used to infer the presence of atrophy or, less commonly, tissue expansion in subjects with disease <sup>36</sup>. The technique has been applied to a number of different disorders, including neurodegenerative diseases <sup>37</sup>, movement disorders <sup>38</sup>, epilepsy <sup>39</sup>, multiple sclerosis <sup>40</sup> and schizophrenia <sup>41</sup>, contributing to the understanding of how the brain changes in these disorders and how brain changes relate to characteristic clinical features <sup>36</sup>.

When focusing on VN-related VBM in the study by Hong et al. <sup>27</sup>, a preliminary review (see Table I) highlighted non-homogeneous laterality of included vestibular lesions. In fact, with respect to FDG-PET/CT studies, they did not recruit patients with the same side of VN. Thus, brain imaging data from patients with different lesion



**Fig. 4.** T1 MRI superimposition showing the cluster of voxels in the right parahippocampal gyrus (BAs 34 and 28) in which FDG uptake was significantly higher at T1 compared to T2 (on the left sagittal and on the right coronal projections) (illustration taken from artwork in <sup>4</sup>).



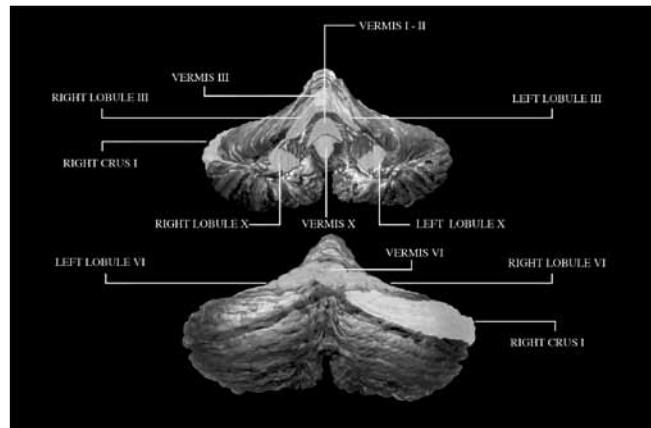
sides were collapsed, in contrast with most previous VBM studies that artificially equalised the lesion side by flipping brain images of patients with lesions on the opposite side (e.g., flipping images of left VN patients to simulate right VN)<sup>26,42,43</sup>. Moreover, nine right-handed VN subjects were studied in T1 and T2 phase and the within-subject model found a significant decrease in grey matter volume (GMV) in the right superior medial gyrus, right middle orbital gyrus, cerebellar vermis and right cerebellar hemisphere in T1 compared to T2 (see Table II in the original text). However, authors focused their discussion on GMV increase related to processes involved in vestibular compensation (T2) rather than in cortical atrophy found in these regions during the acute stage. This aspect may be in line with the employed technique, which is more useful in visualising brain volume changes over the time rather than in the acute stage of disease when a paucity of cortical hypertrophy/atrophy is found.

#### *Sub-cortical structure involvement related to the early phase of VN*

Alessandrini et al.<sup>23</sup> used the same VN patients of a previous study<sup>4</sup> to provide an exclusive cerebellar analysis of FDG uptake changes comparing T1 and T2, by using anatomical automatic labelling (AAL) structural volumes of interest (VOIs). The authors attempted to correlate these findings with those at the cortical level due to cerebellar involvement in different cerebro-cerebellar loops previously highlighted<sup>44</sup>.

In particular, a relative hypometabolism in the early phase of VN in anterior cerebellar lobe was found, including vermis 1-2, 3 and 6, and bilateral lobule III and VI (Fig. 5). These findings were postulated to be consistent with a cortical rCGM decrease in bilateral sensory-motor and parietal cortices, suggesting the relative rCGM decrease in the anterior cerebellar lobe is associated with such hypometabolism<sup>4</sup>. In addition, the hypometabolism seen in the anterior cerebellar lobe was hypothesised to support a bottom-up regulation of sensory conflict during controversial inflow between optical and vestibular input, as it occurs during the early phases of VN<sup>23</sup>. Thus, such a behaviour was interpreted by the authors as a realignment of the relationship between sensory inputs<sup>45</sup> such as those coming from optical<sup>46</sup>, proprioceptive<sup>47,48</sup> and vestibular<sup>49</sup> organs and cerebellum<sup>50</sup> via olivary climbing fibers<sup>51</sup> that could convey an erroneous signal arising from mismatch between mentioned sensory inflow.

Moreover, the study by Alessandrini et al.<sup>23</sup> highlighted a relative hypometabolism in the nodulus and flocculus at T1 compared to T2, suggesting a primary adaptive behaviour of these regions in response to abrupt conflicting inputs conveyed by retinal slip and vestibular loss in the early phase of VN. Curiously, the negative correlation found between metabolism in the right lobule 10 and slow phase velocity (SPV) scores highlighted a specific pivotal



**Fig. 5.** 3D rendering of cerebellum showing in orange and green colours the VOIs in which FDG uptake was significantly lower and higher, respectively, at T1 compared to T2. On the top the ventral; on the bottom the dorsal cerebellar surface (illustration modified from artwork in<sup>23</sup>).

role of the flocculus in modulating and controlling nystagmus parameters and in adapting VOR by mediating the functional interaction between vestibular inputs and the eye movement network<sup>52</sup>.

Finally, the study found a significant rCGM increase when comparing T1 to T2 in right crus I and a significant positive correlation between the metabolism found in this structure at VN onset and anxiety score (see Table I and Figs. 2 and 3 in the text of<sup>23</sup>). These data, along with anxiety/rCGM correlation findings in crus I, were interpreted to add information regarding the function of this region during the acute phase of VN and in subserving cortical emotional processing affecting the early stages of disease<sup>23</sup>.

Hong et al. found a T1-related GMV increase (a relative T2-related GMV decrease) in cerebellar vermis and right Lobule VIIIa<sup>27</sup>. In line with the discussion topic of their longitudinal work (see chapter 1.2 in the text above), the authors explained the former finding as the consequence of a dominance of afferent input in the cerebellar vermis (GM atrophy following loss of peripheral sensory input), which could be underpinned by those cortico-cerebellar loop previously mentioned. The latter finding was found to be related over time with a decrease in nystagmus after impulse acceleration and deceleration; GM atrophy in this area was also associated with better recovery of peripheral vestibular sense<sup>27</sup>. However, although speculative, authors highlighted this area functions to subserve the earliest stages of VN, and hypothesised that as peripheral vestibular function recovers, the functional contribution from this area may decrease and, subsequently, decrease GMV.

Finally, these data could be not completely conflicting as it was chosen to investigate patients in different T2 moments with a more strengthened rehabilitation protocol in

Hong et al. and by using different methods of scanning and data and imaging handling.

#### *Functional connectivity in VN*

It has been shown that brain networks known to support visual, motor, attentional, or cognitive functions show spontaneous<sup>53</sup> and anticorrelated fluctuations<sup>54</sup> even without a specific task. In fact, large-amplitude spontaneous low-frequency (0.1 Hz) fluctuations in blood-oxygen-level dependent (BOLD) signal, investigated by fMRI, are temporally correlated across functionally related areas<sup>55</sup>. By using these methods, many authors have attempted to identify changes in functional connectivity within neural networks<sup>56,57</sup> with the basic idea that spontaneous fluctuations in brain activity during rest reflect the interconnectivity of brain areas necessary to accommodate highly diverse processing demands. Indeed, using resting state analysis it has been shown that the brain is organised into “dynamic, anticorrelated functional networks”<sup>54</sup>.

According to these aspects, Helmchen and colleagues<sup>28</sup> evaluated the BOLD signal changes in 20 right-handed VN patients with acute VN at T1 (within 3 days from symptom onset) and 3 months later (T2). In addition, they compared T1 brain images both with T2 phase and an age- and sex-matched CG. For patients with right peripheral vestibular failure, the smoothed images were mirrored along the y axis so that the left side was the lesion side for all patients. They performed two statistical analyses, an independent component analysis (ICA) and a region-of-interest analysis based on the local-to-global ratio. A similar fMRI approach was recently adopted by Klingner et al.<sup>28</sup> in order to discover the inter-network functional connectivity changes in 14 patients during the early (mean:  $4.9 \pm 1.9$  days after onset of symptoms) and delayed (mean:  $12 \pm 4.6$  months) phase of VN.

In the former study, one component (“component 50”) showed significant between-group changes in resting-state activity at T1. This component revealed a functional network of the parietal lobe, medial aspect of the superior parietal lobule, posterior cingulate cortex, middle frontal gyrus, middle temporal gyrus, parahippocampal gyrus, anterior cingulate cortex, insular cortex, caudate nucleus, thalamus and midbrain. VN patients at T1 showed decreased resting-state activity in the contralateral intraparietal sulcus (IPS) in close vicinity to the rostro-dorsal aspect of the IPL, i.e. the supramarginal gyrus (SMG), compared with CG. When the two measurements of the patients were compared, a change in resting-state activity in the same region became apparent indicating normalisation of resting-state activity in patients over time.

While the network revealed by component 50 in that study likely supports multiple functions, it is interesting to note that several of the implied areas have been shown to process vestibular signals (see review in<sup>5</sup>). Within this neural network, significant differences between patients

and controls were found in IPS contralateral to the vestibular lesion.

The IPS<sup>58</sup> extends ventrally to the parietal operculum, including the parietal opercular area OP2, which has recently been identified as the core region for vestibular processing in humans<sup>59</sup>, and therefore suggested to be the human equivalent to the PIVC previously described in monkey<sup>60</sup>. This findings – and subsequent seed-based functional connectivity analysis based on resting-state oscillations<sup>59</sup> – led some authors to suggest that the IPL is a cortical multisensory integration area<sup>59</sup>.

Moreover, in VN patients of this study the IPS coordinates of reduced resting-state activity overlapped with the ventral intraparietal area (VIP) contained in its fundus, the neuronal responses of which are more strongly influenced by vestibular than visual inputs<sup>61</sup> and are strongly linked to heading, which make them well equipped to play a role in multisensory integration for heading perception<sup>62</sup>.

In addition, effective connectivity analysis has shown a role of the IPS for memory retrieval<sup>63</sup>. The SMG along the IPS, which also showed changes of resting-state activity in patients in that study, is critical for mediating spatial working memory and shifts in spatial attention<sup>64</sup>. This is of interest as the IPS is linked to the hippocampal formation<sup>65</sup>, and reduced resting-state activity in IPS might also influence hippocampal and parahippocampal function. Thus, it was speculated that reduced vestibular input<sup>66</sup> leads to changes of resting-state activity in IPS, which in turn may trigger adaptive hippocampal reorganisation and impairment in navigational and spatial orientation tasks.

However, VN patients might suffer from impaired spatial navigation which has been shown for bilateral<sup>67</sup>, but not unilateral nor surgical vestibular nerve deafferentation<sup>68</sup>. Furthermore, lesion studies in humans have provided evidence for a cortical influence on vestibular function in the context of spatial representation<sup>31</sup>. In line with these studies and findings from PET and neuropsychological investigations<sup>4,69</sup>, one might speculate that the reduction of resting-state activity in the IPS and adjacent SMG in the acute stage of VN patients could be related to impaired spatial orientation, i.e. by deficient spatial working memory or spatial attention<sup>64</sup>.

In the latter study, Klingner et al.<sup>29</sup> found decreased inter-network connectivity in T1 compared to T2 (after complete clinical remission of symptoms) between the “default mode” network (DMN) and multiple other networks such as the somatosensory cortex, auditory/vestibular/insular cortex, motor cortex, occipital cortex and left and right fronto-parietal cortex (FPC). By comparing the first measurement in T1 with the group of healthy control subjects, the same areas (except the occipital cortex) showed decreased connectedness to the DMN (Fig. 1 in the original text). It is generally agreed that the brain is composed of two spatially distinct functional networks: the DMN and “task-positive” network

(TPN)<sup>54 70 71</sup>. During performance of attention-demanding tasks, prefrontal and parietal structures that comprise the task-positive network are characterised by increased activity; in contrast, the DMN, including the posterior cingulate and medial prefrontal cortices, is characterised by decreased activity. During wakeful rest, the opposite pattern emerges<sup>54 70-72</sup>.

The reduced connectivity between these two networks was suggested to be related to the diverging information arising in the resting condition from vestibular, spontaneous eye movements and other sensory modalities<sup>29</sup>. The attempt to integrate this conflicting information requires significantly greater capacity for the processing information about spatial orientation and brings sensory information processing to our attention, which is normally an automated process that does not require attentional demand<sup>29</sup>. These mechanisms are reflected by increased activity within brain areas responsible for processing of vestibular information and integration of multisensory information<sup>22</sup>. The sustained increased activity in parts of the TPN and the attentional demand reduce the activity within the DMN. In turn, the DMN compensates by decreasing the amount of information that is received from the task positive network, leading to decreased connectiveness<sup>29</sup>. Furthermore, the involvement of the DMN in this pathology is further supported by findings of difficulties with cognitive skills such as reading, arithmetic and concentration suggesting a decreased ability to engage the task positive networks<sup>73</sup>.

#### Final overview

The vestibulo-cortical system, which includes the PIVC activated by vestibular stimulation, is composed of multisensory cortical networks connected with other cortical and subcortical processing areas, including oculomotor, somatosensory, visual areas and cerebellar sub-regions.

The present review clearly reveals that sudden UVF may induce a wide variety of cortical intersensory responses, with changes in different, sensory modules as a result of acute plasticity in the central nervous system.

Interestingly, during the acute phase of disease perfusion-al and metabolic studies demonstrated such rCGM changes in the so-called “vestibular cortex”, decreased resting-state activity in the contralateral IPS – close to the human equivalent of PIVC – and a decreased inter-network connectivity between the DMN and multiple other networks. Simultaneously, a neural cascade of acute plasticity related events was found in the visual and multisensory cortex as well as in those areas (entorhinal, SMG) involved in spatial navigation.

Overall, findings from imaging and neuropsychological studies can disclose two side of the same coin for which the acute dissociation of sensory inflow was pinpointed, highlighting phenomena of emotional and orientation impairment.

Finally, we hope the present review can serve as a framework of the intricate puzzle represented by multi-scale brain changes involved in the acute phases of VN and can provide additional considerations for future acute VN studies.

## Acknowledgements

The authors express sincere thanks to MichelAngela Studio for skillful and creative preparation of illustrations.

## References

- Chihara Y, Iwasaki S, Murofushi T, et al. *Clinical characteristics of inferior vestibular neuritis*. Acta Otolaryngol 2012;132:1288-94.
- Strupp M, Brandt T. *Peripheral vestibular disorders*. Curr Opin Neurol 2013;26:81-9.
- Alessandrini M, D’Erme G, Bruno E, et al. *Vestibular compensation: analysis of postural re-arrangement as a control index for unilateral vestibular deficit*. Neuroreport 2003;14:1075-9.
- Alessandrini M, Pagani M, Napolitano B, et al. *Early and phasic cortical metabolic changes in vestibular neuritis onset*. PLoS ONE 2013;8:e57596.
- Dieterich M, Brandt T. *Functional brain imaging of peripheral and central vestibular disorders*. Brain 2008;131:2538-52.
- Leigh RJ, Zee DS. *The neurology of eye movements*. Fourth edition. New York: Oxford University Press; 2006.
- Guldin WO, Grüsser OJ. *The anatomy of the vestibular cortices of primates*. In: Collard M, Jeannerod M, Christen Y, eds. *Le cortex vestibulaire*. Paris: Ipsen; 1996. p. 17.
- Klam F, Graf W. *Vestibular response kinematics in posterior parietal cortex neurons of macaque monkeys*. Eur J Neurosci 2003;18:995-1010.
- Klam F, Graf W. *Vestibular signals of posterior parietal cortex neurons during active and passive head movements in macaque monkeys*. Ann NY Acad Sci 2003;1004:271-82.
- Hegemann S, Fitzek S, Fitzek C, et al. *Cortical vestibular representation in the superior temporal gyrus*. J Vestib Res 2004;14:33-5.
- Lackner JR, DiZio P. *Vestibular, proprioceptive, and haptic contributions to spatial integration*. Annu Rev Psychol 2005;56:115-47.
- Dieterich M, Bense S, Lutz S, et al. *Dominance for vestibular cortical function in the non-dominant hemisphere*. Cereb Cortex 2003;13:994-1007.
- Taube JS, Goodridge JP, Golob EJ, et al. *Processing the head direction signal: a review and commentary*. Brain Res Bull 1996;40:477-86.
- Wiener SI, Korshunov VA, Garcia R, et al. *Interial, sub-stratal and landmark cue control of hippocampal CA1 place cell activity*. Eur J Neurosci 1995;7:2206-19.
- Smith PF. *Vestibular-hippocampal interactions*. Hippocampus 1997;7:465-71.
- Horii A, Russell NA, Smith PF, et al. *Vestibular influences on*



- CA1 neurons in the rat hippocampus: an electrophysiological study in vivo. *Exp Brain Res* 2004;155:245-50.
- 17 Vitte E, Derosier C, Caritu Y, et al. *Activation of the hippocampal formation by vestibular stimulation: a functional magnetic resonance imaging study.* *Exp Brain Res* 1996;112:523-6.
  - 18 Nathan PW, Smith M, Deacon P. *Vestibulospinal, reticulospinal and descending propriospinal nerve fibres in man.* *Brain* 1996;119:1809-33.
  - 19 Pompeiano O, d'Ascanio P, Centini C, et al. *Gene expression in rat vestibular and reticular structures during and after space flight.* *Neuroscience* 2002;114:135-55.
  - 20 Balaban CD. *Projections from the parabrachial nucleus to the vestibular nuclei: potential substrates for autonomic and limbic influences on vestibular responses.* *Brain Res* 2004;996:126-37.
  - 21 Balaban CD, Thayer JF. *Neurological bases for balance-anxiety links.* *J Anxiety Disord* 2001;15:53-79.
  - 22 Bense S, Bartenstein P, Lochmann M, et al. *Metabolic changes in vestibular and visual cortices in acute vestibular neuritis.* *Ann Neurol* 2004;56:624-30.
  - 23 Alessandrini M, Micarelli A, Chiaravalloti A, et al. *Cerebellar metabolic involvement and its correlations with clinical parameters in vestibular neuritis.* *J Neurol* 2014;261:1976-85.
  - 24 Alessandrini M, Napolitano B, Bruno E, et al. *Cerebral plasticity in acute vestibular deficit.* *Eur Arch Otorhinolaryngol* 2009;266:1547-51.
  - 25 zu Eulenburg P, Stoeter P, Dieterich M. *Voxel-based morphology depicts central compensation after vestibular neuritis.* *Ann Neurol* 2010;68:241-9.
  - 26 Helmchen C, Klinkenstein J, Machner B, et al. *Structural changes in the human brain following vestibular neuritis indicate central vestibular compensation.* *Ann NY Acad Sci* 2009;1164:104-15.
  - 27 Hong SK, Kim JH, Kim HJ, et al. *Changes in the gray matter volume during compensation after vestibular neuritis: a longitudinal VBM study.* *Restor Neurol Neurosci* 2014;32:663-73.
  - 28 Helmchen C, Ye Z, Sprenger A, et al. *Changes in resting-state fMRI in vestibular neuritis.* *Brain Struct Funct* 2014;219:1889-900.
  - 29 Klingner CM, Volk GF, Brodoehl S, et al. *Disrupted functional connectivity of the default mode network due to acute vestibular deficit.* *Neuroimage Clin* 2011;6:109-14.
  - 30 Varrone A, Asenbaum S, Vander Borgh T, et al. *EANM procedure guidelines for PET brain imaging using [18F]FDG, version 2.* *Eur J Nucl Med Mol Imaging* 2009;361:2103-10.
  - 31 Ventre-Dominey J, Nighoghossian N, Denise P. *Evidence for interacting cortical control of vestibular function and spatial representation in man.* *Neuropsychologia* 2003;41:1884-98.
  - 32 Talairach J, Tournoux P. *Co-planar stereotaxic atlas of the human brain.* New York: Georg Thieme Verlag; 1988.
  - 33 Friston KJ, Ashburner J, Frith CD, et al. *Spatial registration and normalization of images.* *Hum Brain Mapp* 1995;2:165-89.
  - 34 Davidson RJ. *Affective style and affective disorders: perspectives from affective neuroscience.* *Cogn Emot* 1998;12:307-330.
  - 35 Cope LM, Schaich Borg J, et al. *Hemispheric asymmetries during processing of immoral stimuli.* *Front Evol Neurosci* 2010;2:110.
  - 36 Whitwell JL. *Voxel-based morphometry: an automated technique for assessing structural changes in the brain.* *J Neurosci* 2009;29:9661-4.
  - 37 WhitwellJL, Jack CR Jr. *Comparisons between Alzheimer disease, frontotemporal lobar degeneration, and normal aging with brain mapping.* *Top Magn Reson Imaging* 2005;16:409-25.
  - 38 Whitwell JL, Josephs KA. *Voxel-based morphometry and its application to movement disorders.* *Parkinsonism Relat Disord* 2007;3:S406-16.
  - 39 Keller SS, Roberts N. *Voxel-based morphometry of temporal lobe epilepsy: an introduction and review of the literature.* *Epilepsia* 2008;49:741-57.
  - 40 Prinster A, Quarantelli M, Orefice G, et al. *Grey matter loss in relapsing-remitting multiple sclerosis: a voxel-based morphometry study.* *Neuroimage* 2006;29:859-67.
  - 41 Williams LM. *Voxel-based morphometry in schizophrenia: implications for neurodevelopmental connectivity models, cognition and affect.* *Expert Rev Neurother* 2008;8:1049-65.
  - 42 Helmchen C, Klinkenstein JC, Kruger A, et al. *Structural brain changes following peripheral vestibulo-cochlear lesion may indicate multisensory compensation.* *J Neurol Neurosurg Psychiatry* 2011;82:309-16.
  - 43 Hüfner K, Stephan T, Hamilton DA, et al. *Gray-matter atrophy after chronic complete unilateral vestibular deafferentation.* *Ann NY Acad Sci* 2009;1164:383-5.
  - 44 Stoodley CJ, Valera EM, Schmahmann JD. *Functional topography of the cerebellum for motor and cognitive tasks: an fMRI study.* *Neuroimage* 2012;59:1560-70.
  - 45 Martin TA, Keating JG, Goodkin HP, et al. *Throwing while looking through prisms. II. Specificity and storage of multiple gaze-throw calibrations.* *Brain* 1996;119:1199-211.
  - 46 Glickstein M. *How are visual areas of the brain connected to motor areas for the sensory guidance of movement?* *Trends Neurosci* 2000;23:613-7.
  - 47 Bauswein E, Kolb FP, Leimbeck B, et al. *Simple and complex spike activity of cerebellar Purkinje cells during active and passive movements in the awake monkey.* *J Physiol* 1983;339:379-94.
  - 48 Donga R, Dessem D. *An unrelayed projection of jaw-muscle spindle afferents to the cerebellum.* *Brain Res* 1993;626:347-50.
  - 49 Angelaki DE, Cullen KE. *Vestibular system: the many facets of a multimodal sense.* *Annu Rev Neurosci* 2008;31:125-50.
  - 50 Wolpert DM, Miall RC, Kawato M. *Internal models in the cerebellum.* *Trends Cogn Sci* 1998;2:338-47.
  - 51 Ito M. *Cerebellar long-term depression: characterization, signal transduction, and functional roles.* *Physiol Rev* 2001;81:1143-95.
  - 52 Voogd J, Barmack NH. *Oculomotor cerebellum.* *Prog Brain Res* 2006;151:231-68.
  - 53 Marx E, Stephan T, Nolte A, et al. *Eye closure in darkness animates sensory systems.* *Neuroimage* 2003;19:924-34.

- <sup>54</sup> Fox MD, Snyder AZ, Vincent JL, et al. *The human brain is intrinsically organized into dynamic, anticorrelated functional networks*. Proc Natl Acad Sci USA 2005;102:9673-8.
- <sup>55</sup> Biswal BB, Mennes M, Zuo XN et al. *Toward discovery science of human brain function*. Proc Natl Acad Sci USA 2010;107:4734-9.
- <sup>56</sup> Beckmann CF, DeLuca M, Devlin JT, et al. *Investigations into resting-state connectivity using independent component analysis*. Philos Trans R Soc Lond B Biol Sci 2005;360:1001-13.
- <sup>57</sup> Mohammadi B, Kollwe K, Samii A, et al. *Changes in resting-state brain networks in writer's cramp*. Hum Brain Mapp 2012;33:840-8.
- <sup>58</sup> Bremmer F, Klam F, Duhamel JR, et al. *Visual-vestibular interactive responses in the macaque ventral intraparietal area (VIP)*. Eur J Neurosci 2002;16:1569-86.
- <sup>59</sup> Zu Eulenburg P, Caspers S, Roski C, et al. *Meta-analytical definition and functional connectivity of the human vestibular cortex*. Neuroimage 2011;60:162-9.
- <sup>60</sup> Grusser OJ, Pause M, Schreiter U. *Vestibular neurones in the parieto-insular cortex of monkeys (Macaca fascicularis): visual and neck receptor responses*. J Physiol 1990;430:559-83.
- <sup>61</sup> Gu Y, Angelaki DE, Deangelis GC. *Neural correlates of multisensory cue integration in macaque MSTd*. Nat Neurosci 2008;11:1201-10.
- <sup>62</sup> Chen A, Deangelis GC, Angelaki DE. *Functional specializations of the ventral intraparietal area for multisensory heading discrimination*. J Neurosci Off J Soc Neurosci 2013;33:3567-81.
- <sup>63</sup> Miyamoto K, Osada T, Adachi Y, et al. *Functional differentiation of memory retrieval network in macaque posterior parietal cortex*. Neuron 2013;77:787-99.
- <sup>64</sup> Silk TJ, Bellgrove MA, Wrafter P, et al. *Spatial working memory and spatial attention rely on common neural processes in the intraparietal sulcus*. Neuroimage 2010;53:718-24.
- <sup>65</sup> Ding SL, Van Hoesen G, Rockland KS. *Inferior parietal lobule projections to the presubiculum and neighboring ventromedial temporal cortical areas*. J Comp Neurol 2000;425:510-30.
- <sup>66</sup> Hübner K, Strupp M, Smith P, et al. *Spatial separation of visual and vestibular processing in the human hippocampal formation*. Ann N Y Acad Sci 2011;1233:177-86.
- <sup>67</sup> Brandt T, Schautzer F, Hamilton DA, et al. *Vestibular loss causes hippocampal atrophy and impaired spatial memory in humans*. Brain 2005;128:2732-41.
- <sup>68</sup> Hübner K, Hamilton DA, Kalla R, et al. *Spatial memory and hippocampal volume in humans with unilateral vestibular deafferentation*. Hippocampus 2007;17:471-85.
- <sup>69</sup> Candidi M, Micarelli A, Viziano A, et al. *Impaired mental rotation in benign paroxysmal positional vertigo and acute vestibular neuritis*. Front Hum Neurosci 2013;7:783.
- <sup>70</sup> Micarelli A, Jacobsson H, Larsson SA, et al. *Neurobiological insight into hyperbaric hyperoxia*. Acta Physiol 2013;209:69-76.
- <sup>71</sup> Alessandrini M, Micarelli A, Chiaravalloti A, et al. *Cortico-subcortical metabolic correlates of olfactory processing in healthy resting subjects*. Sci Rep 2014;4:5146.
- <sup>72</sup> Fox MD, Zhang D, Snyder AZ, et al. *The global signal and observed anticorrelated resting state brain networks*. J Neurophysiol 2009;101:3270-83.
- <sup>73</sup> Hanes DA, McCollum G. *Cognitive-vestibular interactions: a review of patient difficulties and possible mechanisms*. J Vestib Res 2006;16:75-91.

Received: March 14, 2015 - Accepted: July 25, 2015



HEAD AND NECK

# Intraoperative radiation therapy as adjuvant treatment in locally advanced stage tumours involving the middle ear: a hypothesis-generating retrospective study

## *Radioterapia intraoperatoria nei tumori maligni avanzati estesi all'orecchio medio: valutazione da uno studio retrospettivo*

G. CRISTALLI<sup>1</sup>, G. MERCANTE<sup>1</sup>, L. MARUCCI<sup>2</sup>, A. SORIANI<sup>3</sup>, S. TELERA<sup>4</sup>, G. SPRIANO<sup>1</sup>

<sup>1</sup> Department of Otolaryngology Head and Neck Surgery, Regina Elena National Cancer Institute, Rome, Italy;

<sup>2</sup> Department of Radiotherapy, Regina Elena National Cancer Institute, Rome, Italy; <sup>3</sup> Laboratory of Medical Physics, Regina Elena National Cancer Institute, Rome, Italy; <sup>4</sup> Department of Neurosurgery, Regina Elena National Cancer Institute, Rome, Italy

### SUMMARY

The objective of this study was to evaluate the safety, effectiveness and functional outcomes of intraoperative radiotherapy (IORT) followed by intensity-modulated radiation therapy (IMRT) in locally advanced stage tumours involving the middle ear. Data on 13 consecutive patients treated for malignant tumor of external auditory canal involving the middle ear were retrospectively reviewed. Median follow-up was 33 months (range 6-133). Five (38%) patients were stage III and 8 (62%) were Stage IV according to the University of Pittsburgh staging system. Lateral temporal bone resection (LTBR) was performed in all cases. LTBR was associated with parotidectomy in 5 (38%) cases, and with neck dissection and parotidectomy in 6 (46%) cases. No patients had gross residual tumour. Surgical treatment was followed by IORT (12 Gy) and IMRT (50 Gy). Adjuvant chemotherapy was used in 4 (30%) cases. Preoperative and postoperative audiometric tests were performed to assess hearing loss. 5-year local-control (LC), 5-year distant-metastasis (DM), 5-year disease-free-survival (DFS) and 5-year overall-survival (OS) were calculated with Kaplan-Meier method. Significant changes in bone conduction were reported after treatment. Partial flap necrosis was the only early complication observed in three (23%) cases, while meningeal fistula was seen in one (7.6%) case as a late complication. The 5-year LC-rate was 68%. The 5-year DM-rate was 90%. The 5-year DFS-rate was 61%. The 5-year OS-rate was 69%. IORT followed by IMRT for the treatment of advanced external auditory canal and middle ear tumours seems to be safe. No intraoperative death was reported. IORT may reduce the postoperative irradiation of remnant tissue obtaining the same full dose on the tumour bed. No complications of the residual external ear were observed. Detriment of neurosensory hearing may be expected. Future studies are required to confirm the benefit of this procedure in the ear.

KEY WORDS: Ear tumours • Intraoperative radiotherapy • IORT • Toxicity • Hearing loss • Middle ear cancer

### RIASSUNTO

Obiettivo dello studio è stato quello di valutare la sicurezza, l'efficacia e i risultati funzionali della radioterapia intraoperatoria (IORT) seguita dalla radioterapia a intensità modulata (IMRT) nel trattamento di tumori maligni avanzati estesi all'orecchio medio. Sono stati inclusi nello studio in modo retrospettivo 13 pazienti consecutive affetti da tumore dell'orecchio esterno esteso all'orecchio medio. Il follow-up è stato in media di 33 mesi (range 6-133). Cinque pazienti (38%) erano di stadio III e 8 pazienti (62%) erano di stadio IV secondo la classificazione dell'Università di Pittsburgh. Una petrosectomia laterale (LTBR) è stata eseguita in tutti i pazienti, la LTBR è stata associata a parotidectomia in 5 (38%) casi e a svuotamento latero-cervicale associato a parotidectomia in 6 (46%) casi. In tutti i casi si è effettuata asportazione della malattia macroscopicamente evidente. Il trattamento chirurgico è stato completato da IORT (12 Gy) e IMRT (50Gy). Chemioterapia adiuvante è stata eseguita in 4 (30%) casi. Test audiometrici pre- e post-operatori sono stati eseguiti per valutare la perdita uditiva. Il tasso di controllo di malattia locale (LC) a 5 anni, di metastasi a distanza (DM) a 5 anni, la sopravvivenza libera da malattia (DFS) e la sopravvivenza globale (OS) a 5 anni sono state calcolate con il metodo di Kaplan-Meier. Variazioni significative nella conduzione per via ossea sono state osservate dopo trattamento. Una necrosi parziale del lembo di ricostruzione è stata l'unica complicanza precoce osservata in 3(23%) casi, mentre una fistola meningea è stata osservata in un solo caso (7,6%) come complicanza tardiva. Il tasso di LC è stato del 68%. Il tasso di DM è stato del 90%. Il tasso di DFS è stato del 61%. Il tasso di OS è stato del 69%. La IORT seguita dalla IMRT nel trattamento dei tumori maligni avanzati dell'orecchio esterno e medio sembra essere sicuro. Nel nostro studio non sono riportati morti. La IORT può ridurre la dose di radioterapia postoperatoria a livello del tessuto residuo ottenendo la medesima dose a livello della sede del tumore. Non abbiamo osservato alcuna complicanza a livello dell'orecchio esterno residuo, mentre si è notato un peggioramento dell'udito anche a livello neurosensoriale. Sono necessari studi prospettici al fine di confermare quanto da noi osservato.

PAROLE CHIAVE: Tumori dell'orecchio • Radioterapia intraoperatoria • IORT • Tossicità • Perdita dell'udito • Cancro dell'orecchio medio

## Introduction

Malignant tumours affecting the middle ear are uncommon. The incidence for squamous cell carcinoma of the external auditory canal, middle ear, mastoid and temporal bone is estimated to be 1-6/1,000,000 population<sup>1</sup>. Early stage tumours of the external canal and middle ear are difficult to diagnose due to the presence of otitis media and deafness, and thus patients are usually diagnosed with advanced disease. Complete surgical resection and radiotherapy (RT) are considered the gold standard treatment for these patients<sup>2</sup>. Prognosis of advanced ear cancers is poor due to the difficulty in performing resections with adequate margins given the close proximity to vital surrounding structures (carotid artery, meninx and brain, skull base venous sinuses)<sup>3</sup>. There are limited data on the complications and functional outcomes after temporal bone cancer treatment. Deafness is one of the most invalidating complications. Conductive hearing loss is a consequence of surgery, while neurosensory hearing loss has been already reported as a likely complication after radiotherapy when it is not possible to completely exclude the inner ear from the radiation field<sup>4</sup>.

In the last few years, intraoperative radiotherapy (IORT), a direct application of irradiation to the tumour bed during an operative procedure, has been proposed to reduce the delay between surgery and intensity-modulated radiation therapy (IMRT), achieving the full dose on the tumour bed with a lower dose to surrounding tissues without an increase in morbidity.

IORT has emerged as a feasible treatment modality for patients with advanced head and neck cancer<sup>5</sup>, although the effectiveness of IORT in ear malignancy has never been investigated. The objective of this retrospective study was to evaluate the safety and feasibility of IORT by evaluating function of the inner ear and complications.

## Materials and methods

Data on 13 consecutive patients affected by a malignancy involving the middle ear were reviewed. All cases had biopsy proven squamous cell carcinoma and were treated at the Department of Otorhinolaryngology Head and Neck Surgery of the National Cancer Institute of Rome between January 2002 and February 2013. There were 9 males (70%) and 4 females (30%). Median age was 69 years (range 47-91). Median follow-up was 33 months (range 10-133). Eight patients (62%) had a primary tumour and 5 (38%) had a recurrence. Stage was based on clinical examination, computed tomography (CT), magnetic resonance imaging (MRI), positron emission tomography (PET-CT) and ultrasound (US). Patients were stage III in 5 (38%) cases and stage IV in 8 (62%) cases according to the University of Pittsburgh TNM staging system proposed by Arriaga for temporal bone tumours<sup>6</sup>. Patients treated by sub-total lateral petrosectomy were excluded from the study due to removal of the otic capsule. Table I shows demographic and characteristics of patients. Preoperative evaluation of the facial nerve showed grade I according to the House-Brackmann (H-B) classification<sup>7</sup> in all cases.

### Surgery

Lateral temporal bone resection (LTBR) was used to treat the primary tumour in all cases. LTBR was conducted by the principles detailed by Conley and Novack<sup>8</sup>. Only LTBR was performed in 2 (16%) cases, LTBR was associated with parotidectomy in 5 (38%) cases and with neck dissection with parotidectomy in 6 (46%) cases. The facial nerve was sacrificed in 9 (69%) cases; 4 (30%) patients underwent nerve grafting after the resection (3 cases with the sural nerve and 1 case with the great auricular nerve). The skin and soft tissues defect were reconstructed by myocutaneous pectoralis major flap in 10 (77%) cases,

Table I.

Pts.	Age	Gender	Histology	Grading	TNM by Arriaga <sup>6</sup>	Stage by Arriaga <sup>6</sup>	Surgery	IORT dose (Gy)	IMRT dose (Gy)
1	73	m	SCC	2	T3 N2b	IV	LSTP + P + ND	12	
2	86	f	SCC	3	T3 N2b	IV	LSTP + ND	12	
3	64	f	SCC	2	T3 N0	III	LSTP + P + ND	12	
4	60	m	SCC	3	T3 N2b	IV	LSTP + ND	12	
5	68	m	SCC	3	T3 N0	III	LSTP + P	12	
6	67	m	SCC	2	T3 N2b	IV	LSTP + P + ND	12	
7	73	f	SCC	2	T4 N0	IV	LSTP	12	
8	91	f	SCC	2	T3 N0	III	LSTP	12	
9	56	m	SCC	2	T4 N0	IV	LSTP + P	12	
10	82	m	SCC	2	T4 N2b	IV	LSTP + P + ND	12	
11	64	m	SCC	2	T3 N0	III	LSTP + P	12	
12	72	m	SCC	3	T3 N0	III	LSTP + P	12	
13	47	m	SCC	2	T3 N2b	IV	LSTP + P	12	

m: male; f: female; SCC: squamous cell carcinoma; LSTP: lateral subtotal petrosectomy; P: parotidectomy; ND: neck dissection.

temporalis flap in 2 (15%) cases and sterno-cleido-mastoid muscle in 1 (8%) case. IORT was delivered after complete tumour resection and report of frozen-section analysis confirming free surgical margins. The IORT team was composed of the surgeon, radiation oncologist and medical physicist. Irradiation was performed with a dedicated mobile accelerator, NOVAC7 (Hitesys spa, now SIT spa, Latina, Italy), located in the operating theatre (Fig. 1). This accelerator allows to irradiate patient while driving the structure close to the operatory field and using movable shield panels for the protection of the personnel. Two nominal electron energy levels at 7 and 9 MeV were used for IORT. The NOVAC7 is equipped with a cylindrical PMMA applicator series, diameter ranging from 4 to 10 cm and incidence angles of 0° or 22.5°. Main characteristics of NOVAC7 include the high dose rate, ranging from 6 to 26 Gy/min. The energy and applicator diameter were chosen by the IORT team for each patient on the basis of tumour extension and depth. The energy used was 7 MeV in all patients. For this energy level, the maximum and 90% isodose depths were 12 mm and 17 mm, respectively. The applicator mean diameter was 6 cm (range 4-8 cm). The IORT dose delivered was 12 Gy in all patients calculated at 90% isodose. The accuracy of the actual delivered dose was checked using in vivo dosimetry. The microMOSFET dosimeter was chosen for measurements because of its small size (active area 0.2 mm x 0.2 mm) that assumes no field perturbation. Dosimetric characterisation and the use of MOSFET dosimeters in vivo during IORT has been extensively described in the literature<sup>9</sup>. The microMOSFET dosimeter, placed inside a sterile catheter, was positioned in the centre of the IORT field to measure the entrance dose.

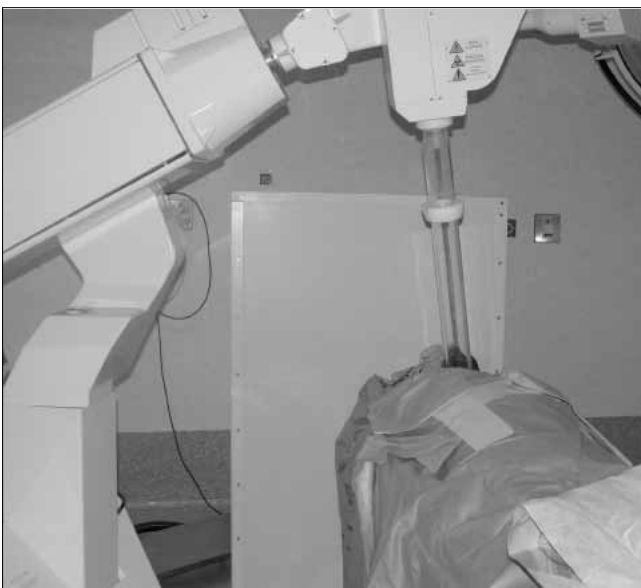

Fig. 1. Mobile accelerator NOVAC7 during the IORT procedure.

### Hearing tests

Audiologic hearing tests were conducted at baseline (before treatment) and at every follow-up after completing radiotherapy. Conductive hearing was not considered because of the presence of the tumour before treatment and due to the excision of the middle ear and obliteration of the cavity after surgery. Bone conduction thresholds were used to establish the changes in hearing frequencies. Each test consisted of pure-tone audiometry using bone conduction test on 0.5 kHz, 1 kHz, 2 kHz, 4 kHz, 6 kHz masking the contralateral ear using an Amplaid 309 audiometer (Amplifon, Italy). The baseline threshold level (bTL) of the treated ear was compared to the hearing threshold level after treatment (ptTL). The audiometry recorded during the last follow up was used to obtain data on hearing loss after treatment (with a 6 month minimum follow-up). Contralateral hearing was tested to assess the difference between the two sides.

### Facial nerve monitoring

Facial nerve function was scored by the H-B classification<sup>7</sup>.

### Complications

Observed complications were classified as early (observed between surgery + IORT and the beginning of IMRT) and late (after the beginning of IMRT).

### Follow-up

All patients were seen every month for the first year and every 3 months thereafter. Routine CT was performed after 6 months and every year. PET-CT scan was performed every year.

### Oncologic results

Recurrence was evaluated as rates of local control (LC) and distant metastasis (DM). Disease specific survival (DSS) and overall survival (OS) were adopted for survival estimation. Kaplan-Meier analysis was used for testing.

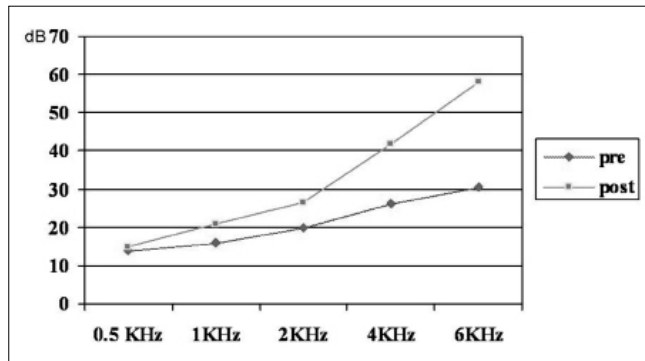
## Results

### Hearing tests

Differences in neurosensory hearing before and after treatment was significant at all tested frequencies ( $p < 0.05$ ) except 0.5 kHz in the ear affected by tumor. Differences in neurosensory hearing before and after treatment in the contralateral ear were not significant. Figure 2 shows mean bone conduction before and after treatment in the ear affected by tumour. Figure 3 shows median values of bone conduction before and after treatment at all tested frequencies in both ears.

### Facial nerve

The facial nerve was sacrificed in 9 (69%) of 13 cases and a facial nerve graft was performed in 4 patients (3 with sural nerve and 1 with great auricular nerve). Recovery to



**Fig. 2.** Bone conduction in the affected ear. Mean bone conduction (decibels) before and after treatment of the affected ear.

Stage IV according to the H-B function scale was achieved in 2 cases and stage V in the other 2 cases. In the 4 patients without facial nerve resection, grade I according to the H-B function scale was observed.

#### Complications

There were no intraoperative or postoperative deaths. The only early complication consisted in partial necrosis of the flap in 3 (23%) patients. Complete healing was achieved after dressing was applied in all cases. Meningeal fistula was the only late complication at 4 months after radiotherapy in a single (7.6%) previously untreated patient. CT showed local recurrence with fistula in this case. No other early or late complications were reported.

#### Disease control and survival

One patient had a recurrence on the tumour bed at 6 months after surgery, while three patients had regional recurrence after 7, 8 and 11 months. Lung metastases were observed in one case after 9 months of treatment. The 5-year LC rate was 68%. The 5-year DM rate was 90%. The 5-year DFS rate was 61%. The 5-year OS rate was for 69%.

## Discussion

This study focused on advanced stage tumours involving the middle ear, which generally have poor prognosis and require an aggressive surgical approach. The difficulty in performing a resection with adequate margins is due to proximity to vital surrounding structures, which may justify the low rate of survival. Considering the latter, postoperative RT is mandatory for high stage tumours of the middle ear<sup>3</sup>. No data are reported in the literature concerning the use of IORT during surgical procedures for advanced stage tumours of the middle ear followed by external RT. Clinical experience has shown that IORT may improve local control and disease-free survival in different tumours such as gastric, pancreatic, colorectal<sup>10</sup> and breast<sup>11</sup>. The oncologic value of IORT in advanced stage tumours involving the middle ear remains to be determined. The theoretical

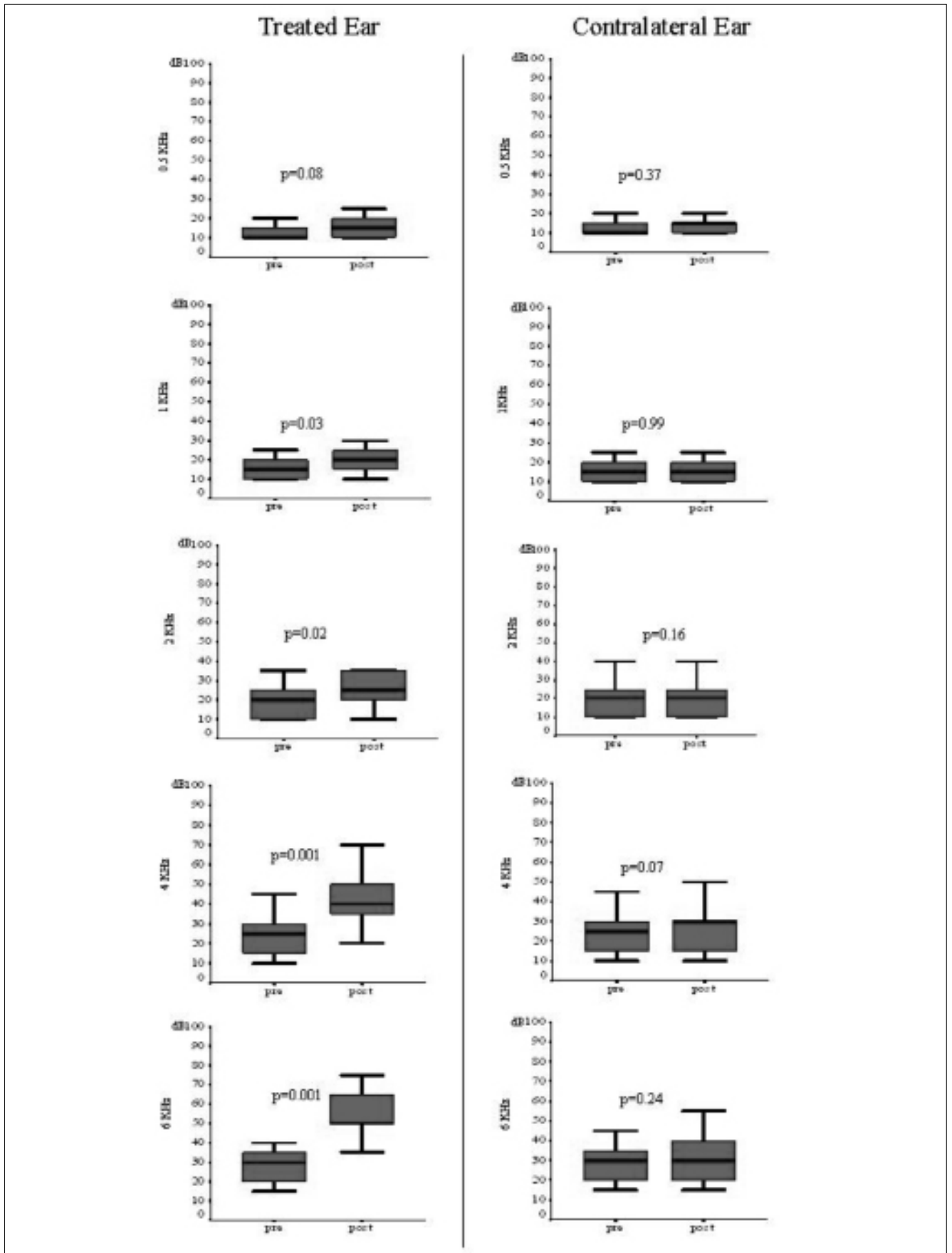
advantages of IORT are: 1) to deliver radiation at the time of surgery, with direct visualisation of the tumour bed, minimising the risk of a geographical miss; 2) to achieve good local tumour control with low morbidity; 3) to reduce the delay between surgery and RT.

One of the major endpoints of this pilot study was to consider the potential benefits of IORT and to assess the presence of complications related to the procedure, especially for hearing, facial nerve function and healing of tissues. Obliteration of the surgical field after LTBR with pedicled flap seems to prevent complications assuring good vascularisation of the operating field<sup>12</sup> and allowing a complete separation between the middle ear and the rhinopharynx by closure of the Eustachian tube thus avoiding entrance of pathogenic bacteria, especially after high doses of radiotherapy. We used the same technique with pedicled flap anticipated by 12 Gy of IORT to reduce flap exposure to radiation in order to prevent necrosis. Intraoperative complications have not been reported, while early complications consisted of partial necrosis of the flap in three (23%) patients, but it is difficult to correlate this type of complication with IORT or with the length and tension of the flap pedicle. In fact, we prefer to adopt free flaps for reconstruction, but follow-up data are not yet available. No other early complications were observed.

Complications after RT on the skull base reported in literature include brain necrosis, osteoradionecrosis, osteitis on remnant temporal bone, swelling of basal brain structures and headache<sup>12</sup>. The only late complication observed in our series was a meningeal fistula (7.6%) seen at 5 and 4 months after IORT and IMRT, respectively, but this cannot be related to the treatment because of the presence of local recurrence by CT. This patient died of disease 13 months after diagnosis.

There is a general consensus that ear toxicity is related to doses exceeding 50 Gy; however, no agreement has been reached on the maximum dosage tolerated by the inner ear before showing complete deafness. We investigated a group of patients with ear cancer representing the only series of cases treated with surgery and IORT followed by IMRT. Previously published data considered inner ear toxicity after RT for the treatment of rhinopharyngeal carcinoma. This site requires irradiation of both cochleas, and comparison between the two ears before and after treatment is not possible. In our experience, only one side underwent IMRT and the contralateral ear was used for comparison, thus reducing the bias of confounding events such as viral infections, chemotherapy, or other.

Early postoperative hearing tests (between surgery + IORT and IMRT) did not show any significant modification in bone conduction, and possible explanations may be: a) radiation related hearing loss has longer latency compared to conductive hearing loss that is related to the surgical procedure, and b) the dose of IORT did not exceed 12 Gy. Late neurosensory hearing impairment (after IMRT) occurred after IMRT



**Fig. 3.** Bone conduction in both ears. Median values of bone conduction before and after treatment at 0.5 kHz, 1 kHz, 2 kHz, 4 kHz and 6 kHz in the affected ear (left side) and the contralateral ear (right side).



throughout the all frequencies and was statistically significant from 1 to 6 kHz. Late hearing loss after RT seems to be related to vascular injury of inner ear structures with progressive onset of fibrosis and ossification of the inner ear fluid space. At any rate, in this study, CT scan did not show any evidence of inner ear ossification after RT<sup>4</sup>.

In the literature, nerve toxicity has been observed in humans (lumbar tract) undergoing doses over 10 Gy and in a canine model over 15 Gy<sup>13</sup>. Nonetheless, our 4 cases did not show any facial nerve deficit after RT (12 Gy of IORT + 50 Gy IMRT). Furthermore, the results after neural graft repair were comparable with those reported in the literature where the RT regimen did not impact functional recovery<sup>14</sup>.

Luc et al. described the prognostic factors for survival and recurrence in temporal bone cancer<sup>3</sup>. Yeung et al. reported a 5-year local control rate of 67% for T3-T4 ear malignancies<sup>15</sup>. Pfreunder et al. observed a 2-year local control rate of 85% for T1-2 and 50% for T3-T4<sup>16</sup>. Bacciu et al. reported 5-year disease specific survival of 86.2% and 48.7% for patients with T3 and T4 disease, respectively<sup>17</sup>. Our data confirmed the possibility to achieve a good control of disease with a LC rate of 68% and DFS rate of 61%, even in advanced stage<sup>18</sup>. It is difficult to compare our results with those of other series given the heterogeneity of staging classifications and treatment used. The low number of cases did not permit drawing any conclusion about the role of IORT in improving oncologic outcomes. This study represents the first for future studies with larger series in order to demonstrate the effectiveness of IORT in ear cancer.

## Conclusions

A dose of 12 Gy of IORT on the inner ear and surrounding tissues during advanced ear cancer surgery can be considered as safe. Early complications were not observed, while late complications such as mild neurosensorial hearing loss on middle-high frequencies can be expected after IORT followed by IMRT. Future studies are required to assess the oncologic value of IORT in local control of disease, confirming the hypothesis of this retrospective study.

## Acknowledgments

The authors acknowledge Ms. Tania Merlino for editing the English language of the text.

## References

<sup>1</sup> Kinney SE. *Tumours of the external auditory canal, middle ear, mastoid and temporal bone*. In: *Comprehensive Management of Head*

*and Neck Tumours*. Thawley SE, Panje WR, Batsakis JG, Lindberg RD (eds). Philadelphia: WB Saunders Co.; 1987. p. 81-206.

- <sup>2</sup> Morris LGT, Mehra S, Shah JP, et al. *Predictors of survival and recurrence after temporal bone resection for cancer*. *Head and Neck* 2012;34:1231-9.
- <sup>3</sup> Lassig AA, Spector ME, Soliman S, et al. *Squamous cell carcinoma involving the temporal bone: lateral temporal bone resection as primary intervention*. *Otol Neurotol* 2013;34:141-50.
- <sup>4</sup> Jereczek-Fossa BA, Zarowski A, Milani F, et al. *Radiotherapy induced ear toxicity*. *Cancer Treat Rev* 2003;29:417-30.
- <sup>5</sup> Marucci L, Pichi B, Iaccarino G, et al. *Intraoperative radiation therapy as an "early boost" in locally advanced head and neck cancer: preliminary results of a feasibility study*. *Head Neck* 2008;30:701-8.
- <sup>6</sup> Arriaga M, Curtin H, Takahashi H, et al. *Staging proposal for external auditory meatus carcinoma based on preoperative clinical examination and computed tomography findings*. *Ann Otol Rhinol Laryngol* 1990;99:714-21.
- <sup>7</sup> House JW, Brackmann DE. *Facial nerve grading system*. *Otolaryngol Head Neck Surg* 1985;93:146-7.
- <sup>8</sup> Conley J, Novack AJ. *The surgical treatment of malignant tumors of the ear and temporal bone*. *Arch Otolaryngol* 1960;71:635-52.
- <sup>9</sup> Soriani A, Landoni V, Marzi S, et al. *Setup verification and in vivo dosimetry during intraoperative radiation therapy (IORT) for prostate cancer*. *Med Phys* 2007;34:3205-10.
- <sup>10</sup> Kusters M, Valentini V, Calvo FA, et al. *Results of European pooled analysis of IORT-containing multimodality treatment for locally advanced rectal cancer: adjuvant chemotherapy prevents local recurrence rather than distant metastases*. *Ann Oncol* 2010;21:1279-84.
- <sup>11</sup> Veronesi U, Orecchia R, Luini A, et al. *Full-dose intraoperative radiotherapy with electrons during breast-conserving surgery experience with 590 cases*. *Ann Surg* 2005;242:101-6.
- <sup>12</sup> Nguyen MT, Billington A, Habal MB. *Osteoradionecrosis of the skull after radiation therapy for invasive carcinoma*. *J Craniofac Surg* 2011;22:1677-81.
- <sup>13</sup> Sindelar WF, Kinsella TJ. *Normal tissue tolerance to intraoperative radiotherapy*. *Surg Oncol Clin N Am* 2003;12:925-42.
- <sup>14</sup> Leong SC, Lesser TH. *Long-term outcomes of facial nerve function in irradiated and nonirradiated nerve grafts*. *Ann Otol Rhinol Laryngol* 2013;122:695-700.
- <sup>15</sup> Yeung P, Bridger A, Smees R, et al. *Malignancies of the external auditory canal and temporal bone: a review*. *Anz J Surg* 2002;72:114-20.
- <sup>16</sup> Pfreunder L, Schwagener K, Willner J, et al. *Carcinoma of the external auditory canal and middle ear*. *Int J Radiation Oncology Biol Phys* 1999; 44:777-8.
- <sup>17</sup> Bacciu A, Clemente IA, Piccirillo E, et al. *Guidelines for treating temporal bone carcinoma based on long-term outcomes*. *Otol Neurotol* 2013;34:898-907.
- <sup>18</sup> Cristalli G, Mancio V, Pichi B, et al. *Treatment and outcome of advanced external auditory canal and middle ear squamous cell carcinoma*. *J Craniofac Surg* 2009;20:816-21.

Received: November 11, 2014 - Accepted: July 24, 2015

Address for correspondence: Giuseppe Mercante, Department of Otolaryngology, Head and Neck Surgery, Regina Elena National Cancer Institute, via Elio Chianesi 53, 00144 Rome, Italy. E-mail: mercante.giuseppe@gmail.com

HEAD AND NECK

# Post-operative pain management in head and neck cancer patients: predictive factors and efficacy of therapy

## *Dolore post-operatorio nei pazienti affetti da neoplasia testa-collo: fattori predittivi ed efficacia della terapia*

C. BIANCHINI<sup>1</sup>, M. MALAGÒ<sup>1</sup>, L. CREMA<sup>1</sup>, C. AIMONI<sup>1</sup>, T. MATARAZZO<sup>2</sup>, S. BORTOLAZZI<sup>2</sup>, A. CIORBA<sup>1</sup>, S. PELUCCHI<sup>1</sup>, A. PASTORE<sup>1</sup>

<sup>1</sup> ENT and Audiology Department, <sup>2</sup> Anaesthesiology Department, "S. Anna" University Hospital of Ferrara, Italy

### SUMMARY

There is increasing interest about all aspects of pain sensation for patients undergoing head and neck surgery, and efforts have been made to better assess, monitor and reduce the occurrence of pain. The aetiology of pain is considered to be "multifactorial", as it is defined by several features such as personal experience, quality perception, location, intensity and emotional impact. The aim of this paper is: (i) to evaluate the efficacy of analgesic treatment in patients with head and neck cancer treated by surgery, and (ii) to study the variables and predictive factors that can influence the occurrence of pain. A total of 164 patients, affected by head and neck cancer and surgically treated, between December 2009 and December 2013, were included in this study. Data collected include age, gender, assessment of anaesthetic risk, tumour localisation, pathological cancer stage, TNM stage, type of surgery performed, complexity and duration of surgery, post-operative complications, postoperative days of hospital stay and pain evaluation on days 0, 1, 3 and 5 post-surgery. We studied the appropriateness of analgesic therapy in terms of incidence and prevalence of post-operative pain; we also related pain to patient characteristics, disease and surgical treatment to determine possible predictive factors. The population studied received adequate pain control through analgesic therapy immediately post-surgery and in the following days. No associations between gender, age and post-operative pain were found, whereas pathological cancer stage, complexity of surgery and tumour site were significantly associated with the risk of post-operative pain. Adequate pain control is essential in oncological patients, and particularly in head and neck cancer patients as the prevalence of pain in this localisation is reported to be higher than in other anatomical sites. Improved comprehension of the biological and psychological factors that characterise pain perception will help to enhance its control in the future.

KEY WORDS: Pain • Head and neck cancer • Surgery • Quality of life • Pain therapy

### RIASSUNTO

*Negli anni è aumentata l'attenzione verso i molteplici aspetti associati alla "sfera" dolore, anche nei pazienti oncologici sottoposti a chirurgia testa-collo. Il dolore, definito infatti da diverse caratteristiche, quali l'esperienza personale, gli aspetti qualitativi della percezione, l'intensità, l'impatto emotivo, riconosce un'eziologia "multifattoriale". Scopo del presente lavoro è stato: (i) valutare l'efficacia della terapia analgesica in pazienti affetti da tumore testa-collo e sottoposti a trattamento chirurgico; (ii) studiare le possibili variabili ed i fattori predittivi che possano influenzare l'insorgenza di dolore. Sono stati studiati 164 pazienti, affetti da neoplasia maligna del distretto testa-collo, trattati chirurgicamente tra il dicembre 2009 ed il dicembre 2013. I dati raccolti comprendono l'età, il sesso, la valutazione del rischio anestesiológico, la sede del tumore, la stadiazione TNM, il tipo di intervento effettuato, la complessità e la durata dell'intervento, le eventuali complicanze post-operatorie, i giorni di degenza post-intervento, la valutazione del dolore nei giorni 0, 1, 3 e 5 post-chirurgia. L'adeguatezza della terapia analgesica è stata espressa in termini di incidenza e prevalenza del dolore post-operatorio, le variabili legate al paziente, alla malattia, al trattamento chirurgico e farmacologico, sono state poi associate all'insorgenza del dolore così da poter descrivere eventuali fattori predittivi. Dai dati ottenuti emerge che la popolazione studiata ha ricevuto un'adeguata terapia antalgica, sia nell'immediato post-operatorio che nei giorni successivi. Non sono risultate associazioni statisticamente significative tra sesso, età ed incidenza del dolore post-chirurgico, mentre lo stadio del tumore, la complessità dell'intervento chirurgico e la sede della neoplasia hanno presentato correlazione significativa con il rischio di insorgenza di dolore post-operatorio. L'elevata prevalenza del dolore in ambito oncologico testa-collo, fa sì che un'appropriata ed attenta gestione del dolore risulti fondamentale. Nel futuro pertanto si auspica una sempre migliore comprensione dei fattori biologici, sociali e psicologici che caratterizzano la percezione del dolore ai fini di migliorarne il controllo.*

PAROLE CHIAVE: Dolore • Tumore testa-collo • Chirurgia • Qualità della vita • Analgesia

## Introduction

Over the past years, the definition of pain has become “multidimensional”, as it is considered to be not just a sensation, but has also been described by several features such as quality perception, location, intensity, emotional impact and frequency<sup>1</sup>. Pain intensity is the most relevant clinical dimension of a painful experience; nonetheless, emotional, cognitive and behavioural aspects are part of the subjective perception of pain<sup>1,2</sup>. The multifactorial nature of pain is particularly evident in oncological patients<sup>3,4</sup>, as it can be accompanied by psychological, emotional and social problems<sup>5,6</sup>. If poorly controlled, it can be associated with physical and mental deterioration, leading to increased morbidity, increased anxiety and depression, and as a result decreased quality of life.

Pain is one of the most common anxieties before and after surgery, and pain control after surgery still continues to receive little attention in the literature, particularly among head and neck patients<sup>3,4,7-10</sup>. It has been reported that pain in head and neck cancer patients has a nociceptive origin due to the direct invasion and destruction of soft tissue and bone tissue by local invasion, but it can also be of neuropathic origin due to inflammation or compression of nervous structures. Furthermore, its intensity can be exacerbated by actions such as speech, chewing and/or swallowing<sup>3,4,8</sup>. The purpose of this study is: (i) to evaluate the efficacy of analgesic treatment in patients with head and neck cancer treated by surgery, and (ii) to understand the possible relation between head and neck pain and predictive factors.

## Materials and methods

A total of 164 patients affected by head and neck cancer and surgically treated in the period between December 2009 and December 2013 at the ENT Department of the University Hospital of Ferrara were included in this retrospective study.

Patient history, informed consent and pre-operative anaesthesiologic evaluation data were collected for each patient. Prior to surgery, each patient received information about pain and its treatment, verbally and with paper-based information sheets given by the ENT and anaesthesiology team using a pain evaluation data sheet (incomplete or partially completed surveys were excluded).

The pre-operative exams included: blood tests, electrocardiography, chest X-ray and any further endoscopic, radiological, histopathological diagnostic investigations in order to correctly stage the tumour and to study associated comorbidities. Data collected for each patient included: gender, age, tumour site, previous treatments (radiation therapy, chemotherapy, surgery), previous analgesic therapy, assessment of anaesthetic risk (ASA), type of surgery performed, complexity of surgery according to the anaesthesiology protocols (Annex), duration of surgery, post-operative complications, post-operative days of hospital stay, drugs used in the immediate post-operative period, analgesic therapy administered during hospitalisation, pain evaluation twice a day (in the morning and in the evening) on days 0, 1, 3 and 5 post-op, definitive histological diagnosis, pTNM staging (according to UICC/AJCC Classification of Malignant Tumours<sup>11</sup>), pathological cancer stage and any analgesic therapy prescribed at home.

All patients received antibiotic and antithrombotic prophylaxis and gastric protection during hospitalisation. Pharmacological control of pain was obtained based on a preoperative established pain program, accordingly to the type of surgery performed (minor, medium and major surgery) (Table I). This consists of multimodal therapy: a combination of opioids, non-steroidal anti-inflammatory drugs and paracetamol. The anaesthesiologist usually prescribed postoperatively analgesic therapy infused by elastomeric pump for the first 24 hours, and sometimes for 48 or 72 hours post-operatively (Table I).

**Table I.** Post-operative analgesic therapy in relation to surgical complexity.

Surgical complexity	Post-operative analgesic therapy
Minor (i.e. tracheotomy)	A. Non-steroidal anti-inflammatory drugs (NSAIDs), at fixed times, every 6/8 hours 1. ketoprofen 100 mg 2. ketorolac 30 mg B. Paracetamol 1 g iv every 6/8 hours; tramadol 100 mg iv every 8 hours.
Medium (i.e. thyroidectomy, parotidectomy, partial glossectomy; without neck dissection)	A. Morphine 2 mg/kg/24 hours in elastomeric pump; B. Morphine 2 mg/kg/24 hours in elastomeric pump + NSAIDs, at fixed times, every 8 hours; C. Morphine 2 mg/kg/24 hours in elastomeric pump + paracetamol 1 g iv every 6/8 hours; D. NSAIDs in elastomeric pump (i.e. ketoprofen 300 mg/24 hours).
Major (i.e. laryngectomy, neck dissections, pull-through, flap reconstructive surgery after extensive demolition)	A. Morphine 3 mg/kg/24 hours in elastomeric pump; B. Morphine 3 mg/kg/24 hours in elastomeric pump + NSAIDs, at fixed times, every 8 hours; C. Morphine 3 mg/kg/24 hours in elastomeric pump + paracetamol 1 gm iv every 6/8 hours; D. NSAIDs in elastomeric pump (i.e. ketoprofen 300 mg/24 hours) + paracetamol 1 gm iv every 6/8 hours.

### Notes:

- NSAIDs are not indicated in case of coagulopathy, hepatopathy, renal failure, or high risk of bleeding conditions.
- The use of morphine alone or in combination with other drugs is related to the expected pain.
- Morphine is not indicated in those affected by suspected (or history of) paralytic ileus, psychiatric illness, or severe respiratory disease.

Post-operative pain trend, in terms of number of episodes and intensity, during the entire hospital stay (on the day of surgery and then on the following days, until discharge) was recorded. Pain intensity during mornings (M) and evenings (E), as well as the maximum value of numeric rating scale (NRS) reached, was recorded each day.

#### *Pain evaluation data sheet*

The pain evaluation datasheet was completed on admission for all patients, updated daily and after patient discharge, and was archived together with the patient's medical records. Pain evaluation was performed through several methods. Visual analogue scale (VAS) measured post-operative intensity pain immediately after surgery, while Numeric Rating Scale (NRS) was used during the remaining post-operative hospital stay. The Behavioural Pain Scale (BPS) was used if patients were held in the intensive care unit in the immediate post-operative period<sup>12-15</sup>. Different sections composed the pain evaluation datasheet adopted for this study.

Section I. Includes patient personal data and medical diagnosis. Other information collected in this part include: pain at admission (assessed by NRS), type of pain (acute vs chronic); pain management/therapy at home; type of surgical procedure and anaesthesia. Expected pain and pain management plan proposed by the anaesthesiologist and type of surgical plan (with the aim of tailoring pain management for each patient and its specific disease) is also reported in this section.

Section II. This part is dedicated to pain measurement and recording procedures. These measures were performed at different post-operative days. It was generally measured and recorded twice a day after surgery, and there is an extra section to report episodes of acute pain. Only if NRS > 3 can extra analgesic drugs can be administered to patients on the basis of the anaesthesiologist prescriptions.

#### *Statistical analysis*

Statistical analysis was performed using contingency tables analysed by chi-square ( $\chi^2$ ) or by Fisher's test to compare small groups of data. To investigate the possible contribution of different variables in multivariate methods, binary logistic processing procedures were used. The calculations were performed using the statistical system Systat v.5 (Systat Inc. Evanstone, IL USA).

If not otherwise specified, p values < 0.05 were considered statistically significant, while p values between 0.06 and 0.1 were considered of borderline significance.

## Results

A total of 164 patients were enrolled in this study. There were 101 males (61.5%) and 63 females (38.5%). Age range was 16 and 86 years, with a mean of 62.84 years. Patients were divided into two age groups: 0-60 years (56 patients, 34.1%) and > 60 years (108 patients, 65.9%; Table II).

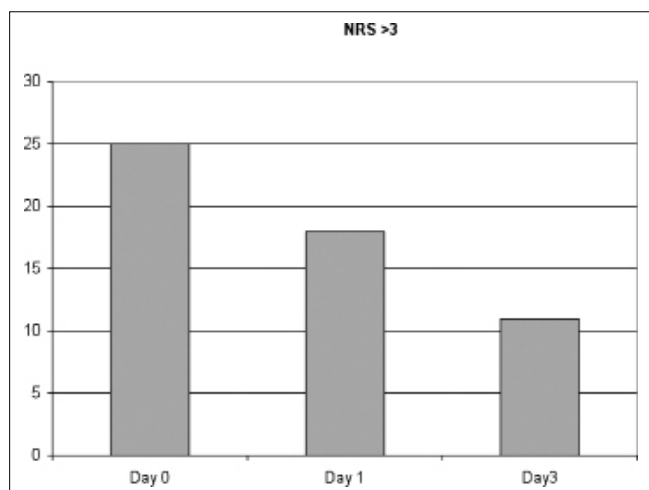
The primary cancer sites were very different and patients were grouped into four cohorts identified by a number: (1) pharyngeal and laryngeal tumours (64 patients, 39.1%); (2) thyroid, salivary gland and neck tumours (58 patients, 35.4%); (3) oral cavity tumours (32 patients, 19.5%); (4) tumours at other sites (i.e. head and neck skin or occult carcinomas to neck nodes; 10 patients, 6.1%; Table II).

TNM stage was available in only 141 patients (as lymphomas, skin tumours and neck metastases from occult cancers were excluded). Therefore, 2 patients were classified as Tis (1.4%), 58 as T1 (41.1%), 28 as T2 (19.8%), 31 as T3 (22%) and 22 as T4 (15.6%). On the base of tumour staging, 2 patients (1.4%) had oncological stage 0,

**Table II.** Demographic and clinical characteristics of patients.

		Patients N (%)	Mean
Demographic data	Gender		
	• Male	101 (61.5)	
	• Female	63 (38.4)	
	Age		62.84
	• 0-60 years	56 (34.1)	
	• ≥ 60 years	108 (65.9)	
Clinical features	Tumour site		
	• Pharynx-larynx	64 (39.1)	
	• Neck-thyroid-salivary glands	58 (35.4)	
	• Oral cavity	32 (19.5)	
		10 (6.1)	
	Stage		
	• Low (0-I-II)	52 (36.8)	
	• High (III-IV)	89 (63.2)	
	Previous therapies		
	• No	114 (69.5)	
	• Yes	50 (30.5)	
	ASA		
	• 1	5 (3.1)	
• 2	59 (36.0)		
• 3	86 (52.5)		
• 4	14 (8.6)		
Surgical complexity			
• Minor	1 (0.6%)		
• Moderate	56 (34.2)		
• Major	107 (65.2)		
Post-operative complications			
• No	138 (84.1)		
• Yes	26 (15.9)		
Hospital stay		11.46	
• ≤ 5 days	63 (38.5)		
• 6-20 days	77 (46.9)		
• ≥ 21 days	24 (14.6)		
Post-op analgesic therapy			
• Opioids	27 (16.5)		
• Opioids+NSAIDs/paracetamol	121 (73.7)		
• NSAIDs	16 (9.8)		
Analgesic therapy at discharge			
• No	69 (42.0)		
• Yes	90 (54.9)		
• Data not available	5 (3.1)		





**Fig 1.** Incidence of uncontrolled pain. There is a trend of a gradual pain decrease during hospital stay, with a peak on the day of surgery.

38 (27.2%) had stage I, 12 (8.5%) had stage II, 39 (27.7%) stage III and 50 (35.5%) stage IV (Fig. 1). For statistical analysis, patients were divided into those with low tumour stage (stages 0, I and II: 52 patients) and advanced tumour stage (stages III and IV: 89 patients; Table II).

A total of 114 patients were previously untreated (69.5%), while 50 (30.5%) had received previous treatment with radio-chemotherapy ( $n = 3$ ), surgery ( $n = 42$ ), or both ( $n = 5$ ). Surgical procedures were grouped as minor (1 patient, 0.6%), moderate surgery (56 patients, 34.2%) and major surgery (107 patients, 65.2%). Possible complications in the postoperative period were classified as local (13 cases) and systemic (13 cases; Table II).

The average duration of hospitalisation was 11.46 days; patients were classified into 3 groups based on duration of hospitalisation: first group,  $\leq 5$  days (63 patients, 38.5%); second group, 6-20 days (77 patients, 46.9%); third group,  $\geq 21$  days (24 patients, 14.6%). In relation to anaesthesiological risk, 5 patients were ASA 1 (3.1%), 59 patients ASA 2 (36%), 86 ASA 3 (52.5%) and 14 patients were ASA 4 (8.6%) (Table II).

Considering pain therapy administered, 27 (16.5%) patients received opioids in the immediate postoperative period, 121 (73.7%) patients received a combination of opioids, non-steroidal anti-inflammatory drugs and/or paracetamol, 16 (9.8%) patients received only non-steroidal anti-inflammatory drugs (Table II). Analgesic pain therapy on discharge was prescribed to 90 of 164 patients.

#### *Prevalence and incidence of pain episodes during post-operative recovery*

When evaluating the effectiveness of post-operative pain therapy, we firstly considered the prevalence of post-operative pain that was uncontrolled by therapy (NRS > 3) in the total group of patients. Therefore, 46 of 164 (28.1%)

**Table III.** The PMI (Pain Management Index) was used to evaluate the effectiveness of pain medications administered immediately after surgery (at days 0 and 1): in 95.7%, the analgesic prescription was adequate.

	No drugs	No opioids	Weak opioids	Strong opioids
No pain	0	2	1	16
Mild pain	0	8	28	71
Moderate pain	0	6	6	21
Severe pain	0	0	1	4

patients had at least one episode of post-operative pain that was not controlled by therapy (NRS > 3) during the hospital stay. Of these 46 patients, 31 had a single episode of pain (NRS > 3), 11 had 2 episodes, 2 had 3 episodes and 2 had 4 episodes.

Regarding the incidence of uncontrolled pain on the day of surgery and the first three post-operative days, we recorded a total of 25 episodes during the day of surgery (M+E), 18 episodes (M+E) in the day after surgery and 11 episodes (M+E) in the third day of hospital staying. These data show that there is a trend of a gradual pain decrease during hospitalisation, with a peak on the day of surgery (Fig. 1).

According to the PMI (Pain Management Index), patients were divided into 4 categories in relation to pain episodes and into 4 groups in relation to the analgesic drugs administered. The results showed adequate analgesic prescription, with a prevalence of cases with a negative PMI (4.3%) (Table III).

#### *Variables and predictive factors that can influence the occurrence of pain*

Multivariate binary logistic regressions were employed on different days and different times within a single day (morning/evening) from surgery (days 0, 1, 2, 3) in order to determine any possible associations between post-operative pain and parameters such as gender, age, site of disease, tumour stage and complexity of intervention. A dependent binary variable was therefore defined, first as to the simple presence of pain, then as to a pain level higher than 3, (pain scale ranging from 0: no pain to 10: maximum level pain). The simple pain presence (NRS > 3) showed monivariate association, at day 0, with malignant localisation. In particular, at M0, neck, thyroid and salivary glands tumours were at greater risk of inducing pain ( $p < 0.04$ ) than those located at the pharynx and larynx (OR 4.2; 95% CI: 0.07-16.3). Moreover, at M0, at monivariate analysis there was a significant reduction ( $p < 0.05$ ) of pain in relation to the increase of hospital stay (OR: 0.86; 95% CI 0.74-0.99). At M0, there was a borderline association ( $p < 0.07$ ) between surgery complexity and post-operative pain, with a higher risk for moderate surgery (OR: 0.4; 95% CI 0.12-1.1). At M3, there was a correlation between pain occurrence and gender, as women had higher risk of developing pain ( $p < 0.03$ ) (OR: 6.2; 95% CI: 1.2-30.8).



Finally, when considering days 1 and 5 post-surgery, there was no significant association between pain and the different variables examined.

## Discussion

There are few studies evaluating pain sensation and quality of life in head and neck cancer patients. Moreover, most of the reports suggest that the management of acute post-operative pain, in particular, is still sub-optimal<sup>3 4 7-10 16-18</sup>. According to a 2007 review, the prevalence of pain in patients with head and neck tumour is reported to be 70%<sup>17</sup>. Keefe FJ reported that the incidence of pain in patients suffering from head and neck cancer ranges between 40% and 70%<sup>7</sup>. Literature data concerning incidence of post-operative pain in patients undergoing surgery for malignant head and neck disease show that 48% of patients present a pain intensity greater than 4 at VAS<sup>18</sup>.

Moreover, considering the effectiveness of analgesic therapy for head and neck surgery patients, the data available are limited. A meta-analysis by Deandrea et al. found that 43% of cancer patients from 26 different studies had insufficient control of pain<sup>19</sup>. Orgill et al. hypothesised that the cause of the inadequateness of analgesic therapy in a laryngectomy series (35% of patients) was the incorrect prescription and/or use of a suboptimal drug dosage (in relation to the extent and type of surgery)<sup>20</sup>. Inhestern et al. described that many patients with head and neck cancer have moderate or severe pain within 24 hours after surgery, and that pain can be related to factors such as duration of surgery and presence of preoperative pain<sup>21</sup>.

Analysing the data obtained from our group, it is interesting to note that pain therapy was adequate. Assuming that values of NRS > 3 indicate inadequate pain control, only 26.5% of patients in the days examined had at least one episode of pain that was not effectively controlled by therapy. In our group, pain intensity presented a peak on the day of surgery and then decreased in the following days. This trend is consistent with the results in the literature. In fact, Mom et al. also described a peak of pain intensity in the immediately post-surgery period (median value VAS = 7), and a value < 3 at 30 hours after surgery<sup>9</sup>. When considering the type of analgesics administered, in our patient group, opioids alone or in combination with other analgesics (paracetamol and/or non-steroidal anti-inflammatory drugs), are the most commonly used agents on days 0 and 1. In particular, these drugs were used in 94.8% of patients: in 93.1% of cases there was a continuous administration via elastomeric pump that was effective in 95.7% of cases (Table III). No side effects due to the administration via infusion pump were reported. Therefore, opioids can be considered as the most effective drugs within the series presented, as for other series in the literature<sup>22</sup>.

Other reports have investigated whether there are predic-

tive factors that might influence post-operative pain outcome in head and neck oncology<sup>4 8 23-26</sup>. In general, it has been observed that pain is more intense in older patients and in those with comorbidities. In particular, alcohol abuse, smoking and depression were found to be associated with greater intensities of pain in head and neck cancer patients<sup>4 23 24</sup>. Neck surgery was found to be associated to an increased risk of developing pain<sup>25</sup>; according to Talmi, this can be attributed to the interruption of the nerve fibres, and differentiation may also result in other symptoms such as of dysaesthesia, paraesthesia and hypersensitivity<sup>3</sup>. In our study, there were no significant differences between gender, age and the risk of developing post-operative pain. Pathological cancer stage, complexity of surgery and tumour site, however, were significantly associated with a increased risk of post-operative pain. In particular, patients with advanced stages of cancer (III and IV) had a lower risk of developing post-operative pain compared to patients with low-stage tumours (0, I, II). This could be explained since the latter received less effective analgesic therapy, and patients with advanced stages of cancer are planned to receive a more potent analgesic therapy due to the more complex and invasive surgical procedures programmed.

In conclusion, analysis of the data herein show that:

- the population studied received adequate pain control immediately post-surgery and in the following days;
- there was a significant correlation between occurrence of post-operative pain and sex, tumour site, tumour stage and complexity of the intervention.

We believe that the good pain control overall registered in our series can be attributable to the good counselling performed for each patient of the present series; we tried to tailor, for each patient, analgesic therapy to the expected post-operative pain, thus considering patient characteristics, comorbidities and type of surgery.

The limitations of this study are:

- the number of parameters studied; with a greater number of patients it would be possible to include other features such as chronic pain prior to surgery, diabetes mellitus, alcohol and/or smoking.
- mental status prior to surgery was not evaluated (i.e. those affected by chronic pain have been reported to be more prone to pain perception in the literature<sup>21</sup>).

## Conclusions

In conclusion, there is growing attention about quality of life and particularly of pain perception for head and neck surgery patients, and several efforts have been made in order to better assess, monitor and minimise the incidence of pain. Hopefully, better comprehension of the biological and psychological factors that characterise the pain sensation will help to enhance its control in the future, therefore increasing the quality of life of these patients.

## Acknowledgements

The authors would like to thank Dr. Giuseppe Gilli for his assistance with statistical analysis.

## References

- <sup>1</sup> Merskey H, Bogduk N. *Classification of Chronic Pain: Descriptions of Chronic Pain Syndromes and Definitions of Pain Terms*. Second edition. Washington, DC: IASP Press; 1994. p. 209-214.
- <sup>2</sup> Frank-Stromborg M, Olsen O. *Instruments for Clinical Health-Care Research*. Burlington, MA: Jones & Bartlett; 1999. p. 528-564.
- <sup>3</sup> Talmi YP, Horowitz Z, Pfeffer MR, et al. *Pain in the neck after neck dissection*. *Otolaryngol Head Neck Surg* 2000;123:302-6.
- <sup>4</sup> Chen SC, Liao CT, Chang JT. *Orofacial pain and predictors in oral squamous cell carcinoma patients receiving treatment*. *Oral Oncology* 2011;47:131-5.
- <sup>5</sup> Ghei A, Khot S. *Pain management in patients with head and neck carcinoma*. *Otorhinolaryngology Clinics: An International Journal* 2010;2:69-75.
- <sup>6</sup> Portenoy RK, Lesage P. *Management of cancer pain*. *Lancet* 1999;353:1659-700.
- <sup>7</sup> Keefe FJ, Manuel G, Brantley A, et al. *Pain in the head and neck cancer patient: changes over treatment*. *Head Neck Surg* 1986;8:169-76.
- <sup>8</sup> Chaplin JM, Morton RP. *A prospective, longitudinal study of pain in head and neck cancer patients*. *Head Neck* 1999;21:531-7.
- <sup>9</sup> Mom T, Commun F, Derbal C, et al. *Postoperative pain evaluation in the surgery of head and neck cancers*. *Rev Laryngol Otol Rhinol (Bord)* 1996;117:93-6.
- <sup>10</sup> Ziv G, Darryl B, Nissim M, et al. *Treatment of pain after head and neck surgeries: control of acute pain after head and neck oncological surgeries*. *Otolaryngol Head Neck Surg* 2006;135:182-8.
- <sup>11</sup> Edge SB, Byrd DR, Compton CC, et al. *AJCC cancer staging manual*. New York: Springer; 2010.
- <sup>12</sup> Williamson A, Hoggart B. *Pain: a review of three commonly used pain rating scales*. *J Clin Nurs* 2005;14:798-804.
- <sup>13</sup> Collins SL, Moore RA, McQuay HJ. *The visual analogue pain intensity scale: what is a moderate pain in millimeters*. *Pain* 1997;72:95-7.
- <sup>14</sup> Chanques G, Payen JF, Mercier G, et al. *Assessing pain in non-intubated critically ill patients unable to self report: an adaptation of the Behavioral Pain Scale*. *Intens Care Med* 2009;35:2060-7.
- <sup>15</sup> Rodriguez CS, McMillan S, Yarandi H. *Pain measurement in older adults with head and neck cancer and communication impairments*. *Cancer Nurs* 2004;27:425-33.
- <sup>16</sup> Mitera G, Zeiadin N, Kirou-Mauro A, et al. *Retrospective assessment of cancer pain management in an outpatient palliative radiotherapy clinic using the Pain Management Index*. *J Pain Symptom Manage* 2010;39:259-67.
- <sup>17</sup> Van den Beuken-Van Everdingen MH, De Rijke JM, Kessels AG, et al. *Prevalence of pain in patient with cancer: a systematic review of the past 40 years*. *Ann Oncol* 2007;18:1437-49.
- <sup>18</sup> Sommer M, Geurts JW, Stessel B, et al. *Prevalence and predictors of postoperative pain after ear, nose and throat surgery*. *Arch Otolaryngol Head Neck Surg* 2009;135:124-30.
- <sup>19</sup> Deandrea S, Montanari M, Moja L, et al. *Prevalence of undertreatment in cancer pain. A review of published literature*. *Ann Oncol* 2008;19:1985-91.
- <sup>20</sup> Orgill R, Krempel GA, Medina JE. *Acute pain management following laryngectomy*. *Arch Otolaryngol Head Neck Surg* 2002;128:829-32.
- <sup>21</sup> Inhestern J, Schuerer J, Illge C, et al. *Pain on the first post-operative day after head and neck cancer surgery*. *Eur Arch Otorhinolaryngol* 2015;272:3401-9.
- <sup>22</sup> Cavalcanti IL, Carvalho AC, Musauer MG, et al. *Safety and tolerability of controlled-release oxycodone on postoperative pain in patients submitted to the oncologic head and neck surgery*. *Rev Col Bras Cir* 2014;41:393-9.
- <sup>23</sup> Shuman AG, Terrell JE, Light E, et al. *Predictors of pain among patients with head and neck cancer*. *Arch Otolaryngol Head Neck Surg* 2012;138:1147-54.
- <sup>24</sup> Duffy SA, Ronis DL, Valenstein M, et al. *Depressive symptoms, smoking, drinking, and quality of life among head and neck cancer patients*. *Psychosomatics* 2007;48:142-8.
- <sup>25</sup> Gellrich NC, Schimming R, Schramm A, et al. *Pain, function, and psychologic outcome before, during, and after intraoral tumor resection*. *J Oral Maxillofac Surg* 2002;60:772-7.
- <sup>26</sup> Bianchini C, Maldotti F, Crema L, et al. *Pain in head and neck cancer: prevalence and possible predictive factors*. *J Buon* 2014;19:592-7.

Received: November 12, 2014 - Accepted: June 6, 2015

Address for correspondence: Chiara Bianchini, ENT and Audiology Department, "S. Anna" University Hospital of Ferrara, via Aldo Moro 8, 44124 Ferrara, Italy. E-mail: chiara.bianchini@unife.it

## RHINOLOGY

# The effects of inferior turbinoplasty on nasal airflow during cosmetic rhinoplasty

## *Gli effetti sul flusso aereo nasale della turbinoplastica inferiore in corso di rinoseptoplastica*

R. ZOJAJI<sup>1</sup>, M. KESHAVARZMANESH<sup>2</sup>, M. BAKHSHAEI<sup>3</sup>, R. BEHDANI<sup>4</sup>, S. ESMAEELZADEH<sup>4</sup>, M. MAZLOUM FARSI BAF<sup>5</sup>

<sup>1</sup> Otorhinolaryngology Department, Mashhad Branch, Islamic Azad University, Mashhad, Iran; <sup>2</sup> Otolaryngologist, Mashhad, Iran; <sup>3</sup> Rhinologist, Associate professor of the Sinus and Surgical Endoscopic Research Center, Faculty of Medicine, Mashhad University of Medical Sciences, Mashhad, Iran; <sup>4</sup> General Practitioner, Sinus and Surgical Endoscopic Research Center, Faculty of Medicine, Mashhad University of Medical Sciences, Mashhad, Iran; <sup>5</sup> General Practitioner, Faculty of Medicine, Mashhad Branch, Islamic Azad University, Mashhad, Iran

## SUMMARY

Rhinoplasty is one of the most common and challenging cosmetic procedures. One of the complications of rhinoplasty associated with dissatisfaction is nasal obstruction, which is often due to narrowing of the nasal valve area. Application of certain procedures such as turbinoplasty can prevent and correct this problem. This study aim was to investigate the effect of inferior turbinoplasty in reduction of airflow resistance and nasal obstruction. Using active anterior rhinomanometry, nasal airflow was measured in 50 patients who underwent cosmetic rhinoplasty and bilateral turbinoplasty before and 6 months after surgery. None of the patients subjectively complained of nasal obstruction before or after surgery. According to rhinomanometry results, improvement in nasal airflow was seen both in inspiration and expiration, although only expiration was significant ( $p = 0.034$ ). Airflow changes in males and females and in different age groups was not significant ( $p > 0.05$ ). It appears that rhinoplasty does not adversely affect nasal airflow when it is accompanied by simple adjuvant procedure inferior turbinoplasty.

KEY WORDS: Rhinoplasty • Rhinomanometry • Turbinoplasty

## RIASSUNTO

*La rinoplastica è una procedura chirurgica molto comune e al tempo stesso di elevata complessità. Uno degli aspetti più discussi di tale chirurgia sono gli insoddisfacenti esiti funzionali dovuti spesso ad un eccessivo restringimento dell'area della valvola nasale. Alcune procedure, come la turbinoplastica inferiore, possono favorire la prevenzione di tali problematiche ostruttive. L'intento del presente studio è quello di indagare gli effetti della turbinoplastica inferiore sulla resistenza nasale e sull'ostruzione respiratoria. In 50 pazienti è stata effettuata un'analisi preoperatoria e sei mesi dopo rinoplastica con turbinoplastica inferiore mediante rinomanometria anteriore attiva. Nessuno dei pazienti ha lamentato sintomatologia ostruttiva nasale nel preoperatorio o nel corso del postoperatorio. In accordo con i dati rinomanometrici sia le resistenze inspiratorie che quelle espiratorie hanno presentato valori migliori nel postoperatorio, ma solo le resistenze espiratorie hanno presentato una significatività statistica ( $p = 0,034$ ). Le differenze in termini di flusso nasale fra maschi, femmine e differenti gruppi di età non sono state significative ( $p > 0,05$ ). In conclusione dai dati del nostro studio emerge che la rinoseptoplastica, associate a turbinoplastica parziale non ha un impatto negativo sulla funzionalità nasale ed in particolare sul flusso aereo attraverso le cavità nasali.*

PAROLE CHIAVE: *Rinoplastica • Rinomanometria • Turbinoplastica*

Acta Otorhinolaryngol Ital 2016;36:97-100

## Introduction

Respiratory problems following rhinoplasty are a major concern, and despite a favourable cosmetic outcome, can cause dissatisfaction for the patient. Some researchers have reported such breathing disturbances are as high as 70% following rhinoplasty, although scars and loss of mucosal sensation can also give the feeling of a “blocked” nose<sup>1</sup>. The aetiology of nasal obstruction after rhinoplasty includes various factors that result from a combination of

both undiagnosed nasal disorders such as septal deviation, turbinate hypertrophy and mucosal diseases in addition to reduced nasal valve area following this type of surgery<sup>2,3</sup>. On the other hand, the inferior nasal turbinate is an independent bone<sup>4</sup>; forming a part of the nasal lateral wall, it is a major structure in the nose<sup>5</sup>. The inferior turbinate causes resistance against the nasal airflow that is essential for normal respiration. Moreover, as part of the valvular area it changes the lamellar and laminar flow into the turbinate state<sup>6</sup>.

Rhinoplasty may cause reduction of nasal valve area and result in severe airflow obstruction and respiratory problems. Accordingly, as for any type of surgery in this region it should be performed with utmost care and precision. The use of techniques such as inferior turbinate fracture or turbinoplasty and inferior turbinate size reduction by improving nasal airflow<sup>7</sup> can be beneficial in improving the post-operative results and increase patient satisfaction. We hypothesised that removing part of the inferior turbinates (turbinoplasty) during rhinoplasty by increasing the internal nasal space might reduce airflow resistance and nasal obstruction and consequently improve patient breathing. Inferior turbinoplasty is a procedure that reduces the size of the inferior turbinates.

Considering above hypothesis, this study aimed at investigating the effect of inferior turbinoplasty in reducing the airflow resistance and nasal obstruction following rhinoplasty.

## Materials and methods

This prospective study was performed on patients referred to a private clinic for rhinoplasty between 2010 and 2012. Among patients referred for rhinoplasty, those with wide nose and large inferior turbinates and without symptomatic septal deviation, turbinate hypertrophy, and without history of chronic sinusitis or allergy were selected because the chance of developing airflow resistance and nasal obstruction is higher in this group of patients after reduction of nose size. In other words, selected patients were candidates for elective rhinoplasty without septoplasty.

Informed consent was obtained from each patient. The study protocol was approved by the local institutional review board (IRB).

A total of 50 patients were randomly selected among eligible patients using a table of random numbers who underwent rhinomanometry and subsequent rhinoplasty. Active anterior rhinomanometry was performed by placing the nozzle into both nasal cavities. Patients were evaluated under similar circumstances (during certain periods of the day, no smoking and no exercise before the test). Rhinomanometry was performed for all female patients

during the first week after menstruation. For all patients, closed rhinoplasty was performed by the same surgeon without any intervention or reconstruction of nasal valve. Bilateral high-low-high internal lateral osteotomy and inferior turbinate outfracture with preservation of Webster's triangle was performed for all patients.

Nasal airflow was measured by active anterior rhinomanometry before and 6 months after the operation. Rhinomanometry was performed with a Rino 4000 device (Homoth Medizinelektronik GmbH & Co. KG, Hamburg, Germany). The airflow during inspiration and expiration was measured at 75, 150 and 300 Pascal, whereas in data analysis 150 Pascal was considered as the standard level of pressure. The results were reported as numbers and diagrams for each patient and were then analysed by a statistician.

The patients were also evaluated for post-operative complications such as respiratory problems after the operation.

Based on rhinomanometry results, patients were divided into three groups. Group 1: nasal airflow changes after surgery between -50 and 50 ml/sec that was considered as the default change in the airflow due to device error, moderator error or error in the patient's respiration (unchanged condition); Group 2: those with airflow changes less than -50 ml/sec were considered as patients with a worsened condition; Group 3: patients with more than 50 ml/sec changes in the nasal airflow during the same time regarded as improved condition.

### Statistical analysis

Statistical analysis was performed using SPSS ver. 11.5 for Windows. Normally distributed quantitative variables were demonstrated as mean  $\pm$  standard deviation. The normality condition of the quantitative variables was investigated using the Kolmogorov-Smirnov test. Mann-Whitney U test was used to compare equality distribution of age in two gender and changes in nasal airflow following rhinoplasty in two groups. Chi-square and maximum likelihood ratio tests were used to assess relation between Changes in nasal airflow following rhinoplasty and ratio variant. A p value < 0.05 was considered as significant.

**Table I.** Changes in nasal airflow following rhinoplasty (Classification A).

Variable	Group 1 (Between -50 to 50 ml/sec) n (%)	Group 2 (Less than -50 ml/sec) n (%)	Group 3 (More than 50 ml/sec) n (%)	Test statistic	P value
Right nasal cavity inspiratory airflow	26 (52)	9 (18)	15 (30)	8.92	0.012*
Right nasal cavity expiratory airflow	25 (50)	8 (16)	17 (34)	8.68	0.013*
Left nasal cavity inspiratory airflow	26 (52)	11 (22)	13 (26)	7.96	0.019*
Left nasal cavity expiratory airflow	28 (56)	9 (18)	13 (26)	12.04	0.002*
Both nasal cavities inspiratory airflow	17 (34)	13 (26)	20(40)	1.48	0.477
Both nasal cavities expiratory airflow	21 (42)	8 (16)	21(42)	6.76	0.034*

\*p < 0.05 significant



**Table II.** Changes in nasal airflow following rhinoplasty (Classification B).

Variable	Comparing the unchanged with worsened condition (Group 1 & 2)		Comparing the unchanged with improved condition (Group 1 & 3)	
	Test statistic	P value	Test statistic	P value
Right nasal cavity inspiratory airflow	26.000	0.007*	26.000	0.118
Right nasal cavity expiratory airflow	25.000	0.005*	17.000	0.280
Left nasal cavity inspiratory airflow	11.000	0.021*	26.000	0.055
Left nasal cavity expiratory airflow	9.000	0.003*	28.000	0.029*
Both nasal cavities inspiratory airflow	13.000	0.584	17.000	0.742
Both nasal cavities expiratory airflow	21.000	0.026*	21.000	0.999

\*  $p < 0.05$ .

## Results

Among the 50 cases, 8 (16%) were male and 42 (84%) female. Their age ranged from 15 up to 59 years with mean age of  $26.84 \pm 8.81$ . The mean age of men and women was not significantly different ( $p = 0.055$ ,  $Z = 1.921$ ). Considering symptoms, none of the patients complained of nasal obstruction, either before or after surgery.

Mean inspiratory airflow before and after rhinoplasty was  $670.32 \pm 697.5$  and  $694.62 \pm 715.5$  ml/sec, respectively. In addition, mean expiratory airflow before and after rhinoplasty were  $676.38 \pm 703$  and  $716.26 \pm 718$  ml/sec, respectively. Based on rhinomanometry results, the inspiratory and expiratory airflows changed significantly at 6 months after rhinoplasty with turbinoplasty (Table I). The number of patients without airflow changes (Group 1) was higher than those with a worsened condition (Group 2); no significant difference was found in the number of patients without airflow change (Group 1) and those with improved condition (Group 3) (Table II).

Both inspiratory and expiratory nasal airflows improved at 6 months after rhinoplasty and inferior turbinoplasty, but the improvement was significant only for expiratory airflow ( $p = 0.034$ ). In addition, the level of airflow changes in males and females and in different age groups was not significant ( $p > 0.05$ ).

## Discussion

Nasal obstruction is a major complication of rhinoplasty that results in true problems and discomfort for the patient<sup>8</sup>. Since the airflow in each nasal cavity changes based on the prominence and lack of space caused by the inferior turbinate, changes in the turbinate structure can

thus affect nasal function, which is important in rhinoplasty surgeries and post-operative nasal obstruction.

The importance and necessity of the present research is that if the efficacy of turbinoplasty during rhinoplasty is improved, common post-operative complications such as nasal obstruction are resolved, and further costs for revision surgeries can be avoided.

Due to the increase in the demand for rhinoplasty, the results of this study can have a major impact on its costs and patient satisfaction. Herein, the role of fracture of the inferior turbinate or turbinoplasty was investigated in the prevention of post-operative nasal obstruction in those cases that had been referred for cosmetic rhinoplasty without respiratory complaints. In addition to qualitative and subjective studies by clinical history, quantitative and objective studies by anterior rhinomanometry were also performed which adds further value to our results.

In a study by Grymer, which was performed 6 months after rhinoplasty surgery using acoustic rhinometry, it was observed that the internal diameters of the nasal cavity, especially in the anterior section, decreased after rhinoplasty surgery<sup>9</sup>; this factor plays a major role in post-operative nasal obstruction.

Kosh et al., in 2004, reported that rhinoplasty is the most important cause of nasal obstruction followed by nasal trauma (15%) and congenital anomaly (6%)<sup>10</sup>. However, in the study by Courtiss, the findings suggested that rhinoplasty had no impact on nasal airflow<sup>11</sup>. In another study regarding the complications of nasal obstruction following rhinoplasty surgery, revision osteotomy with turbinoplasty was proposed for overcoming this problem<sup>3</sup>, a finding which is consistent with our results. In a similar study, the role of turbinectomy in cases of hypertrophic inferior and middle turbinates was highlighted as a solution for post-operative nasal breathing problems<sup>12</sup>.

Mlynski et al. concluded that anterior turbinoplasty and turbinectomy reduce nasal airflow resistance, but due to disruption of the natural shape of the lateral nasal wall, worsen its respiratory function<sup>13</sup>. In another study on cases with nasal airway obstruction, significant reduction in obstruction was seen following inferior turbinectomy by carbon dioxide laser in comparison with those receiving cryotherapy, turbinate submucosal resection and partial turbinectomy<sup>14</sup>. This is also in agreement with our findings.

Moreover, the studies by Ophir et al. on patients complaining from nasal obstruction due to inferior turbinate hypertrophy showed that total turbinectomy reduces nasal obstruction in 84% of cases and also improves nasal-conditioning<sup>15</sup>.

Buyuklu et al., in a study on patients with mild and moderate inferior turbinate hypertrophies, showed that outfracture of the inferior turbinate (turbinoplasty) is an effective technique that can increase the nasal airway in these patients<sup>16</sup>. Moreover, in a recent study by Zhang et al. on 50 patients with chronic hypertrophic rhinitis and inferior

turbinate hypertrophy, it was found that inferior turbinate outfracture surgery is a proper method that can expand the nasal cavity and improve nasal ventilatory function<sup>17</sup>. The findings of the two latest studies are consistent with our results, although with different patient cohorts (inferior turbinate hypertrophies vs rhinoplasty).

The findings of our study are very similar to most previous reports on this issue, demonstrating that fracture of the inferior turbinate can be of major importance in improving nasal function, preventing post-operative obstructive symptoms and increase patient satisfaction following rhinoplasty surgeries. It also shows that turbinoplasty improves nasal airflow during both inspiration and more prominently expiration, with no association with age or sex. It also highlights that the number of patients with no significant change in nasal airflow is greater than those who experience significant worsening in airflow, meaning that due to the decreased nasal space following rhinoplasty, no change can also be interpreted as improvement. The main limitation of this study is lack of a matched control arm that may limit the conclusions. Therefore, our findings should be interpreted with caution.

As nasal obstruction following rhinoplasty is very common, further studies using the unilateral turbinoplasty technique and larger case-control studies and in different countries are recommended.

## Conclusions

Based on the evidence herein, turbinoplasty during cosmetic rhinoplasty in patients with large nose and large inferior turbinates may prevent nasal obstruction and adverse effects of surgery on nasal airflow.

## References

- <sup>1</sup> Retinger G. *Risks and complications in rhinoplasty*. *GMS Curr Top Otorhinolaryngol Head Neck Surg* 2007;6:Doc08.
- <sup>2</sup> Romo T, Pearson JM, Presti P, et al. *Rhinoplasty, Post rhinoplasty Nasal Obstruction*. New York medscape; 2007 [updated 2007 12/10/2007; cited]; Available from: <http://emedicine.medscape.com/article/841574-overview>.
- <sup>3</sup> Pontell J, Slavit DH, Kern EB. *The role of out fracture in correcting post-rhinoplasty nasal obstruction*. *Ear Nose Throat J* 1998;77:106-8.
- <sup>4</sup> Nurse LA, Duncavage JA. *Surgery of the inferior and middle turbinates*. *Otolaryngol Clin North Am* 2009;42:295-309.
- <sup>5</sup> Hakan C, Egeli E, Kutluhan A, et al. *Pneumatization of the turbinate inferior as a cause of nasal obstruction*. *Rhinology* 2001;39:109-11.
- <sup>6</sup> Hol MKS, Huizing EH. *Treatment of inferior turbinate pathology: a review and critical evaluation of the different techniques*. *Rhinology* 2000;38:157-66.
- <sup>7</sup> Chen XB, Leong SC, Lee HP, et al. *Aerodynamic effects of inferior turbinate surgery on nasal airflow – a computational fluid dynamics model*. *Rhinology* 2010;48:394-400.
- <sup>8</sup> Ghazipour A, Dilmaghani NA. *Post rhinoplastic nasal obstruction in 180 patients*. *Iran J Otorhinolaryngol* 2005;17:46-50.
- <sup>9</sup> Grymer LF. *Reduction rhinoplasty and nasal patency: change in the cross-sectional area of the nose evaluated by acoustic rhinometry*. *Laryngoscope* 1995;105:429-31.
- <sup>10</sup> Khosh MM, Jen A, Honrado C, et al. *Nasal valve reconstruction: experience in 53 consecutive patients*. *Arch Facial Plast Surg* 2004;6:167-71.
- <sup>11</sup> Courtiss EH, Goldwyn RM. *The effects of nasal surgery on airflow*. *Plast Reconstr Surg* 1983;72:9-21.
- <sup>12</sup> Mahler D, Reuven S. *The role of turbinectomy in rhinoplasty*. *Aesthetic Plast Surg* 1985;9:277-9.
- <sup>13</sup> Mlynski G, Grützenmacher S, Mlynski B, et al. [Model studies of nasal turbinate surgery]. *Laryngorhinootologie* 1993;72:614-7.
- <sup>14</sup> Selkin SG. *Laser turbinectomy as an adjunct to rhinoseptoplasty*. *Arch Otolaryngol* 1985;111:446-9.
- <sup>15</sup> Ophir D. *Resection of obstructing inferior turbinates following rhinoplasty*. *Plast Reconstr Surg* 1990;85:724-7.
- <sup>16</sup> Zhang QX, Zhou WG, Zhang HD, et al. *Relationship between inferior turbinate outfracture and the improvement of nasal ventilatory function*. *Chin J Otorhinolaryngol Head Neck Surg* 2013;48:422-5.
- <sup>17</sup> Buyuklu F, Cakmak O, Hizal E, et al. *Outfracture of the inferior turbinate: a computed tomography study*. *Plastic Reconstruct Surg* 2009;123:1704-9

Received: April 22, 2015 - Received: June 18, 2015

RHINOLOGY

# In vivo tissue response and durability of five novel synthetic polymers in a rabbit model

## *Biocompatibilità e durata in vivo di cinque nuovi polimeri sintetici testati su coniglio*

E. SAHIN<sup>1</sup>, C. CINGI<sup>2</sup>, G. ESKIIZMIR<sup>3</sup>, N. ALTINTOPRAK<sup>4</sup>, A. CALLI<sup>5</sup>, C. CALLI<sup>6</sup>, I. YILGÖR<sup>7</sup>, E. YILGÖR<sup>7</sup>

<sup>1</sup> Bayindir Icerenkoy Hospital, ENT Clinic, Istanbul; <sup>2</sup> Eskisehir Osmangazi University, Department of Otolaryngology-Head and Neck Surgery, Eskisehir, Turkey; <sup>3</sup> Celal Bayar University, Department of Otolaryngology-Head and Neck Surgery, Manisa, Turkey; <sup>4</sup> Tuzla State Hospital, ENT Clinic, Istanbul, Turkey; <sup>5</sup> Izmir Atatürk Training and Research Hospital, Department of Pathology, Izmir, Turkey; <sup>6</sup> Ekol ENT Hospital, Izmir, Turkey; <sup>7</sup> Koc University, Department of Chemistry, Istanbul, Turkey

### SUMMARY

Alloplastic materials are frequently used in facial plastic surgeries such as rhinoplasty and nasal reconstruction. Unfortunately, the ideal alloplastic material has not been found. This experimental study evaluates the tissue response and durability of five novel polymers developed as an alloplastic material. In this experimental study involving a tertiary university hospital, six subcuticular pockets were formed at the back of 10 rabbits for the implantation of each polymer and sham group. Each pocket was excised with its adjacent tissue after three months, and collected for histopathological examination. Semi-quantitative examination including neovascularisation, inflammation, fibrosis, abscess formation, multinucleated foreign body giant cells was performed, and integrity of polymer was evaluated. A statistical comparison was performed. No statically significant difference was detected in neovascularisation, inflammation, fibrosis, abscess formation and multinucleated foreign body giant cells when a paired comparison between sham and polymer II, III and IV groups was performed individually. Nevertheless, the degree of fibrosis was less than sham group in polymer I ( $p = .027$ ) and V ( $p = .018$ ), although the other variables were almost similar. The integrity of polymers III (9 intact, 1 fragmented) and IV (8 intact, 2 absent) was better than the other polymers. These novel synthetic polymers could be considered as good candidates for clinical applicability. All polymers provided satisfactory results in terms of tissue response; however, fibrovascular integration was higher in polymers II, III and IV. In addition, the durability of polymer III and IV was better than the others.

**KEY WORDS:** Alloplastic material • Polymer • Rhinoplasty • Nasal reconstruction • Bioavailability

### RIASSUNTO

*I materiali alloplastici vengono frequentemente utilizzati negli interventi di chirurgia plastica sul volto, quali la rinoplastica e la chirurgia ricostruttiva del naso. Ad oggi non è stato ancora individuato un materiale alloplastico con caratteristiche ottimali. Il presente studio sperimentale si propone di valutare la risposta tissutale e la resistenza nel tempo di cinque nuovi polimeri proposti come materiali alloplastici. Il presente studio è stato condotto presso un ospedale universitario di terzo livello. Sono state ricavate sei tasche sottocutanee sul dorso di 10 conigli che sono state usate per l'impianto di ciascuno dei polimeri testati più una tasca di controllo. Ciascuna delle tasche è stata escissa congiuntamente al tessuto circostante dopo tre mesi, ed è stata sottoposta ad un esame istopatologico. È stata quindi condotta una valutazione semi quantitativa con focus su neo angiogenesi, infiammazione, fibrosi, formazione di ascessi, presenza di cellule giganti multinucleate contenenti corpi estranei e stato dei polimeri testati. E' stata inoltre effettuata una valutazione statistica, che per quanto riguarda la comparazione diretta fra la tasca di controllo e i polimeri II, III e IV non ha mostrato differenze significative in merito alla neo vascolarizzazione, all'infiammazione, alla fibrosi, alla presenza di ascessi ed alla presenza di cellule giganti multinucleate. Il polimero I ha invece mostrato un grado di fibrosi inferiore rispetto alla tasca di controllo ( $p = .027$ ) and V ( $p = .018$ ), benché le altre variabili prese in considerazione fossero sostanzialmente uguali. L'integrità nel tempo dei polimeri III (9 intatti, uno frammentato) e IV (8 intatti, 2 assenti) è stata migliore di quella ottenuta con gli altri polimeri testati. Questo gruppo di nuovi polimeri può essere considerato interessante per future applicazioni cliniche. Tutti i polimeri hanno mostrato risultati accettabili in termini di risposta dei tessuti, tuttavia i fenomeni di integrazione fibrovascolare sono stati maggiori nel caso dei polimeri II, III e IV. Inoltre la durata nel tempo dei polimeri III e IV è stata la migliore in assoluto.*

**PAROLE CHIAVE:** Materiali alloplastici • Polimeri • Rinoplastica • Ricostruzione nasale • Biocompatibilità

## Introduction

Alloplastic materials play a significant role and are widely used in the field of facial plastic and reconstructive surgery, although autogenous tissues (e.g. cartilage, bone, skin/dermis, etc.) are generally preferred for most cases, if possible. They generally provide a significant decrease in operative time and prevent donor-site morbidity, especially in revision cases in whom a second surgical site for harvesting a graft is almost always inevitable<sup>1</sup>. A virtual explosion in the technologies of alloplastic materials has taken place; indeed, several types of different alloplastic materials such as expanded polytetrafluoroethylene (Gore-Tex; W. L. Gore and Associates, Flagstaff, Ariz), silicone rubber (such as silastic), polyethylene (such as Medpore; Porex, Fairburn, Ga), plastipore (Richards Manufacturing Company, Memphis, Tenn), polyesters and polyamides (such as Dacron; Ethicon Inc., Somerville, NJ), Mersilene (Ethicon Inc), Supramid (S. Jackson Inc, Alexandria, Va), Cooley Dacron knitted implant (Meadox; Boston Scientific, Quincy, Mass) have been used in different aspects of surgery in order to reconstruct or augment facial structures or improve deformities. Unfortunately, most of these alloplastic materials have different amounts of potential risk for inflammatory reaction, extrusion, infection and resorption<sup>2-5</sup>. Therefore, an ideal alloplastic material should be: (i) biocompatible, (ii) non-carcinogenic, (iii) non-mutagenic, (iv) non-antigenic, (v) resistant to infections, (vi) durable, (vii) easily carved, (viii) pliable, (ix) easily fixed and removed, (x) inexpensive and (xi) available in sufficient quantities.

Biocompatibility has been recently defined as “*the ability of a material to perform its desired function with respect to a medical therapy, without eliciting any undesirable local or systemic effects in the recipient or beneficiary of that therapy, but generating the most appropriate beneficial cellular or tissue response in that specific situation, and optimizing the clinically relevant performance of that therapy*”<sup>6</sup>. Therefore, the main component of biocompatibility is tissue response. It is well known that once a tissue is injured for the implantation of an alloplastic material, a wound healing response which constitutes a sequence of complex events such as neovascularisation, inflammatory reaction, fibrosis and foreign body reaction take place in the adjacent tissues. Experimental and clinical studies have demonstrated that physical and chemical properties of alloplastic materials may influence and affect host response and lead to extrusion, overinflammation, infection and resorption or fragmentation of implants<sup>2-5</sup>. Therefore, the search for an ideal alloplastic material still remains a challenge. In this study, five novel synthetic polymers were introduced as potential candidates for clinical application. Moreover, durability of polymers and quality and intensity of tissue response against polymers were histologically examined in a rabbit model.

## Materials and methods

The experimental study was approved by the Research Ethics Committee of the Eskişehir Osmangazi University and DETAM (Eskişehir Osmangazi University Hospital Experimental Study Center), Eskişehir. All procedures were supervised by a veterinarian. Animals were placed in appropriate cages and had free access to water and a standardised commercial ration.

Ten adult New Zealand Albino rabbits, weighting between 2.5 and 4 kg and aged between 15 to 18 months, were included and followed for three months. The pieces of polymers were prepared in a standardised fashion (0.5x0.5 cm in size). All pieces were packed separately and sterilised in a gas autoclave prior to surgery.

### Polymer production

Five newly synthesised polymers were used in this study. The properties of these materials were as follows:

1. ELASTOSIL LR3003/20 (shore hardness 30A, soft);
2. ELASTOSIL LR3003/30 (shore hardness 37A, medium soft);
3. IY-PO-03-149-B FTPU (fluorinated thermoplastic polyurethane) (shore hardness 50A, medium soft);
4. PTMO-1K/PDMS/50% EXTR (shore hardness 90A, hard);
5. PTMO1K/PDMS/40% EXTR (shore hardness 80A, hard).

### Physical and chemical properties of polymers

*ELASTOSIL LR3003/20 and ELASTOSIL LR3003/30:* Both polymers were highly elastic, cross-linked silicone rubbers supplied by Wacker Chemie. They were obtained by the platinum catalysed reactions of methylhydrogen-siloxane oligomers with methylvinylsiloxane oligomers. Elastosil rubbers were usually filled with small amounts of fumed silica and display good mechanical integrity.

*IY-PU-03-149-B (FTPU (fluorinated thermoplastic polyurethane):* Poly(tetramethylene oxide) glycol (PTMO-2000) with a <Mn> value of 2040 g/mol was kindly provided by DuPont, USA. Fluorolink E10 H, which is an ethylene glycol terminated perfluoroether oligomer (E10 H) with a <Mn> value of 1400 g/mol, is a product of Solvay Solexis, Belgium. Bis(4-isocyanatocyclohexyl) methane (HMDI) (99.5%) was supplied by Bayer. 2-methyl-1,5-diaminopentane (Dytek A) (DuPont) and reagent grade reaction solvents, isopropyl alcohol (IPA) (Merck) and tetrahydrofuran (THF) (Merck) were all used as received. Dibutyltindilaurate (DBTDL) catalyst was obtained from Air Products, USA. The polymerisation procedure was conducted in a 3-neck, round-bottom Pyrex flask equipped with an overhead stirrer, addition funnel and thermometer. Reaction was carried out by using a two-step procedure. PTMO-2000 2.283 g (1.119 mmol), E10 H 2.264 g (1.617 mmol) and HMDI 1.203 g (4.585



mmol) were weighed into the reactor, stirred and heated to 70°C. Next, 150 ppm of DBTDL in THF was added as the catalyst and the reaction was continued for 60 min to form the prepolymer. The mixture was then cooled to room temperature, dissolved in 15 g of THF and diluted with 8 g of IPA. Chain extender, 0.215 g (1.849 mmol) Dytek A, was dissolved in 7 g IPA and added to the reaction mixture drop-wise, under strong agitation. The yield was quantitative. Polymer films were prepared by solution casting into Teflon molds from THF/IPA. The solvent was first evaporated in an air oven at 50°C overnight and then in a vacuum oven at 50°C until constant weight was reached. Films obtained were kept in sealed polyethylene bags in a desiccator.

*PTMO-1K/PDMS/40% EXTR and PTMO1K/PDMS/50% EXTR:* These polymers are polyurethaneurea elastomers based on PTMO-1000 and polydimethylsiloxane (PDMS-2000). They contained 40% and 50% by weight of PDMS, respectively, for improved biocompatibility. They were obtained by melt polymerisation in a twin-screw extruder.

#### *Animals and implantation procedure*

All experiments were performed under anaesthesia using intramuscular injection of xylazine (5 mg/kg) and ketamine (50 mg/kg). Six surgical pockets for five polymer implantations and sham operation were generated to the dorsal area of rabbits after a skin incision of 1.5 cm in size, and undermining and elevation of subcutaneous tissue. All surgical pockets were performed approximately 2 cm apart from each other. Afterwards, pieces of pre-shaped and sterilised polymers were administered into the surgical pockets and placed just over muscles, under the subcutaneous tissue. Skin incisions were closed by simple interrupted sutures of mononylon 3-0 sutures. In the sham group, all surgical procedures were performed similarly except for polymer implantation.

The animals were given a single injection of intramuscular ceftriaxone (100 mg/kg) for five days, and followed for a period of three months. None of the polymers were extruded during the experimental period. All rabbits were sacrificed with anaesthetic (combination of xylazine and ketamine) overdose at the end of 3 months. The surgical pockets at the sites of polymer implantation and sham sites were dissected and excised. The integrity of polymer (absent, fragmented or intact) was evaluated and noted initially. Finally, all specimens were immediately fixed in neutralised 10% buffered formaldehyde for histopathological examination.

#### *Histopathological examination*

Sections of 5 µm in size were obtained from paraffin blocks and processed individually. Paraffin sections were submitted to deparaffinisation in xylene for a short time and followed by rehydration in decreasing alcohol solu-

tions. All sections were embedded. The paraffin sections were stained with haematoxylin-eosin and toluidine Blue for histopathological examination. The areas of tissue adjacent to the implants were first observed under low magnification and later scrutinised under high magnification. The tissue response was examined and graded with the following criteria: (i) vascular congestion (mild congestion, significant congestion with dilated vessels, highly dilated vessels with red blood cell extravasation), (ii) inflammation (absent, mild, moderate, intense), (iii) fibrosis (absent, present of fibroblasts alone, reparative fibroblastic proliferation with thickness), (iv) abscess formation (absent, present), (v) foreign body giant cell (absent, present).

All histopathological examinations were performed by a blinded board-certified pathologist.

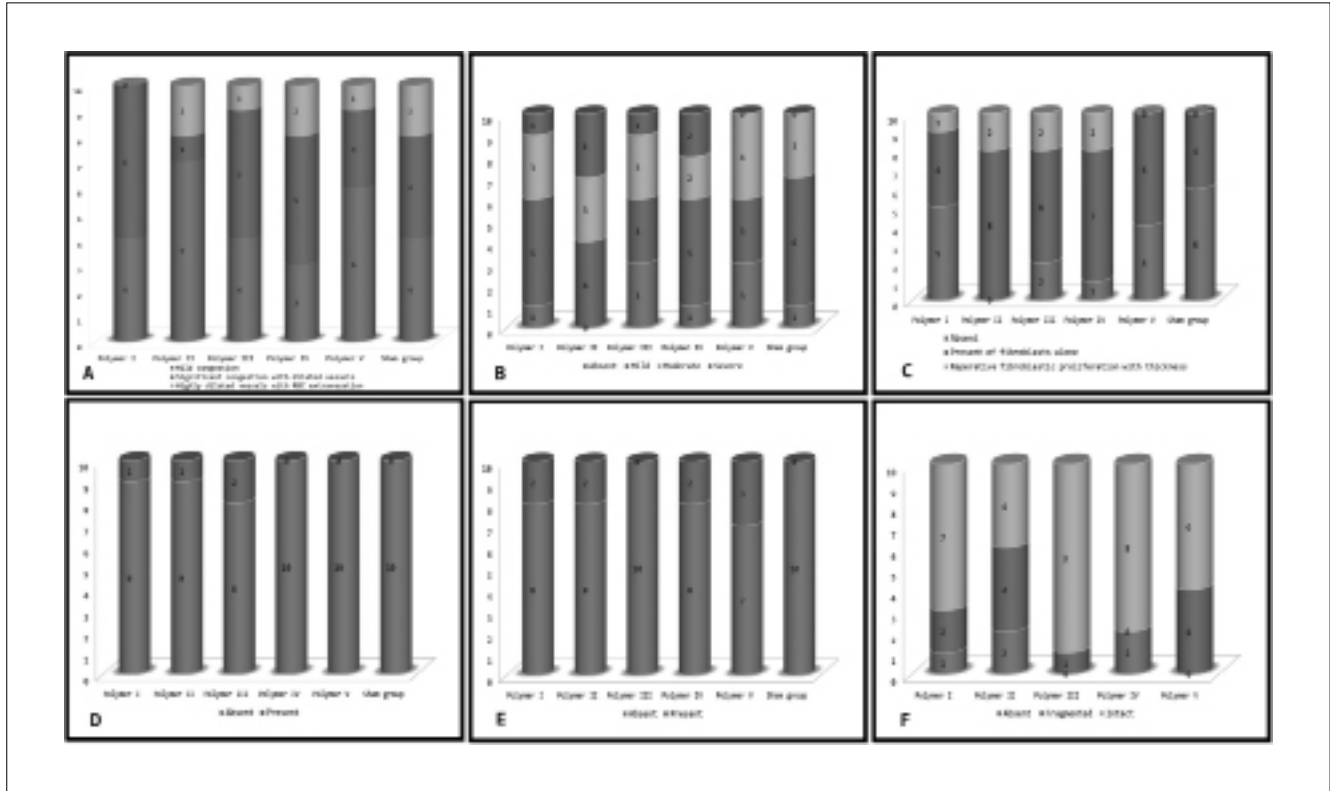
#### *Statistical analysis*

The statistical analysis was performed using SPSS for Windows 17.0. A paired comparison between polymers and sham group was performed for each variable individually using the chi square test. A p value <0.05 was considered statistically significant.

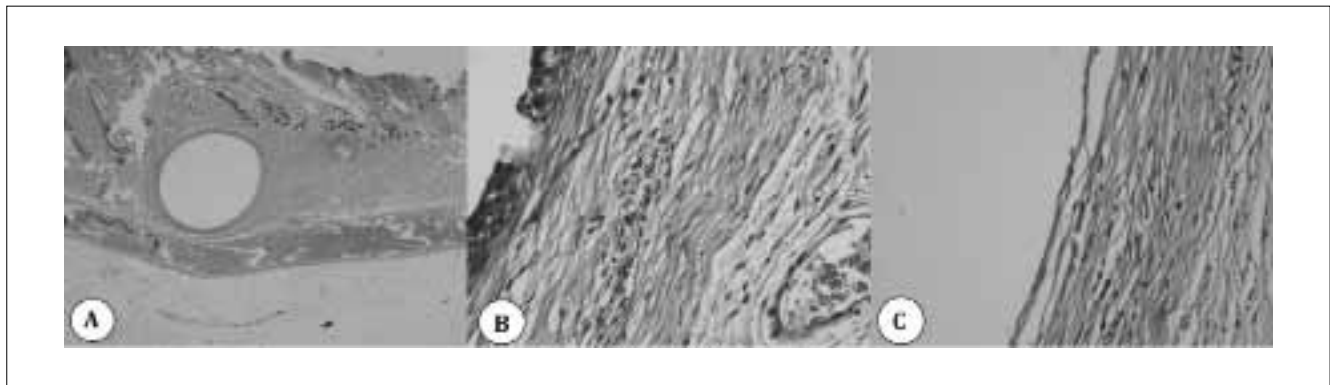
## **Results**

None of the animals was lost before the planned schedule. All polymers were tolerated well without causing gross infection, and no extrusion was observed. The distribution of tissue responses in polymer and sham groups are presented in Figure 1. The degree of vascularisation is very similar to sham group in polymers II and III, although none of the polymers demonstrated a statistically significant difference compared with the sham group (Table I). The inflammatory reaction against all polymers was comparable with sham group (Fig. 2A-C, Table I). No significant difference was observed when comparisons between polymer II-sham group, polymer III-sham group and polymer IV-sham group were performed according to the degree of fibrosis (Fig. 2A-C, Table I). On the other hand, the statistical comparison between polymer I-sham group and polymer V-sham group showed significant differences in the favour of sham group ( $p = .027$  and  $p = .018$ ). Finally, when polymer groups were individually compared with sham group according to the presence of abscess formation and multinucleated foreign body giant cell, none of the polymers showed a statistically significant difference (Table I).

The durability of polymer III was considered excellent (90% intact) as shown in Figure 1. In addition, the durability of polymer IV (80% intact) and I (70% intact) was acceptable. However, more than half of polymer II was fragmented or lost at the end of the experiment. However, no significant difference was detected when polymer II-III, polymer II-IV, polymer II-I and polymer II-V were



**Fig. 1.** The distribution of tissue response [neovascularisation (A), inflammation (B), fibrosis (C), abscess formation (D), foreign body giant cell (E) and integrity of polymers (F)] in polymer and sham groups.



**Fig. 2.** Photomicrograph showing the intact implant material (haematoxylin and eosin, x40). (A), Infiltration of the connective tissue capsule surrounding the implant by the inflammatory infiltrate which is mainly composed of lymphocytes and plasma cells (B), accompanied by eosinophils in some (C).

compared according to durability ( $p = 0.057$ ,  $p = 0.069$ ,  $p = 0.403$  and  $p = 0.301$ ).

**Discussion**

Several alloplastic materials have been used in surgery. In general, they shorten the duration of surgery, reduce trauma to donor region and are readily available. However, one of the main drawbacks of these alloplastic mate-

rials is tissue response, which may also lead to extrusion and/or poor resistance to infection. Therefore, the quest for finding an ideal alloplastic material still remains of wide interest. In this study, five new synthetic polymers, differing in physical structure and hardness, were introduced as potential candidates for clinical application. An *in vitro* experimental model was preferred for assessment of tissue response and durability of these polymers, and histopathological examination, a gold standard technique

**Table I.** Statistical comparison between polymer and sham groups according to neovascularisation, inflammation, fibrosis, abscess formation and multinucleated foreign body giant cells.

	Neovascularisation	Inflammation	Fibrosis	Abscess formation	Multinucleated foreign body giant cell
Polymer I-Sham group	0.301	0.779	0.027†	0.305	0.136
Polymer I-Polymer II	0.041†	.550	0.036†	1.000	1.000
Polymer I-Polymer III	0.580	0.682	0.364	0.531	0.136
Polymer I-Polymer IV	0.327	0.912	0.148	0.305	1.000
Polymer I-Polymer V	0.301	0.450	0.470	0.305	0.606
Polymer II-Sham group	0.270	0.221	0.329	0.305	0.136
Polymer II-Polymer III	0.148	0.246	0.319	0.531	0.136
Polymer II-Polymer IV	0.118	0.680	0.587	0.305	1.000
Polymer II-Polymer V	0.494	0.099	0.043†	0.305	0.606
Polymer III-Sham group	0.801	0.392	0.264	0.136	NS
Polymer III-Polymer IV	0.788	0.566	0.815	0.136	0.136
Polymer III-Polymer V	0.638	0.767	0.264	0.136	0.060
Polymer IV-Sham group	0.881	0.514	0.418	NS	0.136
Polymer IV-Polymer V	0.400	0.244	0.144	NS	0.606
Polymer V-Sham group	0.645	0.343	0.018	NS	0.060

NS: Not computed because parameter was a constant. †Statistically significant ( $p < 0.05$ ).

for determining the degree of tissue response, was performed<sup>3,5,7</sup>. The assessment of tissue response includes neovascularisation, inflammation, fibrosis, abscess formation and multinucleated foreign body giant cells.

Previous histopathological examination of explanted porous polyethylene implants demonstrated a significant decrease in fibrovascular invasion, increase in inflammatory reaction and presence of multinucleated foreign body cells<sup>8</sup>. In this study, none of the polymers was extruded, which considered a high tissue ingrowth and low inflammatory response. In fact, implants that have a high capacity of fibrovascular integration are prone to behave more like natural tissue; thus, they can become more stable and more resistant to infections. In addition, Naik et al. emphasised the positive effect of vascularisation for reduction of extrusion, migration and infection after polymer implantation<sup>9</sup>. In this experimental study, assessment of neovascularisation showed similar histological findings in all experimental groups (polymer implanted and sham groups) (Fig. 1 and Table I). On the other hand, the degree of fibrosis seems in favour of polymers II, III and IV, although no statistically significant difference was detected when compared with the sham group (Fig. 1 and Table I). However, the degree of fibrosis was less than sham group for polymer I ( $p = 0.027$ ) and V ( $p = 0.018$ ). Therefore, complete invasion by fibrovascular tissue at the site of polymer implantation, especially in polymers II, III and IV, was demonstrated. Sclafani et al. examined the tolerability of porous high-density polyethylene and nonporous silicone implants in an experimental study, and observed better fibrovascular integration with porous high-density

polyethylene<sup>2</sup>. Moreover, they detected no inflammatory cells in the periphery of implant, even though several other studies have demonstrated a vibrant inflammatory response with porous polytetrafluoroethylene<sup>10-12</sup>. This experimental study found no sign of increase in inflammatory response at the adjacent sites of polymer implantation (Fig. 1 and Table I). Moreover, the presence of multinucleated foreign body giant cell, an important indicator of vigorous inflammatory response to implants, was not significantly different when individual comparison between polymer and sham groups was performed (Table I). Therefore, high tolerability against all polymers was seen, although better results were observed with polymers III and IV.

The moulding and fashioning of an implant is crucial, especially for facial reconstructive and aesthetic surgeries. Softer implants are generally preferred because they can be easily carved and structured, and have a more natural appearance. Polymers I, II and III are softer materials; therefore, moulding and fashioning of these polymers is easier than with polymers IV and V. Finally, one of the most important characteristics of an ideal alloplastic material is the durability and/or firmness of an implant. An ideal implant should preserve its integrity, which is essential for long-term stability. In this experimental study, the durability of all synthetic polymers was acceptable, and no significant difference was seen when a paired comparison was performed (Fig. 1 and Table I). Nevertheless, polymers III (90% intact) and IV (80% intact) demonstrated the highest reliability.

## Conclusions

Five novel synthetic polymers have been developed and introduced as potential candidates for clinical application. In this experimental study, histopathological examination of tissue response against these polymers demonstrated high tolerability, especially with polymers II, III and IV. In addition, polymers III and IV had a better durability and protected their integrity. Therefore, these synthetic polymers may be suitable for facial plastic and reconstructive surgery; however, further studies are also required to evaluate their biocompatibility.

## References

- <sup>1</sup> Vuyk HD, Adamson PA. *Biomaterials in rhinoplasty*. Clin Otolaryngol Allied Sci 1998;23:209-17.
- <sup>2</sup> Sclafani AP, Romo III T, Silver L. *Clinical and histologic behavior of exposed porous high-density polyethylene implants*. Plast Reconstr Surg 1997;99:41-50.
- <sup>3</sup> Batniji RK, Hutchison JL, Dahiya R, et al. *Tissue response to expanded polytetrafluoroethylene and silicone implants in a rabbit model*. Arch Facial Plast Surg 2002;4:111-3.
- <sup>4</sup> Uysal A, Kayiran O, Karaaslan O, et al. *Evaluation and management of exposed high-density porous polyethylene implants: an experimental study*. J Craniofac Surg 2006;17:1129-36.
- <sup>5</sup> Kolb CM, Pierce LM, Rooft SB. *Biocompatibility comparison of novel soft tissue implants vs commonly used biomaterials in a pig model*. Otolaryngol Head Neck Surg 2012;147:456-61.
- <sup>6</sup> Williams DF. *On the mechanisms of biocompatibility*. Biomaterials 2008;29:2941-53.
- <sup>7</sup> Amorim WL, Costa HO, Souza FC, et al. *Experimental study of the tissue reaction caused by the presence of cellulose produced by Acetobacter xylinum in the nasal dorsum of rabbits*. Braz J Otorhinolaryngol 2009;75:200-7.
- <sup>8</sup> Chuo JY, Dolman PJ, Ng TL, et al. *Clinical and histopathologic review of 18 explanted porous polyethylene orbital implants*. Ophthalmology 2009;116:349-54.
- <sup>9</sup> Naik MN, Murthy RK, Honavar SG. *Comparison of vascularization of Medpor and Medpor-Plus orbital implants: a prospective, randomized study*. Ophthalm Plast Reconstr Surg 2007;23:463-7.
- <sup>10</sup> Spector M, Harmon SL, Kreutner A. *Characteristics of tissue growth into Proplast and porous polyethylene implants in bone*. J Niomed Mater Res 1979;13:677-92.
- <sup>11</sup> Maas CS, Merwin GE, Wilson J, et al. *Comparison of biomaterials for facial bone augmentation*. Arch Otolaryngol Head Neck Surg 1990;116:551-6.
- <sup>12</sup> Wellisz T, Dougherty W, Gross J. *Craniofacial applications for the Medpor porous polyethylene flexblock implant*. J Craniofac Surg 1992;101-7.

Received: November 15, 2015 - Accepted: January 15, 2016



SKULL BASE

# Endoscopic endonasal approach to the craniocervical junction: the importance of anterior C1 arch preservation or its reconstruction

## *Approccio endoscopico endonasale alla giunzione craniocervicale: l'importanza di preservare o ricostruire l'arco anteriore dell'atlante*

M. RE<sup>1</sup>, M. IACOANGELI<sup>2</sup>, L. DI SOMMA<sup>2</sup>, L. ALVARO<sup>2</sup>, D. NASI<sup>2</sup>, G. MAGLIULO<sup>3</sup>, F.M. GIOACCHINI<sup>1</sup>, D. FRADEANI<sup>1</sup>, M. SCERRATI<sup>2</sup>

<sup>1</sup> Department of Otorhinolaryngology, Umberto I University General Hospital, Università Politecnica delle Marche, Ancona, Italy; <sup>2</sup> Department of Neurosurgery, Umberto I University General Hospital, Università Politecnica delle Marche, Ancona, Italy; <sup>3</sup> Organi di Senso Department, University "la Sapienza", Rome, Italy

### SUMMARY

We report our experience with the endoscopic endonasal approaches (EEA) for different craniocervical junction (CCJ) disorders to analyse outcomes and demonstrate the importance and feasibility of anterior C1 arch preservation or its reconstruction. Between January 2009 and December 2013, 10 patients underwent an endoscopic endonasal approach for different CCJ pathologies at our Institution. In 8 patients we were able to preserve the anterior C1 arch, while in 2 post-traumatic cases we reconstructed it. The CCJ disorders included 4 cases of irreducible anterior bulbo-medullary compression secondary to rheumatoid arthritis or CCJ anomalies, 4 cases of inveterate fractures of C1 and/or C2 and 2 tumours. Pre- and postoperative neuroradiological evaluation was always obtained by magnetic resonance imaging (MRI), computed tomographic (CT) scanning and dynamic cranio-vertebral junction x-ray. Pre- and postoperative neurologic disability assessment was obtained by Ranawat classification for patients with rheumatoid arthritis and by Nurick classification for the others. At a mean follow-up of 31 months (range: 14-73 months), an improvement of at least one Ranawat or Nurick classification level was observed in 6 patients, while in another 4 patients neurological conditions were stable. Radiological follow-up revealed an adequate bulbo-medullary decompression in all patients and a regular bone fusion in cases of C1 and/or C2 fractures. In all patients spinal stability was preserved and none required subsequent posterior fixation. The endoscopic endonasal surgery provided adequate exposure and a low morbidity minimally invasive approach to the antero-medial located lesions of the CCJ, resulting in a safe, effective and well-tolerated procedure. This approach allowed preservation of the anterior C1 arch and the avoidance of a posterior fixation in all patients of this series, thus preserving the rotational movement at C0-C2 segment and reducing the risk of a subaxial instability development.

**KEY WORDS:** Endoscopic endonasal surgery • C2 odontoidectomy • Anterior C1 arch preservation • Spine instability

### RIASSUNTO

*Riportiamo la nostra esperienza con l'approccio endoscopico endonasale (EEA) in una serie consecutiva di 10 pazienti affetti da lesioni anteriori della giunzione cranio-cervicale. L'obiettivo dello studio è analizzare l'outcome di questi pazienti focalizzando l'attenzione sulla possibilità di preservare o ricostruire l'arco anteriore di C1, quale importante elemento di stabilità della giunzione cranio-cervicale. Dal gennaio 2009 al dicembre 2013, 10 pazienti con patologia della giunzione craniocervicale sono stati operati mediante approccio endoscopico endonasale. Le lesioni trattate includevano 4 casi di non riducibile compressione bulbo-midollare extradurale anteriore della giunzione (secondarie ad artrite reumatoide o anomalie della giunzione), 4 casi di fratture inveterate di C1 o del dente dell'epistrofeo e 2 casi lesioni tumorali. La valutazione clinica pre- e postoperatoria è stata effettuata mediante la scala di Ranawat per i casi di artrite reumatoide e di Nurick per gli altri. Il follow-up radiologico comprendeva invece RM, TC e RX con prove morfo-dinamiche per eventuale preesistente severa instabilità. Dopo l'approccio EEA puro alla giunzione craniocervicale, nessun paziente ha presentato un peggioramento neurologico, né si sono verificate significative complicanze. Al follow-up medio di 31 mesi (range 14-73 mesi), un miglioramento di almeno un livello della classificazione Ranawat o Nurick si è osservato in 6 pazienti mentre gli altri 4 sono rimasti stabili. Il follow-up neuroradiologico ha documentato in tutti i casi un'adeguata decompressione bulbo-midollare, mentre nei casi di frattura di C1 o C2 una regolare fusione ossea delle rime di frattura. Nessun paziente ha presentato segni di instabilità e non è stata pertanto necessaria alcuna procedura di stabilizzazione e fusione posteriore. L'approccio endoscopico endonasale garantisce un'adeguata esposizione delle lesioni antero-mediali della giunzione craniocervicale. Nella nostra serie di pazienti tale procedura ha permesso di preservare o ricostruire l'arco anteriore di C1, evitando quindi una sintesi posteriore e la relativa perdita di movimento rotazionale C0-C2 e l'instabilità subassiale.*

**PAROLE CHIAVI:** Chirurgia endoscopica endonasale • Odontoidectomia • Risparmio arco anteriore dell'atlante • Instabilità spinale

## Introduction

The craniocervical junction (CCJ) represents a surgical challenge because of the complexity of its anatomy and difficulty in accessing it in a minimally invasive manner. Anterior approaches for ventral pathology of the CCJ have traditionally involved open surgical procedures. The transoral-transpharyngeal approach is still the treatment of choice in a variety of diseases affecting the CCJ, including inflammatory (rheumatoid), post-traumatic atlantoaxial disease and neoplastic diseases<sup>1,2</sup>.

This approach provides good exposure, but it includes some disadvantages such as a deep surgical corridor, a non-direct angle to the region, potential damages related to tongue retraction, palate splitting and upper airway swelling, risk of a postoperative oral flora contamination and prolonged intubation<sup>3</sup>.

Recently, Kassam et al.<sup>4</sup> proposed a new approach: the endoscopic endonasal route (EEA). EEA provides a “natural” anterior corridor that avoids many of the transoral approach-related morbidities<sup>4-6</sup>. Furthermore, the endonasal endoscopic route allows a straightforward and better working angle with the possibility to preserve the anterior arch of C1 that is critical for the biomechanical stability of the occiput-C2 segment<sup>7-8</sup>.

We report our experience with the EEA for CCJ diseases to assess outcomes, advantages and limitations of this procedure, and to further stress the importance and feasibility of the anterior C1 arch preservation or its reconstruction, in most cases.

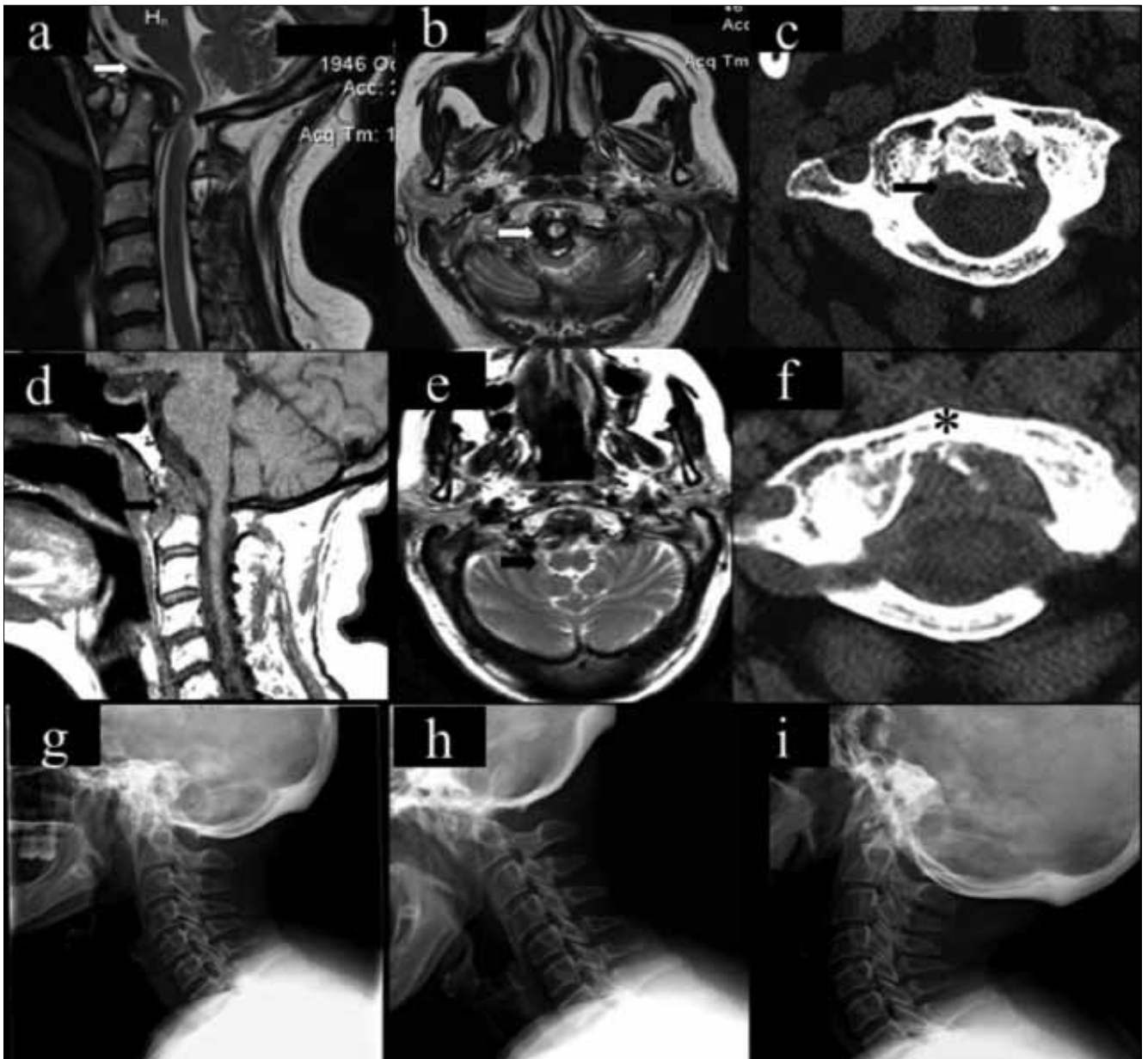
## Materials and methods

Between January 2009 and December 2013, 27 patients underwent pure endoscopic endonasal approach for different CCJ diseases at our Institution. Among these, in 8 patients we were able to preserve the anterior C1, while in 2 patients the integrity of the anterior C1 arch was restored. The present series includes 3 males and 7 females. Mean age was 60.6 years (range: 18-81 yr). As reported in Table I, two patients had post-traumatic inveterate C2 Anderson-D'Alonso type II fractures with pseudo-arthrosis, 3 had irreducible anterior bulbo-medullary compression related to rheumatoid arthritis (basilar invagination and/or rheumatoid pannus), 1 presented with an atlanto-occipital malformation with platibasia and basilar invagination, 1 had a C1-C2 meningioma and 1 harboured CCJ cancer metastasis. Finally, the last two patients with atlas fracture non-union after conservative treatment (the second in combination with Anderson-D'Alonso type II odontoid fracture) were treated by a fully endoscopic endonasal anterior C1 arch reconstruction, in one patient combined along with the anterior transcervical screwing for the C2 fracture. Informed consent had been obtained at the time of surgery from all patients included in the study.

Preoperative evaluation always included physical neurological examination, magnetic resonance imaging (MRI), computed tomographic (CT) scanning with multiplane reconstruction and angiographic sequences, and dynamic craniocervical junction X-ray, when feasible without excessive risks, to evaluate a potential instability of the CCJ. Pre- and post-operative neurologic disability assessment was obtained by Ranawat classification for patients with rheumatoid arthritis and by Nurick classification for the other ones<sup>9,10</sup>. Postoperative neuroradiologic workup was scheduled by immediate CT scan and by MRI at 1-3 and 6 months depending on the pathology (neoplastic or not), MRI yearly (to check for the myelopathy), CT scan (to verify the completeness of the arthrodesis process) and dynamic X-ray (to assess spinal stability). Serial office-based endoscopic controls were performed routinely after surgery. The first outpatient endoscopic control was carried out 3-4 days after surgery for removal of nasal tampons under endoscopic guidance. During this procedure, after removal of nasal tampons, nasal cavities and nasopharyngeal mucosa was inspected. Gentle suction and forceps were used to clean the nostrils and nasal cavities from any soft blood clot and/or nasal secretions up to the nasopharyngeal mucosa. In case of small mucosa dehiscence defect, fresh autologous blood was injected over the nasopharyngeal mucosa to speed up healing. Before discharge, usually after 1 week, and 15 days, 1 month and 3 months thereafter, all patients underwent endoscopic follow-up while awake to evaluate the status of nasal mucosa. The mean follow-up was 31 months (range: 14-73 months).

### *Surgical technique*

All the EEA were performed by a multidisciplinary team composed of a senior neurosurgeon and the senior Ear, Nose and Throat (ENT) surgeon. Patients with anterior irreducible bulbo-medullary compression underwent endoscopic endonasal odontoidectomy with anterior C1 arch preservation (Fig. 1 a-f). The principal steps of this procedure have already been described<sup>11-15</sup>. Briefly, surgical procedures were carried out using rod lens endoscopes (4 mm in diameter, 18 cm in length, 0° scope) with a high-definition camera. In all operations, we adopted the neuronavigation system and, in some cases of fractures, fluoroscopy was used to check the correct positioning of cannulated screws and plates. Routinely, the posterior part of the hard palate was thinned by drilling out the outer bone layer, making the hard palate more flexible to enhance the angle of “nasopalatine line” (Fig. 2a). Then, after the identification of anterior C1 tubercle by anatomical landmarks and neuronavigation, a small linear incision (about 3 cm) was made in the midline of the nasopharyngeal mucosa (Fig. 2b). After subperiosteal preparation, all efforts were made to preserve the anterior arch of the atlas by drilling the odontoid base which weakens in its api-



**Fig. 1.** Patient 2 (see Table I). A 65-year-old woman, with a long-lasting history of rheumatoid arthritis and recent onset of drop attacks. A, B. Pre-operative sagittal and axial T2 MRI images demonstrating basilar invagination and rheumatoid pannus with resulting severe bulbomedullary compression and associated myelopathy (white arrows). C. Pre-operative axial CT scan showing the peri-odontoid rheumatoid pannus (black arrow). D, E. Post-operative sagittal T1 and axial T2 MRI images showing the adequate spinal cord decompression after odontoidectomy and rheumatoid pannus removal, as highlighted by the increased cerebrospinal fluid space ventral to the bulbomedullary junction (black arrows). F. Postoperative axial CT scan illustrating the anterior C1 arch integrity (asterisk). G, H, I. One-year follow-up normal and dynamic cervical X-ray showing the absence of cranial settling and C1-C2 instability.

cal part so that it can be then easily pulled downward in the working area and removed along with any remaining compressive inflammatory lesions, using a combination of high-speed drill, ultrasonic bone curette and standard Kerrison rongeurs. The wide surgical cavity was subsequently inspected by angled lens endoscope and anatomical limits of resection were verified by neuronavigation (Fig. 2c-h). Finally, the nasopharyngeal defect was sutured (Fig. 2i). In the case of C1-C2 neoplastic lesions,

the surgery proceeded with the dural opening and tumour removal.

For inveterate C2 Anderson-D'Alonso type II fractures, the operation consists in an anterior transcervical odontoid screw fixation combined, at the same session, with a transnasal endoscopic approach to the odontoid. In these cases, the EEA allows inflammatory pannus removal (related to the pseudoarthrosis process) between the bony fragments and subsequent "in situ" anterior arthrodesis by

**Table I.** Summary of patient profiles.

**RA** = rheumatoid arthritis; **CCJ** = craniocervical junction; **EEO** = endoscopic endonasal odontoidectomy; **EEA** = endoscopic endonasal approach.

Patient no	Age (sex)	Primary Disease	Clinical status Preop/ Postop	Treatment
1	54 (F)	RA, irreducible bulbo-medullary compression secondary to basilar invagination and rheumatoid pannus	Ranawat Grade IIIa/II	EEO + RA pannus removal
2	65 (F)	RA, irreducible bulbo-medullary compression secondary to basilar invagination and rheumatoid pannus	Ranawat Grade III/II	EEO + RA pannus removal
3	49 (M)	Inveterate C1 fracture with cranial settling	Nurick Grade 0/0	EE C1 arch reconstruction (with autologous bone and titanium mash)
4	61 (F)	RA, irreducible bulbo-medullary compression secondary to basilar invagination and rheumatoid pannus	Ranawat Grade III/II	EEO + RA pannus removal
5	59 (F)	CCJ meningioma	Nurick Grade I/II	Complete removal with EEA
6	63 (F)	CCJ osteolytic cancer metastasis	Nurick Grade 0/0	Subtotal removal with EEA
7	77 (F)	Inveterate C2 fracture with pseudarthrosis (Anderson-D'Alonso type II)	Nurick Grade IV/IV	Anterior transcervical screwing + endoscopic anterior arthrodesis
8	18 (M)	Platibasia with basilar invagination and dens dislocation	Nurick Grade I/II	EEO
9	81 (F)	Inveterate C2 fracture with pseudarthrosis (Anderson-D'Alonso type II)	Nurick Grade III/II	anterior transcervical screwing + endoscopic anterior arthrodesis
10	79 (M)	Inveterate C1 and C2 fracture (Anderson-D'Alonso type II) with pseudo-arthritis	Nurick Grade IV/III	anterior transcervical screwing + endoscopic anterior arthrodesis + Endoscopic endonasal C1 arch reconstruction (plate and screws)

packaging the autologous bone and/or bone substitutes in the fracture space up to the underlying clivus. This combined approach may grant a minimally invasive direct access to the odontoid fractures for the removal of the pseudoarthrosis cloth aiming at cleaning the bone borders up to the normal cancellous bone just before the subsequent anterior screw fixation by self-tapping screws for a better fracture healing and spinal realignment.

In one patient, with a combination of anterior C1 arch fracture and odontoid fracture (Fig. 3ab), after anterior transcervical screwing and endoscopic endonasal arthrodesis of the odontoid fracture, we rebuilt the integrity of the anterior arch of C1 stumps by placing bone chips compressed between the bone under endoscopic control that were then fixed by three screws and one plate (Fig. 3cdef). This procedure was performed during EEA by insertion of

three guide wires under fluoroscopy and neuronavigation control into the edges of C1 fractures and into the tip of odontoid. The wires then guided the insertion of the cannulated screws inserted under imaging control until they reached the posterior cortex of the odontoid (Fig. 4a-h). The length of the screw was determined pre-operatively on the basis of CT scan and intraoperatively by neuronavigation supplemented by fluoroscopy. This step was useful just to guarantee temporary stabilisation of the autologous bone during the arthrodesis process and to avoid the further displacement of C1 articular masses. Finally, the last patient with a non-union anterior atlas fracture after conservative treatment that developed C1 lateral masses displacement with cranial settling, was treated by a fully endoscopic endonasal anterior C1 arch reconstruction using autologous bone graft and titanium mash.

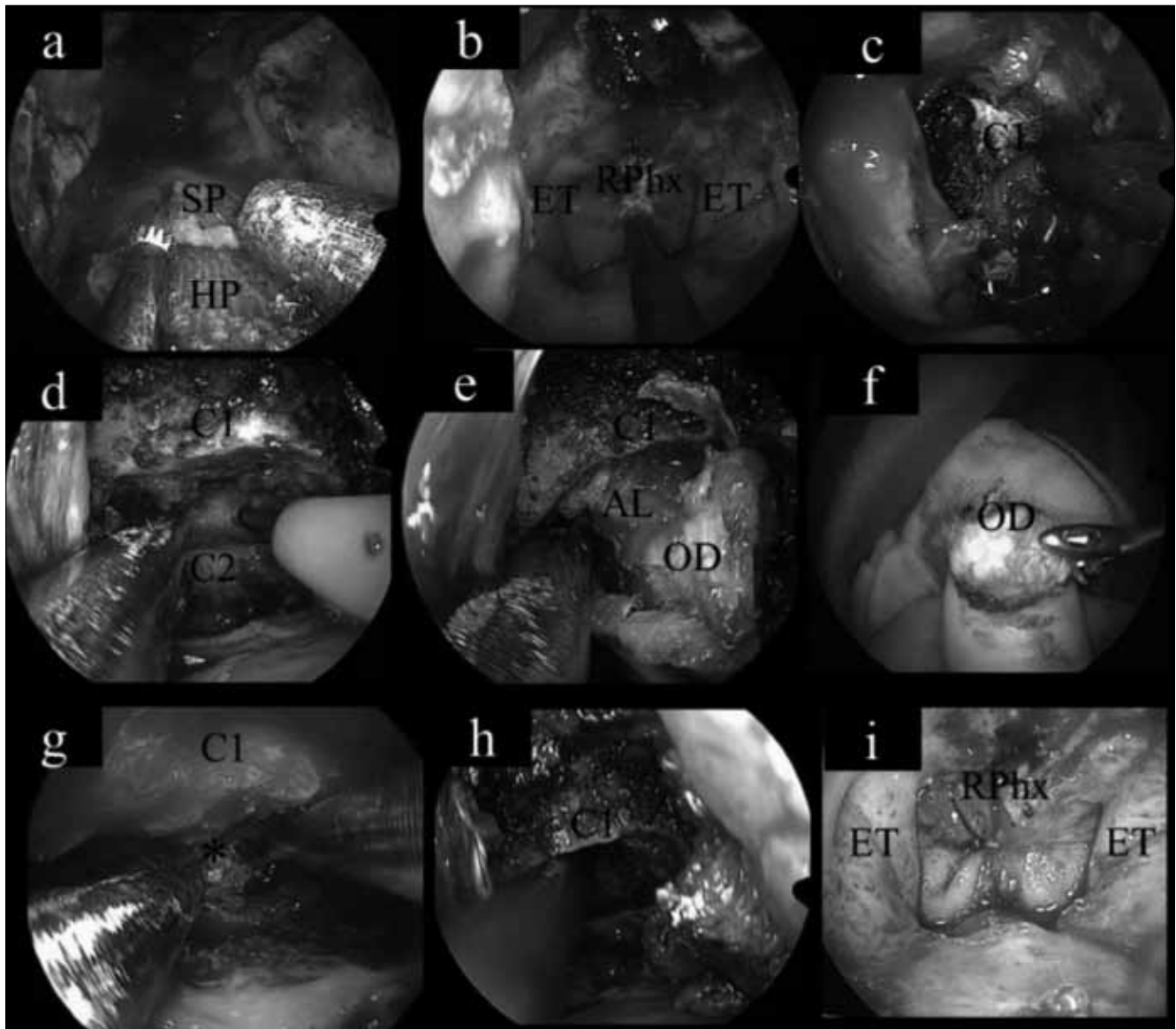


C1 Arch Integrity	Posterior Fusion	External Orthosis	Follow-up (months)	Tracheostomy/extubation (days)	Re-start oral feeding (days)
Yes	No	rigid cervical collar / 1 month	73	No / 0	1
Yes	No	rigid cervical collar / 2 months	49	No / 0	1
Yes (following anterior C1 arch reconstruction)	No	rigid cervical collar / 1 month	37	No / 0	1
Yes	No	rigid cervical collar / 1 month	31	No / 0	1
Yes	No	no collar	27	No / 0	1
Yes	No	no collar	25	No / 0	1
Yes	No	rigid cervical collar / 2 months	21	No / 5	7
Yes	No	rigid cervical collar / 2 months	19	No / 0	1
Yes	No	rigid cervical collar / 2 months	17	No / 0	1
Yes (following anterior C1 arch reconstruction)	No	rigid cervical collar / 3 months	14	No / 2	3

## Results

Adequate surgical exposure and working angle was achieved by the EEA in all 10 patients. In 8 patients we were able to preserve the anterior C1 arch, while in 2 post-traumatic cases it was reconstructed. The EEA allowed achievement of adequate decompression of the upper cervical medulla in all patients with basilar invagination and/or rheumatoid pannus and in the patient with a CCJ metastasis. The C1-C2 meningioma included in this series consisted in a relatively ventral small tumour (maximum diameter of 2.5 cm) determining symptomatic bulbo-medullary compression. The peculiar characteristics of this meningioma (antero-median location, small dimension, soft consistency, presence of the so-called “cortical cuff” between the meningioma and neurovascular structures and the limited dural tail) were particularly adequate

for the working angle granted by endoscopic endonasal approach and led to complete removal of the lesion with a limited osteo-dural dissection (see Fig. 5a-h). Thus, we were able to preserve the anterior C1 arch that represents in this case not only an element of stability, but also an important layer for reconstruction (see Fig. 5i). The reconstruction of relatively small dural defect was done with a multilayer technique including the harvesting of autologous bone dust anchored to the C1 arch along with the tip of odontoid and the suture of the mucosa as an additional reinforcing layer between cranial and nasal cavity to speed up healing and reduce the incidence of CSF leak. A lumbar drain was placed in the operating theatre and maintained for 5 days. Ambulatory endoscopic controls performed at 4, 7 and 15 days after surgery no showed signs of CSF leak.



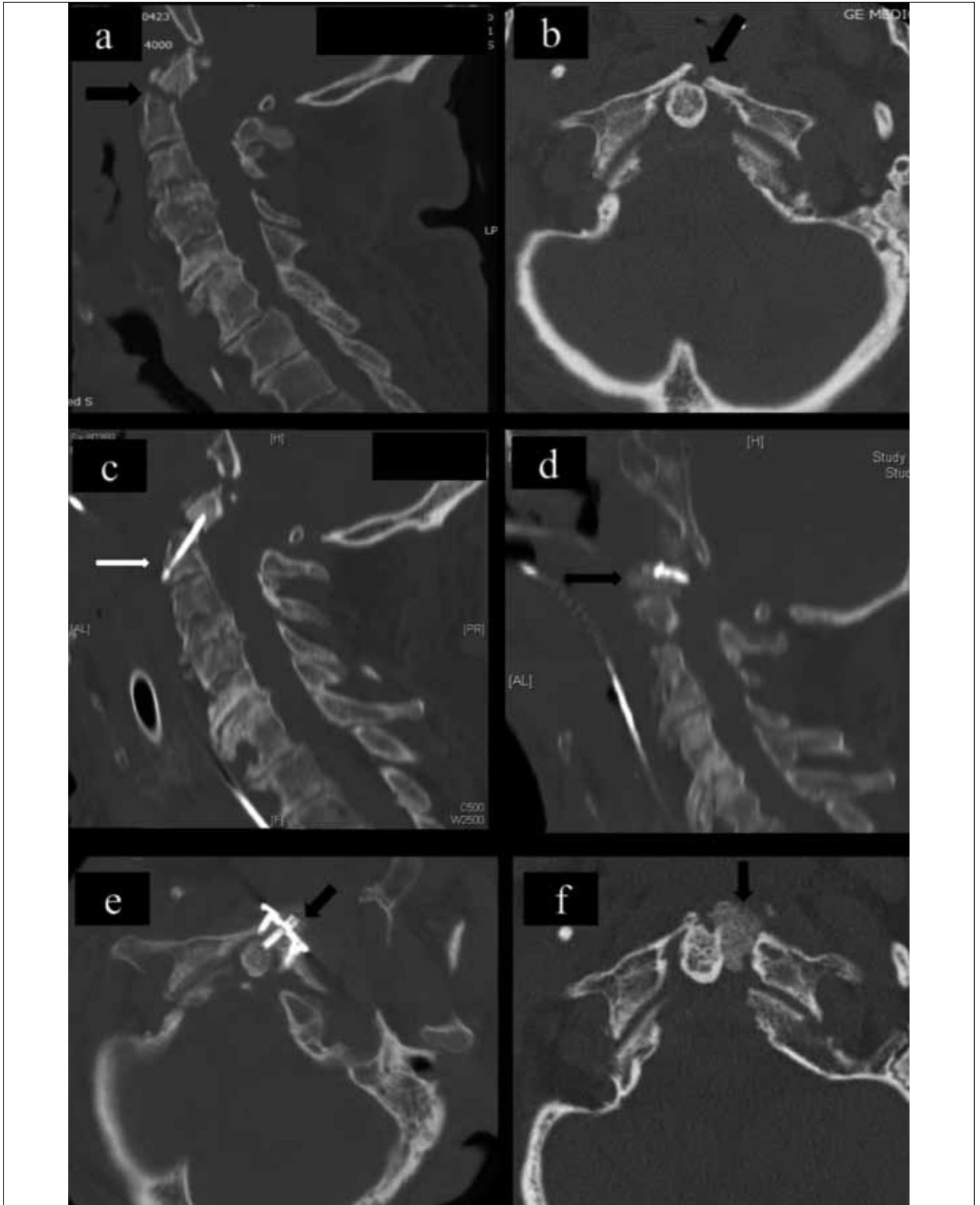
**Fig. 2.** Patient 2 (see Table I). Intraoperative endoscopic transnasal images. A. The posterior part of the hard palate was thinned by drilling out the outer bone layer with ultrasonic bone dissector, making the hard palate more flexible to enhance the angle of “nasopalatine line”. B, C. Linear incision in the midline of the nasopharyngeal mucosa and subperiosteal preparation of anterior C1 arch. D, E, F. Drilling out the base of odontoid process with preservation of the anterior C1 arch. This weakens the apex of dens that can be now easily pulled down by curette freed from ligaments and inflammatory tissue, and then removed with forceps. G. The rheumatoid pannus was removed by curette working behind the intact anterior C1 arch (asterisk). H. Pulsating surgical cavity after decompression with preservation of continuity of atlas ring. I. The suture of the mucosa in order to speed up the healing process. (SP: soft palate; HP: hard palate; ET: Eustachian tube, RPhx: rhinopharynx, OD: odontoid, AL: alar ligaments).

In two patients with inveterate C2 Anderson-D'Alonso type II fractures, treated by the anterior transcervical screwing combined with endoscopic trans-nasal anterior arthrodesis, radiological follow-up revealed regular bone fusion. Finally, in the two patients submitted to anterior C1 arch reconstruction, satisfying radiological bone ossification was reached in about 3 months. In all patients, spinal stability was preserved and none required a subsequent posterior fixation at a mean follow-up of 31 months (range: 14-73 months). No major complications occurred after surgery, no patients required intra- or postoperative repair of CSF leaks, intensive

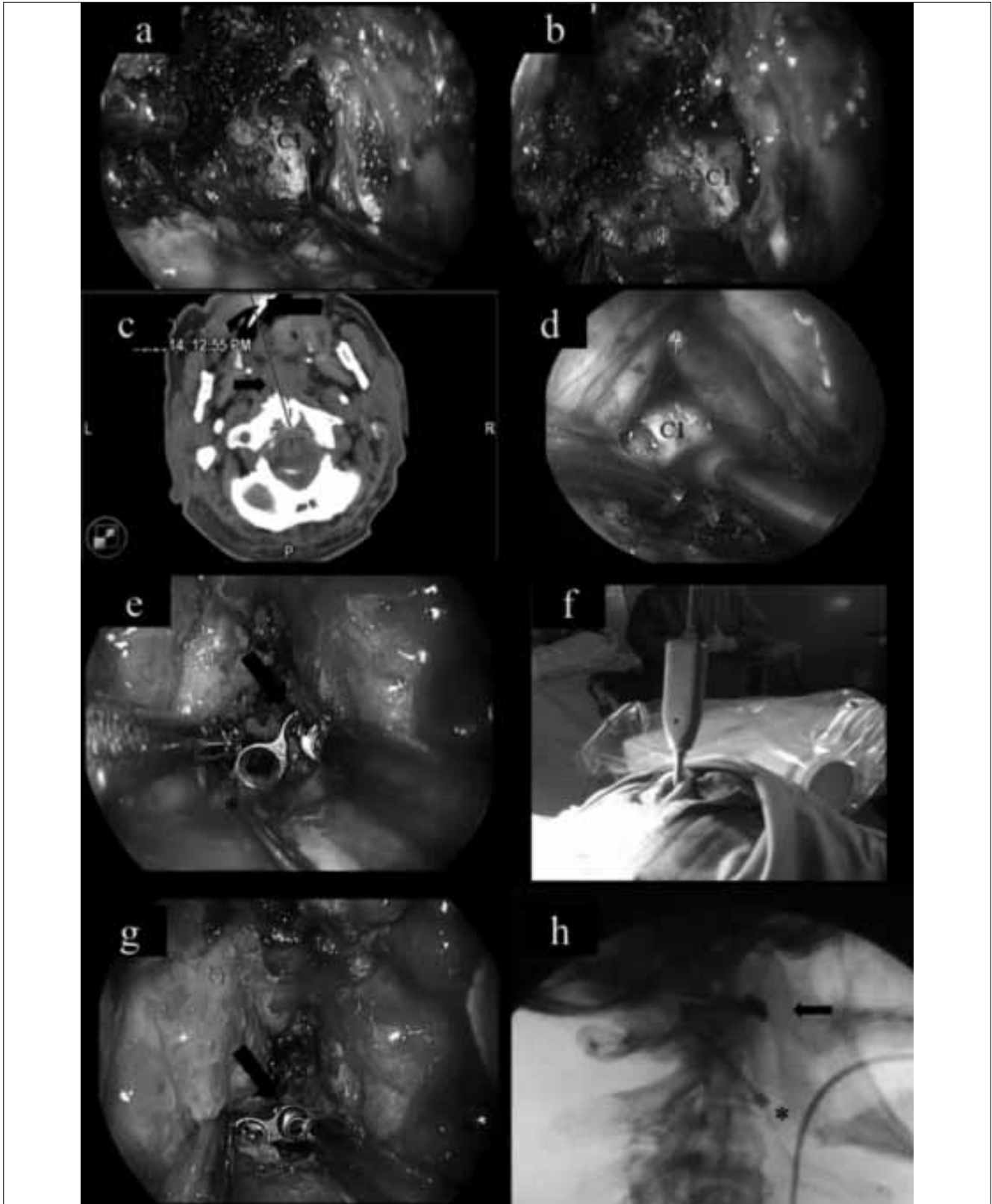care unit (ICU) staying, if needed, was short and uneventful, and oral feeding was rapidly re-started. Length of hospitalisation was usually less than 1 week. No patient worsened or developed new neurological deficits postoperatively. An improvement of at least one Ranawat or Nurick classification level was observed in 6 patients, while in the remaining four patients neurological conditions were stable (Table I).

## Discussion

The most common disorders treated at the CCJ are degene-



**Fig. 3.** Patient 10. A 79-year-old man with a previous cervical trauma (4 months ago) and inveterate anterior C1 arch and odontoid (Anderson-D'Alonso, type II) fractures with pseudoarthrosis. A. Preoperative sagittal CT scan revealing non-union type II odontoid fracture (black arrow). B. Preoperative axial CT scan revealing inveterate anterior C1 arch fracture (black arrow). C, D, E, F. Postoperative sagittal and axial CT scans showed anterior odontoid screw fixation (white arrow) combined with endoscopic transnasal C1 arch reconstruction by placing autologous cancellous bone chips to bridge the osseous gap and then fixed by plate and screws for future arthrodesis (black arrows).



**Fig. 4.** Patient 10 (see Table I). A, B. Intraoperative endoscopic transnasal images showing sub-periosteal preparation of the anterior C1 arch and non-union fracture with pseudoarthrosis inflammatory pannus in between. C, D. Drilling of the edges of odontoid fracture below anterior C1 arch after verification with the neuronavigator. The EEA allows the inflammatory pannus (pseudoarthrosis) removal and cleaning the bone borders up to the normal cancellous bone just before the subsequent anterior C2 screw fixation and C1 arch plating. E, F, G. Reconstruction of the anterior arch of C1 by positioning bone chips compressed between the bone edges and a plate fixed the insertion of cannulated screws. H. Final intra-operative fluoroscopy image showed the correct placement of plate (black arrow) and cervical screw (asterisk).



erative or posttraumatic atlantoaxial disease, meningiomas, chordomas and other rare bony tumours. Rheumatoid arthritis is the most common inflammatory disease involving the spine with predilection for the upper cervical spine. Surgery is usually reserved to the patients with symptomatic CCJ instability, basilar invagination with odontoid dislocation, or irreducible upper spinal cord compression by rheumatoid pannus. Treatment of anterior bulbo-medullary junction compressions can be performed by different surgical procedures and is the type of the approach dictated by the nature and extension of the lesion<sup>3 11-16 17-33</sup>.

Transoral and transcervical approaches, and recently a transnasal approach to the CCJ, are the most widely used. The procedures have different trajectories, working angles and extents of exposure; therefore, several considerations should be taken into account to tailor the most appropriate surgical strategy for the different patients<sup>3</sup>. The transoral-transpharyngeal technique is still considered the gold standard anterior approach and still represents the most experienced technique<sup>1 2</sup>.

However, this surgical technique is not properly minimally-invasive in the general sense of the respect of the anatomical planes and/or its precise layer-by-layer reconstruction<sup>13 14</sup>. In fact, this approach often involves the splitting of structures such as the soft palate, mandible and maxilla. However, Visocchi et al. proposed the use of a 30° endoscope for the transoral approach to avoid full soft-palate splitting, hard-palate splitting or extended maxillo/mandibulotomy. In fact, the use of the endoscope allows direct vision in all directions by rotating the instrument, and the authors concluded that with the aid of an endoscope, abnormalities as high as the mid-clivus can be visualised without extensive soft- or hard-palate manipulation<sup>35-39</sup>.

Furthermore, the transoral route is not a straightforward approach to the lesion and could present a deep surgical field with a small and asymmetric angle of working related to the mouth opening and upper direction. The transoral approach also includes the risk of bacterial contamination secondary to oral cavity penetration, prolonged postoperative intubation and nasogastric tube feeding, along with potential effects on phonation. Finally, healing of the oropharyngeal incision can be difficult because of wound contamination by saliva and bacterial flora.

All these issues have served as a stimulus to explore alternative and less invasive treatment options<sup>4-6 11-16</sup>. Advances in endoscopic technology and equipment<sup>17-19</sup> have allowed the use of minimally-invasive techniques in the CCJ.

In 2005, Kassam et al.<sup>4</sup> first reported on EEA for resection of an odontoid process and rheumatoid pannus in a 73-year-old woman. At present, few other similar cases have been reported in literature<sup>4 11-14 20-33</sup>.

The EEA is a more direct and straightforward approach with a shorter working distance in comparison with the transoral ones, offering good exposure and working area

from the clivus down to C2. All these concerns represent, in our opinion, a significant advancement in the management of irreducible compressive lesions of the anterior CCJ. The decompression is at least as effective as that obtained with the other approaches with a potential lower morbidity, and greater respect of the cervical spine biomechanics.

The lower morbidity can be attributed to earlier extubation, prompt oral feeding and lower risk of bacterial wound contamination because the mucosal defect created by a transnasal approach is linear, smaller and above the level of the soft palate<sup>4 11-14</sup>.

Furthermore, by this approach, we were able to spare the hard and soft palate and to remove only a small portion of the posterior nasal septum preserving most of the nasal mucosa, thus leaving the physiological mechanisms of breathing and phonation unaffected. Finally, the use of an endoscope has some advantages in itself, including the close-up vision and a larger field of vision in the depth, which are benefits enhanced by the use of dedicated angled lenses. However, it should be noted that there are some limitations to this approach. The lesion must be located almost in the midline and above the "nasopalatine line"<sup>4</sup> and, occasionally, partial posterior drilling of the hard palate is needed to gain a more caudal access<sup>11-14</sup>. Regardless of the learning curve, similar to the transoral approach, some limitations still remain in terms of a narrow and deep surgical corridor; thus, these procedures should be performed only in selected centres by a multidisciplinary, well trained team in endoscopic techniques.

In approaching the CCJ we used the technique described by Kassam et al.<sup>4</sup>, albeit with some modifications. These include: a midline linear incision of the nasopharyngeal mucosa rather than the creation of a flap, the non-opening of the sphenoid sinus and the attempt to preserve the anterior C1 arch continuity working above and below it. Furthermore, for fractures, we always tried to fix the fracture by screws and plates, even in a narrow space, and filling the gap by autologous bone and/or bone substitutes to guarantee the better future arthrodesis.

In the present series, in 8 patients we were able to preserve the anterior C1 arch, while in 2 cases we reconstructed it. In our experience and according to the literature, anterior C1 arch preservation plays an important role for the biomechanical stability of the CCJ, as it could avoid two dreadful conditions: the phenomenon of cranial settling and the need for a posterior occipitocervical or C1-C2 fixation, with its related risk of subaxial subluxation development<sup>7 8 11 12 14</sup>. On the contrary, in the transoral approach, for the angled working corridor, the anterior ring of C1 and the base of the odontoid process are almost always completely resected as well as in the transcervical approach, where C1 ring removal is essential to gain access to the lower clivus<sup>3</sup>. The last controversial issue

is represented by literature reports that describe the risk of spine instability secondary to disruption of craniocervical junction ligamentous attachments, even in case of bony preservation (i.e. anterior C1 arch). So far, all our cases did not present such complications even in the long term<sup>11-14</sup>. We can hypothesise on some possible explanations based on our experience and literature evidence. Atlas ring integrity could prevent C1-C2 subluxation even in cases of transverse ligament disruption thanks to the important role of second stabilisers (capsular ligaments, paraspinal muscle, tectorial membrane, anterior longitudinal ligament, and ligamentum flavum) that provide a relevant restraint to C1-C2 segment motion<sup>28-34</sup>. Furthermore, analysing our cases of rheumatoid arthritis we found that in many cases, because of the inflammatory process of the synovial capsule and joints, the articulation between C0-C1 and C1-C2 already present some grade of fusion that limits movement and dislocations. Moreover, in most cases, in order to spare the anterior C1 arch, we do not remove the base of the odontoid process but only the dislocated tip to relieve brainstem compression. In these cases, the transverse ligament with its attachment to the bone, most likely, is almost entirely preserved and we noted after a few months a sort of fusion between the residual odontoid process and the posterior border of the C1 arch. Keeping this concept in mind, in the last cases we intentionally fused C1 to the residual C2 dens by screws and bone substitutes to enhance future spinal stability. Finally, management of odontoid and atlas fractures is still a matter of debate. Stable atlas fractures are treated conservatively, while unstable ones are surgically managed, usually by posterior occipito-cervical or C1-C2 fixations<sup>29-34</sup>. These procedures provide CCJ stability, but their serious disadvantage are the elimination of the rotational mobility at C1-C2 segment and the abolition of flexion-extension movement at C0-C1, resulting in an increased risk of lower cervical spine degeneration and instability<sup>29</sup>. As demonstrated in two of our cases of odontoid fracture, a possible minimally-invasive alternative to posterior approaches is represented by the combined approach through the classic anterior cervical screwing supplemented by an EEA to clean up the bony borders, put bone chips in between to enhance the future arthrodesis and eventually reinforce the stability by C1 to C2 screws. All patients submitted to this combined approach presented radiologic evidence of fusion of the bone segments at follow-up without any clinical and radiological evidence of cervical instability. This is, in our opinion, the key point because the arthrodesis is the most important objective of the surgeon in these situations. This is without doubt obtained thanks to the direct contact between surfaces of the bony fragments and the bone chips that in the fracture gap replace the pseudoarthrosic tissue. The importance of C1-ring reconstruction, even after an anterior transoral or transcervical approach, was recently

stressed by other authors to restore CCJ stability with motion preservation<sup>28 31 40 41</sup>. Pure endoscopic endonasal anterior C1 arch reconstruction could represent an innovative and function preserving option in the surgical treatment of atlas fractures. In our opinion, this approach is really minimally-invasive from an anatomical point of view, and considering patient discomfort provides the shortest way to the target and offers the best working angle with the possibility to gain a bilateral control of the entire anterior C1 arch. In all patients treated for post-traumatic atlantoaxial disease, neck pain quickly disappeared, no major complications occurred and oral feeding was re-started the day after surgery. At the last follow-up, the range of motion of the cervical spine was only slightly reduced (15% in rotation) and CT demonstrated the anterior C1 arch reconstruction with arthrodesis and anterior atlanto-occipital fusion between the atlas and lower clivus that further reinforces spine stability. Posterior occipito-cervical or C1-C2 fixation was not required.

## Conclusions

An EEA may represent an innovative and complementary option for treatment of complex anteromedial located CCJ lesions, avoiding many of the morbidities associated with the transoral or transcervical approaches, resulting, in a safe, effective and well tolerated procedure. EEA allowed, in properly selected patients, preservation of the anterior C1 arch and avoidance of posterior fixation, thus preserving the rotational movement at C0-C2 segment and reducing the risk of development of subaxial instability. The main limitation of this approach consists of the narrow and deep surgical corridor; thus, these procedures should be performed only in selected centres by a multidisciplinary team that is well trained in endoscopic techniques. Obviously, long-term clinical studies will be needed to better understand the indications, clinical advantages and disadvantages of this technique.

## References

- 1 Crockard HA. *The transoral approach to the base of the brain and upper cervical cord*. Ann R Coll Surg Engl 1985;67:321-5.
- 2 Blazier CJ, Hadley MN, Spetzler RF. *The transoral surgical approach to craniocervical pathology*. J Neurosci Nurs 1986;18:57-62.
- 3 Baird CJ, Conway JE, Sciubba DM, et al. *Radiographic and anatomic basis of endoscopic anterior craniocervical decompression: a comparison of endonasal, transoral, and transcervical approaches*. Neurosurgery 2009;65 (Suppl 6):158-63.
- 4 Kassam AB, Snyderman C, Gaedner P, et al. *The expanded endonasal approach: a fully endoscopic endonasal approach and resection of the odontoid process: technical case report*. Neurosurgery 2005;57(Suppl 1):E213.

- 5 Alfieri A, Jho HD, Tschabitscher M. *Endoscopic endonasal approach to the ventral craniocervical junction: anatomical study*. Acta Neurochir 2002;144:219-25.
- 6 Cavallo LM, Messina A, Cappabianca P, et al. *Endoscopic endonasal surgery of the midline skull base: anatomical study and clinical considerations*. Neurosurg Focus 2005;19:E2.
- 7 Naderi S, Crawford NR, Melton MS, et al. *Biomechanical analysis of cranial settling after transoral odontoidectomy*. Neurosurg Focus 1999;6:E7.
- 8 Steinmetz MP, Mroz TE, Benzel EC. *Craniovertebral junction: biomechanical considerations*. Neurosurgery 2010;66(Suppl 3):7-12.
- 9 Revanappa KK, Rajshekhar V. *Comparison of Nurick grading system and modified Japanese Orthopaedic Association scoring system in evaluation of patients with cervical spondylotic myelopathy*. Eur Spine J 2011;20:1545-51.
- 10 Ranawat CS, O'Leary P, Pellicci P, et al. *Cervical spine fusion in rheumatoid arthritis*. J Bone Joint Surg Am 1979;61:1003-10.
- 11 Iacoangeli M, Gladi M, Alvaro L, et al. *Endoscopic endonasal odontoidectomy with anterior C1 arch preservation in elderly patients affected by rheumatoid arthritis*. Spine J 2013;13:542-8.
- 12 Gladi M, Iacoangeli M, Specchia, et al. *Endoscopic transnasal odontoid resection to decompress the bulbo-medullary junction: a reliable anterior minimally invasive technique without posterior fusion*. Eur Spine J 2012;21 (Supp. 1):55-60.
- 13 Iacoangeli M, Di Rienzo A, di Somma LG, et al. *Improving the endoscopic endonasal transclival approach: the importance of a precise layer by layer reconstruction*. Br J Neurosurg 2014;28:241-6.
- 14 Iacoangeli M, Di Rienzo A, Alvaro, et al. *Fully endoscopic endonasal anterior C1 arch reconstruction as a function preserving surgical option for unstable atlas fractures*. Acta Neurochir 2012;154:1825-6.
- 15 Roselli R, Iacoangeli M, Pompucci A, et al. *Anterior cervical epidural abscess treated by endoscopy-assisted minimally invasive microsurgery via posterior approach*. Minim Invasive Neurosurg 1998;41:161-5.
- 16 Wolinsky JP, Sciubba DM, Suk I, et al. *Endoscopic image-guided odontoidectomy for decompression of basilar invagination via a standard anterior cervical approach. Technical note*. J Neurosurg Spine 2007;6:184-91.
- 17 Re M, Magliulo G, Romeo R, et al. *Risks and medicolegal aspects of endoscopic sinus surgery. A review*. Eur Arch Otorhinolaryngol 2014;271:2103-17.
- 18 Re M, Masegur H, Ferrante L, et al. *Traditional endonasal and microscopic sinus surgery complications versus endoscopic sinus surgery complications. A meta-analysis*. Eur Arch Otorhinolaryngol 2012;269:721-9.
- 19 Wu JC, Mummaneni PV, El-Sayed IH. *Diseases of the odontoid and craniocervical junction with management by endoscopic approaches*. Otolaryngol Clin North Am 2011;44:1029-42.
- 20 Mazzatenta D, Zoli M, Mascari C, et al. *Endoscopic endonasal odontoidectomy: clinical series*. Spine 2014;39:846-53.
- 21 Wu JC, Huang WC, Cheng H, et al. *Endoscopic transnasal transclival odontoidectomy: a new approach to decompression: technical case report*. Neurosurgery 2008;63(Suppl 1):ONSE92-4.
- 22 Hankinson TC, Grunstein E, Gardner P, et al. *Transnasal odontoid resection followed by posterior decompression and occipitocervical fusion in children with Chiari malformation type I and ventral brainstem compression*. J Neurosurg Pediatr 2010;5:549-53.
- 23 Gempt J, Lehmeberg J, Meyer B, et al. *Endoscopic transnasal resection of the odontoid in a patient with severe brainstem compression*. Acta Neurochir 2010;152:559-60.
- 24 Gempt J, Lehmeberg J, Grams AE, et al. *Endoscopic transnasal resection of the odontoid: case series and clinical course*. Eur Spine J 2011;20:661-6.
- 25 Leng, LZ, Anand VK, Hartl R, et al. *Endonasal endoscopic resection of an os odontoides to decompress the cervicomedullary junction: a minimal access surgical technique*. Spine 2009;34:E139-43.
- 26 Cornelius JF, Kania R, Bostelmann R, et al. *Transnasal endoscopic odontoidectomy after occipitocervical fusion during the same operative setting - technical note*. Neurosurg Rew 2011;34:115-21.
- 27 Magrini S, Pasquini E, Mazzatenta D, et al. *Endoscopic endonasal odontoidectomy in a patient affected by Down syndrome: technical case report*. Neurosurgery 2008;63:E373-4.
- 28 Ito H, Neo M, Sakamoto T, et al. *Subaxial subluxation after atlantoaxial transarticular screw fixation in rheumatoid patients*. Eur Spine J 2009;18:869-76.
- 29 Panjabi MM. *The stabilizing system of the spine. Part I. Function, dysfunction, adaptation, and enhancement*. J Spinal Disord 1992;5:383-9.
- 30 Kakarla UK, Chang SW, Theodore N. *Atlas fractures*. Neurosurgery 2010;66(Suppl 3):60-7.
- 31 Ruf M, Melcher R, Harms J. *Transoral reduction and osteosynthesis C1 as a function preserving option in the treatment of unstable Jefferson fractures*. Spine 2004;29:823-7.
- 32 Wang J, Zhou Y, Zhang ZF, et al. *Direct repair of displaced anterior arch fracture of the atlas under microendoscopy: experience with seven patients*. Eur Spine J 2012;21:347-51.
- 33 Koller H, Resch H, Tauber MA. *A biomechanical rationale for C1-ring osteosynthesis as treatment for displaced Jefferson burst fractures with incompetency of the transverse atlantal ligament*. Eur Spine J 2010;19:1288-98.
- 34 Agrawal A, Reyes PM. *A novel technique of odontoidoplasty and C1 arch reconstruction: anatomical and biomechanical basis*. Neurosurgery 2011;68(Suppl 1 Operative):103-13.
- 35 Visocchi M, Della Pepa GM, Doglietto F, et al. *Video-assisted microsurgical transoral approach to the craniocervical junction: personal experience in childhood*. Childs Nerv Syst 2011;27:825-31.
- 36 Visocchi M, Doglietto F, Della Pepa GM, et al. *Endoscope-assisted microsurgical transoral approach to the anterior craniocervical junction compressive pathologies*. Eur Spine J 2011;20:1518-25.
- 37 Visocchi M, La Rocca G, Della Pepa G, et al. *Anterior video-assisted approach to the craniocervical junction: transnasal or transoral? A cadaveric study*. Acta Neurochir 2004;156:285-92.
- 38 Visocchi M, Pietrini D, Tufo T, et al. *Preoperative irreducible C1-C2 dislocations: intra-operative reduction and pos-*

- terior fixation. The “always posterior strategy”.* Acta Neurochir 2009;151:551-9.
- <sup>39</sup> Visocchi M, Di Martino A, Maugeri R, et al. *Videoassisted anterior surgical approaches to the craniocervical junction: rationale and clinical results.* Eur Spine J 2015;24:2713-23.
- <sup>40</sup> Mendes GA, Dickman CA, Rodriguez-Martinez NG, et al. *Endoscopic endonasal atlantoaxial transarticular Screw fixation technique: an anatomical feasibility and biomechanical study.* J Neurosurg Spine 2015 22:470-7.
- <sup>41</sup> Duntze J, Eap C, Kleiber JC, et al. *Advantages and limitations of endoscopic endonasal odontoidectomy. A series of nine cases.* Orthop Traumatol Surg Res 2014;100:775-8.

Received: March 16, 2015 - Accepted: October 19, 2015

Address for correspondence: Massimo Re, Department of Otorhinolaryngology, Ospedali Riuniti di Ancona, Università Politecnica delle Marche, via Conca 71, 60020 Ancona Torrette, Italy. Tel. +39 071 5964625. Fax +39 071 5964415. E-mail: remassimo@hotmail.com, neurotra@tiscali.it



## AUDIOLOGY

# Idiopathic sensorineural hearing loss in the only hearing ear

## *Ipoacusia neurosensoriale idiopatica nell'unico orecchio udente*

S. BERRETTINI<sup>1,2</sup>, A. DE VITO<sup>1</sup>, L. BRUSCHINI<sup>1</sup>, S. FORTUNATO<sup>1</sup>, F. FORLI<sup>1</sup><sup>1</sup> ENT, Audiology and Phoniatics University Unit of "Azienda Universitaria Ospedaliera Pisana" Pisa, Italy; <sup>2</sup> Guest Professor at Division of ENT Diseases, Karolinska Institutet, Stockholm, Sweden

## SUMMARY

A retrospective chart review was used for 31 patients with sudden, progressive or fluctuating sensorineural hearing loss (SHL) in the only hearing ear who had been consecutively evaluated at the ENT, Audiology and Phoniatics Unit of the University of Pisa. The group of patients was evaluated with a complete history review, clinical evaluation, imaging exam (MRI, CT), audiologic tests (tone and speech audiometry, tympanometry, study of stapedial reflexes, ABR and otoacoustic emission) evaluation. In order to exclude genetic causes, patients were screened for CX 26 and CX30 mutations and for mitochondrial DNA mutation A1555G. Patients with sudden or rapidly progressive SHL in the only hearing ear were treated with osmotic diuretics and corticosteroids. In patients who did not respond to intravenous therapy we performed intratympanic injections of corticosteroid. Hearing aids were fitted when indicated and patients who developed severe to profound SHL were scheduled for cochlear implant surgery. The aim of this study is to report and discuss the epidemiology, aetiopathogenesis, therapy and clinical characteristic of patients affected by SHL in the only hearing ear and to discuss the issues related to the cochlear implant procedure in some of these patients, with regard to indications, choice of the ear to implant and results.

KEY WORDS: Sensorineural hearing loss • Only hearing ear • Progressive sensorineural hearing loss • Cochlear implant

## RIASSUNTO

Uno studio retrospettivo è stato condotto su 31 pazienti, giunti all'osservazione della clinica ORL Audiologia e Foniatria dell'Università di Pisa dal 2007 al 2013, affetti da ipoacusia neurosensoriale improvvisa, fluttuante o progressiva nell'unico orecchio udente. L'intero gruppo di pazienti è stato valutato con una adeguata anamnesi, otomicroscopia, esami di imaging (TC RMN), test audiologici (audiometria tonale e vocale, impedenziometria, potenziali evocati uditivi e otoemissioni acustiche). Questo gruppo di pazienti è stato sottoposto anche a una valutazione genetica (ricerca mutazioni CX 26, CX 30 e DNA mitocondriale A1555G) e a test di laboratorio. I pazienti con ipoacusia improvvisa o rapidamente progressiva sono stati trattati con diuretici osmotici e corticosteroidi (endovena o intratimpanici). I pazienti che non hanno recuperato in maniera adeguata dopo il trattamento sono stati avviati a un percorso di protesizzazione. Nei pazienti con insufficiente resa protesica sono stati sottoposti ad impianto cocleare. Lo scopo di questo studio è quello di discutere l'epidemiologia, l'eziopatogenesi e le caratteristiche cliniche di pazienti affetti da ipoacusia neurosensoriale nell'unico orecchio udente e inoltre discutere le indicazioni e la scelta dell'orecchio da impiantare in questa categoria di pazienti.

PAROLE CHIAVE: Ipoacusia neurosensoriale • Unico orecchio udente • Ipoacusia progressiva • Impianto cocleare

Acta Otorhinolaryngol Ital 2016;36:119-126

## Introduction

Patients suffering from severe to profound unilateral sensorineural hearing loss (SHL) in one ear can develop idiopathic SHL in the contralateral ear after a period varying from months to years. This condition may be sudden, progressive or fluctuating. The development of SHL is a dramatic event leading patients with an only hearing ear to be confused, worried, anxious and isolated from the surrounding world, and thus worthy of special consideration. This small sub-population of patients becomes practically deaf, so that SHL in the only hearing ear is an audiologic emergency. So far, it has not been possible to provide any specific therapy, while

steroids, vasodilators and diuretics are frequently prescribed. Cochlear implants are often the last resort to rehabilitate these patients when medical therapy and hearing aids do not result in satisfactory hearing performance.

We believe it is of interest to investigate the clinical characteristics of this specific group of patients because the scientific literature describing this "disease" is relatively limited. To our knowledge, the aetiopathogenesis and incidence of this clinical condition have never been previously reported. There are only a few studies reporting on sudden SHL<sup>1-4</sup> in the only hearing ear, but none describing the progressive forms of the disease.

In this regard, delayed endolymphatic hydrops (DEH) is

a clinical entity that may present with features similar to SHL in the only hearing ear. This disease, first reported by Nadol et al. in 1975<sup>5</sup>, is characterised by the early onset of profound or total SHL in one ear. After a prolonged period of stagnation, a late phase of the disease appears with different otologic symptoms that can be described as two main types of DEH: ipsilateral and contralateral variants. Ipsilateral DEH appears with episodic vertigo in the deaf ear, while contralateral DEH appears as fluctuating hearing loss and/or episodic vertigo in the previously normal ear. In contralateral DEH, the SHL first affects the low-tone frequencies and is always fluctuating<sup>6</sup>.

In this paper, we report on a retrospective case series of 34 patients (collected over 6 years) with one deafened ear – as a result of various causes – who subsequently developed progressive, fluctuating or sudden SHL in the contralateral ear. The aim is to present and discuss epidemiology, aetiopathogenesis and clinical characteristics of patients affected by SHL in the only hearing ear and to discuss the issues related to the cochlear implant procedure in these patients with regards to indications, choice of the ear to implant and results.

## Materials and methods

A retrospective chart review was used for 34 patients with SHL in the only hearing ear who had been consecutively evaluated at the Ear, Nose and Throat (ENT) Audiology and Phoniatrics Unit of the University of Pisa (tertiary referral centre for audiological disease) between January 2007 and January 2013. The sample was composed of 19 men and 15 women. All data were collected after receiving informed consent by all patients involved and according to the Declaration of Helsinki. All patients were evaluated with a complete history review (with particular attention to family history and other systemic diseases). Patients underwent otomicroscopy, pure tone audiometry, speech audiometry, tympanometry and study of stapedial reflexes. All patients were also evaluated with auditory brainstem responses and otoacoustic emissions. Patients who complained of dizziness underwent vestibular examination with videonystagmography.

Several blood tests were carried out to exclude any known cause of hearing loss (complete blood cell count, general chemistry screen, VES, PCR, mucoproteins, fibrinogen, urine test, total and fractionated protein, bilirubin, vGT, LDH, SGOT, SGPT, CPK, TSH, T3, T4, serological tests for toxoplasmosis, syphilis, borrelia burgdorferi, antibodies ANA, ENA, AMA, ASMA, CLIF test, ANCA). In order to exclude genetic causes, patients were screened for connexin 26 and connexin 30 mutations and for the most frequent mitochondrial DNA mutation related to deafness (A1555G). Patients were also evaluated with 1.5–3.0 Tesla contrast-enhanced magnetic resonance imaging (MRI) of the brain, cerebellopontine angle and inner ear. The study

protocol of the inner ear includes a thin slice heavily T2W 3D sequence (FIESTA) to stress the signal difference between the cerebrospinal fluid (CSF) and other tissues, and thin axial and coronal SE or FSE 2D T1W with and without gadolinium administration. Axial FLAIR imaging was performed, which covered the entire brain. All patients underwent CT scan of petrous bone to exclude advanced otosclerosis, perilymphatic fistulas or other bone pathologies. Patients with a history of hypertension or cardiovascular disease were also evaluated with colour Doppler ultrasound of neck vessels.

Patients with known autoimmune diseases, vascular diseases, diabetes and other metabolic systemic diseases were excluded.

Out of 34 patients three were excluded: one because of the presence of a mutation in the connexin 26 gene (M34T), another for an enlarged bilateral vestibular aqueduct (EVA) and one because of the presence of superficial hemosiderosis of the central nervous system. This patient experienced unilateral profound deafness after a head trauma with a temporal bone fracture and some years later developed fluctuating progressive SHL in the contralateral ear<sup>7</sup>.

In 18 of the 31 patients included, the aetiology of SHL in the first deafened ear was unknown and was defined as idiopathic; in 6 patients SHL was due to ear surgery (1 patient with translabyrinthine surgery for acoustic neuroma; in 5 patients deafness was due to tympanoplasty for cholesteatoma or middle ear chronic otitis with postoperative severe or profound SHL). In another patient SHL was subsequent to a head trauma with a temporal bone fracture. An infectious aetiopathogenesis (bacterial meningitis, acute otitis media, systemic viral infection etc.) was recognised in another 6 cases.

Idiopathic SHL occurring in the second affected ear was classified as follows:

- *progressive*: SHL  $\geq 15$  dB HL (PTA at 0.5–1–2–4 kHz) occurring in a 10-year period<sup>8</sup>;
- *sudden*: abrupt hearing deterioration of  $\geq 30$  dB HL in at least 3 consecutive frequencies occurring in a period no longer than 3 days<sup>9</sup>;
- *progressive-fluctuating*: recurrent episodes of SHL of any entity that recover rapidly.

The entire group of patients was evaluated by the same audiological team and submitted to the battery of audiological tests that we routinely use to evaluate patients with progressive, fluctuating or sudden SHL (Table I).

Patients with sudden or rapidly progressive SHL in the only hearing ear were treated with glycerol 10% 500 ml/day i.v. for 7 days, methylprednisolone 250 mg/day for 3 days, and then tapered for a 15-day period and a proton pump inhibitor (lansoprazole 30 mg/die) was added. In patients who did not respond to intravenous therapy we performed intratympanic injections of dexamethasone (4 mg/ml 3 injections for 10 days). Hearing aids were fitted

**Table I.** Protocol of clinical evaluation for SHL in the only hearing ear.

<b>Auditory test</b>	Tonal and speech audiometry
	Tympanometry study of stapedial reflex
	ABR and otoacoustic emission
	Auditory skills test
<b>Laboratory test</b>	Blood count
	Glucose, cholesterol, triglycerides
	Creatinine, blood urea nitrogen, electrolytes
	Total protein and fractionated
	Bilirubin, vGT, LDH, SGOT, SGPT, CPK
	TSH, T3, T4
	Urine test
	Serological tests for toxoplasmosis, syphilis, Borrelia burgdorferi
	ESR, CRP, mucoproteins, fibrinogen
	Antibodies: ANA, ENA, AMA, ASMA, CLIF test
	ANCA, anti-collagen type II, antiphospholipids
<b>Genetic test</b>	Mutation of CX 26 and 30
	Mitochondrial DNA (A1555G)
<b>Imaging test</b>	3.0 Tesla MRI
	CT
	Colour Doppler of neck vessels
<b>Specialist evaluation</b>	Neurological
	Rheumatologic

when indicated and patients who developed severe to profound SHL were scheduled for cochlear implant surgery.

## Results

The mean age of patients when SHL occurred in the first ear was 28.09 years (age range 0-62 years). The mean pure tone average (PTA between 0.5 kHz and 1 kHz, and 2 kHz) in the first deafened ear was 82.03 dB (range 70 dB-120dB). SHL occurred in the contralateral ear after a mean period of 25.09 years (age range 2-57 years). The onset of SHL in the contralateral ear was sudden in 12 patients, progressive in 13 cases and progressive with fluctuations in another 6 cases.

With regards to the hearing threshold curve in the second affected ear, 18 patients developed downsloping SHL, 4 patients upsloping SHL and the last 9 patients a flat curve SHL. The mean mean pure tone audiometry (PTA) in the second ear that developed a hearing loss was 42.03 dB (range 30-120 dB) (Table II).

Eleven of 31 patients complained monolateral tinnitus (only in the first ear interested by SHL), while 20 of 31 complained of bilateral tinnitus. Four of 31 patients complained of occasional and non-recurrent vertigo, not temporally related to the development of SHL.

Of the 18 patients with sudden or rapidly progressive SHL in the second ear, 5 (# 1, 7, 18, 25, 26) were treated with the above-mentioned mentioned protocol; the remaining

13 patients referred to our clinic over 6 months after the onset of SHL and with no indications to medical treatment. In these patients, the mean PTA before therapy was 59.6 dB and 47.6 dB after therapy with a mean improvement of 12.0 dB.

Hearing aids fitting in the best hearing ear, or bilaterally when indicated, was proposed to 25 of 31 patients. In 17 of 25 patients, hearing performance were good: mean open-set speech-recognition score in silence was 78.8% (range 60-100%). While in 8 of 25 patients (# 3, 8, 11, 27, 28, 29, 30, 31) the hearing performance with hearing aids was very poor (mean open-set speech-recognition score in silence 25.6%, range 0-45%), and cochlear implant surgery was proposed. Patients 3 and 11 declined the cochlear implant (CI) procedure. The remaining 6 patients were implanted by using a Nucleus Contour Advance CI24RE (Cochlear) (Table III). Of a group of 184 patients (both children and adults), 6 were implanted in the same period (2007-2013). All patients were operated by the same surgical team and the final insertion of the CI was performed by the same senior surgeon. The array of electrodes was fully inserted in all cases. A post-operative X-ray of the skull was performed to confirm the correct placement of the implant. Five of six patients were implanted in the second deafened ear, while one patient (# 8) was implanted in the first deafened ear. The mean preoperative open-set speech-recognition score in silence was 20% (range 0-40%). The mean post-operative score (Table III), measured 1 year after the switch-on of the implant, was 83% (range 70-100%) with a significant improvement in hearing performance.

## Discussion

### *Epidemiology*

To our knowledge, there are no papers in the literature reporting epidemiologic data of idiopathic SHL in the only hearing ear.

Few reports<sup>1,2,10,11</sup> on sudden SHL in the only hearing ear have been published. Stahl and Cohen<sup>2</sup> reported that 20% of patients with sudden SHL were deaf in the contralateral ear (9 of 45 patients), while Lee et al.<sup>1</sup> reported a percentage of 11.5% (25 out of 217 patients). Fetterman et al.<sup>12</sup> found that 1.7% of patients (14/823 patients) with sudden SHL had bilateral loss. Shaia and Sheehy<sup>11</sup> reported 1,220 cases of sudden SHL observed at the House Ear Clinic from 1964 to 1972, 4% of which were bilateral. Half of their cases occurred simultaneously while the others were sequential. Therefore, the occurrence of sudden SHL seems to be a rather common event in patients with only one hearing ear, and more frequent than sudden SHL in the normal population, which is reported to be 5 to 160 per 100,000<sup>13-14</sup>. Concerning the involvement of the only hearing ear, patients with progressive or fluctuating SHL (19/31 or 61% in our sample) should be added to patients

**Table II.** Patients and clinical characteristics.

	Age	Age of first SHL	Aetiology first SHL	Age SHL contralateral ear	PTA first ear	PTA second ear	Development SHL in the second ear	Audiometric curve
1	45	18	Idiopathic	42	73	80	Sudden	Downsloping
2	50	28	Idiopathic	50	78.3	60	Fluctuating	Downsloping
3	76	61	Surgery for neuroma	63	120	80	Progressive	Downsloping
4	32	5	Infective	30	120	70	Fluctuating	Downsloping
5	62	38	Idiopathic	52	87	90	Progressive	Downsloping
6	70	60	Idiopathic	69	70	30	Progressive	Upsloping
7	69	55	Infective (OMC)	57	120	50	Sudden	Downsloping
8	57	41	Idiopathic	52	120	80	Progressive	Downsloping
9	36	15	Idiopathic	34	120	32.5	Fluctuating	Upsloping
10	75	14	Surgery for OMC	65	95	65	Progressive	Downsloping
11	75	14	Trauma	65	120	100	Progressive	Pantonal
12	60	5	Infective	60	70	57	Sudden	Downsloping
13	72	62	Surgery for OMC	72	73	63	Sudden	Downsloping
14	66	9	Infective	65	120	50	Progressive	Upsloping
15	72	33	Surgery for OMC	70	110	45	Progressive	Downsloping
16	71	47	Surgery for OMC	52	90	86.25	Progressive	Pantonal
17	61	6	Surgery for OMC	54	120	47.5	Fluctuating	Downsloping
18	53	1	Infective	38	112.5	40	Sudden	Downsloping
19	64	62	Idiopathic	64	82.5	70	Sudden	Downsloping
20	45	1	Idiopathic	38	120	58.75	Sudden	Downsloping
21	65	48	Idiopathic	57	120	77.5	Sudden	Downsloping
22	29	2	Infective	16	120	35	Sudden	Upsloping
23	22	0	Idiopathic	21	120	46.7	Progressive	Pantonal
24	58	4	Idiopathic	29	116.7	50	Progressive	Pantonal
25	68	48	Idiopathic	63	90	35	Fluctuating	Pantonal
26	44	0	Idiopathic	42	105	33	Fluctuating	Downsloping
27	74	14	Idiopathic	71	120	73.3	Sudden	Downsloping
28	65	60	Idiopathic	65	81.6	120	Sudden	Pantonal
29	69	40	Idiopathic	66	120	78.3	Progressive	Pantonal
30	70	60	Idiopathic	69	113.3	76.6	Sudden	Pantonal
31	65	20	Idiopathic	58	98.3	101.6	Progressive	Pantonal
32	52	20	M34T	41	115	45	Progressive	Pantonal
33	45	6	EVA	15	80	40	Fluctuating	Pantonal
34	75	50	Trauma _ SS	70	120	52.5	Progressive	Downsloping

**Table III.** Patient who underwent a CI procedure.

Patient n	Ear implanted: 1 <sup>st</sup> ear or 2 <sup>nd</sup> ear	Auditory skills test recognition open-set bisyllabic word in silence	Use of bimodal hearing stimulation	Time from onset of HL in the implanted ear	Use of hearing aid in the ear implanted before surgery
8	1 <sup>st</sup>	70% (100% IC+HA)	Yes	16 years	Yes (for 5 years)
27	2 <sup>nd</sup>	85%	No	3 years	Yes (for 2 years)
28	2 <sup>nd</sup>	80%	Yes	3 months	No
29	2 <sup>nd</sup>	75%	No	3 years	Yes (for 1 year)
30	2 <sup>nd</sup>	100%	No	2 months	No
31	2 <sup>nd</sup>	90%	No	6 years	Yes (for 4 years)



affected by sudden SNHL. This has led us to think that the development of SHL in the two ears is not an independent event, but that it could be related to aetiopathogenetic factors.

We believe that the possibility of developing SHL in the only hearing ear is not a negligible fact and that further epidemiologic studies should be conducted in this particular group of patients to better understand the risks for patients with an only hearing ear to develop SHL in the contralateral ear.

### *Aetiology*

The aetiological study of hearing loss is greatly important for both comprehensive treatment of disease and prognosis. The aetiology of this condition has been the subject of numerous reports in the literature, but to our knowledge no data are available concerning the aetiology of hearing loss in patients with an only hearing ear. In the past years our group has made a great effort to investigate the aetiology of hearing loss, in particular of progressive SHL and, as previously described<sup>8</sup>, we have defined the following causes: genetic mutations, inner ear malformations, infectious diseases, autoimmune disease, neoplastic, trauma, etc. Patients with hearing loss, especially those with an only hearing ear should be submitted to accurate and comprehensive aetiologic evaluation to investigate a possible correlation between the aetiology and the risk of developing a contralateral SHL.

Despite the comprehensive aetiological study in our patients, the aetiology of SHL in the only hearing ear remains unknown in a high percentage of these patients (31/34 patients, 91%). Therefore, we defined the disease as idiopathic and can only make some hypotheses on its origins.

A first hypothesis is genetic: unknown genetic mutations might lead to the development of SHL, possibly with a time lapse between the two ears.

A second hypothesis is the presence of microscopic osseous or membranous labyrinth malformations that are not visible at the resolution of our diagnostic tools. The most recent imaging techniques have revealed inner ear malformations in a relevant percentage of patients affected by SHL. The data, reported in the scientific literature, mainly concern the paediatric population with a reported prevalence of inner ear malformations in children with profound SHL between 14-30%<sup>15</sup>. However, minor malformations or malformations limited to the membranous labyrinth, not detectable with common diagnostic tools, may be responsible for some cases of SHL of unknown origin.

A third hypothesis is the viral one. Some authors have hypothesised two different possibilities in the development of SHL by viral damage. Schuknecht et al.<sup>16</sup> explained the genesis of DEH, and hypothesised a praecox viral labyrinthopathy leading to early cochleo-vestibular

damage in one ear with subsequent delayed hydrops in the contralateral ear due to an alteration of endolymph production and resorption. Other authors<sup>17</sup> have considered that a praecox viral infection could be responsible for SHL in the first ear and then a delayed reactivation of the same virus could cause SHL in the second ear. They found the genome cytomegalovirus (CMV) within the cochlea of a deaf patient with no evidence of acute infection. The presence of this virus suggested a possible role in inner ear injury through reactivation of the latent virus within the cochlea.

A final possible hypothesis is the autoimmune one. To explain the genesis of DEH, our group<sup>18</sup> hypothesised that contralateral hydrops could be mediated by an autoimmune process. We found a non-specific immunological pattern that was altered in 50% of patients with DEH and was significantly higher than in patients affected by Ménière's disease. A similar hypothesis is that SHL in the contralateral ear may be caused by an autoimmune mechanism involving recirculating memory cells sensitised against cochlear tissues. A comparable mechanism is described in ophthalmology, which is called sympathetic ophthalmia<sup>19</sup> in which there is an inflammatory reaction in the healthy eye after a traumatic destruction of the other eye. The pathologic mechanism could be explained as follows: during an infection, trauma, or surgery there is exposure of anatomically sequestered proteins of the inner ear. These proteins, recognised as 'foreign', serve as antigens, and result in the induction of lymphocytes. These cells re-circulate as memory cells and reach the intact contralateral cochlea, thus leading to immune response and damage of the organ. In 1994, Gloddek et al.<sup>20</sup> described an animal model of this "sympathetic cochleo-labyrinthitis". They found a high percentage of sensitised lymphocytes on the apical turn of the cochlea that is not in agreement with the clinical findings herein, since the patients examined in this study (18/31) mainly showed a downsloping audiometric curve.

### *Clinical issues and therapies*

In reviewing the literature, we found a number of studies reporting patients with sudden SHL in the only hearing ear and describing their clinical features, treatment and results (Table IV)<sup>1-4</sup>. The samples<sup>1-4</sup> (Table IV) were heterogeneous and the therapy protocols were different, so that it was difficult to compare the results and efficacy of the therapies.

In 2006, Stahl and Cohen<sup>2</sup> reported 9 cases of patients affected by sudden SHL in the only hearing ear, and described the clinical characteristics of patients and features of the hearing threshold curve. The authors treated patients with prednisolone 60-80 mg/day, who achieved a mean improvement of  $9 \pm 8.7$  dB in the three main affected frequencies. Stahl and Cohen<sup>2</sup> concluded that patients affected by a sudden SHL in the only hearing ear might

**Table IV.** Studies reporting patients with sudden SHL in the only hearing ear.

Article	Year	Patients	Aetiology of 1 <sup>st</sup> ear HL	Development of 2 <sup>nd</sup> ear HL	Type of audiometric curve in the 2 <sup>nd</sup> ear	Treatment	Cochlear implant
Stahl and Cohen	2006	9	-	Sudden	4 Downsloping 5 Upsloping	Prednisolone 60-80 mg/day	-
Lee et al.	2010	25	12 idiopathic 7 Inflammatory 2 Trauma 1 Acoustic Schwannoma 2 AVL	Sudden	-	Prednisolone 1-1.15 mg/kg/day tapered MgSO <sub>4</sub> (4 g/day) Dextran (10 ml/kg in 5% dextrose) Carbogen Inhalation Intratympanic injection if no recovery	6
Hawkings	2008	1	Congenital	Sudden	Pantonal	Oral steroids	-
Pykko et al.	1997	10	6 Ménière 1 Cogan 3 Idiopathic	2 Sudden 1 Fluctuating 7 Progressive	-	Azathioprine (25 mg tid) Prednisolone (5-15 mg/day) after initial dose of 20-40 mg	

receive the same treatment with corticosteroids as other patients affected by sudden SHL.

Pykko et al.<sup>4</sup> reported on 10 cases of patients, 6 of whom were affected by Ménière's disease, one by Cogan's syndrome and 3 by idiopathic SHL; they treated patients with corticosteroids and immunosuppressants, and hypothesised an autoimmune genesis of SHL in the contralateral ear. Patients were treated with azathioprine (25 mg tid) and prednisolone (5-15 mg/day) after an initial dose of 20-40 mg and reported a mean improvement of 22.4 dB.

Lee et al.<sup>1</sup> disposed of a larger case series of 24 patients and were the only authors reporting on patients who had undergone cochlear implantation. They treated patients with prednisolone 1-1.15 mg/kg/day tapered, MgSO<sub>4</sub> (4 g/day), Dextran (10 ml/kg in 5% dextrose), Carbogen inhalation and corticosteroid intratympanic injection if there was no improvement. A recovery rate of 64% was reported.

We treated our group of patients with the following therapeutic protocol: glycerol 10% 500 ml/day i.v. for 7 days, methylprednisolone 250 mg/day for 3 days then tapered for a 15-day therapy and a proton pump inhibitor (lansoprazole 30 mg/day)<sup>21</sup>. Patients who did not respond to intravenous therapy after 7 days were submitted to 3 intratympanic injections of dexamethasone (4 mg/ml) in 10 days.

We treated only 5 (# 1, 7, 18, 25, 26) of 18 patients with sudden or rapidly progressive SHL because the remaining 13 patients had referred to our clinic with a time-lapse that was longer than 6 months from the onset of SHL in the second ear, and there were no indications about medical treatment. Mean PTA improvement in treated patients was 12.0 dB [range 0-24 dB]. These results are similar to those found by other authors<sup>2</sup>.

The treatment of sudden idiopathic SHL is debated in the literature and there is currently no evidence of its efficacy.

Recent clinical guidelines<sup>22</sup> suggest to use only corticosteroids (oral, iv, or intratympanic) as first line therapy and eventually hyperbaric oxygen therapy. Guidelines discourage clinicians from using pharmacologic agents (antivirals, thrombolytics, vasodilators, vasoactive substances, antioxidants) that may have side effects and no documented efficacy. The guidelines also recommend the use of intratympanic injection of corticosteroids as a salvage therapy. In this specific group of patients, we decided to add glycerol to the therapeutic protocol, owing to the analogies between idiopathic SHL in the only hearing ear and contralateral-type DEH. Diuretics significantly improve the hearing of patients with this type of DEH<sup>23</sup>.

#### *Outcomes of CI procedure in patients with SHL in the only hearing ear*

CI is a viable option for patients whose hearing deficit becomes bilaterally severe to profound and who no longer benefit from hearing aids.

Only one paper<sup>1</sup> reported on patients with idiopathic SHL in the only hearing ear that underwent a CI procedure. Six of 25 patients were submitted to CI; the results in terms of reaching the top of the category of auditory performances (CAP) defined as 'use of telephone with known speaker' were good. All these patients were implanted in the second ear that developed SHL. The time necessary to reach CAP was linked to the time of auditory deprivation in the second ear. The authors concluded that a treatment like CI might be considered as early as 3 months so that the patient can return to daily verbal communication.

In our group, 6 of 31 patients underwent a CI procedure; 5 of 6 were implanted in the second ear that developed SHL, and consequently with a shorter deprivation. The hearing performances were very good in all these patients with a mean of 87.5% [range 75-100%] of post-operatively disyllabic word recognition scores.

Only one patient was implanted in the first ear that developed SHL. This choice was due to the fact that the hearing threshold was significantly better in the second deafened ear (so as to allow the use of a hearing aid, even if with partial results), and also to the fact that the first ear had a history of slight progressive SHL with long term use of a hearing aid. The auditory performances with CI only were good and satisfactory even in this patient, but lower than in the previously reported 6 patients (70% recognition of bisyllabic words). However, with bimodal stimulation the patient reached 100% of the recognition score. Moreover, he reported good satisfaction with the implant and benefits in the quality of life.

In patients with bilateral severe to profound SHL, candidates for a CI procedure, the criteria employed for the choice of the ear to implant has changed over the years. If residual hearing in one ear is suitable for hearing aid fitting, implantation in the worse ear is preferred to allow bimodal stimulation. If none of the ears is good for HA fitting, it is usually recommended to implant the ear with less hearing deprivation. Hearing deprivation is one of the stronger predictors of CI outcome in adults with post-verbal hearing loss.

However, in the literature there is no clear agreement on the choice of the side to implant in patients with monoaural sound deprivation. Several authors<sup>24-25</sup> have reported that implanting the ear with a longer deprivation did not appear to have a negative impact on CI outcome. Notwithstanding, the UK Cochlear Implant Study Group<sup>26</sup> argued that CI was less effective in the ear with a longer deprivation even if residual hearing is better.

Recently, Boisvert et al. 2012<sup>27</sup> examined speech recognition results in 30 adults with bilateral SHL using only one hearing aid. Fifteen received the implant in the sound-deprived ear and 15 in the aided ear. The authors concluded that there was no significant difference in speech recognition results for the 2 groups when the patient in the group with CI in the sound deprived ear were tested with bimodal stimulation.

Among the 6 patients of our sample submitted to CI, 5 were not suitable for HA fitting, and the second deafened ear was implanted with good results. We decided to implant the remaining one patient on the first deafened ear, because the second ear was suitable for HA fitting.

## Conclusions

Herein, we focus our attention on progressive, sudden or fluctuating SHL in the only hearing ear. SHL occurrence is not negligible and it would be important to better understand the risk for patients with an only hearing ear to develop SHL in the contralateral one.

We believe a comprehensive diagnostic protocol is mandatory to investigate all known causes of hearing loss (ear malformations, genetic anomalies, superficial siderosis,

etc.) and, if possible, to prevent contralateral involvement. Further studies should be conducted in the aetiology, epidemiology and aetiopathogenesis, because at present only hypotheses (genetic, micro-malformation, autoimmune, viral) can be made regarding the genesis of SHL in the only hearing ear.

HA fitting may not be simple for the progression or fluctuation of hearing loss over time, and therefore CI may be indicated in patients that developed a bilateral severe to profound SHL. According to literature data, the results of our patients submitted to CI are satisfactory. Our data (even if the sample is small) seem to indicate that better results can be expected in patients implanted in the ear with a shorter deprivation. Good results can be also achieved in patients implanted in the first deafened ear by using bimodal stimulation.

## References

- 1 Lee SS, Ho Cho H, Ho Jang C, et al. *Fate of sudden deafness occurring in the only hearing ear: outcomes and timing to consider cochlear implantation*. J Korean Med Sci 2010;25:283-6.
- 2 Stahl N, Cohen D. *Idiopathic sudden sensorineural hearing loss in the only hearing ear: patient characteristics and hearing outcome*. Arch Otolaryngol Head Neck Surg 2006;132:193-5.
- 3 Hawkins DB. *Hearing rehabilitation in a patient with sudden sensorineural hearing loss in the only hearing ear*. Am Acad Audiol 2008;19:267-74.
- 4 Pyykkö I, Ishizaki H, Peltomaa M. *Azathioprine with cortisone in treatment of hearing loss in only hearing ear*. Acta Otolaryngol Suppl 1997;529:83-5.
- 5 Nadol JB Jr, Weiss AD, Parker SW. *Vertigo of delayed onset after sudden deafness*. Ann Otol Rhinol Laryngol 1975;84:841-6.
- 6 Giannoni B, Pagnini P, Vannucchi P. *Delayed endolymphatic hydrops*. [Article in Italian]. Acta Otorhinolaryngol Ital Suppl 1998;59:66-70.
- 7 Berrettini S, De Vito A, Bruschini L, et al. *Cochlear implantation in patients affected by superficial hemosiderosis of the central nervous system*. Eur Arch Otorhinolaryngol 2012;269:25-31.
- 8 Berrettini S, Piragine F. *Progressive sensorineural hearing loss: definition, classification, main etiological factors*. [Article in Italian]. Acta Otorhinolaryngol Ital Suppl 1998;59:9-12.
- 9 Zadeh MH, Storper IS, Spitzer JB, et al. *Diagnosis and treatment of sudden-onset sensorineural hearing loss: a study of 51 patients*. Otolaryngol Head Neck Surg 2003;128:92-8.
- 10 Kirikae I, Matsuzaki T. *Clinical observations of bilateral sudden deafness*. Audiol Jpn 1967;10:320-5.
- 11 Shaia FT, Sheehy JL. *Sudden sensori-neural hearing impairment: a report of 1,220 cases*. Laryngoscope 1976;86:389-98.
- 12 Fetterman BL, Luxford WM, Saunders JE, et al. *Sudden bilateral sensorineural hearing loss*. Laryngoscope 1996;106:1347-50.

- <sup>13</sup> Byl FM Jr. *Sudden hearing loss: eight years' experience and suggested prognostic table*. *Laryngoscope* 1984;94:647-61.
- <sup>14</sup> Klemm E, Deutscher A, Mosges R. *A present investigation of the epidemiology in idiopathic sudden sensorineural hearing loss* [in German]. *Laryngorhinootologie* 2009;88:524-7.
- <sup>15</sup> Agarwal SK, Singh S, Ghuman SS, et al. *Radiological assessment of the Indian children with congenital sensorineural hearing loss*. *Int J Otolaryngol* 2014;2014:808759.
- <sup>16</sup> Schuknecht HF, Gulya AJ. *Endolymphatic hydrops. An overview and classification*. *Ann Otol Rhinol Laryngol Suppl* 1983;106:1-20.
- <sup>17</sup> Di Nardo W, Cattani P, Lopizzo T, et al. *Multiple viral genome search in endolabyrinthic fluids of profoundly deaf patients: possible cytomegalovirus intracochlear reactivation*. *Audiol Neurootol* 2009;14:290-5.
- <sup>18</sup> Casani A, Fattori B, Berrettini S, et al. *Delayed endolymphatic hydrops: an analysis of 12 cases*. [Article in Italian] *Acta Otorhinolaryngol Ital* 1993;13:297-303.
- <sup>19</sup> Dreyer WB, Zegarra H, Zakov ZN, et al. *Sympathetic ophthalmia*. *Am J Ophthalmol* 1981;92:816-9.
- <sup>20</sup> Gloddek B, Rogowski M, Arnold W. *Adoptive transfer of an autoimmune labyrinthitis in the guinea pig; animal model for a sympathetic cochleolabyrinthitis* *Clin Exp Immunol* 1994;97:133-7.
- <sup>21</sup> Berrettini S, Ravecca F, Forli F, et al. *Diagnostic and therapeutic approach to progressive sensorineural hearing loss*. [Article in Italian]. *Acta Otorhinolaryngol Ital Suppl* 1998;59:87-94.
- <sup>22</sup> Stachler RJ, Chandrasekhar SS, Archer SM, et al. *Clinical practice guideline: sudden hearing loss*. *Otolaryngol Head Neck Surg* 2012;146:S1-35.
- <sup>23</sup> Fujino K, Naito Y, Endo T, et al. *Clinical characteristics of delayed endolymphatic hydrops: long-term results of hearing and efficacy of hyperbaric oxygenation therapy*. *Acta Otolaryngol Suppl* 2007;557:22-5.
- <sup>24</sup> Francis HW, Yeagle JD, Brightwell T, et al. *Central effects of residual hearing: implications for choice of ear for cochlear implantation*. *Laryngoscope* 2004;114:1747-52.
- <sup>25</sup> Chen JM, Shipp D, Al-Abidi A, et al. *Does choosing the "worse" ear for cochlear implantation affect outcome?* *Otol Neurotol* 2001;22:335-9.
- <sup>26</sup> UK Cochlear Implant Study Group. *Criteria of candidacy for unilateral cochlear implantation in postlingually deafened adults I: theory and measures of effectiveness*. *Ear Hear* 2004;25:310-35.
- <sup>27</sup> Boisvert I, Lyxell B, Mäki-Torkko E, et al. *Choice of ear for cochlear implantation in adults with monaural sound-deprivation and unilateral hearing aid*. *Otol Neurotol* 2012;33:572-9.

Received: February 1, 2015 - Accepted: September 3, 2015



## OTOLOGY

# Early and late surgical site infections in ear surgery

## *Complicanze infettive locali precoci e tardive nella chirurgia otologica*

P.L. BASTIER<sup>1</sup>, C. LEROYER<sup>2</sup>, A. LASHÉRAS<sup>2</sup>, A.-M. ROGUES<sup>2</sup>, V. DARROUZET<sup>1</sup>, V. FRANCO-VIDAL<sup>1</sup>

<sup>1</sup> ENT and Head and neck surgery department, Bordeaux University Hospital, Bordeaux, France;

<sup>2</sup> Infection control unit, Bordeaux University Hospital, Bordeaux, France

### SUMMARY

A retroauricular approach is routinely used for treating chronic otitis media. The incidence of surgical site infections after ear surgery is around 10% in contaminated or dirty procedures. This observational prospective study describes surgical site infections after chronic otitis media surgery with the retroauricular approach and investigated their potential predictive factors. This observational prospective study included patients suffering from chronic otitis media and eligible for therapeutic surgery with a retroauricular approach. During follow-up, surgical site infections were defined as “early” if occurring within 30 days after surgery or as “late” if occurring thereafter.

The data of 102 patients were analysed. Concerning early surgical site infections, four cases were diagnosed (3.9%) and a significant association was found with preoperative antibiotic therapy, wet ear at pre-operative examination, class III (contaminated) in the surgical wound classification, NNIS (National Nosocomial Infection Surveillance) index > 1, and oral post-operative antibiotic use. Seven late surgical site infections were diagnosed (7.1%) between 90 and 160 days after surgery and were significantly correlated to otorrhoea during the 6 months before surgery, surgery duration ≤60 minutes, canal wall down technique and use of fibrin glue. Surgical site infections after chronic otitis media surgery seem to be associated with factors related to the inflammatory state of the middle ear at the time of surgery in early infections and with chronic inflammation in late infections.

**KEY WORDS:** Otitis media • Otologic surgical procedure • Surgical wound infection • Nosocomial infection

### RIASSUNTO

*La via retroauricolare rappresenta l'approccio di scelta nel trattamento dell'otite media cronica. Nelle procedure “sporche” l'incidenza della complicanza infettiva locale è del 10%. Il presente studio analizza le infezioni del sito chirurgico dopo la chirurgia dell'otite media cronica e ne investiga i potenziali fattori predittivi. Il presente studio, dal design osservazionale prospettico, ha incluso pazienti affetti da otite media cronica e candidati alla chirurgia mediante approccio retroauricolare. Sono state definite precoci le complicanze postoperatorie insorte entro i 30 giorni e tardive quelle insorte oltre i 30 giorni. Sono stati analizzati i dati di 102 pazienti. Sono stati registrati 4 casi (3,9%) di infezione precoce, per la quale è stata evidenziata un'associazione significativa con l'antibiotico terapia preoperatoria, l'orecchio in fase secerne all'esame otoscopico preoperatorio, una classe III (contaminato) nella classificazione delle ferite chirurgiche, indice NNIS (National Nosocomial Infection Surveillance) >1 e assunzione di antibiotici per OS nel postoperatorio. Sono state inoltre registrate 7 complicanze tardive (7,1%), occorse fra i 90 e i 160 giorni dall'intervento, significativamente correlate alla presenza di otorrea nei sei mesi precedenti la chirurgia, una durata del tempo chirurgico inferiore o uguale a 60 minuti, una tecnica aperta e all'uso della colla di fibrina. L'infezione del sito chirurgico sembra essere associata ai fattori correlati allo stato infiammatorio dell'orecchio medio al momento della chirurgia nelle infezioni precoci e all'infiammazione cronica nelle infezioni tardive.*

**PAROLE CHIAVE:** Otite media • Procedura chirurgica • Infezione della breccia chirurgica • Infezione nosocomiale

Acta Otorhinolaryngol Ital 2016;36:127-134

## Introduction

The term chronic otitis media (COM) covers a wide range of otological pathologies characterised by the presence of chronic inflammation of the middle ear and mastoid cavities mucosa<sup>1</sup>. Dry or suppurative tympanic perforations, cholesteatomas and inflammatory mediated ossicular lesions are the main presentations of COM<sup>2</sup>. The retroauricular approach, which is routinely performed for treating COM, allows access to the tympanic membrane, middle ear cleft and mastoid through a retroauricular incision. The goals of COM surgery differ according to the

type of lesions: removal of infective and devitalized tissues within the mastoid, cholesteatoma excision, opening of all the air cells in a common cavity, and repair of the tympanic membrane or sound-conducting mechanisms<sup>3,4</sup>. As infectious complications may arise spontaneously in COM both intra- and extra-cranially, there is a potential for surgical site infection (SSI) after intervention<sup>5</sup>. The incidence of SSI after ear surgery is around 10% in contaminated or dirty procedures<sup>6</sup>. The three main sources of contamination are flora of the normal middle ear and rhinopharynx, flora of the skin through the external auditory

canal (EAC) or retroauricular incision, and pathogenic bacteria within infected mastoid cells <sup>6</sup>.

Local infection after tympanoplasty may require antibiotic treatment, hospitalisation and even re-intervention. Moreover, infection may impair tympanic graft uptake and long-term functional results of hearing and mastoid cell ventilation <sup>7</sup>.

The aim of this work was to study potential predictive factors for SSI after COM surgery performed with a retroauricular approach.

## Materials and methods

This observational prospective study was conducted by the ENT department of a tertiary referral centre in association with an infection control unit. This study protocol was approved by the local ethics committee.

All the patients suffering from COM and eligible for therapeutic surgery with a retroauricular approach were consecutively included. Exclusion criteria were: presence of another active otologic disease including acute otitis media or external, retroauricular cutaneous infection at the time of surgery, history of previous head and neck radiotherapy, previous SSI of the operated ear 30 days before surgery. Patients receiving intradermal corticosteroid injections for the treatment of a retro-auricular keloid at the same time were also excluded.

Patients were admitted on the evening before or day of surgery in ambulatory or conventional hospitalisation. The day before and the morning of surgery, patients took a povidone-iodine shower including shampoo. Retroauricular hair was clipped at admission. All the patients were operated on by one of two experienced senior surgeons. The operative field was scrubbed with povidone-iodine scrub solution then painted with povidone-iodine solution associated with a povidone-iodine ear bath. Subcutaneous tissues were infiltrated using adrenalinated lidocaine solution from the hypodermis to the periosteum. The retroauricular approach was performed in every patient by a retroauricular cutaneous incision to reach the middle ear by dissection along the osseous EAC and/or by drilling through the mastoid cavities. According to the disease, several other procedures may have been performed, such as antromastoidectomy using the canal wall up (CWU) or canal wall down (CWD) method, cholesteatoma removal, ossiculoplasty, or tympanoplasty. These techniques may have used autologous (auricular cartilage, ossicle, fascia temporalis) or foreign materials (titanium ossicular prosthesis, myringotomy tube, fibrin glue, gelatine sponge). After the procedure, single interrupted suturing was used with nylon monofilament in adults and polymeric absorbable suture in children. Ear packing was then set into the EAC using silicone sheets and ear wicks. Retroauricular incision care included daily cleaning, disinfection with an antiseptic and dressing by a nurse at the patient's home.

According to applicable standards <sup>8</sup>, antibiotic prophylaxis

was not given systematically. Intravenous intra-operative and oral post-operative antibiotic treatments were given in the event of an active infectious or inflammatory state discovered in the middle ear during surgery. However, all patients received local antibiotics (auricular ofloxacin) during packing and for 10 days after its removal.

Packing duration and delay between total packing removal and first control visit depended on the characteristics of the patients and the interventions performed.

Follow-up ended at the first control visit (one month or more later after total packing removal depending on the type of surgery) or in the event of an SSI diagnosis. SSI were defined by one or more of the following criteria: inflammation of the retroauricular scar, retroauricular purulent discharge, purulent otorrhoea or otitis media. All SSI diagnoses were validated by the surgeons responsible for patient care. SSI were defined as "early SSI" if occurring within 30 days after surgery or as "late SSI" if occurring thereafter. Early SSI patients were excluded from the analysis of late SSI.

Pre-, intra- and post-operative data were recorded by a member of the surgical team at each follow-up. Parameters were patient age and sex, tobacco use, existence of previous surgery on the same ear, ear discharge during the six months before surgery, rhinosinusitis or antibiotic treatment (systemic or topical use) during the two weeks before surgery, results of pre-operative ear examination, month of surgery, type of hospitalisation (ambulatory or conventional), order of the intervention in the day's planning of the operating theatre, duration of surgery, presence of cholesteatoma in the middle ear cavities, need for bone drilling, use of CWU or CWD technique, need for autologous graft (bone, cartilage, fascia), foreign material (gelatine sponge, fibrin glue, non-resorbable implant), resorbable suture, use of intravenous intra-operative or post-operative oral antibiotics, and ear packing duration. According to the pre-operative otoscopic examination, "wet ear" patients were differentiated from "dry ear" patients. Wet ears were defined as a non-purulent otorrhoea of the EAC. This state was different from infected ears, which were excluded, and was considered as a sign of active COM. We also determined the American Society of Anesthesiologists (ASA) score and the surgical wound contamination class for each patient in order to calculate the National Nosocomial Infection Surveillance (NNIS) index <sup>9-11</sup>. Contaminated surgery included wet ears and ears where an inflammatory state was diagnosed after opening the middle ear. Other interventions were classified as clean-contaminated.

Analyses were done with Microsoft Access 2007 for Windows and GraphPad Prism V6.01 for Windows (GraphPad Software, Inc., San Diego, CA). Associations between SSI and characteristics of patients and surgery were analysed using Fisher's exact test. Results were expressed as hazard ratio (95% confidence interval) [HR (95% CI)]. A  $P < 0.05$  was considered as statistically significant.

## Results

Between November 2011 and June 2012, 111 patients were included. Of these, three were excluded because the inclusion criteria were not respected. Five patients were lost to follow-up after complete packing removal. One patient was excluded for acute otitis media diagnosed during surgery. Analyses were performed on the remaining 102 patients. There were 62 men and 40 women with a mean age of  $34.5 \pm 19.5$  years. A canal wall up approach was needed in 94% of interventions and 44% needed bone drilling. Cholesteatoma was found in middle ear cavities in 62 patients. Mean follow-up was  $124.7 \pm 83.2$  days. Eleven SSI were diagnosed during the follow-up (overall SSI rate 10.8%). Characteristics of patients and SSIs are described shown in Table I.

### Early SSI

Four early SSI were diagnosed (early SSI rate 3.9%) between 3 and 30 days after surgery. The symptoms were mainly purulent otorrhoea and scar inflammation. In univariate analysis, the following factors were significantly correlated with early SSI: pre-operative antibiotic therapy, wet ear at pre-operative examination, class III (contaminated) in surgical wound classification, NNIS score >1 and, oral post-operative antibiotic use (Table II).

### Late SSI

Seven late SSI were diagnosed amongst the 98 remaining patients (late SSI rate 7.1%) between 90 and 160 days after surgery. The most common presentation of late SSI was purulent otorrhoea. In univariate analysis, the following factors were significantly correlated with late SSI: ot-

**Table I.** Characteristics of SSI patients. Eleven patients were diagnosed with SSI during the follow-up. (CWU: Canal Wall Up, CWD: Canal Wall Down, Scar infl.: scar inflammation, Purulent otor.: purulent otorrhoea, Atb: antibiotic therapy, Hosp.: hospitalisation).

Case number	Early SSI				Late SSI						
	1	2	3	4	5	6	7	8	9	10	11
Age (y)	53	39	59	16	48	31	23	68	12	17	40
Sex	F	M	M	M	M	F	F	F	M	M	M
Otorrhoea during the previous 6 months	No	Yes	Yes	No	Yes	Yes	Yes	No	No	No	Yes
Pre-operative antibiotic therapy	No	Local	Oral, Local	No	No	No	No	No	No	No	No
Pre-operative ear examination	Wet	Wet	Wet	Dry	Wet	Dry	Dry	Dry	Dry	Dry	Wet
Cholesteatoma	No	No	Yes	Yes	No	No	Yes	Yes	No	No	Yes
Drilling	No	No	Yes	Yes	No	Yes	Yes	Yes	No	No	Yes
Technique	CWU	CWU	CWD	CWU	CWU	CWU	CWU	CWD	CWU	CWU	CWD
Autologous graft	Cartilage	Cartilage, fascia, bone	Cartilage	No	Fascia	Cartilage, fascia	Cartilage, fascia, bone	Cartilage	Cartilage, fascia	Cartilage	Cartilage, fascia
Foreign material	No	No	Fibrin Glue	No	Gelatine Sponge	Gelatine Sponge	No	Fibrin Glue	No	No	Fibrin Glue
Resorbable suture	No	No	No	No	No	No	Yes	No	Yes	No	No
Intravenous intra-operative antibiotic administration	No	Yes	No	No	Yes	No	No	No	No	No	Yes
Oral post-operative antibiotic administration	Yes	Yes	No	Yes	Yes	No	No	No	No	No	Yes
NNIS score <sup>a</sup>	2	2	2	1	1	0	1	1	1	1	2
Clinical examination at SSI diagnosis	Scar infl., purulent otor.	Scar infl.	Purulent otor.	Purulent otor.	Purulent otor.	Purulent otor.	Purulent otor.	Purulent otor.	Pain, purulent otitis media	Purulent otor.	Pain, purulent otor.
Time to SSI diagnosis after surgery (days)	3	7	11	30	90	100	116	122	150	157	160
Treatment of SSI	Atb, hosp., surgery	Atb, hosp.	Atb	Atb	Atb	Atb	Atb	Atb	Atb	Atb	Atb

<sup>a</sup> NNIS score: one point given for each of the following criteria: ASA score of 3-5, contaminated or dirty-infected surgery and surgery lasting longer than 60 minutes.

**Table II.** Univariate analysis of early SSI of patients and intervention characteristics. The statistical association between early SSI and patients or interventions characteristics was studied using Fisher's exact test. P values in bold are statistically significant. (HR: Hazard Ratio, CI: Confidence interval; CWU: Canal Wall Up, CWD: Canal Wall Down).

		Total n = 102	SSI n = 4	No SSI n = 98	HR [95% CI]	p =
Age	≤ 15	32	0	32	1.13 [0.35; 3.6]	1.00
	> 15	70	4	66		
Gender	M	62	3	59	1.93 [0.2; 17.97]	1.00
	F	40	1	39		
Tobacco use	Yes	28	1	27	0.88 [0.1; 8.12]	1.00
	No	74	3	71		
Number of interventions on same ear	First	54	1	53	0.34 [0.03; 2.76]	0.34
	Second or more	48	3	45		
Otorrhoea during previous six months	Yes	22	2	20	3.64 [0.54; 24.38]	0.20
	No	80	2	78		
Infectious episodes during previous 15 days	Yes	5	0	5	0 [+∞; -∞]	1.00
	No	97	4	93		
Pre-operative antibiotic therapy	Yes	10	2	8	9.2 [1.45; 58.43]	<b>0.047</b>
	No	92	2	90		
Pre-operative ear examination	Wet	12	3	9	22.5 [2.54; 199.53]	<b>0.005</b>
	Dry	90	1	89		
Day off surgery	Yes	31	0	31	0 [+∞; -∞]	0.31
	No	71	4	67		
Surgery duration (min)	≤ 60	46	2	44	1.22 [0.18; 8.31]	1.00
	> 60	56	2	54		
Surgical wound classification	III	19	4	15	48.48 [2.48; 947.3]	<b>0.0009</b>
	II	83	0	83		
NNIS score	> 1	17	4	13	57 [2.9; 1120]	<b>0.0006</b>
	≤ 1	85	0	85		
Cholesteatoma	Yes	62	2	60	0.65 [0.09; 4.4]	0.64
	No	40	2	38		
Drilling	Yes	45	2	43	1.27 [0.19; 8.64]	1.00
	No	57	2	55		
Technique	CWU	96	3	93	0.19 [0.02; 1.54]	0.22
	CWD	6	1	5		
Autologous graft	Yes	97	3	94	0.15 [0.02; 1.24]	0.18
	No	5	1	4		
Foreign material	Yes	48	1	47	0.38 [0.04; 3.49]	0.62
	No	54	3	51		
Fibrin glue	Yes	5	1	4	6.47 [0.81; 51.64]	0.18
	No	97	3	94		
Non-resorbable foreign material	Yes	10	0	10	0 [+∞; -∞]	1.00
	No	92	4	88		
Resorbable suture	Yes	33	0	33	0 [+∞; -∞]	0.30
	No	69	4	65		
Intravenous intra-operative antibiotic administration	Yes	16	1	15	1.79 [0.2; 16.17]	0.50
	No	86	3	83		
Oral post-operative antibiotic administration	Yes	18	3	15	14 [1.54; 127.1]	<b>0.02</b>
	No	84	1	83		
Ear packing duration (d)	≤ 7	56	2	54	0.82 [0.12; 5.61]	1.00
	> 7	46	2	44		



orrhoea during the 6 months before surgery, surgery duration  $\leq 60$  minutes, canal wall down technique and use of fibrin glue (Table III).

The number of SSI cases in each group was insufficient to perform multivariate analysis.

## Discussion

Early and late SSI after surgery for COM with the retroauricular approach were associated with various predictive factors, underlining the fact that the two types of infection do not share the same pathophysiology.

Early SSI are linked to the inflammatory state of the ear at the time of surgery. Surgical procedures on inflammatory tissues seem to promote the proliferation of bacteria already present in the middle ear or on the patient's skin. The five predictive factors we found significantly associated with early SSI are related and reflect the inflammatory state of the middle ear in the days before or during the surgery. Some authors distinguish active vs. inactive COM<sup>4,12</sup>. The difference is based on the presence or absence of ear discharge at pre-operative examination<sup>12</sup> or within one month in the pre-operative period<sup>4</sup>. Wet ear in COM can be caused by mucosal oedema or myringitis along the edge of the perforation<sup>4</sup>. The distinction between wet and dry ear is based on the surgeon's assessment just before the intervention and may be more reliable than patient anamnesis and more related to COM activity on the day of surgery.

Our definition of early SSI matches with that of nosocomial SSI given by the Center for Disease Control (CDC)<sup>13</sup>, and can also be considered as being due to pathogens brought to the surgical site by various manoeuvres in spite of the preventive measures taken pre-, intra- and post-operatively. Nosocomial SSI has received much attention in the literature, although data on SSI in ear surgery are relatively scarce and lack specific or standardised definitions and indices. For example, the delay used to consider an infection as nosocomial varies from 2 weeks to 3 months, whereas the CDC consider it as 30 days<sup>6,14-18</sup>. Moreover, the CDC definitions of nosocomial SSI differentiate incisional infections (superficial and deep) and specific organ/space infections<sup>13</sup>. The CDC considers the ear and mastoid as a specific organ/space. Owing to communication created between the mastoid cavities and the subcutaneous plane by the retroauricular approach, the distinction between incisional and organ/space infection may be difficult in the event of retroauricular purulent discharge. It is also difficult to specify the origin of purulent otorrhoea. It may be due to superficial incisional infection of the EAC skin, to mechanical discharge of middle ear cavity infection through the separation planes, or to residual tympanic perforation. Exact diagnosis may require mastoid exploration surgically or by CT scan. However, the recent tendency is to apply a more helpful and clinically relevant definition

that distinguishes only wound infection from middle ear infection<sup>14</sup>.

The determination of Altemeier's surgical wound contamination class is a matter of debate in ear surgery. The middle ear is covered by a respiratory epithelium and communicates with the pharynx through the auditory tube. It can be considered as a part of the respiratory tract and thus middle ear surgery should be considered at least as clean-contaminated surgery according to Altemeier's terms. However, some authors feel that ear surgery can be classified as clean surgery in the absence of purulent ear discharge and outside the context of COM<sup>14</sup>. In our study, both wet ears and dry ears with an intra-operative diagnosis of local inflammation were classified as contaminated, while other ears i.e. dry ears without middle ear inflammation, were considered as clean-contaminated. The pre-operative distinction between dry and wet ears has some advantages compared to the exact determination of Altemeier contamination class. The latter can be determined only during surgery after opening the middle ear. In the study by Mills et al., mucosal disease was found in 28% of ears classified as inactive COM after otoscopic examination compared to 83% in active ears<sup>12</sup>. Calculation of the NNIS index requires the determination of the T cut point, which differentiates short and long operations. In the initial description of the NNIS index, the T time for ENT interventions (except head and neck surgery) was defined as the 75<sup>th</sup> percentile of the distribution of duration of surgery, rounded to the nearest whole number of hours. The authors obtained a T time equal to 3 hours from a pool of 1,061 ear, nose, mouth and pharynx interventions<sup>11</sup>. In our study, we used a T time equal to one hour, as recommended by the French SSI surveillance program (RAISIN). This value is also applicable to a wide range of non-otologic interventions. In our study on 102 interventions, the calculated T time was 105.75 minutes rounded to 2 hours. It may be useful to determine a more specific T time in a large population of ear interventions in order to increase the accuracy of the NNIS index in this specific context.

Our sample size was too small to determine the interdependence between antibiotic use, wet ear, surgical wound classification and NNIS score. Nevertheless, it appears that wet ear is the most clinically relevant factor predictive of early SSI. However, in the event that wet ear is diagnosed before surgery, there is no consensus as to whether the intervention should be postponed or whether antibiotic prophylaxis should be administered. Some authors have found that healing and functional results of tympanoplasty in ears with active COM are poorer than those in ears with inactive COM<sup>19,20</sup>. The wet/dry distinction has already been included in prognostic scores used in middle ear surgery and for predicting anatomical and functional long-term outcome<sup>3</sup>. Other authors found no difference between wet and dry ears with regards to the

**Table III.** Univariate analysis of late SSI of patients and intervention characteristics. The statistical association between late SSI and patients or intervention characteristics was studied by Fisher's exact test. P values in bold are statistically significant. (HR: Hazard Ratio, CI: Confidence interval; CWU: Canal Wall Up, CWD: Canal Wall Down).

		Total n = 98	SSI n = 7	No SSI n = 91	HR [95%CI]	p =
Age	≤ 15	32	1	31	0.34 [0.04; 2.74]	0.42
	> 15	70	6	60		
Gender	M	62	4	55	0.88 [0.21; 3.73]	1.00
	F	40	3	36		
Tobacco use	Yes	28	2	25	1.05 [0.22; 5.1]	1.00
	No	74	5	66		
Number of interventions on same ear	First	54	3	50	0.64 [0.15; 2.7]	0.70
	Second or more	48	4	41		
Otorrhoea during previous six months	Yes	22	4	16	5.2 [1.26; 21.39]	<b>0.03</b>
	No	80	3	75		
Infectious episodes during previous 15 days	Yes	5	0	5	0 [+∞; -∞]	1.00
	No	97	7	86		
Pre-operative antibiotic therapy	Yes	10	0	8	0 [+∞; -∞]	1.00
	No	92	7	83		
Pre-operative ear examination	Wet	12	2	7	3.96 [0.89; 17.55]	0.124
	Dry	90	5	84		
Day off surgery	Yes	31	3	28	1.62 [0.39; 6.81]	0.68
	No	71	4	63		
Surgery duration (min)	≤ 60	46	6	38	7.36 [0.92; 58.93]	<b>0.043</b>
	> 60	56	1	53		
Surgical wound classification	III	19	2	13	2.21 [0.47; 10.38]	0.29
	II	83	5	78		
NNIS score	>1	17	1	12	1.09 [0.14; 8.34]	1.00
	≤1	85	6	79		
Cholesteatoma	Yes	62	3	57	0.48 [0.11; 2.01]	0.43
	No	40	4	34		
Drilling	Yes	45	4	39	1.71 [0.4; 7.22]	0.70
	No	57	3	52		
Technique	CWU	96	5	88	0.13 [0.03; 0.53]	<b>0.04</b>
	CWD	6	2	3		
Autologous graft	Yes	97	7	87	0.77 [0.04; 15.75]	1.00
	No	5	0	4		
Foreign material	Yes	48	4	43	1.45 [0.34; 6.13]	0.71
	No	54	3	48		
Fibrin glue	Yes	5	2	2	9.4 [2.56; 34.47]	<b>0.025</b>
	No	97	5	89		
Non-resorbable foreign material	Yes	10	0	10	0 [+∞; -∞]	1.00
	No	92	7	81		
Resorbable suture	Yes	33	2	31	0.79 [0.16; 3.84]	1.00
	No	69	5	60		
Intravenous intra-operative antibiotic administration	Yes	16	2	13	2.21 [0.47; 10.38]	0.29
	No	86	5	78		
Oral post-operative antibiotic administration	Yes	18	2	13	2.21 [0.47; 10.38]	0.29
	No	84	5	78		
Ear packing duration (d)	≤ 7	56	5	49	2.04 [0.41; 10]	0.45
	> 7	46	2	42		

outcome of tympanoplasty and affirmed that ear discharge was not a reason to postpone surgery<sup>12</sup>. However, no indication was given in that study concerning the causes of failure, including the rates of SSI. Functional outcome (auditory status, tympanic closure) was not collected during our study and the occurrence of SSI ended the follow-up. Data concerning the effects of SSI on functional outcome could have helped in the decision to postpone surgery in the event of a wet ear. This was especially true in the event of minor SSI such as delayed purulent ear discharge accessible to local antibiotic therapy without the need for surgery or rehospitalisation. Ears with active COM are usually treated medically before surgery to stop the discharge and lower mucosal inflammation<sup>12</sup>. The only active COM ears that we operate are those that are resistant to medical treatment and where surgery may help in controlling the inflammatory process by removing any infective tissues and re-establishing normal middle ear cavity ventilation. Concerning antibiotic prophylaxis, a recent meta-analysis showed that there was no significant evidence that antibiotic prophylaxis is helpful in reducing SSIs after ear surgery<sup>14</sup>. The same authors also found a bias in some studies where surgical wound class was determined pre-operatively according to the type of surgery without taking intra-operative findings into account<sup>14</sup>. The late SSI diagnosed in this study were not due to nosocomial infection in view of their time to onset. Unlike early SSI, late SSI mechanisms seem to involve anatomical modifications of middle ear cavities due to surgery and chronic inflammatory activity of COM before surgery. Otorrhoea during the 6 months before surgery could be a marker of this chronic inflammation and is associated with late SSI onset, while wet ear at the time of surgery seems only to predict early SSI. The anatomical goals of COM surgery to avoid recurrence are the removal of all inflammatory tissue and the readjustment of the V/S ratio where V is for ventilation (the volume of air circulating in the middle ear) and S is for surface (the area of the walls of the middle ear cavities)<sup>21</sup>. In some cases of common tympanoplasty, tympanic membrane repair may impair ventilation of the middle ear and decrease the elimination of inflammatory secretions. This can lead to SSI even if the normal anatomy has been restored. Massive cholesteatoma or recurrent COM need a wide opening of the antromastoid cavities using the CWD method, and perfect ventilation is difficult to achieve in such cases, leading to recurrent infections. This kind of surgery, especially in multi-operated ears, might be more rapid than simple tympanoplasty in ears with fewer extended lesions. This might partly explain the paradoxical correlation between late SSI and shorter duration of surgery. Long duration of surgery is usually associated with SSI, a parameter that is included in the NNIS score<sup>11,22</sup>. However, duration of surgery does not seem to influence retroauricular wound infection rates at 3 weeks after tympanomastoid surgery<sup>4</sup>. The associa-

tion between fibrin glue usage and late SSI remains unclear and has not been reported to date either in either ear surgery or in interventions involving other areas of the body. The small number of patients in our study in whom fibrin glue was used could have introduced a bias. The number of cases with fibrin glue use may also have been biased. Fibrin glue is often used with bone powder or hydroxyapatite to fill mastoid cavities, but these materials are to be avoided in the event of active inflammation. Further studies are needed to confirm this association.

A limitation in of the present study was the absence of exhaustive bacteriological analysis. Only a few sterile bacteriological analyses were performed for every case of wet ear and for each case of SSI. The data obtained were not sufficient to draw conclusions about important questions such as the difference between pre- and post-operative bacteriological flora or the pre-operative identification of germs significantly implicated in SSI.

## Conclusions

The abovementioned data highlight the need for specific SSI surveillance procedures and for risk indices in otologic surgery<sup>22</sup>. Larger studies would help to confirm our results and the use of long-term functional parameters and bacteriological analysis would help aid in guiding the clinician when confronted by the different kinds of COM that may be encountered.

## Acknowledgements

The authors thank the Drs O. Bellec, C. Nagouas, D. Dunion, M. Cauchois, I. Larget, D. Bonnard, F. Porez, D. Fonmarty and J. Nodimar for their valuable help in caring for the patients included in this study.

## References

- 1 Verhoeff M, van der Veen EL, Rovers MM, et al. *Chronic suppurative otitis media: a review*. Int J Pediatr Otorhinolaryngol 2006;70:1-12.
- 2 Pulec JL, Deguine C. *Classification of chronic suppurative otitis media*. Oper Tech Otolaryngol-Head Neck Surg 1995;6:2-4.
- 3 Becvarovski Z, Kartush JM. *Smoking and tympanoplasty: implications for prognosis and the Middle Ear Risk Index (MERI)*. Laryngoscope 2001;111:1806-11.
- 4 Bidkar VG, Jalisatigi RR, Naik AS, et al. *Perioperative only versus extended antimicrobial usage in tympanomastoid surgery: a randomized trial*. Laryngoscope 2014;124:1459-63.
- 5 Panda NK, Sreedharan S, Mann SB, et al. *Prognostic factors in complicated and uncomplicated chronic otitis media*. Am J Otolaryngol 1996;17:391-6.
- 6 Govaerts PJ, Raemaekers J, Verlinden A, et al. *Use of antibiotic prophylaxis in ear surgery*. Laryngoscope 1998;108:107-10.

- 7 Pignataro L, Grillo Della Berta L, Capaccio P, et al. *Myringoplasty in children: anatomical and functional results*. J Laryngol Otol 2001;115:369-73.
- 8 Société Française d'Anesthésie-Réanimation. *Antibioprophylaxie en chirurgie et médecine interventionnelle (patients adultes)* [Internet]. 2010 [cité 2014 juill 25]; Available from: [http://www.sfar.org/\\_docs/articles/Antibioprophylaxieversion2010.doc.pdf](http://www.sfar.org/_docs/articles/Antibioprophylaxieversion2010.doc.pdf)
- 9 Dripps R. *New classification of physical status*. Anesthesiology 1963;24:111.
- 10 Altemeier W A, Burke J F, Pruitt B A, et al. *Manual on Control of Infection in Surgical Patients*. 2<sup>nd</sup> Ed. Philadelphia, PA, USA: JB Lippincott 1984.
- 11 Culver DH, Horan TC, Gaynes RP, et al. *Surgical wound infection rates by wound class, operative procedure, and patient risk index. National Nosocomial Infections Surveillance System*. Am J Med 1991;91:152S-157S.
- 12 Mills R, Thiel G, Mills N. *Results of myringoplasty operations in active and inactive ears in adults*. Laryngoscope 2013;123:2245-9.
- 13 Horan TC, Gaynes RP, Martone WJ, et al. *CDC definitions of nosocomial surgical site infections, 1992: a modification of CDC definitions of surgical wound infections*. Infect Control Hosp Epidemiol Off J Soc Hosp Epidemiol Am 1992;13:606-8.
- 14 Verschuur HP, de Wever WWH, van Benthem PPG. *Antibiotic prophylaxis in clean and clean-contaminated ear surgery*. Cochrane Database Syst Rev Online 2004;CD003996.
- 15 Hester TO, Jones RO. *Prophylactic antibiotics in surgery for chronic ear disease*. Laryngoscope 1998;108:1334-7.
- 16 Kattipattanapong W, Isaradisaiikul S, Hanprasertpong C. *Surgical site infections in ear surgery: hair removal effect; a preliminary, randomized trial study*. Otolaryngol Head Neck Surg 2013;148:469-74.
- 17 Borgstein J, de Zwart G, Bruce IA. *Ear packing after ear surgery: is it really necessary?* J Laryngol Otol 2008;122:253-4.
- 18 Winerman I, Segal S, Man A. *Effectiveness of prophylactic antibiotic treatment in mastoid surgery*. Am J Otol 1981;3:65-7.
- 19 Denoyelle F, Roger G, Chauvin P, et al. *Myringoplasty in children: predictive factors of outcome*. Laryngoscope 1999;109:47-51.
- 20 Onal K, Uguz MZ, Kazikdas KC, et al. *A multivariate analysis of otological, surgical and patient-related factors in determining success in myringoplasty*. Clin Otolaryngol 2005;30:115-20.
- 21 Portmann M, Portmann D. *Management of open and closed cavities in otology*. Rev Laryngol Otol Rhinol 1990;111:181-3.
- 22 Mangram AJ, Horan TC, Pearson ML, et al. *Guideline for Prevention of Surgical Site Infection, 1999. Centers for Disease Control and Prevention (CDC) Hospital Infection Control Practices Advisory Committee*. Am J Infect Control 1999;27:97-132; quiz 133-4; discussion 96.

Received: March 31, 2015 - Accepted: July 25, 2015

Address for correspondence: Pierre-Louis Bastier, ENT and Head and Neck Surgery Department, Bordeaux University Hospital, Place Amélie Raba-Leon, 33000 Bordeaux, France. Tel. +33 5 57 82 02 84. Fax +33 5 56 79 87 68. E-mail: [plbastier@hotmail.fr](mailto:plbastier@hotmail.fr)



OTOLOGY

# Can the learning curve in stapes surgery predict future functional outcome?

*L'analisi della curva di apprendimento della chirurgia dell'otosclerosi può aiutare a predire i risultati funzionali?*

B. SERGI, G. PALUDETTI

Clinic of Otorhinolaryngology; Università Cattolica di Roma, Italy

## SUMMARY

Over the last 20 years, the number of stapes operations performed has decreased steadily. This inadequate exposure to stapes surgery poses problems for both trainees and trainers. We retrospectively reviewed the outcomes of stapedotomy performed by a young physician at the ENT Clinic of the "A. Gemelli" Hospital of Rome. We used the technique of "one-shot" CO<sub>2</sub> Laser stapedotomy using a titanium-Teflon piston. For data analysis, we considered the audiograms obtained 24 hours preoperatively and at the last follow-up examination (mean 45 months). Air conduction (AC) and bone conduction (BC) PTA were calculated for 0.25, 0.5, 1, 2 and 4 kHz thresholds. Air bone gap (ABG) were obtained from ACPTA and BCPTA. Postoperative hearing gain was calculated from the ABG before the operation minus the ABG at late follow-up examination. Analysis of outcomes did not show a clear endpoint for the learning curve; complete closure of the ABG was obtained in a large number of patients at the beginning followed by patients who showed a higher ABG. Fortunately, we did not observe any "dead ear". The study supports a learning curve in stapes surgery, but the results can vary widely among surgeries with excellent results followed by others that are not fully satisfactory. Stapes surgery should not be one of the first ear surgeries performed by a young otologist due to the functional outcome expected by patients and the lack of necessary surgical skills.

KEY WORDS: Otosclerosis • Stapedotomy • CO<sub>2</sub> laser • Learning curve • Hearing threshold

## RIASSUNTO

*Il numero di interventi per otosclerosi è progressivamente diminuito nel corso degli ultimi 20 anni. Questa riduzione crea difficoltà sia al chirurgo esperto ma soprattutto a quello giovane che inizia il suo percorso di formazione. Abbiamo analizzato in maniera retrospettiva i risultati funzionali ottenuti dopo stapedotomia effettuati da un giovane chirurgo presso la Clinica Otorinolaringoiatrica del Policlinico "A. Gemelli" di Roma. La tecnica impiegata è quella della stapedotomia con laser CO<sub>2</sub> e utilizziamo una protesi in teflon e titanio. I risultati funzionali sono stati valutati come riduzione della ipoacusia trasmissiva sulle frequenze comprese tra 250 e 4000 Hz all'ultimo esame eseguito durante il follow-up. L'analisi dei dati non ha evidenziato un momento in cui la curva di apprendimento possa essere considerata conclusa poiché ottimi risultati con una riduzione pressoché completa della ipoacusia trasmissiva si sono alternati con altri i cui risultati funzionali non sono stati altrettanto ottimi. In nessun caso si è comunque registrata una coclearizzazione dell'ipoacusia. Questa analisi supporta l'esistenza di una curva di apprendimento della chirurgia dell'otosclerosi senza però individuare un punto dopo il quale si possa prevedere che i risultati funzionali saranno tutti ottimi. La chirurgia dell'otosclerosi non dovrebbe essere effettuata all'inizio della pratica della chirurgia otologica, data l'aspettativa funzionale che il paziente ripone nell'intervento e la mancanza delle capacità chirurgiche necessarie.*

PAROLE CHIAVE: Otosclerosi • Stapedotomia • Laser CO<sub>2</sub> • Curva di apprendimento • Soglia uditiva

Acta Otorhinolaryngol Ital 2016;36:135-138

## Introduction

Stapes surgery is one of the most highly satisfying but technically challenging otologic procedures, and several studies have documented that clinical outcomes are dependent on surgical experience<sup>1,2</sup>. During the last years, the number of stapes surgeries seems to be reduced, and some reasons can explain this trend: fluoridation of water supplies, improvement of quality of hearing aids and increasing number of surgeons. It follows that few cases of otosclerosis present to each surgeon per year leading to problems for acquiring the needed surgical skills for training. On the other hand, the

surgical technique and the technological tools have been improved over the decades rendering some tricky points more simple: stapedectomy surgeons changed to the small fenestra technique thus reducing the risk of an inner ear damage; microdrills and lasers allowed to perform safer platinotomy; the self crimping prosthesis have eliminated this dangerous part of the procedure.

We report and analyse the outcomes of our first surgeries for otosclerosis to determine if the functional results can be related to our learning curve and if we can draw some conclusions regarding future teaching activities.

### Materials and methods

From January 2008 to December 2011, 171 ears affected by otosclerosis were operated on at the Clinic of Otorhinolaryngology of the Università Cattolica del Sacro Cuore of Rome. There were 125 females and 46 males. The age at the time of surgery ranged between 18 and 74 years, with an average of 45 years (standard deviation 12 years). A diagnosis of otosclerosis was based on a clinical history of progressive hearing loss, normal otoscopic findings, an audiogram showing a mean conductive hearing loss of 20 dB in the range of 0.5 to 4 kHz and absence of cochleostapedial reflexes.

Surgery was performed under local anaesthesia with adequate preoperative sedation. In a few cases, upon the patient's request, general anaesthesia was used. A transcanal approach through an ear speculum was standard. After having visualised and evaluated the ossicular chain, cut the stapedial tendon, separated the incudostapedial joint and removed the stapes arch previously fractured by a hook, perforation of the footplate was obtained with a CO<sub>2</sub> laser using the SurgiTouch system (Lumenis Co., Tel Aviv, Israel) and the "one-shot technique". In all cases, the desired perforation diameter was achieved by a single shot, and in 12 cases, we rounded off the edges with the smallest hook. Usually, we use a power setting of 20 to 22 W with an exposure time of 0.03 to 0.05 second per pulse and a diameter of the shot of 0.6 mm. A 0.4 mm titanium Teflon prosthesis was then inserted in the perforation and crimped to the long process of the incus. The prosthesis diameter is 0.1 to 0.2 mm smaller than the perforation diameter. Finally, the oval window niche was sealed with connective tissue or a blood clot, the tympanomeatal flap was replaced and the ear canal was packed with Merocel.

Audiograms were obtained at least 24 hours preoperatively. Functional results were recorded at the last follow-up examination (mean 45 months; standard deviation 13 months; range 24-70 months). Audiologic evaluation was performed using a tonal audiometric test according to the guidelines of the Committee on Hearing and Equilibrium (1995; American Academy of Otolaryngology Head and Neck Surgery Foundation). Air-conduction and BC pure-tone average (PTA) values were calculated as the mean of 0.25, 0.5, 1, 2 and 4 kHz thresholds. Air-bone gaps (ABG) were obtained from ACPTA and BCPTA thresholds. Finally, the postoperative hearing gain was calculated from the ABG before the operation minus the ABG of the last follow-up examination. Patients were queried about occurrence of nystagmus, vertigo and tinnitus.

Data distribution was preliminarily assessed with a Kolmogorov-Smirnov test. After verifying the normal distribution of data, statistical analysis was performed using a Student's t test when 2 sets of data were compared and a paired, 2-way analysis of variance when more than 2 data sets were compared. The level of significance was set at  $p < 0.05$ .

### Results

Analysis of the data involved the consecutive surgeries performed by a single surgeon younger than 40 years at the beginning of his experience with stapes surgery. Among all the stapedotomies performed, 31 patients were operated on by the same surgeon. Two patients were excluded by the analysis because one patient was lost to follow-up and another was not considered because a stapedectomy was accidentally performed when fracturing the stapes superstructure.

No patient complained of tinnitus, nystagmus, or vertigo. The results are summarised in Figures 1 to 5.

The mean preoperative ACPTA was 55 dB, and the mean preoperative BCPTA was 23 dB. The mean pre-operative ABG was 32 dB (Fig. 1).

At the last follow-up, ACPTA was 31 dB, and BCPTA was 22 dB. Considering each frequency, the postoperative ACPTA improvement was greater at low and middle frequencies than at high frequencies: the ACPTA improvement was 33,

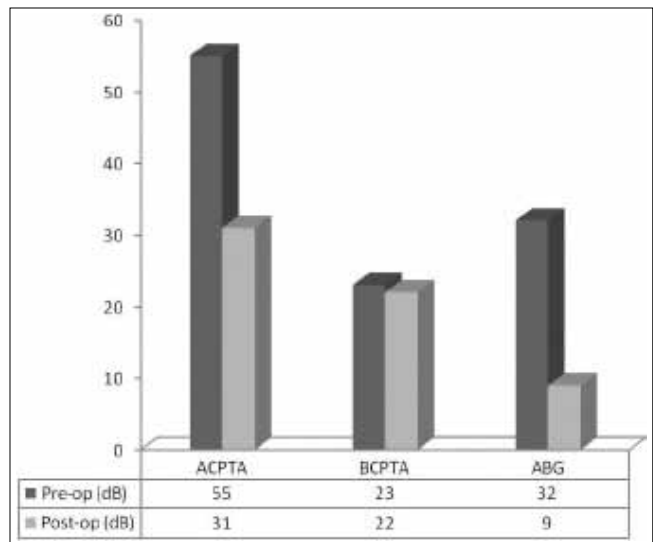


Fig. 1. Histograms show the main outcome of the study.

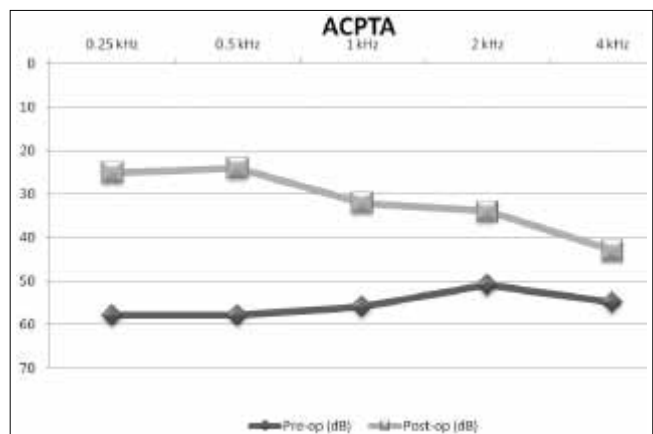


Fig. 2. Mean AC thresholds before and after surgery.

34, 24, 17 and 12 dB at 0.25, 0.5, 1, 2 and 4 kHz, respectively (Fig. 2). Bone conduction PTA remained almost stable at 0.25, 0.5 and 1 kHz, improved by 4 dB at 2 kHz and worsened by 2 at 8 kHz (Fig. 3). The mean post-operative ABG was 9 dB: 18 patients (62%) had an ABG of 10 dB or less; 10 patients (34,4%) presented an ABG between 11

and 20 dB; 1 patient (3,4%) showed an ABG between 21 and 30 dB (Fig. 4). The post-operative ABG for the 29 consecutive patients is reported in Figure 5.

Analysis of variance showed a statistically significant difference between preoperative and postoperative ACPTA ( $p < 0.001$ ); the postoperative ABG also improved significantly compared with preoperative ABG ( $p < 0.001$ ).

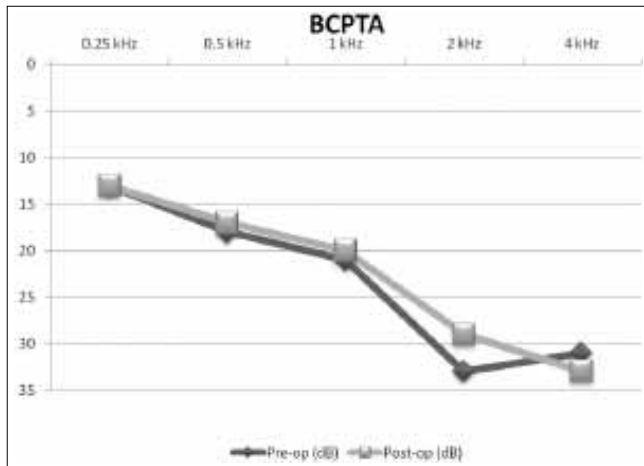


Fig. 3. Mean BC thresholds before after surgery.

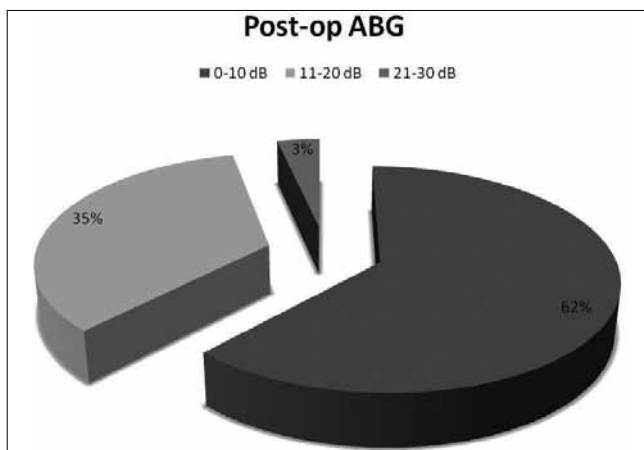


Fig. 4. Distribution of patients by the level of ABG after surgery.

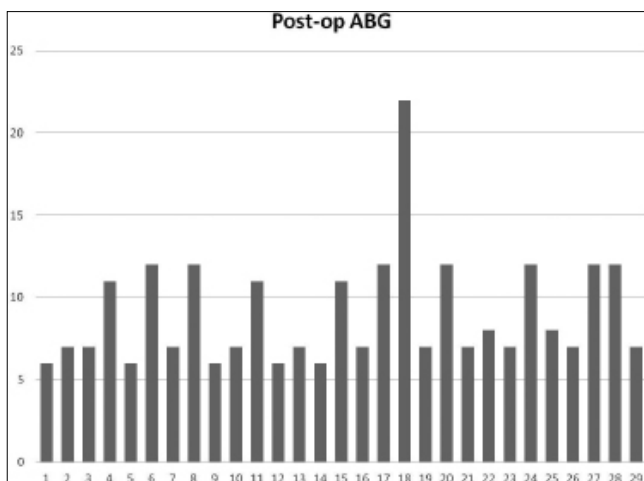


Fig. 5. Post-operative ABG for all patients.

## Discussion

When learning a new procedure, performance tends to improve with experience, and graphically plotting performance against experience produces a learning curve. The challenge becomes providing enough time and employing teaching strategies that facilitate universal achievement. Learning differs from surgeon to surgeon, and some surgeons will reach a peak faster than others. The key elements in learning are: unequivocal definition of what is to be learned and how it will be evaluated; allowing trainees to learn at their own pace; assessment of progress with appropriate feedback; and testing that the expert phase has been achieved. Learning a surgical technique is a process that goes through some stages. Didactic phase: study, watch videos and training with instruments and techniques on artificial and cadaver models; training phase: under staff supervision; practice phase: perform the procedure with increasing degrees of independence.

Stapes surgery is regarded as the ideal operation to investigate the learning curve of surgery. It is conceptually simple, but technically difficult. Once the technique is mastered, the results of stapes surgery are predictably good. Furthermore, the outcome of the operation is easily measured and can be compared with gold standard results of stapes surgery that are well documented. However, due to the few cases operated on each year, some otolaryngologists only perform their first complete stapes operation when they become consultants. It is natural that they go through a learning curve before they can achieve good results.

Many authors have reported on the learning curve in stapes surgery: some focused the analysis on the results obtained by residents<sup>3,4</sup>, others on the use of laser<sup>5</sup> and others on the decreasing number of surgeries performed with following impact for training<sup>6</sup>. Some authors quantified the learning curve analysing their results: Hughes<sup>1</sup> indicates that it took 50 stapes operations over a 9 year period to obtain a postoperative air-bone gap of 10 dB or better in 90% of patients. Yung reported that the peak on his learning curves appears to be at 60 to 70 cases over a 10 year period: there was no cochlear damage, and 90% of the cases had a postoperative air-bone gap of less than 10 (mean 6) dB. However, such favourable results were not maintained in subsequent cases. Oates, analysing his learning curve, noted two peaks, one at 30 to 40 cases (mean air-bone gap of 5.5 dB) and the other at 70 to 80 cases (mean air-bone gap of 5.2 dB) over a 6 year period. Both authors had a “dead” ear at the early

stage of their learning curve: case 13 for Yung and case 5 for Oates<sup>7</sup>. This volume of surgical experience stands in stark contrast to the number of surgeries performed by residents during training.

The analysis of our first surgeries showed that we achieved a good functional outcome in 29 patients over a 4 year period: the median air-bone gap was 6 dB, 62% of patients showed an air-bone gap less than 10 dB and we had no “dead” ears. However, if we analyse the post-operative air-bone gap of each patients, as shown in Figure 5, we noted that all results except one (patient 18) were acceptable, and that this unsatisfactory result was not at the beginning of our series but later on in the series.

As noted by Yung and Oates, we believe that it is wrong to set a clear endpoint in a functional technique such as stapes surgery, and that it would be better to speak of important milestones during the learning curve. Moreover, it is almost impossible to select the easiest cases for training in stapes surgery: in our series, we had an unintentional stapedectomy (not included in the analysis) and faced complications as intraoperative bleeding and some anatomical anomalies such as a narrow window niche and dehiscent facial nerve protruding over the stapes and the oval window. No preoperative technique, including high resolution CT, can help the young surgeon in diagnosis allowing referral of difficult cases to a more experienced surgeon. Nevertheless, we obtained good results since each surgery was performed under control of a well trained surgeon with immediate feedback. In this way, the young surgeon can feel more comfortable because the trainer can intervene at any time in the operation, if necessary; this is recommended because the well-being of patients is the first priority.

Moreover, the use of laser simplifies the procedure by avoiding manual fenestration of the oval window, which is one of the most challenging and difficult steps of stapes surgery: a small mistake can lead to disastrous results and complete sensorineural hearing loss. We use the CO<sub>2</sub> laser with the SurgiTouch system (Lumenis Co., Tel Aviv, Israel): in this device, the microprocessor-controlled rotating mirrors are synchronised to the laser, guiding the laser beam over the surface enabling a one-shot footplate perforation of a preselected diameter; it also reduces the generation of heat and induction of pressure waves in the scala vestibuli. One shot CO<sub>2</sub> laser stapedotomy can shorten the learning curve for a young surgeon: indeed, the laser allows to perforate the platina avoiding danger-

ous manipulation, permitting the young surgeon to feel more confident. However, the surgeon has to be aware of the target of the laser beam to avoid damage to surrounding structures. On the other hand, surgeons should know and apply more conventional techniques because the surgery must be concluded even in case of device failure.

## Conclusions

Stapedotomy is a highly satisfying but technically challenging otologic procedure, and several studies have documented that clinical outcomes are dependent on surgical experience. There has been an overall decline in volume of stapes surgery, and thought must be given to how to provide trainees with adequate training to perform this surgery safely and effectively. The reality is that the majority of current residency programs are not providing adequate training for stapedotomy. Surgical observation, graded surgical responsibility and temporal bone laboratory experience have remained the mainstay of otological training. For these reasons, we do not recommend to treat otosclerosis at the beginning of the surgical experience: it is desirable to achieve optimal surgical skills in middle ear surgery before dealing with a stapedotomy. We perform surgeries knowing that our first dead ear could be just around the corner, and we believe that the number of surgeries performed is not enough to ensure good hearing results.

## References

- 1 Hughes GB. *The learning curve in stapes surgery*. Laryngoscope 1991;101:1280-4.
- 2 Sargent EW. *The learning curve revisited: stapedotomy*. Otolaryngol Head Neck Surg 2002;126:20-5.
- 3 Backous DG, Coker NJ, Jenkins HA. *Prospective study of resident-performed stapedectomy*. Am J Otol 1993;14:451-4.
- 4 Vernick DM. *Stapedectomy results in a residency training program*. Ann Otol Rhinol Laryngol 1986;95:477-9.
- 5 Garin P, Watelet JB. *Lasers used by a young surgeon for stapes surgery*. Rev Laryngol Otol Rhinol 1998;119:55-8.
- 6 Ruckenstein MJ, Staab JP. *Who is performing stapedectomy surgery? Implications for residency and fellowship training*. Laryngoscope 2008;118:1224-7.
- 7 Yung MW, Oates J, Vowler SL. *The learning curve in stapes surgery and its implication to training*. Laryngoscope 2006;116:67-71.

Received: December 12, 2014 - Accepted: January 8, 2015

Address for correspondence: Bruno Sergi, University School of Medicine and Surgery, Department Head and Neck Surgery, Institute of Otorhinolaryngology, “A. Gemelli” Hospital, largo A. Gemelli 1, 00168 Rome, Italy. Tel. +39 06 30155544. Fax +39 06 3051194. E-mail: bruno.sergi@rm.unicatt.it



CLINICAL TECHNIQUES AND TECHNOLOGY

# Oral cavity reconstruction with the masseter flap

## *Ricostruzione del cavo orale con lembo massetere*

R. MAHIEU<sup>1,2</sup>, S. RUSSO<sup>3</sup>, T. GUALTIERI<sup>1</sup>, G. COLLETTI<sup>4</sup>, A. DEGANELLO<sup>1</sup>

<sup>1</sup> Department of Surgery and Translational Medicine, University of Florence, Italy; <sup>2</sup> University Medical Center, Groningen, The Netherlands; <sup>3</sup> National Cancer Institute Giovanni Paolo II, Bari, Italy; <sup>4</sup> Department of Maxillo-facial Surgery, University of Milan, Italy

### SUMMARY

The purpose of this report is to highlight how an unusual, outdated, unpopular and overlooked reconstructive method such as the masseter flap can be a reliable, straightforward and effective solution for oral reconstruction in selected cases. We report the transposition of the masseter crossover flap in two previously pre-treated patients presenting a second primary oral squamous cell carcinoma; excellent functional results with satisfactory cosmetic appearance were obtained in both cases. In the literature, only 60 cases of oral cavity and oropharyngeal reconstructions using the masseter flap have been reported. The possible clinical utility of this flap, even in modern head and neck reconstructive surgery, is presented and discussed. We believe that the masseter flap should enter in the armamentarium of every head and neck surgeon and be kept in mind as a possible solution since it provides an elegant and extremely simple procedure in suboptimal cases for microvascular reconstruction.

**KEY WORDS:** Oral cavity reconstruction • Masseter flap • Second primary tumor • Vessel depleted neck • Pedicled flap

### RIASSUNTO

*Lo scopo di questo lavoro è quello di evidenziare come una metodica ricostruttiva inusuale, datata ed impopolare come il lembo di massetere possa invece rappresentare, per casi selezionati, una soluzione affidabile, semplice ed efficace nelle ricostruzioni del cavo orale. Riportiamo di seguito l'utilizzo del lembo di massetere in due pazienti che presentavano un secondo tumore del cavo orale e che in precedenza erano già stati sottoposti ad intervento chirurgico nel distretto testa collo; in entrambi i casi sono stati ottenuti eccellenti risultati funzionali e soddisfacenti risultati estetici. In letteratura, fino ad oggi, sono stati riportati solo 60 casi di ricostruzione del cavo orale e dell'orofaringe con il lembo di massetere. L'utilità clinica del lembo di massetere, anche nell'ambito di un approccio moderno alle ricostruzioni del distretto testa collo, viene discussa approfonditamente in questo articolo. Riteniamo che il lembo di massetere debba far parte del bagaglio culturale di ogni chirurgo del testa-collo ed essere considerato fra le alternative proponibili, in quanto ha dimostrato di essere una metodica elegante ed estremamente semplice in casi in cui sussistono delle perplessità sulle procedure microvascolari.*

**PAROLE CHIAVE:** Ricostruzione cavo orale • Lembo di massetere • Secondo tumore primitivo • Lembo peduncolato

Acta Otorhinolaryngol Ital 2016;36:139-143

## Introduction

The most popular method for the management of oral cavity and oropharyngeal defects following cancer ablation is nowadays represented by the transposition of microvascular flaps<sup>1-3</sup>, and free flaps, in fact, offer the head and neck surgeon a broad variety of available tissues (bone, muscle, skin, etc.) for optimal restoration of form and function. However, not every defect strictly requires a free flap to achieve good functional results<sup>4,5</sup>, and not every patient is an optimal candidate for a microvascular procedure<sup>6</sup>. Therefore, alternative pedicled flaps<sup>7-12</sup> may have an important role even in the free flap era when dealing with elderly patients suffering from severe comorbidities<sup>6</sup> or with pretreated patients presenting recurrences<sup>13</sup> or second primary tumours<sup>14</sup>.

The masseter muscle has been widely used for reanimation in facial nerve palsy; on the other hand, it has been seldomly reported for oral cavity and oropharyngeal reconstruction. Conley and Gullane in 1978 first introduced the masseter muscle flap as a reconstructive method for the management of oropharyngeal defects<sup>15</sup>. This report remained isolated and was followed 10 years later by papers from Tiwari and Snow<sup>16</sup> and Langdon<sup>17</sup>. These authors highlighted the usefulness and reliability of this flap, the ease and rapidity of its harvest and the minimal technical support required for the procedure. The main reported complication, of both superiorly and inferiorly based masseter flaps, was postoperative reduction of mouth opening<sup>18</sup>.

This paper presents two clinical cases treated at the Department of Surgery and Translational Medicine of the

University of Florence in which the defect resulting from tumour resection was reconstructed by the transposition of the masseter crossover flap; the senior author (AD) performed both procedures. The advantages of this unusual reconstructive method over other more popular solutions are discussed in the light of a personalised and tailored surgical approach.

### Clinical technique and cases

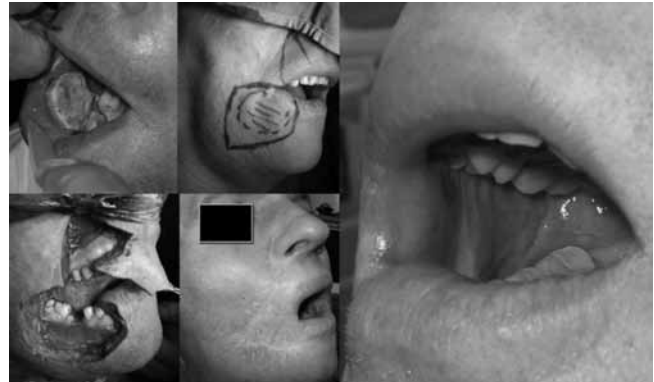The masseteric branches of the maxillary artery (MbMA), facial artery (MbFA), transverse facial artery (MbTFA) and superficial temporal artery (MbSTA) supply the masseter. Based on its diameter, frequency of occurrence and distribution area, the MbTFA can be considered to be the main branch supplying the masseter muscle. This artery is never encountered during standard comprehensive or selective neck dissection, which makes the harvest of the flap perfectly reliable even after previous or concomitant neck dissection as long as the external carotid artery is not transected. Venous drainage of the masseter muscle is provided by the facial vein which flows into the internal jugular vein; in case of previous neck dissection, the pterygoid venous plexus will provide venous drainage as long as the internal jugular vein is preserved.

The flap can be harvested as a crossover flap by maintaining the superior zygomatic attachments, or as an island flap by transecting both insertions. The only careful step is elevation of the parotid gland and terminal branches of the facial nerve from the superficial aspect of the muscle. This step, however, is easily performed with adequate exposure; the fascia of the masseter just above the angle of the mandible is incised and dissected free along with the cheek flap to preserve the branches of the facial nerve, and the muscle is freed along its posterior margin from the parotid gland. The detachment of the mandibular or zygomatic insertions is very quickly obtained with electrocautery and the muscle is ready to be transposed.

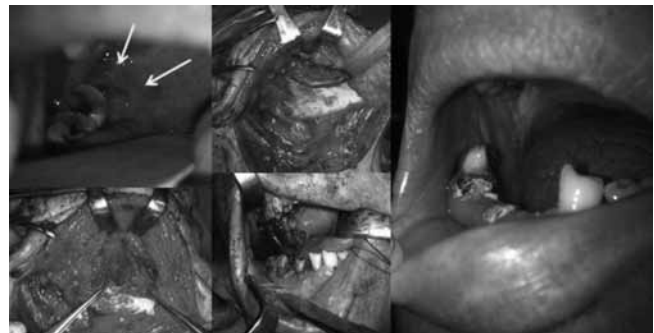
#### Patient 1

At routine follow-up consultation a second primary tumour in the retromolar trigone/posterior alveolar ridge on the right side was detected in a 64-year-old man. Biopsy revealed adenosquamous cell carcinoma, contrast enhanced CT scan was acquired and preoperative staging was cT1N0M0. Five years previously he had undergone full thickness resection of the cheek and labial commissure at the right hand side with bilateral neck dissection (levels I-V ipsilateral, and I-III contralateral) and post-operative radiotherapy for a cT4aN2bM0/pT4aN1 oral squamous cell carcinoma. Reconstruction at that time was achieved with an Abbé-Estlander flap from the upper lip and a facial artery musculomucosal flap (Fig. 1).

The area of the second primary tumour was approached via lateral visor flap, and tumour resection included mar-



**Fig. 1.** Full thickness resection of the right cheek and labial commissure, bilateral neck dissection and reconstruction with Abbé-Estlander + FAMM flap.

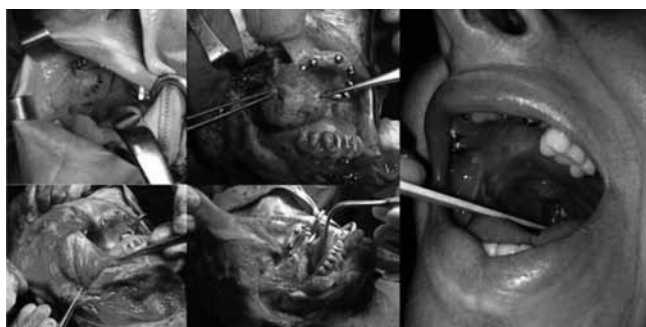

**Fig. 2.** Resection of the second primary tumour (arrows) and reconstruction with the masseter crossover flap, complete re-epithelisation of the muscle and full coverage of the remaining mandible was obtained.

ginal mandibulectomy; reconstruction was performed by transposition of the masseter crossover flap. Healing was uncomplicated and the flap epithelialised within 3 weeks. The pathological report confirmed adenosquamous cell carcinoma pT1, which was radically removed. The patient remains free of disease at 23 months follow-up (Fig. 2).

#### Patient 2

At routine follow-up consultation a second primary squamous cell carcinoma of the right superior retromolar trigone was detected in a 56-year-old woman. Biopsy revealed a squamous cell carcinoma, contrast enhanced CT scan was acquired and preoperative staging was cT4aN0M0. Nine years previously she had undergone resection of a cT2N0M0 squamous cell carcinoma of the right inferior alveolar ridge and floor of mouth via inferior labiotomy and lower cheek flap approach, together with selective neck dissection (levels I-III); the defect was closed primarily. The pathological report confirmed a pT2N0 squamous cell carcinoma with negative surgical margins, R0. The area of the second primary tumour was approached through the previous inferior labiotomy and harvesting a



**Fig. 3.** Inferior-posterior maxillectomy with masseter crossover flap reconstruction, complete re-epithelisation and tight separation between the oral cavity and maxillary sinus was obtained.

lower cheek flap. The resection of the coronoid process of the mandible provided lateral access to the pterygoid plates to ensure an adequate posterior margin, and inferior posterior maxillectomy with wide macroscopic margins was performed. The resection resulted in a class Ib post-maxillectomy defect (Okay classification) with extension to a full thickness resection of the lateral quarter of the soft palate; reconstruction was very easily achieved by transposition of a masseter crossover flap (Fig. 3).

The pathological report confirmed bony involvement of the squamous cell carcinoma, pT4a, with negative surgical margins (mucosal and bony, R0), with an indication for adjuvant radiotherapy. The postoperative course was complicated by the onset of a sialocele, which was managed by weekly transcutaneous needle evacuations for 3 weeks. Despite this minor complication, healing was uneventful, the defect underwent spontaneous epithelisation and the patient completed postoperative radiotherapy.

## Discussion

The masseter flap has been seldomly reported for oral cavity and oropharyngeal reconstructions, and in the literature only the results of 60 cases are available (Table I)<sup>16-18</sup>. In the series reported by Tiwari and Snow<sup>16</sup>, the flap survived in 23 of 24 cases. In two cases, there was a temporary cutaneous fistula in the neck. Three patients had temporary trismus. One patient had persistent trismus. Two patients had unexplained postoperative pain over the temporomandibular area in the first week, but it improved with time until complete recovery.

In the series by Langdon<sup>17</sup>, there were no complications related to the flap and in all cases the bare muscle epithelialised spontaneously with no breakdown of the suture margins. No complications were reported either with previous or adjuvant radiotherapy.

In the series reported by Antoniades et al.<sup>18</sup>, the viability of the flap was excellent in all patients and epithelisation was completed within 3 weeks. The authors stated how the island masseter muscle flap was more flexible and pliable than the crossover version. The island masseter flap is free to pivot around its pedicle with increased mobility and is useful for oropharyngeal defects; in the crossover masseter flap, the superior zygomatic insertions are maintained with obvious limitations in the mobility, and it is therefore used for more adjacent defects, mainly the retromolar trigone. In these series, the masseter flap was a safe one-stage procedure, which does not require elaborate techniques or postoperative care, and results in acceptable aesthetic loss.

In our opinion, the disadvantages of the masseter muscle flap, which restricted its wider use, are represented by the

**Table I.** Overview of previously-reported cases.

Author	No. of flaps	Site*	Stage of tumour	Previous neck RT	Masseter Muscle Flap†	Adjuvant treatment‡	Complications after surgery	Patients requiring further surgery**
Tiwari 1988	24	RTr: 10 LFM: 6 PF: 3 LBMT: 3 AFM: 2 SP: 1	T2: 16 T3: 8	NR	NR	None: 16 RT: 8	None: 14 Fistula: 2 Trismus: 2 PO-pain: 2 BoA: 1 WI: 1	VP: 6
Langdon 1989	14	EA: 1 PFM+RTr: 1 SP+HP: 1 NR: 11	NR	NR	NR	NR	Fistula: 1 Trismus: 1 None: 13	CF: 1 None: 2 NR: 11
Antoniades 2005	22	NR	T2: 2 T3: 13 T4: 7	None: 22	SBMF: 12 IMF: 10	CT+RT: 15 RT: 7	SI: 2 SH: 1 Trismus: NR	NR

NR: Not Reported

\*RTr: Retromolar trigone LFM: lateral floor of mouth PF: palatoglossal fold LBMT: lateral border of the middle third of the tongue AFM: anterior floor of the mouth SP: soft palate EA: edentulous alveolus PFM: posterior floor mouth HP: hard palate

† SBMF: superiorly based masseter muscle flap IMF: island masseter muscle flap

‡ RT: radiotherapy CT+RT: chemo radiation therapy

¶ PO-pain: postoperative pain BoA: Breakdown of anastomoses WI: Wound infection SI: Superficial infection SH: small haematoma

\*\* VP: Vestibuloplasty CF: closure fistula

close vicinity to the primary tumour, which often results in its inclusion with the resected specimen, and by the dimensional limitations and limited mobility that make it inadequate for large or complex defects.

In the cases presented, the masseter cross-over flap was chosen instead of a fasciocutaneous free flap or a temporal myofascial flap for several reasons. Both cases were considered suboptimal for a microvascular procedure; in fact, both had an ipsilateral vessel depleted neck which raised some concerns about recipient vessels. Furthermore, since both second primaries were ipsilateral to the previously dissected neck and distant from the midline, there were no indications for an additional neck dissection. Reconstruction by means of an alternative pedicled flap was sought, and the masseter cross-over flap was favoured over the temporal flap in both cases. By approaching the tumour through a lateral visor flap and a lower cheek flap, the masseter muscle could be harvested immediately and very easily in both cases, without the need for an additional incision. Both surgical procedures were conducted without temporary tracheotomy, and hospitalisation lasted for 9 and 8 days, respectively; no further reduction in mouth opening was recorded for patient #1 and no postoperative trismus was seen in patient #2.

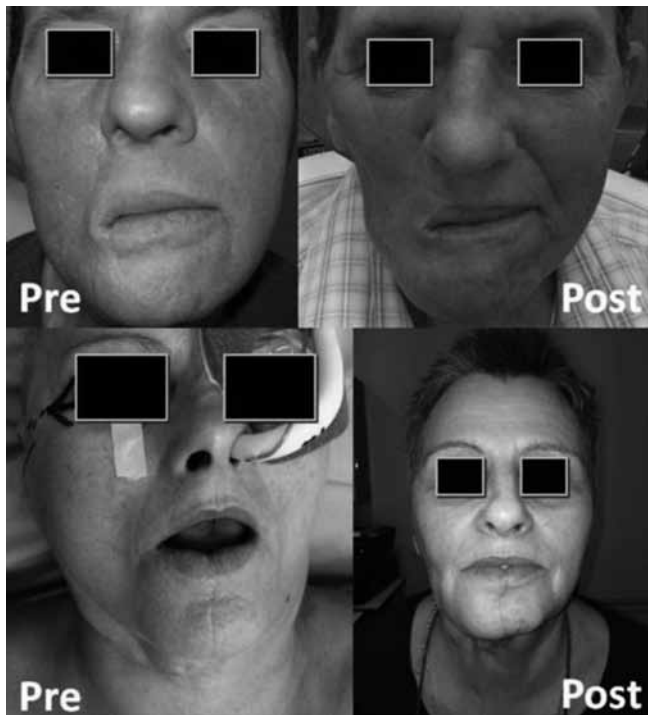
## Conclusions

The masseter flap offers a reliable method for oral cavity and oropharyngeal reconstruction in selected cases; it is a

safe, single stage procedure, which does not require elaborate technique or postoperative care. Especially advantageous are the low postoperative morbidity, low rate of postoperative complications and good functional results with acceptable cosmetic donor site morbidity (Fig. 4).

## References

- 1 Tarsitano A, Ciocca L, Cipriani R, et al. *Mandibular reconstruction using fibula free flap harvested using a customised cutting guide: how we do it*. Acta Otorhinolaryngol Ital 2015;35:198-201.
- 2 Berrone M, Crosetti E, Succo G. *Repositioning template for mandibular reconstruction with fibular free flaps: an alternative technique to pre-plating and virtual surgical planning*. Acta Otorhinolaryngol Ital 2014;34:278-82.
- 3 Pellini R, Pichi B, Marchesi P, et al. *External monitor for buried free flaps in head and neck reconstructions*. Acta Otorhinolaryngol Ital 2006;26:1-6.
- 4 Deganello A, Manciocco V, Dolivet G, et al. *Infrahyoid fascio-myocutaneous flap as an alternative to free radial forearm flap in head and neck reconstruction*. Head Neck 2007;29:285-91.
- 5 Deganello A, Gitti G, Parrinello G, et al. *Cost analysis in oral cavity and oropharyngeal reconstructions with microvascular and pedicled flaps*. Acta Otorhinolaryngol Ital 2013;33:380-7.
- 6 Deganello A, Gitti G, Parrinello G, et al. *Infrahyoid flap reconstruction of oral cavity and oropharyngeal defects in elderly patients with severe general comorbidities*. Head Neck 2012;34:1299-305.
- 7 Deganello A, Leemans CR. *The infrahyoid flap: a comprehensive review of an often overlooked reconstructive method*. Oral Oncol 2014;50:704-10.
- 8 Deganello A, Gitti G, Struijs B, et al. *Palliative combined treatment for unresectable cutaneous basosquamous cell carcinoma of the head and neck*. Acta Otorhinolaryngol Ital 2013;33:353-6.
- 9 Deganello A, Gallo O, De Cesare JM, et al. *Surgical management of surgery and radiation induced peristomal neck ulcerations*. B-ENT 2008;4:169-74.
- 10 Giordano L, Bondi S, Toma S et al. *Versatility of the supraclavicular pedicle flap in head and neck reconstruction*. Acta Otorhinolaryngol Ital 2014;34:394-8.
- 11 Leite AK, de Matos LL, Belli M, et al. *Pectoralis major myocutaneous flap for head and neck reconstruction: risk factors for fistula formation*. Acta Otorhinolaryngol Ital 2014;34:389-93.
- 12 Bussu F, Gallus R, Navach V et al. *Contemporary role of pectoralis major regional flaps in head and neck surgery*. Acta Otorhinolaryngol Ital 2014;34:327-41.
- 13 Deganello A, Franchi A, Sardi I, et al. *Genetic alterations between primary head and neck squamous cell carcinoma and recurrence after radiotherapy: recurrence, genetically related cancer, or second primary?* Cancer 2010;116:1291-7.
- 14 Deganello A, Gitti G, Mannelli G, et al. *Risk factors for multiple malignancies in the head and neck*. Otolaryngol Head Neck Surg 2013;149:105-11.



**Fig. 4.** Pre- and postoperative appearance of both patients; the aesthetic deformity following a masseter flap reconstruction is minimal.



- <sup>15</sup> Conley J, Gullane PJ. *The masseter muscle flap*. Laryngoscope 1978;88:605-12.
- <sup>16</sup> Tiwari RM, Snow GB. *Role of masseter crossover flap in oropharyngeal reconstruction*. J Laryngol Otol 1989;103:298-301.
- <sup>17</sup> Langdon JD. *The masseter muscle cross-over flap: a versatile flap for reconstruction in the oral cavity*. Br J Oral Maxillofac Surg 1989;27:124-31.
- <sup>18</sup> Antoniadis K, Lasaridis N, Vahtsevanos K, et al. *Superiorly based and island masseter muscle flaps for repairing oropharyngeal defects*. J Craniomaxillofac Surg 2005;33:334-9.

Received: November 28, 2015 - Accepted: December 2, 2015

Address for correspondence: Alberto Deganello, Department of Surgery and Translational Medicine, Azienda Ospedaliero-Universitaria Careggi, largo Brambilla 10, 50134 Firenze, Italy. Tel/Fax +39 055 7947054. E-mail: adeganello@hotmail.com

CASE SERIES AND REPORTS

# Endonasal endoscopic resection of ossifying fibroma involving the ethmoid sinus, orbit and anterior skull base: case report and literature review

## *Resezione endoscopica di un fibroma ossificante interessante il seno etmoidale, l'orbita e il basicranio anteriore: case report e revisione della letteratura*

M. JURLINA<sup>1</sup>, N. SKITARELIĆ<sup>2</sup>, D. PASSALI<sup>3</sup>, F.M. PASSALI<sup>4</sup>, R. MLADINA<sup>1</sup>

<sup>1</sup> Department of Otolaryngology Head and Neck Surgery, University Hospital Rebro, Zagreb, Croatia;

<sup>2</sup> Department of Otolaryngology Head and Neck Surgery, General Hospital Zadar, Zadar, Croatia;

<sup>3</sup> Department of ORL, University of Siena, Italy; <sup>4</sup> Department of ORL University of Rome Tor Vergata, Italy

### SUMMARY

Ossifying fibroma is a benign fibro-osseous tumour that rarely involves the ethmoid sinuses and orbit. It is classified as a benign fibro-osseous lesion, a term that is synonymous with a variety of lesions reported in the literature. Recurrence rate with deleterious effects in cases of extramandibular ossifying fibroma is the impetus for open en bloc resection of the tumour. Continuously evolving techniques in endonasal endoscopic sinus surgery has rendered resection of large benign sinonasal and cephalonasal tumours possible. The authors report a case of ossifying fibroma involving the ethmoid sinus, orbit and anterior skull base in a 65-year-old previously healthy woman completely resected by endonasal endoscopic sinus surgery. The patient was free from postoperative complications and was dismissed from hospital on the sixth postoperative day. At present, the patient is disease-free at a regular five-year postoperative follow-up. Endonasal endoscopic resection of sinonasal ossifying fibromas is an excellent therapeutic option when performed by a surgeon experienced in endoscopic sinonasal surgery. The advantages of an endonasal endoscopic approach include direct visualization, enhanced visibility and magnification resulting in decreased intraoperative and postoperative morbidity. Aesthetic outcome is excellent in the absence of facial scars.

**KEY WORDS:** Ossifying fibroma ethmoid • Endonasal endoscopic sinus surgery

### RIASSUNTO

*Il fibroma ossificante è un tumore fibro-osseo benigno che solo raramente interessa il seno etmoidale e l'orbita. Viene classificato come una lesione fibro-ossea benigna, una dicitura che raggruppa una discreta varietà di lesioni riportate in letteratura. Una tendenza alla recidiva con importanti sequele ha rappresentato la spinta verso una resezione open en bloc nelle forme extramandibolari di questo tipo di lesione. La continua evoluzione delle tecniche di endoscopia endonasale ha reso possibile la resezione delle grandi lesioni benigne nasali e cefalo-nasali. Gli autori descrivono l'asportazione completa di un voluminoso fibroma ossificante interessante seno etmoidale, orbita e basicranio anteriore in una paziente di 65 anni in buone condizioni generali. La paziente non ha avuto complicanze postoperatorie ed è stata dimessa in sesta giornata. La paziente è al momento al quinto anno di follow-up e si presenta libera da malattia. L'asportazione endoscopica del fibroma ossificante endonasale è un'ottima scelta terapeutica nelle mani del chirurgo esperto. I vantaggi della tecnica includono la visualizzazione diretta della neoformazione e la sua maggiore magnificazione, che portano a una riduzione delle complicanze intra e postoperatorie. L'outcome estetico è ovviamente eccellente per l'assenza di cicatrici.*

**PAROLE CHIAVE:** Fibroma ossificante • Etmoide • Chirurgia endoscopica nasale

Acta Otorhinolaryngol Ital 2016;36:144-148

### Introduction

Ossifying fibroma (OF) is a rare, benign fibro-osseous tumour typically found in the mandible, and therefore has been reported mainly by oral surgeons<sup>1,2</sup>. About 10% of all cases are found in the maxilla<sup>3</sup>. OF rarely involve the ethmoid sinuses and orbit<sup>1,4,5</sup>. The authors present an unusual case of OF involving the left ethmoid sinus, or-

bit and anterior skull base occurring in an elderly woman who was completely resected by endonasal endoscopic sinus surgery.

### Case report

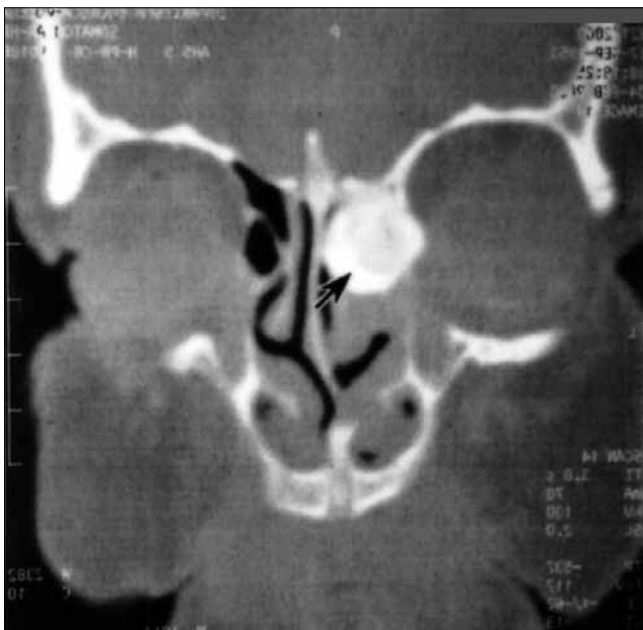A 65-year-old previously healthy woman who presented with the sensation of pressure in the left orbit. She did not

refer any disturbances of smell or vision. The patient was not taking any medications and had no known drug allergies. Ophthalmologic examination showed no pathologic findings. There was no conjunctival oedema or haemorrhage. The showed any pathologic changes.

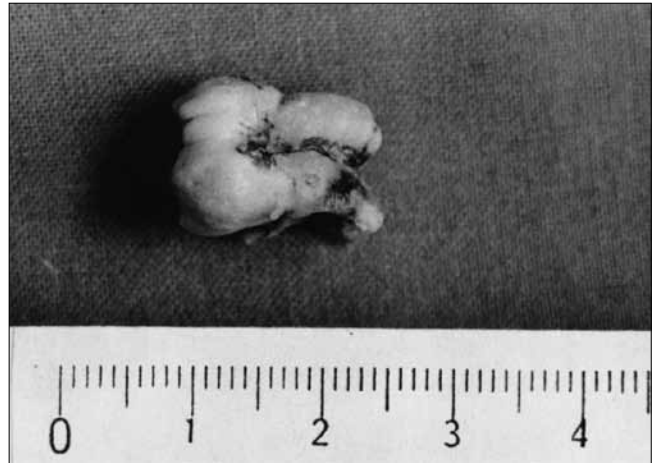Endoscopic evaluation of the left nasal cavity showed oedema within the left middle meatus. Multi-slice computed tomography (MSCT) of the paranasal sinuses demonstrated an ovoid mass expanding within the left ethmoid complex. On coronal MSCT, the tumour was seen to occupy the left nasal cavity and eroding the lamina papyracea. It was attached to the anterior skull base by a narrow, stalk like base (Fig. 1).

Based on the physical examination findings and imaging studies, the patient was admitted to the hospital and prepared for surgery. The patient was operated under general, hypotensive anaesthesia. During the procedure, the tumour was found to be attached to the anterior skull base and eroding the left lamina papyracea. A 30° endoscope was used to proceed to delicate preparation of the anterior skull base. The tumour was completely resected endoscopically using straight powered drill bits with clear intraoperative presentation of cribriform plate. The intraoperative tumour is presented in Figure 2. The left periorbita and skull base were not surgically violated and orbital fat did not protrude into the surgical field at the end of procedure.

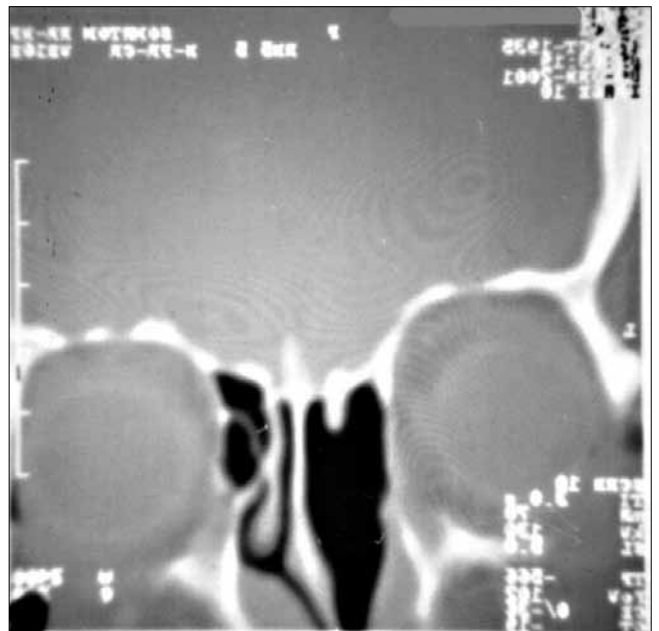
There were no postoperative complications. Routine postoperative endoscopic examination of the left sinonasal cavity was performed and no evidence of cerebrospinal fluid leaks from the anterior cranial fossa was present.



**Fig. 1.** Preoperative coronal MSCT scan showing the tumour occupying the left nasal cavity and eroding the lamina papyracea. It was attached to the anterior skull base by a narrow, stalk-like base (black arrow).



**Fig. 2.** Intraoperative tumour specimen.



**Fig. 3.** Postoperative coronal MSCT scan at one year postoperative follow-up.

The histopathological finding was consistent with an OF. The tumour mainly consisted of two components: a fibrous stroma, rich in fibroblasts and small vessels surrounded with bony lamellae that were rimmed by osteoblasts and occasionally by osteoclasts.

A postoperative coronal MSCT scan after one year postoperative follow-up is shown in Figure 3. The patient is presently completely free of disease at a regular five-year follow-up.

## Discussion

OF holds a tenuous place in the classification of bony lesions. It was first mentioned by Menzel in 1872, who considered it to be a form of osteoma<sup>6</sup>. OF is classified

as a benign fibro-osseous lesion, a term that is synonymous with a variety of lesions reported in available literature (Table I).

The origin of OF is debated with a predominant theory claiming the tumour originates from periodontal roots because of their capacity to produce cementum and osteoid tissue<sup>6</sup>. The tumour has the capability of producing cement, lamellar bone and fibrous tissue in widely differing proportions. The periodontal membrane is a mesodermal germ layer product. The normal migration of the medial part of nasal anlage occurs through the ethmoid sinus region, and a small portion of this mesenchyme differentiates into the periodontal membrane<sup>6</sup>. The ethmoidal localisation of OF could therefore be explained by incomplete migration and maturation of the periodontal membrane. Marvel et al. stated that OF originates from primitive mesenchymal cells that are believed to produce cementum at sites distant from odontogenic tissue<sup>7</sup>.

Both benign and malignant fibro-osseous lesions should be considered in the differential diagnosis of OF. These include well-differentiated osteosarcoma, and the spectrum of fibro-osseous lesions of the head and neck<sup>8</sup>.

Regardless of the theory of origin, fibro-osseous lesions and OF differ from fibrous dysplasia not only histologically, but also in their distinct clinical behaviour. Some authors have suggested that sharply defined calcifying spherulation is an important differential finding not seen in fibrous dysplasia, but most pathologists agree that it is very difficult to differentiate between these two entities using histological criteria alone. No hereditary tendencies have been observed, and no pigmentary or endocrine changes have been reported associated with ossifying fibromas. Moreover, abnormal serum calcium, phosphorous or alkaline phosphatase levels have not been reported.

OF is usually well circumscribed rather than diffuse and most often involves a single bone. The tumour produces moderate expansion of the tables of the involved bone, but usually leaves a thin "egg shell" boundary on either side with no periosteal reaction. It has definite bounda-

ries but is not truly encapsulated<sup>9</sup>. All previously mentioned features were present in our case.

OF typically presents in the mandible (75%) and thus is usually reported and treated by oral surgeons. Other reported locations of OF are maxilla, frontal bone, sphenoid bone, ethmoid bone, temporal bone, orbit, anterior cranial fossa and auricula<sup>1 5 6 8-12</sup>. The otolaryngologist's concern lies with the extramandibular presentation because OF is believed to behave more aggressively than its mandibular counterpart and requires complete surgical resection<sup>13</sup>.

Presenting symptoms of OF depend on the location of the tumour and range from nasal obstruction to disfiguration. Individual patients may present with ophthalmologic symptoms, such as proptosis and diplopia. Intracranial extension of OF fibroma itself or associated mucoceles may give rise to neurological symptoms<sup>14</sup>. Patients with OF range from newborns<sup>14</sup> to those in their eighth decade of life, with more aggressive behaviour at an earlier age<sup>15-17</sup>. The highest incidence of OF is reported between the ages of 20 to 40 years with a female predilection<sup>7 18 19</sup>.

Although malignant transformation in OF has not been reported<sup>1</sup>, surgery is the treatment of choice<sup>20</sup>. Radiotherapy is contraindicated for OF because it may increase the possibility of malignant transformation. Reported rates of malignant transformation range from 4% to 40%<sup>4</sup>. Mandibular OF is traditionally treated with curettage because of the favourable results in this particular anatomical location. Recurrence rate with deleterious effects when OF is located in extramandibular regions is the impetus for open en bloc resection of the tumour<sup>3 7 21 22</sup>. Complete resection of extramandibular OF is curative, and the exact surgical approach depends on the location and extent of the tumour. For the accomplishment of that task a variety of open approaches have been reported including: Caldwell-Luc operation, curettage, with peripheral ostectomy when the tumour is located in the floor of the maxillary sinus; lateral rhinotomy with medial maxillectomy when the tumour is located in the medial wall of the maxillary sinus; external ethmoidectomy for recurrent ethmoid tumour, transcranial/subcranial approach, and subfrontal approach<sup>1 3 4 7 23 24</sup>.

Continuously evolving techniques in endonasal endoscopic sinus surgery have made resection of large benign sinonasal and cephalonasal tumours possible<sup>25 26</sup>. A total of 15 cases of sinonasal OF endoscopically treated have been published in the available literature<sup>12 27-30</sup>. The advantages of endonasal endoscopic approach include direct visualisation, enhanced visibility and magnification resulting in decreased intraoperative trauma and postoperative morbidity. The advent of 3D navigation devices further enhances previously mentioned advantages. Aesthetic outcome is excellent in the absence of facial scars. Postoperative surveillance is accurate and flaw-

**Table I.** Various terms reported in the literature for different histological variations of ossifying fibromas.

Ossifying fibroma
Cementifying fibroma
Cemento-ossifying fibroma
Desmo-osteoblastoma
Psammo-osteoid fibroma
Psammonmatoid ossifying fibroma
Juvenile ossifying fibroma
Juvenile aggressive ossifying fibroma
Juvenile active ossifying fibroma



less. All these features make an endoscopic approach a preferable option wherever possible. Complications of the endoscopic technique include injury to the skull base with resultant cerebrospinal fluid leak, infection, bleeding and injury to orbital structures<sup>27 31</sup>.

## Conclusions

In this report, we present a case of a 18 mm OF that was completely resected endoscopically without complications or recurrence after five-year follow-up. The tumour's well-demarcated borders allowed for complete resection and ensured assurance of tumour-free margins. The unusual feature of OF in our case was its adherence to the anterior skull base in the form of a narrow stalk and without dural involvement. It significantly complicated the operating procedure because of imminent endocranial complications. The tumour was successfully and completely drilled off from the skull base and further extracted through the choanae and mouth. Endonasal endoscopic resection of sinonasal ossifying fibromas is an excellent therapeutic option when performed by a surgeon experienced in endonasal endoscopic sinus surgery. The endoscopic examination also provides excellent postoperative surveillance for early detection of recurrence. It should be anticipated as a treatment of choice in case of sinonasal OF with hesitation only in cases of extensive orbital or intracranial extension.

## References

- Nakagawa K, Takasato Y, Ito Y, et al. *Ossifying fibroma involving the paranasal sinuses, orbit, and anterior cranial fossa: case report*. Neurosurgery 1995;36:1192-5.
- Godt A, Gulicher D, Kalwitzki M, et al. *Dislocation of an upper third molar by an ossifying fibroma – case report*. J Craniomaxillofac Surg 2008;36:360-4.
- Cox VS, Rimell FL, Marenttete LJ, et al. *Ethmoidal cemento-ossifying fibroma: The transglabellar/subcranial approach*. Otolaryngol Head Neck Surg 1996;114:335-8.
- Vaidya AM, Chow JM, Goldberg K, et al. *Juvenile aggressive ossifying fibroma presenting as an ethmoid sinus mucocele*. Otolaryngol Head Neck Surg 1998;119:665-8.
- Oukabli M, Akhaddar A, Qamouss O, et al. *Nasoethmoidal psammomatoid cemento-ossifying fibroma with intraorbital extension*. Rev Stomatol Chir Maxillofac 2010;111:43-5.
- Brademann G, Werner JA, Janig U, et al. *Cemento-ossifying fibroma of the petromastoid region: case report and review of the literature*. J Laryngol Otol 1997;111:152-5.
- Marvel JB, Marsh MA, Catlin FI. *Ossifying fibroma of the mid-face and paranasal sinuses: diagnostic and therapeutic considerations*. Otolaryngol Head Neck Surg 1991;104:803-8.
- Kaufmann RA, Padmore RF, Ridge JA, et al. *Primary extraosseous cemento-ossifying fibroma of the auricle*. Head Neck 1999;21:578-81.
- Thomas GK, Kasper KA. *Ossifying fibroma of the frontal bone*. Arch Otolaryng 1966;83:69-72.
- Sterling KM, Stollman A, Sacher M, et al. *Ossifying fibroma of sphenoid bone with coexistent mucocele: CT and MRI*. J Comput Assist Tomogr 1993;17:492-4.
- Shetty SD, Salib RJ, Nair SB, et al. *Ossifying fibromyxoid tumour of the sphenoid sinus*. J Laryngol Otol 2010;124:437-40.
- Singhal A, Ram R, Singhal P, et al. *Cemento-ossifying fibroma of maxillary antrum in a young female patient*. Indian Soc Pedod Prev Dent 2011;29:44-7.
- London SD, Schlosser RJ, Gross CW. *Endoscopic management of benign sinonasal tumors: a decade of experience*. Am J Rhinol 2002;16:221-7.
- Al-Mazrou KA, Mansoor A, Payne M, et al. *Ossifying fibromyxoid tumor of the ethmoid sinus in a newborn: report of a case and literature review*. Int J Pediatr Otorhinolaryngol 2004;68:225-30.
- Johnson LC, Yousefi M, Vinh TN, et al. *Juvenile active ossifying fibroma: its nature, dynamics and origin*. Acta Otolaryngol Suppl 1991;488:1-40.
- De Riu G, Meloni SM, Raho MT, et al. *Complications of mandibular reconstruction in childhood: report of a case of Juvenile Aggressive Fibromatosis*. J Craniomaxillofac Surg 2006;34:168-72.
- Bohn OL, Kalmar JR, Allen CM, et al. *Trabecular and psammomatoid juvenile ossifying fibroma of the skull base mimicking psammomatoid meningioma*. Head and Neck Pathol 2011;5:71-5.
- MacDonald-Jankowski DS, Li TK. *Ossifying fibroma in a Hong Kong community: the clinical and radiological features and outcomes of treatment*. Dentomaxillofac Radiol 2009;38:514-23.
- Efune G, Perez CL, Tong L, et al. *Paranasal sinus and skull base fibro-osseous lesions: when is biopsy indicated for diagnosis?* Int Forum Allergy Rhinol 2012;2:160-5.
- Wenig BM, VinthTN, Smirniotopoulos JG, et al. *Aggressive Psammomatoid Ossifying Fibromas of the Sinonasal Region*. Cancer 1995;76:1155-65.
- MacDonald-Jankowski DS. *Ossifying fibroma: a systematic review*. Dentomaxillofac Radiol 2009;38:495-13.
- Verma P, Rarthore PK, Mrig S, et al. *Cemento-ossifying fibroma of the maxilla: a case report*. Indian J Otolaryngol Head Neck Surg 2011;63:38-40.
- Chong VFH, Tan LHC. *Maxillary sinus ossifying fibroma*. Am J Otolaryngol 1997;18:419-24.
- Shekhar MG, Bokhari K. *Juvenile aggressive ossifying fibroma of the maxilla*. J Indian Soc Pedod Prev Dent 2009;27:170-4.
- Fei Z, Zhang X, Jiang XF, et al. *Removal of large benign cephalonasal tumours by transbasal surgery combined with endonasal endoscopic sinus surgery and neuronavigation*. J Craniomaxillofac Surg 2007;35:30-4.
- Ooi EH, Glicksman JT, Vescan AD, et al. *An alternative management approach to paranasal sinus fibro-osseous lesions*. Int Forum Allergy Rhinol 2011;1:55-63.
- Brodish BN, Morgan CE, Sillers MJ. *Endoscopic resection of fibroosseous lesions of the paranasal sinuses*. Am J Rhinol 1999;13:111-6.
- Choi YC, Jeon EJ, Park YS. *Ossifying fibroma arising*

- in the right ethmoid sinus and nasal cavity.* Int J Pediatr Otorhinolaryngol 2000;54:159-62.
- <sup>29</sup> Garrett P, Stilianos MS, Kountakis E. *Endoscopic resection of large sinonasal ossifying fibroma.* Am J Otolaryngology 2005;26:54-6.
- <sup>30</sup> Selmani Z, Anttila J, Mertakorpi J, et al. *Cemento-ossifying fibroma of the ethmoidal sinus in a child presenting with isolated pain in the nasal region.* J Craniofac Surg 2004;15:215-7.
- <sup>31</sup> May M, Levine HL, Mester SJ, et al. *Complications of endoscopic sinus surgery. analysis of 2018 patients – Incidence and prevention.* Laryngoscope 1994;104:1080-3.

Received: February 1, 2015 - Accepted: June 1, 2015

CASE SERIES AND REPORTS

# Traumatic intra-sphenoidal pseudoaneurysm lodged inside the fractured sphenoidal sinus

## *Pseudoaneurisma di origine traumatica localizzato in un seno sfenoidale fratturato*

P. PELLICCIA<sup>1,2</sup>, M. BARTOLOMEO<sup>1</sup>, G. IANNETTI<sup>2</sup>, A. BONAFÉ<sup>3</sup>, M. MAKEIEFF<sup>1</sup>

<sup>1</sup> Department of Head and Neck Surgery, CHU, Montpellier, France; <sup>2</sup> Department of Maxillo-Facial Surgery, University of Rome La Sapienza, Rome, Italy; <sup>3</sup> Department of Neuroradiology, CHU, Montpellier, France

### SUMMARY

We describe a case of traumatic intra-sphenoidal right internal carotid artery pseudoaneurysm lodged inside the fractured sphenoidal sinus that developed in a patient with a previous history of frontal and skull base fractures involving the sphenoid sinus and walls of the carotid canal, but with normal intracranial findings at early CT angiography. The patient presented two episodes of massive life-threatening delayed epistaxis before successful endovascular treatment combining the use of coils and an uncovered stent was instituted. This case report highlights that patients with head trauma who present sphenoid sinus fractures with or without massive epistaxis should be evaluated for the development of traumatic internal carotid artery pseudoaneurysm as soon as possible. If the first angiographic evaluation reveals normal findings, repeated epistaxis should prompt a second angiographic evaluation because pseudoaneurysm takes time to develop. Early treatment with uncovered stent of the aneurysm can be a life-saving therapeutic approach.

**KEY WORDS:** Epistaxis • Delayed epistaxis • Pseudoaneurysm • Head injuries • Sphenoidal sinus fracture • Endovascular procedures

### RIASSUNTO

*Descriviamo il caso di un pseudoaneurisma di origine traumatica dell'arteria carotide interna destra localizzato all'interno di un seno sfenoidale fratturato che si è sviluppato in un paziente che aveva riportato delle fratture dell'osso frontale e della base cranica che coinvolgevano le pareti del seno sfenoidale e il canale della carotide malgrado l'angio-TC precoce fosse negativa. Il paziente ha presentato due episodi di epistassi ritardata massiva potenzialmente letale prima di essere trattato con successo con tecniche endovascolari utilizzando spirali metalliche e uno stent non ricoperto. Questo caso sottolinea il fatto che i pazienti con trauma cranico che presentano fratture nel seno sfenoidale con o senza epistassi massiva dovrebbero essere studiati il più presto possibile alla ricerca dello sviluppo di un pseudoaneurisma postraumatico della carotide interna. Se la prima angio-TC è negativa, un'epistassi ricorrente dovrebbe condurre alla realizzazione di una seconda angio-TC poiché lo pseudoaneurisma richiede tempo per svilupparsi. Un trattamento endovascolare precoce con uno stent non ricoperto può impedire il decesso del paziente.*

**PAROLE CHIAVE:** Epistassi • Epistassi ritardata • Pseudoaneurisma • Trauma cranico • Frattura del seno sfenoidale • Procedure endovascolari

Acta Otorhinolaryngol Ital 2016;36:149-152

## Introduction

A false aneurysm (pseudoaneurysm) corresponds histologically to an external lumen that develops into a surrounding haematoma following disruption of all layers of the vessel wall<sup>1-5</sup>.

Post-traumatic pseudoaneurysms of the intracranial portion of the internal carotid artery (ICA) are uncommon<sup>2</sup>. They represent a rare complication of head injury, especially in adults<sup>3,4,7</sup>. Mortality is high (up to 50%)<sup>2,4,6,8</sup>. These lesions may appear in the petrous, cavernous, or supraclinoid portions of the internal carotid artery. Most frequently, they are located in the cavernous portion<sup>1-5</sup>.

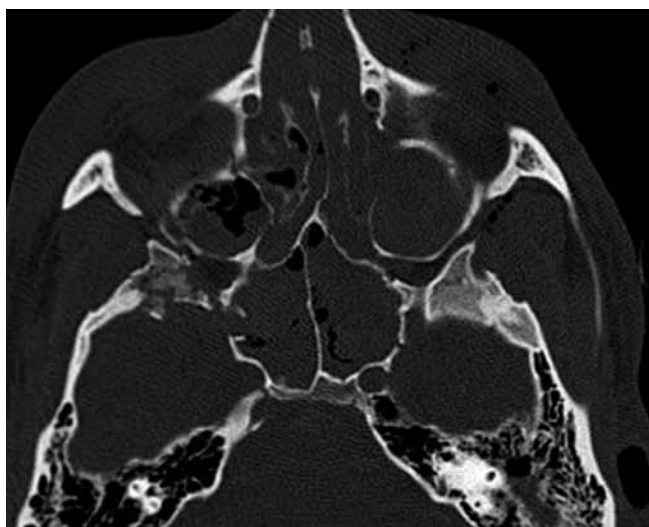
The patients may present with massive epistaxis due to the rupture of the pseudoaneurysm into the sphenoid si-

nus. Epistaxis appears at variable times after trauma, usually less than 6 months afterwards; however, in a previous review of 100 cases from the literature, in 7 cases epistaxis appeared later than 6 months after trauma<sup>5</sup>. In some cases, recurrent episodes of epistaxis can occur before diagnosis is reached<sup>5</sup>. The likelihood of exsanguination increases with each subsequent episode of epistaxis<sup>5</sup>.

## Case

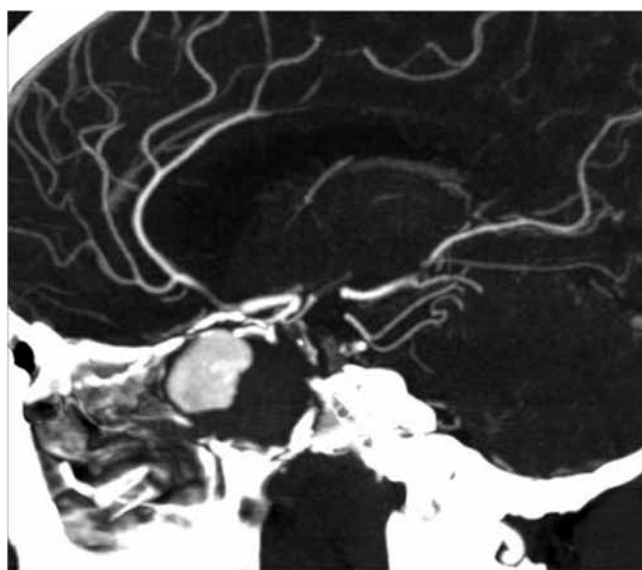
A 22-year-old man suffered from non-penetrating head and neck injury with loss of consciousness due to a car accident. He was admitted to the Emergency Department of the nearest primary care hospital in France. At admission, the patient had regained consciousness and complained of

headache and neck pain. Neurological examination was normal. CT scan of the head and the neck showed frontal and skull base fractures involving the right sphenoid sinus and walls of the right carotid canal (Fig. 1). Early vascular study performed by CT angiography showed normal findings on the vessels of the right side, whereas the left ICA was dissected and occluded in the neck. However, the patient did not develop cerebral ischaemic symptoms. The patient was referred to the Teaching Hospital of Montpellier, where conservative management of ICA dissection was preferred.

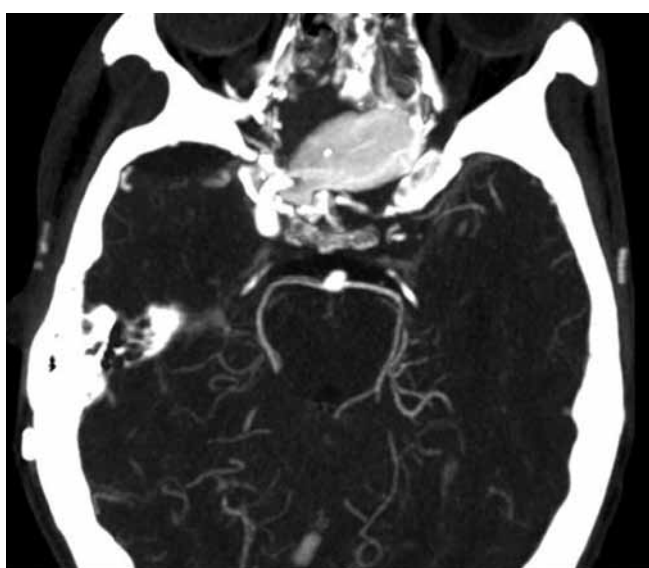


**Fig. 1.** CT scan of the head performed the day of the car accident (axial view) showing frontal and skull base fractures involving the right sphenoid sinus and walls of the right carotid canal.

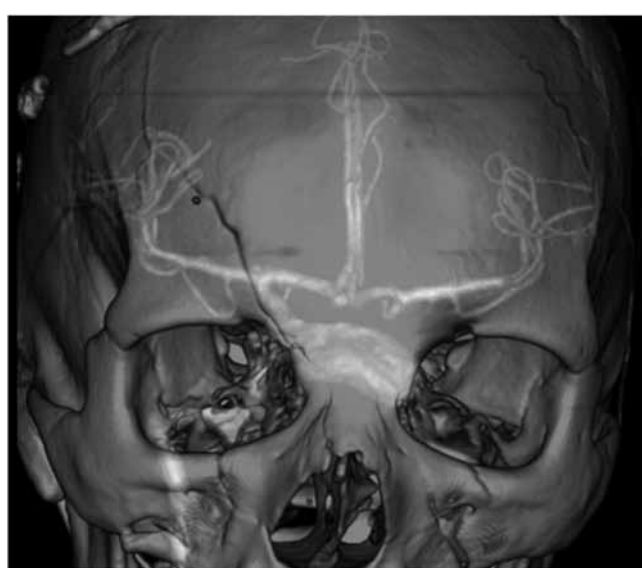During the hospital stay, he presented two episodes of massive life-threatening delayed epistaxis. The first occurred 20 days after trauma and was self-limiting. Apparently the hemorrhage was from both nostrils. Anterior rhinoscopy performed between the two episodes failed to identify an anterior source. Nasal endoscopy with a rigid endoscope found a septal deviation on the left side; clots were suctioned and no active bleeding was found. Laboratory tests (complete blood count with differential, bleeding time, prothrombin time, activated partial thromboplastin time) identified no underlying medical problems.



**Fig. 3.** Second CT angiography performed after the first episode of massive self-limiting delayed epistaxis. Sagittal view showed the saccular traumatic pseudoaneurysm of the right ICA lodged inside the fractured sphenoidal sinus.

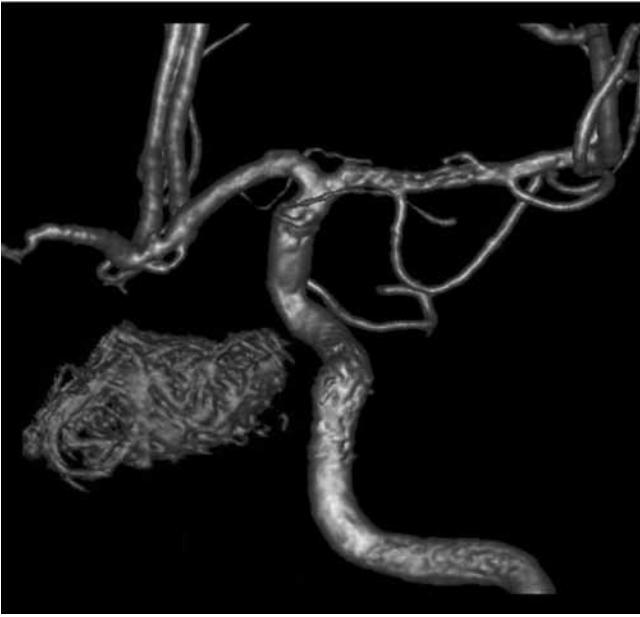


**Fig. 2.** Second CT angiography performed after the first episode of massive self-limiting delayed epistaxis, 20 days after the trauma. Axial view revealed a saccular traumatic pseudoaneurysm of the right ICA. The dissected left ICA was occluded, but the patient did not develop cerebral ischaemic symptoms.



**Fig. 4.** Processed image of second CT angiogram with volume rendering reconstruction (anterior view) showing the right ICA pseudoaneurysm. The left ICA was dissected and occluded.





**Fig. 5.** Final angiogram performed after endovascular treatment of the pseudoaneurysm showing subtotal exclusion with residual opacification of the proximal sac near the ICA orifice.

Another CT angiography was performed just before the second episode (Figs. 2 and 3: axial and sagittal views, respectively). Angiographic evaluation revealed a saccular traumatic pseudoaneurysm of the right internal carotid artery (ICA) lodged inside the fractured sphenoidal sinus. Figure 4 shows a processed image of a CT angiogram with volume rendering reconstruction (anterior view).

Few minutes after the exam the patient presented a massive haemorrhage that required bilateral nasal packing with inflatable balloon devices. The patient was then treated using a stent-assisted endovascular technique under general anaesthesia. The right ICA pseudoaneurysm sac was outlined in multiple projections using a diagnostic biplane and interventional angiography imaging system (Neurostar T.O.P.; Siemens, Erlangen, Germany). It measured 30x20x18 mm, was pear-shaped and had an anterior, inferior and medial orientation. The neck was situated a few mm below the ophthalmic artery. Most of the sac opacification was observed in late arterial and early venous phases, with marked contrast stagnation. An Echeleon™ 0.014-inch microcatheter (ev3 Inc., Plymouth, MN, USA) was used to selectively catheterize the pseudoaneurysm. Next, two concentric nitinol auto-expandable stents (Enterprise™ 4.5x28 mm and 4.5x22 mm, Cordis Corp., Warren, NJ, USA) were deployed in the targeted arterial segment. The pseudoaneurysm was treated with 15 detachable coils in a single session: three MicroPlex-10 Compass Complex and 12 helical 0.014-inch HydroCoils™ (MicroVention Inc., Tustin, CA, USA). The final angiogram showed a subtotal exclusion with residual opacification of the proximal sac near the ICA orifice (Fig. 5).

There was no procedure-related complication and the epistaxis definitively stopped.

## Discussion

Fracture of the lateral wall of the sphenoid may lead to the formation of a pseudoaneurysm in the sphenoid sinus. Rarely, traumatic ICA pseudoaneurysms present similar to an asymptomatic sphenoid sinus mass lesion. Massive bleeding can occur if a biopsy of the mass by nasal endoscopy is attempted<sup>9</sup>.

Traumatic pseudoaneurysms are fragile and prone to rupture. Death is three times less likely if the pseudoaneurysm is diagnosed before it has ruptured, compared with diagnosis after rupture<sup>10</sup>. Consequently, early diagnosis with cerebral angiography and prompt treatment are essential.

Unilateral blindness (absent in this case) is often present and its association with massive delayed epistaxis after severe craniofacial trauma should indicate diagnosis. Of this classic clinical triad, epistaxis was a constant finding in a previous review of 100 cases from the literature, whereas unilateral blindness appeared in 73 patients; a history of fracture occurred in 77 of 88 patients<sup>5</sup>.

The loss of unilateral vision that occurs immediately after trauma is often the result of either a direct lesion to the optic nerve, injury to the ophthalmic artery or compression by a lesion such as a pseudoaneurysm. In some cases, the loss of vision may appear late. Traumatic pseudoaneurysms of the cavernous portion of the carotid artery may also produce symptoms related to compression of the cranial nerves in the cavernous sinus or symptoms secondary to a carotid cavernous fistula (proptosis, loss of visual acuity, or homonymous hemianopsia)<sup>10</sup>.

Traumatic carotid cavernous fistula concomitant with pseudoaneurysm in the sphenoid sinus is extremely rare but has been documented; the cases reported in the literature mostly resulted from penetrating head trauma and motor vehicle accidents<sup>10</sup>. In this setting, the intracavernous high pressure of carotid cavernous fistula is presumed to further destroy the fractured sphenoid sinus wall<sup>10</sup>.

Since angiography is no longer a routine examination for head injury, traumatic ICA pseudoaneurysms tend to be underdiagnosed<sup>1 4 6</sup>. A high level of suspicion is necessary to detect such lesions early on. CT or conventional angiography may be used, but the latter remains the gold standard for exploration. The typical image is an irregular-shaped dilatation of the injured branch without a well-defined neck and located elsewhere than at a branch point<sup>2 4</sup>. It is best seen on late arterial or early venous phases of the angiogram and empties slowly<sup>3 4</sup>.

If a diagnostic angiogram is performed early, it may or may not reveal the presence of a pseudoaneurysm, because it takes time to develop. Chambers et al. have indicated that a second angiogram, which must be performed

in 2 to 3 weeks, may then show the traumatic aneurysm<sup>5</sup>. However, it is not safe to postpone angiography in patients with a high risk of traumatic intracranial pseudoaneurysm, such as the one reported in the present report. The high mortality associated with this entity underlines the importance of early angiography to confirm diagnosis. A follow-up angiogram should be obtained if the initial study was negative<sup>2</sup>.

Many methods have been reported to treat intracavernous pseudoaneurysm, including endovascular stent and coils, endovascular covered stent, detachable balloons, direct surgical repair the internal carotid, trapping procedures, etc.<sup>2-6</sup>. In our institution, we prefer to treat these lesions by combining the use of coils and an uncovered stent.

In conclusion, pseudoaneurysm of internal carotid artery is an uncommon, but potentially fatal cause of epistaxis. Optimal management demands rapid recognition and treatment to give the best functional outcome. High suspicion and carotid arteriography are essential for diagnosis. In differential diagnosis of patients with intractable epistaxis and isolated sphenoid sinus lesions, ICA pseudoaneurysm should be considered, even in patients with normal findings at urgent vascular study. Early treatment with an uncovered stent of the aneurysm can be a life-saving therapeutic approach.

Patients with head trauma who present with sphenoid sinus fractures with or without massive epistaxis should be evaluated for the development of traumatic ICA pseudoaneurysms as soon as possible. If the first angiographic evaluation reveals normal findings, recurrent epistaxis should prompt a second angiographic evaluation.

Current treatment of traumatic ICA pseudoaneurysm involves the occlusion of the main artery or exclusion of the pseudoaneurysm through the use of endovascular tech-

niques. Patients who do not tolerate test occlusion require extracranial-to-intracranial bypass surgery.

## References

- <sup>1</sup> Britz GW, Newell DW, West GA. *Traumatic cerebral aneurysms secondary to penetrating intracranial injuries*. In: Richard Winn H, ed. *Youmans Neurological Surgery*. 5<sup>th</sup> ed. Philadelphia: Saunders Elsevier; 2004. p. 2131-5.
- <sup>2</sup> Dubey A, Sung WS, Chen YY, et al. *Traumatic intracranial aneurysm: a brief review*. J Clin Neurosci 2008;15:609-12.
- <sup>3</sup> Guillaume DJ, Haddad FS, Haddad GF, et al. *Diagnosis and management of traumatic intracranial aneurysms*. In: Schmidek HH, Sweet WH, eds. *Operative Neurosurgery: Indications, Methods and Results*. 5<sup>th</sup> ed. Philadelphia: Saunders Elsevier; 2005. p. 1224-32.
- <sup>4</sup> Holmes B, Harbaugh RE. *Traumatic intracranial aneurysms: a contemporary review*. J Trauma 1993;35:855-60.
- <sup>5</sup> Chambers EF, Rosenbaum AE, Norman D, et al. *Traumatic aneurysms of cavernous internal carotid artery with secondary epistaxis*. AJNR Am J Neuroradiol 1981;2:405-9.
- <sup>6</sup> Cohen JE, Gomori JM, Segal R, et al. *Results of endovascular treatment of traumatic intracranial aneurysms*. Neurosurgery 2008;63:476-86.
- <sup>7</sup> En-Nouali H, Akhaddar A, Mahi M, et al. *Les faux anévrysmes artériels traumatiques intracrâniens. A propos d'un cas*. Journal de Neuroradiologie 2002;29:281-4.
- <sup>8</sup> Larson PS, Reisner A, Morassutti DJ, et al. *Traumatic intracranial aneurysms*. Neurosurg Focus 2000;8:e4.
- <sup>9</sup> Tseng YY, Yang ST, Yeh YS, ET AL. *Traumatic internal carotid artery pseudoaneurysm mimicking sphenoid sinus tumor*. Rhinology 2007;45:332-4.
- <sup>10</sup> Huai RC, Yi CL, Ru LB, ET AL. *Traumatic carotid cavernous fistula concomitant with pseudoaneurysm in the sphenoid sinus*. Interv Neuroradiol 2008;14:59-68.

Received: September 18, 2013 - Accepted: September 23, 2013

# Calendar of events – Italian and International Meetings and Courses

Acta Otorhinolaryngol Ital 2016;36:153

Information, following the style of the present list, should be submitted to the Editorial Secretariat of Acta Otorhinolaryngologica Italica (actaitalicaorl@rm.unicatt.it).

**In accordance with the Regulations of S.I.O. and Ch.C.-F. (Art. 8) Members of the Society organising Courses, Congresses or other scientific events should inform the Secretary of the Association (A.U.O.R.L., A.O.O.I.) within the deadlines set down in the respective Statutes and Regulations.**

## MAY-DECEMBER 2016

**ENDOCHICAGO 7<sup>th</sup> WORLD CONGRESS FOR ENDOSCOPIC SURGERY OF THE SKULL BASE AND BRAIN • May 15-18, 2016 • Chicago (IL) – USA**

Course Directors: Amin B. Kassam, Martin Corsten, Ricardo L. Carrau, Daniel M. Prevedello, Vijay Anand, Theodore H. Schwartz – Website: [www.endoworld.org/d-1\\_7TH\\_WORLD\\_CONGRESS](http://www.endoworld.org/d-1_7TH_WORLD_CONGRESS)

**103° CONGRESSO NAZIONALE SIO SOCIETA ITALIANA DI OTORINOLARINGOLOGIA E CHIRURGIA CERVICO-FACCIALE • May 25-28, 2016 • Rome – Italy**

President: Roberto Filipo – Website: [www.sioechcf.it](http://www.sioechcf.it)

**HEAL (HEARING ACROSS THE LIFESPAN): “EARLY INTERVENTION: THE KEY TO BETTER HEARING CARE” • June 2-4, 2016 • Lake Como – Italy**

Website: [www.heal2016.org](http://www.heal2016.org) – E-mail: [meet@meetandwork.com](mailto:meet@meetandwork.com) – Tel. +39 049 8601818 – Fax +39 0498602389

**CORSO PRATICO DI ANATOMIA CHIRURGICA E DISSEZIONE SPERIMENTALE OTOLOGICA 2° LIVELLO - XXVII EDIZIONE • June 6-10, 2016 • Sanremo (IM) – Italy**

A cura di: A. Tombolini, F. Baricalla – Coordinato da: A. Tombolini

**CONGRESSO NAZIONALE DEL GENACOLO ITALIANO DI AUDIOVESTIBOLOGIA June 23-25, 2016 • Chieti – Italy**

President: Adelchi Croce. Scientific Secretariat: Giampiero Neri. E-mail: [info@nsmcongressi.it](mailto:info@nsmcongressi.it)

**26<sup>th</sup> CONGRESS OF THE EUROPEAN RHINOLOGIC AND THE 35<sup>TH</sup> INTERNATIONAL SYMPOSIUM OF INFECTION AND ALLERGY OF THE NOSE & 17<sup>th</sup> CONGRESS OF THE INTERNATIONAL RHINOLOGIC SOCIETY (ERS 2016) • July 3-7, 2016 • Stockholm – Sweden**

President: Pär Stjärne – Website: [www.ers-isian2016.com](http://www.ers-isian2016.com)

**INSTRUCTIONAL WORKSHOP EUROPEAN ACADEMY OF OTOLOGY AND NEURO-OTOLOGY September 28 - October 1, 2016 • Izmir, Turkey**

President: O. Nuri Ozgirgin – Website: [www.eaono.org](http://www.eaono.org)

## JANUARY-DECEMBER 2017

**CORSO DI DISSEZIONE OTOLOGICA, OTONEUROLOGICA E IMPLANTOLOGIA Uditiva, DISSEZIONE ENDOSCOPICA DELL'ORECCHIO MEDIO E INTERNO • January 10-12, 2017 • Paris, France**

Directors: Olivier Sterkers and Daniele Bernardeschi

**9<sup>th</sup> MILANO MASTERCLASS • March 24-28, 2017 • Milan – Italy**

Charimen: Paolo Castelnuovo and Pietro Palma – Website: [www.milanomasterclass.it](http://www.milanomasterclass.it)

**2<sup>nd</sup> WORLD CONGRESS ON ENDOSCOPIC EAR SURGERY • April 27-29, 2017 • Bologna – Italy**

Chairmen: Livio Presutti, Muaaz Tarabichi, Daniele Marchioni

**IFOS PARIS 2017 - ENT WORLD CONGRESS • June 24-28, 2017 • Paris – France**

Telephone +33 (0)1 44 64 15 15 – E-mail: [contact@ifosparis2017.org](mailto:contact@ifosparis2017.org) – Website: [www.ifosparis2017.org](http://www.ifosparis2017.org)