

HEAD AND NECK

# Intraoperative radiation therapy as adjuvant treatment in locally advanced stage tumours involving the middle ear: a hypothesis-generating retrospective study

## *Radioterapia intraoperatoria nei tumori maligni avanzati estesi all'orecchio medio: valutazione da uno studio retrospettivo*

G. CRISTALLI<sup>1</sup>, G. MERCANTE<sup>1</sup>, L. MARUCCI<sup>2</sup>, A. SORIANI<sup>3</sup>, S. TELERA<sup>4</sup>, G. SPRIANO<sup>1</sup>

<sup>1</sup> Department of Otolaryngology Head and Neck Surgery, Regina Elena National Cancer Institute, Rome, Italy;

<sup>2</sup> Department of Radiotherapy, Regina Elena National Cancer Institute, Rome, Italy; <sup>3</sup> Laboratory of Medical Physics, Regina Elena National Cancer Institute, Rome, Italy; <sup>4</sup> Department of Neurosurgery, Regina Elena National Cancer Institute, Rome, Italy

### SUMMARY

The objective of this study was to evaluate the safety, effectiveness and functional outcomes of intraoperative radiotherapy (IORT) followed by intensity-modulated radiation therapy (IMRT) in locally advanced stage tumours involving the middle ear. Data on 13 consecutive patients treated for malignant tumor of external auditory canal involving the middle ear were retrospectively reviewed. Median follow-up was 33 months (range 6-133). Five (38%) patients were stage III and 8 (62%) were Stage IV according to the University of Pittsburgh staging system. Lateral temporal bone resection (LTBR) was performed in all cases. LTBR was associated with parotidectomy in 5 (38%) cases, and with neck dissection and parotidectomy in 6 (46%) cases. No patients had gross residual tumour. Surgical treatment was followed by IORT (12 Gy) and IMRT (50 Gy). Adjuvant chemotherapy was used in 4 (30%) cases. Preoperative and postoperative audiometric tests were performed to assess hearing loss. 5-year local-control (LC), 5-year distant-metastasis (DM), 5-year disease-free-survival (DFS) and 5-year overall-survival (OS) were calculated with Kaplan-Meier method. Significant changes in bone conduction were reported after treatment. Partial flap necrosis was the only early complication observed in three (23%) cases, while meningeal fistula was seen in one (7.6%) case as a late complication. The 5-year LC-rate was 68%. The 5-year DM-rate was 90%. The 5-year DFS-rate was 61%. The 5-year OS-rate was 69%. IORT followed by IMRT for the treatment of advanced external auditory canal and middle ear tumours seems to be safe. No intraoperative death was reported. IORT may reduce the postoperative irradiation of remnant tissue obtaining the same full dose on the tumour bed. No complications of the residual external ear were observed. Detriment of neurosensory hearing may be expected. Future studies are required to confirm the benefit of this procedure in the ear.

KEY WORDS: Ear tumours • Intraoperative radiotherapy • IORT • Toxicity • Hearing loss • Middle ear cancer

### RIASSUNTO

Obiettivo dello studio è stato quello di valutare la sicurezza, l'efficacia e i risultati funzionali della radioterapia intraoperatoria (IORT) seguita dalla radioterapia a intensità modulata (IMRT) nel trattamento di tumori maligni avanzati estesi all'orecchio medio. Sono stati inclusi nello studio in modo retrospettivo 13 pazienti consecutive affetti da tumore dell'orecchio esterno esteso all'orecchio medio. Il follow-up è stato in media di 33 mesi (range 6-133). Cinque pazienti (38%) erano di stadio III e 8 pazienti (62%) erano di stadio IV secondo la classificazione dell'Università di Pittsburgh. Una petrosectomia laterale (LTBR) è stata eseguita in tutti i pazienti, la LTBR è stata associata a parotidectomia in 5 (38%) casi e a svuotamento latero-cervicale associato a parotidectomia in 6 (46%) casi. In tutti i casi si è effettuata asportazione della malattia macroscopicamente evidente. Il trattamento chirurgico è stato completato da IORT (12 Gy) e IMRT (50Gy). Chemioterapia adiuvante è stata eseguita in 4 (30%) casi. Test audiometrici pre- e post-operatori sono stati eseguiti per valutare la perdita uditiva. Il tasso di controllo di malattia locale (LC) a 5 anni, di metastasi a distanza (DM) a 5 anni, la sopravvivenza libera da malattia (DFS) e la sopravvivenza globale (OS) a 5 anni sono state calcolate con il metodo di Kaplan-Meier. Variazioni significative nella conduzione per via ossea sono state osservate dopo trattamento. Una necrosi parziale del lembo di ricostruzione è stata l'unica complicanza precoce osservata in 3(23%) casi, mentre una fistola meningea è stata osservata in un solo caso (7,6%) come complicanza tardiva. Il tasso di LC è stato del 68%. Il tasso di DM è stato del 90%. Il tasso di DFS è stato del 61%. Il tasso di OS è stato del 69%. La IORT seguita dalla IMRT nel trattamento dei tumori maligni avanzati dell'orecchio esterno e medio sembra essere sicuro. Nel nostro studio non sono riportati morti. La IORT può ridurre la dose di radioterapia postoperatoria a livello del tessuto residuo ottenendo la medesima dose a livello della sede del tumore. Non abbiamo osservato alcuna complicanza a livello dell'orecchio esterno residuo, mentre si è notato un peggioramento dell'udito anche a livello neurosensoriale. Sono necessari studi prospettici al fine di confermare quanto da noi osservato.

PAROLE CHIAVE: Tumori dell'orecchio • Radioterapia intraoperatoria • IORT • Tossicità • Perdita dell'udito • Cancro dell'orecchio medio

## Introduction

Malignant tumours affecting the middle ear are uncommon. The incidence for squamous cell carcinoma of the external auditory canal, middle ear, mastoid and temporal bone is estimated to be 1-6/1,000,000 population<sup>1</sup>. Early stage tumours of the external canal and middle ear are difficult to diagnose due to the presence of otitis media and deafness, and thus patients are usually diagnosed with advanced disease. Complete surgical resection and radiotherapy (RT) are considered the gold standard treatment for these patients<sup>2</sup>. Prognosis of advanced ear cancers is poor due to the difficulty in performing resections with adequate margins given the close proximity to vital surrounding structures (carotid artery, meninx and brain, skull base venous sinuses)<sup>3</sup>. There are limited data on the complications and functional outcomes after temporal bone cancer treatment. Deafness is one of the most invalidating complications. Conductive hearing loss is a consequence of surgery, while neurosensory hearing loss has been already reported as a likely complication after radiotherapy when it is not possible to completely exclude the inner ear from the radiation field<sup>4</sup>.

In the last few years, intraoperative radiotherapy (IORT), a direct application of irradiation to the tumour bed during an operative procedure, has been proposed to reduce the delay between surgery and intensity-modulated radiation therapy (IMRT), achieving the full dose on the tumour bed with a lower dose to surrounding tissues without an increase in morbidity.

IORT has emerged as a feasible treatment modality for patients with advanced head and neck cancer<sup>5</sup>, although the effectiveness of IORT in ear malignancy has never been investigated. The objective of this retrospective study was to evaluate the safety and feasibility of IORT by evaluating function of the inner ear and complications.

## Materials and methods

Data on 13 consecutive patients affected by a malignancy involving the middle ear were reviewed. All cases had biopsy proven squamous cell carcinoma and were treated at the Department of Otorhinolaryngology Head and Neck Surgery of the National Cancer Institute of Rome between January 2002 and February 2013. There were 9 males (70%) and 4 females (30%). Median age was 69 years (range 47-91). Median follow-up was 33 months (range 10-133). Eight patients (62%) had a primary tumour and 5 (38%) had a recurrence. Stage was based on clinical examination, computed tomography (CT), magnetic resonance imaging (MRI), positron emission tomography (PET-CT) and ultrasound (US). Patients were stage III in 5 (38%) cases and stage IV in 8 (62%) cases according to the University of Pittsburgh TNM staging system proposed by Arriaga for temporal bone tumours<sup>6</sup>. Patients treated by sub-total lateral petrosectomy were excluded from the study due to removal of the otic capsule. Table I shows demographic and characteristics of patients. Preoperative evaluation of the facial nerve showed grade I according to the House-Brackmann (H-B) classification<sup>7</sup> in all cases.

### Surgery

Lateral temporal bone resection (LTBR) was used to treat the primary tumour in all cases. LTBR was conducted by the principles detailed by Conley and Novack<sup>8</sup>. Only LTBR was performed in 2 (16%) cases, LTBR was associated with parotidectomy in 5 (38%) cases and with neck dissection with parotidectomy in 6 (46%) cases. The facial nerve was sacrificed in 9 (69%) cases; 4 (30%) patients underwent nerve grafting after the resection (3 cases with the sural nerve and 1 case with the great auricular nerve). The skin and soft tissues defect were reconstructed by myocutaneous pectoralis major flap in 10 (77%) cases,

Table I.

Pts.	Age	Gender	Histology	Grading	TNM by Arriaga <sup>6</sup>	Stage by Arriaga <sup>6</sup>	Surgery	IORT dose (Gy)	IMRT dose (Gy)
1	73	m	SCC	2	T3 N2b	IV	LSTP + P + ND	12	
2	86	f	SCC	3	T3 N2b	IV	LSTP + ND	12	
3	64	f	SCC	2	T3 N0	III	LSTP + P + ND	12	
4	60	m	SCC	3	T3 N2b	IV	LSTP + ND	12	
5	68	m	SCC	3	T3 N0	III	LSTP + P	12	
6	67	m	SCC	2	T3 N2b	IV	LSTP + P + ND	12	
7	73	f	SCC	2	T4 N0	IV	LSTP	12	
8	91	f	SCC	2	T3 N0	III	LSTP	12	
9	56	m	SCC	2	T4 N0	IV	LSTP + P	12	
10	82	m	SCC	2	T4 N2b	IV	LSTP + P + ND	12	
11	64	m	SCC	2	T3 N0	III	LSTP + P	12	
12	72	m	SCC	3	T3 N0	III	LSTP + P	12	
13	47	m	SCC	2	T3 N2b	IV	LSTP + P	12	

m: male; f: female; SCC: squamous cell carcinoma; LSTP: lateral subtotal petrosectomy; P: parotidectomy; ND: neck dissection.

temporalis flap in 2 (15%) cases and sterno-cleido-mastoid muscle in 1 (8%) case. IORT was delivered after complete tumour resection and report of frozen-section analysis confirming free surgical margins. The IORT team was composed of the surgeon, radiation oncologist and medical physicist. Irradiation was performed with a dedicated mobile accelerator, NOVAC7 (Hitesys spa, now SIT spa, Latina, Italy), located in the operating theatre (Fig. 1). This accelerator allows to irradiate patient while driving the structure close to the operatory field and using movable shield panels for the protection of the personnel. Two nominal electron energy levels at 7 and 9 MeV were used for IORT. The NOVAC7 is equipped with a cylindrical PMMA applicator series, diameter ranging from 4 to 10 cm and incidence angles of 0° or 22.5°. Main characteristics of NOVAC7 include the high dose rate, ranging from 6 to 26 Gy/min. The energy and applicator diameter were chosen by the IORT team for each patient on the basis of tumour extension and depth. The energy used was 7 MeV in all patients. For this energy level, the maximum and 90% isodose depths were 12 mm and 17 mm, respectively. The applicator mean diameter was 6 cm (range 4-8 cm). The IORT dose delivered was 12 Gy in all patients calculated at 90% isodose. The accuracy of the actual delivered dose was checked using in vivo dosimetry. The microMOSFET dosimeter was chosen for measurements because of its small size (active area 0.2 mm x 0.2 mm) that assumes no field perturbation. Dosimetric characterisation and the use of MOSFET dosimeters in vivo during IORT has been extensively described in the literature<sup>9</sup>. The microMOSFET dosimeter, placed inside a sterile catheter, was positioned in the centre of the IORT field to measure the entrance dose.

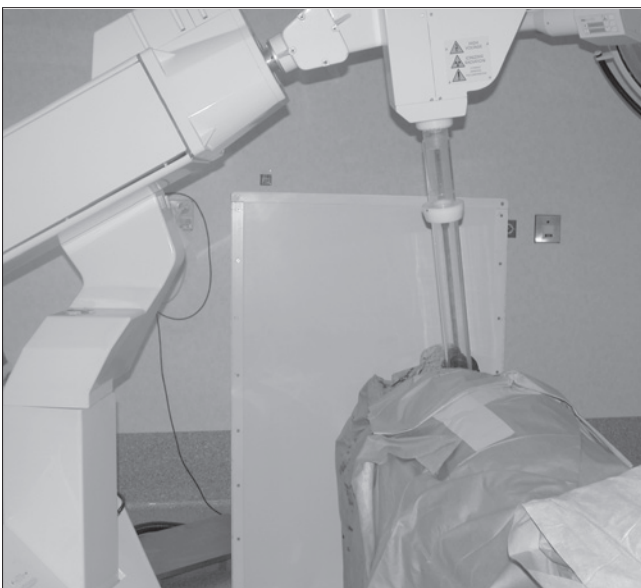

Fig. 1. Mobile accelerator NOVAC7 during the IORT procedure.

### Hearing tests

Audiologic hearing tests were conducted at baseline (before treatment) and at every follow-up after completing radiotherapy. Conductive hearing was not considered because of the presence of the tumour before treatment and due to the excision of the middle ear and obliteration of the cavity after surgery. Bone conduction thresholds were used to establish the changes in hearing frequencies. Each test consisted of pure-tone audiometry using bone conduction test on 0.5 kHz, 1 kHz, 2 kHz, 4 kHz, 6 kHz masking the contralateral ear using an Amplaid 309 audiometer (Amplifon, Italy). The baseline threshold level (bTL) of the treated ear was compared to the hearing threshold level after treatment (ptTL). The audiometry recorded during the last follow up was used to obtain data on hearing loss after treatment (with a 6 month minimum follow-up). Contralateral hearing was tested to assess the difference between the two sides.

### Facial nerve monitoring

Facial nerve function was scored by the H-B classification<sup>7</sup>.

### Complications

Observed complications were classified as early (observed between surgery + IORT and the beginning of IMRT) and late (after the beginning of IMRT).

### Follow-up

All patients were seen every month for the first year and every 3 months thereafter. Routine CT was performed after 6 months and every year. PET-CT scan was performed every year.

### Oncologic results

Recurrence was evaluated as rates of local control (LC) and distant metastasis (DM). Disease specific survival (DSS) and overall survival (OS) were adopted for survival estimation. Kaplan-Meier analysis was used for testing.

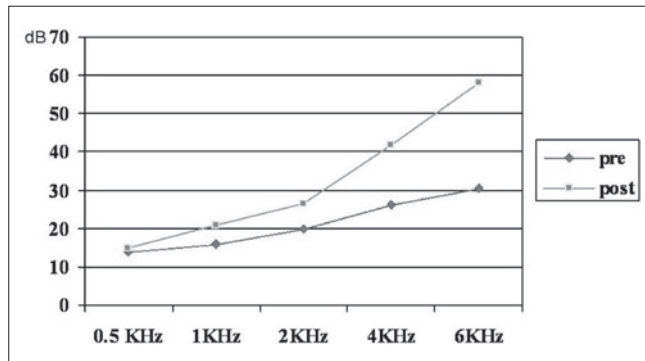
## Results

### Hearing tests

Differences in neurosensory hearing before and after treatment was significant at all tested frequencies ( $p < 0.05$ ) except 0.5 kHz in the ear affected by tumor. Differences in neurosensory hearing before and after treatment in the contralateral ear were not significant. Figure 2 shows mean bone conduction before and after treatment in the ear affected by tumour. Figure 3 shows median values of bone conduction before and after treatment at all tested frequencies in both ears.

### Facial nerve

The facial nerve was sacrificed in 9 (69%) of 13 cases and a facial nerve graft was performed in 4 patients (3 with sural nerve and 1 with great auricular nerve). Recovery to



**Fig. 2.** Bone conduction in the affected ear. Mean bone conduction (decibels) before and after treatment of the affected ear.

Stage IV according to the H-B function scale was achieved in 2 cases and stage V in the other 2 cases. In the 4 patients without facial nerve resection, grade I according to the H-B function scale was observed.

#### Complications

There were no intraoperative or postoperative deaths. The only early complication consisted in partial necrosis of the flap in 3 (23%) patients. Complete healing was achieved after dressing was applied in all cases. Meningeal fistula was the only late complication at 4 months after radiotherapy in a single (7.6%) previously untreated patient. CT showed local recurrence with fistula in this case. No other early or late complications were reported.

#### Disease control and survival

One patient had a recurrence on the tumour bed at 6 months after surgery, while three patients had regional recurrence after 7, 8 and 11 months. Lung metastases were observed in one case after 9 months of treatment. The 5-year LC rate was 68%. The 5-year DM rate was 90%. The 5-year DFS rate was 61%. The 5-year OS rate was for 69%.

## Discussion

This study focused on advanced stage tumours involving the middle ear, which generally have poor prognosis and require an aggressive surgical approach. The difficulty in performing a resection with adequate margins is due to proximity to vital surrounding structures, which may justify the low rate of survival. Considering the latter, postoperative RT is mandatory for high stage tumours of the middle ear<sup>3</sup>. No data are reported in the literature concerning the use of IORT during surgical procedures for advanced stage tumours of the middle ear followed by external RT. Clinical experience has shown that IORT may improve local control and disease-free survival in different tumours such as gastric, pancreatic, colorectal<sup>10</sup> and breast<sup>11</sup>. The oncologic value of IORT in advanced stage tumours involving the middle ear remains to be determined. The theoretical

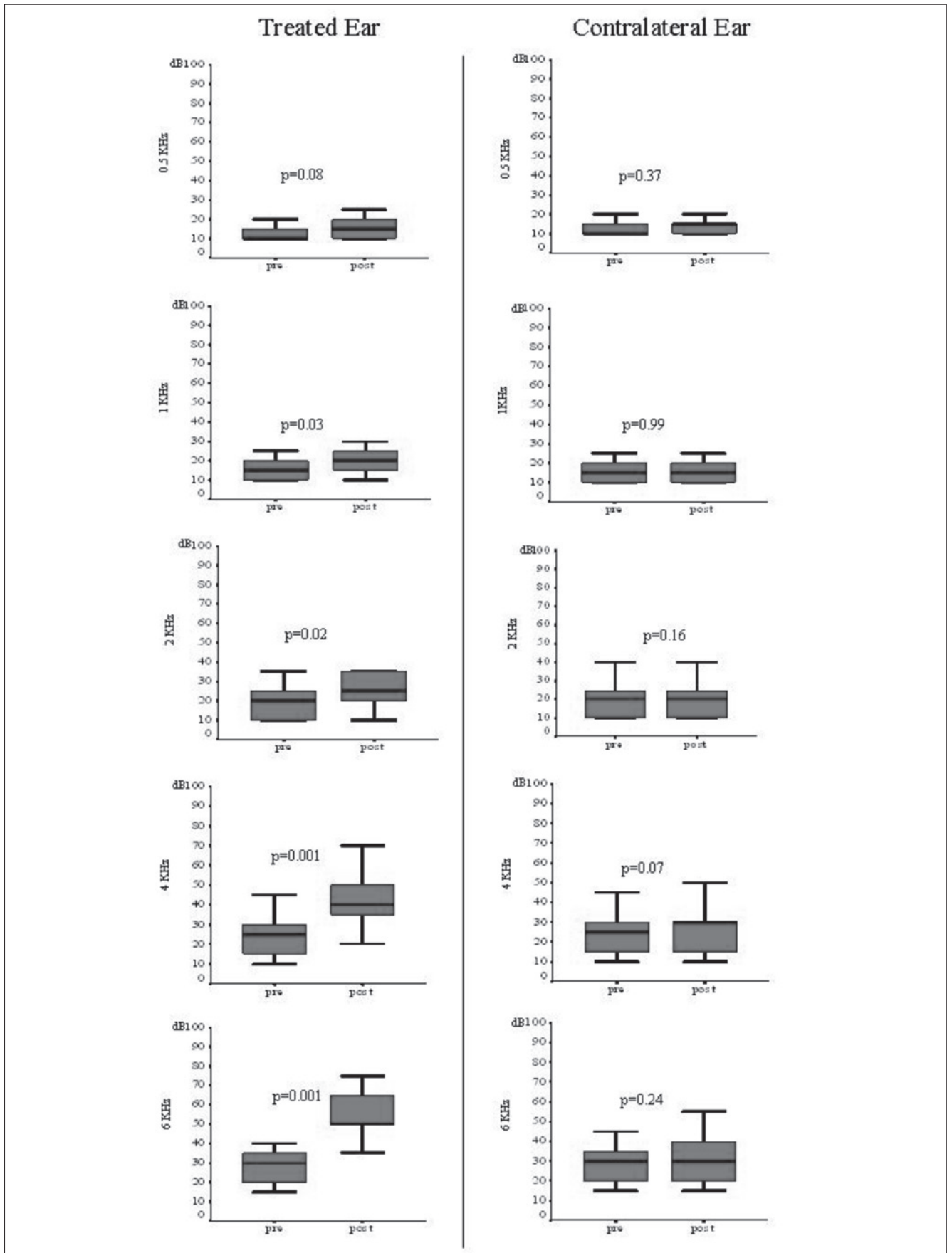
advantages of IORT are: 1) to deliver radiation at the time of surgery, with direct visualisation of the tumour bed, minimising the risk of a geographical miss; 2) to achieve good local tumour control with low morbidity; 3) to reduce the delay between surgery and RT.

One of the major endpoints of this pilot study was to consider the potential benefits of IORT and to assess the presence of complications related to the procedure, especially for hearing, facial nerve function and healing of tissues. Obliteration of the surgical field after LTBR with pedicled flap seems to prevent complications assuring good vascularisation of the operating field<sup>12</sup> and allowing a complete separation between the middle ear and the rhinopharynx by closure of the Eustachian tube thus avoiding entrance of pathogenic bacteria, especially after high doses of radiotherapy. We used the same technique with pedicled flap anticipated by 12 Gy of IORT to reduce flap exposure to radiation in order to prevent necrosis. Intraoperative complications have not been reported, while early complications consisted of partial necrosis of the flap in three (23%) patients, but it is difficult to correlate this type of complication with IORT or with the length and tension of the flap pedicle. In fact, we prefer to adopt free flaps for reconstruction, but follow-up data are not yet available. No other early complications were observed.

Complications after RT on the skull base reported in literature include brain necrosis, osteoradionecrosis, osteitis on remnant temporal bone, swelling of basal brain structures and headache<sup>12</sup>. The only late complication observed in our series was a meningeal fistula (7.6%) seen at 5 and 4 months after IORT and IMRT, respectively, but this cannot be related to the treatment because of the presence of local recurrence by CT. This patient died of disease 13 months after diagnosis.

There is a general consensus that ear toxicity is related to doses exceeding 50 Gy; however, no agreement has been reached on the maximum dosage tolerated by the inner ear before showing complete deafness. We investigated a group of patients with ear cancer representing the only series of cases treated with surgery and IORT followed by IMRT. Previously published data considered inner ear toxicity after RT for the treatment of rhinopharyngeal carcinoma. This site requires irradiation of both cochleas, and comparison between the two ears before and after treatment is not possible. In our experience, only one side underwent IMRT and the contralateral ear was used for comparison, thus reducing the bias of confounding events such as viral infections, chemotherapy, or other.

Early postoperative hearing tests (between surgery + IORT and IMRT) did not show any significant modification in bone conduction, and possible explanations may be: a) radiation related hearing loss has longer latency compared to conductive hearing loss that is related to the surgical procedure, and b) the dose of IORT did not exceed 12 Gy. Late neurosensory hearing impairment (after IMRT) occurred after IMRT



**Fig. 3.** Bone conduction in both ears. Median values of bone conduction before and after treatment at 0.5 kHz, 1 kHz, 2 kHz, 4 kHz and 6 kHz in the affected ear (left side) and the contralateral ear (right side).

throughout the all frequencies and was statistically significant from 1 to 6 kHz. Late hearing loss after RT seems to be related to vascular injury of inner ear structures with progressive onset of fibrosis and ossification of the inner ear fluid space. At any rate, in this study, CT scan did not show any evidence of inner ear ossification after RT<sup>4</sup>.

In the literature, nerve toxicity has been observed in humans (lumbar tract) undergoing doses over 10 Gy and in a canine model over 15 Gy<sup>13</sup>. Nonetheless, our 4 cases did not show any facial nerve deficit after RT (12 Gy of IORT + 50 Gy IMRT). Furthermore, the results after neural graft repair were comparable with those reported in the literature where the RT regimen did not impact functional recovery<sup>14</sup>.

Luc et al. described the prognostic factors for survival and recurrence in temporal bone cancer<sup>3</sup>. Yeung et al. reported a 5-year local control rate of 67% for T3-T4 ear malignancies<sup>15</sup>. Pfreunder et al. observed a 2-year local control rate of 85% for T1-2 and 50% for T3-T4<sup>16</sup>. Bacciu et al. reported 5-year disease specific survival of 86.2% and 48.7% for patients with T3 and T4 disease, respectively<sup>17</sup>. Our data confirmed the possibility to achieve a good control of disease with a LC rate of 68% and DFS rate of 61%, even in advanced stage<sup>18</sup>. It is difficult to compare our results with those of other series given the heterogeneity of staging classifications and treatment used. The low number of cases did not permit drawing any conclusion about the role of IORT in improving oncologic outcomes. This study represents the first for future studies with larger series in order to demonstrate the effectiveness of IORT in ear cancer.

## Conclusions

A dose of 12 Gy of IORT on the inner ear and surrounding tissues during advanced ear cancer surgery can be considered as safe. Early complications were not observed, while late complications such as mild neurosensorial hearing loss on middle-high frequencies can be expected after IORT followed by IMRT. Future studies are required to assess the oncologic value of IORT in local control of disease, confirming the hypothesis of this retrospective study.

## Acknowledgments

The authors acknowledge Ms. Tania Merlino for editing the English language of the text.

## References

<sup>1</sup> Kinney SE. *Tumours of the external auditory canal, middle ear, mastoid and temporal bone*. In: *Comprehensive Management of Head*

*and Neck Tumours*. Thawley SE, Panje WR, Batsakis JG, Lindberg RD (eds). Philadelphia: WB Saunders Co.; 1987. p. 81-206.

<sup>2</sup> Morris LGT, Mehra S, Shah JP, et al. *Predictors of survival and recurrence after temporal bone resection for cancer*. *Head and Neck* 2012;34:1231-9.

<sup>3</sup> Lassig AA, Spector ME, Soliman S, et al. *Squamous cell carcinoma involving the temporal bone: lateral temporal bone resection as primary intervention*. *Otol Neurotol* 2013;34:141-50.

<sup>4</sup> Jereczek-Fossa BA, Zarowski A, Milani F, et al. *Radiotherapy induced ear toxicity*. *Cancer Treat Rev* 2003;29:417-30.

<sup>5</sup> Marucci L, Pichi B, Iaccarino G, et al. *Intraoperative radiation therapy as an "early boost" in locally advanced head and neck cancer: preliminary results of a feasibility study*. *Head Neck* 2008;30:701-8.

<sup>6</sup> Arriaga M, Curtin H, Takahashi H, et al. *Staging proposal for external auditory meatus carcinoma based on preoperative clinical examination and computed tomography findings*. *Ann Otol Rhinol Laryngol* 1990;99:714-21.

<sup>7</sup> House JW, Brackmann DE. *Facial nerve grading system*. *Otolaryngol Head Neck Surg* 1985;93:146-7.

<sup>8</sup> Conley J, Novack AJ. *The surgical treatment of malignant tumors of the ear and temporal bone*. *Arch Otolaryngol* 1960;71:635-52

<sup>9</sup> Soriani A, Landoni V, Marzi S, et al. *Setup verification and in vivo dosimetry during intraoperative radiation therapy (IORT) for prostate cancer*. *Med Phys* 2007;34:3205-10.

<sup>10</sup> Kusters M, Valentini V, Calvo FA, et al. *Results of European pooled analysis of IORT-containing multimodality treatment for locally advanced rectal cancer: adjuvant chemotherapy prevents local recurrence rather than distant metastases*. *Ann Oncol* 2010;21:1279-84.

<sup>11</sup> Veronesi U, Orecchia R, Luini A, et al. *Full-dose intraoperative radiotherapy with electrons during breast-conserving surgery experience with 590 cases*. *Ann Surg* 2005;242:101-6.

<sup>12</sup> Nguyen MT, Billington A, Habal MB. *Osteoradionecrosis of the skull after radiation therapy for invasive carcinoma*. *J Craniofac Surg* 2011;22:1677-81.

<sup>13</sup> Sindelar WF, Kinsella TJ. *Normal tissue tolerance to intraoperative radiotherapy*. *Surg Oncol Clin N Am* 2003;12:925-42.

<sup>14</sup> Leong SC, Lesser TH. *Long-term outcomes of facial nerve function in irradiated and nonirradiated nerve grafts*. *Ann Otol Rhinol Laryngol* 2013;122:695-700.

<sup>15</sup> Yeung P, Bridger A, Smees R, et al. *Malignancies of the external auditory canal and temporal bone: a review*. *Anz J Surg* 2002;72:114-20.

<sup>16</sup> Pfreunder L, Schwagener K, Willner J, et al. *Carcinoma of the external auditory canal and middle ear*. *Int J Radiation Oncology Biol Phys* 1999; 44:777-8.

<sup>17</sup> Bacciu A, Clemente IA, Piccirillo E, et al. *Guidelines for treating temporal bone carcinoma based on long-term outcomes*. *Otol Neurotol* 2013;34:898-907.

<sup>18</sup> Cristalli G, Mancio V, Pichi B, et al. *Treatment and outcome of advanced external auditory canal and middle ear squamous cell carcinoma*. *J Craniofac Surg* 2009;20:816-21.

Received: November 11, 2014 - Accepted: July 24, 2015

Address for correspondence: Giuseppe Mercante, Department of Otolaryngology, Head and Neck Surgery, Regina Elena National Cancer Institute, via Elio Chianesi 53, 00144 Rome, Italy. E-mail: mercante.giuseppe@gmail.com