

## HEAD AND NECK

# Technical refinements in mandibular reconstruction with free fibula flaps: outcome-oriented retrospective review of 99 cases

## *Accorgimenti tecnici nelle ricostruzioni mandibolari con lembi liberi di fibula: analisi retrospettiva dei risultati su 99 casi*

G. COLLETTI<sup>1</sup>, L. AUTELITANO<sup>1</sup>, D. RABBIOSI<sup>1</sup>, F. BIGLIOLI<sup>1</sup>, M. CHIAPASCO<sup>2</sup>, M. MANDALÀ<sup>3</sup>, F. ALLEVI<sup>1</sup>

<sup>1</sup> Department of Maxillo Facial Surgery, "San Paolo" Hospital, University of Milano, Italy; <sup>2</sup> Department of Oral Surgery, "San Paolo" Hospital, University of Milano, Italy; <sup>3</sup> Department of Otolaryngology, Azienda Ospedaliera Universitaria Integrata, University of Verona, Italy

## SUMMARY

Congenital disease, major trauma, tumour resection and biphosphonate-related osteonecrosis can lead to partial, subtotal, or total loss of the mandibular bone. Minor defects can be easily reconstructed using bone grafts, whereas microvascular free tissue transfer may be unavoidable in the case of major bone loss or poor quality of soft tissue. Simple bone or composite osteocutaneous fibula free flaps have proven invaluable and remain the workhorse for microvascular mandibular reconstruction in daily practice. Our experience with 99 consecutive fibular free flaps confirms the available data in terms of high success rate. In these cases, 90% had total success, while 7 had complete flap failures. Three of our patients showed skin paddle necrosis with bony conservation. This report focuses on the technical refinements used by the authors that can prove valuable in obtaining predictable and precise results: in particular, we discuss surgical techniques that avoid vascular pedicle ossification by removing the fibular periosteum from the vascular pedicle itself and reduce donor site morbidity and aid in management of the position in the new condylar fossa. Finally, new technologies such as intraoperative CT and custom premodelled fixation plates may also increase the predictability of morpho-functional results.

KEY WORDS: Mandibular reconstructions • Fibula free flap

## RIASSUNTO

*Patologie congenite, traumi, osteonecrosi da bifosfonati, osteoradionecrosi o resezioni mandibolari conseguenti a patologie neoplastiche spesso comportano deficit ossei mandibolari parziali, subtotali o totali. In presenza di piccoli difetti, si ricorre generalmente all'impiego di innesti ossei; diverso il caso di grandi deficit che richiedono ricostruzioni complesse che si servono di lembi liberi microvascolari. In questo articolo gli autori presentano la loro esperienza con 99 lembi liberi microvascolari di fibula impiegati nelle ricostruzioni mandibolari, confermando l'elevato tasso di successo già riportato in letteratura: questo lavoro infatti riporta un successo totale nel 90% dei casi, con 7 perdite complete del lembo e 3 perdite parziali, vale a dire limitate alla padella cutanea del lembo. Gli autori hanno posto l'attenzione su accorgimenti tecnici che contribuiscono a garantire eccellenti risultati, in particolar modo per quel che concerne l'ossificazione del peduncolo vascolare del lembo ricostruttivo, la morbilità a carico del sito di prelievo e il posizionamento della nuova testa condilare nella fossa articolare. Infine vengono prese in considerazione le nuove tecnologie proposte recentemente in letteratura, quali l'impiego della TC intraoperatoria e di mezzi di sintesi customizzati premodellati, che garantiscono una maggiore predicibilità dei risultati.*

PAROLE CHIAVE: Ricostruzioni mandibolari • Lembo libero microvascolare di fibula

Acta Otorhinolaryngol Ital 2014;34:342-348

## Introduction

Mandibular integrity can be affected by a variety of causes, including infection, benign and malignant neoplasms, osteoradionecrosis and trauma. Restoration of mandibular integrity after such insults is pivotal in restoring form and function. Furthermore, adequate bone height must be provided if dental fixture positioning is requested by the patient<sup>1</sup>.

In case of minor resections with total or nearly-total conservation of the mandibular margin, a bone graft usually provides more than adequate bone height for reconstruction and subsequent implant positioning<sup>2</sup>. Larger defects and/or defective recipient soft tissues, as in the case of osteonecrosis or radiation therapy, pose a completely different surgical challenge. Such defects may only be addressed through free tissue transfer of osseous flaps with or without skin paddles<sup>1,3,4</sup>.

Different flaps have already been proposed including the iliac crest microvascular free flap<sup>5</sup>, radial forearm flap with partial radius inclusion<sup>6</sup> and scapula osteocutaneous flap<sup>7</sup>. Nevertheless, the fibula flap, introduced by Taylor and colleagues<sup>8</sup> and rendered popular in oral reconstructions by Hidalgo<sup>9</sup>, has become the gold standard in mandibular reconstruction due to its favourable characteristics (co-harvesting with multiple skin paddles<sup>10</sup>, harvesting as a neurosensory flap<sup>11</sup>, optimal form restoration and acceptable functional results<sup>1</sup>), high rate of success and low rate of complications in both recipient and donor sites.

While ancillary techniques such as virtual surgical planning using computer-assisted modelling<sup>12 13</sup> and distraction osteogenesis<sup>14</sup> are undoubtedly changing the rules of fibula flap mandibular reconstructions, there are nevertheless some basic, somewhat minor, aspects of fibula free flap harvesting and defect reconstructions that must not be forgotten in order to ensure the highest rates of success.

The authors retrospectively review all their fibula flap mandibular reconstructions performed between 2002 and 2010, providing information on patients, procedures and results, with the aim of describing the technical refinements used during planning and execution which have proven valuable in obtaining precise and predictable results.

## Materials and methods

We performed a retrospective review to identify all patients who underwent free flap mandibular reconstructions between 2002 and 2010. A total of 109 free flap mandibular reconstructions were performed. Ten patients who underwent mandibular reconstruction using free

flaps other than fibula were excluded from this study. The remaining 99 patients underwent free fibula flap reconstruction and were included in the study. Mean age was  $56.98 \pm 14.78$  years (minimum age 14 years, maximum age 76 years). Patient demographics, specific information on presentation at diagnosis, type of resection and type of reconstruction are detailed in Table I. Mean follow-up time was  $8.62 \pm 2.42$  years (minimum 4.48 years, maximum 12.76 years).

All procedures were carried out under general anaesthesia following the widely used technique originally proposed by Hidalgo<sup>9</sup>. Antithrombotic agents were routinely used during the postoperative period. All patients underwent preoperative CT angiography to investigate the presence of peripheral vascular disease and tibio-peroneal arterial anatomic variants, such as peroneal arteria magna<sup>15</sup> and peroneal artery absence<sup>16</sup>.

## Results

The incidence of complete flap loss was 7% (7 flaps); partial flap losses (fibular skin paddle necrosis) were encountered in 3 cases (3%). Overall, the total success rate was 90% with fibular free flaps for mandibular reconstruction; the partial success rate was 93%.

Other common complications included the ossification of the vascular pedicle of the fibula around the periosteum (4%) and partial or total necrosis affecting the skin graft used to reconstruct the donor site (18%). One patient presented extensive muscle and skin necrosis of the leg surrounding the site of harvest and required major microvascular reconstruction of these soft tissues; this procedure was performed elsewhere. Two of our most representative

**Table I.** Demographic and clinical data on sex, reason for mandibular resection, extent of mandibular resection and type of free fibula flap employed in reconstruction.

	Number of patients	% of patients
Sex		
male	71	72%
female	28	28%
Reason for mandibular resection		
resection of malignant tumour	85	86%
resection of benign tumour	9	9%
trauma	3	3%
osteonecrosis	2	2%
Extent of mandibular resection		
partial mandibulectomy	13	13%
hemimandibulectomy	34	34%
total mandibulectomy	52	53%
Type of flap used		
osteofascial flap	81	82%
osteofasciocutaneous flap	18	18%

microvascular reconstructions are presented in Figures 1 and 2 and 3-5, respectively.

## Discussion

Most authors report a success rate with the fibula free flap of 90-100% with almost no donor site morbidity<sup>17,18</sup>. Such optimal characteristics make the fibula flap an excellent choice for mandibular reconstructions, independent of the cause of bone loss<sup>1,19,20</sup>.

Data in the present case series are strongly coherent with literature reports. Flap failure (both complete or limited to the skin paddle) is well below 10% and reports of morbidity in the donor site are around 1% for major complications and 20% for minor complications such as necrosis of local skin graft. It is of utmost importance, no matter how trivial it may seem, that a high rate of success can be achieved only through an extremely careful procedure, as suggested in the literature<sup>21-23</sup>.

It is obviously beyond the scope of this paper to provide a step-by-step description of the procedures required to maximise the success rate. However, we would like to briefly point out some minor aspects that are often overlooked, which appear pivotal in our experience. Such features involve both pre-surgical planning, the surgical procedure itself, and during and after flap harvesting and preparation.

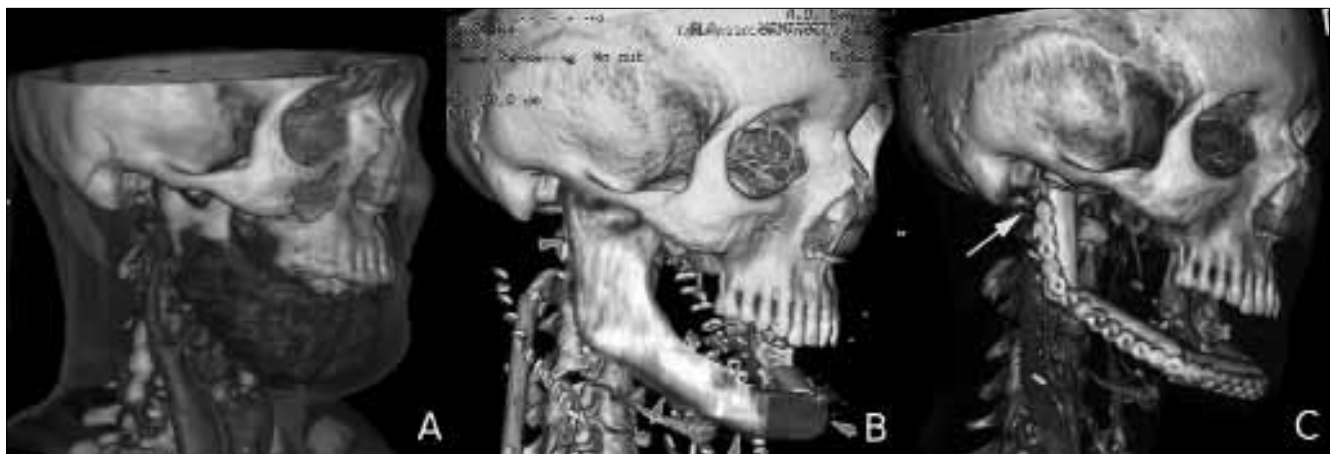Concerning pre-surgical planning, vascular imaging plays a major role in the donor site. If we observed no nervous or vascular complications in the donor site, this is mostly due to the use of routine lower limb vascular CT scan. In fact, vascular CT scans can highlight blood flow anomalies in the popliteal trifurcation, motivating the switch to different flaps, such as the free iliac crest. Vascular CT scans, as well as Doppler echography and, most notably, vascular MRI are nowadays considered an invaluable

tool during surgical planning that are able to identify pre-existing conditions and potentially dangerous anatomical anomalies<sup>25,26</sup>.

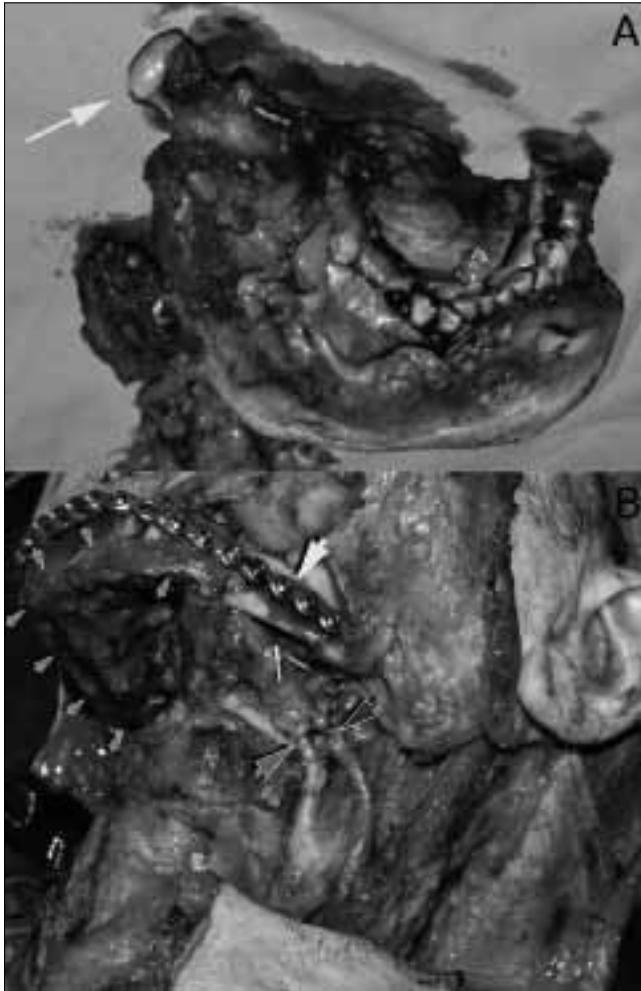
Focusing on flap harvesting, first of all we believe that a delicate and respectful attitude is mandatory in managing peroneal vessels, and that the same treatment should be given to the recipient vessel. As Khoukri stated<sup>23</sup>, it is probably during this phase that reducing the pace and increasing the delicateness and attention is most critical and typical of the experienced microvascular surgeon. A careful harvesting phase not only increases the chance of successful reconstruction, but also dramatically reduces donor site morbidity, such as muscle and skin necrosis, thrombosis, chronic pain and abnormal gait<sup>24,27</sup>.

After carefully harvested the flap, modelling should also be performed with the utmost attention in order to grant the best results. Most notably, the chance of ossification of the periosteum of the fibula must be taken into account if this is elevated with the vascular pedicle as pointed out by Autelitano et al.<sup>22,28</sup>. Therefore, instead of raising the vascular pedicle from the bone subperiosteally, it is wise to carefully separate the pedicle from the periosteum and then discard the excess bone with the attached periosteum secondarily. Since we introduced this technical innovation, we have not experienced an increase in flap failure. Therefore, we consider pedicle separation to be a safe procedure.

Another useful and safe “tip” we adopted is exploiting any periosteal excess in the flap to grant a better blood supply, mostly in the case of planned post-surgical radiotherapy, as suggested by Trignano et al<sup>29</sup>. Obviously, reconstruction of the surgical defect is the most delicate part of the process, and the surgeons’ attention should be addressed to several relevant issues. When using a reconstructive plate, pre-plating is associated with good results, both in the literature and in our experience<sup>30</sup>. Nevertheless, pre-



**Fig. 1.** Case 1. (A) Preoperative 3D-CT scan with window for bone and soft tissues. A bulky tumour involves the whole right mandible and half of the left mandible. (B) 3D-CT scan showing the simulated position of the fibula free flap for reconstruction of the right mandibular body and ramus. (C) Post-operative 3D-CT scan showing mandibular reconstruction with fibula free flap.



**Fig. 2.** Case 1. (A) Intra-operative view of the mandibulectomy specimen including the right condylar process (arrow). Intra-operative image showing the fibula free flap placed to reconstruct the mandible (small blue arrows) and stabilised with a reconstructive plate and screws (yellow arrow). Note the microvascular anastomosis (blue and red arrows).

plating is not feasible whenever the tumour has involved the surrounding soft tissues and/or has deformed the original shape of the mandible. In these cases, a custom premodelled plate, CT custom osteotomy guides, or surgery simulators can offer the best reconstructive chances<sup>31,32</sup>. However, the high cost of these instruments is an issue that still must be addressed, and we have been unable to implement them at our institution.

If the resection involves the condylar process, it is imperative to correctly place the newly created condyle in the articular fossa. If this is not achieved, then a postoperative loss of occlusion is very likely to occur. We usually adhere to the following “condyle position check” protocol: after resection, if the glenoid fossa is near and visible, a blind tentative positioning can be performed. Having positioned the neocondyle, the plates used for rigid fixation are secured and mandibular movements are checked. This procedure, however, can be tricky and even in the most experienced hands it is prone to failure. Intraoperative

CT can be useful to verify the condyle position in difficult cases. If intraoperative CT scan is not available, the glenoid fossa must be accessed surgically to validate the position of the condyle. Even if more sparing accesses to the condylar fossa are available<sup>34,35</sup>, we believe that the most appropriate access to the glenoid fossa in major mandibular reconstructions is the preauricular access with or without endaural modification. Once the glenoid fossa is reached a resorbable suture can be passed through the newly created condyle and the bony glenoid fossa by inserting a hole in both bony stumps. The suture can finally be tightened to hold the new condyle in place.

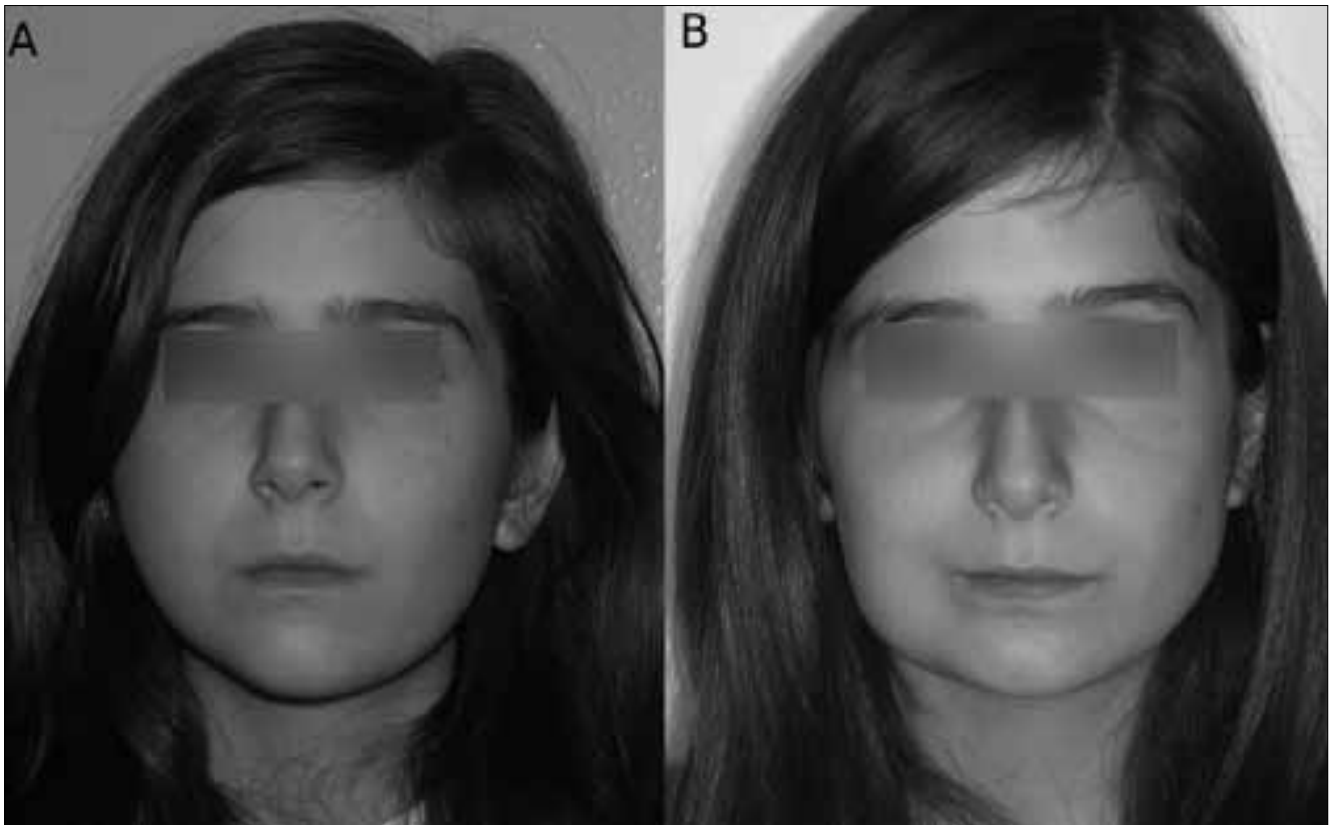One last important consideration should be given to intermaxillary fixation. We routinely use intermaxillary fixation in order to maximise the precision of the reconstruction. There are, however, many new techniques that may be employed to achieve intermaxillary fixation. While intermaxillary fixation screws are one of the most popular techniques, despite their routine use in mandibular trauma, we do not rely on them in major mandibular reconstructions since conventional arch bars are more precise where teeth contacts are less immediate and where more stability is needed.

After having harvested and modelled the flap, most of the surgeons’ attention is devoted to reconstructing the surgical defect, and donor site health if often jeopardised. For example, one patient in our series suffered from extensive necrosis of the skin and muscles around the donor site. This complication can be related to two major causes: primary closure of the donor site with excess tension and local administration of anaesthetics at the donor site that may have masked the signs of compartmental syndrome. Aggressive debridement followed by free flap reconstruction of the donor site skin defect can circumvent this the complication. We therefore strongly advise against administration of long-acting anaesthetics for control of post-operative pain.

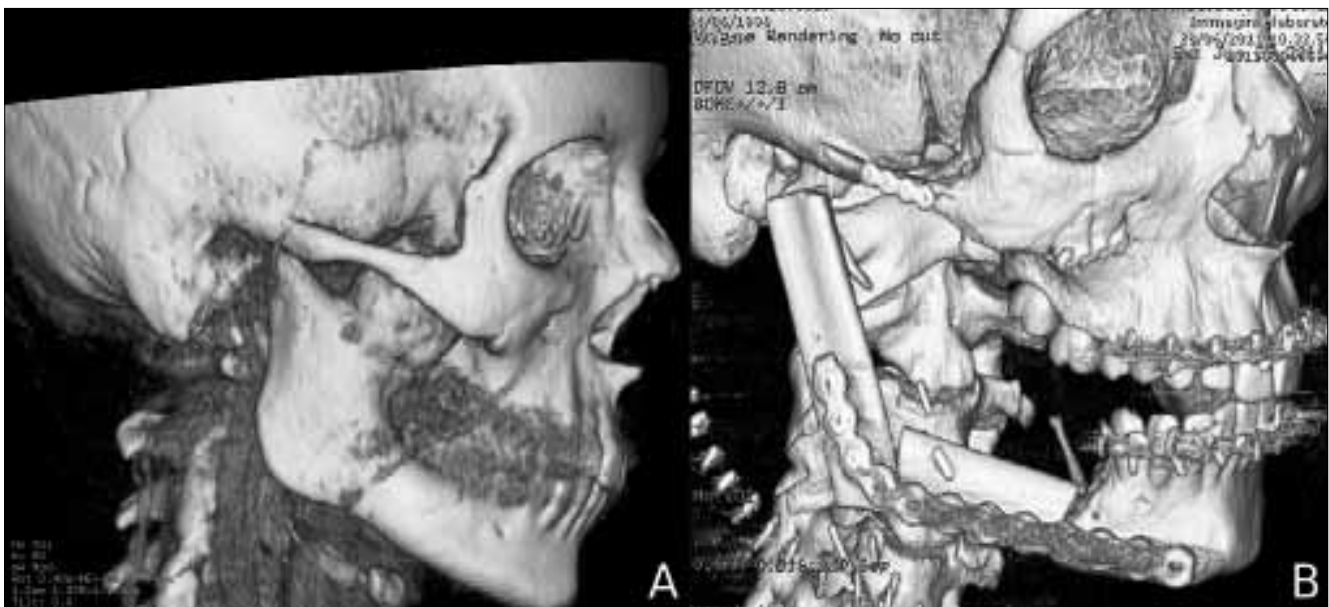Lastly, another interesting method that may be performed at the end of the procedure should be mentioned, namely bone banking. If a major part of the fibula is to be discarded, it is possible to bank the remaining bone at the harvesting site. In one of our patients, who required a second surgical procedure for pre-prosthetic purposes, we harvested the banked bone which had survived with minimal resorption. This issue needs further investigation, but it might prove useful, or prudent at least, to perform in any patient where a major bone discard is required. It is important to not mistake bone banking with flap prefabrication proposed by Nazerani et al.<sup>33</sup>, the use of which we strongly discourage.

In our experience, if all of the above steps are followed, a more predictable and precise outcome can be expected in mandibular reconstructions with free fibular flaps.





**Fig. 3.** Case 2. (A) Frontal pre-operative picture showing severe facial asymmetry characterised by bulging in the right ramus and condylar region. (B) Frontal view of the patient 2 years after surgery showing the excellent symmetry of the face.

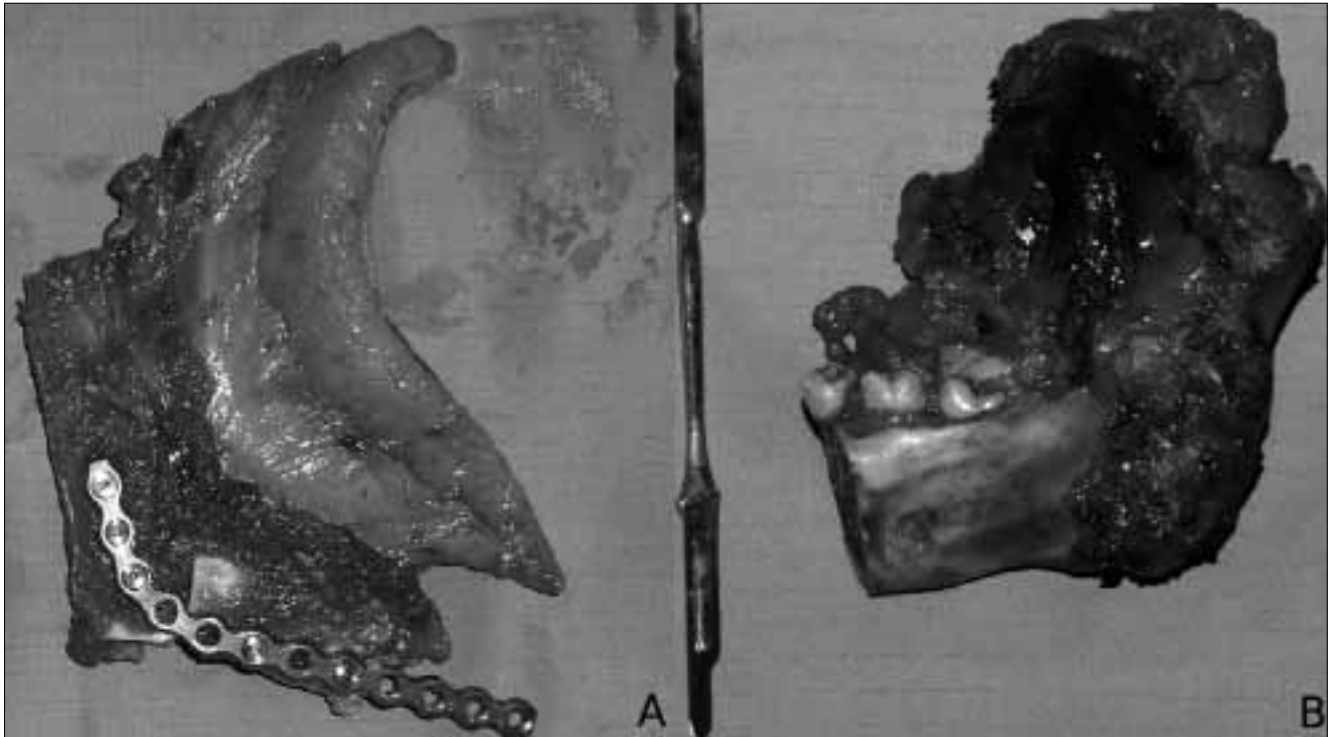


**Fig. 4.** Case 2. (A) Pre-operative CT scan showing the neoplasm, which extends through the whole right mandibular ramus and the posterior part of the body. (B) Post-operative 3D-CT scan showing microvascular mandibular reconstruction using a fibula free flap.

## Conclusion

While many reconstructive surgeons consider the fibula as the workhorse for mandibular reconstructions, we believe that many small details are often underlooked. However,

greater attention to a few crucial aspects can help the surgeon to obtain a predictable result<sup>36</sup>. Many new techniques, such as intraoperative CT scan and custom premodelled reconstructive plates, are powerful tools that can be of considerable value during the reconstructive phase.



**Fig. 5.** Case 2. (A) Intra-operative view of the right hemimandibulectomy specimen and (B) fibula flap before its position in the surgical site.

## References

- <sup>1</sup> Hayden RE, Mullin DP, Patel AK. *Reconstruction of the segmental mandibular defect: current state of the art.* *Curr Opin Otolaryngol Head Neck Surg* 2012;20:231-6.
- <sup>2</sup> Chiapasco M, Colletti G, Romeo E, et al. *Long term results of mandibular reconstruction with autogenous bone grafts and oral implants after tumor resection.* *Clin Oral Implants Res* 2008;19:1074-80.
- <sup>3</sup> Deganello A, Gitti G, Parrinello G, et al. *Cost analysis in oral cavity and oropharyngeal reconstructions with microvascular and pedicled flap.* *Acta Otorhinolaryngol Ital* 2013;33:380-7.
- <sup>4</sup> Tarsitano A, Vietti MV, Cipriani R, et al. *Functional results of microvascular reconstruction after hemiglossectomy: free anterolateral thigh flap versus free forearm flap.* *Acta Otorhinolaryngol Ital* 2013;33:274-9.
- <sup>5</sup> Taylor GI, Townsend P, Corlett R. *Superiority of the deep circumflex iliac vessels as the supply for free groin flaps.* *Plast Reconstr Surg* 1979;64:595-604.
- <sup>6</sup> Soutar DS, Scheker LR, Tanner NS, et al. *The radial forearm flap: a versatile method for intraoral reconstruction.* *Br J Plast Surg* 1983;36:1-8.
- <sup>7</sup> Swartz WM, Banis JC, Newton ED, et al. *The osteocutaneous scapular flap for mandibular and maxillary reconstruction.* *Plast Reconstr Surg* 1986;77:530-45.
- <sup>8</sup> Taylor GI, Miller GD, Ham FJ. *The free vascularized bone graft. A clinical extension of microvascular techniques.* *Plast Reconstr Surg* 1975;55:533-44.
- <sup>9</sup> Hidalgo DA. *Fibula free flap: a new method of mandible reconstruction.* *Plast Reconstr Surg* 1989;84:71-9.
- <sup>10</sup> Daya M. *Peroneal artery perforator chimeric flap: changing the perspective in free fibula flap use in complex oromandibular reconstruction.* *J Reconstr Microsurg* 2008;24:413-18.
- <sup>11</sup> O'leary MJ, Martin PJ, Hayden RE. *The neurocutaneous free fibula flap in mandibular reconstruction.* *Otolaryngol Clin North Am* 1994;27:1081-96.
- <sup>12</sup> Cutting C, Bookstein FL, Grayson B, et al. *Three-dimensional computer-assisted design of craniofacial surgical procedures: optimization and interaction with cephalometric and CT-based models.* *Plast Reconstr Surg* 1986;77:877-87.
- <sup>13</sup> Hirsch DL, Garfein ES, Christensen AM, et al. *Use of computer-aided design and computer-aided manufacturing to produce orthognathically ideal surgical outcomes: a paradigm shift in head and neck reconstruction.* *J Oral Maxillofac Surg* 2009;67:2115-22.
- <sup>14</sup> Sacco AG, Chepeha DB. *Current status of transport-disc-distraction osteogenesis for mandibular reconstruction.* *Lancet Oncol* 2007;8:323-30.
- <sup>15</sup> Rosson GD, Singh NK. *Devascularizing complications of free fibula harvest: peronea arteria magna.* *J Reconstr Microsurg* 2005;21:533-8.
- <sup>16</sup> Young DM, Trabulsky PP, Anthony JP. *The need for preoperative leg angiography in fibula free flap.* *J Reconstr Microsurg* 1994;10:283-7.
- <sup>17</sup> Ho MW, Brown JS, Magennis P, et al. *Salvage outcomes of free tissue transfer in Liverpool: trends over 18 years (1992-2009).* *Br J Oral Maxillofac Surg* 2012;50:13-8.
- <sup>18</sup> Salvatori P, Paradisi S, Calabrese L, et al. *Patients' survival after free flap reconstructive surgery of head and neck squamous cell carcinoma: a retrospective multicentre study.* *Acta Otorhinolaryngol Ital* 2014;34:99-104.

- <sup>19</sup> Hanasono MM, Militsakh ON, Richmon JD, et al. *Mandibulectomy and free flap reconstruction for biphosphonate related osteonecrosis of the jaws*. JAMA Otolaryngol Head Neck Surg 2013;139:1135-42.
- <sup>20</sup> Deganello A, Gitti G, Strijs B, et al. *Palliative combined treatment for unresectable cutaneous basosquamous cell carcinoma of the head and neck*. Acta Otorhinolaryngol Ital 2013;33:353-6.
- <sup>21</sup> Khouri RK. *Avoiding free flap failure*. Clin Plast Surg 1992;19:773-81.
- <sup>22</sup> Tarsitano A, Sgarzani R, Betti, et al. *Vascular pedicle ossification of free fibular flap: is it a rare phenomenon? Is it possible to avoid this risk?* Acta Otorhinolaryngol Ital 2013;33:307-10.
- <sup>23</sup> Baj A, Beltramini GA, Demarchi M, et al. *Extended-pedicle peroneal artery perforator flap in intraoral reconstruction*. Acta Otorhinolaryngol Ital 2013;33:282-5.
- <sup>24</sup> Ling XF, Peng X. *What is the price to pay for a free fibula flap? A systematic review of donor-site morbidity following free fibula flap surgery*. Plast Reconstr Surg 2012;129:657-74.
- <sup>25</sup> Akashi M, Nomura T, Sakakibara S, et al. *Preoperative MR angiography for free fibula osteocutaneous flap transfer*. Microsurgery 2013;33:454-9.
- <sup>26</sup> Tarsitano A, Pizzigallo A, Sgarzani R, et al. *Head and neck cancer in elderly patients: is microsurgical free-tissue transfer a safe procedure?* Acta Otorhinolaryngol Ital 2012;32:371-5.
- <sup>27</sup> Colletti G, Autelitano L, Tewfik K, et al. *Autonomized flaps in secondary head and neck reconstructions*. Acta Otorhinolaryngol Ital 2012;32:329-35.
- <sup>28</sup> Autelitano L, Colletti G, Bazzacchi R, et al. *Ossification of vascular pedicle in fibular free flaps: a report of four cases*. Int J Oral Maxillofac Surg 2008;37:669-71.
- <sup>29</sup> Trignano E, Fallico N, Faenza M, et al. *Free fibular flap with periosteal excess for mandibular reconstruction*. Microsurgery 2013, Aug 14 [Epub ahead of print].
- <sup>30</sup> Marchetti C, Bianchi A, Mazzoni S, et al. *Oromandibular reconstruction using a fibula osteocutaneous free flap: four different "preplating" techniques*. Plast Reconstr Surg 2006;118:643-51.
- <sup>31</sup> Stirling Craig E, Yuhasz M, Shah A, et al. *Simulated surgery and cutting guides enhance spatial positioning in free fibular mandibular reconstruction*. Microsurgery 2014, Jan 28 [Epub ahead of print].
- <sup>32</sup> Coppen C, Weijs W, Bergé SJ, et al. *Oromandibular reconstruction using 3D planned triple template method*. J Oral Maxillofac Surg 2013;71:e243-7.
- <sup>33</sup> Nazerani S, Behnia H, Motamedi MH. *Experience with the prefabricated free fibula flap for reconstruction of maxillary and mandibular defects*. J Oral Maxillofac Surg 2008;66:260-4.
- <sup>34</sup> Biglioli F, Colletti G. *Mini-retromandibular approach to condylar fractures*. J Craniomaxillofac Surg 2008;36:378-83.
- <sup>35</sup> Biglioli F, Colletti G. *Transmasseter approach to condylar fractures by mini-retromandibular access*. J Oral Maxillofac Surg 2009;67:2418-24.
- <sup>36</sup> Pellini R, Mercante G, Spriano G. *Step-by-step mandibular reconstruction with free fibula flap modeling*. Acta Otorhinolaryngol Ital 2012;32:405-9.

Received: February 4, 2014 - Accepted: October 6, 2014

Address for correspondence: Giacomo Colletti, University of Milano, Department of Maxillo-Facial Surgery, "San Paolo" Hospital, via di Rudinì 8, 20140 Milano, Italy. Tel. +39 02 81844594. Fax +39 02 81844704. E-mail: giacomo.colletti@gmail.com