

CLINICAL TECHNIQUES AND TECHNOLOGY

# Repositioning template for mandibular reconstruction with fibular free flaps: an alternative technique to pre-plating and virtual surgical planning

*Dima di riposizionamento per ricostruzione mandibolare con lembo libero di fibula: tecnica alternativa al pre-plating e alla programmazione chirurgica virtuale*

M. BERRONE<sup>1</sup>, E. CROSETTI<sup>2</sup>, G. SUCCO<sup>3</sup>

<sup>1</sup> Dept. of Oncology, University of Turin, Resident, PhD program in Experimental Medicine and Therapy, San Luigi Gonzaga Hospital, Orbassano, Turin, Italy; <sup>2</sup> Dept. of Oncology, University of Turin, ENT Dept., Martini Hospital, Turin, Italy; <sup>3</sup> Dept. of Oncology, University of Turin, ENT University Unit, San Luigi Gonzaga Hospital, Orbassano, Turin, Italy

## SUMMARY

Oral malignancies involving the mandibular bone require a complex reconstructive plan. Mandibular reconstruction with a fibular free flap is currently considered the best choice for functional and aesthetic rehabilitation after oncological surgery. This flap can be modelled with multiple osteotomies and can provide bone, muscle and skin for composite reconstruction. One of the most delicate aspects of mandibular reconstruction is the technique of bone modelling; the risk of prolonging the period of ischaemia and not restoring the correct maxillo-mandibular and occlusal relationships can ultimately lead to a higher rate of complications as well as poor aesthetic and functional results. Recently, there has been rising interest in virtual surgical planning and computer-assisted mandibular reconstruction in pre-operative planning; however, this is not always possible because of the costs involved and the set-up time for the entire procedure. In this paper, we present a simple and inexpensive technique for fibular free flap modelling and repositioning after segmental resection of the mandible; the technique entails the pre-operative preparation of a resin repositioning template on a stereolithographic model. This technique has been successfully applied in four cases: two cases underwent resection involving only the mandibular body, one case involving the mandibular body and symphysis and one case in which a ramus to ramus resection was performed. In this preliminary report, we show that the resin repositioning template is an easy, safe and useful tool for mandibular reconstruction with a fibular free flap.

**KEY WORDS:** Mandibulectomy • Mandibular reconstruction • Oral cavity reconstruction • Reconstruction plates

## RIASSUNTO

*I tumori maligni del cavo orale che coinvolgono l'osso mandibolare necessitano di una programmazione ricostruttiva complessa. A oggi la ricostruzione mandibolare con lembo libero di perone è considerata la miglior scelta per la riabilitazione funzionale ed estetica dopo chirurgia resettiva. Questo lembo può essere modellato mediante osteotomie multiple, e può fornire osso, muscolo e cute per ricostruzioni composite. Uno dei punti più delicati della ricostruzione mandibolare è la tecnica della modellazione ossea, il rischio di prolungare il periodo di ischemia, il mancato ripristino di corretti rapporti occlusali e maxillo-mandibolari può portare ad un più alto tasso di complicanze e scarsi risultati estetici e funzionali. Recentemente c'è stato un crescente interesse nella pianificazione chirurgica virtuale e nella ricostruzione mandibolare computer assistita per la pianificazione preoperatoria, ma non è sempre possibile effettuare tale opzione sia per i costi che per il tempo di organizzazione di tutta la procedura. In questo articolo presentiamo una tecnica semplice e conveniente per la modellazione del lembo libero di perone e per il riposizionamento dei segmenti mandibolari nativi dopo la resezione della mandibola; la tecnica prevede la preparazione pre-operatoria di una guida in resina di riposizionamento preparata su modello stereolitografico. Questa tecnica è stata applicata con successo in 4 casi. Due casi sottoposti a resezione del corpo mandibolare, 1 caso di resezione corpo mandibolare e sinfisi ed 1 caso in cui è stata eseguita una resezione da ramo a ramo. In questo rapporto preliminare si dimostra che la guida di riposizionamento in resina è un metodo utile, semplice e sicuro, applicabile con successo per la ricostruzione mandibolare con lembo libero di fibula.*

**PAROLE CHIAVE:** Mandibulectomia • Ricostruzione mandibolare • Ricostruzione cavità orale • Placche da ricostruzione

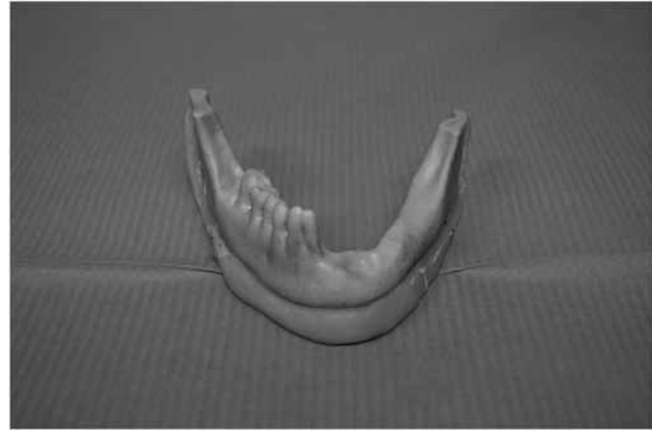
Acta Otorhinolaryngol 2014;34:278-282

## Introduction

Adequate assessment of the mandible for invasion by primary tumours of the oral cavity is crucial to accurate surgical treatment planning. Mandibular reconstruction with a fibular free flap (FFF) is currently considered the best choice for functional and aesthetic rehabilitation after oncological surgery. Particularly in extended bone and soft tissue resections, this flap can be modelled with multiple osteotomies and can provide bone, muscle and skin for composite reconstruction<sup>1</sup>; this can be considered a safe surgical procedure even in elderly head and neck cancer patients<sup>2</sup>. One of the most delicate aspects of these reconstructions is the technique of bone modelling; the non-linear nature of the mandible and need for accurate repositioning of the mandibular segment may negatively affect the final condylar position as well as the maxillo-mandibular and occlusal relationships. At present, the most popular method used to restore correct mandibular segment positioning is the technique of pre-plating. In the literature, many techniques have been described for pre-plating<sup>3</sup>, including an interesting one recently reported by Pellini et al. to improve the final outcome in mandibular reconstruction<sup>4</sup>. Furthermore, the introduction of computer-assisted mandibular reconstruction (CAMR) with the pivotal role of virtual surgical planning has increased the accuracy of the pre-operative plan, which leads to greater precision of the surgical procedure and a reduction of surgical time, especially in complex mandibular reconstruction<sup>6</sup>. However, is not always possible to carry out virtual surgical planning for mandibular reconstruction because of the costs involved and the set-up time for the entire procedure. Herein, we present a simple and inexpensive technique for non-tooth bearing mandibular segment repositioning after mandible segmental resection and manually pre-bending the titanium plate used in reconstruction.

## Clinical technique

The technique utilises a 64-slice high resolution CT scan of the patient's craniofacial skeleton. The Dicom data are sent to the modelling company and 3 to 4 days later a stereolithographic model (SM) is available in the Department; the model is used to produce a resin mandibular repositioning template (RT) (Fig. 1), and to pre-bend the titanium reconstruction plate. The RT is produced with acrylic resin contouring the inferior mandibular profile of the SM so as not to obstruct the correct positioning of the reconstruction plate; the template's size is a function of the programmed resection. Normally, to obtain good stability of the non-tooth bearing mandibular segments, the ideal length is from the posterior border of the ramus to the contralateral body; when a body to body resection is required, the length of the RT must be from the posterior border of the ramus to the posterior border of the contralateral one. Both the bone resection and the final fibula position can be programmed on the SM as well as the pos-

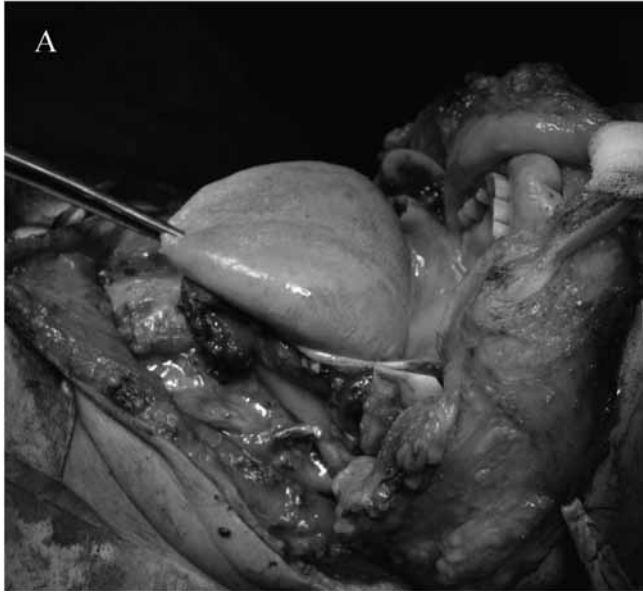

**Fig. 1.** Mandibular stereolithographic model and resin repositioning template. Notice the left mandibular bony defect as a result of the tumour.

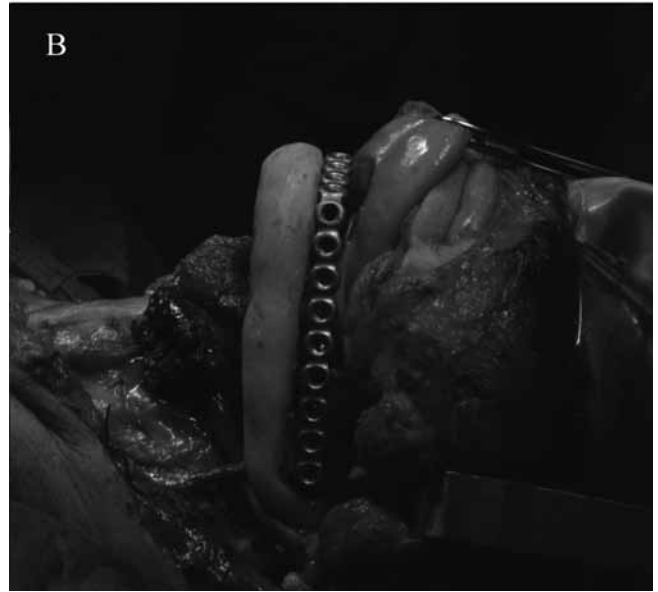
sible choice of 45° oblique osteotomies towards the inner mandible; this allows about 1 cm of additional radicality to be gained on the side of the tumour with an increase in the contact area of about 35.3% compared to a traditional 90° cut, as demonstrated by Haddock et al.

The RT contains oriented screw holes that are useful for good fixation and perfect template-bone contact. The RT is then sterilised with STERRAD® to avoid volumetric changes of the acrylic resin. After RT construction, the stereolithographic model is cut simulating the ablative surgery, the two mandibular segments are then fixed to the RT and a resin simulation of the fibular reconstructive plan is made; the reconstructive plate is then manually pre-bent on this model. Simulation of fibular segments is always carried out with an average segment length greater than 2 cm. Segment positioning must be programmed in the optimum location for future implant supported dental rehabilitation because dental rehabilitation with osseointegrated implants is an integral part of mandibular reconstruction following ablative surgery.

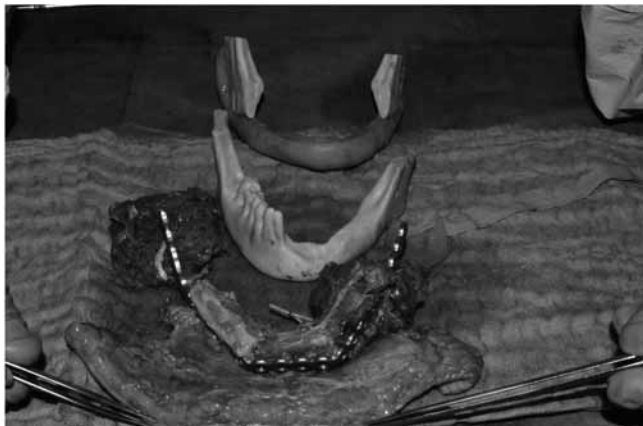In oral malignancies, after ablative surgery (Fig. 2A) and after the results of frozen sections of the mandibular periosteum, bone marrow and soft tissues are assessed to check radicality, and the mandibular RT is secured with four screws to the inferior border of the mandible and posterior profile of the mandibular ramus; after RT positioning, the pre-bent reconstruction plate is secured on the mandible to locate the screw holes in the correct position and draw the precise points of contact on the plate between the bone segments (Fig. 2B); at the same time, the lengths of the fibular segments necessary for reconstruction are calculated accurately. The RT and the reconstruction plate are then removed, and the fibular segments are modelled and fixed to the reconstruction plate (Fig. 3). Finally, the reconstruction complex is positioned and secured to the native mandible with excellent precision in bone to bone contact (Fig. 4). At the end of the macroscopic procedure, microvascular anastomoses are performed.



**Fig. 2a.** Intraoperative view after ablative surgery.



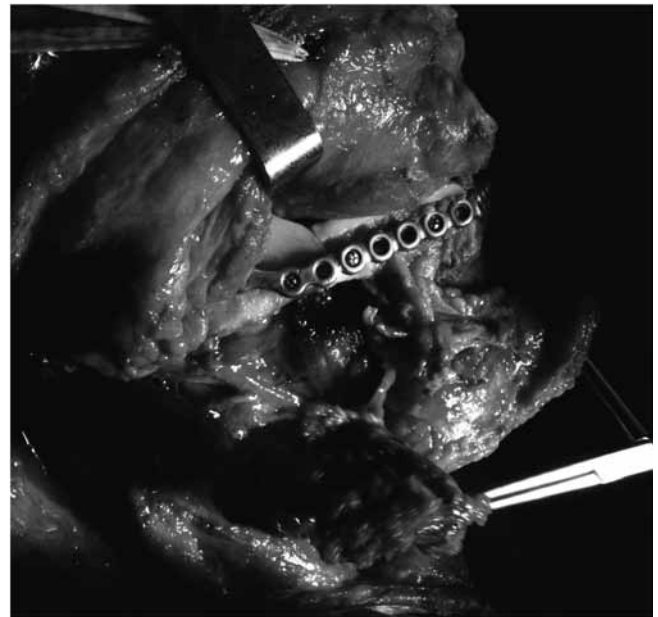
**Fig. 2b.** Repositioning template and reconstructive plate fixed on the remaining mandible.



**Fig. 3.** Osteofascial-myocutaneous fibular flap modelled, adapted and fixed on the reconstructive plate.

## Discussion

The pre-operative demographic data for four patients undergoing FFF reconstruction using RT are summarised in Table I. All patients were managed primarily with surgical resection of malignant disease involving the body and/or the symphysis of the mandible. Segmental mandibulectomy and fibular osteotomies were performed with or without cutting guides. In all patients, the surgical margins (soft tissues and bones) were tumour free. Mandibular defects ranged from 4.543 cm to 10.123 cm with an average of 7.446 cm and were categorised following Urken's classification for mandibular bone defects. In two cases, one fibular segment was used to create the neo-mandible while in one case, two segments, and in one case, three segments were used. Ischaemia time was recorded in all four cases, with an average of



**Fig. 4.** Flap and plate fixed on the mandible. Notice the optimal bone to bone contact between native bone and fibula.

$84 \pm 20$  min. There were no problems during any surgical step. A high precision in reconstruction and a good fit of the pre-bent plate were found intraoperatively both on the mandible and the fibula. Excellent precision in bone to bone contact (Fig. 4) and position between mandible and fibula graft was also noticed. There were no major complications and the average post-operative hospital stay was  $18 \pm 3$  days. In all four patients, we found a satisfying final aesthetic result with good oral function. A pre-operative programme is crucial for mandibular reconstruction to obtain the best functional and aesthetic

**Table I.** Pre-operative demographic data for four patients undergoing FFF reconstruction.

Sex	Age	Pathol	UC	RES. cm	No. SEG.
Female	45	SCC	B	7.834	1
Female	69	SCC	BSB	10.123	3
Female	61	SCC	B	4.543	1
Male	67	SCC	BS	7.287	2

Pathol: pathology; SCC: squamous cell carcinoma.

UC: Urken classification of mandibular defects; B-body, S-symphysis.

RES. cm: length of mandibular resection (cm).

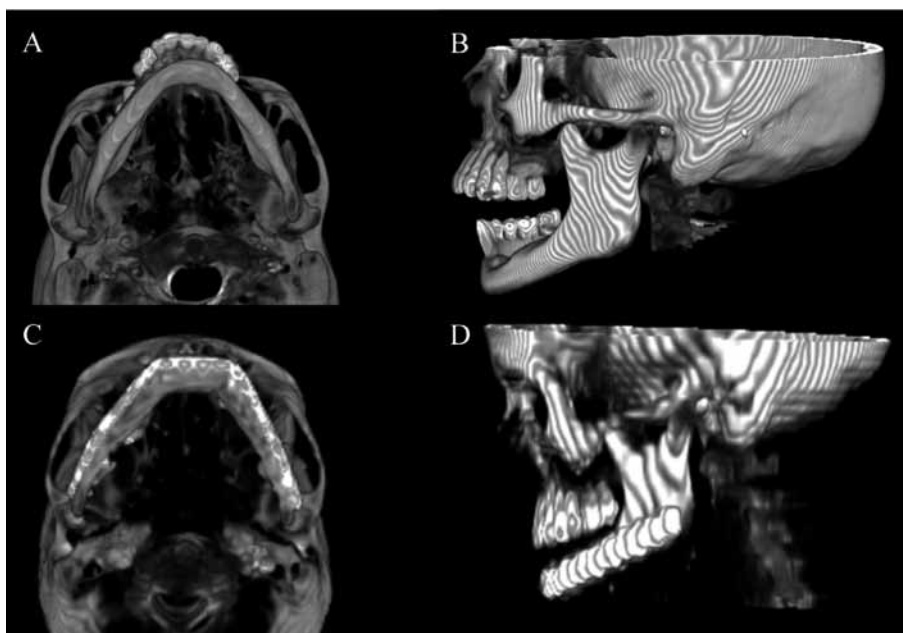
No. SEG.: number of fibular segments used for mandibular reconstruction.

outcome. Planning for implantation begins before surgical resection. A careful pre-operative programme permits a reduction in surgical time and is instructive in teaching the principles of bone reconstruction. In mandibular reconstruction with FFF all the surgical steps are important, but fibular modelling and final inseting play a key role in the final outcome. When pre-plating is not correctly performed, or not performed at all, the best outcome may not be obtained. The introduction of a SM, both of the mandible and of the fibula, has made preoperative plate pre-bending and osteotomy planning possible for fibular modelling<sup>7</sup>; this has resulted in a positive impact on the accuracy of the reconstruction and a reduction in surgical times. Ablative and reconstructive teams can work simultaneously following a programme previously agreed between all interested specialists. Thanks to very accurate inseting, the aesthetic (mandibular edge and contour of the lower third of the face) and

functional outcomes (condylar position not altered) are guaranteed as also demonstrated by the comparison between pre-operative and post-operative CT scan (Fig. 5). As a rule, pre-plating with a mandibular reconstruction plate is carried out on the outer cortex of the mandible, not directly affected by the tumour and with unaltered profile. In this case, in addition to acting as a guide, pre-plating will represent the final plate after resection. In the case of outer cortex involvement, pre-plating must be made on the lower border of the mandible as described by Pellini et al.<sup>4</sup>, but a second plate is required for the final reconstruction.

Despite the limited number of cases treated, only four, some preliminary conclusions can be drawn. The resin RT reproduces pre-plating placed under the lower contour of the mandible, saving the cost of a second reconstruction plate and also allowing ablative surgery to take place completely independently of the reconstructive team. In fact, the RT is performed on the SM but the extent of the resection is decided directly during surgery and checked with frozen sections. It is not necessary to use a second titanium plate, and the technique can also save time during surgery since it is prepared preoperatively. Moreover, when considering costs, the technique is competitive compared with inferior border pre-plating. The cost of the stereolithographic model and repositioning template is about € 300 in comparison to a titanium plate which costs about € 600.

The disadvantages are related to the material, which is not sterile when provided and therefore must be sterilised in STERRAD®, and the timing for completion of the project, which is about 4 to 5 days. In our experience, this technique has proven particularly effective for mandibular reconstruction when the tumour invades the outer cortex and modifies the mandibular contour. The usefulness of the SM and RT was also demonstrated in teaching, as the RT is normally prepared by residents and surgeons with less experience in reconstructive surgery. Moreover, this technique is totally independent of resection criteria, and is safer and more inexpensive than other techniques. In our experience, it is a viable alternative for repositioning of mandibular non-tooth bearing segments. Further investigations should be carried out on the application of this technique, and a comparative study with other pre-plating techniques is required to validate this procedure.



**Fig. 5.** a) Pre-operative CT scan inferior view. b) Pre-operative CT scan lateral view. c) Post-operative CT scan inferior view. d) Post-operative CT scan lateral view.



## References

- <sup>1</sup> Kannan RY, Mathur BS, Tzafetta K. *Single flap reconstruction for complex oro-facial defects using chimeric free fibular flap variants*. J Plast Reconstr Aesthet Surg 2013;66:358-63.
- <sup>2</sup> Tarsitano A, Pizzigallo A, Sgarzani R, et al. *Head and neck cancer in elderly patients: is microsurgical free-tissue transfer a safe procedure?* Acta Otorhinolaryngol Ital 2012;32:371-5.
- <sup>3</sup> Marchetti C, Bianchi A, Mazzoni S, et al. *Oromandibular reconstruction using a fibula osteocutaneous free flap: four different "preplating" techniques*. Plast Reconstr Surg 2006;118:643-51.
- <sup>4</sup> Pellini R, Mercante G, Spriano G. *Step-by-step mandibular reconstruction with free fibula flap modeling*. Acta Otorhinolaryngol Ital 2012;32:405-9.
- <sup>5</sup> Roser SM, Ramachandra S, Blair H, et al. *The accuracy of virtual surgical planning in free fibula mandibular reconstruction: Comparison of planned and final results*. J Oral Maxillofac Surg 2010;68:2824-32.
- <sup>6</sup> Succo G, Berrone M, Battistoni B, et al. *Step-by-step surgical technique for mandibular reconstruction with fibular free flap: application of digital technology in virtual surgical planning*. Eur Arch Otorhinolaryngol 2014; May 10. DOI 10.1007/500405-014-3078-3
- <sup>7</sup> Ro EY, Ridge JA, Topham NS. *Using stereolithographic models to plan mandibular reconstruction for advanced oral cavity cancer*. Laryngoscope 2007;117:759-61.

Received: December 23, 2013 - Accepted: March 18, 2014