

Otorhinolaryngologica Italica

Volume 34

3

June 2014

*Official Journal of the Italian Society of Otorhinology
Head and Neck Surgery*

Organo Ufficiale della Società Italiana di Otorinolaringologia
e Chirurgia Cervico-Facciale

Reviews

Results of endoscopic middle ear surgery for cholesteatoma treatment:
a systematic review

OSAS and metabolic diseases:
Round Table, 99th SIO National Congress, Bari 2012

Head and neck

Combined chemoradiotherapy with local microwave hyperthermia for treatment
of T3N0 laryngeal carcinoma: a retrospective study with long-term follow-up

Laryngology

Direct autofluorescence during CO₂ laser surgery of the larynx:
can it really help the surgeon?

Otology

Closure of the sigmoid sinus in lateral skull base surgery

Vestibology

Anterior canal BPPV and apogeotropic posterior canal BPPV:
two rare forms of vertical canalolithiasis

Basic research in otolaryngology

The effect of the NMDA channel blocker memantine
on salicylate-induced tinnitus in rats

Rhinology

Endoscopic ultrasonic curette-assisted removal of frontal osteomas

Letter to the Editor

The role of cricothyroidopiglotomy in the era
of transoral laser surgery and radio/chemotherapy

Medico-legal cases

Current trends for medico-legal disputes related
to functional nasal surgery in Italy

Case report

Papillary carcinoma on a thyroglossal duct cyst:
diagnostic problems and therapeutic dilemma. A case report

PACINI
EDITORE
MEDICINA

www.actaitalica.it



ACTA

Otorhinolaryngologica Italica

Official Journal of the Italian Society of Otorhinolaryngology - Head and Neck Surgery
Organo Ufficiale della Società Italiana di Otorinolaringologia e Chirurgia Cervico-Facciale

Former Editors-in-Chief: C. Calearo†, E. de Campora, A. Staffieri, M. Piemonte, F. Chiesa

Editorial Board

Editor-in-Chief:

G. Paludetti

President of S.I.O.:

A. Serra

*Former Presidents of S.I.O.
and Editors-in-Chief:*

I. De Vincentiis, D. Felisati, L. Coppo,
G. Zaoli, P. Miani, G. Motta,
L. Marcucci, A. Ottaviani,
P. Puxeddu, M. Maurizi, G. Sperati,
D. Passali, E. de Campora, A. Sartoris,
P. Laudadio, M. De Benedetto,
S. Conticello, D. Casolino,
A. Rinaldi Ceroni, M. Piemonte,
A. Staffieri, F. Chiesa, R. Fiorella,
A. Camaioni

Editorial Staff

Editor-in-Chief:

G. Paludetti

Deputy Editor:

J. Galli

Associate Editors:

G. Almadori, F. Ottaviani

Editorial Coordinator:

E. De Corso

Editorial Assistant:

P. Moore

Treasurer:

L. de Campora

Italian Scientific Board

L. Bellussi, G. Danesi, C. Grandi,

A. Martini, L. Pignataro, F. Raso,

R. Speciale, I. Tasca

International Scientific Board

J. Betka, P. Clement, M. Halmagyi,

L.P. Kowalski, M. Pais Clemente,

J. Shah, H. Stammberger, R. Laszig,

G. O'Donoghue, R.J. Salvi, R. Leemans,

M. Remacle, F. Marshal, H.P. Zenner

Editorial Office

Editor-in-Chief:

G. Paludetti

Department of Head and Neck Surgery -
Otorhinolaryngology

Catholic University of the Sacred Heart

“A. Gemelli” Hospital

L.go F. Vito, 1 - 00168 Rome, Italy

Tel. +39 06 30154439

Fax + 39 06 3051194

actaitalicaorl@rm.unicatt.it

Editorial Coordinator:

E. De Corso

eugenio.decorso@rm.unicatt.it

Editorial Secretary:

R. Gallus

gallusroberto@gmail.com

Argomenti di Acta

Otorhinolaryngologica Italica

Editor-in-Chief: G. Paludetti

Editorial Coordinator: M.R. Marchese

raffaellamarchese@gmail.com

© Copyright 2014 by

Società Italiana di Otorinolaringologia

e Chirurgia Cervico-Facciale

Via Luigi Pigorini, 6/3

00162 Rome, Italy

Publisher

Pacini Editore SpA

Via Gherardesca, 1

56121 Pisa, Italy

Tel. +39 050 313011

Fax +39 050 3130300

info@pacinieditore.it

www.pacini medicina.it

*Acta Otorhinolaryngologica Italica is cited
in Index Medicus, MEDLINE, PubMed
Central, Science Citation Index Expanded,
Scopus, DOAJ, Open-J Gate, Free Medical
Journals, Index Copernicus, Socolar*

Journal Citation Reports:

Impact Factor 0.786

*Acta Otorhinolaryngologica Italica is
available on Google Scholar*

PACINI
EDITORE
MEDICINA

www.actaitalica.it



Contents

Reviews

Results of endoscopic middle ear surgery for cholesteatoma treatment: a systematic review

Risultati della chirurgia endoscopica dell'orecchio medio per il trattamento del colesteatoma: una revisione sistematica

L. Presutti, F.M. Gioacchini, M. Alicandri-Ciufelli, D. Villari, D. Marchioni pag. 153

OSAS and metabolic diseases: Round Table, 99th SIO National Congress, Bari 2012

OSAS e patologie metaboliche: Tavola Rotonda, 99° Congresso Nazionale SIO, Bari 2012

D. Passàli, P. Tatti, M. Toraldo, M. De Benedetto, F. Peverini, G. Caruso, A. Marzetti, F.M. Passàli, L. Bellussi » 158

Head and neck

Combined chemoradiotherapy with local microwave hyperthermia for treatment of T3N0 laryngeal carcinoma: a retrospective study with long-term follow-up

Trattamento radiochemioterapico combinato con l'ipertermia locale a microonde nel trattamento dei carcinomi laringei T3N0: studio retrospettivo e follow-up a lungo termine

V. Kouloulas, S. Triantopoulou, J. Vrouvas, K. Gennatas, N. Ouzounoglou, J. Kouvaris, P. Karaiskos, P. Aggelakis, C. Antypas, A. Zygogianni, K. Papavasiliou, K. Platoni, N. Kelekis » 167

Laryngology

Direct autofluorescence during CO₂ laser surgery of the larynx: can it really help the surgeon?

Autofluorescenza diretta in corso di laserchirurgia transorale con laser CO₂: un reale aiuto per il chirurgo?

G. Succo, P. Garofalo, M. Fantini, V. Monticone, G.C. Abbona, E. Crosetti » 174

Otology

Closure of the sigmoid sinus in lateral skull base surgery

Chiusura del seno sigmoide nella chirurgia della base cranio laterale

E. Zanoletti, D. Cazzador, C. Faccioli, A. Martini, A. Mazzoni » 184

Vestibology

Anterior canal BPPV and apogeotropic posterior canal BPPV: two rare forms of vertical canalolithiasis

Vertigine parossistica posizionale benigna da canalolithiasi anteriore e da canalolithiasi posteriore apogeotropica: due rare forme di canalolithiasi verticale

L. Califano, F. Salafia, S. Mazzone, M.G. Melillo, M. Califano » 189

Basic research in otolaryngology

The effect of the NMDA channel blocker memantine on salicylate-induced tinnitus in rats

Effetti della memantina, antagonista non competitivo dei recettori NMDA, sull'acufene indotto da salicilato nel ratto

M. Ralli, D. Troiani, M.V. Podda, F. Paciello, S.L.M. Eramo, E. De Corso, R. Salvi, G. Paludetti, A.R. Fetoni » 198

Rhinology

Endoscopic ultrasonic curette-assisted removal of frontal osteomas

Curette per l'osso ad ultrasuoni per la rimozione degli osteomi del frontale

A. Bolzoni Villaret, A. Schreiber, I. Esposito, P. Nicolai » 205

Letter to the Editor

The role of cricothyroidotomy in the era of transoral laser surgery and radio/chemotherapy

Il ruolo della cricoideopiglottopessia nell'era della chirurgia laser transorale e della radio/chemioterapia

A. De Virgilio, A. Greco, M. De Vincentiis » 209

Medico-legal cases

Current trends for medico-legal disputes related to functional nasal surgery in Italy

Attuali tendenze medico-legali in Italia relative alla chirurgia funzionale nasale

S. Motta, S. Nappi » 210

Case report

Papillary carcinoma on a thyroglossal duct cyst: diagnostic problems and therapeutic dilemma. A case report

Un raro caso di carcinoma papillare insorto su cisti del dotto tireoglossale: problematiche diagnostiche e dilemmi terapeutici

G. Proia, M.F. Bianciardi Valassina, G. Palmieri, M. Zama » 215

Calendar of events - Italian and International Meetings and Courses » 218

Information for authors including editorial standards for the preparation of manuscripts
available on-line: www.actaitalica.it

REVIEW

Results of endoscopic middle ear surgery for cholesteatoma treatment: a systematic review

Risultati della chirurgia endoscopica dell'orecchio medio per il trattamento del colesteatoma: una revisione sistematica

L. PRESUTTI, F.M. GIOACCHINI, M. ALICANDRI-CIUFELLI, D. VILLARI, D. MARCHIONI

Otolaryngology-Head and Neck Surgery Department, University Hospital of Modena, Modena, Italy

SUMMARY

Traditional surgery for cholesteatoma of the middle ear is performed by microscopic approaches. However, in recent years endoscopic instrumentation, techniques and knowledge have greatly improved, and in our opinion endoscopic surgical techniques will gain increasing importance in otologic surgery in the future. The aim of this study was to focus on outcomes obtained using endoscopic surgery for the treatment of middle ear cholesteatoma. A systematic review of the literature was performed. A total of 7 articles comprising 515 patients treated exclusively with endoscope or with a combined technique were found. During post-surgical follow-up, 48 (9.3%) patients showed a residual or recurrent pathology. Despite the small number of patients analyzed in our review, the outcomes of this technique appear to be promising. In particular, concerning the rates of recurrences and residual disease, endoscopic middle ear surgery appears to guarantee similar results in comparison to classic microscopic approaches with the advantage of performing minimally invasive surgery.

KEY WORDS: Cholesteatoma • Endoscopic ear surgery • Recurrence • Residual

RIASSUNTO

La chirurgia tradizionale per il colesteatoma dell'orecchio medio è praticata mediante approcci microscopici. Comunque durante gli anni più recenti la strumentazione endoscopica, le tecniche, e la coscienza sono nettamente migliorate, e secondo il nostro parere in futuro, le tecniche di chirurgia endoscopica acquisiranno importanza nella otocirurgia. L'obiettivo di questo studio è stato quello di focalizzare i risultati ottenuti mediante l'uso della chirurgia endoscopica nel trattamento del colesteatoma dell'orecchio medio. È stata eseguita una revisione sistematica della letteratura. Sono stati trovati un totale di sette articoli che comprendevano 515 pazienti trattati esclusivamente con l'endoscopia o con una tecnica combinata. Complessivamente durante il follow-up post chirurgico, 48 (9,3%) pazienti hanno mostrato una recidiva o un residuo di malattia. Nonostante il piccolo numero di pazienti analizzati nella nostra revisione, i risultati di questa tecnica sembrano essere promettenti. In particolare, riguardo alle percentuali di recidive e residui di malattia, la chirurgia endoscopica dell'orecchio medio sembra garantire risultati simili a confronto di quelli ottenuti con i classici approcci microscopici avendo però anche il grande vantaggio di poter eseguire una chirurgia mini invasiva.

PAROLE CHIAVE: Colesteatoma • Chirurgia endoscopica • Recidiva • Residuo

Acta Otorhinolaryngol Ital 2014;34:153-157

Introduction

Surgical management of cholesteatoma is still a controversial issue. Classic concepts are based on microscopic surgical management, as is the traditional classification of open tympanoplasties-canal wall down (CWD) and closed tympanoplasties-canal wall up (CWU), depending on the preservation of the posterior ear canal wall. The choice between these two techniques is based on a number of factors, although in most cases, the main factors influencing the definitive attitude toward surgical management of cholesteatoma are experience, personal beliefs and confidence of each surgeon with each technique.

Starting in the 1990s, operative endoscopy was introduced in otologic surgery ¹, and significantly changed not only

surgical concepts ² but also anatomic and physiologic concepts ³, and has become increasingly popular during the last 15 years.

Since the introduction of this instrument, the concept of a minimally invasive approach in middle ear surgery is changing. Endoscopic middle ear surgery can offer some advantages compared to the traditional microscopic technique, guaranteeing excellent visualization of mesotympanic structures and direct visual control of hidden areas such as anterior epitympanic spaces, retrotympanum and protympanum.

Nonetheless, when a new technique is introduced, evaluation of results is essential to its acceptance by the scientific community. The aim of present paper was to

perform a systematic literature review, which may help to better understand the results associated with endoscopic techniques (both used exclusively and in combination with microscopic approaches) in treatment of cholesteatoma.

Materials and methods

Search strategy

This systematic review sought to answer the question: is endoscopic ear surgery effective in treatment of middle ear cholesteatoma? A structured search of the literature was performed on PUBMED with the following search terms: “middle ear cholesteatoma” and “endoscopic ear surgery”.

After running the above-search terms, abstracts and titles were obtained. The titles and abstracts of the search results were screened and articles eligible for further review were identified.

Inclusion criteria for abstracts were:

- article describing the results of endoscopic ear surgery (alone or in association with the operating microscope) for treatment of middle ear cholesteatoma;
- English language;
- original papers.

Exclusion criteria for abstracts were:

- clearly unrelated pathologies of the ear;
- no original analysis (e.g. reviews) or animal or other basic science laboratory studies.

The full texts of the articles identified were obtained for a second screening, in order to select studies for inclusion.

Inclusion criteria for full-text articles identified were:

- diagnosis of middle ear cholesteatoma;
- use of endoscopic middle ear surgery alone or combined with microscopic techniques;

Exclusion criteria for full-text articles identified were:

- lack of definitive diagnosis of cholesteatoma;
- lack of sufficient clinical data;
- redundant cohorts of patients that were already reported by the same authors.

A further manual check was performed on the references included within articles. The final number of articles included in the present review was identified, and the main information was extracted and summarized.

Results

Running the above-search string in PubMed, 72 articles were identified. After an initial check, full-text retrieval and manual cross-checking of references included within the articles, 7 studies, published between 2002 and 2013 (comprising a total of 515 patients and 517 surgeries overall) clearly met inclusion criteria and were chosen for the analysis (Table I).

All articles analyzed only patients suffering from middle ear cholesteatoma with no history of previous ear surgeries. The disease status at last control was available in all patients, and the mean follow time was 23.4 months (range, 11-43 months). Analyzing the articles chosen for our review, it can be noted that three authors (Tarabichi, Migirov and Barakate) exclusively performed transcanal endoscopic surgeries, while in the other five reports a combined technique was also applied if necessary.

Table I. Main characteristics of the selected studies.

Authors	Year	N. patients	Mean age	Type of surgery		Residual	Recurrence	Mean follow-up (months)
				Exclusive endoscopic transcanal TPL	Microscopic TPL assisted by endoscopy			
Ayache et al. ²³	2008	80	N/A	0	80	11	N/A	17
Marchioni et al. ²²	2013	146	N/A	120	26	7	4	31
Badr-El-Dine ²⁴	2002	92	N/A	0	92	2	3	11
Tarabichi ⁷	2004	69	N/A (4-51)	69	0	0	5	43
Migirov et al. ²⁵	2011	30	N/A	30	0	0	0	12
Barakate and Bottrill ²⁶	2008	66	18 (5-63)	68*	0	10	4	16
Presutti et al. ²⁷	2008	32	34	6	26	2	0	34
Total N.		515		293	224	32	16	

N/A: not available; TPL: tympanoplasty; *68 operations performed on 66 patients.

Overall, exclusive endoscopic management of the pathology was obtained in 293 (57%) cases, while 224 (43%) operations were performed with a combined technique.

During the follow-up period, a total of 48 patients showed residual pathology: in particular, 32 patients had residual disease, while 16 patients presented with a recurrence of cholesteatoma.

Discussion

The exposure and visualization of the entire middle ear space are sometimes difficult using only microscopic vision. With recent advances in minimally-invasive surgery, the use of the endoscope has led to new treatment options for middle ear pathologies^{4,5}. Moreover, the anatomy of the middle ear is particularly complex and an endoscopic approach represents an improvement with regard to the anatomic concepts of this region because it guarantees round-the-corner views of hidden areas such as the sinus tympani, facial recess, anterior epitympanic spaces, attic, hypotympanum and protympanum⁶. Cholesteatoma surgery primarily aims to eradicate the disease process and provide the patient with a safe and dry ear. The main problems regarding attic cholesteatoma removal are residual and recurrence. The former is due to insufficient primary resection of the epidermal matrix, and classically presents a pearl-like aspect. Insufficient resection may be due to a very fine epidermal matrix or middle-ear inflammation, in addition to limited exposition of hidden areas such as the epitympanic space and sovratubal recess. Actually, the view during microscopic surgery is defined and limited by the narrowest segment of the ear canal; this basic limitation has forced surgeons to create a parallel port through the mastoid to gain keyhole access to the attic. Despite the illumination and magnification offered by the operating microscope, it has distinct limitations.

The persistence of physiopathologic phenomena that determined cholesteatoma development, presents as a new attic retraction that requires a further surgical approach to avoid the reformation of attic cholesteatoma.

Recurrence consists in a new, dangerous tympanic retraction pocket caused by inadequate reconstruction of the scutum and tympanic loss of substance inducing persistence of the physiopathologic process of middle-ear depression.

While recurrence can be diagnosed otoscopically, residual cholesteatoma is classically independent of the eardrum and only surgical revision can determine definite diagnosis; this is the rationale of second look procedures, in addition to functional issues.

This review focuses on surgical improvements related to the mini-invasive treatment of middle ear cholesteatoma. At the moment, the main treatment options for this pathology are two basic, well-standardized microscopic surgical

procedures: canal wall-down (CWD) and the canal wall-up (CWU) mastoidectomy with tympanoplasty. Both these traditional approaches to the attic have mainly provided limited access through postauricular mastoidectomy, with many surgeons using the ear canal to access the anterior part of the attic⁷. The intact canal wall approach has traditionally been favoured for its simpler postoperative care and maintenance⁸. Moreover, by preserving the anatomy of the middle ear, the cavity is permitted to get wet and, thereby, does not limit patients in future activities⁹.

However, many surgeons have noted high rates of recurrent and residual disease using this approach, and thus advocate a staged or 'second-look' procedure that occurs months to years after the first^{10,11}. Because of these disadvantages, others prefer to remove the posterior canal in their treatment of cholesteatoma^{12,13}. This group conjectures that improved visualization of the disease and affected middle ear anatomy, including the sinus tympani and anterior attic that are the most frequent sites of residual cholesteatoma in traditional intact canal wall surgery^{14,15}, result in greater long-term disease-free states.

Although open tympanoplasty decreases the rate of recurrence, nevertheless, in our opinion, the removal of the posterior canal does not always ensure complete visualization of sinus tympani that often remain hidden from surgical view. This situation may strongly be connected with the high rate of residual disease observed after this procedure. These observations suggest that there is no single procedure to treat all cases of cholesteatoma, and that the otologic surgeon should be flexible in choosing a procedure depending on the individual case.

Literature data show that recurrent cholesteatoma is still observed in nearly 20% of CWU tympanoplasties, with an overall relapse rate of up to 70%, while open techniques are often accredited with a rate of residual disease of less than 7% and nearly no recurrent disease¹⁶.

Gaillardin et al.¹⁷ after a mean follow-up of 48 months (range, 24-96 months) found a rate of residual disease of 25% considering cholesteatomas in 113 ears operated with a closed canal wall-up tympanoplasty. Mishiro et al.¹⁸ described recurrent cholesteatoma in 19.4% of ears treated with closed tympanoplasty. Haginomori et al.¹⁹ performed 85 canal wall-down tympanoplasties and observed 18 (21%) residual cholesteatomas after 1 year at second-look. Over a follow-up period ranging from 4 to 15 years (mean follow-up, 8 years), de Zinis et al. observed only 4 (2.1%) residual cholesteatomas and no recurrent cholesteatomas among 189 ears treated with CWD tympanoplasty for cholesteatoma of the middle ear. Nevertheless, 17 patients (9.0%) developed small keratin pearls, while recurrent otorrhoea and mastoid cavity granulation tissue formation occurred in 10 cases (5.2%). Sanna et al.²⁰ evaluated 222 cases of cholesteatomas operated with their modified Bondy's technique: they reported a pearl-like residual cholesteatoma in 7.4% of ears, while

no recurrence was discovered over a mean follow-up of 7.8 years (range, 5-16 years).

In their meta-analysis performed on 13 studies including a total of 4720 patients, Tomlin et al.²¹ demonstrated that, when realized as a single-stage surgery, an intact canal wall approach to cholesteatoma treatment has nearly 3 times greater likelihood of recurrence than a canal wall down surgery.

In general, only 2 of the studies reported no significant differences between the two techniques, while 11 of the 13 data sets statistically favoured the canal wall down approach. However, the rate of cholesteatoma recurrence depends not only on the follow-up period, surgical methods and surgical techniques, but also in the methods used for statistical analysis. For this reason, Mishiro et al.¹⁸ analyzed the recurrence rate of cholesteatoma after 345 interventions of tympanoplasty (n = 113, CWD; n = 232, CWU) using Kaplan-Meier survival analysis. After a mean follow-up period of 5 years, the recurrence rate (comprising residual and recurrent cholesteatomas) was 11.8% although the authors underlined how the follow-up rates of patients decreased during the time after surgery (93.3% after 1 years, 78.3% after 3 years, 70.1% after 5 years).

In our opinion, this observation represents an important point of view that authors should always keep in mind to obtain a more correct analysis of surgical outcomes. In fact, the data of many reports may be affected/alterd by the number of patients who dropped out from clinical follow-up.

Regarding the data in our review, the high rate of exclusive endoscopic transcanal procedures performed (57%) should be noted in comparison of the lower rate of combined approaches requiring mastoidectomy (43%). Another point of interest is the rate of residual disease and recurrences that appear lower compared to data reported in the literature for canal wall up interventions performed exclusively by mean microscopy. These promising results seem to confirm the usefulness of the endoscope in terms of outcomes.

The main limitations related to the seven studies analyzed in our review are the short time of follow-up and the limited number of patients treated by the authors. In fact, with the exception of Tarabichi et al.⁷ there is no report showing a follow-up greater than three years, and only Marchioni et al.²² reported a cohort larger than 100 patients. In general, both these issues are closely connected with the recent introduction of endoscopic middle ear surgery that needs more time to reach a sufficient number of cases and an adequate time of follow-up.

Nevertheless, from studies analyzed in our review, the endoscope appears to allow an important reduction of unnecessary mastoidectomies in cases of cholesteatoma limited to the middle ear cavity, favouring the increase of exclusive transcanal middle ear surgeries. Moreover, in cases of pathologies involving the mastoid, endoscopic assistance may promote the choice of canal wall up proce-

dures limiting the rate of recurrences and residual disease typically associated with this approach.

Conclusions

On the basis of literature data, canal wall down tympanoplasty still remains the most effective procedure in preventing recurrent disease after a single-stage surgery. Nevertheless, because the surgical approach depends on patient preference and lifestyle factors, the maintenance of posterior ear canal should be achieved in young patients, and the endoscopic technique may represent an important tool in obtaining this aim. Our review appears to confirm the importance of this tool in middle ear surgery. Obviously further reports are still needed to confirm and integrate this initial data, increasing the number of patients and organizing an accurate follow-up method to avoid the "drop out" issues.

References

- 1 Thomassin JM, Duchon-Doris JM, Emram B, et al. *Endoscopic ear surgery. Initial evaluation*. Ann Otolaryngol Chir Cervicofac 1990;107:564-70.
- 2 Marchioni D, Alicandri-Ciufelli M, Molteni G, et al. *Ossicular chain preservation after exclusive endoscopic transcanal tympanoplasty: preliminary experience*. Otol Neurotol 2011;32:626-31.
- 3 Marchioni D, Alicandri-Ciufelli M, Molteni G, et al. *Selective epitympanic dysventilation syndrome*. Laryngoscope 2010;120:1028-33.
- 4 Marchioni D, Villari D, Alicandri-Ciufelli M, et al. *Endoscopic open technique in patients with middle ear cholesteatoma*. Eur Arch Otorhinolaryngol 2011;268:1557-63.
- 5 Marchioni D, Alicandri-Ciufelli M, Gioacchini FM, et al. *Transcanal endoscopic treatment of benign middle ear neoplasms*. Eur Arch Otorhinolaryngol 2013;270:2997-3004.
- 6 Marchioni D, Alicandri-Ciufelli M, Piccinini A, et al. *Inferior retrotympanum revisited: an endoscopic anatomic study*. Laryngoscope 2010;120:1880-6.
- 7 Tarabichi M. *Endoscopic management of limited attic cholesteatoma*. Laryngoscope 2004;114:1157-62.
- 8 Tos M, Lau T. *Hearing after surgery for cholesteatoma using various techniques*. Auris Nasus Larynx 1989;16:61-73.
- 9 Nikolopoulos TP, Gerbesiotis P. *Surgical management of cholesteatoma: the two main options and the third way - atticotomy/limited mastoidectomy*. Int J Pediatr Otorhinolaryngol 2009;73:1222-7.
- 10 Ho SY, Kveton JF. *Efficacy of the 2-staged procedure in the management of cholesteatoma*. Arch Otolaryngol Head Neck Surg 2003;129:541-5.
- 11 Syms MJ, Luxford WM. *Management of cholesteatoma: status of the canal wall*. Laryngoscope 2003;113:443-8.
- 12 Nyrop M, Bonding P. *Extensive cholesteatoma: long-term results of three surgical techniques*. J Laryngol Otol 1997;111:521-6.
- 13 Quaranta A, Cassano P, Carbonara G. *Cholesteatoma surgery:*

- open vs closed tympanoplasty.* Am J Otol 1988;9:229-31.
- 14 Hulka GF, McElveen JT Jr. *A randomized, blinded study of canal wall up versus canal wall down mastoidectomy determining the differences in viewing middle ear anatomy and pathology.* Am J Otol 1998;19:574-8.
 - 15 Palva T. *Surgical treatment of chronic middle ear disease. II. Canal wall up and canal wall down procedures.* Acta Otolaryngol 1987;104:487-94.
 - 16 de Zinis LO, Tonni D, Barezzani MG. *Single-stage canal wall-down tympanoplasty: long-term results and prognostic factors.* Ann Otol Rhinol Laryngol 2010;119:304-12.
 - 17 Gaillardin L, Lescanne E, Morinière S, et al. *Residual cholesteatoma: prevalence and location. Follow-up strategy in adults.* Eur Ann Otorhinolaryngol Head Neck Dis 2012;129:136-40.
 - 18 Mishiro Y, Sakagami M, Okumura S, et al. *Postoperative results for cholesteatoma in children.* Auris Nasus Larynx 2000;27:223-6.
 - 19 Haginomori S, Takamaki A, Nonaka R, et al. *Residual cholesteatoma: incidence and localization in canal wall down tympanoplasty with soft-wall reconstruction.* Arch Otolaryngol Head Neck Surg 2008;134:652-7.
 - 20 Sanna M, Facharzt AA, Russo A, et al. *Modified Bondy's technique: refinements of the surgical technique and long-term results.* Otol Neurotol 2009;30:64-9.
 - 21 Tomlin J, Chang D, McCutcheon B, et al. *Surgical technique and recurrence in cholesteatoma: a meta-analysis.* Audiol Neurootol 2013;18:135-42.
 - 22 Marchioni D, Villari D, Mattioli F, et al. *Endoscopic management of attic cholesteatoma: a single-institution experience.* Otolaryngol Clin North Am 2013;46:201-9.
 - 23 Ayache S, Tramier B, Strunski V. *Otoendoscopy in cholesteatoma surgery of the middle ear: what benefits can be expected?* Otol Neurotol 2008;29:1085-90.
 - 24 Badr-el-Dine M. *Value of ear endoscopy in cholesteatoma surgery.* Otol Neurotol 2002;23:631-5.
 - 25 Migirov L, Shapira Y, Horowitz Z, et al. *Exclusive endoscopic ear surgery for acquired cholesteatoma: preliminary results.* Otol Neurotol 2011;32:433-6.
 - 26 Barakate M, Bottrill I. *Combined approach tympanoplasty for cholesteatoma: impact of middle-ear endoscopy.* J Laryngol Otol 2008;122:120-4.
 - 27 Presutti L, Marchioni D, Mattioli F, et al. *Endoscopic management of acquired cholesteatoma: our experience.* J Otolaryngol Head Neck Surg 2008;37:481-7.

Received: September 8, 2013 - Accepted: October 17, 2013

REVIEW

OSAS and metabolic diseases: Round Table, 99th SIO National Congress, Bari 2012

OSAS e patologie metaboliche: Tavola Rotonda, 99° Congresso Nazionale SIO, Bari 2012

D. PASSÀLI¹, P. TATTI², M. TORALDO³, M. DE BENEDETTO⁴, F. PEVERINI⁵, G. CARUSO¹, A. MARZETTI⁶, F.M. PASSÀLI⁷, L. BELLUSSI¹

¹ ENT Clinic University of Siena; ² Dep. Marino General Hospital; ³ "A. Galateo" Respiratory Rehabilitation Unit, San Cesario di Lecce; ⁴ ENT Dep. Hospital Fazzi, Lecce; ⁵ Scient. Dir. Foundation "Ricerca e Cura dei Disturbi del Sonno" Rome; ⁶ ENT Clinic San Carlo Hospital, Rome; ⁷ University Tor Vergata, Rome, Italy

SUMMARY

This draft of the Official Round Table held during the 99th SIO National Congress is an updated review on the diagnostic tools, the importance of polysomnographic recording and a critical analysis of the surgical techniques in obstructive sleep apnoea syndrome (OSAS). The review and analysis of available publications is the premise along with a specific analysis of the relationship between OSAS and metabolic and vascular disorders. In addition, the most recent investigations on sleep disorders and altered glucose metabolism are summarised and discussed together with the results of a study by the authors involving a fairly large number of patients with OSAS and diabetes.

KEY WORDS: OSAS • Diabetes • Polysomnography • Nasal obstruction • Cardiovascular diseases

RIASSUNTO

Questo testo è un estratto della tavola rotonda ufficiale tenutasi durante il 99° Congresso Nazionale SIO. Si tratta di una revisione aggiornata sugli strumenti diagnostici, sull'importanza della polisomnografia e di un'analisi critica delle tecniche chirurgiche dell'OSAS. La revisione e l'analisi di tutti gli studi costituiscono la premessa e il completamento dei capitoli; particolare attenzione è posta sul rapporto tra OSAS e disturbi metabolici e vascolari. Inoltre, i lavori più recenti su disturbi del sonno ed alterazioni del metabolismo glucidico sono riassunti e discussi insieme ai risultati di uno studio portato avanti dagli autori che coinvolge un discreto numero di pazienti con OSAS e diabete.

PAROLE CHIAVE: OSAS • Diabete • Polisomnografia • Ostruzione nasale • Patologie Cardiovascolari

Acta Otorhinolaryngol Ital 2014;34:158-166

Introduction

Respiratory disorders play an important role in determining and increasing many metabolic pathologies. Respiration in fact, is a fundamental function of any organism, and it is biologically logical that it should be connected with other critical functions including the control of glucose blood levels.

On the other hand, glucose levels in blood result from the interaction of many factors, one of which is the high overnight activity of the brain.

In patients with diabetes, it has been shown that not only obstructive apnoea, but also simple snoring, has a negative effect on insulin sensitivity, fasting blood glucose and glycated haemoglobin (HbA1c) levels.

As a whole, very recent data point out that sleep disordered breathing (SDB) can be the cause of notable glycae-

mic variability (GV), and this in turn, is one of the many factors that are associated with complications of diabetes. Both direct and indirect mechanisms can explain the effects of SDB on blood glucose levels. Among these, one of the most important is that anoxia during OSAS is a potent stimulus for catecholamine secretion and glycogenolysis. An indirect effect regards obesity, as it is tightly connected with diabetes (to emphasize this connection the term "diabesity" has been created) ¹⁻³.

Nocturnal awakenings and sleep disruption in OSAS lead to debt in sleep which, in turn, is translated into other activity during diurnal hours, thus promoting obesity.

Relevance of OSAS in metabolic disorders

Some studies have demonstrated a role for OSAS using polysomnographic recording and the oral glucose toler-

ance test (OGTT) ⁴. The work of Punjabi ⁵ in 118 non-diabetic subjects who underwent an insulin sensitivity test, FSIGT (frequently sampled intravenous glucose tolerance) ⁶, provides evidence that OSAS reduces insulin sensitivity by 27%, 37% and 48% according to the severity of oxygen reduction, defined as modest, moderate or severe, respectively. However, in that report, the criteria used to define these classes is not clear, and it is unknown if the definition was based on the number of apnoea/hypopnoea episodes or on the level of associated oxygen deprivation. Another study on 150 males showed that an increase of the apnoea/hypopnoea index is associated with an increased risk for impaired glucose tolerance (IGT) and development of insulin resistance. Both these conditions are considered as prodromic to type 2 diabetes and an essential part of what is referred to as metabolic syndrome. We recently demonstrated in 60 OSAS subjects that the number of nocturnal awakenings was strictly related with instability of glucose values upon awakening (glycaemic variability) ⁷. This variability is now deemed to be one of the major risk factors for cardiovascular diseases both in diabetic and non-diabetic individuals. There are many interesting reports on this subject that have been accurately evaluated in a recent review ⁸. There are also some studies that demonstrate the increase of inflammatory factors in subjects with OSAS: among these, C-reactive protein and cytokines, which are responsible for systemic atherosclerosis and probably have a role in the appearance of neoplasms ^{9 10}. There is also evidence of an increase of atherogenic dyslipidaemia in subjects with OSAS ¹¹.

The metabolic–OSA connection is well studied. It is known that poor sleep/OSA may have a negative effect on body weight. OSAS subjects have substantial difficulty losing weight, and tend to increase it ¹². Among the numerous mechanisms hypothesised to explain this effect is a critical that involves the hormone leptin, which regulates appetite ¹³. OSAS subjects show resistance to leptin and a concomitant increase in appetite drive ^{14 15}. Some years ago, the presence of high but ineffective levels of leptin in obese type 2 diabetic subjects was shown to be a markers of insulin resistance ¹⁶. Another interesting connection that is not yet sufficiently explored is the between OSAS and erectile dysfunction ^{17 18}.

Diagnosis of OSAS

The literature makes it increasingly evident, thanks to increasingly advanced diagnostic techniques, that sleep-related respiratory disorders are associated not only with cardiovascular pathologies, such as arterial hypertension ¹⁹ (as already shown by Coccagna and Lugaresi in the 1970s) ²⁰, but also with systemic endocrine and neurological disorders ³.

It is clear from these premises that otolaryngologists are often the first to encounter such patients. There is, therefore,

the challenge to correctly diagnose these patients on the basis of clinical and instrumental investigations while assessing them for therapeutic medical and surgical purposes.

It is especially important to pay attention to diagnostic procedures because of the relative novelty of sleep-related respiratory disorders as a pathology outside the traditional domain of expertise of ENT specialists.

Diagnostic procedures must be aimed at: compiling a thorough clinical history; evaluating, clinically and instrumentally, all alterations of normal anatomy and physiology of the cervical-cephalic regions; locating the obstruction site(s) of the upper airways.

Pursuant to the 2007 Italian Society of Otolaryngology guidelines, it is our view that patients suspected of OSAS should undergo a basic set of tests for gathering clinical data, to be followed by a more advanced clinical-instrumental investigation in case of surgical planning.

Basic Test Set:

- thorough anamnestic evaluation;
- ENT clinical examination;
- Muller's manoeuvre-assisted fiberoptic laryngoscopy.

Advanced clinical-instrumental investigation:

- nose function trials;
- cephalometric analysis;
- sleep endoscopy;
- imaging.

Given the large amount of information to be analysed and integrated with the results from nocturnal cardio-respiratory monitoring, it is useful to adopt specially-dedicated medical records for this disorder, as already advanced by several authors ²¹.

The relationship between nasal obstruction and respiratory disorders has been studied for more than 30 years. A close association has been hypothesised between increased nasal resistance and severity of snoring and sleep apnoea ²². The link between nasal resistance and OSAS severity has been shown by several authors, but there are several contrasting studies which show no association, in clinical trials, between nasal obstruction and apnoea ²³⁻²⁵. On the other hand, perusal of the literature does highlight that many patients affected by sleep-related respiratory disorders show symptoms of nasal obstruction; likewise, it is well known that an integral part of snoring-corrective surgery is nasal surgery. In addition, some authors suggest a decrease in nasal resistance can be of use in CPAP ventilation therapy, due to the lower air pressures required ²⁶. The traditional otolaryngological approach to the patient with nasal obstruction was rendered obsolete by the availability of modern diagnostic tools. Virtually, all instances of nasal ailments can be attributed to their underlying causes and appropriately treated by careful rhinological studies in specialised centres provided with adequate instrumentation. Thus, physical examination needs to be

performed with optical endoscopes reaching areas that are traditionally difficult to access, which allows for earlier and more detailed diagnoses; afterwards, tests of nasal function will be necessary for correct diagnostic framing. Basic tests of nose-sinus function, useful for the assessment of suspected OSAS patients, are measurements of airflow and pressure within the nose by active anterior rhinomanometry, acoustic rhinometry and mucociliary transport time—functional assessments of both the nasal fossa and their mucosal lining.

Much has been written for the last 20 years about nasal fiberoptic endoscopy under sedation (sleep endoscopy). This technique was first described in 1991 by Croft and Pringle²⁴, who started out by observing that snoring and OSAS are dynamic phenomena mainly occurring in sleeping patients, and thought to visualise the sites of obstruction in the upper airways during sleep phases.

In the original study, sleep was induced by short-acting benzodiazepines (midazolam). The fiberoptic endoscope was well-tolerated by 95.8% of study subjects, and the obstructive problem was correctly identified in 79% of cases. Patients are made to lie supine on an operating table with low-intensity lights. Throughout the procedure oximetry and cardiac rhythms are accurately monitored, with supplementary oxygen delivered through a mask if necessary. Propofol is administered at an infusion rate of 50-75 mcg/kg/min in order to meet the target level of anaesthesia. At drug-induced sleep inception, the flexible endoscope is introduced into the anaesthetised nasal cavity, and the examination (digitally recorded throughout) commences. During the examination, dynamic collapse needs to be evaluated at the level of the retro-palatal and retro-lingual

regions, as well as of the laryngeal structures. The severity and type (transverse, circular horizontal pattern) of the collapse needs to be noted for each region. For standardisation purposes, several classification systems have been proposed to report the severity, type and location of obstructions. The most commonly used, at present, are the VOTE classification (Table I), introduced by de Vries²⁸, and the NOHL classification, introduced and standardised by the Italian School of Vicini²⁹ (Table II).

To date, several modifications of the technique have been published³⁰⁻³¹, with varying results. A recent review of the literature by Ravesloot and de Vries³² of patients who underwent sleep endoscopy showed that different regions of the upper airways collapse, such as the velopharynx, oropharynx, base of the tongue and epiglottis, but it also underscored that the collapse is oftentimes multi-level. Furthermore, according to Rodriguez³³⁻³⁵, sleep endoscopy has demonstrated high test-retest reliability compared with other diagnostic techniques for OSAS.

The role of polysomnography

Among sleep disorders, those with the greatest impact on health and highest healthcare-related costs are respiratory disorders in sleep (mainly night apnoeas-OSAS).

Their incidence in the Italian population is estimated at about 180,000 people, 95% of which is probably undiagnosed.

There has been barely any increase in newly-diagnosed patients over the last 20 years, a greatly concerning figure from a public health and social point of view. Unfortunately, this problem is still inadequately addressed, in all

Table I. VOTE Classification according de Vries et al.²⁸ (shaded boxes reflect the fact that a specific structure-configuration cannot be seen).

Degree of obstruction:

- 0 No obstruction/vibration < del 50%
- 1 Partial obstruction/vibration >del 50% < del 75%
- 2 Complete collapse
- X Not visualised

STRUCTURE	DEGREE OF OBSTRUCTION	CONFIGURATION		
		A-P	Lateral	Concentric
Velum				
Oropharynx lateral walls				
Tongue base				
Epiglottis				

Table II. NOHL Classification according Vicini et al. (This is associated with the pattern of collapse and tonsil size) Example: N304cTS3H2tLn.

Site	Nose	Oropharynx	Hypopharynx	Larynx Supraglottic Glottic
Grade of Obstruction/Collapse	Grade 1: 0-25%	Grade 1: 0-25%	Grade 1: 0-25%	Collapse present/absent
	Grade 2: 25-50%	Grade 2: 25-50%	Grade 2: 25-50%	
	Grade 3: 50-75%	Grade 3: 50-75%	Grade 3: 50-75%	
	Grade 4: 75-100%	Grade 4: 75-100%	Grade 4: 75-100%	

its complexity, at the educational (university), preventative or patient-care level.

Daytime sleepiness, a paramount symptom of OSAS, results from non-restful sleep at night and can lead to very serious consequences (traffic accidents, workplace accidents, etc.). Furthermore, traffic accidents by excessive daytime sleepiness carry high costs, both public and private, are generally more severe and result in a mortality rate almost twice that of accidents due to other causes.

Different, but equally relevant for public health, is the impact of sleep apnoea syndromes on cardiovascular risk: few disorders such as sleep apnoea display such a strong and important association with hypertension, cardiac arrhythmias and heart failure.

Several studies have reported that 45-50% of all hypertensive subjects are actually suffering from a hidden, undiagnosed sleep apnoea, and the same applies to 25-50% of patients with heart failure.

The most impressive datum concerns patients who have had a transient ischaemic attack (TIA) or stroke: a sleep apnoea syndrome may be present in 60% of these cases, and this figure increases consistently once the presence of a relatively common heart defect, such as a patent “foramen ovalis”, is factored in.

The majority of OSAS patients also display a constellation of metabolic and non-metabolic cardiovascular risk factors typical of metabolic syndrome. Indeed, the suggestion has been put forth that OSAS may be a manifestation of metabolic syndrome (“syndrome Z”) ³⁶ (Fig. 1).

Polysomnography permits detection and classification of a number of respiratory (apnoeas, O₂ desaturations) and neurological phenomena (e.g. arousals, or periodic movements of the lower limbs), as well as blood pressure and cardiac activity; it is therefore essential, for the interpretation of such data, to have some basic knowledge of specific technical standards.

In order to establish adequate treatment, OSAS medical specialists need to make the best use of the available severity criteria provided by international guidelines. However, it is often the case that the indexes resulting from the scoring parameters of sleep-related respiratory events (RDI, AHI, ODI) are inadequate to classify and confidently deal with all clinical situations.

Indeed, patterns of sleep-related events frequently occur that hardly fit a patient on the exclusive basis of strict taxonomic criteria, providing an interesting interpretative and therapeutic challenge. This consideration, together with the high incidence of OSAS in the general population, and the vast array of disease-associated cardiovascular and neurological complications, further highlights the need to assess OSAS patients in a clinical and multi-disciplinary framework, reserving instrumentation exclusively to the task of confirming the physician’s diagnostic hypotheses, developed on the basis of the patient’s signs and symptoms.

It is now necessary to address the question: who should be tested by polysomnography? In Italy, are the current AIMS–AIPO guidelines the most appropriate to deal with the problem? Who are the best specialists for expanding

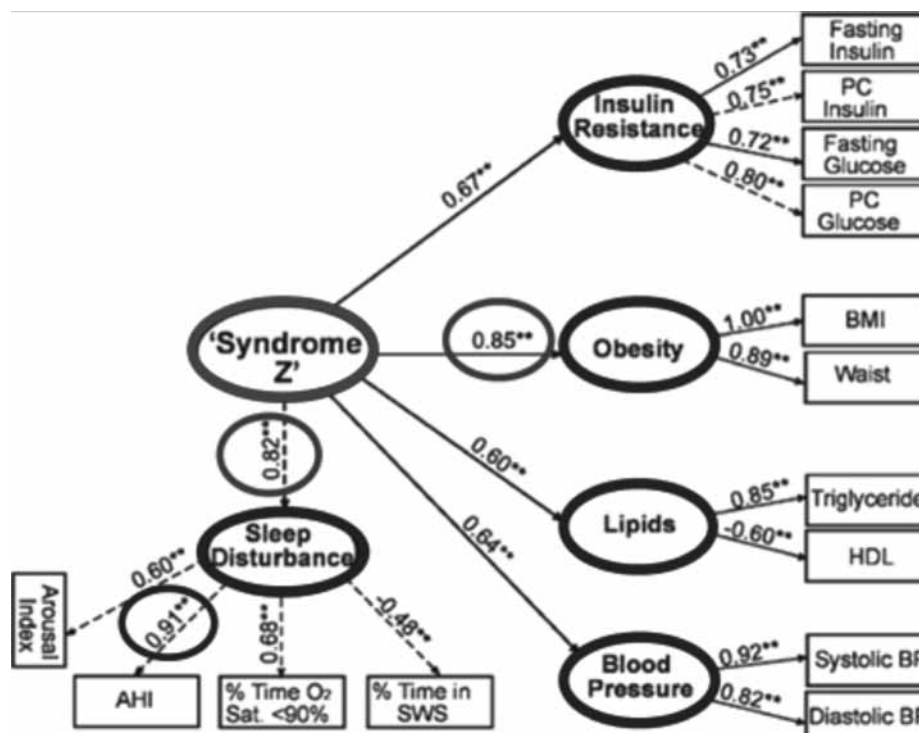


Fig. 1. “Hierarchical” hypothesis of the prevalence of metabolic and non-metabolic risk factors of sleep disorders. Adapted from: NL Nock et al.: Empirical evidence for “syndrome Z”: a hierarchical 5-factor model of metabolic syndrome incorporating measures of sleep disturbance. *Sleep* 2009, 32:615-622.

diagnostic opportunities? The otolaryngologist has always been closely linked to diagnosis and surgical treatment of OSAS. Is it possible to broaden his role in the diagnosis and treatment of OSAS patients?

There is some rationale in this regard:

- I. higher frequency of OSAS patients' first visit;
 - II. early identification of obstruction sites;
 - III. widespread availability of ENT specialists;
- and some challenges to be met:

- I. management of diagnostic polysomnography;
- II. management of the multidisciplinary team;
- III. carrying out prospective studies to evaluate the efficacy of a surgical approach.

The role of severe OSAS in atherosclerotic disease: pharmacological treatment with statins.

The recently published meta-analysis in *The Lancet* by CTT (Cholesterol Treatment Trialists Collaborators) provides further evidence that statins are a safe and effective way to reduce the risk of heart attack and stroke, even among people at very low risk for major cardiovascular events. A recent review³⁷, on the usefulness of long-term statins in primary prevention of cardiovascular disease concluded by inviting clinicians to exercise caution in prescribing statins for primary prevention in patients at low cardiovascular risk. On the basis of these results, patients older than 50 years of age with severe OSAS at high risk for coronary heart disease and stroke should take statins to reduce carotid and coronary early vascular risk. One study³⁸ showed that 20% of severe OSAS patients developed early carotid atherosclerosis.

On the basis of the CTT study, the suggestion can be made that it may be appropriate to prescribe statins to subjects aged > 50 years, since 83% of men over 50 have a 10-year cardiovascular risk of 10%. In fact, the benefits to be gained by giving statins to anyone older than 50 years of age would probably result in a net saving for the public health service by reducing health care costs resulting from heart attacks and strokes, and prevented by statins. OSAS is, among cardiac-metabolic disorders, still underestimated from an epidemiological point of view; it is associated in 67% of cases with an asymptomatic coronary syndrome, and in 51.2% with metabolic syndrome. In the future, substantial public health resources will be needed for diagnosis and early treatment.

Strengthening prevention strategies against primary atherosclerosis will need to be one of the focal aims of future healthcare programs. Furthermore, as increased protection from risk factors hinges on an increased level of education, this means that education towards healthy lifestyles needs to be greatly enhanced and to become an integral part of public healthcare policies. This is a public health service yielding slower effects, but certainly more efficacious considering the economy of the entire public healthcare system. In another paper Ye et al., found increased cell-free DNA in the serum of patients with

OSAS. The authors interpret these results by suggesting that chronic hypoxia-induced apnoea makes cancer cells more resistant and accelerates their growth. This study also provides important evidence that OSAS is associated with increased tumour mortality as well as general and cardiovascular mortality³⁹.

OSAS surgical treatment

While most patients undergo surgery because of CPAP intolerance, it is imperative that they use their CPAP for at least two weeks prior to and after surgery in order to not accumulate sleep debt. Hypertension should be treated aggressively in the perioperative period. After surgery, admission with pulse oximetry and pain management with narcotics is required. Patients need to demonstrate the ability to tolerate a liquid diet, have adequate pain control and have a safe airway prior to discharge.

Nasal surgery: various observational and cross-sectional studies have documented a relationship between chronic nasal obstruction and OSA⁴⁰. Rhinitis constitutes a pathologic condition characterised by an increase in nasal airway resistance due to mucosal swelling, and therefore it may represent a risk factor for OSA. Several studies have correlated nasal congestion from allergic and non-allergic rhinitis as a risk factor for OSAS with differing results. Epidemiological data have shown that chronic rhinitis symptoms and increased nasal resistance measured by rhinomanometry are associated with habitual snoring, but a similar association is not documented for OSAS.

Kohler⁴⁰ reviewed the literature about the role of the nose in the pathogenesis of OSA. From the currently available data, it was concluded that nasal congestion may contribute to the pathogenesis of OSA. Architecture and quality of sleep could be improved by treating nasal congestion, but the clinical relevance remains to be demonstrated. Nasal surgery may be helpful in patients who are unable to tolerate CPAP because of nasal obstruction, but this has never been shown in randomised controlled trials. Although there is no role for nasal surgery as a single treatment for OSA, it is quite useful in improving symptoms in simple snorers and potentially useful as part of multi-level surgery in many patients with SRBD. The ERS task force⁴¹ concludes that nasal surgery as a single intervention is not recommended for treatment of OSAS (grade of recommendation C), but is recommended for reducing high therapeutic CPAP pressure due to nasal obstruction.

Velo-palatal and pharyngeal surgery: the tonsils and retropalatal areas clearly represent common sites of obstruction in OSA.

Palatal stiffening with the pillar implant technique may be useful only for patients with mild to moderate OSA who refused other conservative approaches. Palatal implants are expensive and a partial extrusion occurs in 10.3% of patients³⁷. The overall success rate is limited.

Laser-assisted uvulopalatoplasty (LAUP) is an office-based surgical procedure that progressively shortens and tightens the uvula and palate through a series of carbon dioxide laser incisions and vaporisations. This technique is associated with moderate to severe pain immediately after the procedure, and is weighed against the risk of scar contracture which can reduce the effectiveness of surgery and lead to complications. In mild OSAS, LAUP is not recommended (recommendation B) ⁴¹.

Radiofrequency (RF) surgery of the soft palate is applied by inserting electrodes submucosally usually into five sites of the soft palate. This procedure represents a good treatment option in habitual snorers, but it is not recommended as a single-stage approach in mild OSAS and is not superior to placebo ⁴².

Other procedures for soft palate stabilisation have been proposed such as using nasal septum cartilage or concha cartilage ⁴³.

Uvulopalatopharyngoplasty ^{44 45} (UP3) is the single most common surgical performed procedure for the correction of retropalatal obstruction causing or contributing to OSAS. This basic procedure only corrects obstruction of the palate and tonsils. Firstly, Fujita himself recognised that half of patients submitted to UP3 were non-responders. For those with a component of hypopharyngeal obstruction (Types II and III in Fujita and Simmons classification ⁴⁶, the response rate is only 5.3% ⁴⁷. Actually, for patients with morbid obesity and airway involvement, UP3 treatment is unsuccessful.

Anterior palatoplasty (modified cautery assisted palatoplasty) was proposed by Pang ⁴⁸ in management of patients with mild-moderate OSA. This procedure is very simple and safe, and if associated with UP3 gives excellent results in patients type I Fujita.

Tucker Woodson ⁴⁹ described a method of reconstructing the upper pharynx by performing a posterior maxillary osteotomy and advancing the soft palate anteriorly (posterior palatal osteotomy and palatal advancement flap). A 67% successful response rate was observed in patients who underwent transpalatal advancement. This procedure enlarges the upper oropharyngeal airway, and can be indicated in UP3 failures.

Lateral pharyngoplasty was proposed by Cahali ⁵⁰ in 2003 for patients with moderate to severe OSA to enlarge the collapsed lateral pharyngeal wall: the results seemed initially promising, but many patients had postoperative dysphagia. Expansion sphincter pharyngoplasty consists of a tonsillectomy, expansion pharyngoplasty with or without superolateral incision on the soft palate, horizontal section and superolateral rotation of the palatopharyngeus muscle, partial uvulectomy and a closure of the anterior and posterior tonsillar pillars. The key to this procedure is to not completely isolate the muscle and rotate it. This procedure is simple to perform, but significant pain and swallowing problems may occur.

Tongue surgery: a variety of approaches have been described for lingual tonsillectomy and advancement of the tongue base. Exposure of the tongue base is optimised via suspension laryngoscopy with endoscopy. Isolated retro-lingual obstruction is present in only 25% or less of patients with OSAS.

Radiofrequency tongue base ablation (RFA): Success rates are higher according to the subjects' posture with a rate of 87.5% for the supine position and 56.6% in non-supine positions ⁵¹.

Lingual tonsillectomy can be done with laser, diathermy, cryotherapy, ultrasonic coagulating dissector, or microdebrider. The surgical technique should be always performed under visualisation with telescope, and care should be taken to avoid damage to the lingual neurovascular bundle ⁵². Laser midline glossectomy ⁵³ enlarges the retro-lingual airway by reducing the base of tongue by approximately 2.5 x 5 cm through an intraoral approach. Lingual tonsillectomy, epiglottectomy and aryepiglottic fold reduction may be performed at the same setting. More aggressive resection is associated with more frequent complications such as lingual and airway oedema necessitating tracheotomy.

Submucosal minimally invasive lingual excision (SMILE) ⁵⁴ is a modified version of the description by Robinson et al. of tongue base reduction using coblation through a suprahyoid neck approach. It is a mucosal sparing approach, while allowing aggressive tissue removal using a plasma-mediated radiofrequency device under ultrasonic and endoscopic guidance.

In 1999, Chabolle ⁵⁵ proposed tongue base reduction with hyoepiglottoplasty (TBRHE) through a cervical approach. The lingual neurovascular bundle must be carefully identified and a subtotal tongue base resection is performed. Next, the hyoid bone is suspended at the lower border of the mandible and finally a temporary tracheotomy is carried out.

The tongue-base suspension can also be obtained by means of REPOSE system ⁵⁶. In our opinion, this procedure belongs to the past and should be forgotten.

Recently some reports about the partial glossectomy using transoral robotic surgery (TORS) have been reported ⁵⁷. This procedure can be performed without the need for tracheotomy, but has an increased morbidity compared with the other techniques as RFA or SMILE ⁵⁶.

Hyoid advancement: Riley et al. described hyoid suspension in 1986, although with osteotomy of the mandible and fixation of the hyoid bone to the mandible ⁵⁸. The modified hyoid suspension according to Hörmann and Baish ⁵⁹ may provide good benefits for successful surgical therapy of OSA. Lewis ⁶⁰ proposed a modified technique of inferior hyoid advancement using four sutures between just below the superior border of the thyroid cartilage and the hyoid bone pulled completely over the anterior surface of the thyroid cartilage.

Maxillo-mandibular osteotomy: clearly a very valid option for OSAS failures. This procedure is usually performed after the above surgeries have failed to improve obstructive sleep apnoea and is considered a phase II surgery. Most of these patients have already undergone a staged surgery, often with UP3 and genioglossal advancement as a part of a multilevel surgical program. The success rate of this group varies from 65.2% to 97.5%⁶¹⁻⁶³. This surgery is perceived as an unattractive treatment modality because of the possibility of a significant change in the facial profile. MMO is particularly indicated in presence of craniofacial abnormalities.

Laryngeal surgery: the larynx can also be a possible site of obstruction in OSA. It is documented that an increase in the concavity of the posterior surface of the epiglottis can be correlated with an increase in BMI⁶⁴. Epiglottis reshaping with CO₂ laser irradiation gives a significant improvement even in children with laryngomalacia and obstructive sleep apnoea. The data suggest that this form of airway distress characterised by prolapse of supraglottic structures into the glottic airway during inspiration is an important contributor to OSA, and that its correction can significantly improve sleep in children.

Skin-lined tracheostomy: this procedure bypasses the laryngeal airway and is reserved for use in patients with severe OSA who have failed to improve with other medical and surgical treatments and in special cases in which these modalities are contraindicated or not tolerated. In OSA, patients submitted to tracheostomy showed a severe reduction in blood pressure and hypoglycaemia⁶⁵. Tracheostomy is preferably carried out with the skin-lined technique⁶⁶ to guarantee greater stability, less risk of granulation tissue and wider opening than tracheotomy.

Considerations

Among the phenomena that modulate the activity of the brain, sleep plays an important role. Normal breathing and sleep patterns are essential to survival, and thus it is not unexpected that the importance of SDB and OSAS and their effect on glucose metabolism and diabetes have been evaluated recently in several important publications; in the last Meeting of the European Association for the Study of Diabetes (EASD) an entire session was devoted to SDB and its impact on the diabetes¹⁻³.

At present there is sufficient data to accept the existence of an interaction among OSAS and some recently described metabolic disorders (18), but understanding the mechanisms behind this is much more complicated. We have recently proposed a model of this interaction (Fig. 2).

References

¹ Tatti P, Passali D, Bellussi LM. *The undisclosed role of oxia/hypoxia and disturbed sleep on glucose metabolism.* J Diabetes Mellitus 2012;2:186-90

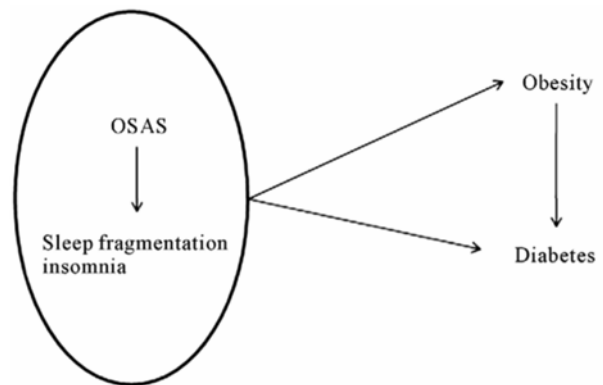


Fig. 2. A simplified scheme of the interactions between respiratory distress and metabolic disorders.

- ² Spiegel K. *Sleep curtailment in healthy young men is associated with decreased leptin levels, elevated ghrelin levels, and increased hunger and appetite.* Ann Internal Med 2004;141:846-50.
- ³ Passàli D, Tatti P, Passàli FM, et al. *The undisclosed role of disturbed sleep and hypoxia on metabolism: the importance of upper airways pathology.* Sleep Breath 2013;17:5-6.
- ⁴ Tiihonen M, Partinen M, Närvänen S. *The severity of obstructive sleep apnoea is associated with insulin resistance.* J Sleep Res 1993;2:56-61.
- ⁵ Punjabi NM, Beamer BA. *Alterations in glucose disposal in sleep-disordered breathing.* Am J Respir Crit Care Med 2009;179:235-40.
- ⁶ Bergman RN. *Toward physiological understanding of glucose tolerance: Minimal model approach.* Diabetes 1989;38:1512-27.
- ⁷ Tatti P, Passali D. *Sleep disturbances and glucose variability.* In: Lopez Garcia CM, Perez Gonzalez PA, eds. *Metabolic Syndrome: Classification, Risk Factors and Health Impact.* Nova Publisher, in Press.
- ⁸ Tatti P, Lehmann ED, Barber AE, Passali D, et al. *Application of technology in endocrine disease.* Int J Endocrinol 2014;2014:715029.
- ⁹ Popko K, Gorska E, Potapinska O, et al. *Frequency of distribution of inflammatory cytokines IL-1, IL-6 and TNF- α gene polymorphism in patients with obstructive sleep apnea.* J Physiol Pharmacol 2008;59(Suppl. 6):607-14.
- ¹⁰ Ciftci TU, Kokturk O, Bukan N, et al. *The relationship between serum cytokine levels with obesity and obstructive sleep apnea syndrome.* Cytokine 2004;28:87-91.
- ¹¹ Williams CJ, Hu FB, Patel SR, et al. *Sleep duration and snoring in relation to cardiovascular disease risk in women with type 2 diabetes.* Diabetes Care 2007;30:1233-40.
- ¹² Mary L. *Obesity and OSA: More than BMI.* Sleep Review 2004;4(D):36-9.
- ¹³ Tatti P, Barber A. *Human obesity: an overview of the mechanisms and the basis for treatment.* Advances in Medicine and Biology 2011;15:341-52.
- ¹⁴ Phillips BG, Kato M, Narkiewicz K, et al. *Higher leptin levels in OSA, independent of body fat content, suggest that OSA is associated with resistance to the weight reducing effects of*

- Leptin*. *Am Physiol Heart Circ Physiol* 2000;279:234-7.
- 15 Spiegel K, Tasali E, Penev P, et al. *Sleep curtailment in healthy young men is associated with decreased leptin levels, elevated ghrelin levels, and increased hunger and appetite*. *Ann Internal Med* 2004;141:846-50.
 - 16 Tatti P, Masselli L, Buonanno A, et al. *Leptin levels in diabetic and nondiabetic subjects*. *Endocrine* 2001;15:305-8.
 - 17 Budweiser S, Enderlein S, Jörres RA, et al. *Sleep apnea is an independent correlate of erectile and sexual dysfunction*. *J Sex Med* 2009;6:3147-57.
 - 18 Fisher WJ. *Current clinical issues: is sleep the new vital sign?* *Ann Int Med* 2005;10:877.
 - 19 Toraldo DM, Peverini F, De Benedetto M, et al. *Obstructive sleep apnea syndrome: blood viscosity, blood coagulation abnormalities, and early atherosclerosis*. *Lung* 2013;191:1-7.
 - 20 Lugaresi E, Coccagna G, Mantovani M, et al. *Effects of tracheostomy in two case of hyperinsomnia with periodic breathing*. *J Neuro Neurosurg Psychiatry* 1973;36:15-26.
 - 21 Passali D, Caruso G, Arigliano LC, et al. *Database application for patients with obstructive sleep apnoea syndrome*. *Acta Otorhinolaryngol Ital* 2012;32:252-5.
 - 22 Passali FM, Bellussi L, Mazzone S, et al. *Predictive role of nasal functionality tests in the evaluation of patients before nocturnal polysomnographic recording*. *Acta Otorhinolaryngol Ital* 2011;31:103-8.
 - 23 Blakley BW, Mahowald MW. *Nasal resistance and sleep apnea*. *Laryngoscope* 1987;97:752-4.
 - 24 Cole P, Haight JSJ. *Mechanism of nasal obstruction in sleep*. *Laryngoscope* 1984;94:1557-9.
 - 25 Duchna HW. *Anamnestic and polygraphic parameters in obstructive sleep apnea syndrome patients with reduced nasal respiration during the day in comparison with obstructive sleep apnea patients with normal nasal respiration*. *Wien Med Wochenschr* 1996;146:348-9.
 - 26 Sugiura T, Noda A, Nakata S, et al. *Influence of nasal resistance on initial acceptance of continuous positive airway pressure in treatment for obstructive sleep apnea syndrome*. *Respiration* 2007;74:56-60.
 - 27 Croft CB, Pringle M. *Sleep nasendoscopy: a technique of assessment in snoring and obstructive sleep apnoea*. *Clin Otolaryngol Allied Sci* 1991;16:504-9.
 - 28 Kezirian KJ, Hohenhorst W, de Vries N. *Drug-induced sleep endoscopy: the VOTE classification*. *Eur Arch Otorhinolaryngol* 2011;268:1233-6.
 - 29 Vicini C, De Vito A, Benazzo M, et al. *The nose oropharynx hypopharynx and larynx (NOHL) classification: a new system of diagnostic standardized examination for OSAHS patients*. *Eur Arch Otorhinolaryngol* 2012;269:1297-300.
 - 30 Faber CE, Grymer L. *Available techniques for objective assessment of upper airway narrowing in snoring and sleep apnea*. *Sleep Breath* 2003;7:77-86.
 - 31 Abdullah VJ, Wing YK, van Hasselt CA. *Video sleep nosenoscopy: the Hong Kong experience*. *Otolaryngol Clin North Am* 2003;36:461-71.
 - 32 Ravesloot MJL, de Vries N. *One hundred consecutive patients undergoing drug-induced sleep endoscopy: results and evaluation*. *Laryngoscope* 2011;121:2710-6.
 - 33 Rodriguez-Bruno K, Goldberg A, McCulloch C, et al. *Test-retest reliability of drug-induced sleep endoscopy*. *Otolaryngol Head Neck Surg* 2009;140:646-51.
 - 34 Salamanca F, Costantini F, Bianchi A, et al. *Identification of obstructive sites and patterns in obstructive sleep apnea syndrome by sleep endoscopy in 614 patients*. *Acta Otorhinolaryngol Ital* 2013;33:261-6.
 - 35 De Corso E, Fiorita A, Rizzotto MG, et al. *The role of drug-induced sleep endoscopy in the diagnosis and management of obstructive sleep apnoea syndrome: our personal experience*. *Acta Otorhinolaryngol Ital* 2013;33:405-13.
 - 36 Nock NL, Li L, Larkin EK, et al. *Empirical evidence for "syndrome Z": a hierarchical 5-factor model of the metabolic syndrome incorporating sleep disturbance measures*. *Sleep* 2009;32:615-22.
 - 37 Taylor F, Ward K, Moore TH, et al. *Statins for the primary prevention of cardiovascular disease*. *Cochrane Database Syst Rev* 2011 Jan 19;1:CD004816.
 - 38 Baguet J P, Nadra M, Barone-Rochette G, et al. *Early cardiovascular abnormalities in newly diagnosed obstructive sleep apnea*. *Vasc Health Risk Manag* 2009;5:1063-73.
 - 39 Ye L, Ma GH, Chen L, et al. *Quantification of circulating-cell-free DNA in the serum of patients with obstructive sleep apnea-hypopnea syndrome*. *Lung* 2010;188:469-74.
 - 40 Kohler M, Bloch KE, Stradling JR. *The role of the nose in the pathogenesis of obstructive sleep apnea*. *Curr Opin Otolaryngol Head Neck Surg* 2009;17:33-7.
 - 41 Randerath WJ, Verbraecken J, Andreas S, et al. *Non-CPAP therapies in obstructive sleep apnoea*. *Eur Resp J* 2011;37:1000-23.
 - 42 Bäck LJ, Liukko T, Rantanen I, et al. *Radiofrequency surgery of the soft palate in the treatment of mild obstructive sleep apnea is not effective as a single-stage procedure: A randomized single-blinded placebo-controlled trial*. *Laryngoscope* 2009;119:1621-7.
 - 43 Tolsdorff P, Honnef B. *Gaumen-Knorpel-Stabilisierung bei Schnarchen und mildem bis mittelschwerem obstruktivem Schlaf-Apnoe-Syndrom*. *Laryngorhinotologie* 2009;88:696-8.
 - 44 Fujita S, Conway W, Zorick F, et al. *Surgical correction of anatomic abnormalities in obstructive sleep apnea syndrome: uvulopalatopharyngoplasty*. *Otolaryngol Head Neck Surg* 1981;89:923-34.
 - 45 Mantovani M, Minetti A, Torretta S, et al. *The velo-uvulopalatopharyngeal lift or "roman blinds" technique for treatment of snoring: a preliminary report*. *Acta Otorhinolaryngol Ital* 2012;32:48-53.
 - 46 Fujita S, Simmons FB. *Pharyngeal surgery for obstructive sleep apnea and snoring*. In: Fairbanks DNF, Fujita S, Ikegami T, et al., eds. *Snoring and Obstructive Sleep Apnea*. NY: Raven Press; 1987. p. 101-128.
 - 47 Sher AE, Schectman KB, Piccirillo JF. *The efficacy of surgical modifications of the upper airway in adults with obstructive sleep apnea syndrome*. *Sleep* 1996;19:156-77.
 - 48 Pang KP, Tan R, Puraviappan P, et al. *Anterior palatoplasty for the treatment of OSA: three-year results*. *Otolaryngol Head Neck Surg* 2009;141:253-6.
 - 49 Tucker Woodson B. *Transpalatal advancement pharyngoplasty*. *Operative Techniques in Otolaryngology* 2007;18:11-6.

- ⁵⁰ Cahali MB. *Lateral pharyngoplasty: a new treatment for obstructive sleep apnea hypopnea syndrome*. Laryngoscope 2003;113:1961-8.
- ⁵¹ Babademez MA, Ciftci B, Acar B, et al. *Low-temperature bipolar radiofrequency ablation (coblation) of the tongue base for supine-position-associated obstructive sleep apnea*. ORL J Otorhinolaryngol Relat Spec 2010;72:51-5.
- ⁵² Barakate M, Havas T. *Lingual tonsillectomy: A review of 5 years' experience and evolution of surgical technique*. Otolaryngol Head Neck Surg 2008;139:222-7.
- ⁵³ Fujita S, Woodson BT, Clark JL, et al. *Laser midline glossectomy as a treatment for obstructive sleep apnea*. Laryngoscope 1991;101:805-9.
- ⁵⁴ Maturo SC, Mair EA. *Submucosal minimally invasive lingual excision (SMILE): Technique for tonguebase reduction*. Operative Techniques in Otolaryngology 2007;18:29-32.
- ⁵⁵ Chabolle F, Wagner I, Blumen M, et al. *Tongue base reduction with hyoepiglottoplasty: A treatment for severe obstructive sleep apnea*. Laryngoscope 1999;109:1273-80.
- ⁵⁶ Fibbi A, Peirano M, Bertino G. *Mini-invasive surgical approach for obstructive sleep apnea syndrome (OSAS). A case report*. Acta Otorhinolaryngol Ital 2000;20:129-33.
- ⁵⁷ Friedman M, Hamilton C, Samuelson GC, et al. *Transoral robotic glossectomy for the treatment of obstructive sleep apnea-hypopnea syndrome*. Otolaryngol Head Neck Surg 2012;146:854-62.
- ⁵⁸ Riley RW, Powell NB, Guilleminault C. *Inferior sagittal osteotomy of the mandible with hyoid myotomy-suspension: A new procedure for obstructive sleep apnea*. Otolaryngol Head Neck Surg 1986;94:589-93.
- ⁵⁹ Hörmann K, Baisch A. *How I do it: The hyoid suspension*. Laryngoscope 2004;114:1677-9.
- ⁶⁰ Lewis R. *A modified technique of hyoid advancement*. Operative Techniques in Otolaryngology 2007;18:17-9.
- ⁶¹ Lin H-C, Friedman M, Chang H-W, et al. *The efficacy of multilevel surgery of the upper airway in adults with obstructive sleep apnea/hypopnea syndrome*. Laryngoscope 2008;118:902-8.
- ⁶² Milano F, Mondini S, Billi MC, et al. *The impact of a multidisciplinary approach on response rate of mandibular advancing device therapy in patients with obstructive sleep apnoea syndrome*. Acta Otorhinolaryngol Ital 2013;33:337-342.
- ⁶³ Giarda M, Brucoli M, Arcuri F, et al. *Efficacy and safety of maxillomandibular advancement in treatment of obstructive sleep apnoea syndrome*. Acta Otorhinolaryngol Ital 2013;33:43-6.
- ⁶⁴ Gazayerli M, Bleibel W, Elhorr A, et al. *A correlation between the shape of the epiglottis and obstructive sleep apnea*. Surg Endosc 2006;20:836-7.
- ⁶⁵ Bhimaraj A, Havaligi N, Ramachandran S. *Rapid reduction of antihypertensive medications and insulin requirements after tracheostomy in a patient with severe obstructive sleep apnea syndrome*. J Clin Sleep Med 2007;3:297-9.
- ⁶⁶ Campanini A, De Vito A, Frassinetti S, et al. *Role of skin-lined tracheotomy in obstructive sleep apnea syndrome: personal experience*. Acta Otorhinolaryngol Ital 2004;24:68-74.

Received: December 12, 2013 - Accepted: January 1, 2014

HEAD AND NECK

Combined chemoradiotherapy with local microwave hyperthermia for treatment of T3N0 laryngeal carcinoma: a retrospective study with long-term follow-up

Trattamento radiochemioterapico combinato con l'ipertermia locale a microonde nel trattamento dei carcinomi laringei T3N0: studio retrospettivo e follow-up a lungo termine

V. KOULOULIAS^{1,4}, S. TRIANTOPOULOU¹, J. VROUVAS², K. GENNATAS³, N. OUZOUNOGLOU⁴, J. KOUVARIS⁵, P. KARAIKOS², P. AGGELAKIS², C. ANTYPAS⁵, A. ZYGOGIANNI⁵, K. PAPAVALIIOU⁵, K. PLATONI¹, N. KELEKIS¹

¹ 2nd Department of Radiology, Radiotherapy Unit, Attikon University Hospital, XAIDARI, Greece; ² Center of Radiation Oncology, Ygeia Hospital, Athens, Greece; ³ Medical Oncology Unit, Aretaieion University Hospital, Athens, Greece; ⁴ Microwave and Optical Fibers Laboratory, Electrical and Computer Engineering, National Technical University of Athens, Greece; ⁵ 1st Department of Radiology, Radiotherapy Unit, Aretaieion University Hospital, Athens, Greece

SUMMARY

The purpose of our study was to test the efficacy and toxicity of hyperthermia in conjunction with chemoradiotherapy for T3N0 laryngeal cancer. From 1997-2006, 25 patients diagnosed with T3N0 laryngeal carcinoma who denied laryngectomy were selected for this retrospective study. Patients received a total dose of 70 Gy (2 Gy per fraction, 5 days per week) in combination with 6 weekly sessions of hyperthermia, in addition to weekly cisplatin chemotherapy. The hyperthermia device was operated as a 433 MHz microwave heating with water loaded and water-cooled waveguides. The temperature was monitored subcutaneously in the skin under the aperture of the waveguide. The median follow-up was 60 months, while 23 of 25 patients (92%) presented complete response to treatment. The two patients that did not respond to thermoradiotherapy underwent total laryngectomy, and during follow-up were alive and free of disease. According to EORTC/RTOG criteria, toxicity was mild: three patients (12%) presented grade III, eight (32%) presented grade II and 14 (56%) presented grade I acute skin toxicity. Grade III laryngeal late toxicity (vocal cord malfunction due to severe oedema) was noted in two patients (8%) at 6-8 months post-thermo-chemoradiotherapy. Tmin was correlated (Spearman rho, $p < 0.05$) with response to treatment as well as with acute skin toxicity and laryngeal function. When a patient with T3N0 laryngeal carcinoma denies laryngectomy, an alternative treatment is combined thermo-chemoradiotherapy which seems to be effective and generally tolerable with radiation-induced skin toxicity and/or late side effects. A larger patient cohort is needed to confirm these results.

KEY WORDS: Hyperthermia • Laryngeal cancer • Radio-chemotherapy • Toxicity • Follow-up

RIASSUNTO

Col presente lavoro abbiamo voluto testare l'efficacia e la tossicità del trattamento combinato dei carcinomi laringei T3N0 mediante ipertermia e radio-chemioterapia. Per questo studio retrospettivo abbiamo selezionato 25 pazienti, trattati fra il 1997 e il 2006, ai quali era stato diagnosticato un carcinoma laringeo con stadiazione T3N0, che avevano rifiutato la laringectomia come possibile trattamento. Tutti i pazienti sono stati sottoposti ad una dose di 70 Gy di radioterapia (2Gy per frazione per 5 giorni alla settimana) in combinazione con 6 sessioni di ipertermia a cadenza settimanale. I pazienti sono stati inoltre sottoposti ad un trattamento chemioterapico settimanale con cis-platino. L'ipertermia è stata ottenuta mediante un generatore di microonde a 433 MHz con un sistema direzionale raffreddato ad acqua. La temperatura è stata monitorata a livello sottocutaneo in corrispondenza della porzione terminale del sistema direzionale per le microonde. La mediana del follow-up è stata di 60 mesi, nei quali 23 dei nostri 25 pazienti (92%) ha presentato una remissione completa. Nei due pazienti non responsivi alla termo-radioterapia si è proceduto all'esecuzione di una laringectomia totale, ed in corso di follow-up entrambi sono risultati essere vivi e liberi da malattia. Se valutata secondo i criteri dell'EORTC/RTOG la tossicità rilevata è stata leggera: 3 pazienti (12%) hanno presentato un grado III di tossicità cutanea acuta, otto (32%) un grado II e 14 (56%) un grado I. In due pazienti (8%) è stato registrato, a 6-8 mesi dalla termo-chemioterapia una tossicità laringea ritardata di grado III, con edema severo delle corde vocali. La temperatura minima registrata ha mostrato una correlazione sia con la risposta al trattamento (Spearman rho, $p < 0,05$) sia con la tossicità cutanea acuta e la funzione laringea. Nei casi in cui un paziente con un carcinoma T3N0 della laringe rifiuta la laringectomia, la termo-chemioterapia si propone come un'alternativa efficace caratterizzata da effetti collaterali tollerabili quali la tossicità cutanea radioindotta o effetti indesiderati tardivi. La conferma dei nostri dati richiede tuttavia l'analisi di una casistica più ampia.

PAROLE CHIAVE: Ipertermia • Carcinoma laringeo • Radio-chemioterapia • Tossicità • Follow-up

Introduction

Hyperthermia, the elevation of tumour temperature above 42°C, is an anticancer modality that can be used for the treatment of many types of cancer. Hyperthermia is usually applied in conjunction with other therapeutic modalities such as radiotherapy, as their mechanisms of action are complimentary¹. It has been observed that at high temperatures cell death is mainly due to protein denaturation which causes alteration in cell structures and changes in enzyme complexes that are required for DNA synthesis and repair². Radioresistant cancer cells that are hypoxic, acidotic and nutrient deprived, are sensitive to hyperthermia. In addition, hyperthermia and radiotherapy are effective in different phases of the cell cycle. Hyperthermia affects tumour blood flow and oxygenation resulting in enhancement of radiation response³. Many trials have shown that the combined therapy is effective for the treatment of cancer and improves clinical response and local control of disease^{4,5}.

Advanced stage laryngeal carcinoma is associated with poor prognosis and greatly affects the patients' quality of life⁶. The most common treatment modalities are either laryngectomy followed by chemoradiotherapy or radiotherapy alone⁷. The incidence of laryngectomy post-radiotherapy due to local relapse for T3 laryngeal carcinoma remains high^{7,8}. Chemoradiotherapy offers improved clinical outcome in comparison to irradiation alone⁹⁻¹¹. There are patients, however, who deny the above therapeutic approach due to the poor quality of life caused by laryngectomy.

The purpose of our study was to test in a retrospective manner, whether the combination of hyperthermia and irradiation is an effective treatment modality for patients who suffer from T3N0 laryngeal carcinoma and refuse laryngectomy.

Materials and methods

From 1997-2006, 25 patients diagnosed with T3N0 laryngeal carcinoma who denied laryngectomy were selected to participate in this retrospective study. The pre-treatment evaluation included blood test, clinical examination and CT scan of the cervix and thorax. The treatment of hyperthermia took place either in the Aretaieion University Hospital or at the Radiotherapy Department of YGEIA Hospital. The treatment planning used was either PLATO (Nucletron, The Netherlands) or HELAX-TMS (Nucletron B.V., Veenendaal, The Netherlands) depending on the radiotherapy department where irradiation was performed. The technique used in all cases was 3D conformal radiotherapy with CT-based image treatment planning. On all cases, the treatment delivery was performed with a 6MV LINAC SIEMENS MX. There were three phases of irradiation according to the technique of shrinking fields. In the first phase, together with the primary disease, the

levels of IIA, IIB, III and IV were included up to 46 Gy, although no evidence for nodal disease was confirmed. However, this was done due to clinical (radiological) staging of the disease and not surgical (pathological) confirmation. Phase 2 included the laryngeal region with levels IIA and III (due to the close location with the larynx) cervical lymph nodes up to 56-58 Gy. The third phase included only the larynx up to 70 Gy. During phases 2 and 3, the spinal cord was excluded from the irradiation fields. An immobilization mask was used in all cases, while a conventional simulation was used before irradiation for confirmation of portals. In all patients, portal film was taken once per week throughout the entire radiotherapy schedule. Patients received a total dose of 70 Gy (2 Gy per fraction, 5 days per week) in combination with 6 weekly sessions of microwave hyperthermia. The hyperthermia session was performed weekly every Monday or Tuesday throughout the radiotherapy, at the left or the right side of the neck alternately by the weekly session. The hyperthermia device was operated as a 433 MHz microwave heating with water-loaded and water-cooled waveguides¹². The applicator used was a rectangular waveguide 6 × 7 cm with an effective field size of 5 × 6 cm (Fig. 1). The microwave device had an omitted power of 100 Watts RMS. The temperature was monitored with a thermocouple, while temperature measurement was made with 2 sec of power interruption. The temperature was monitored subcutaneously in the skin under the aperture of the waveguide. Thermal parameters such as T_{min} and T_{max} were always monitored. The hyperthermia session was prescribed as an one-hour heating with temperature range between 42-45°C. Radiation induced toxicity was evaluated with the EORTC/RTOG toxicity criteria¹³. All patients received concurrent weekly cisplatin 40 mg/m² as a radio-sensitizing agent for radiotherapy. All patients signed informed consent for the combined treat-




Fig. 1. Rectangular waveguide operating at 433 MHz used for local hyperthermia.

ment according to the Declaration of Helsinki for Human Rights. All patients signed an informed consent that they agreed to have a combination of chemotherapy, radiotherapy and hyperthermia since they have denied surgical intervention. They were informed that the best practice for them would be laryngectomy, while the response to chemoradiotherapy and hyperthermia would not be the same as local excision. Moreover, they were informed about the potential toxicity of the combined treatment. Since there was no reimbursement for hyperthermia, the local board approved the inclusion of hyperthermia, while patients for this certain tumour location received 1-hour local thermotherapy without charge.

According to the study protocol, patients that were included should meet the following criteria:

- Histologically proven glottic T3 squamous cell carcinoma.
- Contrast – enhanced CT scan performed before treatment.
- Confirmation of clinical staging of cervical lymph nodes, in terms of N0, with MRI study of the neck.
- Normal electrocardiogram and normal chest–wall X–ray.
- Age 18–80 years old and life expectancy > 2 months.
- Karnofsky performance status (KPS) > 70% and World Health Organization Status (WHO) 0 - 1.
- Laboratory values (performed one week before study):
Absolute neutrophil count > 3000/mm³;
Platelet count > 100,000/mm³;
Haemoglobin > 10 g/dl.
- Urea and serum creatinine lower than upper limit of laboratory normal.
- Total and direct bilirubin lower than upper limit of laboratory normal.
- Serum glutamic – oxaloacetic transaminase, serum glutamic – pyruvic transaminase lower than upper limit of laboratory normal.
- Alkaline phosphatase lower than upper limit of laboratory normal.
- Patient denial for laryngectomy.

The exclusion criteria for the study were:

- Age > 80 years old.
- Patients with pacemaker.
- Patients with implanted electronic devices.
- Patients with implanted stents.
- Patients with fever before treatment.

The primary endpoints were response to treatment according to RECIST criteria¹⁴ together with loco-regional control rate and overall survival. The secondary endpoint was treatment-related toxicity. All patients underwent CT and/or MRI study together with direct laryngoscopy every 3 months the first year and every six months thereafter. According to the local protocol in our department for follow-up in head and neck patients, the intention was to follow-up patients for 5 years post-treatment.

Statistical analysis

The correlation between thermal parameters and toxicity grading (acute and late) as well as response rate was performed with the Spearman rho non-parametric test. The Kaplan-Meier method was used for survival analysis. Comparison of KPS values before and after treatment was done with the Wilcoxon non-parametric test. The significance level in all cases was taken at the level of 0.05. All analyses were performed with SPSS ver. 10 (IL, USA).

Results

In our study, 25 patients with laryngeal carcinoma who received local hyperthermia combined with chemo-radiotherapy were included in this retrospective study. According to CT images before treatment, the mean tumour volume was 3.26 (\pm 0.19) cm³, with a range of 2.9–3.5 cm³. The median follow-up was 60 months (range 60–72 months), while 23 of 25 patients (92%) presented complete response to treatment. Concerning the two failures, one presented stable disease at three months post-treatment, while the other had progressive disease at 6 months post-treatment. The two patients that did not respond to thermoradiotherapy underwent total laryngectomy with clear margins and lymph node dissection of levels II and III, with pathological confirmation of N0 disease. During follow-up these patients remained alive and free of disease. Toxicity was mild: three patients (12%) presented grade III, eight (32%) presented grade II and 14 (56%) presented grade I acute skin toxicity. There was an increased acute skin toxicity (mainly erythema) in the area of hyperthermia treatment at the footprint of the antenna. Moderate late toxicity consisted of vocal cord malfunction due to severe oedema (grade III), and was noted in two patients (8%) at 6–8 months post-thermoradiotherapy. The loco-regional control rate at 5 years is shown in Figure 2. Acute and late skin toxicity together with the late laryngeal toxicity related to laryngeal function is reported in Table I.

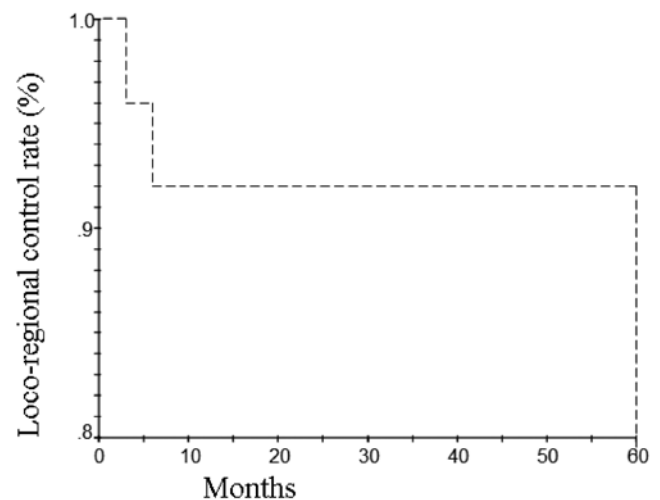


Fig. 2. Loco-regional control rate for a median follow-up of five years.

Table I. Acute/late skin toxicity and late laryngeal toxicity according to EORTC/RTOG criteria.

	Grade I	Grade II	Grade III
Acute skin toxicity	Follicular, faint or dull erythema / epilation / dry desquamation / decreased sweating 14/25 (56%)	Tender or bright erythema, patchy moist desquamation / moderate oedema 8/25 (32%)	Confluent, moist desquamation other than skin folds, pitting oedema 3/25 (12%)
Late skin toxicity	Slight atrophy; pigmentation change 5/25 (20%)	Patch atrophy; moderate telangiectasia 2/25 (8%)	Marked atrophy; gross telangiectasia -
Late laryngeal toxicity	Hoarseness; slight arytenoid oedema 19/25 (76%)	Moderate arytenoid edema; chondritis 4/25 (16%)	Severe oedema; severe chondritis 2/25 (8%)

Table II. Spearman rho correlation between thermal parameters, response rate, EORTC/RTOG acute skin toxicity and laryngeal function.

		Tmax	Response (yes/no)	EORTC/RTOG (acute)	Laryngeal function (EORTC/RTOG late)
Tmin	rho	0.69	-0.47	0.54	-0.48
	p	< 0.01	0.017	0.005	0.021
Tmax	rho		-0.31	0.78	-0.45
	p		0.136	< 0.01	0.029
Response (yes/no)	rho			-0.25	0.74
	p			0.223	< 0.01
EORTC/RTOG (acute)	rho				-0.52
	p				0.012

During the hyperthermia session, thermal parameters such as Tmin and Tmax were monitored for all patients. From our statistical analysis, it was found that Tmax correlated with Tmin (Spearman rho = 0.69, $p < 0.01$), acute skin toxicity (Spearman rho = 0.78, $p < 0.01$) and late reactions such as laryngeal function (Spearman rho = -0.45, $p < 0.029$). A correlation was found between Tmin and response to treatment (Spearman rho = -0.47, $p < 0.017$) as well as acute toxicity (Spearman rho = 0.54, $p < 0.005$) and laryngeal function (Spearman rho = -0.48, $p = 0.021$). All these correlations were statistically significant. Finally, statistically significant correlation was noted between laryngeal function and response as well as acute toxicity (Spearman rho = 0.74, $p < 0.01$ and Spearman rho = -0.52, $p = 0.012$ respectively). The results of the statistical analysis are presented in Table II. No haematological toxicity was seen in any case. The mean Karnofsky performance status score before and after combined treatment was 88.4% (± 8.9) and 88.2% (± 9.8), respectively ($p = 0.805$, Wilcoxon test).

Discussion

The treatment of choice for laryngeal carcinoma consists of surgery in addition with chemoradiotherapy or radiotherapy alone^{7 15}. This treatment often causes toxicity and is related with limited local control and survival^{6 15}. Studies have shown that total laryngectomy has a survival ad-

vantage over chemoradiation or radiation alone. Chen¹⁰ demonstrated that considering one-year survival, the hazard ratio (HR) is 1.0 for total laryngectomy, while for chemoradiotherapy is 1.35 and 1.51 for radiotherapy alone. Concerning 4-year survival, these ratios were 1.0, 1.24 and 1.39, respectively. Corry⁷ showed that for patients treated with chemoradiotherapy without surgical treatment, overall survival was disappointing. Three-year overall survival and 5-year overall survival were 67% and 45%, respectively. The rates for 3-year local disease control and 5-year local disease control were 83% and 77%, respectively. In another study, patients treated with either induction chemotherapy and hyperfractionated radiation therapy or chemoradiation overall survival was 66%; an anatomically intact larynx was retained in 79% of patients, but 30% never resumed their pretreatment organ function⁸. In addition, many trials demonstrate that chemoradiotherapy leads to better therapeutic results than radiotherapy alone^{9 11 16-18}.

Hyperthermia seems very promising in combination with radiotherapy, showing an enhancement in response to irradiation¹⁹. Several studies have shown the potential radio-sensitization both in animals and in humans^{20 21}. In our study, we investigated if the combination of local hyperthermia with chemoradiotherapy in patients who denied laryngectomy is an effective treatment for T3N0 laryngeal cancer. We also assessed the acute and late toxicity of this therapeutic modality. Our results showed that for T3N0 the complete response rate was up to 92% after

combined thermo-chemoradiotherapy. Only two patients did not respond to treatment and underwent total laryngectomy. Hinohira²² showed that for patients suffering from laryngeal carcinoma and treated with hyperthermia and chemoradiation, the response rate (complete and partial response) was 100%. Other studies testing the combination of irradiation and hyperthermia in patients suffering from head and neck cancer showed that the complete response rates ranged from 76-78.6%²³⁻²⁶. The trials of Engin²⁷ and Gabriele²⁸ showed complete response rates of 58% and 40%, respectively. In the trial of Serin, the local complete response rate of patients treated with hyperthermia and chemoradiotherapy was 82%²⁹. Chang³⁰ treated patients with head and neck cancer (stage IV) with a combination of hyperthermia and chemotherapy with a response rate (complete and partial response) of 37.5%. The median follow-up of our patients was 60 months, and a significant 5-year survival rate was observed. In comparison with the above mentioned studies, treatment outcome in our study appears to be high (response rate up to 92%), whereas the rates for 5-year survival referred to in the current literature concerning thermoradiotherapy are 24%, 50-55% and 68.2%^{23 24 31}.

The acute toxicity observed by combined treatment was mild; vocal cord malfunction was noted as late toxicity at 6-8 months post thermoradiotherapy in only two patients. It is well established in many trials that hyperthermia in addition to radiation therapy is well tolerated and is not associated with severe side effects^{23 27 28}.

In studies that tested the correlation between thermal parameters of hyperthermia and clinical outcome of patients with head and neck cancer, there was an impact of thermoradiotherapy on both therapeutic outcome²⁸ and morbidity²⁷, although this correlation did not reach statistical significance. From our statistical analysis, it was found that Tmax correlated with Tmin (Spearman rho = 0.69, $p < 0.01$) and acute (Spearman rho = 0.78, $p < 0.01$) and late reaction-laryngeal function (Spearman rho = -0.45, $p < 0.029$). A correlation was also found between Tmin with response (Spearman rho = -0.47, $p < 0.017$), acute toxicity (Spearman rho = 0.54, $p < 0.005$) and laryngeal function (Spearman rho = -0.48, $p = 0.021$). All these correlations were statistically significant. In a previous study³², we reported on the impact of Tmin with response of superficial tumours. In addition, the reason for the correlation of Tmin with high radiation induced morbidity might be the elevated temperatures affecting both skin tolerability and glottic cord functionality, in terms of the radiosensitivity that the thermotherapy produces in normal tissues. Finally, statistically significant correlation was noted between laryngeal function as well as response and acute toxicity (Spearman rho = 0.74, $p < 0.01$ and Spearman rho = -0.52, $p = 0.012$, respectively). The reason for this is obviously the highly deposited microwave power in both the glottic tumour and the normal surrounding tis-

ues, since hyperthermia has the disadvantage of the lack of focusing only in cancerous tissue. The effective field size of our hyperthermia applicator is 5 × 6 cm, by including both anatomically normal structures and the glottic tumour in the hyperthermia field.

Hyperthermia seems to play an important role in the cure of head and neck cancer, since it was observed that when hyperthermia is added to radiotherapy the response rates are significantly higher than those of radiation therapy alone. Valdagni, reported the results of a randomized study on 44 metastatic squamous cell cervical lymph nodes comparing radical irradiation vs. radical irradiation plus twice a week local microwave hyperthermia³³. They showed that the complete response rate for patients treated with irradiation alone was 37% and increased to 82% with the addition of hyperthermia. Huilgol²⁶, in a randomized trial with 56 patients, found a statistically significant difference in complete response: 42.4% for irradiation alone and 78.6% for thermoradiotherapy. Hoshima³¹, comparing thermochemoradiotherapy in 18 patients with 25 recurrent lesions vs. chemoradiotherapy in 22 patients with 27 recurrent lesions, reported similar results with combined thermo-chemotherapy with a total response rate up to 92.0%, while there was a significant difference in complete response between the two groups. In the same study, the 5-year cumulative local control was 68.2% vs. 22.2% in favour of hyperthermia.

Several studies have been published on radical irradiation ± chemotherapy instead of laryngectomy for T3N0 disease. Hinerman³⁴ studied 68 patients who received radiotherapy without chemotherapy and reported a local control rate up to 78% and overall survival up to 52%. Bergqvist³⁵ retrospectively reported a 5-year survival rate up to 72% for patients who underwent radiotherapy. Jackson³⁶, in 70 patients with T3 disease, reported a 5-year recurrence free rate of 65% with radiotherapy alone. It should not be underestimated that the high loco-regional response rate in our study with complete response was up to 92%. There are three possible reasons for this result. In our opinion, the first is the addition of local hyperthermia to the laryngeal area. The second is the fact that all of our patients had a tumour volume less than 3.5 cm³. Indeed, Lee³⁷ as well as Pameijer³⁸ reported excellent results with larynx preservation up to 85-92% when tumour volume was less than 3.5 cm³, such as in our case. The third is the prophylactic irradiation of clinical N0 lymph nodes, even without surgical dissection and consequent pathological staging. In fact, Yu³⁹, in 83 patients with T3-4 laryngeal tumours, reported a neck recurrence rate of clinical N0 patients of 14.3%. It should not be underestimated that the frequency used for local hyperthermia was 433 MHz instead of 915 MHz, which is commercially used for superficial heating. The approximate penetration depth for 433 MHz and 915 MHz is 3.5 cm and 2 cm respectively, by deeper heating with our applicator.

Other than the small number of patients and the retrospective inclusion of the patients, the main weakness of the present study is the lack of objective temperature measurements in the tumour, since monitoring with the thermocouple was performed on the skin surface. However, it seems difficult to put a thermocouple in the larynx of the patient without general anaesthesia. Although it was not available in our clinical study, non-invasive thermometry with magnetic resonance using proton resonance frequency shift⁴⁰ would be a potential solution to this problem.

Conclusions

In the present study, we report our experience with combined hyperthermia and chemoradiotherapy for T3N0 squamous cell carcinoma of the glottis. This retrospective study covers a long period of time, due to the low number of patients who met the inclusion criteria. Indeed, the incidence of patients with T3N0 laryngeal carcinoma who denied laryngectomy is low, although all consecutive patients were referred in our department from several centres in Athens.

The quality of life for patients after laryngectomy and radiotherapy is definitely worse than those with chemoradiotherapy⁴¹. However, the quality of life is sometimes worse in patients who underwent combined and multimodality therapy rather than monotherapy with surgery or radiotherapy alone, while in some cases patients considered the laryngectomy as a liberation⁴². However, in our case, patients simply avoided laryngectomy as their first line of treatment. The response rate of 92% reported here is one of the highest in the current literature, especially for T3N0 glottic carcinoma, where the commonly-reported response rate is 60-70%^{7-11 16-18 36 43}. Although no quality of life measurements were performed in our study, the KPS score did not change significantly before and 3 months post-combined treatment. When the patient with T3N0 laryngeal carcinoma denies laryngectomy, an alternative treatment can be combined thermo-chemoradiotherapy, which seems effective and generally tolerable although it is associated with radiation induced skin toxicity and late side effects.

Our results seem encouraging, and more patients are needed to confirm the effectiveness and toxicity of this combined treatment for cure of laryngeal carcinoma. However, due to the retrospective design of the present study, it should be mentioned that no definite conclusions can be reached, and that the final results are likely to be related to hyperthermia only, since a tri-modality treatment was applied to all cases. Thus, a randomized study with chemoradiotherapy vs. thermo-chemoradiotherapy is needed to confirm confirmation these results. Lastly, the danger for bias in a retrospective study is always present: in our case, all patients had a tumour volume less than 3.5 cm³ which is a favourable factor.

References

- 1 Kouloulis VE. *Hyperthermia in solid tumors*. Aktinotekhnologia 2003;12:38-45.
- 2 van der Zee J. *Heating the patient: a promising approach?* Ann Oncol 2002;13:1173-84.
- 3 Jones EL, Oleson JR, Prosnitz LR, et al. *Randomized trial of hyperthermia and radiation for superficial tumors*. J Clin Oncol 2005;23:3079-85.
- 4 van der Zee J, Vujaskovic Z, Kondo M, et al. *The Kadota Fund International Forum 2004-Clinical Group consensus*. Int J Hyperthermia 2008;24:111-22.
- 5 Engin K, Leeper DB, Tupchong L, et al. *Thermoradiotherapy in the management of superficial malignant tumors*. Clin Cancer Res 1995;1:139-45.
- 6 Machtay M, Moughan J, Trotti A, et al. *Factors associated with severe late toxicity after concurrent chemoradiation for locally advanced head and neck cancer: an RTOG analysis*. J Clin Oncol 2008;26:3582-9.
- 7 Corry J, Rischin D, Cotton S, et al. *Larynx preservation with primary non-surgical treatment for loco-regionally advanced larynx cancer*. J Med Imaging Radiat Oncol 2011;55:229-35.
- 8 Guadagnolo BA, Haddad RI, Posner MR, et al. *Organ preservation and treatment toxicity with induction chemotherapy followed by radiation therapy or chemoradiation for advanced laryngeal cancer*. Am J Clin Oncol 2005;28:371-8.
- 9 Hoffman HT, Porter K, Karnell LH, et al. *Laryngeal cancer in the United States: changes in demographics, patterns of care, and survival*. Laryngoscope 2006;116:1-13.
- 10 Chen AY, Fedewa S, Pavluck A, et al. *Improved survival is associated with treatment at high-volume teaching facilities for patients with advanced stage laryngeal cancer*. Cancer 2010;116:4744-52.
- 11 Gourin CG, Conger BT, Sheils WC, et al. *The effect of treatment on survival in patients with advanced laryngeal carcinoma*. Laryngoscope 2009;119:1312-7.
- 12 Uzunoglu NK, Angelikas EA, Cosmidis PA. *A 432-MHz Local hyperthermia system using an indirectly cooled, water-loaded waveguide applicator*. IEEE Transactions on Microwave Theory and Techniques 1987;35:106-11.
- 13 Cox JD, Stenz J, Pajak TF. *Toxicity criteria of the radiation therapy oncology group (RTOG) and the European organization for research and treatment of cancer*. Int J Radiat Oncol Biol Phys 1995;31:1341-6.
- 14 Therasse P, Arbuck SG, Eisenhauer EA, et al. *New guidelines to evaluate the response to treatment in solid tumours*. J Natl Cancer Inst 2000;92:205-16.
- 15 Lefebvre J-L. *Larynx preservation*. Curr Opin Oncol 2012;24:218-22.
- 16 Hartl DM, Ferlito A, Brasnu DF, et al. *Evidence-based review of treatment options for patients with glottic cancer*. Head Neck 2011;33:1638-48.
- 17 Wolf GT, Hong WK, Gross Fisher S. *Induction chemotherapy plus radiation compared with surgery plus radiation in patients with advanced laryngeal cancer. The Department of Veterans Affairs Laryngeal Cancer Study Group*. N Engl J Med 1991;324:1685-90.
- 18 Forastiere AA, Goepfert H, Maor M, et al. *Concurrent*

- chemotherapy and radiotherapy for organ preservation in advanced laryngeal cancer. *N Engl J Med* 2003;349:2091-8.
- 19 Triantopoulou S, Efstathopoulos E, Platoni K, et al. *Radiotherapy in conjunction with superficial and intracavitary hyperthermia for the treatment of solid tumors: survival and thermal parameters*. *Clin Transl Oncol* 2013;15:95-105.
 - 20 Sawas-Dimopoulou C, Papavasilion C, Iordanou I, et al. *Comparative evaluation of combined irradiation and hyperthermia versus irradiation alone*. *Eur Radiol* 1994;4:167-71.
 - 21 van der Zee J, Vujaskovic Z, Kondo M, et al. *The Kadota Fund International Forum 2004 – clinical group consensus*. *Int J Hyperthermia* 2008;24:111-22.
 - 22 Hinohira Y, Yumoto E, Hyodo M, et al. *Thermoradiotherapy combined with daily administration of low dose cisplatin for locally advanced laryngeal carcinoma*. *Gan To Kagaku Ryoho* 1997;24:1961-5.
 - 23 Amichetti M, Romano M, Busana L, et al. *Hyperfractionated radiation in combination with local hyperthermia in the treatment of advanced squamous cell carcinoma of the head and neck: a phase I-II study*. *Radiother Oncol* 1997;45:155-8.
 - 24 Amichetti M, Zurlo A, Cristoforetti L, et al. *Prognostic significance of cervical lymph nodes density evaluated by contrasted computer tomography in head and neck squamous cell carcinoma treated with hyperthermia and radiotherapy*. *Int J Hyperthermia* 2000;16:539-47.
 - 25 Huilgol NG, Gupta S, Dixit R. *Chemoradiation with hyperthermia in the treatment of head and neck cancer*. *Int J Hyperthermia* 2010;26:21-5.
 - 26 Huilgol NG, Gupta S, Sridhar CR. *Hyperthermia with radiation in the treatment of locally advanced head and neck cancer: a report of randomized trial*. *J Cancer Res Ther* 2010;6:492-6.
 - 27 Engin K, Tupchong L, Waterman FM, et al. *Thermoradiotherapy for superficial tumour deposits in the head and neck*. *Int J Hyperthermia* 1994;10:153-64.
 - 28 Gabriele P, Ferrara T, Baiotto B, et al. *Radio hyperthermia for re-treatment of superficial tumours*. *Int J Hyperthermia* 2009;25:189-98.
 - 29 Serin M, Erkal HS, Cakmak A. *Radiation therapy, cisplatin and hyperthermia in combination in management of patients with carcinomas of the head and neck with N2 or N3 metastatic cervical lymph nodes*. *Radiother Oncol* 1999;50:103-6.
 - 30 Chang P, Sapozink MD, Grunberg SM, et al. *Unresectable primary and recurrent head and neck tumors: effect of hyperthermia and carboplatin--preliminary experience*. *Radiology* 2000;214:688-92.
 - 31 Hoshina H, Takagi R, Tsurumaki H, et al. *Clinical result of thermochemoradiotherapy for advanced head and neck cancer*. *Gan To Kagaku Ryoho* 2001;28:331-6.
 - 32 Kouloulis V, Dardoufas C, Kouvaris J, et al. *Combined radiotherapy and hyperthermia in the treatment of superficial carcinomas. The experience of the University of Athens Medical School*. *J BUON* 2001;6:245-53.
 - 33 Valdagni R, Amichetti M, Pani G. *Radical radiation alone versus radical radiation plus microwave hyperthermia for N3 (TNM-UICC) neck nodes: a prospective randomized clinical trial*. *Int J Radiat Oncol Biol Phys* 1988;15:13-24.
 - 34 Hinerman RW, Mendenhall WM, Morris CG, et al. *T3 and T4 true vocal cord squamous carcinomas treated with external beam irradiation: a single institution's 35-year experience*. *Am J Clin Oncol* 2007;30:181-5.
 - 35 Bergqvist M, Brodin O, Pouzon A, et al. *Radiation treatment of T1-T4 squamous cell carcinoma of the larynx: a retrospective analysis and long-term follow-up of 135 patients*. *Anti-cancer Res* 2002;22:1239-42.
 - 36 Jackson SM, Hay JH, Flores AD. *Local control of T3N0 glottic carcinoma by 60 Gy given over five weeks in 2.4 Gy daily fractions. One more point on the biological effective dose (BED) curve*. *Radiother Oncol* 2001;59:219-20.
 - 37 Lee WR, Mancuso AA, Saleh EM, et al. *Can pretreatment computed tomography findings predict local control in T3 squamous cell carcinoma of the glottic larynx treated with radiotherapy alone?* *Int J Radiat Oncol Biol Phys* 1993;25:683-7.
 - 38 Mendenhall WM, Parsons JT, Mancuso AA, et al. *Definitive radiotherapy for T3 squamous cell carcinoma of the glottic larynx*. *J Clin Oncol* 1997;15:2394-402.
 - 39 Yu WB, Zeng ZY, Chen FJ, et al. *Correlation of cervical lymphatic metastasis to prognosis of T3-T4 glottic cancer*. *Ai Zhong* 2006;25:1271-4.
 - 40 Ludemann L, Wlodarczyk W, Nadobny J, et al. *Non-invasive magnetic resonance thermography during regional hyperthermia*. *Int J Hyperthermia* 2010;26:273-82.
 - 41 Terrell JE, Fisher SG, Wolf GT. *Long-term quality of life after treatment of laryngeal cancer. The Veterans Affairs Laryngeal Cancer Study Group*. *Arch Otolaryngol Head Neck Surg* 1998;124:964-71.
 - 42 Succo G, Bramardi F, Airoidi M, et al. *Quality of life after treatment in patients with laryngeal carcinoma*. *Acta Otorhinolaryngol Ital* 1997;17:32-44.
 - 43 Bourhis J, Lefebvre JL, Temam S, et al. *Larynx preservation: nonsurgical approaches*. *Cancer Radiother* 2004;8:24-8.

Received: August 11, 2012 - Accepted: June 12, 2013

Address for correspondence: V. Kouloulis, Radiation Oncology, Medical School, National Kapodistrian University Athens, Greece, Attikon University Hospital, 2nd Dpt Radiology, Rimini 1, XAIDARI, 12462, Greece. E-mail: vkouloul@ece.ntua.gr

LARYNGOLOGY

Direct autofluorescence during CO₂ laser surgery of the larynx: can it really help the surgeon?

Autofluorescenza diretta in corso di laserchirurgia transorale con laser CO₂: un reale aiuto per il chirurgo?

G. SUCCO¹, P. GAROFALO¹, M. FANTINI¹, V. MONTICONE¹, G.C. ABBONA², E. CROSETTI³

¹ ENT University Department, University of Torino, San Luigi Gonzaga Hospital, Turin, Italy; ² Pathology Department, Martini Hospital of Torino, Turin, Italy; ³ ENT Department, Martini Hospital of Torino, Turin, Italy

SUMMARY

Herein we assessed the impact of direct autofluorescence during intraoperative work-up on obtaining superficial free resection margins, identifying new areas of malignant transformation and altering disease-free survival and local control at 3 years in patients submitted to transoral laser surgery (TLS) for early glottic cancer. Prospective cohort evaluation was carried out on the diagnostic accuracy of the superficial extent and TNM staging in 73 patients with glottic carcinoma undergoing transoral CO₂ laser surgery. The use of direct autofluorescence was associated with superficial disease-free margins in 97.2% of cases, and with superficial close margins in 2.8%. The improvement in diagnostic accuracy was 16.4%; in 8.2% of cases, there was upstaging of the TNM classification (in one case, a second neoplastic area in a different laryngeal site was observed and considered to be a second endolaryngeal primary). The sensitivity of direct autofluorescence was 96.5% with a specificity of 98.5%. Overall, 3-year disease-specific survival and local control with laser alone were, respectively: T1a (97.5%, 100%), T1b (86.7%, 86.7%), T2 (88.9%, 88.9%). This study demonstrates that direct autofluorescence can help to identify positive superficial margins, and has a favourable impact on disease-specific survival and local control at 3 years.

KEY WORDS: Autofluorescence • Transoral laser surgery • Resection margins • Endoscopic surgery • Laryngeal cancer • Glottic tumour

RIASSUNTO

Obiettivo di questo studio è stato valutare l'impatto dell'autofluorescenza diretta durante il work-up intraoperatorio nell'ottenere margini di resezione superficiale indenni, nell'individuare nuove aree di trasformazione maligna e nel migliorare a 3 anni la sopravvivenza libera da malattia/controllo locale nei pazienti sottoposti a laserchirurgia transorale (TLS) per cancro della glottide in fase iniziale. (Disegno dello studio: studio di coorte prospettico). Una valutazione prospettica sull'accuratezza diagnostica dell'estensione superficiale e sulla stadiazione TNM è stata condotta in 73 pazienti con carcinoma della glottide sottoposti a laserchirurgia transorale. L'utilizzo dell'autofluorescenza diretta ha determinato margini superficiali liberi da malattia nel 97,2 % dei casi e margini superficiali esigui nel 2,8 %. Un miglioramento nell'accuratezza diagnostica si è verificato nel 16,4 % mentre nell'8,2 % dei casi si è assistito ad un up-staging della classificazione TNM (in un caso un'area neoplastica in una sede laringea distinta è stata considerata un secondo tumore endolaringeo primitivo). La sensibilità dell'autofluorescenza diretta è stata del 96,5%, la specificità del 98,5%. Nel complesso la sopravvivenza malattia-specifica ed il controllo locale con laser a 3 anni sono stati rispettivamente: T1a (97,5 %, 100 %), T1b (86,7%, 86,7%), T2 (88,9%, 88,9%). Concludendo questo studio dimostra che l'autofluorescenza diretta può aiutare il chirurgo nell'identificare i margini superficiali positivi e risulta associata ad un impatto favorevole sulla sopravvivenza malattia-specifica e sul controllo locale a 3 anni.

PAROLE CHIAVE: Autofluorescenza • Chirurgia laser transorale • Margini di resezione • Chirurgia endoscopica • Carcinoma laringeo • Tumore glottico

Acta Otorhinolaryngol Ital 2014;34:174-183

Introduction

Correct loco-regional work-up of laryngeal squamous cell carcinoma (SCC), especially in early stage glottic carcinoma amenable to transoral carbon dioxide laser surgery (TLS), includes accurate endoscopic examination to evaluate the superficial extent of the tumour and precise imaging to assess the extent of depth to muscular, fibrous and cartilage structures and laterocervical lymph node status^{1,2}. Regardless of treatment modality (TLS or radiation therapy), the treatment goals of early stage laryngeal glottic carcinoma are good oncological outcome and preservation of vocal function³.

To optimise the oncological results of TLS, without compromising functional outcomes, many authors have stressed the utility of intraoperative endoscopic work-up with 0° and angled telescopes^{1,4,5} to accurately identify the superficial extent of the tumour and provide disease-free mucosal margins of at least 1-3 mm⁶.

Endoscopic tools for examination of the upper aero-digestive tract, especially autofluorescence and narrow band imaging (NBI), have undergone significant developments in recent years⁷⁻⁹; compared to endoscopic evaluation using white light alone, these endoscopic methods provide important biological information that is useful to improve intraoperative assessment of the superficial extent of the lesion and to identify new areas of malignant transformation that are distinct from the primary lesion.

Oncology in general, and in particular, head and neck oncology, is increasingly oriented towards therapeutic choices that are "custom tailored" to obtain both organ and functional preservation¹⁰⁻¹²; in this regard, a precise definition of the superficial extent of a tumour and correct evaluation of laryngeal motility in addition to high-quality imaging are strategic and fundamental aspects in evaluating all features of the lesion.

Herein, a prospective study was carried out to determine the accuracy of diagnosis of superficial extent and TNM staging in 73 patients with early neoplastic lesions of the glottis undergoing TLS, with the aim of determining whether the intraoperative use of direct autofluorescence helps the surgeon to obtain disease-free resection margins and identify separate areas of malignant transformation. An additional goal was to assess the impact of direct autofluorescence on disease-free survival and local control with laser alone at 3 years in patients submitted to TLS for early glottic cancer.

Materials and methods

In the period between January 2005 and December 2009, a prospective study was carried out at the ENT Department of the University of Turin on 73 patients, all of whom were current smokers (65 males and 8 females; mean age 63 years) affected by a suspected, previously untreated, early

squamous cell carcinoma (SCC) with glottic localisation. Overall, in the same period, autofluorescence endoscopy was applied in a cohort of 286 patients with suspected SCC of the larynx and hypopharynx. However, any case of cancer at a more advanced stage or with localisation other than glottic was excluded from the study to obtain a group characterised by homogeneous lesions, for which endoscopic treatment using TLS was planned.

Pre-operative work-up included physical examination, routine blood test, chest X-ray and careful evaluation of the superficial and depth extent of the tumour, which was preoperatively examined using flexible videolaryngoscopy (Olympus Medical Systems Corporation, Tokyo, Japan) and/or rigid videolaryngoscopy coupled to a high definition television (HDTV) and videolaryngostroboscopy (Karl Storz, Tuttlingen, Germany). Magnetic resonance imaging (MRI) of the neck was performed in cases of bulky T1a and in all cases of T1b and T2 to exclude infiltration of the laryngeal framework and assess the extension of the lesion to the paraglottic and pre-epiglottic spaces. Disease was classified according to the 2002 (6th Edition) Union Internationale Contre le Cancer (UICC)/American Joint Committee on Cancer (AJCC) TNM system¹³.

Demographic characteristics and clinical staging of the study cohort are shown in Table I. All patients were subjected to cordectomy (preferably en bloc technique, in a single procedure) using a CO₂ laser (Sharplan 1055S CO₂ laser; Sharplan, Tel Aviv, Israel) under microlaryngoscopy with superpulse delivery in continuous mode (1 to 5 W), coupled with an AcuBlade micromanipulator (270 mm spot size). The type of resection was graded according to the European Laryngological Society (ELS) Classification which includes six types of cordectomy: subepithelial (type I), subligamental (type II), transmuscular (type III), total (type IV), extended (type V) and anterior commissure (type VI)^{14,15}.

Table I. Demographic characteristics of the study cohort.

No. of patients	73
Gender	
Male	65
Female	8
Age	
Range	48-79 yrs
Mean	63 yrs
TNM staging (level C2)	
Glottic	
T1a	47
T1b	13
T2	13
Impairment of motility	4
Subglottic/supraglottic extension	9

The intraoperative work-up protocol involved examination of the larynx of each patient with direct endoscopy under white light and in direct autofluorescence, in a stepwise fashion. All endoscopies were recorded for documentation and for immediate re-evaluation before proceeding with TLS.

First, the evaluation of the superficial extent of the lesion was carried out using rigid 0° and 70° angled telescopes with white light (WL) coupled to HDTV (Fig. 1A, step 1); on the basis of this assessment, after careful enlargement of the ventricular bands with dilating forceps, the area of excision was marked with several laser spots, maintaining an apparent margin of healthy tissue of approximately 2 mm compared to the visible limits of the suspected neoplastic lesion (Fig. 1B, step 2). Next, an additional endoscopic evaluation with direct autofluorescence was carried out coupled with a 3CCD camera (D-light Autofluorescence System, Karl Storz, Tuttlingen, Germany) using rigid 0° and angled 70° telescopes. In agreement with literature data, any area showing a bright green fluorescence was considered normal, while any well-defined blue/dark violet area compared to the surrounding mucosa was considered positive.

Following re-evaluation with direct autofluorescence, comparing area(s) found by autofluorescence to be positive with the surgical margins outlined by laser spots, all cases were assigned to one of three categories: (a) area of surgical excision analogous to the positive area determined by autofluorescence, (b) area of surgical excision insufficient compared to that found by autofluorescence and (c) area positive by autofluorescence in another site compared to the area of surgical excision.

In all cases where the areas positive by autofluorescence were different from those planned on the basis of evaluation under white light (Fig. 1C, step 3), surgical intervention consisted of widening the mucosal resection of the respective area to obtain apparently free superficial margins of at least 2 mm, which were considered to be definitive superficial margins (DSMs); in the case of area(s) positive by direct autofluorescence that were immediately adjacent to the lesion evident by white light enlargement, the resection was performed in monobloc; in some locations, due to the technical difficulty, it was preferred to obtain a biopsy or carry out a separate resection of the area considered to be positive. In the case of suspected superficial extension to the bottom/roof of the ventricle or to the false cord, at the time of vestibulectomy, particular care was taken to precisely coincide the inferior extreme of the vestibulectomy with the lateral extreme of the area previously marked for excision (Fig. 2A,B).

The deep margins of surgical specimens were marked with black ink, and both the specimen and the eventual enlargement of the resection were sent for histological examination to the same pathologist (GA) on a paper diagram of the larynx with precise indications of the procedure to identify the actual DSMs.

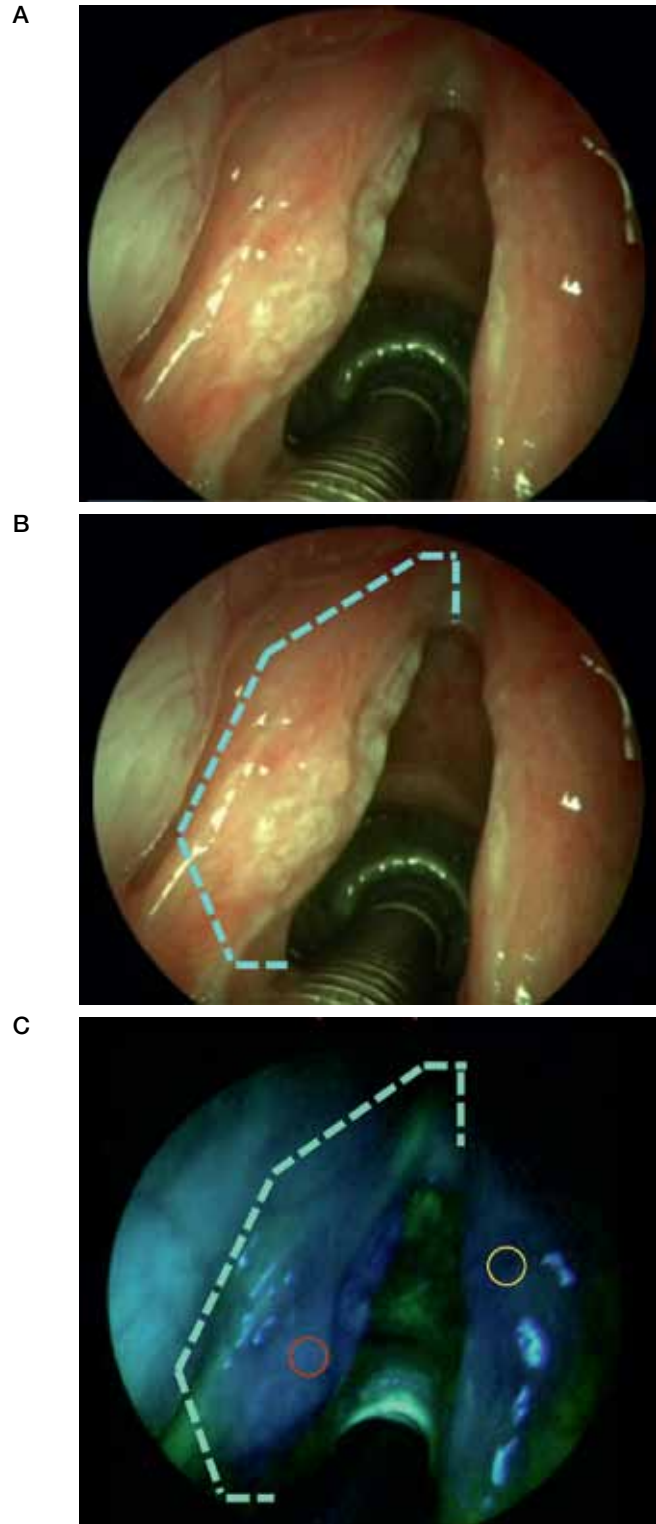


Fig. 1. Stepwise protocol used for intraoperative work-up. **A:** during direct microlaryngoscopy, initial assessment in white light of a suspected left vocal cord SCC staged cT1a; **B:** the area of excision is marked with several laser spots, maintaining an apparent margin of healthy tissue of approximately 2 mm compared to the visible limits of the suspected neoplastic lesion; **C:** assessment of field using direct autofluorescence showing an area of surgical excision insufficient compared to that found by autofluorescence in the dark [the histological examination on the surgical specimen and biopsy on the contralateral vocal cord found an invasive SCC in both the site of the clinically visible tumour (red circle) and in the contralateral vocal cord (yellow circle) → upstaging from glottic T1a to T1b].

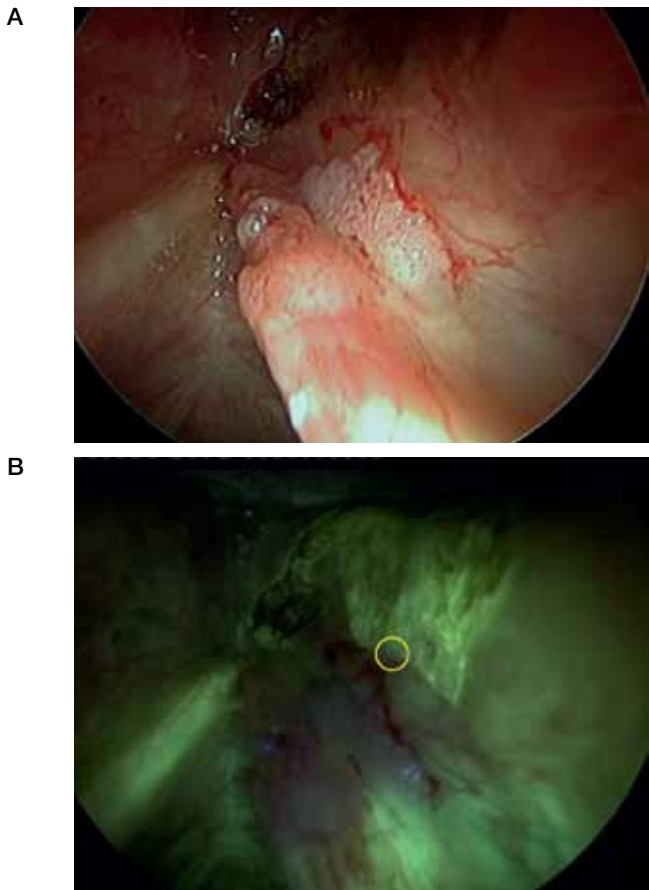


Fig. 2. A: during direct microlaryngoscopy, initial assessment in white light of a suspected right vocal cord SCC staged cT2; **B:** assessment of field using direct autofluorescence showing the safe margin between the inferior extremity of vestibulectomy (yellow circle) and the lateral extremity of the area previously marked for excision (histological examination on the surgical specimen found a free margin = 2 mm).

Histopathological evaluation focused on the following aspects: presence of dysplasia, carcinoma in situ or invasive carcinoma at the level of DSMs and deep margins (positive margins); presence of dysplasia, carcinoma in situ or invasive carcinoma at a distance less than 1 mm from the DSMs and deep margins (close margins); presence of dysplasia, carcinoma in situ or invasive carcinoma in specimens containing lesions evident both to white light and direct autofluorescence (tumour) or containing area(s) positive to direct autofluorescence, but negative by white light endoscopy (white light endoscopy negative areas; WLENA).

No elective neck dissection was performed in this patient population. In this study, we focused our attention on early diagnosis of persistence/recurrence of disease and identification of secondary tumours. Endoscopic retreatment was performed 30-60 days after the first procedure in all cases with positive deep margins. In cases with close surgical margins (< 1 mm), during the first post-operative year, endoscopic follow-up with monthly endoscopic con-

trols was chosen. All patients underwent follow-up that included flexible videolaryngoscopy and/or rigid videolaryngoscopy coupled with HDTV every 3 months and neck MRI in cases of suspected submucosal recurrence. In the case of indirect endoscopy with suspected recurrence/secondary tumour, patients were subjected to microlaryngoscopic re-evaluation under general anaesthesia followed by excisional biopsy of the suspect area.

For the calculation of sensitivity and specificity of autofluorescence, the following endoscopic and pathological criteria were adopted: among the 73 patients treated, all cases who had negative superficial margins of more than 1 mm at histological examination and for the 12-month period after TLS with endoscopic examination judged as “not suspicious” for recurrence (and therefore not receiving a histological evaluation) were considered true negatives; in contrast, false negatives were considered to be any positive or close (< 1 mm) superficial margin and every superficial recurrence occurring within the first 12 months after TLS, considering this as a failure criterion of autofluorescence to detect areas of epithelial transformation “upstream” of the line of resection; true positives were considered to be any area(s) positive to direct autofluorescence in which histological examination was able to find areas of dysplasia, in situ carcinoma or invasive carcinoma; false positives were considered to be those area(s) positive to direct autofluorescence in which histological examination did not reveal epithelial transformation (dysplasia, in situ carcinoma or invasive carcinoma) and for 12 months after TLS, endoscopic examinations were judged as “not suspicious” for recurrence (and therefore not receiving histological evaluation).

Statistical methods

The SPSS statistical package was used for statistical analysis. Three-year survival was estimated. The entry point was the date of surgery. The endpoint for disease-specific survival was the date of first recurrence. The endpoint for local control with laser alone was the date of local recurrence requiring open-neck surgery or nonsurgical salvage treatment.

Results

The study group included 73 patients with glottic carcinoma with TNM staging (level of evidence C2) as follows: T1a glottic, 47 patients (64.3%); T1b glottic, 13 patients (17.8%); T2 glottic, 13 patients (17.8%) (four for hypomobility of the vocal cord, nine for superficial extent of the ventricular or subglottic mucosa). Cordectomies were classified according to the classification system of the European Laryngological Society (ELS): Type I, 4 (5.5%); Type II, 10 (13.7%); Type III, 26 (35.6%); Type IV, 8 (11.0%); Type V, 25 (34.2%).

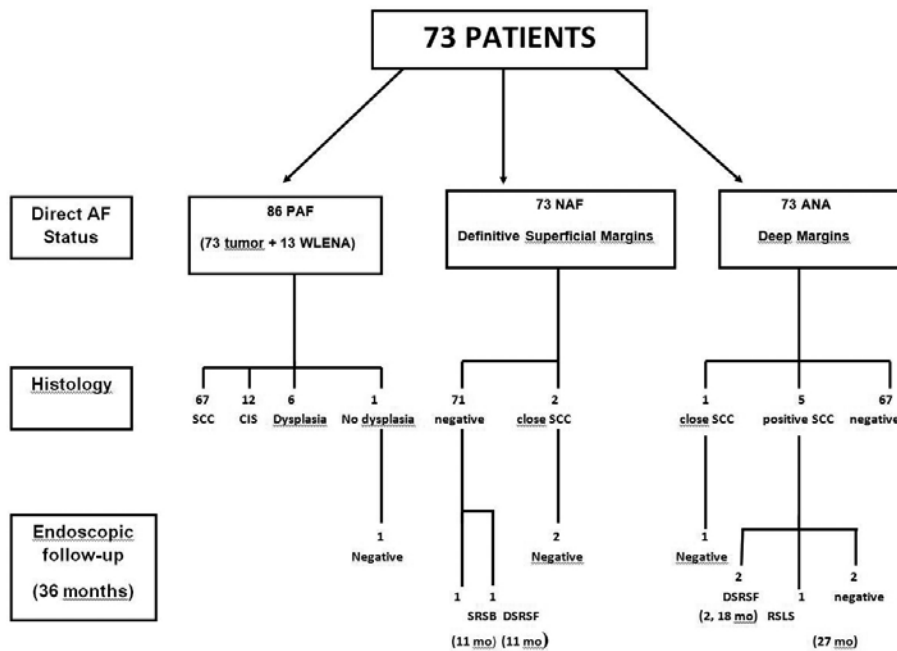


Fig. 3. Study design showing results of histological evaluation and endoscopic follow-up in 73 patients. Each evaluation is described with respect to direct autofluorescence status [positive to autofluorescence (PAF), negative to autofluorescence (NAF), autofluorescence not applicable (ANA)], location of examined areas [tumour, white light endoscopy negative area (WLENA), definitive superficial margins, deep margins], status to endoscopic follow-up Negative (N), superficial recurrence on surgical boundaries (SRSB) deep submucosal recurrence in surgical field (DSRSF), recurrence in separate laryngeal site (RSLs)].

The use of direct autofluorescence was associated with better definition of superficial margins of excision in seven patients (9.6%), all who received wider superficial resections, without changing the T category (2 T1a, 3 T1b, 2 T2), while in six patients (8.2%) direct autofluorescence led to up-staging of the TNM category. The study design as well as data on specimens obtained and categorised by direct autofluorescence status, histology and endoscopic follow-up are shown in Figure 3.

In total, there were 12 WLENA considered to be positive by direct autofluorescence (PAF) that were also shown to be positive by histological analysis [severe dysplasia, carcinoma in situ (CIS), SCC], while there was one PAF that was negative by histological evaluation (hyperplasia). All DSMs were negative by direct autofluorescence (NAF); the histological analysis of the surgical specimens (for the 13 patients in whom the results of direct autofluorescence led to use of wider surgical margins, the latter was considered the last area of superficial resection) showed that 71 (97.3%) had negative superficial margins, while superficial margins were found in two cases (2.7%). Histological analysis of the deep margins of the surgical specimens (on which direct autofluorescence did not provide additional information) was positive in five cases (6.8%) and adjacent in one case (1.3%) (Table II).

Comparison between clinical TNM (cTNM) and pathological TNM (pTNM) showed that two cases were up-staged

from T1a to T1b for involvement of the anterior commissure mucosa or contralateral vocal cord (Fig. 4A,B), two cases passed from T1a to T2 for involvement of the mucosa of the bottom/roof of the ventricle, one case passed from T1a to T2 for a second primary CIS on the contralateral false cord, and one case from T1b to T2 due to involvement of the supraglottic mucosa overlying the anterior commissure. Five patients (6.8%) received endoscopic retreatment for positive deep margins. Two of these patients (40%) underwent supracricoid open partial laryngectomy: one for positive margins after endoscopic re-excision and one for early recurrence after re-excision. In two cases (40%), there was no evidence for the presence of disease, while in one case (20%) recurrent disease was completely excised with clean margins. In these cases, only strict endoscopic and radiological follow-up was carried out.

The minimal follow-up was 36 months (mean 50, range

Table II. Status of resection margins.

Margin status	N (%)
Negative	65
Positive	5
superficial	0
deep	5
Close (< 1 mm)	3
superficial	2
deep	1

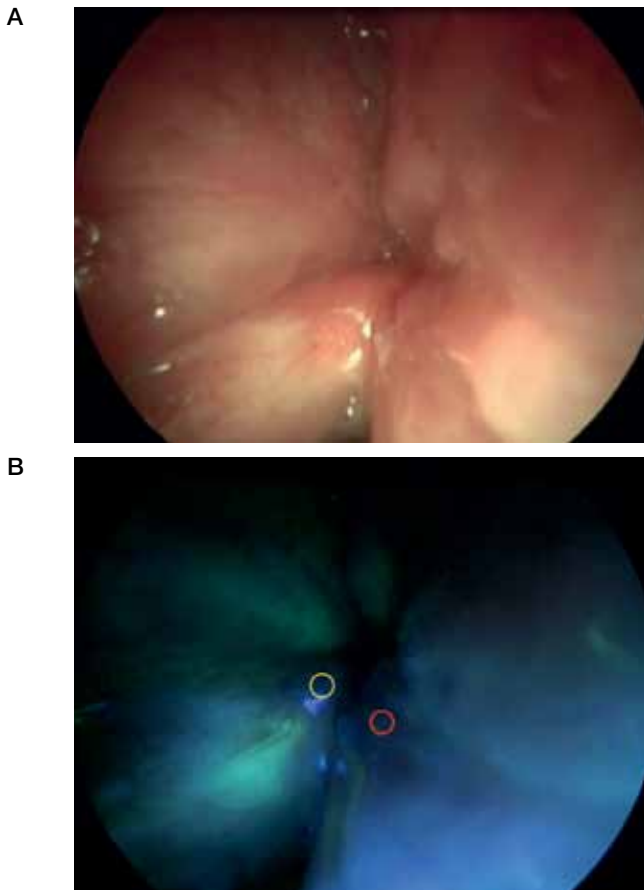


Fig. 4. **A:** during direct microlaryngoscopy, initial assessment in white light of a red hyperplastic lesion at the anterior part of the vocal cord; **B:** assessment of field using direct autofluorescence showing an area positive to direct autofluorescence encompassing the anterior commissure (histological examination on the surgical specimen found a CIS both at the site of a clinically more visible red lesion (red circle) and in the contralateral vocal cord (yellow circle).

36-70 months) during which five recurrences were observed and classified according to the mode of presentation: three deep submucosal recurrences in the surgical field, respectively, at 2, 11 and 18 months after surgery (two in positive deep margins, one in negative superficial and deep margins), one superficial recurrence on surgical boundaries (in a patient with NAF superficial margins) within 11 months and therefore considered to be a false negative to autofluorescence and one recurrence (in a patient with positive deep margins) at a separate supraglottic laryngeal site at 29 months after TLS. No loco-regional or regional recurrences were observed during follow-up. Four patients affected by deep submucosal recurrence or recurrence at a separate laryngeal site underwent open partial laryngectomies, while the only superficial recurrence was treated by TLS. The 3-year disease-specific survival and local control rates with laser alone were, respectively, 97.5% and 100% for T1a, 86.7% and 86.7% for T1b, and 88.9% and 88.9% for T2 (Table III).

Discussion

Work-up in a patient undergoing CO₂ laser surgery for laryngeal SCC is no longer a matter of debate. Preoperative evaluation is based on flexible fibrolaryngoscopy and/or rigid videolaryngoscopy with a 70°/90° telescope, while CT or MRI and ultrasound examination of the neck (fine needle aspiration cytology in cases with suspect lymph node metastases) are carried out in the majority of cases and avoided only for selected cT1a lesions with a superficial pattern of growth¹. Moreover, intraoperative rigid endoscopy with 0° and angled telescopes, particularly if coupled with HDTV, complete the work-up by providing accurate information on the superficial extent of the lesion, especially in cases of extension to the bottom and roof of the ventricle, anterior commissure involvement or subglottic extension¹². It is clear that any additional endoscopic examination will provide further information, and that each investigation is useful in reducing the proportion of patients with laryngeal lesions that are under- or over-staged during the pre-treatment phase.

In the present study, we assessed the benefits of direct autofluorescence endoscopy in pre-operative work-up of glottic SCC to allow more precise planning of surgical excision, obtain superficial disease-free margins and identify additional areas of malignant transformation. Autofluorescence endoscopy enhances intraoperative work-up, providing information about the biological characteristics of the lesion, and especially about surgical margins. In fact, after direct endoscopy in white light during microlaryngoscopy, performing the same exam in direct autofluorescence allows identification of superficial pathological areas on the basis of chromatic differences compared to healthy tissue¹⁶. Accordingly, direct autofluorescence can only reveal pathologies that involve the mucosal surface of the larynx, but not those involving submucosal or deep layers¹⁷.

In head and neck oncology there are several studies that help to explain the observed differences in autofluorescence between normal and neoplastic tissues¹⁷, which have demonstrated that the aspect and degree of fluorescence of each tissue depend on three factors: amount of fluorophore, morphological aspects and wavelength of excitation¹⁶. The interaction of light with tissue has generally been found to highlight changes in the structure and metabolic activity of the areas optically sampled. Specifically, the loss of autofluorescence is believed to reflect a complex mixture of alterations to intrinsic fluorophore distribution in tissue (such as the breakdown of the collagen matrix and a decrease in flavin adenine dinucleotide concentration due to tissue remodelling), increased metabolism associated with neoplastic development in both the epithelium and lamina propria (e.g. thickening of the epithelium, hyperchromatism and increased cellular/nuclear pleomorphism or increased microvasculature)

Table III. Disease specific survival and local control with laser alone (n = 73) according to pT and status of definitive margins.

Variables	Patients (N)	3-year disease specific survival	3-year local control with laser alone
pT categories			
pT1a	40	97.5%	100%
pT1b	15	86.7%	86.7%
pT2	18	88.9%	88.9%
		p = ns	p = ns
Margins			
Negative	65	96.9%	96.9%
Close	3	100%	100%
Positive superficial	—	—	—
Positive deep	5	40%	60%

leading to increased absorption and/or scattering of light, which in turn reduces and modifies the detectable autofluorescence¹⁸⁻²⁰. In healthy tissues, riboflavins are in an oxidised state and show strong fluorescence emission at wavelengths around 520 nm, leading to bright green fluorescence; in contrast, in dysplasia, in situ carcinoma, and particularly in malignant lesions, since reduced riboflavins are present at a lower concentration there is a marked reduction or an absence of green fluorescence, and the lesion appears as blue/dark violet²⁰.

Considering its ability to distinguish normal mucosa from dysplastic/neoplastic tissue, some features can have a negative impact on the sensitivity and specificity of autofluorescence and must be kept in mind to avoid misinterpretation of the endoscopic picture. Leukoplakia/hyperkeratosis without dysplasia shows a field of intense bright white autofluorescence, while the presence of underlying dysplasia/cancer can lead to a slight change in the underlying colour to dark red/light brown. In these cases, it is important to focus examination on the mucosal margins of the lesion, avoiding the vegetating and keratotic portion, especially in narrow areas (bottom of the ventricle, anterior commissure) without causing bleeding (which would hinder proper examination; Fig. 5A,B). Lesions characterised by abnormal hyperplasia and speckled leukoplakia, such as observed in cases of severe gastrointestinal reflux with extra-oesophageal lesions are associated with a reduction in normal fluorescence, with various degrees of colour from bright green/bright white to blue/violet. Hypervascularised lesions, chronic laryngitis and lesions with bacterial infection are associated with a reduction in autofluorescence compared to normal tissues, and scarring from prior surgical treatment, biopsy or radiotherapy is associated with a reduction in autofluorescence similar to that seen in pre-neoplastic and neoplastic lesions.

Considering rigid endoscopy in white light and HDTV, in 13 cases in the present study, the positive areas seen by direct autofluorescence were wider; at histological analy-

sis on surgical specimens and areas of widened resection/separate biopsy, 12 true positives and one false positive were found (scar on the contralateral vocal fold due to a previous procedure for leukoplakia 8 years before), while

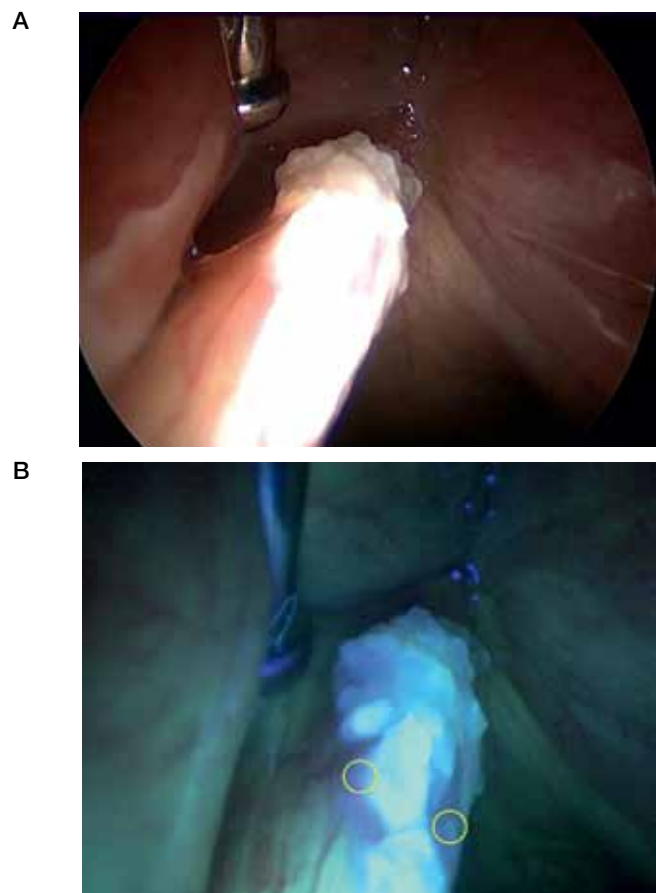


Fig. 5. **A:** during direct microlaryngoscopy, initial assessment of the left vocal cord in white light; **B:** assessment of field using direct autofluorescence showing a bright white hyperkeratotic lesion with slight positivity to direct autofluorescence on the mucosal margins of the lesion (yellow circles) (histological examination on the surgical specimen found a SCC in the areas marked with the yellow circles).

only one superficial recurrence occurred within the first 12 months after surgery. In all other cases, follow-up endoscopic examinations were judged to be “not suspicious” for superficial recurrence. Therefore, in the entire cohort of patients, direct autofluorescence showed a sensitivity of 96.5% and a specificity of 98.5%.

The extensive and combined utilisation of direct autofluorescence before TLS resulted in several advantages compared to the traditional diagnostic methodology in white light because it allowed better definition of the superficial extent of the lesion, which is useful in widening a superficial laser resection and can help the surgeon to obtain disease-free superficial margins. This has a positive impact on endoscopic treatment modulation and, subsequently, on both disease-free survival and local control with laser ²¹.

Considering correct modulation of resection during TLS, it must first be kept in mind that there is an increased risk of dysplastic and malignant changes in the mucosa surrounding the tumour after many years of smoking, alcohol abuse ⁶ and/or gastrointestinal reflux. The surgeon, therefore, must consider the possibility of premalignant and microinvasive disease that is not macroscopically evident. This can frequently be seen in pre-operative evaluation in white light (telescopic/microscopic), and even in expert hands, there is a tendency to under-stage the actual extent of disease, with the consequence that superficial resection margins are often positive. This is evident from several studies. In order to routinely obtain a high degree of disease-free resection margins, some authors recommend wide resection of vocal fold mucosa, and widen the resection near the deep margins of the lesion ²²; this particular type of functional oncological surgery tends to exaggerate the substantial compromise between the necessity of performing a wide resection with clean margins and that of preserving healthy tissue so that good vocal function can be maintained.

Peretti and colleagues reported positive superficial margins after TLS in 38.4% of cases, even though this did not appear to have a negative impact on disease-specific survival or loco-regional control at 5 years ¹. This demonstrates the importance of choosing the widest margins possible in order to resect a tumour with clean margins, thus avoiding any form of overtreatment that would negatively impact good functional preservation.

Achieving a high level of quality in TLS can be aided by correct pathological study of resection margins, which is greatly improved through the use of laser technology (low power, AcuBlade, SuperPulse) as it is associated with less charring along the line of excision ²³⁻²⁶. The same considerations can be made if the surgeon has access to accurate “in vivo” information on apparently healthy tissue surrounding the tumour, and the ability to correctly determine the entity of resection will undoubtedly lead to a lower proportion of positive superficial margins. This will

clearly have an impact on both disease-specific survival and local control.

Indirect evidence for an advantage of endoscopic tools in allowing precise calibration of the entity of superficial resection during TLS is provided by Lucioni and colleagues ³ who studied the impact of surgical margins obtained by CO₂ laser photocoagulation (LPC) on local disease control in patients submitted to endoscopic surgery for early glottic cancer. The authors reported a significant difference in recurrence rate among patients treated with surgical margin LPC compared to those treated with laser cordectomy without LPC (P = 0.022). In particular, a lower recurrence rate in LPC patients was seen in the case of close (≤ 1 mm), non-definable and positive margins with infiltration of the superficial border. No significant difference was observed in the case of negative edges (> 1 mm) or involvement of either deep margins or both superficial and deep edges. Carried out by expert laser surgeons, that study demonstrates that, after apparently radical laser surgery, systematic widening of visible disease-free margins by about 2 mm (the authors used photovaporisation of margins with a defocalised spot that was 1.6 mm in diameter) is associated with benefits in local control of disease and a reduction in recurrence.

In our experience, the use of direct autofluorescence was associated with greater accuracy in defining superficial resection margins in 12 of 73 cases (16.4%), which would have otherwise been positive or close. Following direct autofluorescence, superficial resection was widened by 3-5 mm to incorporate the positive area, which can however be difficult in narrow spaces such as the anterior commissure and bottom/roof of the ventricle.

In a study on 96 patients undergoing pre-operative work-up with narrow band imaging (NBI), Piazza et al. reported improved delineation of the superficial extent of disease category in 35 cases (36.4%), which is a consequence of better definition of tumour category (upstaging of 26 neoplasms) and wider superficial resection ⁸.

The similarity of results even between two studies using different techniques allows discussion about the usefulness of endoscopic tools that provide better definition and information about the biology of the lesions. Similar to HDTV-NBI, direct autofluorescence unquestionably provides a wealth of endoscopic data that leads to better clinical definition in terms of assessment of pre-neoplastic or neoplastic tissues and their superficial extent, especially along the boundaries of a macroscopic lesion, the bottom and roof of the ventricle and anterior commissure. Thus, these tools are valuable in helping the surgeon correctly plan resection during TLS, especially when an excision biopsy is planned.

Compared to AF, NBI endoscopy has the advantage of being able to obtain the same information using both a videoendoscope coupled with a HDTV camera and rigid

telescopes. In our opinion, compared to NBI, there is a shorter learning curve with direct AF since judgment is given on the basis of colour changes; at present, direct AF is not coupled with an HDTV camera and this can be a problem, especially for preliminary evaluation in white light. Finally, the overall ergonomics of the procedure is more complex than with NBI endoscopy, which also seems to show superiority in the ability to properly distinguish post-actinic changes from persistent/recurrent disease²⁷.

Conclusions

In the present study, the use of direct autofluorescence was associated with the absence of positive superficial margins and the presence of close superficial margins in two cases that clearly had a positive impact on both disease-free survival and local control.

It is obvious that the experience of the surgeon has a compensatory mechanism if direct autofluorescence is not used: the choice of a widened superficial resection or photovaporisation of superficial resection margins can lead to similar results in terms of radicality and prognosis. In our opinion, endoscopic tools such as direct autofluorescence and NBI add value to intraoperative work-up, especially for surgeons with less experience.

While the learning curve for autofluorescence is rapid and the number of false positives in previously untreated patients appears to be low in our experience, one must be very careful in assessing any condition that may obstruct visualisation of mucosal margins, such as bulky keratotic lesions, and to consider autofluorescence less useful in conditions in which the number of false positives tend to be much higher, such as in patients previously treated by TLS or radiotherapy since, in these cases, specificity may be greatly reduced²⁸.

References

- Peretti G, Piazza C, Cocco D, et al. *Transoral CO₂ laser treatment for T₁-T₃ glottic cancer: the University of Brescia experience on 595 patients*. *Head Neck* 2010;32:977-83.
- Steiner W. *Experience in endoscopic laser surgery of malignant tumors of the upper aero-digestive tract*. *Adv Otorhinolaryngol* 1988;39:135-44.
- Lucioni M, Bertolin A, D'Ascanio L, et al. *Margin photocoagulation in laser surgery for early glottic cancer: impact on disease local control*. *Otolaryngol Head Neck Surg* 2012;146:600-5.
- Steiner W, Ambrosch P. *Endoscopic laser surgery of the upper aerodigestive tract*. Stuttgart: Thieme; 2000. p. 34-36.
- Ambrosch P. *The role of laser microsurgery in the treatment of laryngeal cancer*. *Curr Opin Otolaryngol Head Neck Surg* 2007;15:82-8.
- Steiner W, Ambrosch P. *Endoscopic laser surgery of the upper aerodigestive tract*. Stuttgart: Thieme; 2000. p. 39.
- Arens C, Glanz H, Dreyer T, et al. *Compact endoscopy of the larynx*. *Ann Otol Rhinol Laryngol* 2003;112:113-9.
- Piazza C, Cocco D, De Benedetto L, et al. *Narrow band imaging and high definition television in the assessment of laryngeal cancer: a prospective study on 279 patients*. *Eur Arch Otorhinolaryngol* 2010;267:409-14.
- Sadri M, McMahon, Parker A. *Management of laryngeal dysplasia: a review*. *Eur Arch Otorhinolaryngol* 2006;263:843-52.
- Rizzotto G, Crosetti E, Lucioni M, et al. *Subtotal laryngectomy: outcomes of 469 patients and proposal of a comprehensive and simplified classification of surgical procedures*. *Eur Arch Otorhinolaryngol* 2012;269:1635-46.
- Rizzotto G, Succo G, Lucioni M, et al. *Subtotal laryngectomy with tracheohyoidopexy: a possible alternative to total laryngectomy*. *Laryngoscope* 2006;116:1907-17.
- Peretti G, Piazza C, Mensi MC, et al. *Endoscopic treatment of cT2 glottic carcinoma: prognostic impact of different pT subcategories*. *Ann Otol Rhinol Laryngol* 2005;114:579-86.
- Union International Contre le Cancer. *TNM classification of malignant tumors*. 6th Edition. New York: Wiley-Liss; 2002.
- Remacle M, Eckel HE, Antonelli A, et al. *Endoscopic cordectomy. A proposal for a classification by the Working Committee, European Laryngological Society*. *Eur Arch Otorhinolaryngol* 2000;257:227-31.
- Remacle M, Van Haverbeke C, Eckel H, et al. *Proposal for revision of the European Laryngological Society classification of endoscopic cordectomies*. *Eur Arch Otorhinolaryngol* 2007;264:499-504.
- Saetti R, Derosas F, Silvestrini M, et al. *Efficacy of autofluorescence videoendoscopy in the diagnosis of laryngeal lesions*. *Acta Otorhinolaryngol Ital* 2007;27:181-5.
- Arens C, Dreyer T, Glanz H, et al. *Indirect autofluorescence laryngoscopy in the diagnosis of laryngeal cancer and its precursor lesions*. *Eur Arch Otorhinolaryngol* 2004;261:71-6.
- Svistun E, Alizadeh-Naderi R, El-Naggar A, et al. *Vision enhancement system for detection of oral cavity neoplasia based on autofluorescence*. *Head Neck* 2004;26:205-15.
- Lane PM, Gilhuly T, Whitehead P, et al. *Simple device for the direct visualization of oral-cavity tissue fluorescence*. *J Biomed Opt* 2006;11:024006.
- Poh CF, Zhang L, Anderson DW, et al. *Direct fluorescence visualization detection of field alterations in tumor margins of oral cancer patients*. *Clin Cancer Res* 2006;12:6716-22.
- Jäckel MC, Ambrosch P, Martin A, et al. *Impact of re-resection for inadequate margins on the prognosis of upper aerodigestive tract cancer treated by laser microsurgery*. *Laryngoscope* 2007;117:350-56.
- Ansarin M, Santoro L, Cattaneo A, et al. *Laser surgery for early glottic cancer. Impact of margin status on local control and organ preservation*. *Arch Otolaryngol Head Neck Surg* 2009;135:385-90.
- Batsakis JG. *Surgical excision margins: a pathologist's perspective*. *Adv Anat Pathol* 1999;6:140-8.
- Brøndbo K, Fridrich K, Boysen M. *Laser surgery of a T1a glottis carcinomas, significance of resection margins*. *Eur Arch Otorhinolaryngol* 2007;264:627-30.
- Meier JD, Oliver DA, Varvares MA. *Surgical margin deter-*

mination in head and neck oncology: current clinical practice: the results of an International American Head and Neck Society Member Survey. Head Neck 2005;27:952-8.

- ²⁶ Caffier PP, Schmidt B, Gross M, et al. *A comparison of white light laryngostroboscopy versus autofluorescence endoscopy in the evaluation of vocal fold pathology.* Laryngoscope 2013;123:1729-34.
- ²⁷ Piazza C, Del Bon F, Peretti G, et al. *Narrow band imaging in endoscopic evaluation of the larynx.* Curr Opin Otolaryngol Head Neck Surg 2012;20:472-6.
- ²⁸ Crosetti E, Pilolli F, Succo G. *A new strategy for endoscopic staging of laryngeal carcinoma: multistep endoscopy.* Acta Otorhinolaryngol Ital 2012;32:175-81.

Received: May 11, 2013 - Accepted: December 9, 2013

Address for correspondence: Erika Crosetti, ENT Department, Ospedale Martini, via Tofane 71, 10141 Turin, Italy. Tel. +39 011 70952305. Fax +39 011 70952252. E-mail: erikacro73@yahoo.com

OTOLOGY

Closure of the sigmoid sinus in lateral skull base surgery

Chiusura del seno sigmoide nella chirurgia della base cranio laterale

E. ZANOLETTI, D. CAZZADOR, C. FACCIOLI, A. MARTINI, A. MAZZONI

Otolaryngology and Otosurgery Unit, Padua University, Padua, Italy

SUMMARY

Closure of the sigmoid-jugular complex is generally planned during various surgical procedures on the skull base, either to repair a jugular foramen lesion or as the oncological boundary of the resection. A series of 218 cases of skull base tumour surgeries was analysed in which closure of the sigmoid-jugular complex was systematically planned (bilaterally in one case) in patients treated for jugular foramen paragangliomas, squamous cell carcinomas and other temporal bone tumours. Surgery was performed via a petro-occipital trans-sigmoid approach in 61 cases, an infratemporal A in 128, *en bloc* subtotal temporal bone resections in 10 and other approaches in 20. In our experience, planned unilateral (and, in one case, bilateral) closure of the sigmoid-jugular complex had no clinical consequences. The vicarious drainage of the skull base was always assessed preoperatively, revealing no contraindications to intraoperative sinus closure. Given the scarcity of literature on this subject, the present report shows that the procedure is associated with low morbidity and helps to improve our understanding of cerebral venous discharge.

KEY WORDS: Sigmoid sinus closure • Lateral approaches • Jugular foramen surgery

RIASSUNTO

La chiusura del complesso seno sigmoide-bulbo giugulare è contemplata in alcuni approcci chirurgici laterali al basi cranio; può essere parte dell'accesso chirurgico stesso al forame giugulare, oppure risultare necessaria come margine di una resezione oncologica del basi cranio laterale. Abbiamo analizzato una casistica personale di 218 pazienti trattati chirurgicamente per patologie tumorali della base cranica, sottoposte a chiusura pianificata del complesso sigmoide-giugulare. In un caso la procedura è stata eseguita bilateralmente. Tra le patologie trattate erano presenti paragangliomi del forame giugulare, carcinomi squamo cellulari dell'osso temporale ed altri tumori dell'osso temporale. Sono stati eseguiti 61 approcci petro-occipitali, 128 approcci infratemporal di tipo A, 10 resezioni subtotali en-bloc dell'osso temporale e 20 approcci di altro tipo. Nella nostra esperienza, la chiusura pianificata unilaterale – bilaterale in un singolo caso – del complesso sigmoide-giugulare non ha mostrato conseguenze cliniche. Per ogni paziente è stata attuata una valutazione preoperatoria del sistema di drenaggio venoso intracranico, che non ha rilevato controindicazioni alla procedura di chiusura. Considerata la carenza di dati in letteratura su questo argomento, il presente lavoro offre alcuni spunti per lo studio dei meccanismi di drenaggio venoso intracerebrale in condizioni fisiologiche e patologiche e dimostra la bassa morbilità della chiusura del complesso sigmoide-giugulare.

PAROLE CHIAVE: Chiusura seno sigmoide • Approccio laterale • Chirurgia del forame giugulare

Acta Otorhinolaryngol Ital 2014;34:184-188

Introduction

Experience with skull base surgical procedures has shown that intraoperative closure of the sigmoid sinus and jugular bulb (sigmoid-jugular complex; SJC) has no clinical consequences¹.

Closure of the SJC may be planned as part of surgical procedures involving the jugular foramen (using an infratemporal A, a petro-occipital trans-sigmoid, or a far lateral approach), or to meet the needs of oncological radicality, as in subtotal *en bloc* temporal bone resections.

SJC closure may also be unplanned but prove necessary during lateral skull base surgery when tearing, coagulation or trauma occur (even without any obvious lesions)

in procedures involving translabyrinthine or retrosigmoid approaches¹.

In cases of tumour involving the jugular foramen, the SJC may already be partially or completely closed by the tumour, whereas the lumen is free in other cases of closure (either unplanned or part of *en bloc* resections). In both conditions, the resulting obstruction of the venous discharge from the brain and skull base has no clinical consequences. Transient cerebral oedema has been observed in rare cases, with no associated clinical signs²⁻⁴, and serious consequences for the central nervous system are exceptional. When they do occur, they are not due the SJC closure per se, but rather to concomitant conditions (e.g. anatomical variations, lack of compensatory mechanisms, latent diseases) behind such clinical consequences.

Venous drainage from the brain has sufficient alternative routes⁵, both in physiological conditions and after closure of the SJC. The anatomical and functional aspects of cerebral venous discharge are discussed here, together with a report on our experience of planned SJC closures. The rates of unplanned SJC closure are probably underestimated because they do not give rise to functional consequences.

Materials and methods

At our tertiary referral centre, 218 patients with skull base tumours were treated surgically with planned closure of the sigmoid sinus between 1985 and 2004. SJC closure was bilateral in one case (Table I).

The series included 64 cases of various jugular foramen (JF) tumors, 144 of C class paragangliomas and 10 primary squamous cell carcinoma of the external auditory canal. The petro-occipital trans-sigmoid (POTS) approach⁶ was used in 60 patients (including one with bilateral chondrosarcoma of the JF who underwent two staged procedures with bilateral closure of the SJC), the infratemporal A (IT-A) approach in 128, other approaches in 20 and subtotal *en bloc* temporal bone resections (STBR) were performed in 10 cases⁷.

All patients were managed by the same senior surgeon using a consistent technique.

In all 219 procedures, the sigmoid sinus and jugular bulb complex was either closed as part of the surgical procedure (in 61 POTS, 128 IT-A, and 20 other approaches), or necessitated by subtotal *en bloc* bone resection (10 STBR).

The lesions originated in or near the JF (schwannoma, paraganglioma, meningioma), or grew to involve the jugular fossa (chordoma, chondrosarcoma, cholesteatoma). In all cases, the lesion extended to a variable degree into the cerebello-pontine angle (CPA), skull base bone and neck. In *en bloc* temporal bone resections (squamous cell

carcinoma of the external auditory canal and temporal bone), the SJC was free of disease but was included in the resections for the sake of oncological radicality. Diagnoses were always obtained with contrast-enhanced CT scans and, since the 1990s, with contrast-enhanced MRI and CT scans. Preoperative angiography was used to investigate venous discharge status through the sinuses and patency of the torcular herophili.

Results

Sixty-one POTS procedures (1 bilateral) were performed for 11 type C jugular foramen paragangliomas and 49 other jugular foramen tumours; 128 IT-A were performed in 113 cases of type C jugular foramen paraganglioma and in 15 patients with other JF lesions; other approaches were used for 20 type C jugular foramen paragangliomas (Table I). In all these procedures, the SJC was closed due to tumour involvement or as part of the surgical procedure.

Cases of primary squamous cell carcinoma of the external auditory canal were treated with *en bloc* STBR. The SJC complex was sacrificed because, though free of disease, it was within the oncological boundaries for the purposes of radical tumour removal.

In all cases, closure of the SJC had no clinical consequences. The case of bilateral sinus closure was a patient with bilateral chondrosarcoma of the JF who was treated with staged POTS. No anomalies came to light on preoperative venous drainage assessment, and none of the patients had any preoperative contraindications to closure of the SJC.

Discussion

Closure of the sigmoid sinus may either be planned or as part of an unintentional outcome of transpetrosal surgical procedures¹.

Table I. Case material of skull base tumours treated surgically using various approaches involving closure of the sigmoid-jugular complex.

Total cases of jugular foramen (JF) – temporal bone tumours	POTS	IT-A	Other approaches	En bloc STBR
	No. of cases	No. of cases	No. of cases	No. of cases
Schwannoma 9-11cranial nerve	16			
Schwannoma 7,8,12 cranial nerve	4			
JF paraganglioma (first diagnosis)	6	98	17	
JF residual paraganglioma	5	15	3	
Meningioma	7			
Chordoma	4	1		
Chondrosarcoma	5	3		
Papillary adenoma	3	4		
Miscellaneous	10	7		
Primary squamous cell carcinoma of the external auditory canal				10
Total cases (N = 218)	60	128	20	10
Total procedures (N = 219)	61	128	20	10

The reason why it has no functional consequences is probably because compensatory drainage mechanisms already exist in physiological conditions, but only become apparent when the SJC is closed.

The anatomy and physiology of venous drainage from the brain and skull base involve a rich network of emissary veins connecting the vessels outside the skull with the intracranial venous sinuses⁵. This network is more evident in children and not all the emissary veins are identifiable in each individual⁸. These veins are valveless and blood can flow bidirectionally. Their function consists in equalizing intracranial pressure, and they act as safety valves at times of cerebral congestion or when the SJC becomes obstructed. Most of these veins connect various subsites of the SJC with the internal vertebral plexus. The posterior condyloid vein runs through the posterior condylar foramen in the retromastoid region, connecting the internal vertebral plexus to the lower end of the sigmoid sinus. The mastoid emissary vein passes through the mastoid canal and connects the sigmoid or transverse sinus to the postauricular or occipital vein, which joins the internal vertebral plexus.

Gilbert Breschet provided the first detailed description of the anatomy of the vertebral venous plexus in 1819⁹. It was described as a large plexiform, valveless network of vertebral veins consisting of three interconnecting divisions and spanning the entire spinal column, with connections to the cranial dural sinuses distributed in a longitudinal pattern, running parallel to and communicating with the venae cavae. It is now considered as being functionally even more important than the SJC in the cerebrospinal venous system¹⁰. It plays an important part in regulating intracranial pressure with changes in posture, and in venous outflow from the brain. In pathological conditions, it provides a potential route for the spread of tumour, infection, or emboli.

The emissary veins are routes connecting the intracranial sinuses to the vertebral venous plexus. The occipital emissary vein connects the transverse sinus with the internal vertebral plexus through the occipital vein; the parietal emissary vein connects the superior sagittal sinus to the occipital vein, and then to the internal vertebral plexus. Other emissary veins connect areas other than the SJC, e.g. the foramen ovale, sphenoid sinus, foramen cecum, foramen lacerum and clivus.

Batson et al.¹¹ studied all the venous channels and emissary veins draining the adult skull base, and found that venous outflow from the brain is via the internal jugular veins, the anterior anastomoses with the orbit and pterygoid plexuses, the emissaries through the skull and multiple channels joining the vertebral plexuses¹².

All these plexuses operate under normal physiological conditions as in coughing, sneezing, straining, and jugular compression. In some individuals, they are capable of completely taking over blood drainage after acute occlusions of the dural sinuses or jugular veins. If these col-

lateral drainage channels were to prove inadequate due to an abnormal occlusion of the major dural venous sinuses, then intrasinal venous pressure would probably increase. In some patients, the sinus is functionally already blocked by tumour, and its closure during surgery does not alter the situation existing preoperatively. Any increase in intrasinal venous pressure can be compensated providing the collateral channels are adequate in number and calibre, and capable of diverting the blood into appropriate exit channels¹².

This network of emissary veins is not always the same in every individual, and this may explain the variety of compensatory mechanisms occurring (and the corresponding clinical aspects) in the event of SJC closure.

When closure of the SJC is an involuntary intra- or post-operative event, it may be due to thrombosis of the sinus, intraoperative tearing of the sinus wall, heat-induced injury during bone drilling, or extrinsic compression¹³⁻¹⁵. Other intraoperative events, such as retractions, parenchymal damage, or injury to the venous system, may make an otherwise asymptomatic event become clinically evident. Very few cases of unplanned sigmoid sinus occlusion have reportedly had serious clinical consequences, and this has been attributed primarily to anatomical variations in the intracranial venous system^{2,4,16,17} and to individual differences in the whole collateral venous circulation network. Preoperative angiography to assess the collateral venous system is commonly recommended before taking a transpetrosal approach to the jugular foramen. When sacrifice of the sinus is planned, occlusion of the sigmoid sinus is safe and symptom-free in the case of a freely communicating torcular herophili, but closure of the sigmoid sinus may have consequences if the lesion is located at the same site in the dominant sinus, the torcular system is only partially communicating and the collateral venous discharge proves insufficient^{4,18}.

Preoperative assessments are not usually prescribed when conventional transpetrosal procedures involve the jugular foramen^{19,20}, and the unplanned sacrifice of the sigmoid sinus has never reportedly been a problem *per se*. It may be that a system of collateral drainage and emissary veins compensates for the sigmoid sinus closure. Alternatively, the fact that closure of the SJC has no adverse effects might be attributed to the slow growth of tumours affecting the jugular bulb prompting a vicarious blood discharge. The same lack of clinical consequences is seen after *en bloc* resections, however, in patients whose SJC had an unobstructed venous flow before surgery, giving the impression that alternative routes may open when the sigmoid sinus is closed. A right dominance of the sigmoid sinus has been reported in 60% of patients, a left dominance in 25% and an asymmetrical dominance in 15% of cases^{12,21}.

The concept of "dominant sinus" has always been discussed on the basis of angiographic evidence, but the ap-

parently dominant pattern has not been investigated from a functional standpoint. It is not yet clear whether it is safe to sacrifice the so-called 'dominant' sigmoid sinus. The collateral unilateral drainage of the non-dominant sinus would seem to be plentiful and compensate for the apparent reduction in venous flow¹². Our case of bilateral (albeit staged) closure of the SJC is of interest, given the lack of any adverse effects in this patient.

Sigmoid sinus thrombosis is also a silent complication of otomastoiditis and its outcome is favourable in most cases. When life-threatening sinus thrombosis is associated with cerebral oedema and symptoms of intracranial hypertension (pseudotumour cerebri), this generally coincides with inadequate collateral venous discharge¹⁸.

Symptoms of intracranial hypertension include headache, blurred vision and vomiting²². Examining the fundus oculi always reveals papilloedema, and often retinal haemorrhage. These symptoms are rarely life-threatening and usually self-limiting, and patients respond to conservative treatments such as steroids and diuretics.

Two mechanisms have been described to explain the cerebral dysfunction that accompanies cerebral venous sinus thrombosis leading to an increase in intracranial pressure⁴. Cortical vein thrombosis causes local venous hypertension and leads to vasogenic and ultimately cytotoxic oedema, ischaemia and haemorrhage. Sinus thrombosis causes intracranial hypertension by impeding CSF absorption at the arachnoid villi, which are located primarily in the superior sagittal and transverse sinuses. Thrombosis of the sinuses and the resulting increase in venous pressure hinders CSF flow into the ventricles, but this does not usually cause hydrocephalus. The intracranial pressure only increases if and when the anastomotic channels between the sinuses and elements of the cerebral venous system proximal to the site of obstruction are inadequate²³. The reason why the ventricle does not increase in size with obstructive hydrocephalus is not clear⁴.

Some conditions existing preoperatively might make it more likely for symptoms to become clinically evident, e.g. infections or chronic diseases such as collagen tissue disorders, cardiac disease, haematological abnormalities and venous abnormalities in the brain's drainage pattern. One in two patients who develop symptoms after cerebral venous thrombosis have a previously unknown prothrombotic state that may relate to anticardiolipin antibodies, deficiencies in proteins C and S, or antithrombin III, or prothrombotic gene mutations involving prothrombin 20210, factor V Leiden, or MTHFR^{18 22 24}.

There is general consensus^{2 4 16 17} that iatrogenic occlusion of the sigmoid sinus is usually uneventful, though there is a paucity of literature on experimental studies. Kanno et al.³ investigated the consequences of acute sigmoid sinus closure in monkeys. The hypothesis that sacrificing the sigmoid or transverse sinus had no consequences was confirmed experimentally by the lack of any significant increase in venous

pressure. The pressure in the contralateral transverse sinus did not change significantly when the sigmoid sinus was occluded³. This might be because blood does not always flow in the same direction and, when the sigmoid sinus is occluded, flows from the transverse sinus to the contralateral transverse sinus through the vein of Labbé and the torcular vein²⁵. Any disturbance caused by the sinus occlusion can thus be compensated by changing the direction of flow. When the transverse sinus is occluded, for instance, more blood drains through the vein of Labbé and the superior petrosal sinus to the sigmoid sinus. It is therefore essential for the vein of Labbé, the superior petrosal sinus, and the bilateral transverse sinuses to be visible on a preoperative angiogram. Otherwise sigmoid or transverse sinus ablation might raise sinus pressure, thereby causing venous congestion and brain swelling, and becoming symptomatic. These experimental findings are important, but it is important to know whether they also apply to humans. Recent reports^{3 25} and common experience suggest that accidental closure of a sigmoid sinus is generally without clinical consequences, but clinical or experimental studies on the outcome of unplanned or accidental sinus ablation in humans remain limited.

When the clinical consequences of cerebral venous thrombosis become evident, their management becomes mandatory. The limited evidence available makes the appropriate management of internal jugular and cerebral sinus thrombosis hard to establish. Most of the literature concerns single case reports or small case series, but there are no controlled studies (due to the rarity of these conditions), and so there is no broad agreement or policy on their management².

The traditional therapy for cerebral venous thrombosis is anticoagulation with heparin followed by oral anticoagulation. This helps to stop the thrombotic process and prevents thromboembolic events. Concerns over venous infarction, embolisation and persistent septic thrombophlebitis have prompted recommendations for the use of anticoagulants in patients with sigmoid sinus thrombosis². Bradley et al.²⁶ suggested that patients with thrombosis confined to the sigmoid sinus should not be given anticoagulants to avoid the associated risks. They emphasise the importance of serial imaging with MRI, MR venography, or CT venography in all patients being monitored for thrombus progression²⁰. The call for anticoagulation is supported by evidence of thrombus progression, extension to sites other than those seen on initial examination (such as the proximal internal jugular vein and the transverse or cavernous sinus), neurological changes, persistent fevers and embolic events². Endovascular thrombolysis can be attempted, administering a thrombolytic enzyme (usually urokinase). Published reports only include case reports and uncontrolled studies, from which it is impossible to say whether the results obtained with endovascular thrombolysis are superior to those achieved with systemic heparin²⁷.

Conclusions

Planned closure of the sigmoid sinus was performed without any consequences in all our 218 cases. The sinus was always sacrificed when the procedure involved the jugular foramen, as well as in cases of *en bloc* STBR. Tumours of the jugular foramen and adjoining sites may have at least partially closed the sigmoid sinus prior to any surgery, with new collateral venous pathways developing before any surgical closure is performed. To assess the safety of sigmoid sinus closure, we critically reviewed our experience and the literature on the venous drainage patterns in the brain and skull base. The vicarious role of the emissary veins and vertebral plexus was investigated, as was the mechanism behind symptomatic intracranial hypertension. Our literature review showed that there is a shortage of experimental studies in humans, but supported our findings, i.e. that planned closures of the sigmoid sinus are clinically irrelevant providing they are done after venous discharge from the skull base and brain has been reliably assessed.

References

- 1 Zanoletti E, Martini A, Emanuelli E, et al. *Lateral approaches to the skull base*. Acta Otorhinolaryngol Ital 2012;32:281-7.
- 2 Handley TP, Miah MS, Majumdar S, et al. *Collet-sicard syndrome from thrombosis of the sigmoid-jugular complex: a case report and review of the literature*. Int J Otolaryngol 2010;2010:203587.
- 3 Kanno T, Kasama A, Suzuki H. *Safety of ablation of the sigmoid and transverse sinuses: an experimental study*. Skull Base Surg 1993;3:146-51.
- 4 Mullen MT, Sansing LH, Hurst RW, et al. *Obstructive hydrocephalus from venous sinus thrombosis*. Neurocrit Care 2009;10:359-62.
- 5 Mortazavi MM, Tubbs RS, Riech S, et al. *Anatomy and pathology of the cranial emissary veins: a review with surgical implications*. Neurosurgery 2012;70:1312-9.
- 6 Mazzoni A. *The petro-occipital trans-sigmoid approach for lesions of the jugular foramen*. Skull Base 2009;19:48-56.
- 7 Mazzoni A, Danesi G, Zanoletti E. *Primary squamous cell carcinoma of the external auditory canal: surgical treatment and long term outcome*. Acta Otorhinolaryngol Ital 2014;34:129-37.
- 8 Eckley W. *Anatomic and physiologic correspondences of child and adult*. J Am Med Assoc 1903;40:1355-8.
- 9 Nathoo N, Caris EC, Wiener JA, et al. *History of the vertebral venous plexus and the significant contributions of Breshet and Batson*. Neurosurgery 2011;69:1007-14.
- 10 Ciuti G, Righi D, Forzoni L, et al. *Differences between internal jugular vein and vertebral vein flow examined in real time with the use of multigate ultrasound color doppler*. AJNR Am J Neuroradiol 2013;34:2000-4.
- 11 Batson OV. *Anatomical problems concerned in the study of cerebral blood flow*. Fed Proc 1944;3:139-144.
- 12 Kinal ME. *Hydrocephalus and the dural venous sinuses*. J Neurosurg 1962;19:195-201.
- 13 Behari S, Tyagi I, Banerji D, et al. *Postauricular, transpetrous, presigmoid approach for extensive skull base tumors in the petroclival region: the successes and the travails*. Acta Neurochir (Wien) 2010;152:1633-45.
- 14 Suzuki M. *Histopathological and enzyme-histochemical changes after brain compression*. Neurol Med Chir 1981;21:221-32.
- 15 Tsutsumi K, Shiokawa Y, Sakai T, et al. *Venous infarction following the interhemispheric approach in patients with acute subarachnoid hemorrhage*. J Neurosurg 1991;74:715-9.
- 16 Bigelow DC, Hoffer ME, Schlakman B, et al. *Angiographic assessment of the transverse sinus and vein of labbe to avoid complications in skull base surgery*. Skull Base Surg 1993;3:217-22.
- 17 Ohata K, Haque M, Morino M, et al. *Occlusion of the sigmoid sinus after surgery via the presigmoidal-transpetrosal approach*. J Neurosurg 1998;89:575-84.
- 18 Leblebisatan G, Yis U, Dogan M, et al. *Obstructive hydrocephalus resulting from cerebral venous thrombosis*. J Pediatr Neurosci 2011;6:129-30.
- 19 Mamikoglu B, Wiet RJ, Esquivel CR. *Translabyrinthine approach for the management of large and giant vestibular schwannomas*. Otol Neurotol 2002;23:224-7.
- 20 Brackmann DE, Green JD. *Translabyrinthine approach for acoustic tumor removal*. Otolaryngol Clin North Am 1992;25:311-29.
- 21 Swift GW. *The transverse sinus and its relation to choked discs*. 1930;3:47-70.
- 22 Galgano MA, Deshaies EM. *An update on the management of pseudotumor cerebri*. Clin Neurol Neurosurg 2013;115:252-9.
- 23 Ideguchi M, Kajiwara K, Yoshikawa K, et al. *Benign fibrous histiocytoma of the skull with increased intracranial pressure caused by cerebral venous sinus occlusion*. J Neurosurg 2009;111:504-8.
- 24 Sebire G, Tabarki B, Saunders DE, et al. *Cerebral venous sinus thrombosis in children: risk factors, presentation, diagnosis and outcome*. Brain 2005;128:477-89.
- 25 Spetzler RF, Dasplit CP, Pappas CT. *The combined supra- and infratentorial approach for lesions of the petrous and clival regions: experience with 46 cases*. J Neurosurg 1992;76:588-99.
- 26 Bradley DT, Hashisaki GT, Mason JC. *Otogenic sigmoid sinus thrombosis: what is the role of anticoagulation?* Laryngoscope 2002;112:1726-9.
- 27 Canhao P, Falcao F, Ferro JM. *Thrombolytics for cerebral sinus thrombosis: a systematic review*. Cerebrovasc Dis 2003;15:159-66.

Received: August 6, 2013 - Accepted: November 11, 2013

Address for correspondence: Elisabetta Zanoletti, Otolaryngology and Otosurgery Unit, Padua University, Padua, Italy. Tel. +39 049 8218778. Fax +39 049 8211994. E-mail: elisabetta.zanoletti@tiscali.it

VESTIBOLOGY

Anterior canal BPPV and apogeotropic posterior canal BPPV: two rare forms of vertical canalolithiasis

Vertigine parossistica posizionale benigna da canalolithiasi anteriore e da canalolithiasi posteriore apogeotropica: due rare forme di canalolithiasi verticale

L. CALIFANO, F. SALAFIA, S. MAZZONE, M.G. MELILLO, M. CALIFANO

Departmental Unit of Audiology and Phoniatics "G. Rummo" Hospital, Benevento, Italy

SUMMARY

Posterior canal benign paroxysmal positional vertigo (BPPV) is the most frequent form of BPPV. It is characterized by a paroxysmal positioning nystagmus evoked through Dix-Hallpike and Semont positioning tests. Anterior canal BPPV (AC) is more rare than posterior canal BPPV; it presents a prevalent down beating positioning nystagmus, with a torsional component clockwise for the left canal, counterclockwise for the right canal. Due to the possible lack of the torsional component, it is sometimes difficult to identify the affected ear. An apogeotropic variant of posterior BPPV (APC) has recently been described, characterised by a paroxysmal positional nystagmus in the opposite direction to the one evoked in posterior canal BPPV: the linear component is down-beating, the torsional component is clockwise for the right canal, counter-clockwise for the left canal, so that a contra-lateral anterior canal BPPV could be simulated. During a 16 month period, of 934 BPPV patients observed, the authors identified 23 (2.5%) cases of apogeotropic posterior canal BPPV and 11 (1.2%) cases of anterior canal BPPV, diagnosed using the specific oculomotor patterns described in the literature. Anterior canal BPPV was treated with the repositioning manoeuvre proposed by Yacovino, which does not require identification of the affected side, whereas apogeotropic posterior canal BPPV was treated with the Quick Liberatory Rotation manoeuvre for the typical posterior canal BPPV, since in the Dix-Hallpike position otoliths are in the same position if they come either from the ampullary arm or from the non-ampullary arm. The direct resolution of BPPV (*one step therapy*) was obtained in 12/34 patients, 8/23 patients with APC and 4/11 patients with AC; canal conversion into typical posterior canal BPPV, later treated through Quick Liberatory Rotation (*two-step therapy*), was obtained in 19 patients, 14/23 with APC and 5/11 with AC. Three patients were lost to follow-up. Considering the effects of therapeutic manoeuvres, the authors propose a grading system for diagnosis of AC and APC: "certain" when a canal conversion in ipsilateral typical posterior canal BPPV is obtained; "probable" when APC or AC are directly resolved; "possible" when disease is not resolved and cerebral neuroimaging is negative for neurological diseases. Our results show that the oculomotor patterns proposed in the literature are effective in diagnosing APC and AC, and that APC is more frequent than AC. Both of these rare forms of vertical canal BPPV can be treated effectively with liberatory manoeuvres.

KEY WORDS: Anterior canal BPPV • Posterior canal BPPV • Apogeotropic posterior canal BPPV • Quick Liberatory Rotation manoeuvre • Yacovino manoeuvre

RIASSUNTO

La VPPB da canalolithiasi posteriore è la forma più frequentemente osservata; essa è caratterizzata da un nistagmo parossistico posizionale evocato dal posizionamento di Dix-Hallpike o di Semont con una componente lineare up-beat ed una componente torsionale oraria per il canale posteriore sinistro, antioraria per il canale posteriore destro. La VPPB da canalolithiasi anteriore è più rara per la posizione più alta del canale anteriore ed è caratterizzata da un nistagmo parossistico evocabile nei posizionamenti Head-Hanging, con una componente lineare down-beating prevalente rispetto ad una incostante componente torsionale, oraria per il canale sinistro, antioraria per quello destro. La incostante presenza della componente torsionale rende talvolta difficile il riconoscimento del lato malato. Recentemente è stata descritta una variante apogeotropica della canalolithiasi posteriore caratterizzata da un quadro nistagmico evocato invertito rispetto alla canalolithiasi posteriore tipica, e cioè con una componente lineare down-beating ed una componente torsionale antioraria per il canale sinistro, oraria per il canale destro, cosicché può essere simulata una canalolithiasi anteriore controlaterale. In un periodo di 16 mesi, applicando come criteri diagnostici i patterns oculomotori descritti in letteratura, gli Autori hanno identificato, su un totale di 934 casi di VPPB, 23 casi di VPPB da canalolithiasi posteriore apogeotropica (2,5%) ed 11 casi di VPPB da canalolithiasi anteriore (1,1%). La VPPB da canalolithiasi anteriore è stata trattata con la manovra di Yacovino, che non necessita dell'individuazione del lato affetto, mentre la VPPB da canalolithiasi posteriore apogeotropica è stata trattata con la manovra di Rotazione Rapida Liberatoria, basandosi sulla considerazione che gli otoconi, sia che provengano dal braccio ampollare che da quello non ampollare del canale posteriore, nella posizione finale dei test diagnostici si trovino nella stessa parte del canale. La risoluzione diretta della VPPB è stata ottenuta con le manovre terapeutiche utilizzate in 8/23 canalolithiasi posteriori apogeotrope ed in 4/11 canalolithiasi anteriori (one-step therapy), mentre la conversione in una canalolithiasi posteriore tipica, trattata con manovra di Rotazione Rapida Liberatoria, è stata osservata in 14/23 canalolithiasi posteriori apogeotrope ed in 5/11 canalolithiasi anteriori (two-step therapy). Tre pazienti sono stati persi al follow-up. Considerando gli effetti delle manovre terapeutiche, gli Autori propongono un sistema di gradazione della diagnosi di VPPB da canalolithiasi posteriore apogeotropica e di VPPB da canalolithiasi anteriore: "grado certo" quando si ottiene una conversione in canalolithiasi posteriore tipica, "grado probabile" quando si ottiene direttamente la risoluzione della malattia, "grado possibile" quando la malattia non si risolve e la RMN cerebrale non evidenzia segni di patologia neurologica. I nostri risultati mostrano come i patterns oculomotori già descritti in letteratura siano efficaci nella diagnosi di VPPB da canalolithiasi posteriore apogeotropica e di VPPB da canalolithiasi anteriore e che la canalolithiasi posteriore apogeotropica sia più frequente rispetto alla canalolithiasi anteriore. Entrambe le forme rispondono bene alla terapia liberatoria.

PAROLE CHIAVE: VPPB da canalolithiasi anteriore • VPPB da canalolithiasi posteriore • VPPB da canalolithiasi posteriore apogeotropica • Manovra di rotazione rapida liberatoria • Manovra di Yacovino

Introduction

The topographic classification of benign paroxysmal positional vertigo (BPPV) is based on the position of otoliths in the semicircular canals, which can, hypothetically, be inferred from the oculomotor patterns observed during positioning tests ¹. The posterior canal (Fig. 1a) is involved in 80% of cases and the lateral canal with its geotropic and apogeotropic variants in 15%, whereas the rarest forms of BPPV (5%) are anterior canalolithiasis (Fig. 2), described in 1987 by Katsarkas ², “short arm canalolithiasis” ³ and apogeotropic posterior canalolithiasis (Fig. 1b), recently described by Vannucchi who, on the basis of the pattern of ocular movement induced by positioning tests, hypothesised the presence of debris in the distal part of the non-ampullary arm of the posterior canal ^{4,5}. In 1995, Agus ⁶ described a “reversed” clinical picture of posterior canalolithiasis with a down-beating paroxysmal nystagmus characterised by torsional components clockwise for the right Dix-Hallpike positioning, and counter-clockwise for left Dix-Hallpike positioning; later, the possible existence of an apogeotropic posterior form was theorised by Giannoni ⁷.

Typical posterior canal BPPV, the most frequent form of BPPV, is characterised by a paroxysmal nystagmus evoked through the Dix-Hallpike test; the nystagmus is torsional clockwise for the left side, counter-clockwise for the right side, with a vertical up-beating component. Anterior canal BPPV (AC) is characterised by an intensity-variable vertical down-beating paroxysmal nystagmus evoked through straight-head hanging and Dix-Hallpike positioning tests, without inversion of the down-beating vertical nystagmus in returning to the sitting position. The torsional component is not always clear and less intense than the vertical one; it is clockwise for the left anterior canal, counter-clockwise for the right anterior canal, regardless of the positioning side; latency is absent or short and nystagmus is sometimes fatigable; positioning usually provokes serious vertiginous symptoms, whereas head hanging position always triggers nystagmus ^{2,7-21}.

Apogeotropic posterior canal BPPV (APC) is characterised by a paroxysmal nystagmus evoked through the Dix-Hallpike test, and sometimes in the straight head-hanging position. The nystagmus has a vertical down-beating component and a torsional component, clockwise for the right canal, counter-clockwise for the left canal. Nystagmus is sometimes fatigable and paroxysm is often not intense; when the patient comes back to the sitting position, nystagmus seldom reverses its direction, and when it reverses, its intensity sometimes rises ^{4,5}.

Differential diagnosis between AC and APC therefore assumes a relevant importance: a right AC, for example, is diagnosed through a vertical down-beating paroxysmal

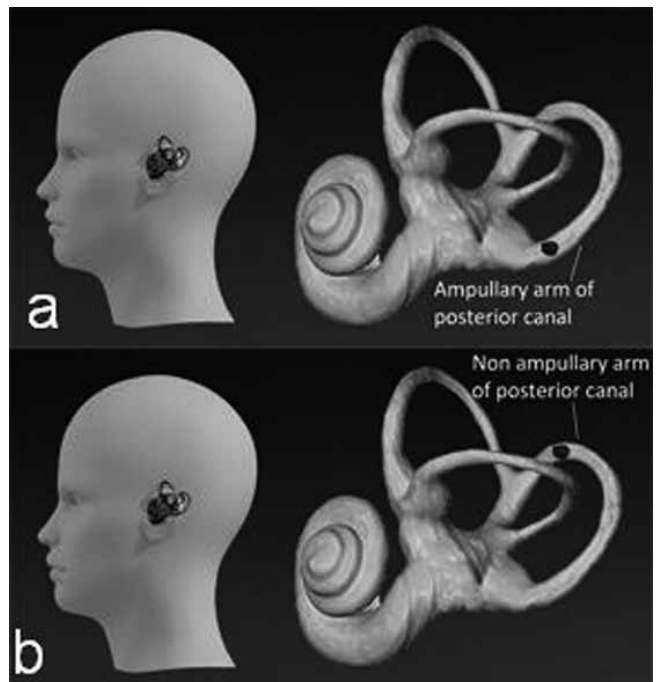


Fig. 1. Left posterior canal BPPV in sitting position. a: TPC: otoliths are in the ampullary arm of the canal; b: APC: otoliths are in the non-ampullary arm of the canal.

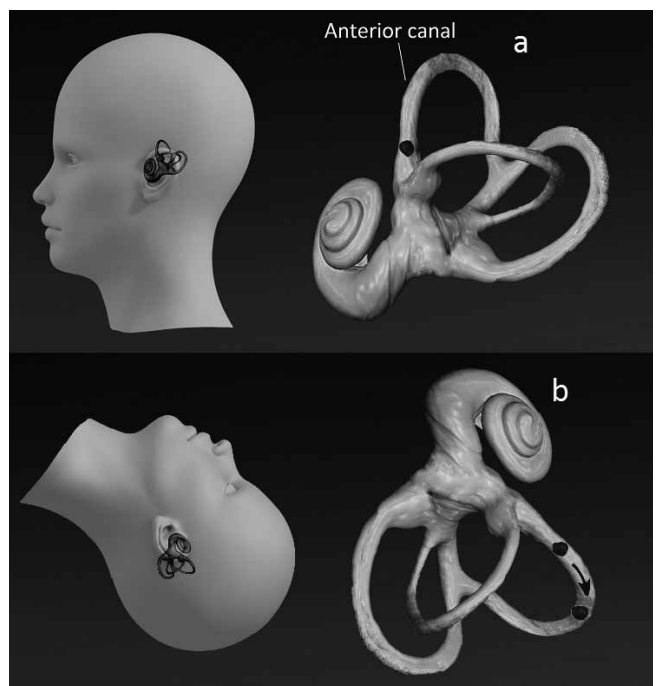


Fig. 2. Anterior canal BPPV in sitting (a) and in straight-head-hanging positioning (b).

nystagmus and a possible counter-clockwise torsional component evoked in straight-head hanging and in Dix-Hallpike positions; however, this oculomotor pattern is similar to a left APC, where, in most cases, the torsional component is more evident than the vertical one. Careful

evaluation of differences in intensity and direction of the nystagmus, triggering position or positions, and inversion of the nystagmus in returning to the sitting position in order to identify the affected canal and its side, and adopt the most appropriate therapeutic manoeuvre for each subtype, is fundamental.

The primary scope of the present research is to confirm, through the effects of therapeutic manoeuvres and the resulting gradation of diagnosis, if the oculomotor criteria proposed in the literature are efficient for diagnosis of both anterior and apogeotropic posterior canalolithiasis. The secondary aim is to verify the efficiency of the Yacovino manoeuvre (YM) in treating AC¹⁶ (Fig. 3A), and the Quick Liberatory Rotation manoeuvre (QLR) in treating APC²² (Fig. 3B).

Materials and methods

From September 2011 to December 2012, of 934 patients affected by BPPV, we identified 23 patients (2.5%) with presumed APC and 11 patients (1.2%) with presumed AC. There were 16 males and 18 females, with a mean age of 52.3 +/- 10.49 years; patients underwent otomicroscopy, pure tone audiometry and infrared videonystagmoscopy to evaluate spontaneous-positional nystagmus in dark-

ness, in both a seated position – through Head Pitching Test^{23,24}, Head Shaking Test, Head Thrust Test, Hyperventilation Test, and Gaze Test – and in a supine position via the straight head-hanging positioning, Dix-Hallpike positioning test and supine head roll test (Pagnini-McClure test)²⁵⁻²⁷.

We used the diagnostic oculomotor patterns of APC and AC as reported in the literature^{2,4,5,7-21}, evoked through the positioning tests (Dix-Hallpike test and straight head hanging positioning) and, according to their presence, we hypothesised a diagnosis of APC or AC. A vertical down-beating nystagmus indicated the involvement of a vertical canal, whereas the torsional component could also indicate the affected side: left AC or right APC for clockwise nystagmus; right AC or left APC for counterclockwise nystagmus. It is important to note that analysis of the nystagmus was performed through infrared videonystagmoscopy, and that different and more sensitive methods (i.e. scleral search coil) could lead to partially different observations.

After diagnosis, all patients signed an informed consent form for treatment.

AC patients were treated with YM, which can be performed regardless of the affected side. The patient is quickly moved from a 30° straight head hanging position to a supine position with a 30° forward inclination of the head for 30 sec, and finally to a sitting position with a 30° forward inclination of the head for 30 sec. APC patients were treated by QLR with a quick rotation of the head and of the body (less than 1 sec) from the Dix-Hallpike positioning on the affected side to a 45° nose-down position on the healthy side, remaining in the final lying-down position for 3 min; finally, they were brought to an upright sitting position.

The expected outcomes of these treatments were either a negative positioning test (*one step therapy*) or a positional paroxysmal nystagmus, torsional and up-beating, suggesting a canal conversion from AC or APC into TPC. TPC was further treated through QLR until a negative positioning test was observed (*two step therapy*). Patients were controlled two hours after the first manoeuvre and later every two days, until positioning tests were negative. Success was considered a negative positioning test while failure was the persistence of a positional paroxysmal nystagmus.

If therapeutic manoeuvres failed, the diagnostic work-up was completed by cerebral MRI, searching for central neurological diseases and/or inner ear CT scans to search for semicircular canal dehiscence.

Based on oculomotor criteria and therapeutic results, we elaborated a grading from “certain” to “possible” AC and APC, where therapeutic results confirmed the initial diagnostic hypothesis and the validity of oculomotor patterns reported in literature for APC and AC, depending on the strength of the evidence.

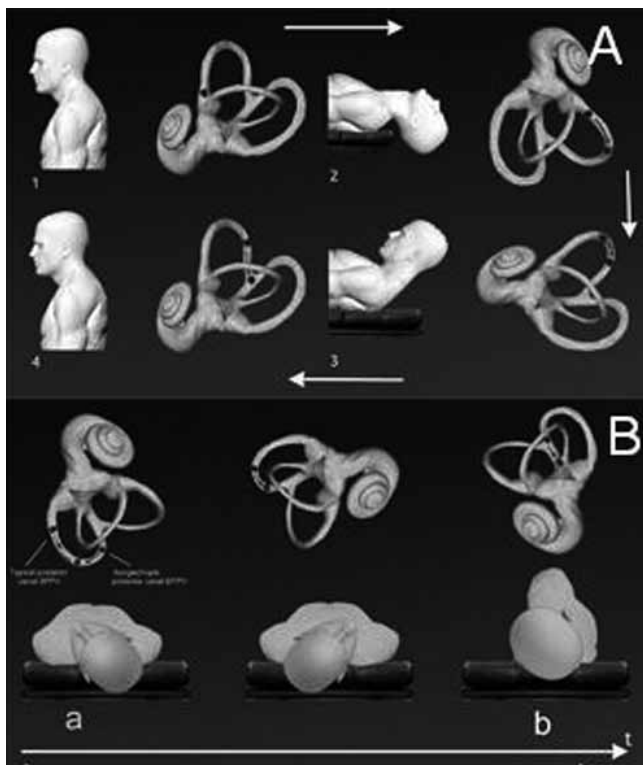


Fig. 3. Yacovino repositioning manoeuvre for anterior canal BPPV (A): during the manoeuvre otoliths move toward the common crus and the utricle. Head position is the same both for left and right anterior canal BPPV. Quick Liberatory Rotation manoeuvre (B) from the starting position (a) to the final contralateral lying-down position (b) for posterior canal BPPV. The time of execution is about one sec.

1. Anterior canal BPPV

1a: "certain" AC

- Presence of a positional vertical down-beating paroxysmal nystagmus evoked through the straight head-hanging positioning and sometimes through the Dix-Hallpike test.
- In such positions, possible presence of a clockwise torsional component for the left AC or of a counter-clockwise torsional component for the right AC.
- Canal conversion in typical posterior canal BPPV (TPC) during or immediately after (no more than two days) the therapeutic manoeuvre, characterised by a vertical up-beating nystagmus, clockwise for the left canal and counter-clockwise for the right canal.

1b: "Probable" AC

- As reported in 1a, but with a direct resolution of disease without canalar conversion in TPC.

1c: "Possible" AC

- Persistence of symptoms after five cycles of therapeutic manoeuvres.
- MRI does not show any neurological disease as a presumed cause of the nystagmus

or

- patient lost to follow-up before the resolution of the disease.

2. Apogeotropic Posterior Canal BPPV

2a: "Certain" APC

- Presence of a down-beating paroxysmal nystagmus, torsional clockwise for the right canal and counter-clockwise for the left canal, evoked through the Dix-Hallpike test and sometimes through the straight head-hanging positioning.
- Possible presence of a vertical down-beating component in the same positioning tests.
- Canalar conversion in TPC during or immediately after (no more than two days) the therapeutic manoeuvre.

2b: "probable" APC

- As reported in 2a, but with a direct resolution of disease without canalar conversion in TPC.

2c: "possible" APC

- Persistence of symptoms after five cycles of therapeutic manoeuvres.
- MRI does not show any neurological disease as a possible cause of nystagmus

or

- patient lost to follow-up before resolution of disease.

Statistical analysis was performed using Fisher's exact test to compare the efficacy of QLR in curing APC and TPC and the efficacy of YM in curing AC. These results depend on the accuracy of the initial diagnosis based on the presence of the above-reported diagnostic criteria; therefore, Fisher's exact test was also used to confirm if vertical nystagmus was actually prevalent in presumed

AC and torsional nystagmus in presumed APC, basing our analysis on the results of the "certain" grade both of APC and AC, where evidence is stronger than in the "probable" and "possible" grades. A p value ≤ 0.05 was considered statistically significant.

Results

No patient showed significant otomicroscopic or audiometric data. Five cases (#7 and #16 in Table I and #1, #2, #7 in Table II) had already been evaluated for TPC from 9 to 42 months before, and had been treated through QLR. Patient #2 in Table I and patient #8 in Table II had been treated by QLR for a left TPC three and five days before diagnosis, respectively, of APC and AC, which were then considered secondary to treatment. One patient (#10 in Table I) was known to have suffered a recent traumatic brain injury. Three patients had already undergone cerebral MRI before our observation, without signs of central nervous system disease. Vertiginous symptoms had occurred between 1 and 30 days before our visit. No patient regularly used neurotropic drugs or had taken vestibular suppressant drugs for at least 5 days before our visit.

The results of positioning tests and therapeutic manoeuvres are reported in Tables I and II.

Final diagnosis of APC and AC was made according to the above-mentioned criteria and grading system ("certain", "probable" and "possible").

Both AC and APC were characterised by paroxysmal nystagmus evoked in different positions and rarely inverting when returning to the sitting position. Paroxysmal nystagmus was usually more intense in frequency, amplitude and/or duration in AC than in APC, lasting in both forms from 1 to 4 min. In 3 patients with APC, the reverted nystagmus in returning to the sitting position was more intense than the nystagmus in Dix-Hallpike positioning. Only in 5 of the 11 patients with AC were we able to identify the affected side through a slight clockwise torsional component for the left canal, counter-clockwise for the right canal, regardless of the side of the head hanging positioning (Tables I and II). According to literature data, a torsional component of nystagmus was present in all 23 cases of presumed APC and in 5/11 cases of presumed AC; a down-beating component of nystagmus was present in 13/23 cases of presumed APC and in all 11 cases of presumed AC.

In APC, all patients presented nystagmus in Dix-Hallpike positioning, 4/23 only on the supposed affected side and 19/23 on both sides. In the head-hanging positioning, nystagmus was present in 16/23 patients; in 14 cases it presented a torsional component, in 8 of these cases the torsional component was associated with a down-beating component and in 2 cases only the down-beating component was present.

In AC, all patients presented nystagmus on both sides in either positioning, with different intensity. The straight head hanging position usually evoked the strongest nystagmus. Therapeutic manoeuvre caused a canal conversion to TPC in 19 cases (14 from the APC group and 5 from the AC group), and cured 12 patients in one step (8 in the APC group and 4 in the AC group).

Analysing the presence of a prevalent torsional nystagmus vs. a prevalent down beating vertical nystagmus in the “certain” APC group (14 patients) and in the “certain” AC group (5 patients), it emerged that torsional nystagmus

was more frequent in the presumed APC group, whereas vertical down-beating nystagmus was more frequent in the presumed AC group ($p = 0.03$ at Fisher’s exact test). All patients with canal conversion in TPC were successfully treated with QLR, performed from 1 to 3 times (Tables III and IV). A significant difference at Fisher’s exact test ($p < 0.0001$) was found in QLR efficacy in curing in one step APC (8/22 cases) vs. TPC (19/19 cases). Neuroimaging was never performed because 31 patients were disease-free after therapeutic manoeuvre and 3 patients, one with APC and two with AC, were lost to follow-up.

Table I. Clinical data of apogeotropic posterior canal BPPV patients.

Patient #	Sex	Age	Right dh nystagmus	Sitting Nystagmus	Left dh nystagmus	Sitting Nystagmus	S-HH-P nystagmus	Diagnosis	Therapeutic manoeuvre	Nr MANs	Outcome	Diagnostic grade
1	F	50	CW +++	CCW+	CCW++	CCW++	CW ++++	Left APC	QLR from left to right	2	Left TPC	Certain
2	M	42	-	-	CCW ++ DB+	-	-	Left APC	QLR from left to right	1	Left TPC	Certain
3	M	48	CW ++	-	CCW++	-	-	Right APC	QLR from right to left	1	Right TPC	Certain
4	M	43	CW +++	-	CCW++	-	-	Right APC	QLR from right to left	1	Right TPC	Certain
5	M	60	CCW++	CW++	CCW++	CW ++	CCW+ DB+	Left APC	QLR from left to right	2	Left TPC	Certain
6	M	65	CCW++	CW +	CCW+	CW +++	CCW+	Left APC	QLR from left to right	3	Left TPC	Certain
7	M	54	-	-	CCW++++ DB++	CW++++	DB+++	Left APC	QLR from left to right	2	Left TPC	Certain
8	M	40	CCW +	-	CCW++	-	DB+	Left APC	QLR from left to right	2	Left TPC	Certain
9	M	43	CW +	-	CW+	-	-	Right APC	QLR from right to left	1	Right TPC	Certain
10	F	70	CW++	-	CW++	-	CW ++	Right APC	QLR from right to left	3	Right TPC	Certain
11	F	61	CW ++ DB ++	-	CW ++ DB+	-	CW ++ DB+	Right APC	QLR from right to left	1	Right TPC	Certain
12	F	62	CW ++++ DB+++	-	CW +++ DB++	-	CW + DB ++	Right APC	QLR from right to left	5	Right TPC	Certain
13	M	60	CCW+++ DB +	-	CCW++ DB+	-	CCW+++ DB+	Left APC	QLR from left to right	2	Left TPC	Certain
14	F	64	CW + DB+	CW+	CW++ DB++	CW ++ DB+	CW++ DB+	Right APC	QLR from right to left	1	Right TPC	Certain
15	M	66	CW ++	-	CW ++	-	-	Right APC	QLR from right to left	2	Direct resolution	Probable
16	F	30	CW ++ DB++	-	CW +	-	CW +	Right APC	QLR from right to left	1	Direct resolution	Probable
17	F	51	CCW ++	CW+++	CCW +	-	-	Left APC	QLR from left to right	2	Direct resolution	Probable
18	F	60	CW + DB +	CCW+	CW +	-	-	Right APC	QLR from right to left	2	Direct resolution	Probable
19	M	59	CCW ++	-	CCW +	-	CW ++ DB+	Left APC	QLR from left to right	1	Direct resolution	Probable
20	M	52	CCW+	-	CCW++	-	CCW+	Left APC	QLR from left to right	2	Direct resolution	Probable
21	F	45	CCW++ DB +	-	CCW++ DB +	CCW++ DB +	CCW++ DB +	Left APC	QLR from left to right	3	Direct resolution	Probable
22	F	55	CCW+++ DB+	CCW+	CCW+++ DB+	CCW+	CCW+++ DB++	Left APC	QLR from left to right	1	Direct resolution	Probable
23	F	34	-	-	CCW++	CW +++	CCW++	Left APC	QLR from right to left	2	Lost to follow-up	Possible

Legend: DH: Dix-Hallpike positioning test; S-HH-P: Straight Head Hanging Positioning test; Nr Mans: Number of manoeuvres; F: Female; M: Male; CW: Clockwise; CCW: Counter-clockwise; DB: Down-beating; APC: Apogeotropic Posterior Canal BPPV; QLR: Quick Liberatory Rotation Manoeuvre; TPC: Typical Posterior Canal BPPV; Grading of Nystagmus: from + (the least) to ++++ (the greatest)

Table II. Clinical data of anterior canal BPPV patients.

Patient#	Sex	Age	Right DH nystagmus	Sitting nystagmus	Left DH nystagmus	Sitting nystagmus	S-HH-P nystagmus	Diagnosis	Therapeutic manoeuvre	Nr MANs	Outcome	Diagnostic grade
1	M	56	DB++	DB+ CCW+	DB +++ CCW++	-	DB+++++	Right AC	Yacovino	1	Right TPC	Certain
2	M	60	DB+++++	DB++	DB+++++	DB+	DB+++++	AC	Yacovino	3	Right TPC	Certain
3	F	46	DB+++	DB++	DB+++	DB+ + CW+	DB+++	(left?)AC	Yacovino	3	Left TPC	Certain
4	F	47	DB+++	-	DB+++	-	DB++	AC	Yacovino	2	Right TPC	Certain
5	M	63	DB+++++	-	DB+++++	-	DB+++++	AC	Yacovino	2	Right TPC	Certain
6	F	39	DB+	-	DB++	-	DB++	AC	Yacovino	1	Direct resolution	Probable
7	F	72	DB+	-	DB++	-	DB+	AC	Yacovino	1	Direct resolution	Probable
8	F	48	DB+ CW+	DB+ CW+	DB++	-	DB+++	Left AC	Yacovino	2	Direct resolution	Probable
9	F	66	DB++ CCW+	-	DB++ CCW+	-	DB++ CCW+	Right AC	Yacovino	1	Direct resolution	Probable
10	F	45	DB+ CW +	DB+ CW +	DB++	-	DB++	Left AC	Yacovino	2	Lost to follow-up	Possible
11	M	49	DB++ CW +	DB+ CW+	DB++	-	DB++++	Left AC	Yacovino	1	Lost to follow-up	Possible

Legend: DH: Dix-Hallpike positioning test; S-HH-P: Straight Head Hanging Positioning test; Nr Mans: Number of manoeuvres; F: Female; M: Male; CW: Clockwise; CCW: Counter-clockwise; DB: Down-beating; AC: Anterior Canal BPPV; TPC: Typical Posterior Canal BPPV; Grading of Nystagmus: from + (the least) to +++++ (the greatest)

Discussion

Anterior canal BPPV is considered rare for anatomic considerations because the anterior canal is higher than both the posterior and lateral ones; furthermore, the fact that the posterior arm of the anterior canal descends directly into the common crus and vestibule should cause a continuous self clearing of otoliths from the canal²⁸. To explain AC, changes in the diameter of the common crus, stenosis of membranous duct and changes in the position of the canal have been proposed^{10 17 28 29}. As reported by Giannoni⁷ and Korres¹⁷, AC can induce ambiguous nystagmus, depending on the position of otoconial debris; the most common clinical picture is characterised by vertical down-beating paroxysmal nystagmus in the Dix-Hallpike test, as well as in the straight head hanging positioning, with clockwise (or counter-clockwise) torsional components, due to a left anterior (or right anterior) canal involvement, without inversion of the nystagmus when coming back to the sitting position. AC is believed to be more frequent in post-traumatic BPPV^{13 20}. A down-beating vertical nystagmus with a clockwise (or counter-clockwise) torsional component for left (or right) canal is coherent with Flourens law, because it respects the plane of the interested canal, whereas according to Zapala¹⁵, an anterior bilateral canalolithiasis can be supposed for the presence of a pure vertical down-beating nystagmus. Nevertheless, a unilateral form of AC can also cause a vertical down-beating nystagmus, due to the orientation of the anterior canal which is closer to the sagittal plane (usually by a 41° angle) than the posterior canal (usually by a 56° angle); these considerations are enough to justify the frequent occurrence of a purely vertical down-beating nystagmus on both sides even in unilateral forms²⁸. The prevalence of down-beating components can

be caused by the fact that vestibulo-oculomotor torsional gain reflex is smaller than horizontal and vertical components gain³⁰.

Down-beating nystagmus syndrome can be associated with cerebellar diseases, and in such cases it is mandatory to exclude these from peripheral down beating nystagmus syndrome. Bertholon²⁸ reported 50 consecutive cases of positional down-beating nystagmus, 12 of which presented without central neurological symptoms or signs and a clinical picture of an anterior canal BPPV. Cambi³¹ recently showed that the natural course of most cases of down-beating nystagmus syndrome is towards a spontaneous resolution, and that it is sometimes associated with BPPV, so that the frequency of peripheral down-beating nystagmus syndrome appears to be more frequent than previously suggested: our data confirmed this possibility. Our diagnostic algorithm gives substantial importance to this aspect of the problem, but we decided to search for central neurological disease as a possible cause of positional vertical down-beating nystagmus not associated with other neurological signs and symptoms, only in the case of failure of therapeutic manoeuvres: in this situation, we included cerebral MRI in our diagnostic work-up. However, the frequent conversion of a down-beating nystagmus syndrome in a posterior canal BPPV or its direct resolution confirmed that, in these cases, as reported by Cambi³¹, a peripheral cause, i.e. anterior canal BPPV, is very probable.

Recently, Vannucchi described a new form of BPPV which he called "Apogotropic Posterior Canal BPPV" that is characterised by a torsional down-beating nystagmus clockwise for the right posterior canal and counter-clockwise for the left posterior canal. He explained the oculomotor pattern of APC is caused by ampullopetal

stimulation of the posterior semicircular canal due to free-floating otoconial debris in the non-ampullary arm, perhaps because putative alterations of posterior canal morphology can cause otolith entrapment in that zone^{4,5}. The less severe paroxysm could be due to the reduced movement of the otoconial mass and to the weaker inhibitory ampullopetal endolymphatic flow (III Ewald's law) caused by otoliths on diagnostic positioning tests³².

Differential diagnosis between APC and AC is possible due to the prevalence of the torsional component compared with the vertical one in APC, whereas differential diagnosis between APC and TPC is possible because of the inverted characteristics of the nystagmus, which in APC is down-beating, clockwise in the right Dix-Hallpike position and counter-clockwise in the left Dix-Hallpike position.

The above-mentioned criteria let us identify two populations in our cohort: the first composed of 23 patients affected by presumed APC (2.5%) and the second of 11 patients affected by presumed AC (1.2%) (Tabs. I and II). Therefore, AC appears to be rarer than reported in the literature, because we have diagnosed some cases as APC which otherwise may have been classified as AC. All patients we included in the APC group showed the oculomotor pattern described by Vannucchi^{4,5}. In three

APC patients, nystagmus reversed its direction with higher intensity in returning to the sitting position, probably because of the stronger excitatory ampullophugal endolymphatic flow (III Ewald's law).

APC was treated through QLR, a manoeuvre usually used in TPC, because in the Dix-Hallpike test on the affected side, the otoconial mass in the posterior canal always moves towards the most sloping part of the canal, regardless of its initial positioning, in both the ampullary and non-ampullary arm (Fig. 4). The canalar conversion from APC to TPC occurred in 14 cases (ranked "certain" in the diagnostic grade), and the direct resolution of APC occurred in 8 cases ("probable" diagnostic grade). One patient was lost to follow up ("possible" diagnostic grade). In conclusion, 22 of 23 patients affected by APC were successfully treated by QLR in a one-step or a two-step therapy, and one was lost to follow up. AC (Table 4) was treated with YM which caused canalar conversion in TPC in 5 patients ("certain" diagnostic grade) and was then cured through QLR (two-step therapy), whereas the direct resolution (one-step therapy) was obtained in 4 patients ("probable" diagnostic grade). Two patients were lost to follow-up ("possible" diagnostic grade) (Table II). The affected side was confirmed in only one patient with "certain" AC where the conversion into

Table III. Clinical data after the conversion from apogeotropic posterior canal to typical posterior canal BPPV.

Patient#	Sex	Age'	Right DH nystagmus	Sitting Nystagmus	Left DH nystagmus	Sitting Nystagmus	S-HH-P nystagmus	Diagnosis	Therapeutic manoeuvre	Nr MANs	Outcome
1	F	50	-	-	CW+++	CCW+		Left TPC	QLR from left to right	2	Resolution
2	M	42	-	-	CW+++	CCW+	CW+	Left TPC	QLR from left to right	1	Resolution
3	M	48	CCW++	CW+	-	-	-	Right TPC	QLR from right to left	1	Resolution
4	M	43	CCW+++	CW+	-	-	-	Right TPC	QLR from right to left	1	Resolution
5	M	60			CW++++	CCW+	-	Left TPC	QLR from left to right	2	Resolution
6	M	65	-	-	CW+++	CCW+	-	Left TPC	QLR from left to right	3	Resolution
7	M	54	-	-	CW+++	CCW+	-	Left TPC	QLR from left to right	2	Resolution
8	M	40	-	-	CW+++	CCW+	-	Left TPC	QLR from left to right	1	Resolution
9	M	43	CCW+++	CW+	-	-	-	Right TPC	QLR from right to left	1	Resolution
10	F	70	CCW+++	CW+	-	-	-	Right TPC	QLR from right to left	2	Resolution
11	F	61	CCW+++	CW+	-	-	-	Right TPC	QLR from right to left	1	Resolution
12	F	62	CCW++++	CW+	-	-	CCW++	Right TPC	QLR from right to left	2	Resolution
13	M	60	-	-	CW+++	CCW+	-	Left TPC	QLR from left to right	3	Resolution
14	F	64	CCW++++	CW ++	-	-	CCW+	Right TPC	QLR from right to left	1	Resolution

Legend: DH: Dix-Hallpike positioning test; S-HH-P: Straight Head Hanging Positioning test; Nr Mans: Number of manoeuvres; F: Female; M: Males; CW: Clockwise; CCW: Counter-clockwise; DB: Down-beating; APC: Apogeotropic Posterior Canal BPPV; QLR: Quick Liberatory Rotation Manoeuvre; TPC: Typical Posterior Canal BPPV; Grading of Nystagmus: from + (the least) to +++++ (the greatest)

Table IV. Clinical data after the conversion from anterior canal to typical posterior canal BPPV.

Patient#	Sex	Age	Right DH nystagmus	Sitting nystagmus	Left DH nystagmus	Sitting nystagmus	S-HH-P nystagmus	Diagnosis	Therapeutic manoeuvre	Nr MANs	Outcome
1	M	56	CCW++	CW+	-	-	-	right TPC	QLR from right to left	5	Resolution
2	M	60	CCW++++	CW++	-	-	-	right TPC	QLR from right to left	1	Resolution
3	F	46	-	-	CW+++	CCW+	CW+	left TPC	QLR from left to right	2	Resolution
4	F	47	CCW++	CW+	-	-	-	right TPC	QLR from right to left	1	Resolution
5	M	63	CCW++++	CW++	-	-	-	right TPC	QLR from right to left	1	Resolution

Legend: DH: Dix-Hallpike positioning test; S-HH-P: Straight Head Hanging Positioning test; Nr Mans: Number of manoeuvres; F: Female; M: Males; CW: Clockwise; CCW: Counter-clockwise; QLR: Quick Liberatory Rotation Manoeuvre; TPC: Typical Posterior Canal BPPV; Grading of Nystagmus: from + (the least) to +++++ (the greatest)

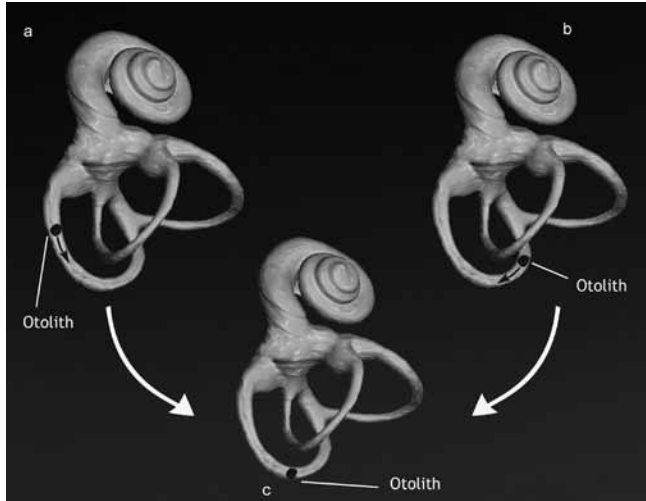


Fig. 4. Left typical (a) and apogeotropic (b) posterior canal BPPV: the final position of otoliths in the Dix-Hallpike positioning test is the same, in the sloping part of the canal (c).

an ipsilateral TPC confirmed our diagnostic hypothesis. QLR appeared more effective ($p < 0.0001$) in curing TPC (19/19 cases, 14 from the APC group, 5 from the AC group) than in curing APC, where a two-step therapy was frequently required (Table III). This result could be explained if an obstacle (i.e. a stenosis) was blocking the exit of otoliths from the non-ampullary arm toward the utricle in case of APC, a situation which could cause, at a later stage, a shift of otoliths toward the ampullary arm of the canal, the most frequent site of entrapment. The efficacy in two steps could be explained by hypothesising a fragmentation of otoliths during the first manoeuvre and their exit through the later manoeuvres.

On a speculative basis, this finding and the analogous finding of the conversion of AC into TPC through YM could further confirm that otoliths floating in semicircular canals could be the pathophysiological mechanism in BPPV even in rare forms of vertical canal BPPV.

Conclusions

Our data, based on the efficacy of therapeutic manoeuvres in the form of canalar conversion or direct resolution of the disease, confirmed that oculomotor patterns reported in the literature allow correct identification of both AC and APC; analysis of positioning-evoked nystagmus through infrared videonystagmoscopy permits differential diagnosis between AC, characterised by a prevalent vertical down-beating nystagmus and APC, in which the torsional component is prevalent and reverted compared to TPC. The diagnostic grading we propose could be useful in the management of these forms of BPPV.

The clinical evolution of our cases showed that the peripheral type of positional down-beating nystagmus is not uncommon, and that it is often the sign of an anterior

canal BPPV, characterised by a benign evolution, always keeping in mind that the presence of a positional down-beat nystagmus needs careful follow-up, particularly if nystagmus persists or reappears: in these cases, cerebral imaging through MRI is mandatory.

Correct differential diagnosis is of significant importance to identify the affected ear and to adopt the most appropriate therapeutic manoeuvre to obtain a good therapeutic outcome in these rare and atypical forms of BPPV. For APC, a specific liberatory manoeuvre can be considered, albeit in our experience based on a limited number of patients, QLR gives good results.

The authors acknowledge Dr. Genoveffa Errico for the original figures of the paper.

References

- 1 Leigh RJ, Zee DS. *The neurology of eye movements*. 4th ed. New York: Oxford University Press Inc 2006, pp. 559-97.
- 2 Katsarkas A. *Nystagmus of paroxysmal positional vertigo: some new insights*. *Ann Otol Rhinol Laryngol* 1987;96:305-8.
- 3 Oas JG. *Benign Paroxysmal positional vertigo. A clinician's perspective*. *Annals New York Academy of Science* 2001;942:201-9.
- 4 Vannucchi P, Giannoni B, Di Giustino F, et al. *La variante apogeotropica della VPP del CSP*. In: *Atti XXXIII Congresso Nazionale della Società Italiana di Audiologia e Foniatria "Audiologia, Foniatria e Scienze correlate"*. Bari 2011; pp. 69-70.
- 5 Vannucchi P, Pecci R, Giannoni B. *Posterior semicircular canal benign paroxysmal positional vertigo presenting with torsional downbeating nystagmus: an apogeotropic variant*. *Int J Otolaryngol* 2012;2012:413603.
- 6 Agus G. *Atypical "reversed" paroxysmal positioning nystagmus in benign paroxysmal positional vertigo*. *Acta Otolaryngol* 1995;520(Suppl.):143-7.
- 7 Giannoni B. *Vertical canal lithiasis*. In: Guidetti VG, Pagnini P, eds. *Labyrintholithiasis-Related Paroxysmal Positional*. Excerpta Medica; 2002. p. 157-170.
- 8 Korres S, Balatsouras DG, Kaberos A, et al. *Occurrence of semicircular canal involvement in benign paroxysmal positional vertigo*. *Otol Neurotol* 2002;23:926-32.
- 9 Califano L, Montanaro SC, Capparuccia PG, et al. *Case report: associazione ipsilaterale di canalolithiasi anteriore e posteriore*. *Acta Otorhinolaryngol Ital* 2002;22:376-9.
- 10 Crevits L. *Treatment of anterior canal benign paroxysmal positional vertigo by a prolonged forced position procedure*. *J Neurol Neurosurg Psychiatry* 200;75:779-81.
- 11 Kim YK, Shin JE, Chung JW. *The effect of canalith repositioning for anterior semicircular canal canalithiasis*. *ORL J Otorhinolaryngol Relat Spec* 2005;67:56-60.
- 12 Lopez-Escamez JA, Molina MI, Gamiz MJ. *Anterior semicircular canal benign paroxysmal positional vertigo and positional downbeating nystagmus*. *Am J Otolaryngol* 2006;27:173-8.
- 13 Jackson LE, Morgan B, Fletcher JC Jr, et al. *Anterior canal benign paroxysmal positional vertigo: an underappreciated entity*. *Otol Neurotol* 2007;28:218-22.

- ¹⁴ Lorin P. *Treatment of anterior semi-circular canalolithiasis by a sedimentation procedure in a vertical rotatory chair*. Ann Otolaryngol Chir Cervicofac 2007;124:184-8.
- ¹⁵ Zapala DA. *Down-Beating Nystagmus in anterior canal benign paroxysmal positional vertigo*. J Am Acad Audiol 2008;19:257-266.
- ¹⁶ Yacovino DA, Hain T, Gualtieri F. *New therapeutic maneuver for anterior canal benign paroxysmal positional vertigo*. J Neurol 2009;256:1851-5.
- ¹⁷ Korres S, Riga M, Sandris V, et al. *Canalolithiasis of the anterior semicircular canal (ASC): Treatment options based on the possible underlying pathogenetic mechanisms*. Int J Audiol 2010;49:606-12.
- ¹⁸ Casani AP, Cerchiai N, Dallan I, et al. *Anterior canal lithiasis: diagnosis and treatment*. Otolaryngol Head Neck Surg 2011;144:412-8.
- ¹⁹ Heidenreich KD, Kerber KA, Carender WJ, et al. *Persistent positional nystagmus: a case of superior semicircular canal benign paroxysmal positional vertigo?* Laryngoscope 2011;121:1818-20.
- ²⁰ Długaiczek J, Siebert S, Hecker DJ, et al. *Involvement of the anterior semicircular canal in posttraumatic benign paroxysmal positional vertigo*. Otol Neurotol 2011;32:1825-90.
- ²¹ Adamec I, Habek M. *Anterior semicircular canal BPPV with positional downbeat nystagmus without latency, habituation and adaption*. Neurol Sci 2012;33:955-6.
- ²² Califano L, Capparuccia PG, Di Maria D, et al. *Treatment of benign paroxysmal positional vertigo of posterior semicircular canal by "Quick Liberatory Rotation Manoeuvre"*. Acta Otorhinolaryngol Ital 2003;23:161-7.
- ²³ Choung Y-H, Shin YR, Kahng H, et al. *"Bow and Lean test" to determine the affected ear of horizontal canal benign paroxysmal positional vertigo*. Laryngoscope 2006;116:1776-81.
- ²⁴ Asprella-Libonati G. *Pseudo-spontaneous nystagmus: a new sign to diagnose the affected side in lateral semicircular canal benign paroxysmal positional vertigo*. Acta Otorhinolaryngol Ital 2008;28:73-8.
- ²⁵ Cipparrone L, Corridi G, Pagnini P. *Cupulolithiasis*. In: *V Giornata Italiana di Nistagmografia Clinica*. Milano: Ed. Boots-Formenti; 1985. p. 36-53.
- ²⁶ McClure JA. *Horizontal canal BPV*. J Otolaryngol 1985;14:30-5.
- ²⁷ Fife TD, Iverson DJ, Lempert TJ, et al. *Practice parameter: therapies for benign paroxysmal positional vertigo (an evidence-based review): Report of the Quality Standards Subcommittee of the American Academy of Neurology*. Neurology 2008;70:2067-74.
- ²⁸ Bertholon P, Bronstein AM, Davies RA, et al. *Positional down beating nystagmus in 50 patients: cerebellar disorders and possible anterior semicircular canalolithiasis*. J Neurol Neurosurg Psychiatry 2002;72:366-72.
- ²⁹ Schratzenstaller B, Wagner-Manslau C, Strasser G, et al. *Canalolithiasis of the superior semicircular canal: An anomaly in benign paroxysmal vertigo*. Acta Otolaryngol 2005;125:1055-62.
- ³⁰ Aw ST, Todd MJ, Aw GE, et al. *Benign positional nystagmus: a study of its three-dimensional spatio-temporal characteristics*. Neurology 2005;64:1897-905.
- ³¹ Cambi J, Astore S, Mandalà M, et al. *Natural course of positional down-beating nystagmus of peripheral origin*. J Neurol 2013;260:1489-96.
- ³² Ichijo H. *Asymmetry of positioning nystagmus in posterior canalolithiasis*. Acta Otolaryngol 2013;133:159-64.

Received: June 27, 2013 - Accepted: December 12, 2013

BASIC RESEARCH IN OTOLARYNGOLOGY

The effect of the NMDA channel blocker memantine on salicylate-induced tinnitus in rats

Effetti della memantina, antagonista non competitivo dei recettori NMDA, sull'acufene indotto da salicilato nel ratto

M. RALLI¹, D. TROIANI², M.V. PODDA², F. PACIELLO¹, S.L.M. ERAMO², E. DE CORSO¹, R. SALVI³, G. PALUDETTI¹, A.R. FETONI¹

¹ Institute of Otolaryngology, Università Cattolica del Sacro Cuore, Roma, Italy; ² Institute of Physiology, Università Cattolica del Sacro Cuore, Roma, Italy; ³ Center for Hearing and Deafness, Department of Communicative Disorders and Sciences, University at Buffalo, NY

SUMMARY

Short-term tinnitus develops shortly after the administration of a high dose of salicylate. Since salicylate selectively potentiates N-methyl-D-aspartate (NMDA) currents in spiral ganglion neurons, it may play a vital role in tinnitus by amplifying NMDA-mediated neurotransmission. The aim of this study was to determine whether systemic treatment with a NMDA channel blocker, memantine, could prevent salicylate-induced tinnitus in animals. Additional experiments were performed to evaluate the effect of memantine on the auditory brainstem response (ABR) and distortion product otoacoustic emissions (DPOAE) to test for changes in hearing function. Thirty-six rats were divided into 3 groups and treated daily for four consecutive days. One group (n = 12) was injected with salicylate (300 mg/kg/d, IP), the second (n = 12) was treated with memantine (5 mg/kg/d, IP) and the third group (n = 12) was injected with salicylate and memantine. All rats were tested for tinnitus and hearing loss at 2, 24, 48 and 72 h after the first drug administration and 24 h post treatment; tinnitus-like behaviour was assessed with gap prepulse inhibition of acoustic startle (GPIAS), and hearing function was measured with DPOAE, ABR and noise burst prepulse inhibition of acoustic startle (NBPIAS). Rats in the salicylate group showed impaired GPIAS indicative of transient tinnitus-like behaviour near 16 kHz that recovered 24 h after the last salicylate treatment. Memantine did not cause a significant change in GPIAS. Combined injection of salicylate and memantine significantly attenuated GPIAS tinnitus-like behaviour at 48 hours after the first injection. None of the treatments induced permanent threshold shifts in the ABR and DPOAE, which recovered completely within one day post treatment. Animals treated with salicylate plus memantine showed results comparable to animals treated with salicylate alone, confirming that there is no effect of memantine on DPOAE which reflects OHC function. The present study confirms the role of cochlear NMDA receptors in the induction of salicylate-induced tinnitus.

KEY WORDS: Tinnitus • Memantine • Salicylate • Startle reflex • NMDA receptors • Rats

RIASSUNTO

Il sodio salicilato, principio attivo dell'aspirina, è una molecola in grado di indurre un acufene transitorio mediante l'attivazione dei recettori N-metil-D-aspartato (NMDA) a livello periferico e centrale. L'obiettivo primario di questo studio è di valutare la potenzialità della memantina, inibitore selettivo dei recettori NMDA, nel contrastare l'insorgenza e la persistenza dell'acufene indotto da salicilato in un modello animale. Obiettivo secondario è lo studio degli effetti della memantina sulla funzione uditiva e sulle cellule ciliate esterne. Nel nostro studio sono stati utilizzati 36 ratti divisi in tre gruppi: nel primo gruppo (n = 12) gli animali sono stati trattati con salicilato (300 mg/kg/d, IP), nel secondo (n = 12) con memantina (5 mg/kg/d, IP), nel terzo (n = 12) con entrambi. In tutti gli animali è stato studiato l'acufene con la tecnica GPIAS ad intervalli di 2, 24, 48, 72 e 96 ore dalla prima somministrazione e la funzione uditiva mediante i prodotti di distorsione (DPOAE) ed i potenziali evocati uditivi (ABR). Negli animali trattati con salicilato la nostra metodica ha evidenziato la presenza di un acufene con frequenza vicina ai 16 kHz insorto dopo la prima somministrazione e risolto spontaneamente 24 ore dopo l'ultima. Negli animali trattati con salicilato e memantina l'acufene, seppur presente, è risultato significativamente attenuato, prevalentemente durante il secondo giorno di trattamento. Né il salicilato né la memantina hanno causato alterazioni permanenti della funzione uditiva; le variazioni registrate mediante i prodotti di distorsione sono regredite al termine del trattamento. Il nostro studio conferma il ruolo dei recettori NMDA nell'acufene da salicilato e le potenzialità della memantina nel contrastarne l'insorgenza e la persistenza. Data la facile reperibilità del farmaco, già utilizzato nel trattamento della malattia di Alzheimer e del morbo di Parkinson, ed i risultati incoraggianti ottenuti nel modello animale, sono auspicabili ulteriori approfondimenti nell'uomo.

PAROLE CHIAVE: Acufene • Memantina • Salicilato • Riflesso di Startle • Recettori NMDA • Ratti

Acta Otorhinolaryngol Ital 2014;34:198-204

Introduction

Subjective tinnitus, defined as the perception of a sound when no external stimulation is present, is a condition that affects a large portion of the world population, with over 16 million subjects in the US reporting frequent tinnitus¹. Tinnitus has been widely studied in humans and animals to better understand the molecular mechanisms that underlie its onset and persistence, and to identify drugs that could be used for treatment.

Short-term tinnitus has been reported following administration of high-doses of sodium salicylate. The molecular mechanisms through which salicylate induces tinnitus have been explored², especially its effects on the cyclooxygenase which blocks the conversion of arachidonic acid to prostaglandin H₂^{3,4}. The increased concentration of arachidonic acid acts on N-methyl-D-aspartic acid (NMDA) receptors, inducing both peripheral and central effects. NMDA receptors are expressed on the synapses between inner hair cells and cochlear spiral ganglion neurons⁵. In vitro, salicylate potentiates the NMDA class of glutamatergic currents on cochlear spiral ganglion neurons. Salicylate also impairs outer hair cell (OHC) electromotility⁶, although prolonged treatment has been reported to strengthen OHC motility^{7,8} and reduces blood flow in the cochlea⁹. High doses of salicylate increase the threshold and reduce the amplitude of the compound action potential (CAP), but salicylate paradoxically results in hyperactivity in the central auditory cortex¹⁰.

Memantine, a drug recently approved for the treatment of moderate to severe Alzheimer's disease¹¹, has been reported to suppress excitatory neurotransmission between the hair cell and auditory nerve afferent fibers by blocking NMDA receptors¹², and is likely to exert effects on the central auditory pathways¹³. Memantine has been previously studied for its ability to suppress tinnitus in animals¹⁴ and humans¹⁵ and found to have little or no effect; however, Zheng et al., in 2012¹⁶, reported encouraging effects of memantine in noise-induced tinnitus in the rat.

The animal model used to study tinnitus is the gap prepulse inhibition of the startle reflex (GPIAS); the method was developed by Turner in 2006¹⁷ and later adopted and optimized by others¹⁸⁻²³. Since GPIAS does not require any training and relies on a reflex response, it is a very efficient method of testing for tinnitus compared to time consuming operant conditioning techniques, thereby allowing a larger number of animals to be evaluated²⁴.

The primary goal of this study was to determine if memantine, a NMDA antagonist, would affect salicylate-induced tinnitus. A secondary goal was to determine what effects memantine or the combination of memantine and salicylate would have on DPOAE and ABR.

Materials and methods

Animals

Thirty-six adult male Sprague Dawley rats (3-5 months, 220-450 g) were used for this study. Rats were divided into three groups: a SAL group (n = 12) injected IP with salicylate (300 mg/kg/d) in bacteriostatic saline, 50 mg/ml (Sigma); a MEM group (n = 12) treated with memantine at a dose of 5 mg/kg/d diluted in bacteriostatic saline, 50 mg/ml (Sigma); a SAL+MEM group (n = 12) injected with salicylate and memantine combined at the dosage used in the other groups. All animals were treated daily for four consecutive days; drug administration was performed 2 h before testing for tinnitus.

The experimental protocol was approved by the Institutional Animal Care and Use Committee of the Catholic University of the Sacred Heart, Rome Italy. Animals were housed in a colony with a 12 h light-dark cycle; food and water were available ad libitum.

Gap prepulse inhibition of acoustic startle

Tinnitus was assessed using gap prepulse inhibition of acoustic startle as described in our previous investigation²⁴. Rats were placed in an acoustically transparent wire mesh cage (7.2 cm W, 20 cm L, 6.5 cm H) on a Plexiglas platform; the platform (20 cm × 10 cm) rested on a 50 mm piezoelectric transducer (MCM 28-745). The test apparatus was located in a soundproof chamber equipped with a tweeter (Fostex FT17H) on the chamber's ceiling about 15 cm above the rat's head. The continuous background noise, gap stimulus, prepulse noise burst and startle stimulus were generated with a digital-to-analogue converter at ~100 kHz sampling rate (Tucker Davis Technologies, RP2.1, PA5, SA1). Startle amplitude measured by the piezoelectric transducer was amplified (10-100×), low-pass filtered at 1,000 Hz; WPI, USA) and fed to the analogue-to-digital converter on a separate data acquisition module (TDT, RP2.1) using custom software.

GPIAS sessions were composed of 80 silent gaps trials (gap) embedded in narrow band noise and 80 no-gap trials (no-gap) in the narrow band noise (Fig. 1A-C). Twenty gap and 20 no-gap trials were made at each of the four narrow band noises centred at 6, 12, 16 or 20 kHz. Gap and no-gap trials were presented in pairs in random order. Trials were separated by a variable period ranging from 7 to 15 sec long. Animals were given a 2-min acclimation period at the beginning of each session during which no gaps or startle sounds occurred. Gap trials were composed of a 60 dB SPL continuous narrow band noise (1,000 Hz wide, centered at 6, 12, 16 and 20 kHz), and a 50 msec startle stimulus (broadband noise burst, 116 dB SPL, 50 msec length, 5 msec rise/fall time) preceded by a 100 msec silent gap that ended 100 msec before the onset of the startle stimulus. In no-gap trials, the background sound was continuous

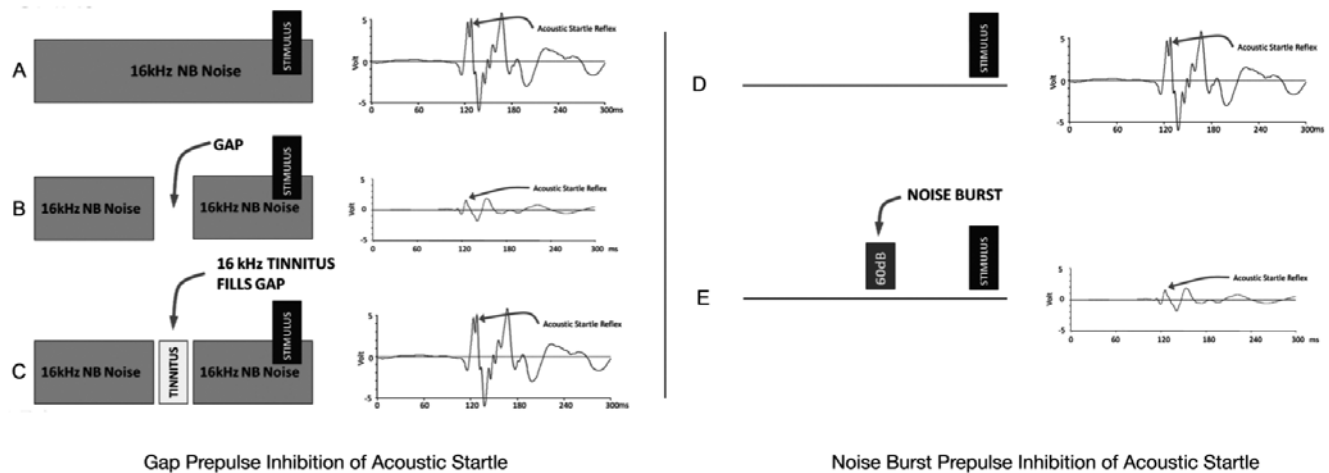


Fig. 1. Schematics of the animal model used to highlight the presence and time course of tinnitus in rats. Gap prepulse inhibition of acoustic startle: (A) Following the startle stimulus without a prepulse gap results in a large amplitude startle reflex. (B) When a 50 msec gap prepulse is inserted prior to the startle stimulus, the startle reflex response is significantly reduced. (C) Tinnitus fills in the gap and the animal can no longer hear the silent gap, resulting in a reduction of the startle response similar to the no-gap condition. (D) Noise burst prepulse inhibition of acoustic startle: NBPIAS is used to evaluate whether the animal can hear the background noise used in the GPIAS paradigm. In NBPIAS, the startle stimulus is presented in a silent environment; this results in a large startle response. (E) When a 60 dB noise burst prepulse precedes the startle stimulus, the startle response is reduced.

without a silent period preceding the startle stimulus. The amplitude of the startle reflex signal was measured as the root-mean-square (RMS) voltage on gap and no-gap trials. Noise burst prepulse inhibition of the acoustic startle reflex (NBPIAS) was used to determine the audibility of the narrow band noises used for GPIAS assessment (Fig. 1D-E). NBPIAS was recorded using the same equipment as GPIAS except that the background noise was removed and the startle stimulus was presented alone (i.e. in quiet) or was preceded by a 60 dB SPL narrow band noise burst (1,000 Hz wide, 100 msec, 5 msec rise/fall time, centred at 6, 12, 16 or 20 kHz.). Twenty noise burst and 20 quiet trials were made at each tested frequency.

Gap and noise burst prepulse inhibition of acoustic startle were calculated as a percentage for each frequency using the formulas $1 - (\text{gap}/\text{no-gap})$ for GPIAS and $1 - (\text{noise burst}/\text{quiet})$ for NBPIAS. For each frequency, a significant reduction of GPIAS was interpreted as behavioural evidence of tinnitus. Conversely, significant inhibition of the startle response in NBPIAS sessions was interpreted as evidence that the animal could hear the narrow band noise used in GPIAS sessions.

Animals were tested daily with GPIAS and NBPIAS before and 2 h after each drug administration; measurements were obtained for five consecutive days (four measurements during treatment; one post treatment).

Auditory brainstem response recordings

Hearing function was evaluated in all animals using the auditory brainstem response (ABR). ABR thresholds were obtained at 6, 12, 16, 24 and 32 kHz in all animals before and 14 days after the end of the drug treatment. Rats were anaesthetized (ketamine 10 mg/kg) and placed

in a sound attenuating booth; the non-inverting (+) electrode was inserted at the vertex, the inverting (-) electrode was placed near the pinna of the test ear and the ground electrode was placed near the pinna of the opposite ear. A TDT System 3 (BioSigRP, Tucker-Davis Technologies, Alachua, Florida, USA) data acquisition system was used for stimulus generation and data acquisition. Tone bursts corresponding to tested frequencies were presented monaurally in an open field (Fostex, TD28D, USA) with the speaker pointed towards the test ear at a distance of 1 cm; the contralateral ear was plugged with a silicon plug. Responses were filtered (100-3,000 Hz band pass), digitized (10 kHz sampling rate) and averaged over 1,000 samples at each frequency. Threshold testing began with the stimulus presented at 100 dB SPL in order to generate a clear ABR waveform; then the intensity was reduced in 10 dB steps until the ABR response disappeared. Next, the intensity of the stimulus was increased in 5 dB steps from below threshold until the ABR response reappeared. The ABR threshold was defined as the lowest intensity at which the ABR could be detected and replicated^{25 26}.

Distortion product otoacoustic emissions

DPOAEs were measured unilaterally using an otoacoustic emission system (Intelligent Hearing System, Miami, FL, USA). The $f2/f1$ ratio of the primary tones was set to 1.2. DPOAE input/output functions were measured at $f2$ frequencies of 4, 8, 12, 16 and 20 kHz. The $f1$ intensity, L1, always presented +10 dB above the $f2$ intensity, L2. Animals were anaesthetized with ketamine as described above and placed on a heating pad in a sound-attenuating booth. The probe assembly was placed in the animal's external ear canal. Input/output functions were obtained

by increasing L1 intensity from 25 to 70 dB SPL at f2 frequencies of 4, 8, 12, 16 and 20 kHz (32 sweeps per frequency pair). DPOAEs were recorded before and 2 h after each drug treatment for 5 consecutive days.

Statistical analysis

GPIAS and NBPIAS data were analyzed using a two-way repeated measures analysis of variance (RM-ANOVA, $\alpha < 0.05$); post-hoc testing was performed using Tukey's test for multiple comparisons. Significant differences between frequency-specific data recorded at each time point and baseline values were analyzed using a one-way ANOVA ($p < 0.05$). Statistical analysis of ABR and DPOAE measurements were performed using a one-way ANOVA with post-hoc Student-Newman-Keuls analysis. All results were presented as mean \pm SEM.

Results

Tinnitus assessment

Figure 1A-C is a schematic of the GPIAS paradigm that shows the stimulus conditions and hypothetical results for no-gap, gap and tinnitus conditions. Figure 2 shows the percent GPIAS values at 6, 12, 16 and 20 kHz before

and at various time points during the four days of drug treatment. Baseline GPIAS values are represented by the horizontal dotted line (line width equals baseline standard deviation; baseline values were 43.8, 42.3, 37.6 and 38.8% for 6, 12, 16 and 20 kHz respectively).

Rats treated with salicylate alone (SAL) showed a significant reduction in GPIAS at 16 kHz, consistent with tinnitus-like behaviour with a pitch near 16 kHz. A significant reduction occurred between 2 and 72 h with a peak at 48 hours; GPIAS returned near to baseline levels 24 h after the last day of drug administration. A statistically significant decrease in mean GPIAS was observed at 16 kHz at 2 h ($p = 0.041$), 24 h ($p = 0.036$), 48 h ($p = 0.019$) and 72 h ($p = 0.047$) during treatments; 24 h after the end of the treatment mean values returned near to baseline levels (34.95%; $p = 0.65$). GPIAS values did not show a significant change at 6, 12 and 20 kHz during the salicylate treatment (2 to 72 h).

Rats treated with memantine alone (MEM) showed no significant changes in GPIAS compared to baseline values during the entire length of treatment (data not shown).

Rats treated with a combination of salicylate and memantine (SAL+MEM) showed less reduction in GPIAS than rats treated with salicylate alone (SAL), particularly at

16 kHz during the first 48 hours of treatment. There was a statistically significant difference at 48 h between the SAL and the SAL+MEM groups ($p = 0.023$). NBPIAS was also tested in the SAL, SAL+MEM and MEM groups; no significant changes were observed over the entire testing period between baseline measures and values obtained during treatments and post-treatment. Data for all groups are compared in Figure 2.

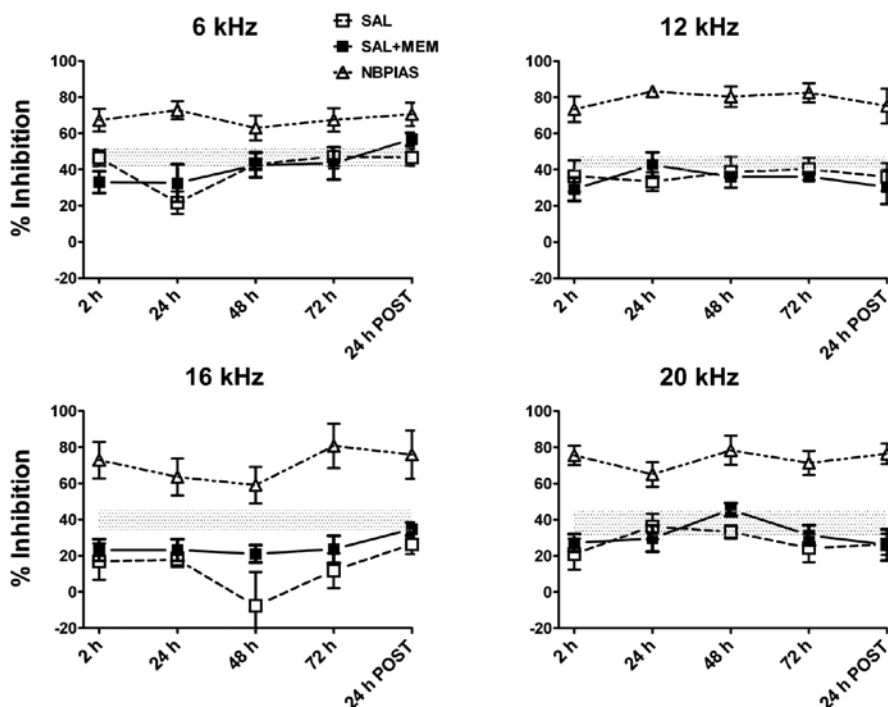


Fig. 2. Data obtained in our animal groups showing the time course of tinnitus for different treatments. Percent GPIAS in rats treated with salicylate alone or salicylate and memantine plotted by frequency; NBPIAS data are also shown for comparison. The horizontal dotted line represents baseline data. Rats treated with memantine alone showed no evidence of tinnitus (data not shown). Rats treated with salicylate alone showed transient tinnitus-like behaviour with a pitch near 16 kHz, starting 2 hours after the first injection, lasting for the entire length of treatment (4 days) and resolving spontaneously 24 hours after the last day of drug administration (24 h POST). In rats treated with salicylate and memantine, tinnitus-like behaviour was greatly attenuated, particularly during the first 48 hours of treatment, suggesting that memantine must suppress tinnitus-like behaviour at peripheral or central NMDA receptors.

ABR

Baseline ABR threshold values recorded before treatment did not show a statistically significant group difference among the SAL, MEM and SAL+MEM groups (Two-way ANOVA, $p = 0.36$). No significant difference was seen between baseline and post-treatment thresholds measured 14 days after the end of treatment ($p = 0.41$). These results indicate that salicylate, memantine or the combination of the two does not produce any long term change in hearing thresholds.

DPOAEs

DPOAEs were tested in all animals at 4, 8, 12, 16 and 20 kHz, and were measured before, during (2, 24, 48 and 72 h) and 24 h after SAL, MEM and SAL+MEM treatments. A progressive decrease in amplitude was observed in the salicylate group for low-level DPOAEs at 8, 12 and 16 kHz. High-level DPOAEs were slightly affected; the largest changes occurred 2 h after salicylate injection at 8 and 12 kHz. Amplitudes returned to near baseline values within one day post-treatment. Memantine alone had no effect on DPOAE amplitude. Treatment with SAL+MEM resulted in a decline of DPOAE amplitude comparable to salicylate alone. Data for all groups (SAL, MEM, SAL+MEM) are plotted in Figures 3A and 3B.

Discussion

The effect of memantine on salicylate-induced tinnitus

Memantine, a non-competitive NMDA antagonist that affects neurotransmission between inner hair cells and afferent auditory nerve fibers, has been hypothesized to suppress tinnitus. Memantine is currently approved for the treatment of moderate to severe cases of Alzheimer’s disease, and has been proposed for the treatment of Parkinson’s disease and certain forms of dementia¹¹. Given its availability in clinical settings, memantine and its analogues have been considered as potential treatments for tinnitus²⁷. To test this hypothesis, Lobarinas and colleagues treated rats with a moderate dose (150 mg/kg) of salicylate and obtained behavioural evidence of tinnitus using an operant lick suppression technique¹⁴. Rats were then treated with 1.5 or 3 mg/kg of memantine combined with 150 mg/kg of salicylate to determine if memantine

would suppress tinnitus-like behaviour. While tinnitus was not completely suppressed by 1.5 or 3 mg/kg memantine, the molecule tended to reduce the tinnitus-like behaviour, which was more pronounced at the higher dose. Therefore, while tinnitus was not completely abolished by memantine, the evidence suggested that tinnitus severity might be somewhat reduced. Lobarinas attempted to use a higher dose of memantine, but found that 10 mg/kg disrupted the operant behaviour; consequently, higher doses of memantine were not evaluated for suppression of tinnitus.

Figueredo et al. published a randomized, double-blind placebo-controlled trial in which tinnitus was studied in 60 patients, and its severity was monitored using the Tinnitus Handicap Inventory (THI). In this study, memantine was administered at a dose of 20 mg per day for 90 days. They reported no statistically significant differences between patients in the memantine group and those in the placebo group¹⁵. Taken together, these two studies suggest that memantine may have little or no effect on tinnitus.

In the current study, using GPIAS as our behavioural metric for tinnitus, we observed evidence of tinnitus at 16 kHz with 300 mg/kg of salicylate and found that the 5 mg/kg dose of memantine significantly reversed tinnitus-like GPIAS behaviour. Thus, our results suggest that a 5 mg/kg dose of memantine, nearly twice that used by Lobarinas, can suppress tinnitus. Importantly, animals treated with memantine alone did not show significant changes in GPIAS.

A recent paper from Zheng et al.¹⁶ investigated the efficacy of a 5 mg/kg dose of memantine in rats with behavioural evidence of tinnitus assessed with an operant lick-

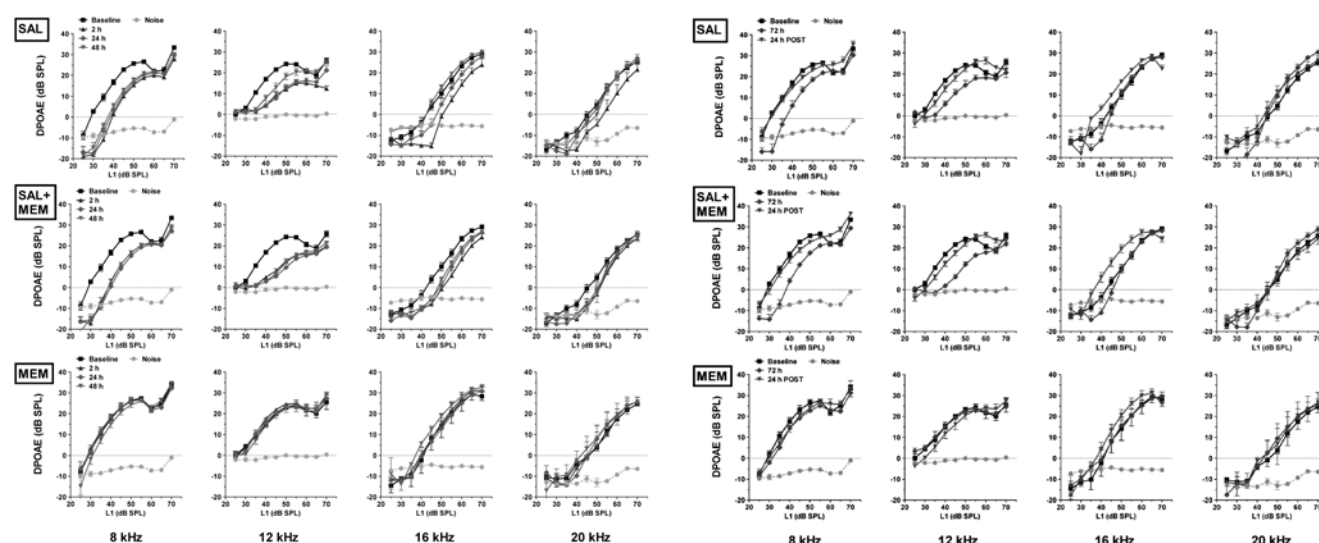


Fig. 3. The effect of salicylate and memantine on outer hair cells. DPOAE measurements in animals treated with memantine, salicylate or a combination of both. Data from baseline and 2, 24 and 48 h time points are shown in Fig 3A; data from baseline and 72, 24 h post time points are shown in Fig 3B. Memantine alone had no effect on DPOAE amplitude whereas salicylate alone caused a progressive decrease in DPOAE over the 4-day treatment. The combination of both drugs resulted in DPOAE amplitudes similar to those obtained in animals treated with salicylate alone.

suppression technique. They found that a 1 h, 110 dB, 16 kHz traumatizing tone induced tinnitus having a pitch of 32 kHz in five of eight exposed rats. After treatment with 5 mg/kg memantine, only 2 of the 5 rats continued to show evidence of noise-induced tinnitus, i.e., memantine eliminated signs of tinnitus in 3 of 5 rats.

Our results are consistent with those of Zheng suggesting that higher doses of memantine may suppress tinnitus. However, it should be noted that while the 5 mg/kg dose of memantine caused a statistically significant improvement in tinnitus, our GPIAS values during SAL+MEM were still slightly below their baseline GPIAS values. In other words, while 5 mg/kg memantine significantly improved tinnitus-like behaviour, it may not have completely suppressed tinnitus. Likewise, memantine only led to a reduction in noise-induced tinnitus in 60% of subjects in the Zheng study. It is conceivable that higher doses of memantine may be more effective in suppressing tinnitus; however, the behavioural side effects, as noted by Lobarinas²⁸ may outweigh the benefits.

Salicylate, memantine and auditory function

Our results show that memantine had no effect on DPOAE amplitudes during treatment. These results are consistent with the view that memantine acts on neuronal NMDA receptors, which are not expressed in adult OHC²⁹. In addition, our results show that memantine had no effect on OHC function, as reflected in DPOAE, when administered with salicylate; results are consistent with the view that memantine is not acting on the OHC. Short-term treatment with salicylate, memantine or the combination of the two had no permanent effects on ABR; thresholds recorded 14 days after drug treatments showed no differences compared to baseline. Serial DPOAE measurements from 2 to 72 h of salicylate treatment revealed a cumulative dose-dependent effect mainly on low-level DPOAEs at 8, 12 and 16 kHz; i.e. DPOAE amplitudes tended to decrease over the 3 day treatment. These results are consistent with previous results showing a gradual decline in DPOAE amplitude over several days of salicylate treatment³⁰. However, DPOAE amplitudes recovered to within normal limits within 1 day after the end of treatment. Since animals treated with salicylate and memantine showed DPOAE alteration comparable to salicylate alone, the effects of memantine on GPIAS are unlikely to be due to changes in OHC function.

Conclusions

The present study confirms that salicylate can induce transient, reversible tinnitus when administered at high doses. More importantly, our behavioural assessment of tinnitus using GPIAS suggests that a 5 mg/kg dose of memantine, which was nearly two fold greater than that used by Lobarinas, can significantly reduce tinnitus-like behaviour.

Since higher doses (10 mg/kg) of memantine can disrupt behaviour, effective treatment of tinnitus using NMDA antagonists may require careful titration of the dose to obtain clinical efficacy without inducing deleterious side effects. The suppression of tinnitus-like behaviour in our study was achieved with systemic memantine treatment, it is therefore unclear if the therapeutic effect of memantine is occurring at the IHC-auditory nerve fibre synapse, as proposed by Puel et al.⁵, or if it is occurring at multiple sites within the central auditory pathway. Given the encouraging results and clinical availability of memantine, it would be interesting to further explore its efficacy in humans with tinnitus. Since the effective therapeutic window for drug dosing appears to be relatively narrow, effective tinnitus therapy may require careful escalation of the dose of memantine to achieve optimal therapy with minimal side effects.

Acknowledgements

Research supported in part by grants from Fondi di Ateneo, UCSC Rome Italy and Office of Naval Research (N000141210731), NIH (R01DC009091; R01DC009219).

References

- Shargorodsky J, Curhan GC, Farwell WR. *Prevalence and characteristics of tinnitus among US adults*. Am J Med 2010;123:711-8.
- Cazals Y. *Auditory sensorineural alterations induced by salicylate*. Prog Neurobiol 2000;62:583-631.
- Vane JR, Botting RM. *Mechanism of action of anti-inflammatory drugs*. Int J Tissue React 1998;20:3-15.
- Mitchell JA, Akarasereenont P, Thiemermann C. et al. *Selectivity of nonsteroidal anti-inflammatory drugs as inhibitors of constitutive and inducible cyclooxygenase*. Proc Natl Acad Sci USA 1993;90:11693-7.
- Ruel J, Chabbert C, Nouvian R, et al. *Salicylate enables cochlear arachidonic-acid-sensitive NMDA receptor responses*. J Neurosci 2008;28:7313-23.
- Ermilov SA, Murdock DR, El-Daye D, et al. *Effects of salicylate on plasma membrane mechanics*. J Neurophysiol 2005;94:2105-10.
- Chen GD, Kermany MH, Ralli M, et al. *Too much of a good thing: long-term treatment with salicylate strengthens outer hair cell function but impairs auditory neural activity*. Hear Res 2010;265:63-9.
- Yang K, Huang ZW, Liu ZQ, et al. *Long-term administration of salicylate enhances prestin expression in rat cochlea*. Int J Audiol 2009;48:18-23.
- Didier A, Miller JM, Nuttall AL. *The vascular component of sodium salicylate ototoxicity in the guinea pig*. Hear Res 1993 ;69:199-206.
- Chen GD, Stolzberg D, Lobarinas E, et al. *Salicylate-induced cochlear impairments, cortical hyperactivity and re-tuning, and tinnitus*. Hear Res 2013;295:100-13.
- Olivares D, Deshpande VK, Shi Y, et al. *N-methyl D-aspar-*

- tate (NMDA) receptor antagonists and memantine treatment for Alzheimer's disease, vascular dementia and Parkinson's disease. *Curr Alzheimer Res* 2012;9:746-58.
- ¹² Oestreicher E, Arnold W, Ehrenberger K, et al. *Memantine suppresses the glutamatergic neurotransmission of mammalian inner hair cells*. *ORL J Otorhinolaryngol Relat Spec* 1998;60:18-21.
- ¹³ Tikhonravov D, Neuvonen T, Pertovaara A, et al. *Dose-related effects of memantine on a mismatch negativity-like response in anesthetized rats*. *Neuroscience* 2010;167:1175-82.
- ¹⁴ Lobarinas E, Yang G, Sun W, et al. *Salicylate- and quinine-induced tinnitus and effects of memantine*. *Acta Otolaryngol Suppl* 2006;(556):13-9.
- ¹⁵ Figueiredo RR, Langguth B, Mello de Oliveira P, et al. *Tinnitus treatment with memantine*. *Otolaryngol Head Neck Surg* 2008;138:492-6.
- ¹⁶ Zheng Y, McNamara E, Stiles L, et al. *Evidence that memantine reduces chronic tinnitus caused by acoustic trauma in rats*. *Front Neurol* 2012;3:127.
- ¹⁷ Turner JG, Brozoski TJ, Bauer CA, et al. *Gap detection deficits in rats with tinnitus: a potential novel screening tool*. *Behav Neurosci* 2006;120:188-95.
- ¹⁸ Yang G, Lobarinas E, Zhang L, et al. *Salicylate induced tinnitus: behavioral measures and neural activity in auditory cortex of awake rats*. *Hear Res* 2007;226:244-53.
- ¹⁹ Wang H, Brozoski TJ, Turner JG, et al. *Plasticity at glycinergic synapses in dorsal cochlear nucleus of rats with behavioral evidence of tinnitus*. *Neuroscience* 2009;164:747-59.
- ²⁰ Longenecker RJ, Galazyuk AV. *Development of tinnitus in CBA/CaJ mice following sound exposure*. *J Assoc Res Otolaryngol* 2011;12:647-58.
- ²¹ Dehmel S, Eisinger D, Shore SE. *Gap prepulse inhibition and auditory brainstem-evoked potentials as objective measures for tinnitus in guinea pigs*. *Front Syst Neurosci* 2012;6:42.
- ²² Longenecker RJ, Galazyuk AV. *Methodological optimization of tinnitus assessment using prepulse inhibition of the acoustic startle reflex*. *Brain Res* 2012;1485:54-62.
- ²³ Chen G, Lee C, Sandridge SA, et al. *Behavioral evidence for possible simultaneous induction of hyperacusis and tinnitus following intense sound exposure*. *J Assoc Res Otolaryngol* 2013;14:413-24.
- ²⁴ Ralli M, Lobarinas E, Fetoni AR, et al. *Comparison of salicylate- and quinine-induced tinnitus in rats: development, time course, and evaluation of audiologic correlates*. *Otol Neurotol* 2010;31:823-31.
- ²⁵ Fetoni AR, Mancuso C, Eramo SL, et al. *In vivo protective effect of ferulic acid against noise-induced hearing loss in the guinea-pig*. *Neuroscience* 2010;169:1575-88.
- ²⁶ Fetoni AR, Ralli M, Sergi B, et al. *Protective effects of N-acetylcysteine on noise-induced hearing loss in guinea pigs*. *Acta Otorhinolaryngol Ital* 2009;29:70-5.
- ²⁷ Suckfull M, Althaus M, Ellers-Lenz B, et al. *A randomized, double-blind, placebo-controlled clinical trial to evaluate the efficacy and safety of neramexane in patients with moderate to severe subjective tinnitus*. *BMC Ear Nose Throat Disord* 2011;11:1.
- ²⁸ Lobarinas E, Sun W, Stolzberg D, et al. *Human brain imaging of tinnitus and animal models*. *Semin Hear* 2008;29:333-49.
- ²⁹ Knipper M, Kopschall I, Rohbock K, et al. *Transient expression of NMDA receptors during rearrangement of AMPA-receptor-expressing fibers in the developing inner ear*. *Cell Tissue Res* 1997;287:23-41.
- ³⁰ Puel JL. *Cochlear NMDA receptor blockade prevents salicylate-induced tinnitus*. *B-Ent 3 Suppl* 2007;7,19-22.

Received: May 5, 2013 - Accepted: June 27, 2013

RHINOLOGY

Endoscopic ultrasonic curette-assisted removal of frontal osteomas

Curette per l'osso ad ultrasuoni per la rimozione degli osteomi del frontale

A. BOLZONI VILLARET, A. SCHREIBER, I. ESPOSITO, P. NICOLAI

Department of Otorhinolaryngology, University of Brescia, Italy

SUMMARY

Indications for endoscopic resection of fronto-ethmoidal osteomas have been progressively expanded thanks to optimization of surgical exposure and the development of dedicated instruments. Curved cutting drills are still suboptimal to treat hard osseous neoplasms of the frontal sinus. We present two patients affected by frontal osteoma treated with an endoscopic procedure using an ultrasonic bone curette. The ultrasonic bone curette may be considered an effective tool to reduce soft tissue manipulation, optimize surgical time and accelerate the healing process. However, the technique requires significant shape innovations to reach the lateral recesses and to manage pure intrasinus lesions.

KEY WORDS: Frontal sinus • Sinusoidal osteomas • Ultrasonic curette

RIASSUNTO

Le indicazioni alla chirurgia endoscopica nel trattamento degli osteomi fronto-etmoidali si sono progressivamente estese grazie all'ottimizzazione dell'esposizione chirurgica ed allo sviluppo di una strumentazione dedicata. Le frese curve sono ancora subottimali nel trattamento di lesioni ossee eburnee del seno frontale. Presentiamo due pazienti affetti da osteoma frontale trattati con procedura endoscopica utilizzando la curette per osso ad ultrasuoni. La curette ad ultrasuoni può essere considerato un efficace strumento chirurgico per ridurre la manipolazione dei tessuti molli e per ottimizzare i tempi chirurgici e del processo di guarigione. Tuttavia è necessario migliorare la forma dello strumento per permettere di raggiungere i recessi più laterali e gestire lesioni localizzate interamente nel seno frontale.

PAROLE CHIAVE: *Seno frontale • Osteomi nasosinusalali • Curette ad ultrasuoni*

Acta Otorhinolaryngol Ital 2014;34:205-208

Introduction

Osteomas of the sinonasal complex are benign bony tumours often incidentally discovered in asymptomatic patients during head imaging or neuroimaging. Their location and dimension may cause recurrent sinusitis, headache or orbital complaints¹⁻⁵.

Since the early 1990s, the indications for endoscopic resection of fronto-ethmoidal osteomas have been progressively expanded, with a constant refinement in the definition of contraindications and limits⁶⁻¹⁴. The evolution of the indications¹⁵⁻¹⁷ clearly reflects the optimization of the surgical exposure (i.e. use of the contralateral nostril in a Draf III procedure) and the development of dedicated instruments. Curved drills are usually adopted in this surgical setting, although all are limited by low speed and efficacy. Straight and 20° high-speed drills can be used, even though the need for aspiration and the bone dust produced may limit visualization and increase the tediousness and length of the procedure. Furthermore, minimizing mucosal trauma is essential to facilitate healing, prevent crusting and infection of denuded bone, reduce scar tissue formation and avoid

stenosis of the frontal recess. Since 2008, during extended transnasal approaches to the skull base we have combined high-speed microdrill and sonic bone emulsification in selected cases. The ultrasonic bone curette (Sonopet Ultrasonic Aspirator, Stryker®, Kalamazoo, MI, USA) was tested in two frontal osteomas to evaluate its cost efficacy and possible advantages in this specific setting. We selected small lesions located in the fronto-ethmoidal recess without complete filling of the frontal sinus. Preliminary evaluation of the device focused on the following endpoints: the traumatic impact of the device on surrounding mucosa, the balance among emulsification, irrigation, suction and endoscopic view, the lack of good visualization of the tip of the instrument in the lateral aspect of frontal sinus, and finally the speed and effectiveness of the healing process.

Materials and methods

Case 1

A 50-year-old woman was seen for symptoms (nasal obstruction, rhinorrhoea, headache) related to chronic

rhinosinusitis. She had previously undergone several endoscopic procedures at other institutions, with minimal improvement of symptoms. CT scan showed a radiodense mass suggestive for osteoma, occupying the right frontal recess with obstruction of the frontal drainage pathway (Fig. 2). Dishomogeneous ossification at the superior aspect of the lesion and its ground-glass pattern suggested a reduced consistence in its upper part. She underwent endoscopic transnasal removal (Fig. 3A); the operative time was about 2 hours and she was discharged on the 2nd postoperative day. Follow-up nasal endoscopy at 1 and 6 months confirmed adequate and quick healing with minimal scar formation (Fig. 3B). She was free from symptoms after 26 months of follow-up.

Case 2

This patient was a 40-year-old male with a clinical history of recurrent frontal sinusitis resistant to conventional conservative treatment. CT scan revealed a hyperdense lesion occupying the right frontal sinus abutting into the frontal recess (Fig. 4). He underwent endoscopic transnasal removal (Fig. 5); the operative time was about 2 hours and he was discharged on the 2nd postoperative day. Follow-up nasal endoscopy at 1 and 6 months confirmed adequate healing. He was free from symptoms at 24 months after surgical procedure.

In both cases, endoscopic evaluation 1 month after surgery showed complete healing without significant oedema or scar deposition.

Surgical procedure

Both patients were positioned supine, with hyperextension of the head (Fig. 1). After topical decongestion and injection of the upper part of the uncinate process with adrenaline and mepivacaine, endoscopic examination directly demonstrated the inferior aspect of the lesion in the first patient. The extent of the surgical approach has been tailored on a case specific basis (i.e. anterior ethmoidectomy, uncinectomy, middle turbinectomy, opening of an antero-superior septal window). In case 1, once the inferior aspect of the osteoma was identified to be covered by scarred mucosa, the ultrasonic bone curette

was introduced through the right nostril, running it over the endoscope; after blunt dissection of surrounding mucosa, the tip of the device was applied directly on the medial aspect of the lesion which was emulsified in 45 min under continuous close-up view. The residual lateral shell of bone was dissected and removed leaving the lamina papyracea intact.

In case 2, a type IIb Draf sinusotomy allowed exposure of the boundaries of the lesion which was gradually reduced

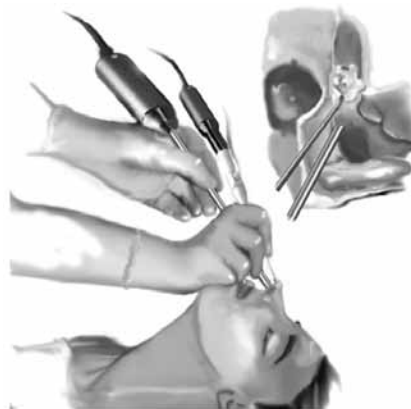

Fig. 1. Schematic drawing shows the position of the device running over the angled endoscope. Head extension improves the working angle.

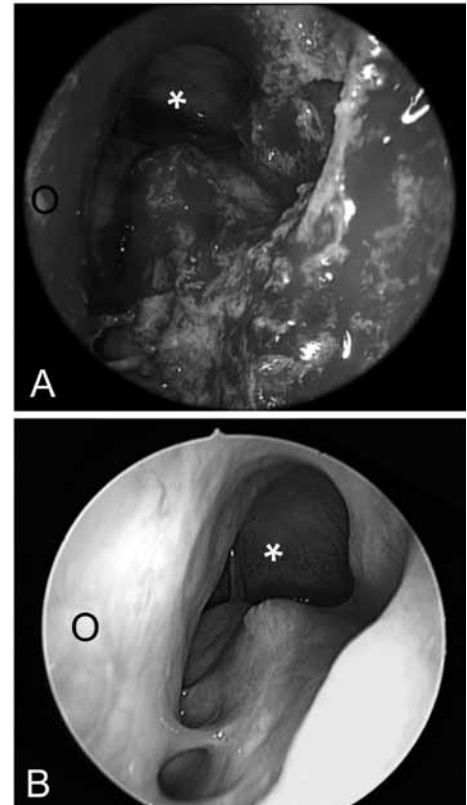


Fig. 3. Intraoperative and postoperative endoscopic views of case 1. A: after lesion removal the mucosa of the lamina papyracea is partially maintained. B: Postoperative examination at 6 months with angled telescope highlights complete healing with no stenosis of the frontal recess.

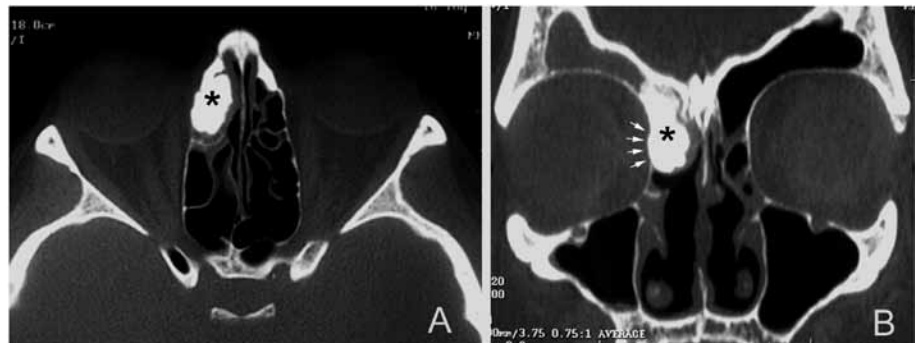


Fig. 2. Preoperative CT scan of case 1 shows an osteoma (asterisk) occluding the right frontal recess. Note the remodelled lamina papyracea (arrows) and the lesion attachment over the posteroinferior aspect of the frontal sinus. Axial (A) and coronal (B) plane.

with the use of the ultrasonic curette in about 1 hour. The Spetzler microclaw tip (Stryker®, Kalamazoo, MI, USA) was adopted in both cases allowing lesion emulsification with only one side of the tip, maximally preserving the surrounding mucosa (Fig. 5).

Discussion

Even if an external approach to the frontal sinus still has a role in the treatment of osteomas, multiple series published in the last 15 years support the efficacy and safety of an endoscopic approach through a transnasal corridor in properly selected fronto-ethmoidal lesions¹⁷. Moreover, the increasing surgical experience and development of dedicated instrumentation allow resection of selected frontal lesions even when extended over the orbital roof¹⁷.

The use of ultrasound curette in endoscopic transnasal procedures has been reported in the literature for inferior turbinoplasty¹⁸, sculpting of the nasal dorsum¹⁹, lateral orbital decompression²⁰

and removal of a fronto-ethmoidal osteoma²¹. This instrument delivers, in one hand piece, tissue fragmentation by rapid longitudinal motion, irrigation through coaxial flows around the tip to suspend fragmented tissue and cool the tip and aspiration with removal of fluid and fragmented tissue with a cannulated tip and suction.

In our Department, between 1996 and 2011, 20 patients underwent endoscopic transnasal removal of a frontal osteoma (17 frontal, 3 fronto-ethmoidal) with a mean operating time of 4.8 hours (1-12 hours; unpublished data). The heterogeneity of cases and progressive evolution of the learning curve are both factors influencing the surgical time. We endoscopically approached these tumours with a type II or III Draf sinusotomy depending on the site and size of the lesion. Standard endoscopic instruments were used to expose the caudal portion of the lesion; subsequently cavitation of the osteoma was performed using curve cutting drills to mobilize the peripheral fragments and minimize damage to surrounding tissues. In our preliminary experience, the ultrasonic bone curette does not increase the operating time in properly selected patients. Furthermore, the possibility to limit the working surface on one side of the device minimized mucosal damage, with subsequent easier care in the early postoperative course with almost no need to remove

granulation tissue or fibrin debris. During the procedure we never experienced slippage of the instrument, and its use was easy and straightforward compared to a traditional microdrill since this device integrates irrigation and aspiration and requires no pressure over the working surface. Quick healing was documented during follow up with minimal scar formation (Fig. 3B). Further experience will be essential to confirm the low morbidity, efficacy, speed and cost-effectiveness of this device. However, two main factors may contribute to a favourable application in transnasal approaches to the frontal sinus: the line of sight is improved since this device provides a bone emulsification-irrigation-suction mechanism in a single hand, and the oscillating energy of the working area is limited to a single side of the tip to prevent slippage. Moreover, minimal bone dust production and its constant aspiration consents continuous clear endoscopic view of the surgical field and the presence of dedicated tips improve the adaptability of the device to the working surface.

In contrast, the absence of curved tips designed specifically for frontal sinus endoscopic surgery limits its use to properly selected cases, and the costs of the tips are not negligible, even if the main unit can be shared among different departments of the same hospital.

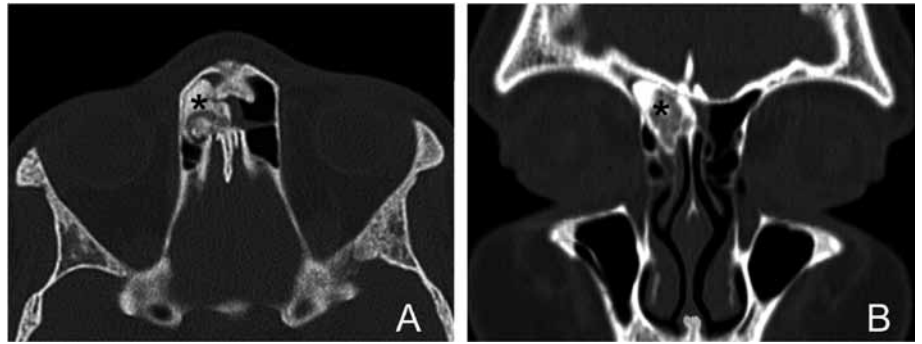


Fig. 4. Preoperative CT scan of case 2 shows an osteoma (asterisk) located in the right frontal recess and inserted at the anterolateral aspect of the right cribriform plate. Axial (A) and coronal (B) plane.

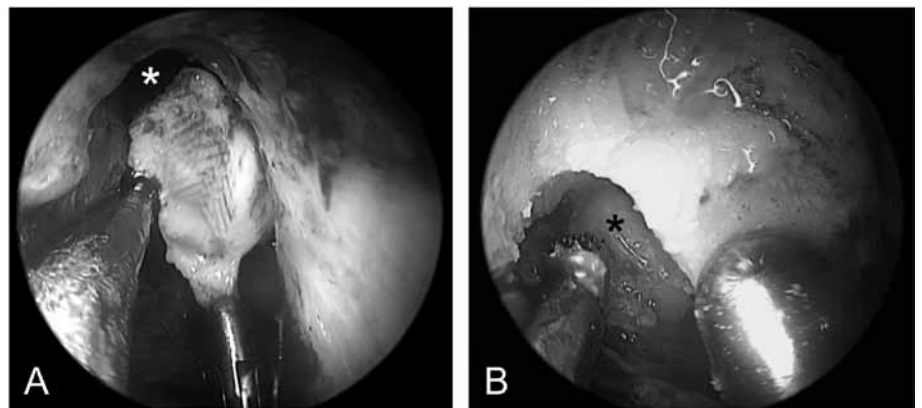


Fig. 5. Intraoperative images of case 2. After lesion cavitation and dissection from surrounding structures, the residual shell of bone is further reduced with a four-hand technique (white asterisk indicates the frontal sinus). B: close-up view. Note the mucosa surrounding the lesion (black asterisk), which is spared by the device.

Conclusions

Endoscopic surgery has a predominant role in the management of benign tumours of the sinonasal tract. Despite advances in image definition and instrumentation, visualization may still represent an issue, mainly during bone drilling in narrow spaces. State-of-the art curved cutting drills are still suboptimal to treat hard osseous neoplasms of the frontal sinus. Therefore, during endoscopic transnasal removal of frontal sinus osteoma, an ultrasound bone curette can be considered an effective tool to reduce soft tissue manipulation, optimize surgical time and speed the healing process. Furthermore, despite its straight configuration, this low profile device may be amenable for further developments and applications far lateral along the coronal plane in the frontal sinus, but which will require significant shape innovations to reach the lateral recesses and manage pure intrasinus lesions.

References

- 1 Pagella F. *Transnasal endoscopic approach to symptomatic sinonasal osteomas*. Am J Rhinol Allergy 2012;26:335-9.
- 2 Viswanatha B. *Maxillary sinus osteoma: two cases and review of the literature*. Acta Otorhinolaryngol Ital 2012;32:202-5.
- 3 Ciorba A, Aimoni C, Bianchini C, et al. *Bilateral osseous stenosis of the internal auditory canal: case report*. Acta Otorhinolaryngol Ital 2011;31:177-80.
- 4 Dispenza C, Martines F, Dispenza F, et al. *Frontal sinus osteoma complicated by palpebral abscess: case report*. Acta Otorhinolaryngol Ital 2004;24:357-60.
- 5 Bertoletti F, Capolunghi B, Bertolini G, et al. *Giant osteoid osteoma of ethmoid sinus: role of functional endoscopic sinus surgery*. Acta Otorhinolaryngol Ital 2004;24:297-301.
- 6 Draf W, Weber R, Keerl R, et al. *Current aspects of frontal sinus surgery. Part I: Endonasal frontal sinus drainage in inflammatory diseases of the paranasal sinuses*. HNO 1995;43:352-7.
- 7 Schick B, Steigerwald C, el Rahman el Tahan A, et al. *The role of endonasal surgery in the management of frontoethmoidal osteomas*. Rhinology 2001;39:66-70.
- 8 Chiu AG, Schipor I, Cohen NA, et al. *Surgical decisions in the management of frontal sinus osteomas*. Am J Rhinol 2005;19:191-7.
- 9 Castelnuovo P, Giovannetti F, Bignami M, et al. *Open surgery versus endoscopic surgery in benign neoplasm involving the frontal sinus*. J Craniofac Surg 2009;20:180-3.
- 10 Castelnuovo P, Valentini V, Giovannetti F, et al. *Osteomas of the maxillofacial district: endoscopic surgery versus open surgery*. J Craniofac Surg 2008;19:1446-52.
- 11 Bignami M, Dallan I, Terranova P, et al. *Frontal sinus osteomas: the window of endonasal endoscopic approach*. Rhinology 2007;45:315-20.
- 12 Dubin MG, Kuhn FA. *Preservation of natural frontal sinus outflow in the management of frontal sinus osteomas*. Otolaryngol Head Neck Surg 2006;134:18-24.
- 13 Seiberling K, Floreani S, Robinson S, et al. *Endoscopic management of frontal sinus osteomas revisited*. Am J Rhinol Allergy 2009;23:331-6.
- 14 Ledderose GJ, Betz CS, Stelter K, et al. *Surgical management of osteomas of the frontal recess and sinus: extending the limits of the endoscopic approach*. Eur Arch Otorhinolaryngol 2011;268:525-32.
- 15 Georgalas C, Goudakos J, Fokkens WJ. *Osteoma of the skull base and sinuses*. Otolaryngol Clin North Am 2011;44:875-90.
- 16 Gil-Carcedo LM, Gil-Carcedo ES, Vallejo LA, et al. *Frontal osteomas: standardising therapeutic indications*. J Laryngol Otol 2011;125:1020-7.
- 17 Turri-Zanoni M, Dallan I, Terranova P, et al. *Frontoethmoidal and intraorbital osteomas: exploring the limits of the endoscopic approach*. Arch Otolaryngol Head Neck Surg 2012;138:498-504.
- 18 Greywoode JD, Van Abel K, Pribitkin EA. *Ultrasonic bone aspirator turbinoplasty: a novel approach for management of inferior turbinate hypertrophy*. Laryngoscope 2010;120(Suppl 4):S239.
- 19 Pribitkin EA, Lavasani LS, Shindle C, et al. *Sonic rhinoplasty: sculpting the nasal dorsum with the ultrasonic bone aspirator*. Laryngoscope 2010;120:1504-7.
- 20 Cho RI, Choe CH, Elner VM. *Ultrasonic bone removal versus high-speed burring for lateral orbital decompression: comparison of surgical outcomes for the treatment of thyroid eye disease*. Ophthal Plast Reconstr Surg 2010;26:83-7.
- 21 Pagella F, Giourgos G, Matti E. *Removal of a fronto-ethmoidal osteoma using the sonopet omni ultrasonic bone curette: first impressions*. Laryngoscope 2008;118:307-9.

Received: January 14, 2013 - Accepted: June 27, 2013

LETTER TO THE EDITOR

The role of cricohyoidoepiglottopexy in the era of transoral laser surgery and radio/chemotherapy

Il ruolo della cricoioideoepiglottopessia nell'era della chirurgia laser transorale e della radio/chemioterapia

A. DE VIRGILIO, A. GRECO, M. DE VINCENTIIS

Department of Sensory Organs, ENT Section, Sapienza Università di Roma, Italy

Acta Otorhinolaryngol Ital 2014;34:209

Dear Editor,

We would like to take the opportunity to comment our point of view on the current role of cricohyoidoepiglottopexy in the treatment of laryngeal squamous cell carcinoma (LSCC). Since 1984 our group has performed 456 supracricoid partial laryngectomies (SPL), 81 of which were crico-hyoid-epiglottopexies (CHEP). We used this technique in T1, T2 and in selected T3 LSCC. Over the years, we gradually reduced the use of CHEP whose indications, in our opinion, are more specific and limited in current practice. This is due to the increasing and more effective use of surgical and non-surgical alternative treatments for LSCC.

Literature data highlight how radiotherapy and endoscopic removal by CO₂ laser are the preferred treatment options for T1 and most T2 glottic LSCC in the majority of centres. Local control and organ preservation rates greater than 90% are reported. In addition, open techniques are related to poorer results in terms of vocal function, quality of life and costs. For these reasons, CHEP currently appears to be a procedure that is too invasive and burdening, and its use should be limited to selected T2 cases (e.g. vocal cord mobility impairment)¹. Even in T3 glottic LSCC, we believe that CHEP has a limited use. In fact, CHEP removes thyroid cartilage, both true and false cords, part of the epiglottis, while saving most of the paraglottic space with the preservation of one or both arytenoids. The paraglottic space represents a lymphatic-adipose region that is contiguous to the pre-epiglottic space. Through the paraglottic space a glottic LSCC can easily spread towards the pre-epiglottic space and possibly into the extra-laryngeal structures². For this reason, in our opinion, the use of CHEP in advanced glottic LSCC should be limited to the rarest unilateral T3, without massive pre-epiglottic space and anterior commissure involvement, and with one-sided and very limited thyroid cartilage involvement.

We believe that crico-hyoid-pexy (CHP) is a safer and more conservative surgical alternative for treatment of locally advanced LSCC. This technique, involving the com-

plete removal of the epiglottis and pre-epiglottic space, in addition to CHEP, allows a more radical and safer excision of selected, locally advanced glottic/supraglottic LSCC³. In our experience, post-operative quality of life and oncological and functional results appear to be comparable to CHEP. However, unlike CHEP, CHP is related to a longer swallowing rehabilitation period, but as documented in the literature, at 12 months after surgery no substantial differences between CHEP and CHP with reference to oral and pharyngeal transit times emerged⁴. Finally, for the reasons discussed above, we believe that the current indications for CHEP should be: 1. Glottic T1-T2 LSCC with poor exposure; 2. Glottic T1-T2 LSCC where radiotherapy is contraindicated due to local or general factors and T2 with impaired vocal cord mobility; 3. Selected glottic T3-T4 LSCC without anterior commissure involvement and/or with limited involvement of the paraglottic space and minimum erosion of the thyroid cartilage.

Acknowledgements

We are grateful to Maria Grazia Saladino for her valuable contribution in editing the manuscript.

References

- Hartl DM, Ferlito A, Brasnu DF, et al. *Evidence-based review of treatment options for patients with glottic cancer*. Head Neck 2011;33:1638-48.
- Gallo A, Moi R, Simonelli M, et al. *Salvage resection after previous laryngeal surgery: total laryngectomy with en bloc resection of the overlying cervical skin*. Arch Otolaryngol Head Neck Surg 2001;127:786-9.
- De Virgilio A, Fusconi M, Gallo A, et al. *The oncologic radicality of supracricoid partial laryngectomy with cricohyoidopexy in the treatment of advanced N0-N1 laryngeal squamous cell carcinoma*. Laryngoscope 2012;122:826-33.
- De Vincentiis M, Calcagno P, Di Cello P, et al. *Transit time of swallowing after subtotal laryngectomy*. Rev Laryngol Otol Rhinol (Bord) 2004;125:223-7.

Received: June 27, 2013 - Accepted: August 13, 2013

Address for correspondence: Armando De Virgilio, viale del Policlinico 155, 00100 Rome, Italy. Fax +39 06 49976803. E-mail: armando.devirgilio@gmail.com

MEDICO-LEGAL CASES

Current trends for medico-legal disputes related to functional nasal surgery in Italy

Attuali tendenze medico-legali in Italia relative alla chirurgia funzionale nasale

S. MOTTA¹, S. NAPPI²¹ Institute of Otolaryngology, Department of Preventive Medical Sciences, University "Federico II", Napoli, Italy;² Department of Legal Sciences, University of Calabria, Cosenza, Italy

SUMMARY

The problem of professional liability in case of adverse outcomes or failures secondary to surgery is very sensitive in many countries of the European Community. In Italy, a recent sentence of the Supreme Court concerning a patient who underwent septoplasty raised considerable doubts in relation to the guidance to be followed in disputes related to an alleged professional liability, further exacerbating the juridical orientation of recent years in this context. This ruling involves any surgery, as well as rhinologic surgery, and calls into question most regulatory and legal principles that have traditionally been adopted by the Italian Civil Law. The sentence states that the plaintiff is only required to document the failure of surgical treatment, but not the breach of the duty of care by the surgeon, thus shifting the burden of proof to the physician-debtor. It also considers that, in assessing the degree of negligence, reference should be made to the qualifications of the surgeon, according to principles that are not covered by current regulations, denying that in general surgery (i.e., not with aesthetic purposes) the surgeon must only to act with diligence and need not guarantee a favourable outcome. This series of statements, complementing one another and evolving more unfavourably towards physicians, facilitate legal disputes for speculative purposes through complainants, with obvious health and socio-economic implications.

KEY WORDS: Medical liability • Nasal surgery • Duty of care

RIASSUNTO

Una recente sentenza della Corte di Cassazione, riguardante una paziente sottoposta ad intervento di settoplastica, ha destato un notevole interesse: essa, infatti, partendo da un problema limitato alla rinologia, ha in pratica finito con il coinvolgere tutta la chirurgia. Il contenzioso preso in considerazione nella sentenza citata fa riferimento al caso di una paziente a cui era stato prospettato, da uno specialista non coinvolto nella vicenda giudiziaria, un intervento di setto-rino-plastica, con finalità estetiche e funzionali; la malata, però, aveva accettato una semplice operazione di settoplastica in quanto nella struttura pubblica, in cui si era ricoverata, non erano previsti gli interventi di chirurgia estetica a spese del Sistema Sanitario Nazionale. La paziente, dopo qualche anno, si era sottoposta presso una struttura privata ad un nuovo intervento, con finalità sia estetiche che funzionali, in quanto, a suo parere, i risultati della prima operazione non erano stati soddisfacenti. Dopo questa seconda operazione la paziente citava in giudizio il chirurgo che aveva eseguito il primo intervento, per i danni da lei subiti a seguito dell'insuccesso dell'operazione. In I ed in II grado i giudici hanno prosciolto il chirurgo affermando sostanzialmente che nell'intervento da lui eseguito, con finalità esclusivamente funzionali, egli aveva operato correttamente. L'interessata era quindi ricorsa in Cassazione; la Corte di legittimità ha espresso una serie di rilievi critici nei riguardi delle sentenze pronunciate dalle Corti di merito, sulla base dei quali il ricorso è stato in parte accolto e il procedimento rinviato ad un'altra sezione della Corte di Appello per una revisione della sentenza. Nella sentenza oggetto del lavoro si mettono in discussione gran parte dei principi normativi e giuridici che erano stati tradizionalmente adottati dalla dottrina giurisprudenziale in Italia. Infatti tale sentenza: contesta che nella chirurgia generale (cioè con finalità non estetiche) l'operatore debba assicurare solo di agire con diligenza (obbligazione di "mezzi"); sostiene che l'attore sia tenuto a documentare solo l'insuccesso del trattamento sanitario ma non la mancanza di diligenza del convenuto, trasferendo l'onere di questa prova al medico-debitore; ritiene che nella valutazione della diligenza si debba fare riferimento alla qualificazione del convenuto secondo un principio non previsto dalle norme vigenti; afferma che la distinzione di interventi chirurgici di facile esecuzione o di problemi tecnici di speciale difficoltà non può valere come criterio di distribuzione dell'onere della prova, bensì solamente ai fini della valutazione del grado di diligenza e del corrispondente grado di colpa. Si tratta di una serie di indirizzi che, integrandosi a vicenda, rendono estremamente agevoli i procedimenti giudiziari di natura speculativa da parte dei pazienti, con ovvie implicazioni sanitarie e socio-economiche.

PAROLE CHIAVE: Responsabilità professionale • Chirurgia nasale • Obbligazione di mezzi

Acta Otorhinolaryngol Ital 2014;34:210-214

Introduction

The issue of medical liability is very sensitive in many countries of the European community and other Western societies, regardless of the approach – continental civil law or common law - taken by different legal systems^{1,2}. The interest in this issue was recently demonstrated by a survey conducted in 2007, whose results were presented at an international workshop³, and by the proceedings of a conference held in Strasbourg and curated by the Council of Europe's Public and Private Law Unit⁴ in June 2008.

In Italy, a recent ruling by the Supreme Court⁵ regarding a patient who underwent septoplasty, has raised considerable concerns in relation to the guidance to be followed in disputes related to an alleged professional responsibility. The conclusions of the sentence have led to radical revision of the legal doctrine for some of the most important medical-legal issues (characteristics of medical obligation, burden of proof, limits of professional liability, assessment of professional diligence, etc.), regardless of the specialization of the defending physician. In the following paragraphs, the ruling of the Supreme Court will be discussed, considering that this sentence seems to counter the greater uniformity of legal criteria and their interpretation, as required by the Council of Europe for the Member States.

Case report

The litigation refers to the case of a middle age woman, to whom septo-rhinoplasty, with aesthetic and functional purposes, had been proposed by a specialist that was not involved in the lawsuit. The patient had accepted the intervention because the aesthetic procedures at the expense of the national health system were not provided in the public institution in which she was hospitalized. After a few years, the patient underwent a new intervention at a private clinic, with aesthetic and functional purposes, as in her view the results of the first operation were unsatisfactory.

The judges acquitted the surgeon in the first and second grade, essentially sustaining that he had operated properly, in full compliance with the duty of care.

The complainant, therefore, resorted to the Court of Cassation which expressed some criticisms concerning judgments by the courts of first and second degree; on the basis of those remarks, the appeal was partly upheld and the case subjected to an other section of the Court of Appeals for a review of the sentence.

Discussion

In recent years, Italy has witnessed a rapid change in the legal interpretation of the physician's professional responsibility. This evolution of ideas has been further consolidated by recent pronouncements of the Supreme Court⁵⁻⁷,

one of which is the subject of this report, considering its particular relevance in otolaryngology surgery⁵. In this respect, it must be pointed out that in Italy the lower courts no longer inaugurate new directions that are later accepted by the judges of legitimacy; currently, the Supreme Court imposes the new directions, systematically nullifying the decisions of the Courts of Appeals⁸.

Nevertheless, it should also be noted that the legal principles for the obligation of professional care is applied in a substantially similar manner in all legal systems of EU member states⁹, regardless of the juridical doctrine adopted: in surgery without aesthetic purposes, and therefore in rhinologic surgery, the contract established between the surgeon and the patient binds the physician with an obligation, commonly defined as obligation of means or duty of care¹⁰⁻¹². Briefly, it is required that the surgeon performs his duties with the diligence of the nature of the professional activity exercised. Therefore, the failure of the professional should not be inferred from the non-achievement of the useful result, but it should be assessed with reference to a breach of duty of care.

This principle was blindly followed in Italy until about 10 years ago, even for interventions considered easy to perform, or "routine" procedures. In this sense, for example, the Supreme Court made a ruling in 2001¹³, stating that in case of easy to perform operations a transition does not automatically occur from obligations of means to obligations of results.

The real turning point of doctrine was postponed to 2004, year of the ruling of the Court of Cassation n. 9471¹⁴, according to which a worsening after easy to perform operations is a presumption of guilt by the physician and the first step of the obligation of the professional from obligation of means to obligation of ("almost") result.

Paradoxically, in the first part of its ruling⁵, the Court of Cassation suggests a number of considerations to support the illogic of considering surgical activity in the same way as an obligation to ensure results, asserting that the professional's failure to fulfil his obligation may not be presumed, *ipso facto*, from the non-achievement of the useful outcome that was targeted by the patient, but must be as one of the duties regarding professional conduct. Furthermore, it argues that "the failure is due to negligent performance, not based on the due diligence by the professional (and/or hospital)."

The successive deductions by the Court of Cassation contradict these premises. It in fact affirms that "if the professional activity does not obtain the normal result in relation to the concrete circumstances of the case, the physician is required (especially if the intervention is considered a simple procedure) to give proof of the occurrence of an unforeseeable event that was not surmountable with proper care". The exposed thesis is not shareable: in fact, if the professional's failure to fulfil his obligation may not be presumed *ipso facto* from the defective achievement of

the useful outcome that was targeted by the complainant, it must be inferred that when the patient complains about the surgical failure, he cannot merely document the failure itself, since – as the same Court of Cassation states – this undesirable outcome does not prove *ipso facto* the breach of duty of care by the professional. We do not believe in this regard that a wrongful conduct by the professional should be inferred in case of a defective surgical outcome, likely to be achieved with proper care, taking into account the many unpredictable factors that in medicine and surgery can affect the outcome of a specific treatment (reasoning that may be valid for cases of easy solution, where the unknowns are limited and the outcomes are generally favourable).

In case law the view is generally shared that the different levels of professional specialization, but not qualification (i.e. consultant, medical assistant, etc.), must be related to a different assessment of diligence. In other words, specialization or super-specialization is a factor that can affect the required conduct by the professional and a further aspect on which to concretely evaluate the degree of professional misconduct^{9 15}.

In some legal systems, including that in Italy, the debtor is held free from liability if the same is facing a particularly difficult technical problem. More precisely, the Italian Civil Code states¹⁶ that if “a work involves particularly difficult technical problems, the work provider shall not respond for harm, but only when he acted intentionally or with recklessness”.

The sentence in question affirms that “a limitation of medical professional liability in cases of wilful misconduct or gross negligence (ex art. 2236, Italian Civil Code) concerns only those situations with problems of particular difficulty and in any case concerns only the inexperience and not the carelessness and negligence...”.

Given that the care required by the professional to settle the obligation must be determined by taking into account his/her activity and therefore his/her possible specialization, the Supreme Court argues that in assessing any wrongful conduct, the qualifications of the professional must also be considered. In the sentence described herein, it was reported that: “...the conduct of the practitioner (a *fortiori* if one of the best in that area) must be examined not less but rather on the contrary more rigorously for the purposes of professional liability...”.

The configuration of diligence in relation to the activity of the surgeon (standard of care) responds to a particular provision of the law; the link between diligence and qualification of the professional is an original thesis, which should not be accepted, finding no support in Italian legislation or, to the best of our knowledge, in other legal systems. In fact, the specialist would be forced to resolve difficult surgical problems in relation on his/her level of preparation; the lack of resolution of these problems could constitute for him/her a presumption of guilt

for unskillfulness, not *vs.* a medium standard, but depending on his/her particular qualification.

In other words, the sentence aggravates the liability of the surgeon, especially when skilled and highly experienced, discouraging his participation in operations that could lead to failures and, consequently, increasing risk for patients.

One of the main issues in medico-legal disputes relating to the physician’s professional liability is the burden of proof^{17 18}. In general, in the case of failure of the surgical intervention and/or if the patient is not satisfied with the surgical outcome and intends to appeal to court to obtain compensation, he will have to prove the failure of the surgeon and his professional liability, with reference to the breach of the duty of care. The proof referred to the surgeon-debtor invests substantially the demonstration that no technical rule has been violated by the surgeon and that the failure was due to a cause not attributable to him/her; in other words, the professional must document to have operated with diligence and prove that he had fulfilled the contractual obligation, as opposed to what is alleged by the plaintiff-creditor.

The Court of Cassation has revised the current addresses concerning medical liability, on the basis of a ruling by the United Sections Supreme Court¹⁹. This particular ruling concerns a dispute related to the soundproofing of a wall, between a customer and a construction company. Based on this ruling, unexpectedly applied to the medical field, the Court of Cassation states that the patient creditor has merely the burden to attach the contract and its defective execution, while he is not required to prove the fault of the physician and/or of the hospital and its severity.

As for “routine” surgical procedures, it is widely accepted that the aggravation of the complainant’s pathology and the onset of new diseases due to the operation presume negligence and inadequate execution, while the physician should prove that the procedures were performed properly and that the worse outcome was determined by unexpected and unforeseeable events. Therefore, for interventions of easy execution the plaintiff must prove the routine nature of the operation, while the professional should demonstrate that the failure was not related to his/her own breach of duty of care.

This has confirmed a juridical orientation introduced in Italy for the first time in 2003 by the Supreme Court²⁰, according to which the doctor is to be waived from the burden of proof if the case entrusted to him is not highly complex. It has therefore consolidated a controversial, and easier for the complainant, rule of proof, which is based precisely on the identification of high or low difficulty of the operation; for “routine” surgery, the plaintiff need only prove that the intervention was followed by a negative outcome (on the basis of the assumption “*res ipsa loquitur*”; Latin for “the thing speaks for itself”).

This clear “favour”, affirmed by the Court for the com-

plaintiff who is acting for compensation for damages suffered as a result of routine surgery, is extended by the examined sentence to all cases of alleged professional negligence. With regard to interventions that entail particular difficulties, the Court of Cassation states that “it is indeed inconsistent and incongruous to require to the professional to provide appropriate proof to overcome the presumption of guilt against him in the case of easy to perform or routine interventions, throwing back to the patient the burden of proving in clear and specific way the defective modalities, when the intervention is of particular or special difficulty ...”. The Supreme Court draws also the attention to the fact that precisely in cases in which the employed diagnostic, therapeutic and surgical procedures are very complex it “is undoubtedly the practitioner to know the rules of art and the specific situation... so as to be able to prove compliance with these rules and to justify his choices”. The sentence, virtually eliminating the burden of proof for the plaintiff-creditor, exacerbates the position of the doctor-defendant and binds the proof in favour of this latter to specific requirements.

It should be carefully considered that the orientations of the Supreme Court that we have examined are constantly evoked by subsequent judgments regarding other medical-legal litigations which further strengthen the idea that the plaintiff had an easy path for the purposes of compensation^{21 22}.

In summary, in our opinion, the plaintiff should document the non-compliance to the obligation by the professional and, consequently, the breach of the duty of care by the debtor-surgeon. Professional liability cannot, in fact, be simply presumed on the basis of a result that the plaintiff claims not to have been reached, taking into account the difficulty of excluding speculative interests of the creditor. It is truly perplexing that in a sentence in which the various aspects of the medical liability were so carefully evaluated, the arguments of the Court of Appeals can be considered eccentric and illogical, without taking into account that the respiratory disorders attributed to professional fault were alleged by the plaintiff about two years after surgery.

Conclusions

The reported law addresses, more and more conducive to plaintiff-creditor, have inevitable consequences on the litigations relative to professional liability in the health sector. In many Western countries, as well as in Italy, an over-simplification of the procedural position of the patient tends to increase the risk of claims for speculative purposes with obvious economic implications. The increase in prosecutions and, at the same time, the greater chances of success of the patient who claimed to have suffered damage as a result of surgery or medical treatment has already produced an substantial growth in the

price of professional insurance, estimated in Italy to have increased by over 600% during the past decade. From another point of view, the impact that this phenomenon has on the media should be emphasized, because doctors are subjected to censorship by the press and public opinion, even before the trial.

In the sentence examined, the Italian Court of Cassation exasperated some juridical orientations introduced in Italy a few years ago and further consolidated by similar and even more recent judgments. In fact, it states that the plaintiff is only required to document the failure of medical treatment, but not to prove the breach of the duty of care of the professional, shifting the burden of proof on the physician-defendant and considering that in assessing the degree of diligence (and, therefore, the possible breach of duty), the main reference should be made to professional qualifications, according to a principle not covered by current regulations. Moreover, according to this ruling, the distinction between routine surgery and surgery with technical problems of special difficulty cannot be used as a criterion to distribute the burden of proof, but only for the purpose of assessing the degree of diligence and the corresponding degree of fault of the doctor-debtor. Finally, the principle according to which in general surgery (i.e., not with aesthetic purposes) the physician has exclusively an obligation of “means” is subject to contestation by the Court, despite an almost constant orientation in jurisprudence. In conclusion, we point out that the principles set forth in the ruling of Italian Court of Cassation, complement one another and facilitate lawsuits by patients, even with speculative intent, with obvious socio-economic and health implications.

References

- 1 Traina F. *Medical malpractice: the experience in Italy*. Clin Orthop Relat Res 2009;467:434-42.
- 2 Bal BS. *An introduction to medical malpractice in the United States*. Clin Orthop Relat Res. 2009;467:339-47.
- 3 Emotional and Legal Aspects in Rhinologic Surgery”. 12th Congress of the International Rhinologic Society. Venice, 5-8 December 2007.
- 4 Nys H. *The factual situation of medical liability in the member states of the council of Europe*. In: *The ever-growing challenge of medical liability: national and European responses*. Council of Europe. Strasbourg, 2-3 June 2008. p. 17-28.
- 5 Italian Court of Cassation, Third Civil Section. Judgement n. 8826, 13 April 2007.
- 6 Italian Court of Cassation, Judgement n. 14759, 26 June 2007.
- 7 Italian Court of Cassation, Judgement n. 577, 11 January 2008
- 8 Zeno-Zencovich V. *Una commedia degli errori? La responsabilità medica fra illecito e inadempimento*. Rivista di Diritto Civile 2008;3:297-340.

- ⁹ Casabona CMR. *The legal approach to medical liability*. In: *The ever-growing challenge of medical liability: national and European responses*. Council of Europe. Strasbourg, 2-3 June 2008. pp. 109-119. Strasbourg, 2-3 June 2008.
- ¹⁰ Art. 1174, Italian Civil Code.
- ¹¹ Art. 1176, Italian Civil Code.
- ¹² Art. 2230, Italian Civil Code.
- ¹³ Italian Court of Cassation, Judgement n. 2335, 16 February 2001.
- ¹⁴ Italian Court of Cassation, Judgement n. 9471, 19 May 2004.
- ¹⁵ Italian Court of Cassation, 3rd Civil Section, Judgement n. 2428, 26 March 1990.
- ¹⁶ Art. 2236, Italian Civil Code.
- ¹⁷ Sanchirico CW. *The burden of proof in civil litigation: a simple model of mechanism design*. *International Review of Law and Economics*. 1997;17:431-37.
- ¹⁸ Sanbar SS. *Legal medicine - American College of Legal Medicine Textbook Committee*. 6th ed. Mosby Ed. 2004. pp. 323-30.
- ¹⁹ Italian Court of Cassation, United Sections, Judgement n. 13533, 30 October 2001.
- ²⁰ Italian Court of Cassation (3rd section), Judgement n. 11316, 21 July 2003.
- ²¹ Italian Court of Cassation, (3rd section), Judgement n. 24791, 8 October 2008.
- ²² Italian Court of Cassation (3rd section), Judgement n. 975, 16 January 2009.

Received: June 17, 2011 - Accepted: July 30, 2011

CASE REPORT

Papillary carcinoma on a thyroglossal duct cyst: diagnostic problems and therapeutic dilemma. A case report

Un raro caso di carcinoma papillare insorto su cisti del dotto tireoglossa: problematiche diagnostiche e dilemmi terapeutici

G. PROIA, M.F. BIANCIARDI VALASSINA, G. PALMIERI, M. ZAMA

Plastic and Maxillofacial Surgery Unit, Children's Hospital Bambino Gesù, Rome, Italy

SUMMARY

Thyroglossal duct cysts are one of the most common congenital abnormalities of the cervical region. Complications of these swellings are rare, and among these, appearance of a carcinoma has also been noted. We present a case of papillary carcinoma arising in a thyroglossal duct cyst in 20-year-old woman with a swelling of about 4 cm, located at the middle region of the neck over the hyoid bone. Our patient was treated using a modified Sistrunk operation, in which thyroidectomy proved crucial for the correct diagnosis and continuation of appropriate treatment. Our case confirms the difficulty in distinguishing a primitive thyroglossal duct carcinoma from a synchronous metastatic papillary carcinoma of the thyroid. This dilemma often remains unresolved.

KEY WORDS: Thyroglossal duct cysts • Papillary carcinoma • Sistrunk operation

RIASSUNTO

Le cisti del dotto tireoglossa sono fra le più comuni anomalie congenite della regione cervicale. Le complicanze di queste tumefazioni sono rare e, fra queste, è stata descritta la comparsa di un carcinoma. Presentiamo un nuovo caso di carcinoma papillare insorto in una cisti del dotto tireoglossa in una giovane donna di 20 anni portatrice di una tumefazione di circa 4 cm, localizzata nella regione media del collo al di sopra dell'osso ioide. La nostra paziente è stata trattata mediante l'operazione di Sistrunk, nella quale la tiroidectomia ha rappresentato uno step avanzato risultato cruciale per il raggiungimento di una corretta diagnosi e la continuazione di un appropriato protocollo terapeutico. Il nostro caso conferma la difficoltà nel distinguere un carcinoma del dotto tireoglossa primitivo da una metastasi sincrona di carcinoma papillare della tiroide. Questo dilemma spesso rimane irrisolto.

PAROLE CHIAVE: Cisti del dotto tireoglossa • Carcinoma papillare • Intervento di Sistrunk

Acta Otorhinolaryngol Ital 2014;34:215-217

Introduction

Thyroglossal duct cysts are one of the most common congenital abnormalities of the cervical region^{1,2}. They originate from the persistence of the thyroglossal duct epithelium in the route of the descent of the thyroid gland from the base of the tongue to the anterior lower neck region². Complications of these swellings are rare, and among these, the appearance of a tumour has also been noted³. We present the case of 20-year-old woman suffering from papillary carcinoma on the thyroglossal duct cysts. The case is interesting for its clinical-pathological findings, and especially for its controversial diagnostic aspects.

Case report

A 20-year-old woman came to our observation for a swelling of about 2.5 cm, located at the middle region of the neck over the hyoid. The swelling had a tense-elastic consistency, and was mobile and nontender, which had formed about a year before. Ultrasound examination was compatible with thyroglossal duct cyst, with no abnormalities in the thyroid, which was in site and size, and the absence of suspicious adenopathy. Thus, there was a clear indication for surgical excision of the lesion using a modified Sistrunk technique, which involved removal of the cyst en bloc from the soft tissue surrounding the central portion of the front bone hyoid.

At macroscopic examination, the sample showed a cystic area with a gelatinous content and a firm mass in the wall.

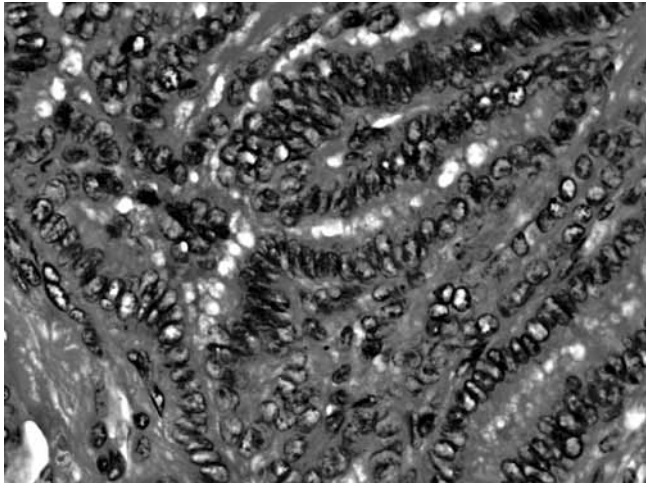


Fig. 1. Tumour tissue with a classic papillary appearance (HE 40X).

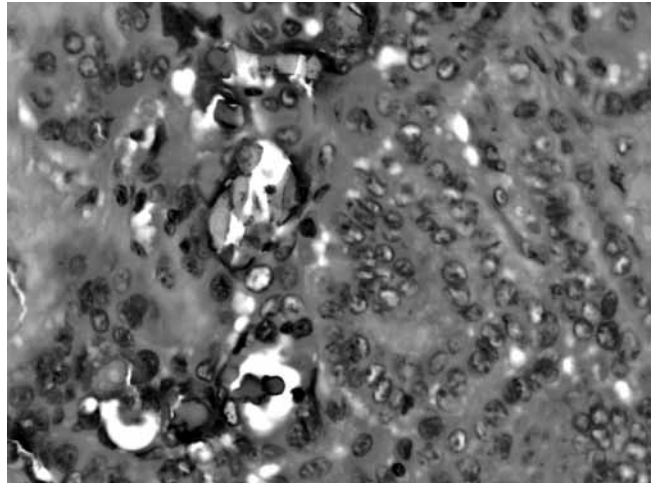


Fig. 3. Tumour tissue with typical microcalcifications (HE 40X).

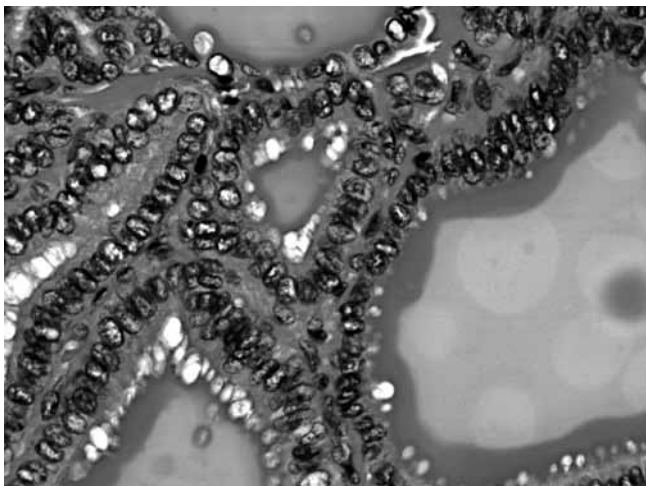


Fig. 2. Tumour tissue with voluminous and overlapping cells, with clear, irregular nucleus, with characteristic notches or grooves (HE 40X).

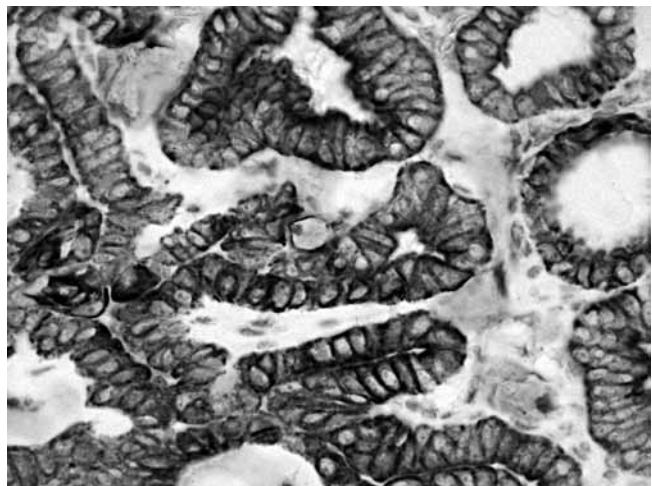

Fig. 4. Immunohistochemistry: clear positivity for CK 19, a marker of papillary carcinoma showing squamous differentiation, is observed (CK19 40X).

Histology revealed a papillary lesion (Fig. 1) with complex architecture in conjunction with follicles of varying sizes. The cellular component showed nuclear clearing or ground-glass appearance. The nuclear contour was irregular with grooves and rarely with any pseudo-inclusion (Fig. 3). Occasionally, psammoma bodies were seen. Immunohistochemical staining revealed reactivity for high-molecular weight, cytokeratin (CK19, (Fig. 4) and galectin-3, while HBME was not expressed. Furthermore, proliferation index assessed with Mib1 was moderate. Thus, a diagnosis of papillary carcinoma arising in the thyroglossal duct cyst was made.

After diagnosis, the patient was subjected to further investigation, and as recommended by the consultant endocrinologist, underwent total thyroidectomy. Final histological examination of the surgical specimen showed the presence of foci of papillary carcinoma, with CK19 and galectin-3 expression. The patient was then subjected to two rounds of radioiodine therapy. No recurrence has been observed over one year of follow-up.

Discussion

Although thyroglossal duct cysts represent the most frequent congenital cervical abnormalities encountered in both adults (7% of the population⁴) and children, neoplastic lesions, either benign or malignant, appear to be particularly unusual and quantifiable in only 1–2% of the cases. The clinical presentation of a neoplasm of thyroglossal duct is similar to that of median cysts of the neck, and therefore, diagnosis is almost always made at the time of histological examination.

Papillary carcinoma, as noted in the thyroid gland itself, is the most common histological type (80%), followed by mixed papillary-follicular (8%) and squamous cell carcinoma (6%). The surgical procedure, reported by Sistrunk in 1920, is considered to be the treatment of choice for radical excision of the thyroglossal duct cyst. The original procedure included resection of the cyst along with the body of the hyoid, extending to the foramen cecum at the floor of the mouth. Later, the technique was modified, and

today, not all surgeons extend the resection further than the body of the hyoid.

Our case, although unusual considering the average age of presentation of this type of lesion, does not differ from the clinical presentation, treatment protocol and timing for diagnosis reported in the literature^{1,5}. However, the finding of foci of cancer cells after thyroidectomy presented interesting insights regarding an issue that is still controversial. Indeed, despite the fact that more than 50% of cases of papillary carcinoma of the thyroglossal duct have not been identified as thyroid cancer⁶, it is often difficult to distinguish a carcinoma on thyroglossal duct cysts from metastatic thyroid cancer.

The histological criteria for diagnosis of primary cancer of the thyroglossal duct provide the need to distinguish the lesion from cystic lymph node metastases and to observe a normal thyroid gland, preferably by microscopic observation⁷. However, these diagnostic criteria are often disregarded as 30% of cases show synchronous neoplastic lesions. Moreover, in many cases presented in the literature, there are no histological thyroid specimens.

Our case confirms the difficulty in distinguishing a primary thyroglossal duct carcinoma from a metastatic papillary carcinoma of the synchronous thyroid³, which often remains unresolved. In our patient, despite the fact that the preoperative blood chemistry and instrumental thyroid tests were all negative, the presence of papillary carcinoma in the lining of the cyst, the higher rate described in young patients and the capsular invasion of tumour prompted us to perform total thyroidectomy⁸.

In conclusion, we present a new case of thyroglossal duct carcinoma, diagnosed and treated using modified Sistrunk operation, in which thyroidectomy proved crucial for correct diagnosis and continuation of appropriate treatment.

References

- 1 Mondin V, Ferlito A, Muzzi E, et al. *Thyroglossal duct cyst: personal experience and literature review*. *Auris Nasus Larynx* 2008;35:11-25.
- 2 Torcivia A, Polliand C, Zioli M, et al. *Papillary carcinoma of the thyroglossal duct cyst: report of two cases*. *Rom J Morphol Embryol* 2010;51:775-7.
- 3 Hofmann V, Kösling S, Thanh PN, et al. *Papillary thyroid carcinoma in a thyroglossal duct cyst: primary tumor or metastasis?* *HNO* 2009;57:719-24.
- 4 Ellis PD, van Nostrand AW. *The applied anatomy of thyroglossal tract remnants*. *Laryngoscope* 1977;87:765-70.
- 5 Patel SG, Escrig M, Shaha AR, et al. *Management of well-differentiated thyroid carcinoma presenting within a thyroglossal duct cyst*. *J Surg Oncol* 2002;79:134-9.
- 6 Mazzaferri EL. *Thyroid cancer in thyroglossal duct remnants: a diagnostic and therapeutic dilemma*. *Thyroid* 2004;14:335-6.
- 7 Peretz A, Leiberman E, Kapelushnik J, et al. *Thyroglossal duct carcinoma in children: case presentation and review of the literature*. *Thyroid* 2004;14:777-85.
- 8 Öztürk O, Demirci L, Egeli E, et al. *Papillary carcinoma of the thyroglossal duct cyst in childhood*. *Eur Arch Otorhinolaryngol* 2003;260:541-3.

Received: September 27, 2011 - Accepted: October 26, 2011

Calendar of events – Italian and International Meetings and Courses

Acta Otorhinolaryngol Ital 2014;34:218-221

Information, following the style of the present list, should be submitted to the Editorial Secretariat of Acta Otorhinolaryngologica Italica (actaitalicaorl@rm.unicatt.it).

In accordance with the Regulations of S.I.O. and Ch.C.-F. (Art. 8) Members of the Society organising Courses, Congresses or other scientific events should inform the Secretary of the Association (A.U.O.R.L., A.O.O.I.) within the deadlines set down in the respective Statutes and Regulations.

MAY-DECEMBER 2014

SKIN CANCER OF THE HEAD AND NECK COURSE • May 1, 2014 • Utrecht – The Netherlands
INTERCONTINENTAL RHINOPLASTY • May 2-3, 2014 • Utrecht – The Netherlands

Websites: <http://reconstruction-skin-cancer.com> – <http://intercontinental-rhinoplasty.nl>

V INTERNATIONAL WORKSHOP ON ENDOSCOPIC EAR SURGERY • May 5-7, 2014 • Modena – Italy

Course Directors: Livio Presutti, Daniele Marchioni. Website: <http://www.meetandwork.it/livesurgerymodena>

2nd ANNOUNCEMENT OTOTOLOGY JUBILEE: 150 YEARS OF THE ARCHIV FÜR OHRENHEILKUNDE
Past-Present-Future in Otolology & Neurology • May 7-10, 2014 • Halle/Saale – Germany

Website: www.otology-jubilee.com

CURSO DE DISECCIÓN ENDOSCÓPICA DE LOS SENOS PARANASALES
ENDOSCOPIC SINUS SURGICAL DISSECTION COURSE • May 8-10, 2014 • Barcelona – Spain

Instituto de Otolología García-Ibáñez, C/ Dr. Roux, 91, 08017 – Barcelona. Tel. 93 205 02 04 – Fax 93 205 43 67 – E-mail: gi.fundacion@gmail.com, fundacion@iogi.org

BALBUZIE - IL TRATTAMENTO TRA STUDIO E HOMEWORK • May 9-10, 2014 • Turin – Italy

Coordinatore Scientifico: Mario D'Ambrosio. Organizing Secretariat: Centro Congressi Internazionale Srl, via San Francesco da Paola 37, 10123 Torino. Tel. +39 011 2446911 – Fax +39 011 2446950 – E-mail: info@congressiefiere.com – Website: www.congressiefiere.com

GIORNATA DI AGGIORNAMENTO AICEF - 6^a edizione • May 10, 2014 • Ravenna – Italy

Scientific Secretariat: Domenico Minghetti, E-mail: minghetti@tin.it – Patrizia Schiavon, E-mail: patrizia.schiavon@gmail.com. Website: www.lopezcongressi.it

3rd IRANIAN CONGRESS ON COCHLEAR IMPLANT & RELATED SCIENCE
May 10-12, 2014 • Tehran – Iran

IRANCI 2014 Secretariat: Tel. - Fax 098-21-8860-0006 – E-mail: info@irancochlear.com – Website: www.irancochlear.com

101° CONGRESSO NAZIONALE SIO – Società Italiana di Otorinolaringologia e Chirurgia Cervico-Facciale
May 28-31, 2014 • Catania – Italy

President: A. Serra. Website: www.sio2014.org – www.eac.it

CURSO DE DISECCIÓN ENDOSCÓPICA DE LOS SENOS PARANASALES - ENDOSCOPIC SINUS
SURGICAL DISSECTION COURSE • May 29-31, 2014 • Barcelona – Spain

Instituto de Otolología García-Ibáñez, Isabel, C/ Dr. Roux, 91, 08017 Barcelona. Tel. 93 205 02 04 – Fax 93 205 43 67 – E-mail: gi.fundacion@gmail.com, fundacion@iogi.org

CORSO BASE DI OTORADIOLOGIA • June 4-6, 2014 • Rovereto – Italy

Coordinatore Scientifico: M. Neri. Organizing Secretariat: Mytime Training & Technology srl, via San Carlo da Sezze 18, 04100 Latina – Tel. +39 0773 662630 – E-mail: segreteria@mytimetandt.it – Website: www.mytimetandt.it

**HEAL 2014 (HEaring Across the Lifespan): “EARLY INTERVENTION: THE KEY TO BETTER HEARING CARE”
June 5-7, 2014 • Cernobbio (Lake Como) – Italy**

Website: <http://www.heal2014.org>

**CORSI DI VIDEOCHIRURGIA ENDOSCOPICA NASO-SINUSALE E DEL BASICRANIO • Milan – Italy
June 9-13, 2014 (corso intermedio)
October 27-31, 2014 (corso avanzato)**

Course Director: Alberto Dragonetti – Scientific Secretariat: Gabriella Mantini, Valentina Casoli- Tel. +39 02 64444545 – Fax +39 02 64444003 – E-mail: gabriella.mantini@ospedaleniguarda.it. Organizing Secretariat: Eurocompany Srl, via Canova 19, 20145 Milano. Tel. +39 02 315532 – Fax +39 02 33609213 – E-mail: corsieconvegni@eurocompany.mi.it

TEMPORAL BONE DISSECTION COURSES 2014 • June 10-13, December 9-12, 2014 • Brazil

Website: www.forl.org.br/courses

3° CORSO DI CHIRURGIA OTOLOGICA CON FRESA IN MANO • June 12-13, 2014 • Reggio Emilia – Italy

Responsabile del Corso: Giovanni Bianchin. Segreteria Organizzativa: Annarita Guglielmi, Campagna Cecilia, Servizio Formazione, Qualità, Rapporti con Università e 3° settore, palazzo Rocca Saporiti, viale Murri 7, 42123 Reggio Emilia. Tel. +39 0522 295817 - Fax +39 0522 295976 – E-mail: campagna.cecilia@asmn.re.it

4th HANDS ON DISSECTION ADVANCED COURSE: “FROM REMOVAL TO RECONSTRUCTION IN HEAD AND NECK CANCERS” • June 17-20, 2014 • Paris – France

Directors: Marco Benazzo, Department of Otolaryngology HN Surgery, University of Pavia, Italy; Fausto Giuseppe Chiesa, Department of Otolaryngology HN Surgery, IEO Milan, Italy. Organizing Secretariat: Bquadro Congressi srl, via S. Giovanni in Borgo 4, 27100 Pavia. Tel. +39 0382 302859 – Fax +39 0382 27697 – E-mail: bolla@bquadro-congressi.it.

**CURSO DE MICROCIRUGÍA DEL OÍDO Y DISECCIÓN DEL HUESO TEMPORAL
TEMPORAL BONE SURGICAL DISSECTION COURSE**

June 18-20, 2014 - November 2014, date to be announced • Barcelona – Spain

Instituto de Otolología García-Ibáñez, Conchi Castilla, C/ Dr. Roux, 91, 08017 – Barcelona. Tel. 93 205 02 04 – Fax 93 205 43 67 – E-mail: iogi@iogi.org

**24th CONGRESS OF EUROPEAN RHINOLOGIC SOCIETY (ERS) and 32nd INTERNATIONAL
SYMPOSIUM OF INFECTION AND ALLERGY OF THE NOSE. THE NOSE AS INTERFACE
June 22-26, 2014 • Amsterdam – The Netherlands**

President: W.J. Fokkens. Website: www.ers-isian2014.com – E-mail: ers-isian2014@kenes.com

**5th WORLD CONGRESS OF THE INTERNATIONAL FEDERATION OF HEAD AND NECK ONCOLOGIC
SOCIETIES (IFHNOS) – ANNUAL MEETING OF THE AMERICAN HEAD AND NECK SOCIETY (AHNS)
July 26-30, 2014 • New York – USA**

Congress Chairman: Jatin Shah. Program Chairman: Bevan Yueh. Websites: www.ifhnos2014.org, www.ahns2014.org

**4th INTERNATIONAL COURSE ON ENDOCRINE SURGERY - INTRAOPERATIVE MONITORING OF
LARYNGEAL NERVES IN THYROID SURGERY • June 27, 2014 • Stresa (Lake Maggiore, VB) – Italy**

Organizing Secretariat: Summeet Srl, via P. Maspero 5, 21100 Varese. Tel. +39 0332 231416 – Fax +39 0332 317748 – E-mail: mb.calveri@summeet.it – Website: www.summeet.it

BEST EVIDENCE ENT 2014 • August 2-5, 2014 • Wisconsin – USA

Course Directors: John S. Rhee, David R. Friedland, Charles J. Harkins. Department of Otolaryngology 9200 West Wisconsin Avenue Milwaukee, WI 53226, USA

**26th INTERNATIONAL COURSE ON ENDOSCOPIC SURGERY OF THE PARANASAL SINUSES AND SKULL BASE
August 27-30, 2014 • Ghent – Belgium**

Course Director: Claus Bachert. Website: www.fess-course.be

40° CONGRESSO CONVENTUS SOCIETAS ORL LATINA • September 1-5, 2014 • Baia de Luanda – Angola

Info: Departamento de ORL da Faculdade de Medicina da Universidade Agostino Neto Hospital Josina Machel-Maria Pia Av. 1° Congresso do MPLA. Tel. 00244-923784901/914381304 – E-mail: mfilipe@snet.co.ao, drmatuba@gmail.com

XL CONVENTUS SOCIETAS ORL LATINA CONGRESSO • September 3-5, 2014 • Luanda – Angola

Website: www.conventusocietasorllatina-luanda2014.org

ORL ENDO 2014 • Modena – Italy

Chirurgia endoscopica dell'orecchio medio (Middle ear endoscopic surgery) • September 9-10, 2014

Chirurgia endoscopica dei seni paranasali (Endoscopic sinus surgery) • November 11-12, 2014

Course Director: Livio Presutti. Scientific Secretariat: Angelo Ghidini, Daniele Marchioni. Tel. +39 059 4222402 - 4223022 – E-mail: Ghidini.angelo@policlinico.mo.it, Marchioni.daniele@policlinico.mo.it - Website: www.meetand-work.it/orl-endo2014

CORSO DI CHIRURGIA ENDOSCOPICA RINOSINUSALE, RINOSOTTOPLASTICA E FILLERS - LIVE SURGERY, III EDIZIONE • September 11-13, 2014 • Atripalda (AV) – Italy

Website: www.avellinose.it Organizing Secretariat: Lingo Communications Srl, via Cinthia - p.co San Paolo, is 25 80126 Napoli. Tel. +39 081 7663737 – Fax +39 081 7675661 – E-mail: ecm@lingomed.it

7th INSTRUCTIONAL WORKSHOP – CONSENSUS IN AUDITORY IMPLANTS “EUROPEAN GUIDELINES IN OTOLOGY AND NEURO-OTOLOGY” • September 13-16, 2014 • Siena – Italy

Website: www.eaono2014.org

THE MODERN SINONASAL SURGERY • Varese, Italy

Basic Course: September 15-17, 2014

Advanced Course: November 17-19, 2014

Director: Paolo Castelnuovo. Website: www.ospedativarese.net/corsinformazione/con-iscrizione

CORSO DI ANATOMIA CHIRURGICA ENDOSCOPICA DEI SENI PARANASALI, CORSO SIACH ITALIA September 18-20, 2014 • Turin – Italy

President: Roberto Albera. Director: Maurizio Catalani. Coordinator: Roberto Gera. Website: www.siach.eu

IV CORSO TEORICO-PRATICO DI AUDIOLOGIA E VESTIBOLOGIA

September 22-24, 2014 • Benevento – Italy

Course Director: L. Califano. Scientific Secretariat: Luigi Califano, Maria Grazia Melillo – E-mail: luigi.califano@tin.it, vertigobn@hotmail.com

11TH INTERNATIONAL SVO CONFERENCE ON HEAD AND NECK CANCER

October 6-8, 2014 • Venice – Italy

Segreteria Organizzativa: Radiovision di G. D'Este & C. snc. Tel. + 39 041 5952420 - 421 – Fax + 39 0415952422 – E-mail: segreteria@radiovision.it – Website: www.radiovision.it

EUROPEAN UNION OF HEARING AID ACOUSTICIANS (EUHA) 59th INTERNATIONAL CONGRESS OF HEARING AID ACOUSTICIANS (EUHA) • October 15-17, 2014 • Hanover – Germany

Website: www.euha.org

5th ASIAN FACIAL PLASTIC SURGERY SOCIETY CONGRESS • October 15-19, 2014 • Cappadocia – Turkey

Website: www.afpss2014.org

5th INTERNATIONAL COURSE ON FUNCTIONAL AND AESTHETIC SURGERY OF THE NOSE

October 19-22, 2014 • Imola (BO) – Italy

Info: Scientific Secretariat: E.N.T. Department, AUSL Imola. Tel. +39 0542 662101/293 – Fax +39 0542 662284 – E-mail: i.tasca@ausl.imola.bo.it. Executive Secretariat: A & R Eventi sas di Verlicchi Clara e C., via R. Benassi 28, 40068 San Lazzaro di Savena (BO). Tel. +39 051 474238 – Fax +39 051 4839525 – E-mail: clara@areventi.it – Website: www.imolarhinoplasty2014.com

CONSENSUS CONFERENCE ON SALIVARY GLAND TUMORS. ADENOID-CYSTIC CARCINOMA AND HIGH-GRADE NEOPLASMS • October 23-24, 2014 • Brescia – Italy

Directors: Adel El-Naggar, Ehab Hanna, Lisa Licitra, Piero Nicolai. Organizing Secretariat: Servizi C.E.C. Srl, via Verdi 18, 24121 Bergamo, Italy. Tel. +39 035 249899 – Fax +39 035 237852 – Website: www.servizicec.it

CORSO DI APPROFONDIMENTO IN OTORADIOLOGIA • November 11-14, 2014 • Rovereto – Italy

Coordinatore Scientifico: M. Neri. Organizing Secretariat: Mytime Training & Technology srl, via San Carlo da Sezze 18, 04100 Latina – Tel. +39 0773 662630 – E-mail: segreteria@mytimetandt.it – Website: www.mytimetandt.it

ISIAN-IRS-PARS 2014 • November 20-24, 2014 • Dubai – UAE

President: Reda Kamel. Website: www.isian-irs-pars2014.org

RhinoForum 2014 • December 5-6, 2014 • Warszawa – Poland

President: Antoni Krzeski. Website: www.rhinoforum.pl

JANUARY-DECEMBER 2015**8° CORSO INTERNAZIONALE “BIENNALE MILANO MASTERCLASS”****A. CHIRURGIA ENDOSCOPICA RINOSINUSALE, ORBITA E BASE CRANICA****B. RINOPLASTICA: DA MINIMAMENTE INVASIVA A STRUTTURALE**

March 20–24, 2015 • Milan – Italy

Direttori: Paolo Castelnuovo e Pietro Palma. Segreteria Organizzativa: MZ Congressi, via C. Farini 81, 20159 Milano. Tel. +39 02 66802323 – Fax +39 02 49542900 | –E-mail: mima@mzcongressi.com – Website: www.milanomasterclass.it

3rd CONGRESS OF CE ORL-HNS • June 7-11, 2015 • Prague – Czech Republic

Website: Congress secretariat: GUARANT International Na Pankraci 17, 14021 Prague4, Czech Republic. Website: www.CEOrl-hnsprague2015.com

22nd INTERNATIONAL CONGRESS ON THE EDUCATION OF THE DEAF • July 6-9, 2015 • Athens – Greece

Website: www.iced2015.com

WORLD CONGRESS ON LARYNX CANCER 2015 • July 26-30, 2015 • Queensland – Australia

Website: www.wclc2015.org