

ACTA

Otorhinolaryngologica Italica

Official Journal of the Italian Society of Otorhinolaryngology - Head and Neck Surgery
Organo Ufficiale della Società Italiana di Otorinolaringologia e Chirurgia Cervico-Facciale

Former Editors-in-Chief: C. Calearo[†], E. de Campora, A. Staffieri, M. Piemonte, F. Chiesa

Editorial Board

Editor-in-Chief:

G. Paludetti

President of S.I.O.:

A. Serra

Former Presidents of S.I.O.

and Editors-in-Chief:

I. De Vincentiis, D. Felisati, L. Coppo,
G. Zaoli, P. Miani, G. Motta,
L. Marcucci, A. Ottaviani,
P. Puxeddu, M. Maurizi, G. Sperati,
D. Passali, E. de Campora, A. Sartoris,
P. Laudadio, M. De Benedetto,
S. Conticello, D. Casolino,
A. Rinaldi Ceroni, M. Piemonte,
A. Staffieri, F. Chiesa, R. Fiorella,
A. Camaioni

Editorial Staff

Editor-in-Chief:

G. Paludetti

Deputy Editor:

J. Galli

Associate Editors:

G. Almadori, F. Ottaviani

Editorial Coordinator:

E. De Corso

Editorial Assistant:

P. Moore

Treasurer:

L. de Campora

Italian Scientific Board

L. Bellussi, G. Danesi, C. Grandi,
A. Martini, L. Pignataro, F. Raso,
R. Speciale, I. Tasca

International Scientific Board

J. Betka, P. Clement, M. Halmagyi,
L.P. Kowalski, M. Pais Clemente,
J. Shah, H. Stammberger, R. Laszig,
G. O'Donoghue, R.J. Salvi, R. Leemans,
M. Remacle, F. Marshal, H.P. Zenner

Editorial Office

Editor-in-Chief:

G. Paludetti

Department of Head and Neck Surgery -
Otorhinolaryngology
Catholic University of the Sacred Heart
"A. Gemelli" Hospital
L.go F. Vito, 1 - 00168 Rome, Italy
Tel. +39 06 30154439
Fax + 39 06 3051194
actaitalicaorl@rm.unicatt.it

Editorial Coordinator:

E. De Corso

eugenio.decorso@rm.unicatt.it

Editorial Secretary:

R. Gallus

gallusroberto@gmail.com

Argomenti di Acta

Otorhinolaryngologica Italica

Editor-in-Chief: G. Paludetti

Editorial Coordinator: M.R. Marchese
raffaellamarchese@gmail.com

© Copyright 2014 by

Società Italiana di Otorinolaringologia
e Chirurgia Cervico-Facciale
Via Luigi Pigorini, 6/3
00162 Rome, Italy

Publisher

Pacini Editore SpA
Via Gherardesca, 1
56121 Pisa, Italy
Tel. +39 050 313011
Fax +39 050 3130300
info@pacineditore.it
www.pacinimedicina.it

*Acta Otorhinolaryngologica Italica is cited
in Index Medicus, MEDLINE, PubMed
Central, Science Citation Index Expanded,
Scopus, DOAJ, Open-J Gate, Free Medical
Journals, Index Copernicus, Socolar*

Journal Citation Reports:

Impact Factor 0.786

*Acta Otorhinolaryngologica Italica is
available on Google Scholar*



Contents

Review

Endoscopic management of posterior epistaxis: a review

Il trattamento endoscopico delle epistassi posteriori: revisione della letteratura

S.W. McClurg, R. Carrau pag. 1

Head and neck

Central neck dissection in differentiated thyroid cancer: technical notes

Dissezione centrale del collo nei carcinomi differenziati della tiroide: note tecniche

G. Giugliano, M. Proh, B. Gibelli, E. Grosso, M. Tagliabue, E. De Fiori, F. Maffini, F. Chiesa, M. Ansarin » 9

Cervical metastasis on level IV in laryngeal cancer

Metastasi latero cervicali al livello IV nei carcinomi della laringe

V.J. Furtado de Araújo Neto, C.R. Cernea, R. Aparecido Dedivitis, V.J. Furtado de Araújo Filho,

J. Fabiano Palazzo, L. Garcia Brandão » 15

Laryngology

How the operated larynx ages

Processi di invecchiamento della laringe sottoposta ad intervento chirurgico

E. Crosetti, P. Garofalo, C. Bosio, P. Consolino, A. Petrelli, G. Rizzotto, G. Succo » 19

Rhinology

External vs. endonasal dacryocystorhinostomy: has the current view changed?

Dacriocistorinostomia esterna ed endonasale a confronto: si è modificata l'opinione comune?

G. Savino, R. Battendieri, S. Traina, G. Corbo, G. D'Amico, M. Gari, E. Scarano, G. Paludetti » 29

Allergic and non-allergic rhinitis: relationship with nasal polyposis, asthma and family history

Riniti allergiche e non allergiche. Correlazioni con poliposi nasale, asma e storia familiare

M. Gelardi, L. Iannuzzi, S. Tafuri, G. Passalacqua, N. Quaranta » 36

Audiology

Cochlea size variability and implications in clinical practice

Variabilità delle dimensioni cocleari e sue implicazioni nella pratica clinica

P. Pelliccia, F. Venail, A. Bonafé, M. Makeieff, G. Iannetti, M. Bartolomeo, M. Mondain » 42

Quantitative enhancement of speech in noise through a wireless equipped hearing aid

Miglioramento della percezione verbale attraverso apparecchi acustici dotati di sistema wireless

A. Ciorba, S. Zattara, G. Loroni, S. Prosser » 50

Basic research in otolaryngology

Mitochondrial DNA (mtDNA) haplotypes and dysfunctions in presbycusis

Correlazioni tra gli aplotipi del DNA mitocondriale (mtDNA) e la presbiacusia

H. Mostafa, M. Saad, A. El-Attar, G. Ahmed, S. Berrettini, F. Forli, G. Siciliano, M. Mancuso » 54

Vestibology

Epigone migraine vertigo (EMV): a late migraine equivalent

Vertigine emicranica epigona (VEE): un equivalente emicranico tardivo

P. Pagnini, P. Vannucchi, B. Giannoni, R. Pecci » 62

Case series

Can lateral semicircular canal dysplasia play a role in the genesis of hyperacusis?

La displasia del canale semicircolare laterale può avere un ruolo nella genesi dell'iperacusia?

G.C. Modugno, C. Brandolini » 71

Calendar of events - Italian and International Meetings and Courses » 75

Information for authors including editorial standards for the preparation of manuscripts
available on-line: www.actaitalica.it

REVIEW

Endoscopic management of posterior epistaxis: a review

Il trattamento endoscopico delle epistassi posteriori: revisione della letteratura

S.W. McCLURG, R. CARRAU

Department of Otolaryngology-Head and Neck Surgery, The Ohio State University, Columbus, OH, USA

SUMMARY

The paradigm for the management of epistaxis, specifically posterior epistaxis, has undergone significant changes in the recent past. Recent prospective and retrospective data has shown that the endonasal surgical management of posterior epistaxis is superior to posterior nasal packing and angiography/embolization with regards to various factors including pain, cost-effectiveness, risk and overall control of bleeding. Endonasal endoscopic surgical techniques for posterior epistaxis include direct cauterization and transnasal endoscopic sphenopalatine/posterior nasal artery ligation or cauterization with or without control of the anterior ethmoidal artery. Despite the evidence provided by the current literature, a universal treatment protocol has not yet been established. This review article provides an up-to-date assessment of the available literature, and presents a structured paradigm for the management of posterior epistaxis.

KEY WORDS: Epistaxis • Endoscopic sphenopalatine artery ligation • Posterior epistaxis • Sphenopalatine artery

RIASSUNTO

Il trattamento delle epistassi posteriori ha subito significativi cambiamenti negli ultimi anni. I recenti dati prospettici e retrospettivi hanno dimostrato che il trattamento chirurgico endoscopico delle epistassi posteriori presenta dei vantaggi rispetto al tamponamento nasale e/o all'embolizzazione previa angiografia ed in particolare in termini di dolore, rapporto costo-beneficio, effetti collaterali, e infine in termini di controllo di sanguinamento. Il trattamento endoscopico chirurgico delle epistassi posteriori include la cauterizzazione diretta e la legatura dell'arteria sfeno-palatina e/o cauterizzazione dell'arteria etmoidale anteriore. Nonostante le evidenze presenti in letteratura un protocollo universale non è stato ancora realizzato. Questa revisione della letteratura offre un aggiornamento sui dati attuali sull'argomento, proponendo un algoritmo per il trattamento delle epistassi posteriori.

PAROLE CHIAVE: Epistassi • Legatura endoscopica della arteria sfeno palatina • Epistassi posteriore • Arteria sfeno-palatina

Acta Otorhinolaryngol Ital 2014;34:1-8

Introduction

Epistaxis is a very common presenting complaint and the most common emergency for the Otolaryngologist-Head and Neck Surgeon. The distribution of epistaxis is bimodal. It is most common before age 10, and then peaks again between ages 45 and 65 years of age^{1,2}. Many factors including seasonal variation, concomitant inhalational allergy, oestrogens (extraneous and endogenous), environmental humidity and upper respiratory tract infections affect the incidence of epistaxis.

Epistaxis can be divided into anterior and posterior based upon the arterial supply and location of the offending vessel. Most cases of epistaxis are anteriorly located (90-95%), and are usually treated effectively after visual localization with local chemical or electrical cauterization via anterior rhinoscopy³. Approximately 5-10% of epistaxis arises posteriorly³, and requires more aggressive measures for control. It has been prospectively shown that

patients with posterior epistaxis are more likely to require hospitalization, are twice as likely to require nasal packing and require a longer hospital stay⁴.

The sphenopalatine (SPA) and posterior nasal (PNA) arteries, terminal branches of the internal maxillary artery (IMA), provide blood supply to the lateral nasal wall below the middle turbinate, rostrum of the sphenoid sinus and posterior nasal septum. Therefore, a majority of posterior epistaxes arise from these two vessels. Measures to control posterior epistaxis include direct cauterization, posterior nasal packing, embolization or surgery. Many studies have shown surgical control to be superior to angiography/embolization^{3,5} as well as posterior packing³. Intervention for posterior epistaxis is direct endonasal endoscopic cauterization of the offending site. However, in a significant number of patients, if not most, with posterior epistaxis, the site will remain undefined. Recent reports suggest that ligation of the sphenopalatine and posterior nasal arteries seems to be the best option for patients with

posterior epistaxis and without comorbidities that would preclude a surgical intervention^{3,5}.

The surgical management of epistaxis has undergone significant transitions and changes. Carnochan⁶ described the first surgical technique to the pterygopalatine fossa (PTPF) in 1858, using a transfacial-transantral approach to the pterygopalatine fossa (PTPF). In 1890, Segond introduced a lateral transfacial approach to the pterygopalatine fossa⁶. Subsequently, Hide introduced the ligation of the external carotid artery for the management of epistaxis. In 1948, Silverblatt first described the ligation of the anterior ethmoid artery. These techniques are still utilized around the world to manage patients with refractory epistaxis. In 1929, Seiffert described the sublabial-transantral approach for ligation of the maxillary artery, which was subsequently standardized and popularized by Chandler (1956); and, further improved upon by Simpson (1982) by focusing on its terminal branches (i.e. sphenopalatine and posterior nasal arteries)⁶. In 1976, Prades described an endonasal microscopic ligation of the sphenopalatine artery, which was emulated by Borgstein who introduced the endoscope as a visualization tool in 1987⁶.

A thorough knowledge of the anatomy of the posterior nasal cavity and pterygopalatine fossa is essential for the proper surgical management of posterior epistaxis. Arterial supply to the nasal cavity is both robust and variable, with contributing arteries deriving from both the internal and external carotid arteries. Contributions from the external carotid artery include the sphenopalatine, posterior nasal, superior labial, greater palatine, angular and ascending pharyngeal arteries. The internal carotid artery furnishes the anterior ethmoid and posterior ethmoid arteries via the ophthalmic artery. Branches of the ethmoidal arteries supply the lateral nasal wall above the level of the middle turbinate. It must be noted that there is ample communication between the two systems. The vidian artery and the artery that accompanies V2 (artery of the foramen rotundum) are robust examples of these communications that can lead to collateral blood flow, thus causing re-bleeding and which must be considered when embolizing the internal maxillary artery.

The sphenopalatine foramen (SPF), which is a notch between the orbital and sphenoidal processes of the ascending aspect

of the palatine bone (Fig. 1), usually lies at the posterior end of the middle turbinate, in the lower part of the superior meatus, and at the junction between the palatine and sphenoid bone on the lateral nasal wall. Simmen reported that the mean vertical and horizontal diameters of the SPF are 6.2 and 5.1 mm, respectively⁷. From an endoscopic standpoint, the foramen can be found just posterior to the superior one-third of the posterior wall of the antrum. Another reliable landmark is the crista ethmoidalis, which is a small spur of bone just anterior to the sphenopalatine foramen (Fig. 2).

The arterial configuration within the pterygopalatine fossa is also highly variable and complex. In a cadaveric study of 128 tissue blocks by Chiu⁸, it was found that the internal maxillary artery bifurcates before reaching the sphenopalatine foramen in 89% of cases, splitting off into two (69%), three (19%) or four branches (2%). In a similar anatomical study, Simmen documented that there may even be up to 10 arterial branches⁷. This study also demonstrated that in 58% of cases the SPF lies in both the superior and middle meati.

Variability of the vascular anatomy within the pterygopalatine fossa is remarkable and ranges from a relatively simple or "classic" pattern to one that is highly complex⁹. In turn, the branching pattern of the sphenopalatine artery is also striking. Schartzbauer showed that in fresh cadavers, approximately 16% of the terminal branches split off from the maxillary artery distal to the sphenopalatine foramen, 42% branch proximally and 42% branch through separate foramina¹⁰. In 75 cadaveric specimens, Simmen showed that in 97% of the samples the sphenopalatine artery had 2 or more branches exiting the lateral nasal wall, 67% had 3 or more branches, 35% had 4 or more branches, 3% had 1 single trunk and 1% had 10 branches⁷. A representative example of the sphenopalatine artery is shown in Fig. 1.

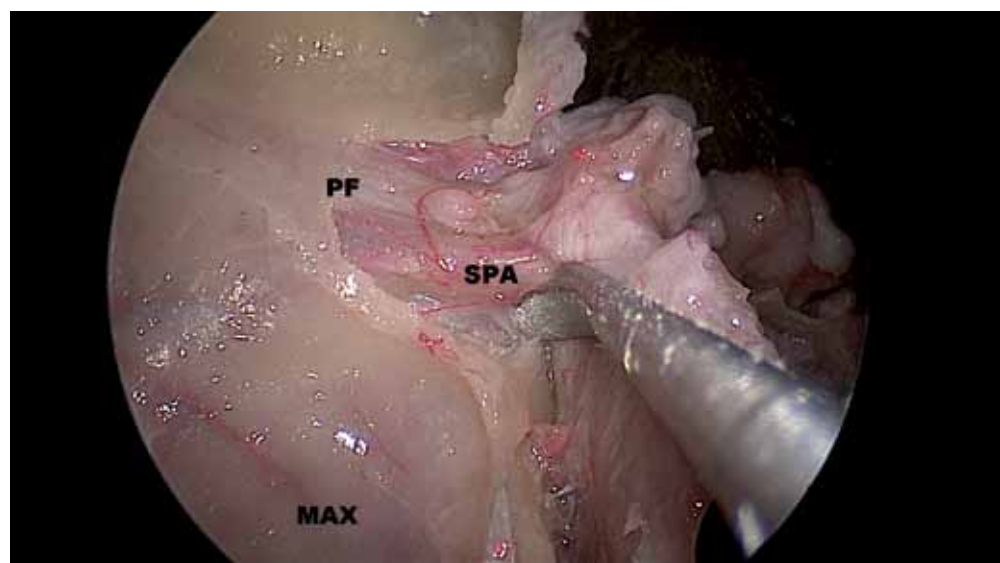


Fig. 1. Right pterygopalatine fossa. PF: pterygopalatine fossa; SPA: sphenopalatine artery; MAX: posterior wall of maxillary sinus.

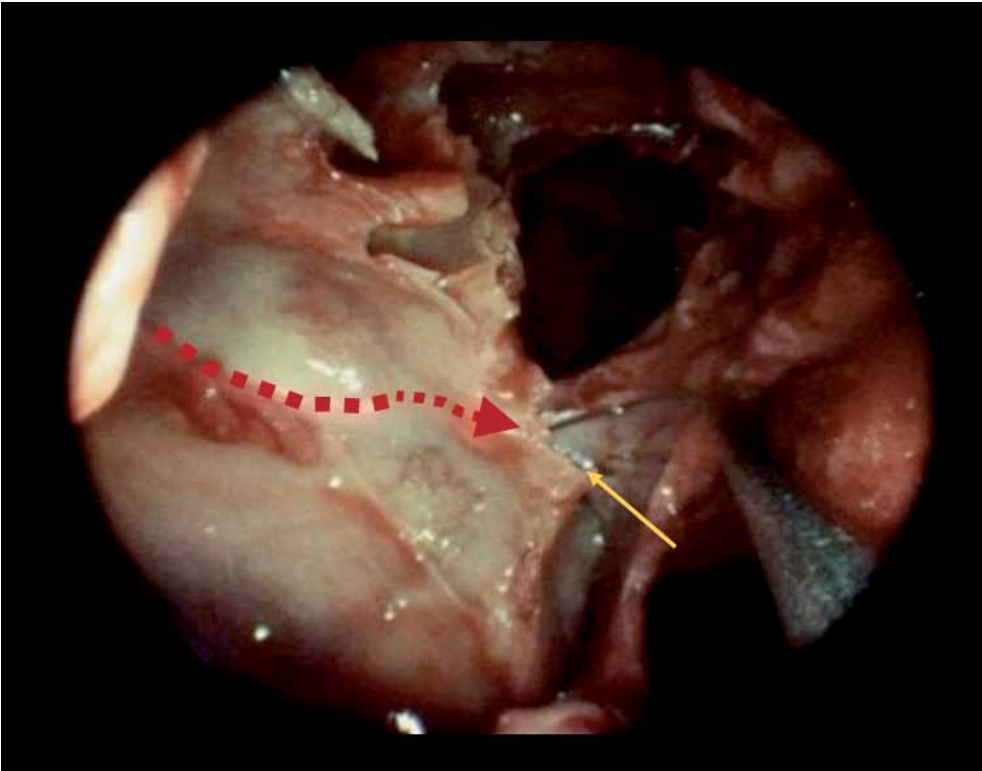


Fig. 2. Right ethmoid crest. Yellow arrow pointing to crista ethmoidalis. Red dashed arrow showing the path of the internal maxillary before it divides into the sphenopalatine and posterior nasal arteries.

Another common and useful landmark for the identification of the sphenopalatine foramen is the ethmoid crest or crista ethmoidalis (CE), (Fig. 2). In a study by Rezende, the crista ethmoidalis was found in 96% of cadaveric specimens, and was located just anterior to the SPF in most cases¹¹. Similar to other aforementioned studies, they found that 43% of specimens had accessory foramina. Similarly, Padua showed that the crista ethmoidalis was anterior to the sphenopalatine foramen in 98% of specimens¹². In this latter study, the SPF was located between the middle meatus and the superior meatus in 87% of specimens, and at the superior meatus in 13%. In Padua's study accessory foramina were present in 10% of specimens. These studies suggest that, in fact, the most reliable localizer for the SPF is the crista ethmoidalis; however, the frequency of multiple foramina and branches is significant; thus, the surgeon should anticipate their presence¹².

Initial management

The initial evaluation of the patient presenting with epistaxis should focus on evaluating the stability of the airway, initial control of the bleeding and stabilization of vital signs with fluid replacement or blood transfusions. In a patient with severe uncontrolled epistaxis, the need for intubation or even a surgical airway, albeit rare, must be

considered. If the airway is deemed stable, non-surgical approaches for haemostasis should first be attempted. Local vasoconstrictors (i.e. epinephrine), either topical and/or injected, may assist with haemostasis. If the site of bleeding is visible, its cauterization may be possible. Posterior epistaxis is usually quite brisk, and also due to its inherent position in the posterior nasal cavity, it is often difficult to pinpoint the location of bleeding. In the surgical theatre, however, Thornton et al.¹³ were able to identify the location of posterior epistaxis in 36 of 43 cases. Of these, 20% were located on the posterior nasal septum, and 80% of those were located on the lateral aspect of the middle or inferior

turbinate or the lateral aspect of the middle or inferior meatus. It should be noted that all identified sites were located within the distribution of the sphenopalatine artery. Intraoperatively, anaesthesia-induced hypotension and/or elevation of the head of the bed may decrease bleeding; thus, potentially facilitating the identification and control of the bleeding site.

Any surgical intervention requires prior stabilization of the patient and control of bleeding. If the patient had previously been treated (commonly by a non-otolaryngologist), the patient may present with posterior packing already in place. In the hands of a non-specialist, posterior packing is efficacious in approximately 70% of cases¹⁴. In the untreated patient, a posterior nasal pack using traditional tonsil packs with ribbon-gauze coated with antibiotic ointment, expandable sponges such as the Merocel Pope nasal packing (Medtronic ENT, Jacksonville, FL, USA), Rapid Rhino (Applied Therapeutics, Tampa, FL, USA) Epistat, Postpac (Medtronic ENT, Jacksonville, FL, USA) or any of the multiple available balloon-packing devices may be effective. Topical haemostatic compounds such as a mixture of gelatin and thrombin (e.g. Floseal, Baxter Healthcare Corp., Deerfield, IL, USA) has been shown to be effective in anterior epistaxis¹⁵, but it has not been properly assessed for posterior bleeds; thus, it is not advocated in the setting of posterior epistaxis where a specific site of bleeding cannot be identified.

There have been multiple studies comparing the various types of nasal packing for anterior bleeds, but unfortunately, there are relatively few studies looking at comparisons between various posterior nasal packings. In a comparison study by Callejo¹⁶, classic tetracaine-coated gauze packing was compared to a bi-chambered pneumatic packing device. They found that the classic packing was less expedient, and less comfortable, but was associated with fewer episodes of re-bleeding (17% against 28%, respectively) and less expensive (€ 1327 vs. € 1648).

Posterior packing is associated with its own set of specific complications, such as the naso-vagal reflex that can trigger cardiac dysfunction or respiratory arrest¹⁷. In addition, packing may be inadvertently swallowed or aspirated if not adequately secured¹⁸. Conversely, if the packing is secured too tightly, it may lead to alar, columellar or septal necrosis¹⁹. Due to the possible compressive ischaemia of nasal structures, we advocate to avoid bilateral posterior packing whenever possible, and to routinely deflate the cuff of balloon occlusive devices to allow septal blood flow.

If a Foley balloon-type device (i.e. any inflatable balloon) is used for posterior packing, air is not suitable for inflating the balloon. Rashid showed that Foley catheters inflated with air deflated within approximately 48 hr²⁰; therefore, saline or sterile water should be utilized for balloon inflation.

We recommend utilizing antibiotics while the posterior packing is in place, even though prophylactic antibiotics have not been shown to decrease infectious complications²¹. However, rare complications such as infective endocarditis and spondylodiscitis have been reported in patients with posterior nasal packing who were not covered with systemic antibiotic prophylaxis²².

Once the bleeding is controlled, all contributing factors that may be exacerbating the epistaxis should be addressed. These may include co-morbidities such as coagulopathies (congenital or acquired), hypertension, maxillofacial trauma, recent endonasal or orthognathic surgery and history of hereditary hemorrhagic telangiectasia (HHT). Basic laboratory studies (including complete blood count, chemistry panel, platelet count, prothrombin time and partial thromboplastin time) should be obtained during initial workup. Consider blood transfusion if haemoglobin is noted to be significantly low (this varies according to patient's cardiovascular reserve, comorbidities, symptoms and regional practices). These contributing factors should be addressed prior to any operative intervention whenever feasible.

There are specific clinical scenarios that deserve special consideration. In patients with hereditary hemorrhagic telangiectasia (HHT), an autosomal dominant disorder resulting in localized vascular malformations, these malformations may extend posteriorly, and their acute management includes surgical cauterization or angiography and

embolization. Ligation of the arteries is rarely performed as this precludes the possibility of angiography and embolization and due to the nature of the disease, and the benefits of the surgery are short-lived. The possibility of a primary or metastatic tumour causing the epistaxis may also need to be addressed with thorough history and physical examination and possibly further imaging studies. In any adolescent male patient, the possibility of a juvenile nasopharyngeal angiofibroma should also be considered. A history of recent maxillofacial trauma, or recent endonasal or orthognathic surgery, poses the possibility of an arterial injury or a pseudoaneurysm. This latter lesion results from an incomplete tear a major artery, causing bleeding from the artery into the arterial adventitia, resulting in a localized haematoma with a continued connection to the offending artery. Pseudoaneurysms are usually unresponsive to nasal packing (immediate re-bleeding upon packing removal). They may arise from any sinusal artery, but the arteries most commonly involved after orthognathic surgery are the internal maxillary artery and the sphenopalatine artery². The treatment for a pseudoaneurysm is arterial selective embolization².

Surgery

After haemodynamic stabilization, the patient is taken to the operative suite. As previously discussed, anaesthesia-controlled hypotension and/or elevation of the head of the bed decreases the bleeding, and potentially facilitates localization of the offending bleeding site. Any previous nasal packing is removed and a thorough nasal endoscopy is performed to identify the specific site of bleeding. Some common locations for bleeding include the spheno-ethmoid recess, turbinates, middle meatus and the septum. If a bleeding site is identified, it may be directly cauterized. Local cauterization has the advantage of requiring no packing, and is associated with shorter hospital stay and greater patient comfort²³. Direct cauterization may also be conducted under topical or local anaesthesia. A potential disadvantage of this technique include a lower success rate than formal sphenopalatine artery ligation (mostly due to inadequate identification of the bleeding site).

Some propose attempting a local cauterization of bleeding sites in cases of posterior epistaxis²³ under general or local anaesthesia, by first visualizing the various sites of possible bleeding including the posterior aspect of the lateral wall of inferior meatus; posterior part of lateral nasal wall near the sphenopalatine foramen; posterior end of inferior turbinate; the middle turbinate and its medial surface; middle and posterior part of septum and floor of nose beneath the inferior turbinate²³. However, the preferred approach for surgical management of posterior epistaxis, in which a specific site is indisputably identified, is endonasal endoscopic ligation of the sphenopalatine and pos-

terior nasal arteries. The efficacy of this technique is dependent on controlling the multiple, robust branches that the sphenopalatine and posterior nasal arteries give rise to. Indications for surgical ligation include the inability to place packing effectively due to an anatomical deformity, failure of non-surgical therapy, recurrent epistaxis, contraindications for embolization and patient preference. Contraindications for embolization include severe carotid atherosclerosis, prior external carotid or internal maxillary artery ligation or bleeding from the anterior ethmoid artery (which arises from the ophthalmic artery, a branch of the ICA).

A cost analysis study by Dedhia²⁴, showed that first-line endonasal endoscopic sphenopalatine/posterior nasal arteries ligation results in a significant overall cost savings if ≥ 3 days of posterior nasal packing were required (\$ 6,450 vs. \$ 8,246, respectively). Therefore, it is recommended that endonasal endoscopic sphenopalatine and posterior nasal artery ligation should be offered as an initial treatment option for medically stable patients diagnosed with posterior epistaxis²⁴.

Our preferred technique for endonasal endoscopic sphenopalatine and posterior nasal artery ligation^{25,26} involves performing a standard uncinectomy, with identification of the natural maxillary sinus ostium and its enlargement inferiorly (to the level of the inferior turbinate), superiorly (to the level of the orbit) and posteriorly (to be flush with the back wall of the antrum). Next, the sphenopalatine foramen is identified using all the previously discussed anatomical landmarks (posterior wall of the antrum, middle turbinate root, and crista ethmoidalis). Using a Freer or Cottle periosteal elevator, the mucoperiosteum over the ascending process of the palatine bone is widely elevated to expose the sphenopalatine foramen and the sphenopalatine and posterior nasal arteries. Wide elevation is important to identify anatomical variants such as multiple foramina and/or multiple vessels traversing the lateral nasal wall from the pterygopalatine fossa. The vessels can frequently be controlled at this point either with haemostatic clips or bipolar electrocautery. If necessary a longer segment of the arteries can be exposed by removing the anterior aspect of the sphenopalatine foramen (i.e. posterior nasal wall) using a Kerrison or Citelli rongeur; thus, following the arteries into the pterygopala-

tine fossa. It is important to dissect the sphenopalatine and posterior nasal arteries free from the posterior aspect of the SPF, as this will allow a complete clipping or cauterization of the arteries.

A concurrent anterior ethmoid artery (AEA) ligation along with the endonasal endoscopic ligation of the sphenopalatine and posterior nasal arteries should be considered, if the site of bleeding is not known pre-operatively, if the patient's history is unreliable, if packing was placed at an outside institution, or if there is no evidence of bleeding at the time of surgery (unidentified site of bleeding). AEA ligation has a low morbidity, and should be strongly considered if the patient has been referred for definitive treatment from a region distant from the hospital. Approaches for AEA ligation include an external incision and dissection between the lamina papyracea and the periorbita with endoscopic assistance, and endonasal approach with bipolar cauterization of the AEA (Fig. 3). Identification of the anterior ethmoidal artery on coronal computed tomography is assisted with its location at the retro-bulbar level, or by utilizing the "nipple or pyramidal sign" (a triangular evagination of the lamina papyracea between the superior oblique and medial rectus muscles) (Fig. 4). It has been shown that 36% of anterior ethmoidal arteries were located in a mesentery, and 20% could be clipped endoscopically²⁷. However, an external approach is safer to access the AEA. A small naso-orbital incision provides access to the periorbita, which is incised and elevated under endoscopic visualization. Following the frontoethmoidal suture leads to the ethmoidal foramina, located an average of 24 mm from the lacrimal crest. In turn, the posterior ethmoid artery (PEA) is located 12 mm

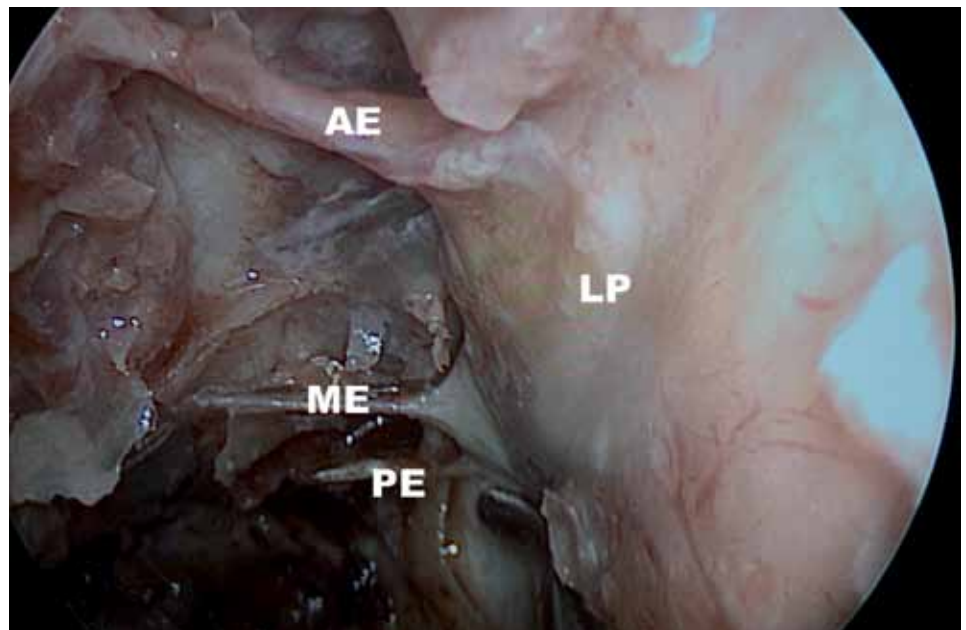


Fig. 3. Endoscopic view of left nasal cavity. Orbital decompression with lamina papyracea bone (LP) removed. This specimen shows a middle ethmoidal artery.
AE: anterior ethmoidal artery; ME: middle ethmoidal artery; PE: posterior ethmoidal artery/

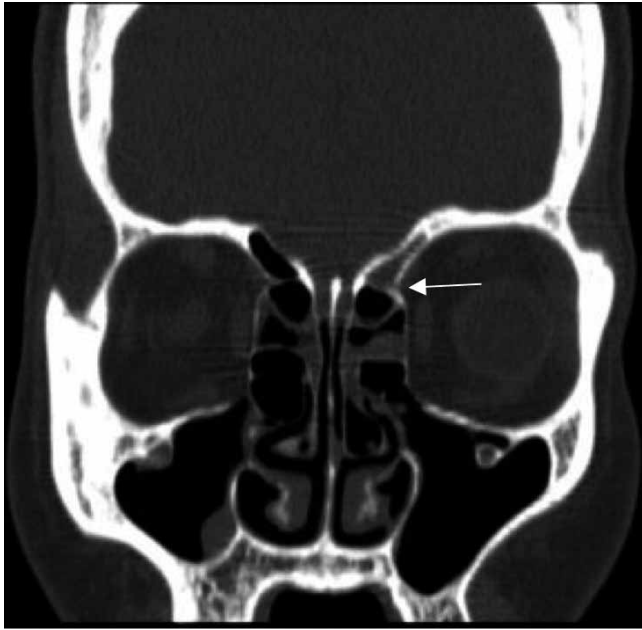


Fig. 4. Coronal cut of CT image showing “nipple sign” at the level of entry (white arrow) of the anterior ethmoid artery into the nasal cavity.

posterior to the anterior ethmoidal artery, and the optic canal is located 6 mm posterior to the posterior ethmoid artery. After surgical control is achieved, silicone septal splints are placed if there was excessive trauma to the mucosa or if there is a possibility of post-operative nasal synechiae.

In a retrospective review, Kumar showed that the overall mean success rate of sphenopalatine artery ligation in 11 case series including 127 patients was 98% (range 92–100%)²⁸. In a retrospective study of 678 patients, Soyka⁵ showed that the successful treatment in patients with posterior epistaxis could be achieved in 62% by packing (Foley + fat-gauze), and in 97% by surgery. Despite the high success rate of arterial ligation, there is still the possibility of failure. Possible reasons for recurrent bleeding include failure to ligate all terminal branches of the sphenopalatine artery, dislodged clips, bleeding diatheses, the development of collateral blood vessels or unrecognized AEA bleeding sites.

In a recent prospective study by Nikolaou²⁹, it was shown that surgery was the most cost effective and least painful treatment regimen for posterior epistaxis. Their treatment regimen consisted of placement of either a Rapid Rhino 7.5 cm packing or balloon packing for posterior epistaxis, followed by endonasal endoscopic sphenopalatine and posterior nasal artery ligation for patients that had further bleeding upon removal of the packing. In this study of 61 patients (45 with anterior epistaxis, 16 with posterior epistaxis), they showed that the median visual analogue scale for the evaluation of pain (VAS score) for Rapid Rhino packing, surgery and balloon packing was 6.0, 3.0 and 7.5, respectively. The median costs of treat-

ment for 96 patients were calculated, and were found to be approximately the same for patients with Rapid Rhino packing and surgery (10,192 Swiss Francs), balloon packing and surgery (10,192 Swiss Francs) and surgery alone (10,269 Swiss Francs). Overall, their findings suggested that surgery is less troublesome to the patient, and does not increase the costs of treatment. This technique has also been shown to be efficacious and safe in the paediatric population³⁰.

After control of the posterior epistaxis is achieved, appropriate postoperative care is needed. Elevate the head of the bed, avoid hypertension, provide appropriate analgesia and promote aggressive nasal hygiene. Nasal hygiene includes saline nasal sprays, saline irrigations, use of oxymetazoline and/or a nasal sling. The patient should follow-up in clinic 5-7 days after surgical intervention for removal of silicone splints, if they were placed.

If endonasal endoscopic sphenopalatine and posterior nasal arteries ligation is not successful, a transantral internal maxillary artery (IMAX) ligation or angiography with embolization may be considered. Further, if IMAX ligation is not successful or angiography with embolization is not available, an external carotid artery ligation may be considered. It should be noted that this is a last resort, as a retrospective review conducted by Spafford³¹ showed a high rate of re-bleeding with external carotid artery ligation (45%), but showed that IMAX ligation was successful in 90% of patients.

Embolization is an alternative option for posterior epistaxis, and is our preferred intervention for recurrent epistaxis after a seemingly adequate endonasal endoscopic sphenopalatine and posterior nasal artery ligation. Angiographic embolization was first described for posterior epistaxis in 1974 by Sokolof³². Possible candidates for embolization include patients with HHT (Osler-Weber-Rendu) syndrome, bleeding tumours, poor surgical candidates or if the patient chooses it. Bleeding during transphenoidal or maxillofacial surgery should be considered for endovascular management due to possible internal carotid artery injury or pseudoaneurysm formation³³. Possible minor complications of angiography include trismus, facial pain, facial paresthesia or haematoma. Possible major complications include cerebrovascular accident, internal carotid artery dissection, blindness, necrosis or facial paralysis. In a retrospective review of 70 patients, Christensen found that 86% of their cases had minor or no complications after embolization, and were discharged within 24 hours³⁴. A major re-bleed, requiring surgical intervention, occurred within 6 weeks of embolization in 13% of these patients, and one patient had a significant cerebrovascular accident. Also of note, this study showed that the average cost of hospitalization in the respective institution was \$ 18,000 per patient with epistaxis, and the cost

of embolization was an average of \$ 11,000³⁴. In a retrospective study by Cohen, 19 patients underwent endovascular embolization with no minor or major complications, and an average hospital stay of 11.1 days³⁵. As previously mentioned, in any adolescent male patient, the possibility of a juvenile nasopharyngeal angiofibroma should also be assessed. In these patients, embolization via angiography is usually utilized prior to surgical resection³³.

Given the various presentations and possible sources of bleeding in a patient with posterior epistaxis, we propose the following diagnostic workup and treatment (Fig. 5) to optimize the management of posterior epistaxis.

Conclusion

Ligation of the sphenopalatine and posterior nasal arteries is a very effective treatment for severe posterior epistaxis. Concomitant anterior ethmoidal artery ligation may be more effective than sphenopalatine artery/posterior nasal artery ligation alone. Surgical intervention of posterior epistaxis provides a low-morbidity and cost-effective treatment. We present a flow diagram for management of posterior epistaxis.

References

- Tomkinson A, Roblin DG, Flanagan P, et al. *Patterns of hospital attendance with epistaxis*. *Rhinology* 1997;35:129-31.
- Nikoyan L, Matthews S. *Epistaxis and hemostatic devices*. *Oral Maxillofac Surg Clin North Am* 2012;24:219-28.
- Douglas R, Wormald PJ. *Update on epistaxis*. *Curr Opin Otolaryngol Head Neck Surg* 2007;15:180-3.
- Supriya M, Shakeel M, Veitch D, et al. *Epistaxis: prospective evaluation of bleeding site and its impact on patient outcome*. *J Laryngol Otol* 2010;124:744-9.
- Soyka MB, Nikolaou G, Rufibach K, et al. *On the effectiveness of treatment options in epistaxis: an analysis of 678 interventions*. *Rhinology* 2011;49:474-8.
- Wentges RT. *Surgical anatomy of the pterygopalatine fossa*. *J Laryngol Otol* 1975;89:35-45.
- Simmen DB, Raghavan U, Briner HR, et al. *The anatomy of the sphenopalatine artery for the endoscopic sinus surgeon*. *Am J Rhinol* 2006;20:502-5.
- Chiu T. *A study of the maxillary and sphenopalatine arteries in the pterygopalatine fossa and at the sphenopalatine foramen*. *Rhinology* 2009;47:264-70.

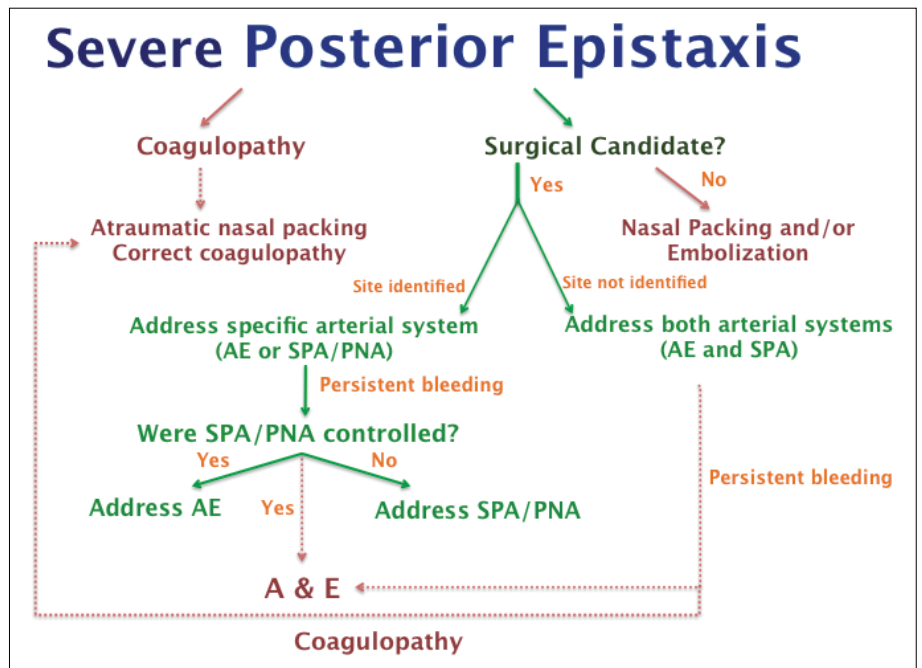


Fig. 5. Flow diagram for management of posterior epistaxis. Note that this diagram should be used for patients that have failed conservative management and local cauterization in the non-operative setting. AE: anterior ethmoid artery; A&E: angiography and embolization; SPA: sphenopalatine artery; PNA: posterior nasal artery.

- Fortes FS, Sennes LU, Carrau RL, et al. *Endoscopic anatomy of the pterygopalatine fossa and the transpterygoid approach*. *Laryngoscope* 2008;118:44-9.
- Schartzbauer HR, Shete M, Tami TA. *Endoscopic Anatomy of the sphenopalatine and posterior nasal arteries: Implications for the endoscopic management of epistaxis*. *Am J Rhinol* 2003;17:63-6.
- Rezende GL, Soares VY, Moraes WC, et al. *The sphenopalatine artery: a surgical challenge in epistaxis*. *Braz J Otorhinolaryngol* 2012;78:42-7.
- Padua FG, Voegels RL. *Severe posterior epistaxis - endoscopic surgical anatomy*. *Laryngoscope* 2008;118:156-61.
- Thornton MA, Mahesh BN, Lang J. *Posterior epistaxis: identification of common bleeding sites*. *Laryngoscope* 2005;115:588-90.
- Schlosser RJ. *Clinical practice. Epistaxis*. *N Engl J Med* 2009;360:784-9.
- Mathiasen RA, Cruz RM. *Prospective, randomized, controlled clinical trial of a novel matrix hemostatic sealant in patients with acute anterior epistaxis*. *Laryngoscope* 2005;115:899-902.
- García Callejo FJ, Muñoz Fernández N, Achiques Martínez MT, et al. *Nasal packing in posterior epistaxis. Comparison of two methods*. *Acta Otorrinolaringol Esp* 2010;61:196-201.
- Fairbanks DN. *Complications of nasal packing*. *Otolaryngol Head Neck Surg* 1986;94:412-5.
- Hashmi SM, Gopaul SR, Prinsley PR, et al. *Swallowed nasal pack: a rare but serious complication of the management of epistaxis*. *J Laryngol Otol* 2004;118:372-3.
- Civelek B, Kargi AE, Sensöz O, et al. *Rare complication of nasal packing: alar region necrosis*. *Otolaryngol Head Neck Surg* 2000;123:656-7.

- ²⁰ Rashid M, Karagama Y. *Inflation of Foley catheters for post-nasal packing*. J Laryngol Otol 2010;124:997-8.
- ²¹ Pepper C, Lo S, Toma A. *Prospective study of the risk of not using prophylactic antibiotics in nasal packing for epistaxis*. J Laryngol Otol 2012;126:257-9.
- ²² Gungor H, Ayik MF, Gul I, et al. *Infective endocarditis and spondylodiscitis due to posterior nasal packing in a patient with a bioprosthetic aortic valve*. Cardiovasc J Afr 2012;23:e5-7.
- ²³ Paul J, Kanotra SP, Kanotra S. *Endoscopic management of posterior epistaxis*. Indian J Otolaryngol Head Neck Surg 2011;63:141-4.
- ²⁴ Dedhia RC, Desai SS, Smith KJ, et al. *Cost-effectiveness of endoscopic sphenopalatine artery ligation vs. nasal packing as first-line treatment for posterior epistaxis*. Int Forum Allergy Rhinol 2013;3:563-6.
- ²⁵ Snyderman C, Carrau R. *Endoscopic ligation of the sphenopalatine artery for epistaxis*. Operative Techniques in Otolaryngology - Head and Neck Surgery 1997;8:85-9.
- ²⁶ Snyderman C, Goldman S, Carrau R, et al. *Endoscopic sphenopalatine artery ligation is an effective method of treatment for posterior epistaxis*. Am J of Rhinol 1999;13:137-40.
- ²⁷ Floreani SR, Nair SB, Switajewski MC, et al. *Endoscopic anterior ethmoidal artery ligation: a cadaver study*. Laryngoscope 2006;116:1263-7.
- ²⁸ Kumar S, Shetty A, Rocker J, et al. *Contemporary surgical treatment of epistaxis. What is the evidence for SPA ligation?* Clin Otolaryngol Allied Sci 2003;28:360-3.
- ²⁹ Nikolaou G, Holzmann D, Soyka MB. *Discomfort and costs in epistaxis treatment*. Eur Arch Otorhinolaryngol 2013;270:2239-44.
- ³⁰ Eladl HM, Khafagy YW, Abu-Samra M. *Endoscopic cauterization of the sphenopalatine artery in pediatric intractable posterior epistaxis*. Int J Pediatr Otorhinolaryngol 2011;75:1545-8.
- ³¹ Spafford P, Durham JS. *Epistaxis: efficacy of arterial ligation and long-term outcome*. J Otolaryngol 1992;21:252-6.
- ³² Sokoloff J, Wickbom I, McDonald D, et al. *Therapeutic percutaneous embolization in intractable epistaxis*. Radiology 1974;111:285-7.
- ³³ Abruzzo TA, Heran MK. *Neuroendovascular therapies in pediatric interventional radiology*. Tech Vasc Interv Radiol 2011;14:50-6.
- ³⁴ Christensen NP, Smith DS, Barnwell SL, et al. *Arterial embolization in the management of posterior epistaxis*. Otolaryngol Head Neck Surg 2005;133:748-53.
- ³⁵ Cohen JE, Moscovici S, Gomori JM, et al. *Selective endovascular embolization for refractory idiopathic epistaxis is a safe and effective therapeutic option: technique, complications, and outcomes*. J Clin Neurosci 2012;19:687-90.

Received: June 21, 2013 - Accepted: June 27, 2013

Address for correspondence: Ricardo L. Carrau, Department of Otolaryngology-Head & Neck Surgery, The Ohio State University Medical Center, Starling Loving Hall – Room B221, 320 West 10th Avenue, Columbus, OH 43210, USA. E-mail: Ricardo.Carrau@osumc.edu

HEAD AND NECK

Central neck dissection in differentiated thyroid cancer: technical notes

Dissezione centrale del collo nei carcinomi differenziati della tiroide: note tecniche

G. GIUGLIANO¹, M. PROH¹, B. GIBELLI¹, E. GROSSO¹, M. TAGLIABUE¹, E. DE FIORI², F. MAFFINI³, F. CHIESA¹, M. ANSARIN¹

¹ Division of Head & Neck Surgery, ² Division of Diagnostic Radiology, ³ Division of Pathology, European Institute of Oncology, Milano, Italy

SUMMARY

Differentiated thyroid cancers may be associated with regional lymph node metastases in 20-50% of cases. The central compartment (VI-upper VII levels) is considered to be the first echelon of nodal metastases in all differentiated thyroid carcinomas. The indication for central neck dissection is still debated especially in patients with cN0 disease. For some authors, central neck dissection is recommended for lymph nodes that are suspect preoperatively (either clinically or with ultrasound) and/or for lymph node metastases detected intra-operatively with a positive frozen section. In need of a better definition, we divided the dissection in four different areas to map localization of metastases. In this study, we present the rationale for central neck dissection in the management of differentiated thyroid carcinoma, providing some anatomical reflections on surgical technique, oncological considerations and analysis of complications. Central neck dissection may be limited to the compartments that describe a predictable territory of regional recurrences in order to reduce associated morbidities.

KEY WORDS: Thyroid cancer • Central neck dissection

RIASSUNTO

I tumori differenziati della tiroide possono essere associati a metastasi linfonodali regionali nel 20-50% dei casi. Il compartimento centrale (VI livello – VII livello superiore) è considerato la prima sede di metastasi linfonodali in tutti i carcinomi tiroidei differenziati. L'indicazione per la dissezione del centrale (CND) è ancora in discussione soprattutto in pazienti cN0. Per alcuni autori, la dissezione centrale è raccomandata solo in pazienti sospetti preoperatoriamente (clinicamente o alla ecografia) e/o per metastasi linfonodali rilevate intra-operativamente. Per una migliore definizione abbiamo diviso la dissezione in quattro diverse aree per mappare la localizzazione delle metastasi. In questo studio presentiamo il razionale per la dissezione centrale del collo in pazienti affetti da carcinoma differenziato della tiroide, fornendo alcune considerazioni anatomiche sulla tecnica chirurgica, considerazione oncologiche e l'analisi delle complicanze. La dissezione centrale del collo potrebbe essere limitata ai compartimenti che descrivono un'area prevedibile di recidive locali, al fine di ridurre la morbilità.

PAROLE CHIAVE: Carcinoma della tiroide • Svuotamento centrale del collo

Acta Otorhinolaryngol Ital 2014;34:9-14

Introduction

Differentiated thyroid cancers generally have a very good prognosis, with a 10-year survival rate greater than 90%¹. However, lymph node metastases are frequent (20-50%)², and up to 15% of patients will develop a regional recurrence after total thyroidectomy³. The prognostic value of nodal metastases is controversial: some Authors consider their presence predictive of local disease recurrence⁴⁻¹¹, but overall disease-specific survival does not seem to be adversely affected. Loco-regional metastasis to the cervical lymph node network can take place in one or more of the levels originally described by Robbins¹². Cervical lymph node levels VI and the upper part of VII, most commonly known as the central compartment, are often

involved in thyroid malignancy. This anatomical district is considered to be the first echelon of nodal metastases in all thyroid carcinomas¹³.

The most important morbidities associated with central neck dissection (CND) consist of recurrent laryngeal nerve damage and hypocalcaemia related to parathyroid hypo-function or to accidental parathyroidectomy. The incidence of surgical complications is variable, surgeon- and centre-dependent, and correlates with pathological features of the tumour. It is important to keep in mind the data available in the most current scientific literature: transient hypocalcaemia has been reported with an incidence of up to 30%¹⁴, while recurrent laryngeal nerve injury has been observed with an incidence of in 1-3%^{15,16}.

Complications are an unpleasant, and sometimes unavoidable, which are a reality of intense surgical activity. Minimization of their incidence can only come from accurate knowledge of the relevant surgical anatomy, standardized and careful surgical techniques and clear therapeutic indications.

In the latest guidelines published by the European Thyroid Association (ETA)¹⁷, compartment-oriented microdissection (CND) of lymph nodes is recommended for lymph nodes that are suspect preoperatively and/or lymph node metastases detected intra-operatively with a positive pathologic examination¹⁸. The rationale for this recommendation is based on the evidence that radical primary surgery has a favorable impact on survival in high-risk patients, and on the recurrence rate in low-risk patients¹⁹⁻²¹. The American Thyroid Association (ATA) Surgery Working Group in collaboration with the AAES, AAO-HNS and the AHNS recently published a consensus statement on the Terminology and Classification of central neck dissection for thyroid cancer²². These guidelines were formulated in response to inconsistencies in the terminology pertaining to central neck dissection in the current scientific literature. While the terminology may now be standardized, controversy remains surrounding treatment indications for CND in papillary thyroid carcinoma. With a view to maximizing disease-free survival and minimizing morbidity, in this paper the Authors provide some technical considerations for CND, as this is often a site of persistent disease or subclinical node involvement.

Materials and methods

Anatomical considerations

The central compartment is composed of level VI and the upper part of level VII (Fig. 1). The VI level (or the anterior neck compartment) is defined as the anatomical area between the hyoid bone, supra-sternal notch and carotid arteries (bilaterally); it includes the peri-thyroidal paralaryngeal, paratracheal (in the tracheo-esophageal groove), pretracheal and prelaryngeal (or Delphian) nodes. The VII level contains the upper anterior mediastinal lymph nodes found above the innominate (brachiocephalic) artery²³.

The peri-glandular lymphatic network and tracheal plexus provide drainage of the thyroid gland to the pre-laryngeal, pre- and para-tracheal lymph nodes. Laterally, lymphatic vessels along the superior thyroid vessels drain to the deep cervical nodes, and additional drainage is provided by the brachiocephalic nodes in the superior mediastinum towards the tracheo-bronchial nodes and ultimately to the thoracic duct.

Most studies show that metastatic lymph nodes are situated in the lateral neck (II III IV levels), and central neck nodes (VI VII levels); I and V levels are of less frequent localization²⁴⁻²⁷. Lateral neck nodes are usually identified

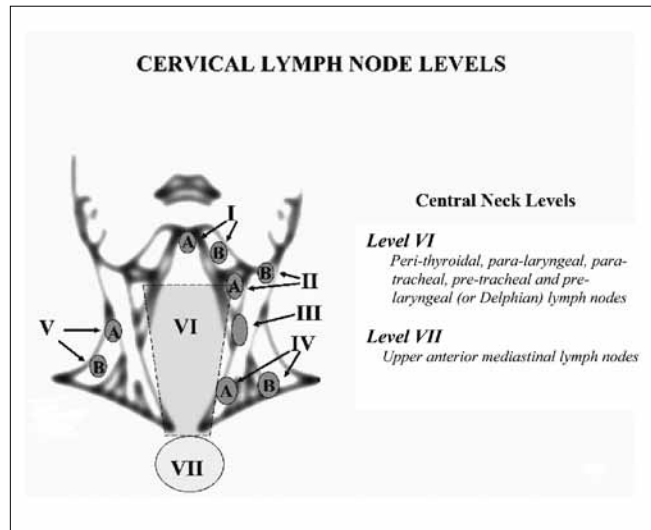


Fig. 1. Standard classification for neck node levels.

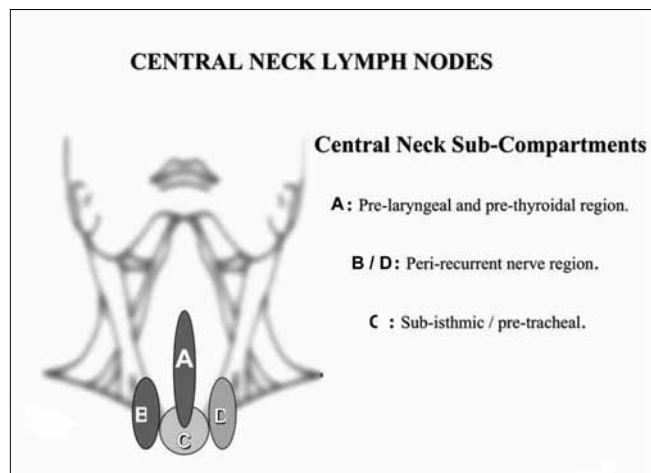


Fig. 2. Central neck sub-compartment. The author's classification.

both with clinical evaluation and/or ultrasound scan, while central neck nodes often bear subclinical metastasis. For this reason, adequate removal of central neck lymph nodes should include: 1) lymph nodes along the midline (linea alba) between the strap muscles; 2) lymph nodes present between the major neurovascular bundles of the neck. It is possible to delineate four areas (or sub-compartments) where the clinically most important lymph nodes are usually found, starting from the classification recently described by Orloff²⁸ (Figs. 2, 3). These sub-compartments may be described in detail as containing the following structures:

Area A: the delphian and pre-thyroidal lymph nodes included in the adipose tissue present in a medial sub-platysmal space that develops from the median fascial folds. This area corresponds to the region of the neck commonly defined as the muscular linea-alba and is superficial to the thyroid capsule and cartilage.

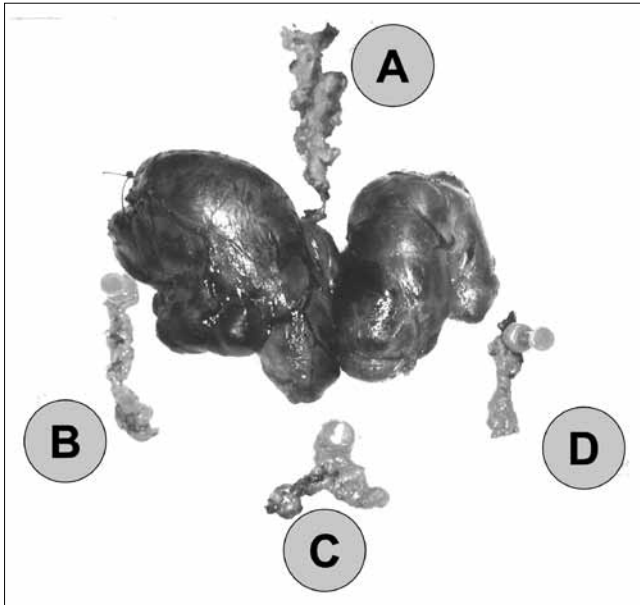


Fig. 3. View of surgical specimen: thyroid gland and central compartment nodes.

Areas B/D: deep lymph nodes contained in the adipose tissue on the right (B) and left side (D) respectively; they are bound laterally by the neuro-vascular bundle of the neck, medially by the trachea, posteriorly by the oesophagus, anteriorly by each lobe of the thyroid, cranially by the horizontal line delimited by the entrance point of the recurrent laryngeal nerves into the cryco-thyroid membrane and inferiorly by the brachiocephalic (innominate) trunk.

Area C: deep pre-tracheal nodes present in the adipose tissues bound superficially by the strap muscles, the pre-tracheal fascia at its deepest point, cranially by the thyroid isthmus and caudally by the brachiocephalic (innominate) trunk.

Oncological considerations

There is a general consensus with regards to the treatment of clinically-evident neck metastases in PTC patients². In contrast, the benefits of prophylactic, *en-bloc*, CND are still controversial²⁹⁻⁴⁰.

Factors supporting prophylactic CND are: 1) accurate staging of disease to plan the best treatment and follow-up; 2) changing radioiodine treatment indication or dosing; 3) decreased rates of local recurrence and the potential morbidity of reoperation^{5 8 9 26}; and 4) possible improvement in overall survival^{30 31}.

Factors against CND are: possible side-effects of dissection, primarily transient or permanent hypocalcaemia related to parathyroid gland damage and recurrent laryngeal nerve injury and overtreatment in N0 patients.

The literature offers no definitive evidence that CND improves both overall survival and disease-free survival. Indeed, most studies are limited to retrospective analysis of

case series. A common bias is the insufficient stratification of nodal involvement according to primary tumour size and overall stage. The indolent course of disease progression⁴¹ is an important obstacle to the evaluation of treatment efficacy and recurrence. Finally, most practitioners do not perform a true CND: sometimes lymphadenectomy is limited to the peri-glandular, pre-tracheal, pre-laryngeal and delphian nodes *without* dissection above the thyroid cartilage all the way to the hyoid bone²³. For all these reasons, the need and the extent of prophylactic CND according to the tumour size and localization are still a matter of debate.

Surgical technique

A recent report in the literature provides one of the first attempts to give a standard and rational description of the surgical technique for central neck (or central compartment) dissection⁴². Lymphadenectomy can be performed either unilaterally (A-B-C/A-D-C areas), or bilaterally (A-B-C-D), (Figs. 2, 3).

We perform a standard Kocher incision. The skin flaps are raised and the strap muscles are dissected and separated to maximize lateral retraction. Visualization of the median inter-muscular line allows identification of area A (the delphian and pre-laryngeal lymph nodes anterior to the cryco-thyroid membrane.) leaving the loose fibro-fatty glandulo-stromal tissue adhering to the thyroid capsule.

After isolation and dissection of the strap muscles on the right side and thus removing the A area, the homolateral hemi-thyroid is visualized, the middle thyroid vein is ligated and the carotid fascia is isolated. Progressing cranially, the superior pole vasculature is ligated preserving the superior parathyroid gland in situ along with its primary blood supply from the superior branch of the inferior thyroid artery. The inferior thyroid artery is identified and ligated terminally after it branches to the parathyroid gland. The inferior thyroid artery allows identification of the recurrent laryngeal nerve in its medial and lateral branches which are visualized and preserved (the nerve may follow a different path, above, below or in between the arterial branches). Superior retraction of the thyroid gland allows removal of compartment B from the medial aspect of the common carotid artery to its origin at the branching point of the innominate trunk. The dissection proceeds in its deepest portion from lateral to medial, detaching the glandulo-stromal tissue from the oesophageal musculature and the lateral aspect of the trachea, taking great care to preserve the branches of the sympathetic cervical plexus and the recurrent laryngeal nerve. The most caudal portion of the compartment (Area C) from the thymus gland and the innominate trunk is dissected after ligation of the inferior thyroid veins and eventually IMA by the innominate trunk, until the left tracheal margin is reached. The right hemi-thyroidectomy is completed *en-bloc* with lymph node compartments B and C after sec-

tioning Berry's ligament and releasing the isthmus from the pre-tracheal fascia.

The B area and the D area differ in some anatomical asymmetries and thus can lead to changes in the surgical approach, but procedures are the same: after left hemithyroidectomy, compartment D is dissected and removed with preservation of the left parathyroid glands, ligation of the inferior thyroid arteries, and identification and preservation of the left recurrent laryngeal nerve in the tracheo-oesophageal recess as described for the right side. It

Table I. Clinical, pathological and follow-up characteristics of patients who received total thyroidectomy and central neck dissection for differentiated thyroid cancer (n = 65).

Characteristics	Value (%)
Age (years)	
Median (range)	51 (26-82)
Sex	
Male	16 (24.6)
Female	49 (75.4)
Tyr	
4	19 (29.2)
5	46 (70.8)
Lateral Neck Dissection	
No	48 (73.9)
Monolateral	16 (24.6)
Bilateral	1 (1.5)
Histology	
Papillary	65 (100)
Multifocality/multicentricity	
Yes	28 (43.1)
Pathological tumour stage	
T1a	15 (23.1)
T1b	15 (23.1)
T2	3 (4.6)
T3	26 (40.0)
T4a	6 (9.2)
Pathological neck stage	
No	29 (44.6)
N1a	20 (30.8)
N1b	16 (24.6)
Post surgery complications	
Yes	37 (56.9)
Transient hypocalcaemia	26 (40.0)
Permanent hypocalcaemia	6 (9.2)
Transient recurrent nerve paresis	8 (12.3)
Permanent recurrent nerve paresis	0 (-)
Local infection	1 (1.5)
Other	2 (3.1)
Follow-up (months)	
Median (range)	16 (1-31)
Status at last clinical visit	
Alive with no evidence of disease	65 (100)
Type of relapsed	
Lateral neck	1 (1.5)

^{*}Dysphagia, lymphorrhoea.

is important to remember the virtual line extending from the brachio-cephalic trunk on the right side to the carotid artery on the left, which delineates the inferior boundary of the central compartment to be dissected and removed.

Results

Between April 2010 and December 2011, 65 patients, 16 (24.6%) males and 49 (75.4%) females with a median age 51 years old (26-82 years), underwent total thyroidectomy and CND with the new technique of 4 areas (A, B, C, D) for papillary thyroid cancer, according to the guidelines currently used at IEO, and were included in this preliminary study.

CND was performed simultaneously during total thyroidectomy. Written informed consent was obtained for surgical options from all patients. The clinical, pathological and follow-up characteristics of patients are shown in Table I.

A total of 601 lymph nodes from central compartment (A, B, C, D areas) were removed in the first 65 patients. Of these, 44 lymph nodes were from A area, 218 from B, 145 from C and 194 from D. The number of metastases were 11 in A, 42 in B, 42 in C and 34 in D. The mean of removed lymph nodes was 9 with a range between 1 and 22. Before using the new technique in IEO we previously had a mean of 4 lymph nodes from each patient.

In 64 (98.5%) patients, the analysis of nodal spreading showed an homolateral nodal diffusion (B if right, D if left) and/or central (A and C) lymph nodal diffusion when T disease arises within each lobe. Lesions from isthmus had wide diffusion, involving both sides and indifferently any areas. One (1.5%) patient had a contralateral nodal spread.

A more recent update of our data showed that from April 2010 to March 2012 167 patients underwent CND of the four areas. Of these, 122 (73%) were total thyroidectomy (TT), of which 101 (83%) were carcinomas. In 122 patients undergoing total thyroidectomy, only 2 patients (3.1%) had metastases in a contralateral side.

Discussion

CND is currently performed for patients with pathological nodes that are clinically apparent at diagnosis. It is clear from the available scientific literature and from the approach taken in multiple major clinical centres worldwide that CND and the central compartment of the neck are not one and the same. As recently pointed out^{23 43 44}, CND should be limited, in an effort to reduce the associated morbidity, to the compartments that describe a predictable territory of regional disease presentation. Our clinical experience is congruent with the consensus recommendation to remove all four areas of the central neck in patients with cN1 disease. The decision to perform a prophylactic CND in patients with cN0 disease should be

taken into account not only for T3 and T4 tumours, but also for all lesions above 1 cm in diameter, because complete pathological examination of central neck nodes can change both the tumour stage and therapeutic approach, especially for small tumours. In fact, pT1 tumours with central node metastasis (pT1pN1) are usually submitted to radioiodine treatment, while larger tumours such as pT2 without nodal involvement can avoid it^{43,44}.

For patients with DTC, neck ultrasound is the most important imaging technique for pre-operative assessment of non-palpable lymph node metastasis, but diagnostic accuracy in central neck disease is lower than that for lateral node disease, even in skilled hands²⁴. CND can overcome the shortcomings of diagnostic techniques. For early stage non-multifocal tumours (T1-T2), we advocate hemi-thyroidectomy plus selective lymphadenectomy of the ipsilateral compartments (A+B+C or A+D+C, Fig. 3), because we found contralateral nodal metastasis only in more advanced or multifocal diseases. In the first 20 months of our experience, the approach seems to be very promising to obtain up a lymphatic drainage map from each tumour localization, and to assess the genuine prognostic value of nodal metastases and micrometastases. These very preliminary data must be validated by further ongoing studies, and currently represent an active area of prospective clinical research in our Institute.

References

- Hundahl SA, Fleming ID, Fremgen AM, et al. *A national cancer data base report on 53,856 cases of thyroid carcinoma treated in the US, 1985-1995*. Cancer 1998;83:2638-48.
- Cooper DS, Doherty GM, Haugen BR, et al. *Management guidelines for patients with thyroid nodules and differentiated thyroid cancer*. Thyroid 2006;16:109-42.
- McConahey WM, Hay ID, Woolner LB, et al. *Papillary thyroid cancer treated at the Mayo Clinic, 1946 through 1970: initial manifestations, pathologic findings, therapy, and outcome*. Mayo Clin Proc 1986;61:978-96.
- Mazzaferrri EL, Jhiang SM. *Long-term impact of initial surgical and medical therapy on papillary and follicular thyroid cancer*. Am J Med 1994;97:418-28.
- Sato N, Oyamatsu M, Koyama Y, et al. *Do the level of nodal disease according to the TNM classification and the number of involved cervical nodes reflect prognosis in patients with differentiated carcinoma of the thyroid gland?* J Surg Oncol 1998;69:151-5.
- Grebe SK, Hay ID. *Thyroid cancer nodal metastases: biological significance and therapeutic considerations*. Surg Oncol Clin N Am 1996;5:43-63.
- Wada N, Suganuma N, Nakayama H, et al. *Microscopic regional lymph node status in papillary thyroid carcinoma with and without lymphadenopathy and its relation to outcomes*. Langenbeck's Arch Surg 2007;392:417-22.
- Hughes CJ, Shaha AR, Shah JP, et al. *Impact of lymph node metastasis in differentiated carcinoma of the thyroid: a matched-pair analysis*. Head Neck 1996;18:127-32.
- Ito Y, Tomoda C, Uruno T, et al. *Clinical significance of metastasis to the central compartment from papillary microcarcinoma of the thyroid*. World J Surg 2006;30:91-9.
- Lundgren CI, Hall P, Dickman PW, et al. *Clinically significant prognostic factors for differentiated thyroid carcinoma: a population-based, nested case-control study*. Cancer 2006;106:524-31.
- Beasley NJP, Lee J, Eski S, et al. *Impact of nodal metastases on prognosis in patients with well-differentiated thyroid cancer*. Arch Otolaryngol Head Neck Surg 2002;128:825-8.
- Robbins KT, Medina JE, Wolfe GT, et al. *Standardizing neck dissection terminology: official report of the Academy's Committee for Head and Neck Surgery and Oncology*. Arch Otolaryngol Head Neck Surg 1991;117:601-5.
- Qubain SW, Nakano S, Baba M, et al. *Distribution of lymph node micrometastasis in pN0 well-differentiated thyroid carcinoma*. Surgery 2002;131:249-56.
- Roh JL, Park JY, Rha KS, et al. *Is central neck dissection necessary for the treatment of lateral cervical nodal recurrence of papillary thyroid carcinoma?* Head Neck 2007;29:901-6.
- Roh JL, Yoon YH, Park CI. *Recurrent laryngeal nerve paralysis in patients with papillary thyroid carcinomas: evaluation and management of resulting vocal dysfunction*. Am J Surg 2009;197:459-65.
- Guercioni G, Siguini W, Taccaliti A, et al. *Surgical Treatment of differentiated thyroid carcinoma*. Ann Ital Chir 2003;74:501-9.
- Pacini F, Schlumberger M, Dralle H, et al.; and the European Thyroid Cancer Taskforce. *European Consensus for the management of patients with differentiated thyroid carcinoma of the follicular epithelium* Eur J Endocrinol 2006;154:787-803.
- Ito Y, Tomoda C, Uruno T, et al. *Preoperative ultrasonographic examination for lymph node metastases: usefulness when designing lymph node dissection for papillary microcarcinoma of the thyroid*. World J Surg 2004;28:498-501.
- Machens A, Hinze R, Thomusch O, et al. *Pattern of nodal metastasis for primary and reoperative thyroid cancer*. World J Surg 2002;26:22-8.
- Scheumann GF, Gimm O, Wegener G, et al. *Prognostic significance and surgical management of locoregional lymph node metastases in papillary thyroid cancer*. World J Surg 1994;18:559-68.
- Tisell LE, Nilsson B, Molne J, et al. *Improved survival of patients with papillary thyroid cancer after surgical microdissection*. World J Surg 1996;20:854-9.
- American Thyroid Association Surgery Working Group; American Association of Endocrine Surgeons; American Academy of Otolaryngology-Head and Neck Surgery; American Head and Neck Society, Carty SE, Cooper DS, Doherty GM, et al. *Consensus statement on the terminology and classification of central neck dissection for thyroid cancer*. Thyroid 2009;19:1153-8.
- Robbins KT, Clayman G, Levine PA, et al.; American Head and Neck Society; American Academy of Otolaryngology-Head and Neck Surgery. *Neck dissection classification update: revisions proposed by the American Head and Neck Society and the American Academy of Otolaryngology-Head and Neck Surgery*. Arch Otolaryngol Head Neck Surg 2002;128:751-8.

- ²⁴ Hughes DT, Doherty GM. *Central neck dissection for papillary thyroid cancer*. *Cancer Control* 2011;18:83-8.
- ²⁵ Son YI, Jeong HS, Baek CH, et al.. *Extent of prophylactic lymph node dissection in the central neck area of the patients with papillary thyroid carcinoma: comparison of limited versus comprehensive lymph node dissection in a 2-year safety study*. *Ann Surg Oncol* 2008;15:2020-6.
- ²⁶ Moo TA, Umunna B, Kato M, et al. *Ipsilateral versus bilateral central neck lymph node dissection in papillary thyroid carcinoma*. *Ann Surg* 2009;250:403-8.
- ²⁷ Moo TA, McGill J, Allendorf J, et al. *Impact of prophylactic central neck lymph node dissection on early recurrence in papillary thyroid carcinoma*. *World J Surg* 2010;34:1187-91.
- ²⁸ Orloff LA, Koppersmith RB. *American Thyroid Association's central neck dissection terminology and classification for thyroid cancer consensus statement*. *Otolaryngol Head Neck Surg* 2010;142:4-5.
- ²⁹ White ML, Gauger PG, Doherty GM. *Central lymph node dissection in differentiated thyroid cancer*. *World J Surg* 2007;31:895-904.
- ³⁰ Costa S, Giugliano G, Santoro L, et al. *Role of prophylactic central neck dissection in cN0 papillary thyroid cancer*. *Acta Otorhinolaryngol Ital* 2009;29:61-9.
- ³¹ Zuniga S, Sanabria A. *Prophylactic central neck dissection in stage N0 papillary thyroid carcinoma*. *Arch Otolaryngol Head Neck Surg* 2009;135:1087-91.
- ³² Tisell LE, Nilsson B, Molne J, et al. *Improved survival of patients with papillary thyroid cancer after surgical microdissection*. *World J Surg* 1996;20:854-9.
- ³³ Scheumann GFW, Gimm O, Wegener G, et al. *Prognostic significance and surgical management of locoregional lymph node metastases in papillary thyroid cancer*. *World J Surg* 1994;18:559-68.
- ³⁴ Shah MD, Hall FT, Eski SJ, et al. *Clinical course of thyroid carcinoma after neck dissection*. *Laryngoscope* 2003;113:2102-7.
- ³⁵ Steinmuller T, Klupp J, Rayes N, et al. *Prognostic factors in patients with differentiated thyroid carcinoma*. *Eur J Surg* 2000;166:29-33.
- ³⁶ Wada N, Duh QY, Sugino K, et al. *Lymph node metastasis from 259 papillary thyroid microcarcinomas: frequency, pattern of occurrence and recurrence, and optimal strategy for neck dissection*. *Ann Surg* 2003;237:399-407.
- ³⁷ Sywak M, Cornford L, Roach P, et al. *Routine ipsilateral level VI lymphadenectomy reduces postoperative thyroglobulin levels in papillary thyroid cancer*. *Surgery* 2006;140:1000-7.
- ³⁸ Pereira JA, Jimeno J, Miquel J, et al. *Nodal yield, morbidity, and recurrence after central neck dissection for papillary thyroid carcinoma*. *Surgery* 2005;138:1095-100.
- ³⁹ Shindo M, Wu JC, Park EE, et al. *The importance of central compartment elective lymph node excision in the staging and treatment of papillary thyroid cancer*. *Arch Otolaryngol Head Neck Surg* 2006;132:650-4.
- ⁴⁰ Kim MK, Mandel SH, Baloch Z, et al. *Morbidity following central compartment reoperation for recurrent or persistent thyroid cancer*. *Arch Otolaryngol Head Neck Surg* 2004;130:1214-6.
- ⁴¹ Sadowski BM, Snyder SK, Lairmore TC. *Routine bilateral central lymph node clearance for papillary thyroid cancer*. *Surgery* 2009;146:696-703; Discussion: 703-5.
- ⁴² Pai S, Tufano RP. *Central Compartment Neck Dissection for Thyroid Cancer – Technical Considerations*. *ORL J Otorhinolaryngol Relat Spec* 2008;70:292-7.
- ⁴³ Raffaelli M, De Crea C, Sessa L, et al. *Can intraoperative frozen section influence the extension of central neck dissection in cN0 papillary thyroid carcinoma?* *Langenbecks Arch Surg* 2013;398:383-8.
- ⁴⁴ Raffaelli M, De Crea C, Sessa L, et al. *Prospective evaluation of total thyroidectomy versus ipsilateral versus bilateral central neck dissection in patients with clinically node-negative papillary thyroid carcinoma*. *Surgery* 2012;152:957-64.

Received: December 3, 2012 - Accepted: March, 18, 2013

Address for correspondence: Gioacchino Giugliano, Division of Head & Neck Surgery, European Institute of Oncology, via Ripamonti 435, 20141 Milano, Italy. Tel. +39 02 57489490. Fax +39 02 94379216. E-mail: gioacchino.giugliano@ieo.it

HEAD AND NECK

Cervical metastasis on level IV in laryngeal cancer

Metastasi latero cervicali al livello IV nei carcinomi della laringe

V.J. FURTADO DE ARAÚJO NETO¹, C.R. CERNEA², R. APARECIDO DEDIVITIS³,
V.J. FURTADO DE ARAÚJO FILHO², J. FABIANO PALAZZO¹, L. GARCIA BRANDÃO²

¹ São Paulo School of Medicine, University of São Paulo, Brazil; ² Department of Head and Neck Surgery, São Paulo School of Medicine, University of São Paulo, Brazil; ³ Department of Head and Neck Surgery, Hospital das Clínicas, Group of Laryngeal and Hypopharyngeal Tumors, Department of Head and Neck Surgery, Hospital das Clínicas, São Paulo School of Medicine, University of São Paulo, Brazil

SUMMARY

The presence of cervical metastasis has substantial negative impact on survival of patients with laryngeal cancer. Bilateral elective selective neck dissection of levels II, III and IV is usually the chosen approach in these patients. However, there is significant morbidity associated with level IV dissection, such as phrenic nerve injury and lymphatic fistula. The objective of the present study was to evaluate the frequency of metastatic nodes in level IV in clinically T3/T4N0 patients with laryngeal cancer. The pathological reports of 77 patients with clinically T3/T4N0 laryngeal squamous cell carcinoma were reviewed. Patients underwent bilateral lateral neck dissection from January 2007 to November 2012. The surgical specimens were subdivided in levels before evaluation. There were 12 patients with neck metastasis (15.58%). In 3 cases (3.89%), there were metastatic lymph nodes in level IV, all T4 and with ipsilateral metastasis. In conclusion, the incidence of level IV metastasis was 3.89%, an in all patients was staged as T4.

KEY WORDS: Laryngeal neoplasms • Neck dissection • Lymphatic metastasis • Squamous cell carcinoma • Neoplasm staging

RIASSUNTO

La presenza di metastasi laterocervicali ha un impatto sostanzialmente negativo sulla sopravvivenza dei pazienti con tumori della laringe. Lo svuotamento laterocervicale elettivo selettivo dei livelli II, III e IV rappresenta di consuetudine l'approccio di scelta in questi pazienti. Tuttavia la morbilità associata allo svuotamento del IV livello non può essere trascurata per il rischio di danno del nervo frenico e di lesione del dotto linfatico. Obiettivo del nostro studio è stato valutare la frequenza di metastasi linfonodali al livello IV in pazienti clinicamente T3/T4N0 affetti da carcinoma della laringe. Abbiamo esaminato retrospettivamente l'esame istopatologico definitivo di 77 pazienti stadati clinicamente T3/T4N0 affetti da carcinoma della laringe. I pazienti furono sottoposti a svuotamento latero cervicale bilaterale nel periodo compreso fra il gennaio 2007 e novembre 2012. I pezzi istopatologici furono suddivisi in livelli prima di essere inviati in anatomia patologica. In 12 pazienti sono state riscontrate metastasi latero cervicali (15.58%). In 3 casi (3.89%), fu riscontrato un interessamento del IV livello, tutti i pazienti erano T4 con metastasi laterocervicali ipsilaterali al tumore. In conclusione nei pazienti clinicamente stadati come T4 l'incidenza di metastasi latero cervicali al IV livello era del 3,89%.

PAROLE CHIAVE: Neoplasia laringea • Dissezione del collo • Metastasi laterocervicali • Carcinoma a cellule squamose • Stadio della neoplasia

Acta Otorhinolaryngol Ital 2014;34:15-18

Introduction

The presence of cervical metastasis has substantial negative impact on the survival of patients with laryngeal cancer. The appropriate dissection of cervical lymph nodes is important in the surgical approach for determination of pathological staging, indication of adjuvant treatment and definition of prognosis¹.

In patients with squamous cell carcinomas of the larynx clinically staged as N+, the goal of surgical management is the total removal of the primary tumour with thera-

peutic neck dissection. However, the treatment strategy for clinically N0 patients is still controversial. Bilateral elective selective neck dissections including levels II, III and IV are usually indicated. Nonetheless, there is important morbidity associated with level IV dissection, such as phrenic nerve injury and lymphatic fistula following thoracic duct injury (when the left level IV is involved)².

Due to these potential complications, some Authors have analyzed the need for inclusion of level IV in neck dissections in patients with T3/T4N0 laryngeal cancer. It has

been reported that the incidence of level IV metastasis is less than 4%³⁻⁶.

The objective of this study was to evaluate the frequency of metastatic nodes in level IV in patients with clinically T3/T4N0 laryngeal cancers who underwent bilateral elective selective neck dissection of levels II, III and IV.

Methods

This is an observational study of pathological reports of 77 patients with clinically T3/T4N0 laryngeal squamous cell carcinoma. Patients underwent bilateral elective selective lateral neck dissection (levels II, III and IV) over a period of 5 years (January 2007 to November 2012) at Hospital das Clínicas of São Paulo School of Medicine, University of São Paulo (HC-FMUSP) and at Institute of Cancer of São Paulo (ICESP). The exclusion criteria were insufficient clinical information, previous treatment with radiotherapy or chemotherapy and oncologic diagnoses other than squamous cell carcinoma of the larynx.

Surgical specimens were subdivided in levels before being sent to the pathologist. The presence of lymph node metastasis in level IV and in the other dissected levels was studied using H-E stain.

Results

Of the 77 patients, there were 7 (9%) women and 70 men (90%). The average age was 58.8 years, ranging from 38 to 82. Twenty-eight cases were T3 (35.8%) and 50 were T4 (64.2%). The primary tumour subsites were 13 supraglottic (16.8%), 42 glottic (45.5%) and 22 transglottic (28.5%). There were 12 patients with neck metastasis (15.58%). In 3 cases (3.89%), there were metastatic lymph nodes in level IV, 2 from transglottic tumours and one in a case of

supraglottic tumour. All 3 cases had T4 tumours and all metastases were ipsilateral to the primary tumour. In one of these, there were simultaneous metastases in level III, ipsilateral to the primary tumour (Table I).

Discussion

Cervical lymph nodes metastases are one of the most significant prognostic factors in patients with laryngeal cancer. The rationale for performing elective selective neck dissections is based on the predictable pattern of lymphatic spread of upper aerodigestive tract tumours⁷. The first echelon of lymphatic drainage should be removed. If it does not harbour metastatic disease, the incidence of metastasis in other levels of the neck is believed to be extremely low. Elective dissection of lymph nodes at levels II-IV is indicated for patients with T3 and T4 laryngeal cancers. However, the need to remove level IV has been questioned. Furthermore, there is a possible risk for associated morbidity⁴.

The patterns of cervical metastasis from laryngeal cancer were studied in 262 radical neck dissection specimens from 247 patients. Occult positive adenopathy was found in 37% of patients, mainly on levels II-IV, whereas only rarely were levels I (14%) and V (7%) involved⁸.

Selective lateral neck dissection (levels II-IV) was prospectively compared to type III modified radical neck dissection as part of elective treatment for patients with supraglottic and transglottic laryngeal cancer. After a mean follow-up of 42 months, no difference was found in the outcome between patients treated with either modality. It supports the use of lateral neck dissection as an effective treatment for patients with T2/T4 supraglottic and transglottic cancer, which is the elective treatment of choice for patients with laryngeal cancer⁹.

Table I. Staging characteristics of patients with neck metastases (n = 12).

Age (years)	Subsite and T staging	Level II	Level III	Level IV
66	Transglottic T4	1 (ipsilateral)	0	0
49	Supraglottic T4	0	0	1 (ipsilateral)
82	Transglottic T4	0	0	1 (ipsilateral)
52	Supraglottic T4	2 (ipsilateral)	1 (ipsilateral)	0
56	Transglottic T4	2 (ipsilateral)	1 (ipsilateral)	0
56	Transglottic T4	2 (ipsilateral)	2 (ipsilateral)	0
49	Glottic T3	1 (contralateral)	1 (contralateral)	0
71	Supraglottic T4	1 (contralateral)	0	0
53	Glottic T4	1 (ipsilateral)	2 (1 ipsilateral and 1 contralateral)	0
68	Glottic T3	1 (ipsilateral)	0	0
59	Glottic T3	4 (2 contralateral and 2 ipsilateral)	0	0
69	Transglottic T4	0	1 (ipsilateral)	1 (ipsilateral)

One hundred forty-five selective neck dissections were performed at levels II-III in 79 patients who were surgically treated for laryngeal carcinomas. A more extensive neck dissection that included levels IV-V was performed in all patients with nodal metastasis pathologically demonstrated by intraoperative frozen section analysis. Pathologic assessment of neck dissection specimens revealed nodal metastasis at level IV in 2 patients (2.5%). After a follow-up of at least 24 months, no patients had regional recurrence¹⁰.

Forty-two patients with supraglottic cancers and 29 with transglottic cancers were reviewed. Levels II-IV had been removed in all cases. Of 43 patients who underwent elective lateral neck dissection, one (2.3%) presented level IV metastasis – with simultaneous level II metastases. The authors recommend dissection of level IV as part of therapeutic neck dissection for patients with clinically enlarged lymph nodes. However, they consider the absence of detectable adenopathy a challenge⁴.

In a series of 155 N0 patients with supraglottic cancer, whose treatment consisted of an elective neck dissection limited just to level II, 10 patients (6.5%) experienced ipsilateral neck recurrences after a minimum follow-up of 5 years¹¹.

A prospective study of 142 lateral neck dissections in 73 patients with laryngeal tumour and N0 neck evaluated the incidence of pathological metastases in level IV. Five necks had positive lymph nodes for microscopic metastasis in level IV (3.5%), all of which were ipsilateral. Separate skip metastases in level IV lymph nodes were observed in two cases. Postoperative chylous leakage and phrenic nerve paralysis occurred in 5.5% and 2.7%, respectively¹². In fact, potential damage to the major lymphatic vessels leading to chylous leakage and phrenic nerve paralysis are the two major complications associated with level IV dissection⁵.

The results of our study further support a more selective approach, with dissection limited to levels II-III as the primary elective treatment of a clinically negative neck for patients with supraglottic and transglottic cancers. In spite of this, further prospective studies are necessary to determine its safety in the clinical setting. On the other hand, for patients with clinically positive adenopathy at higher levels (II-III), a more extensive neck dissection (modified radical neck dissection) would appear to be warranted.

The current clinical staging criteria fail to differentiate patients with occult metastases from those without metastases¹³. Molecular markers of metastatic potential could help to indicate treatment of the neck in patients with undetectable disease and to avoid unnecessary approaches. However, since the metastatic process is complex with the involvement of many factors, there are still no genetic biomarkers, and recently published studies are contradictory and of little benefit for routine clinical use³. Many

investigators are working to identify molecular markers of disease, to improve the understanding of the mechanisms underlying the pathogenesis and development of laryngeal cancer and to improve its clinical staging¹³. The degree of differentiation is the most important histologic factor. Overexpression of EGFR has been associated with poor prognosis, whereas the association with HPV infection is distinguished by better prognosis. p53 mutations and cyclin D1 amplification have also been subject to intensive research¹⁴.

Conclusion

In the present study, the frequency of occult lymph node metastases on level IV in patients with T3-T4 laryngeal cancers was very low (3.89%). No patient with a T3 primary had occult metastases on level IV. Therefore, the results suggest that it is oncologically safe to include only levels II and III in elective neck dissections performed for laryngeal cancer and ipsilateral IV level for T4 tumours. However, prospective studies are necessary to confirm this.

References

- Barroso Ribeiro R, Ribeiro Breda E, Fernandes Monteiro E. *Prognostic significance of nodal metastasis in advanced tumors of the larynx and hypopharynx*. Acta Otorrinolaringol Esp 2012;63:292-8.
- Ferlito A, Silver CE, Suárez C, et al. *Preliminary multi-institutional prospective pathologic and molecular studies support preservation of sublevel IIB and level IV for laryngeal squamous carcinoma with clinically negative neck*. Eur Arch Otorhinolaryngol 2007;264:111-4.
- Ferlito A, Silver CE, Rinaldo A. *Neck dissection: present and future?* Eur Arch Otorhinolaryngol 2008;265:621-6.
- Khafif A, Fliss DM, Gil Z, et al. *Routine inclusion of level IV in neck dissection for squamous cell carcinoma of the larynx: is it justified?* Head Neck 2004;26:309-12.
- Lim YC, Choi EC, Lee JS, et al. *Is dissection of level IV absolutely necessary in elective lateral neck dissection for clinically N0 laryngeal carcinoma?* Oral Oncol 2006;42:102-7.
- Garas J, McGuirt WF. *Squamous cell carcinoma of the subglottis*. Am J Otolaryngol 2006;27:1-4.
- Robbins KT, Shaha AR, Medina JE, et al.; Committee for Neck Dissection Classification, American Head and Neck Society. *Consensus statement on the classification and terminology of neck dissection*. Arch Otolaryngol Head Neck Surg 2008;134:536-8.
- Shah JP. *Patterns of cervical lymph node metastasis from squamous carcinomas of the upper aerodigestive tract*. Am J Surg 1990;160:405-9.
- Brazilian Head and Neck Cancer Study Group. *End results of a prospective trial on elective lateral neck dissection vs type III modified radical neck dissection in the management of supraglottic and transglottic carcinomas*. Head Neck 1999;21:694-702.
- León X, Quer M, Orús C, et al. *Selective dissection of levels II-III with intraoperative control of the upper and middle*

- jugular nodes: a therapeutic option for the N0 neck.* Head Neck 2001;23:441-6.
- ¹¹ Shaha AR, Shah JP. *Carcinoma of the subglottic larynx.* Am J Surg 1982;144:456-8.
- ¹² Tu GY. *Upper neck (level II) dissection for N0 neck supra-glottic carcinoma.* Laryngoscope. 1999;109:467-70.
- ¹³ Allegra E, Puzzo L, Zuccalà V, et al. *Nuclear BMI-1 expression in laryngeal carcinoma correlates with lymph node pathological status.* World J Surg Oncol 2012;10:206.
- ¹⁴ Cojocariu OM, Huguet F, Lefevre M, et al. *Facteurs pronostiques et prédictifs des cancers des voies aérodigestives supérieures.* Bull Cancer 2009;96:369-78.

Received: April 10, 2013 - Accepted: June 27, 2013

LARYNGOLOGY

How the operated larynx ages

Processi di invecchiamento della laringe sottoposta ad intervento chirurgico

E. CROSETTI¹, P. GAROFALO², C. BOSIO³, P. CONSOLINO¹, A. PETRELLI⁴, G. RIZZOTTO⁵, G. SUCCO²¹ ENT Dept., Martini Hospital, Torino, Italy; ² ENT University Dept., San Luigi Gonzaga Hospital, University of Torino, Italy; ³ Radiology Dept., "Martini" Hospital, Torino, Italy; ⁴ Epidemiology Unit, Piemonte Region, Torino, Italy; ⁵ ENT Dept., "Vittorio Veneto" Hospital, Treviso, Italy

SUMMARY

After open partial laryngectomy (HOPL), many patients experience deterioration of laryngeal function over time. The aim of this study was to evaluate laryngeal functional outcome at least 10 years after surgery in a cohort of 80 elderly patients. The incidence of aspiration pneumonia (AP) and objective/subjective laryngeal functional assessments were carried out. Eight patients experienced AP including four with repeated episodes. A significant association was observed between AP and severity of dysphagia ($p < 0.001$). Dysphagia was more pronounced than in a normal population of similar age, but less than would be expected. There was a significant association between the type of intervention and grade of dysphagia/dysphonia; a difference in voice handicap was found, depending on the extent of glottic resection. After HOPL, laryngeal function was impaired, but this did not significantly affect the quality of life. AP is more frequent in the initial post-operative period, and decreases in subsequent years.

KEY WORDS: Open partial laryngectomy • Elderly • Supraglottic partial laryngectomy • Supracricoid partial laryngectomy • Supratracheal partial laryngectomy • Aspiration

RIASSUNTO

Molti pazienti sottoposti ad intervento chirurgico di laringectomia parziale vanno incontro con il tempo a fenomeni di deterioramento della funzione laringea. L'obiettivo del presente lavoro è stato quello di valutare in un campione di 80 pazienti anziani la funzionalità laringea a distanza di almeno 10 anni dall'intervento chirurgico. Abbiamo valutato l'incidenza delle polmoniti da aspirazione (AP) e la funzionalità laringea da un punto di vista oggettivo e soggettivo. Otto pazienti hanno presentato polmoniti da aspirazione, di cui quattro episodi ripetuti. È stata riscontrata un'associazione statisticamente significativa tra polmonite da aspirazione e grado di severità della disfagia ($p < 0,001$). Il fenomeno della disfagia è risultato essere maggiormente accentuato rispetto a quanto osservato nella popolazione normale di età analoga, ma meno di quanto ci si aspettasse. È stata riscontrata un'associazione statisticamente significativa fra tipo di intervento chirurgico e grado di disfagia/disfonia; è stata altresì evidenziata una differenza nel deficit funzionale vocale, a seconda dell'estensione della resezione glottica. Dopo interventi di laringectomia parziale, la funzionalità laringea appare alterata, ma questo non incide significativamente sulla qualità di vita del paziente. Gli episodi di polmonite da aspirazione sono più frequenti nell'immediato periodo post-operatorio, riducendosi poi di numero negli anni successivi.

PAROLE CHIAVE: Laringectomia parziale • Anziano • Laringectomia orizzontale sopraglottica • Laringectomia sopracricoidea • Laringectomia sopratracheale • Aspirazione

Acta Otorhinolaryngol Ital 2014;34:19-28

Introduction

In the second half of the 20th century, horizontal open partial laryngectomies (HOPLs), including, supraglottic laryngectomies (SLs), supracricoid laryngectomies (SCPLs) and most recently, supratracheal laryngectomies (STPLs), have become established as a viable surgical option, primary or salvage, for the treatment of intermediate stage laryngeal cancer. Many authors¹⁻³ have reported the oncological and functional results of HOPLs, while others have reported data relating to complications and, in particular, on the more frequent and problematic complications, namely chronic aspiration of food and aspiration pneumonia (AP)⁴.

Globally, HOPLs have demonstrated the possibility to obtain a high rate of 5-year local/regional control of disease, often in over 70% of cases, and were used widely in the 1980s and 1990s, particularly for SCPLs⁵⁻⁷. It is therefore logical to assume that there is now the opportunity to observe a population of elderly patients, cured of laryngeal cancer, and who have experienced aging with an operated larynx.

An accurate literature analysis was carried out and, to our knowledge, there are few reports focusing on the interesting question of how the operated larynx ages. Therefore, a retrospective cohort study was carried out on a group

of 80 elderly patients (age > 70 years) who underwent HOPLs at least 10 years prior, focusing on swallowing and phonatory results. Laryngeal function analysis was performed using objective and subjective methods, comparing data on episodes of AP during the follow-up period. A comparison was then carried out with literature data on swallowing impairment in elderly subjects who had not undergone laryngeal surgery, as dysfunctions can be considered as an expression of the physiological aging of the larynx.

The goal was to evaluate functional outcomes at least 10 years after HOPL in a cohort of elderly patients to look for correlations between the amount of resection and grade of impairment of swallowing and phonatory parameters detected by self-evaluation and accurate functional tests. Another aim was to examine the relationship between the type of surgery and incidence of AP during follow-up.

Materials and methods

From 1976 to the time of writing, 1486 HOPLs (supraglottic, supracricoid, supratracheal) have been performed at the Departments of Otorhinolaryngology of the Hospital of Vittorio Veneto and the Martini Hospital in Turin (Italy). This group represents a subset of 2986 patients suffering from invasive squamous cell carcinoma of the larynx (SCC) treated during the same period.

This retrospective study focused on a cohort of 80 patients with the following characteristics: patients without evidence of disease with a minimum follow-up performed in the above-mentioned departments of at least 120 months, current age greater than 70 years and previous interventions of SL, SCPL or STPL. At the time of the last follow-up, the current age of the cohort of patients ranged between 70 and 83 years with a mean of 74.8 years.

Seventy-one patients were male (88.8%) and nine female (11.2%); at the time of surgery, 91% were current or former smokers, with a mean age of 63 years (range 56-73); all patients had a biopsy-proven laryngeal SCC staged from II to IVa according to the 2002 TNM staging classification system⁸.

During the 3 weeks preceding surgical treatment, all patients underwent the same diagnostic work-up that included flexible videolaryngoscopy, intraoperative rigid endoscopy with 0°/angled telescopes and biopsy during microlaryngoscopy under general anaesthesia, laryngeal and neck CT-scan or MRI, bronchoscopy and oesophagoscopy to rule out synchronous tumours, chest X-ray or CT-scan to exclude lung tumours or distant metastases, assessment of bronchopulmonary function and comorbidities for at-risk patients, as well as nutritional evaluation. The Karnofsky performance status index had to be at least 80 (i.e. patient able to carry out normal activities, even though with difficulty)⁹.

In addition to a Karnofsky score < 80, exclusion criteria were severe diabetes mellitus, severe bronchopulmonary chronic obstructive disease and severe cardiac disease. Even though historically an age of 70 years is an important cut-off age for relative surgical indication of some partial laryngectomies, in our experience advanced age is no longer, in itself, an exclusion criterion. After accurate selection of patients on the basis of the absence of important comorbidities and the strong desire of the patient to avoid permanent tracheostomy, age was also considered along with the patient's general condition.

On the basis of pathological findings, 13 patients (16.3%) were subjected to post-operative radiation therapy with a mean dose of 64 Gy delivered to the larynx (three patients, range 62-66 Gy) and 54 Gy to the neck (10 patients, range 50-66 Gy).

Surgery

Of the 80 patients, 23 underwent SL, 45 underwent SCPL and 12 underwent STPL. In the subset of SLs, there were 6 extended supraglottic laryngectomies (ESL), 4 to the base of the tongue and 2 to the pyriform fossa. In the subset of SCPLs, the procedures used at the time of reconstruction were cricothyroidopiglottopexy (SCPL-CHEP) and cricothyroidopexy (SCPL-CHP). Removal of one arytenoid was indicated in the surgical records by adding the notation "+ A" to the abbreviation for the laryngectomy, specifying the side, left or right, of the removed arytenoids. In the subset of STPLs¹⁰, the procedures used at the time of reconstruction were tracheothyroidopiglottopexy (STPL-THEP) and tracheothyroidopexy (STPL-THP). Removal of one cricoarytenoid unit was again indicated by adding the notation "+ A" to the abbreviation for the laryngectomy, specifying the side, left or right, of the removed cricoarytenoid unit. Interventions carried out are reported in Table I.

Neck dissection (ND), classified according to the AAO-HNS¹¹, was performed in all patients and was unilateral in

Table I. Surgical procedures in the study cohort.

Type of procedure	No. (%)
SLs	17 (21.2)
Extended SLs	6 (7.5)
to base of tongue	4
to pyriform sinus	2
SCPLs	45 (56.3)
CHEP	19
CHEP + A	17
CHP	4
CHP + A	5
STPLs	12 (15)
THEP	7
THEP + A	3
THP	2

36 and bilateral in 44 patients. Neck dissection was elective (level II-III-IV + ev. level VI in the case of subglottic extension) in 67 cN0 patients (83.8%) and curative (level II-V + ev. level VI in the case of subglottic extension) in 13 cN > 0 patients (16.3%). Overall, lymph node metastases were detected in 12 patients.

In all patients, resection margins were examined intraoperatively by frozen sections; when positive, the resection was expanded until the margins were negative. The margins of the surgical specimen were always checked again until pathology reports indicated that the margins were closed (< 3 mm) in four patients.

Functional assessment

All patients underwent the same rehabilitation protocol, with the obvious exception of those with serious early complications. The post-operative protocol consisted of the following: a) post-operative days 1-4: insertion of un-cuffed tracheal cannula and beginning of phonation; b) post-operative days 4-6: during daytime, intermittent occlusion of the tracheostoma with saline-soaked gauze and starting of feeding without the tracheal cannula in position; c) post-operative day 6 onwards: the nasogastric tube (NGT) was removed as soon as a good level of swallowing of both solids and liquids was achieved.

Grading of post-operative aspiration was performed according to Pearson's scale¹² (0 = none; I = occasional cough but no clinical problems; II = constant cough worsening with meal or swallowing; III = pulmonary complications).

The study took place in 2011, and during the annual follow-up visit, all patients underwent the following evaluations: ENT clinical examination coupled with fibre optic videolaryngoscopy; accurate assessment of episodes of AP occurring during the follow-up period; evaluation of dysphonia using subjective and objective methods; evaluation of dysphagia using subjective and objective methods.

All episodes of AP and acute pneumonia were considered, documented by chest X-rays and/or by a medical report, in the period from the day of discharge to the date of the last follow-up visit, whether the patient had required hospitalization or had been treated at home.

For evaluation of dysphonia, all patients were administered the Voice Handicap Index (VHI) questionnaire proposed by Benninger in 1998¹³ for self-assessment of vocal disability. This is a questionnaire consisting of 30 items referring equally to three different aspects of vocal disorders: physical, functional and emotional. The patient can provide five possible answers, from never to always, assigning a score from 0 to 4. Summing the values assigned to the 30 responses, an overall score between 0 and 120 is obtained that corresponds to the highest level of phonatory disability perceived by the patient. Then a phoniatician and a speech therapist evaluated the voice

in all patients by assigning to each a score based on the GIBBAS scale¹⁴, after reading a standard text from SIFEL (Italian Society of Phoniatics and Logopedics).

For evaluation of dysphagia, all patients were administered the MD Anderson Dysphagia Inventory (MDADI) questionnaire¹⁵, which consists of 20 questions related to three different aspects of dysphagia: functional, physical and emotional. Again, the patient can provide five possible responses, ranging from never to always, assigning a score from 1 to 5, to obtain an overall score between 20 and 100, which corresponds to the highest level of disability perceived by the patient swallowing. Radiological study of swallowing was performed by videofluoroscopy. The radiographs obtained for each patient were then evaluated together by a radiologist (CB) and a phoniatician (PC), and each patient was assigned a score based on the DOSS (Dysphagia Outcome and Severity Scale)¹⁶. The DOSS assigns 7 degrees (the highest level of dysphagia corresponds to level 1), and is based on an objective assessment of dysphagia from the videofluoroscopy and the level of independence during the intake of food and type of food. This score allows us to understand which patients need more attention and care to avoid the risk of AP.

Statistical analysis

Statistical analyses were conducted using SAS System 9.2. The association between AP and type of intervention was analyzed using the chi-square test. Fischer's exact test was used since the number of cells with the expected frequency of less than 5 was greater than 50%. The association among the degree of dysphonia, dysphagia and type of intervention was analyzed using ANOVA tests, whereas the association between AP and degree of dysphagia was analyzed using the Student's *t*-test.

Results

At the time of last follow-up, performed by clinical examination of the neck, fiberoptic videolaryngoscopy and chest X-ray, all 80 patients were free of disease.

At the end of the first post-operative month, normal swallowing (Pearson's Scale Grade 0) was achieved in 56 of 80 patients (70.0%), grades I and II were observed in 10 (12.5%) and 8 (10.0%) patients, respectively, while AP (Pearson's Grade III) was recorded in 6 of 80 patients (7.5%). The nasogastric tube remained in place for an average of 15 days after surgery (range 6-67 days), the mean duration of tracheostomy intermittent occlusion was 25 days (range 13-92 days), and the average time of tracheostomy closure was 57 days (range 29-131 days). In our protocol, progressive closure of the tracheostomy is preferred, and occurs spontaneously in the majority of patients following occlusion. For patients, this leads to a sensation of greater safety concerning small episodes of food inhalation, which are relatively frequent, especially

Table II. Number (%) of patients with AP and association between AP and type of procedure.

Surgical procedures	No. patients (%)	No. AP (%)
SL	1/23 (4.3)	2 (15.4)
SCPL	5/45 (11.1)	6 (46.1)
STPL	2/12 (16.7)	5 (38.5)
Statistical analysis	$p=0.0131$	

in the first week after discharge. When the tracheostomy has almost closed, a small plastic skin closure can then be performed. The tracheostomy tube was removed at average of 39 days after surgery (range 13-92 days), and always when the patient was able to feed themselves. Two months after surgery, Pearson's Grades I and II were noted in four (5%) and two (2.5%) patients, respectively. Due to intense dysphagia and AP episodes in 8 of 80 patients (10%), a temporary gastrostomy was needed; in 75% of the cases, this was removed during the first post-operative year. Only in one case was the gastrostomy maintained for a longer period (4 years) due to repeated episodes of AP and severe dysphagia for liquids. Two patients were subjected to endoscopic procedures of injective laryngoplasty using Vox-Implant which successfully resolved dysphagia, allowing gastrostomy removal.

From the day of discharge and during the whole period of follow-up, eight patients (10%) experienced at least one episode of AP, including four patients who experienced repeated episodes, for a total of 13 episodes of AP reported in the years after intervention (Table II). In three cases, hospitalization of the patient was necessary (1 SCPL-CHEP + A, 1 SCPL-CHP + A, 1 STPL-THEP + A), while among the cases treated at home, one patient had undergone extended SL (extended to base of tongue), five patients had been subjected to SCPL (2 SCPL-CHEP, 2 SCPL-CHEP + A, 1 SCPL-CHP + A), and two patients had been subjected to STPL (1 STPL-THEP + A, 1 STPL-THP). Analysis of AP episodes dem-

onstrated that these occur more frequently in the early years after surgery, but are less frequent at longer times after the operation, as illustrated in Fig. 1. There was a statistically significant association between AP and type of intervention (Fischer test, $p = 0.0131$), and a higher rate of AP was observed in the more extended procedures (one arytenoid resection, one cricoarytenoid unit resection, enlargement at the base of the tongue, supratracheal resection).

The results of videofluoroscopy, assessed using the DOS Scale and divided by type of intervention, are shown in Table III. The vast majority of patients (58/80; 72.5%) achieved and maintained a very good level of rehabilitation over time, identified by grades 6-7 on the DOS Scale. The SLs reached grade 6-7 in 87.0% of cases (20/23), SCPLs in 77.8% (35/45) and STPLs in 25% (3/12); the more pronounced levels of dysphagia, corresponding to grade 3-4 of the DOS Scale, were found in SLs at a rate of 4.3% (1/23), in SCPLs at a rate of 8.9% (4/45) and in STPLs at a rate of 33.3% (4/12).

The study of swallowing function was completed by self-assessment of dysphagia using the MDADI questionnaire, and scores were stratified by type of intervention (Table IV). Overall, in 83.8% of patients, the degree of perceived swallowing disability was low with MDADI scores of 20-40, and it was possible to observe statistically significant differences between the various categories of intervention (100% of SLs, 82.2% of SCPLs, 58.3% of STPLs). The most significant perceived swallowing disability, with MDADI scores of 61 to 80, was observed in two interventions (4.4%) by SCPL. There was a statistically significant association between the type of intervention and degree of dysphagia, evaluated in an objective manner using videofluoroscopy and with the DOS Scale (ANOVA test, $p < 0.001$), both perceived by the patient and self-assessed using MDADI (ANOVA test, $p = 0.0125$). Additionally, in this case, the worst levels of

dysphagia were associated with the most extensive procedures resulting in anatomic-functional violation of the glottic sphincter, particularly when such violation led to the removal of one arytenoid or the removal of the entire cricoarytenoid unit as in supratracheal laryngectomies.

The results of voice analysis using the GIRBAS scale as well as the results of self-evaluation using the VHI questionnaire are shown in Table V and are stratified for each type of intervention. Objective assessment with the GIRBAS scale showed that overall, HOPLs enabled patients to achieve and

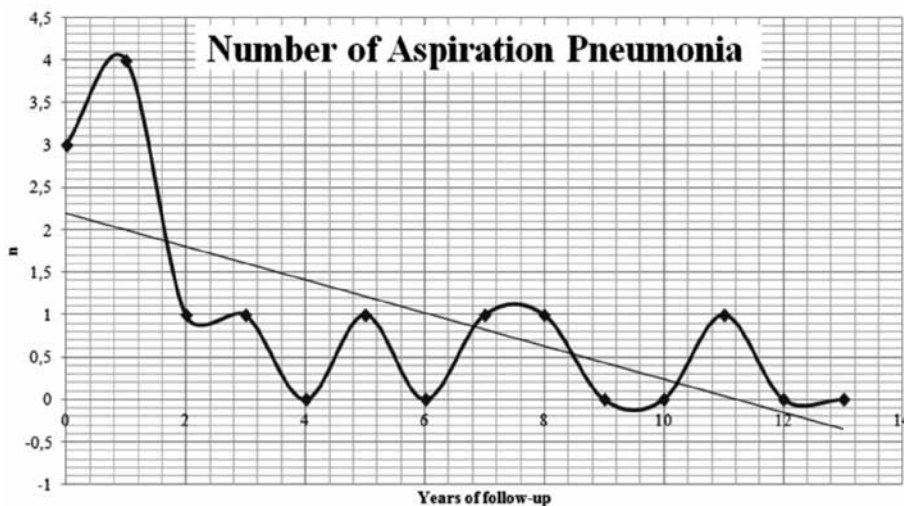
**Fig. 1.** Frequency of AP episodes during the follow-up period.

Table III. Videofluorographic study of swallowing assessed using the DOS scale and listed by type of procedure.

DOSS	No.	%	Type of procedure								
			SL	Extended SL	CHEP	CHEP + A	CHP	CHP + A	THEP	THEP + A	THP
7	34	42.5	15	-	12	4	1	2	-	-	-
6	24	30.0	1	4	3	11	1	1	1	2	-
5	13	16.3	-	2	3	1	1	1	5	-	-
4	7	8.8	1	-	1	1	1	1	1	-	1
3	2	2.5	-	-	-	-	-	-	-	1	1
Statistical analysis						p < 0.001					

Table IV. Results of dysphagia self-assessment using the MDADI questionnaire listed by type of procedure.

MDADI	No.	%	Type of procedure								
			SL	Extended SL	CHEP	CHEP + A	CHP	CHP + A	THEP	THEP + A	THP
20-40	67	83.8	17	6	15	15	3	4	6	1	-
41-60	11	13.8	-	-	3	1	1	1	1	2	2
61-80	2	2.5	-	-	1	1	-	-	-	-	-
81-100			-	-	-	-	-	-	-	-	-
Statistical analysis						p = 0.0125					

maintain very good voice restoration (GIRBAS score 0-1) in 20% of cases, only those patients who underwent SLs (16/23, 69.5%); 50% of patients (the group consisting of 4/23 SLs [17.4%], 30/45 SCPLs [66.7%] and 6/12 STPLs [50%]) showed a medium value of dysphonia (GIRBAS score 1.01-2); the worst results for dysphonia (GIRBAS score 2.01-3) were found in 30% of patients, the group consisting of 3/23 SLs (13.0%), 15/45 SCPLs (33.3%) and 6/12 STPLs (50%). Similar to what was observed for self-assessment of dysphagia, the study of phonatory function using the VHI questionnaire demonstrated that a large number of patients, representing 60% of the study cohort (69.5% of SLs, 62.2% of SCPLs and 33.3% of STPLs), perceived a low level of vocal handicap (VHI score 0-30), while 11 of 80 patients (13.8%) receiving SCPLs (8/45, 17.8%) or STPLs (3/12, 25%) complained of a high degree of speech handicap. Since there is a remarkable difference in voice handicap between HOPLs depending on the extent of glottic resection, a statistically significant association was found between the type of

intervention and grade of dysphonia, both perceived by patients (ANOVA test, $p = 0.0125$) and evaluated in an objective manner (ANOVA test, $p < 0.001$). In addition, in this case, poorer functional results were proportional to the amount of larynx resected downwards (best results for SLs followed by SCPLs and then STPLs).

To understand whether AP was associated with severity of dysphagia, the values of DOS scale and MDADI of the eight patients who developed AP during follow-up were considered (Table VI). A clear correlation was observed between pneumonia and severity of dysphagia both evaluated in an objective manner (Student's t -test, $p < 0.001$) and perceived by the patient (Student's t -test, $p < 0.001$). Patients who complained of repeated episodes of pneumonia were those who had more severe levels of dysphagia. The average DOS Scale value of patients who had at least one episode of pneumonia was 4.38 (range 3-6), whereas in those patients who had never developed an episode of pneumonia, this value was 6.19 (range 4-7). The average MDADI score in patients with at least one

Table V. Results of voice analysis by GIRBAS scale and by self-evaluation using the VHI questionnaire listed by type of procedure.

	No.	%	Type of procedure								
			SL	Extended SL	CHEP	CHEP + A	CHP	CHP + A	THEP	THEP + A	THP
GIRBAS											
0-1	16	20	15	1	-	-	-	-	-	-	-
1.01-2	40	50	1	3	12	11	4	3	4	1	1
2.01-3	24	30	1	2	7	6	-	2	3	2	1
Statistical analysis						p < 0.001					
VHI											
0-30	48	60	13	3	10	10	3	5	1	2	1
31-60	22	27.5	4	3	4	5	1	-	4	1	-
61-90	9	11.3	-	-	5	2	-	-	1	-	1
91-120	1	1.3	-	-	-	-	-	-	1	-	-
Statistical analysis						p = 0.0125					

episode of pneumonia was 56.38 (range 38-73), whereas in patients who had never complained of any episode of pneumonia, the score was 33.00 (range 20-67). These data allow us to conclude that these episodes of pneumonia are closely correlated with the degree of dysphagia.

Discussion

Over the last three decades, HOPLs have emerged as an important weapon in the surgical treatment of laryngeal cancer at intermediate/advanced stages and, especially in Europe, there are now thousands of patients who have undergone HOPLs and are aging with an operated larynx¹⁻³. Dysphagia, dysphonia and aspiration pneumonia have been recognized as major complications in patients subjected to these interventions, and can significantly affect their physical and emotional condition^{4,17}.

Starting from the observation that the phenomena referred to as presbyphagia and presbyphonia represent functional alterations that can occur even in normal elderly subjects never subjected to laryngeal surgery, we asked a series of questions.

What can be expected for a patient subjected to HOPLs and aging with an operated larynx? Will the degree of dysphagia remain stable over time or will it undergo physiological deterioration? What is the degree of AP observed in a cohort of elderly patients undergoing HOPLs compared to a cohort of elderly subjects that were never subjected to laryngeal surgery? During follow-up, is it necessary to use corrective behaviour to ensure that the patient has a good quality of life?

The quality of voice is one of the most critical aspects of HOPL, especially when the resection is extended to the glottis or downward to the subglottis¹⁸. In a functional study on 64 patients who underwent SCPL, Makeieff¹⁹ found that the intervention could have marked social and professional impact. Comparing voice analysis in patients subjected to total laryngectomy and voice prosthesis (TL-VP) vs. SCPL, Yoon Kyoung²⁰ demonstrated that the maximum phonation time was longer in the TL-VP group than in the SCPL group. Finally, Schindler²¹ conducted a cross-sectional study on 20 patients who underwent SCPL and in whom perceptual assessment revealed a very harsh voice, acoustic analysis displayed an irregular signal, and aerodynamic measurements showed an inefficient system. A remarkable difference in voice handicap was found between HOPLs in the study cohort depending on the extent of glottic resection with a statistically significant association between the type of intervention and grade of dysphonia, both perceived by the patient and evaluated in an objective manner. A poorer functional result was found

Table VI. Correlation between number of AP episodes and grade of dysphagia.

Patient	Procedure	No. of AP episodes	DOSS grade	MDADI grade
1	THP	3	3	58
2	THEP + A	2	3	55
3	Extended SL	2	5	38
4	CHEP	2	5	67
5	CHEP	1	4	58
6	CHP	1	4	43
7	CHEP	1	6	59
8	CHEP	1	5	73
Statistical analysis			p < 0.001	p < 0.001

to be proportional to the extent of the larynx resected downwards (best results for SLs, then SCPLs and finally STPLs).

There are several studies on swallowing impairment following HOPLs, especially following SCPLs, demonstrating an overall incidence of temporary aspiration varying from 32-89%, regardless of patient age at surgery²²; similarly, the rate of AP in the initial post-operative period ranges from 4.3-23%. In a large series of patients, Benito⁴ have demonstrated that age (alone) should not be considered as a major contraindication for SCPLs despite the fact that statistical analysis has demonstrated a risk of Grade II-III aspiration (Pearson's scale) only in patients > 70 years old in the case of CHP with partial or total arytenoid resection. In another study, Schindler have compared 10 patients aged > 65 years at the time of surgery with 10 younger patients, concluding that age (alone) was not a major drawback in these interventions²¹. The cases in the present study cohort are different. Patients undergoing surgery ranged between 56 and 73 years, were analyzed after a minimum follow-up period of 120 months (range 120-232 months) and were subjected to different types of open partial interventions on the larynx (nine different types) that essentially differ in the amount of resection and in the functional violation of glottic and sub-glottic sites. This is therefore a study that directly and indirectly analyzes the function of the neolarynx at a considerable period of time after surgery, when, in particular, the function of swallowing may have largely stabilized and therefore be subjected to possible physiological deterioration of function, referred to as 'presbyphagia'.

In 2011, Van der Maarel-Wierink²³ conducted a systematic literature review of risk factors for aspiration pneumonia in the elderly, and the results showed evidence of a positive relationship between AP and dysphagia.

In another literature review, Eisenstadt²⁴ found that dysphagia and the resulting aspiration may be prevalent in the older population, but symptoms are not always clinically evident. In 1995, using videofluoroscopy, Frederick²⁵ showed an increase in swallowing alterations with aging. In particular, in subjects older than 60 years, persistence of the bolus in the valleculae and pyriform fossa was observed with an increased risk of laryngeal penetration

and aspiration, asymmetry and hypertrophy of the crico-pharyngeal muscle and, in some cases, the presence of a Zenker's diverticulum.

These latter features are the same as those found in a subset of our more dysphagic patients who, statistically, were those undergoing more extended resections. In this series, at the end of the first post-operative month, normal swallowing (Pearson's Scale Grade 0) was achieved in 70.0% of patients, while at 2 months after surgery some difficulties of swallowing were encountered with Pearson's Grades I and II in 5% and 2.5% of patients. Overall, for 8 of 80 patients (10%), a temporary gastrostomy was needed and in 75% of these cases, this was removed during the first post-operative year. Only in one case was the gastrostomy maintained for a long period (4 years) due to repeated episodes of AP and severe dysphagia for liquids until the patient had been subjected to two endoscopic procedures of injective laryngoplasty using Vox-Implant that successfully resolved the dysphagia, allowing gastrostomy removal.

After a long-term follow-up period, swallowing analysis showed that, in patients aging with a larynx subjected to HOPLs, the severity of dysphagia in those aged > 70 years was definitely more pronounced than in a normal population of similar age, but certainly less than would be expected as 72.5% of patients, despite a previous intervention of HOPL, achieved and maintained a very good level of rehabilitation, identified by grades 6-7 of the DOS Scale. Since all of these patients were elderly (mean age 74.8 years) at the time of the videofluorographic study of swallowing, it is clear that, in patients who had achieved a good level of swallowing rehabilitation after surgery, dysphagia remains stable over time and, compared to a population of the same age not suffering from particular diseases, is not significantly worse.

These considerations do not apply to patients who have already suffered important swallowing disorders in the immediate post-operative period. The more severe levels of dysphagia, grade 3-4 of the DOS scale, were found in SLs at a rate of 4.3%, in SCPLs at a rate of 8.8% and in STPLs at a rate of 33.3%. AP episodes occur more frequently in the early years after surgery in the more extended procedures (one arytenoid resection, one cricoarytenoid unit resection, enlargement to the base of the tongue, supratracheal resection), but are less frequent at longer times after the operation.

The latter data referring especially to supratracheal laryngectomies require careful and cautious evaluation. In a series of 70 consecutive supratracheal laryngectomies, Rizzotto² observed acute complications in 7.1% of patients. The most frequent was AP, found in 60% of all acute complications. Late sequelae occurred in 28.6% of patients. Of these, the majority were due to laryngeal obstruction (70% of late sequelae), most of which were related to chronic oedema or mucosal flaps of the neolarynx, while in 27.1% of cases, patients suffered from intermittent or persistent

aspiration. The authors emphasized that the majority of late sequelae were treated by one or two transoral procedures using a CO₂ laser. In patients who developed late sequelae, the larynx was spared in 17 of 20 cases (85%), and total laryngectomy was proposed in only one patient for persistent aspiration even though he refused preferring to keep the gastrostomy and maintain voice. After these "extreme" function sparing procedures, it is necessary to be prepared for subsequent endoscopic surgery, laser surgery or injective laryngoplasty to correct anatomical and functional results and to achieve the best possible outcome. Fortunately, in only a few cases, persistent dysphagia and aspiration pneumonia still represent major complications in patients undergoing STPLs and significantly affect their physical and emotional condition.

The reality, therefore, is that, after a supratracheal laryngectomy with cricoarytenoid unit resection, it is difficult to achieve an optimal degree of recovery of swallowing (grade 7-6 of the DOSS in only 25% of cases), and, in most cases (> 75% of cases), the patient still manages to reach and maintain a sufficient level of rehabilitation from dysphagia over time (DOSS grade > 4), which corresponds to an acceptable autonomy of solid and liquid food oral intake. This aspect can be understood by analyzing the characteristics of supratracheal laryngectomy extending to a cricoarytenoid unit¹⁰. In this case, from the side of the resected hemy-cricoid plate, there is a clear lack of wall between the hypopharynx and larynx, represented by the posterolateral portion of the cricoid cartilage, which is only replaced by suturing the hypopharyngeal mucosa to the tracheal stump to recreate good patency of the pyriform sinus (Fig. 2). This defect may represent a route of

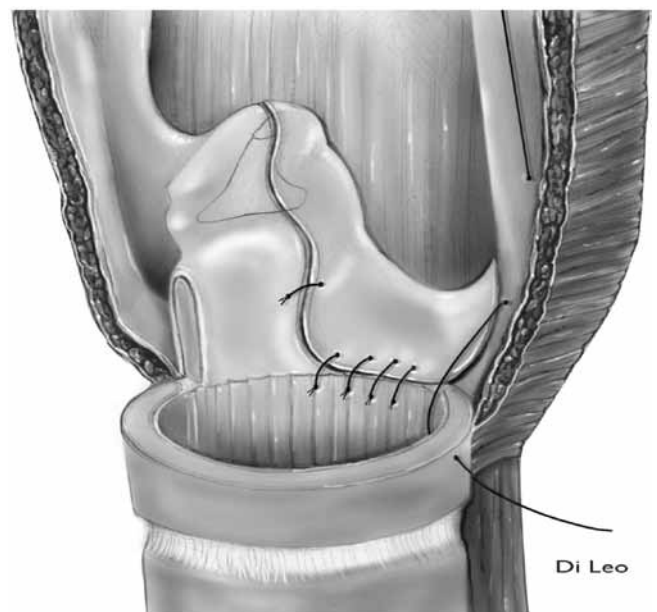


Fig. 2. Supratracheal laryngectomy, highlighting the reconstructive step with suturing of the hypopharyngeal mucosa to the tracheal stump in order to recreate a good patency of the pyriform sinus.

food entry into the larynx that can be treated by maintaining a proper laryngopharyngeal sensation, recreating a functional neoglottic valve with the contralateral cricoarytenoid unit, constructing a pexy between the trachea and hyoid bone, and enhancing physiological coordination during swallowing.

Since the dysphagia observed in patients who underwent HOPL is undoubtedly the product of anatomical and physiological alterations of the larynx, but also due to presbyphagia, what possible explanation can be given for the interesting phenomenon represented by having a degree of dysphagia less than expected (taking into account the amount of larynx resected) and in particular, that the dysphagia does not appear to deteriorate during aging? Furthermore, why did data collected from patients using self-assessment questionnaires of dysphagia report rates that were more than satisfactory in 97.5% of cases?

The explanation could be that, in addition to providing the cornerstone of functional recovery, all horizontal partial laryngectomies offer the following surgical highlights: (a) preservation of the superior laryngeal nerves, (b) good patency of the pyriform sinuses, (c) the presence of at least one functioning cricoarytenoid unit and finally, (d) the suspension of the residual larynx to the

hyoid bone. This latter condition involves the placement of the cricoid at a level higher than what is physiologically found in the healthy adult, in a position more similar to what is found in the newborn, where a facilitated swallowing act is favoured by the higher position of the larynx and large patency of the pyriform sinuses. This is what is obtained by raising the cricoid closer to the base of the tongue, in a more advantageous position for swallowing, and is equivalent to what is observed in the adult during the pharyngeal phase of swallowing. As evidence of this statement, videofluorography frames are shown during the respiratory phase in a newborn (Fig. 3A), in a normal elderly subject (Fig. 3B) and in an elderly patient who had undergone SCPL-CHEP (Fig. 3C). As can be seen, the lower edge of the cricoid both in the newborn and in the patient subjected to SCPL-CHEP is located at the level of the vertebral body of C5, and this is a consistent condition in all patients subjected to HOPL; on the other hand, in the elderly patient, the lower edge of the cricoid is located at the level of the vertebral body of C6-C7, in a less advantageous functional position. It can therefore be said that this condition, reproducing the anatomical conditions found in the newborn, tends to counteract the physiological decay of the laryngeal swallowing function, despite the fact that significant portions of the larynx have been sacrificed.

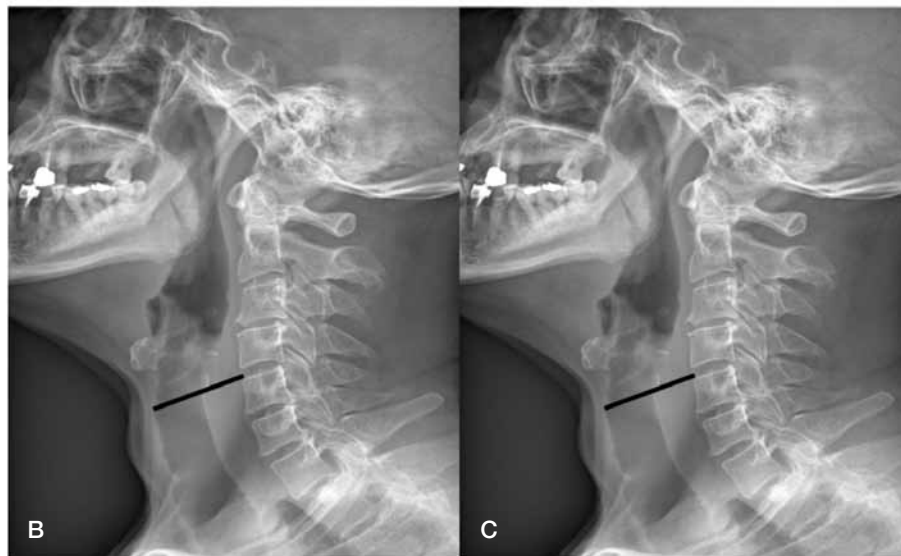
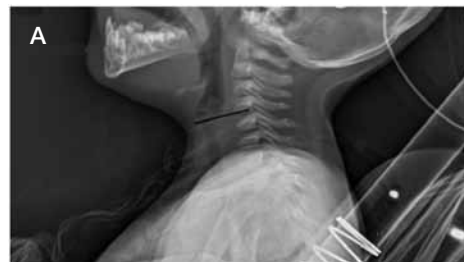
Fig. 3. Videofluoroscopy during the respiratory phase in a newborn (A), in a normal elderly subject (B), and in an elderly patient who had undergone SCPL-CHEP + A (C). The line is placed at the level of the lower edge of the cricoid plate.

In this way, it is possible to explain the low incidence of AP episodes observed during long-term follow-up and the fact that the clinical evaluation of pulmonary function of patients at last follow-up was still satisfactory (no cases of dyspnoea at repose, only four patients with a Karnofsky score less than 80, two patients with a Karnofsky score less than 70). After discharge, 13 episodes of AP were observed, which occurred in only eight of 80 patients. Overall, three episodes of AP occurred in the last 3 years and 10 in the previous 12 years, nine of which occurred in the first 3 years after surgery. In our opinion, this is related to the adoption by physicians and patients of measures to reduce the risk of aspiration (placement of temporary gastrostomy for patients suffering from severe dysphagia, prolonged and repeated chest therapy and swallowing rehabilitation, elimination of at-

risk foods in two patients with more than one episode of pneumonia during follow-up) and the possibility to carry out corrective endoscopic procedures (e.g. injective laryngoplasty in two patients with more than one episode of pneumonia during follow-up).

It is thus established on the basis of indirect findings on the AP episodes that the incidence of these phenomena increases slightly with age, but this is not statistically significant, while a statistically significant correlation was confirmed between the extent of resection and the risk of AP, as already observed by Benito⁴.

In conclusion, the results of laryngeal functionality in a sample of elderly patients (age > 70 years subjected to HOPLs and examined at least 10 years after surgery) are undoubtedly stable and repeatable both for SLs and SC-PLs, as already reported by many authors. For STPLs, this is the first study in terms of functional outcome and, although the function of the remaining larynx is poorer, both objective and subjective outcomes have demonstrated the quite satisfactory validity of STPLs in sparing laryngeal function, albeit at the obvious expense of a 'simplified' laryngeal framework. This shows the immense ability of this organ to recover the essentials of its function after partial surgical mutilation, provided that tissue has been sacrificed and the organ reconstructed according to 'functional criteria'.

The results of this study reveal that, despite the disruption of the normal anatomy of the larynx, in patients who underwent HOPLs (and aged with an operated larynx), laryngeal functions, in particular swallowing, are impaired but this did not significantly affect the quality of life, especially when compared to the laryngeal functions of elderly subjects who did not receive any procedures on the larynx.

Aspiration pneumonia, the most dangerous complication of HOPL, seems to be more frequent in the initial post-operative period and less so in subsequent years, thanks to the maintenance of temporary gastrostomy, prolonged chest therapy and rehabilitation of swallowing. Finally, injective laryngoplasty techniques can now offer effective solutions in the more dysphagic patients²⁶.

References

- 1 Laccourreya O, Brasnu D, Biacabe B, et al. *Neo-adjuvant chemotherapy and supracricoid partial laryngectomy with cricothyroidopexy for advance endolaryngeal carcinoma classified as T3-T4: 5-year oncologic results*. *Head Neck* 1998;20:595-9.
- 2 Rizzotto G, Crosetti E, Lucioni M, et al. *Subtotal laryngectomy: outcomes of 469 patients and proposal of a comprehensive and simplified classification of surgical procedures*. *Eur Arch Otorhinolaryngol* 2012;269:1635-46.
- 3 De Vincentiis M, Minni A, Gallo A, et al. *Supracricoid partial laryngectomies: oncologic and functional results*. *Head Neck* 1998;20:504-9.
- 4 Benito J, Holsinger FC, Pérez-Martín A, et al. *Aspiration after supracricoid partial laryngectomy: Incidence, risk factors, management, and outcomes*. *Head Neck* 2011;33:679-85.
- 5 Piquet JJ, Desaulty A, Decroix G. *La Crico-hyoido-épiglotto-pexie. Technique opératoire et résultats fonctionnels*. *Ann Otolaryngol Chir Cervicofac* 1974;91:681-90.
- 6 Labayle S, Bismuth R. *La laryngectomie totale avec reconstruction*. *Ann Otolaryngol Chir Cervicofac* 1971;88:219-28.
- 7 Serafini I. *Reconstructive laryngectomy*. *Rev Laryngol Otol Rhinol* 1972;93:23-32.
- 8 Union International Contre le Cancer. *TNM classification of malignant tumors*. 6th ed. New York: Wiley-Liss; 2002.
- 9 Karnofsky DA, Burchenal JH. *The clinical evaluation of chemotherapeutic agents in cancer*. In: MacLeod CM, editor. *Evaluation of chemotherapeutic agents*. New York: Columbia University Press; 1949. p. 199-205.
- 10 Rizzotto G, Succo G, Lucioni M, et al. *Subtotal laryngectomy with tracheohyoidopexy: a possible alternative to total laryngectomy*. *Laryngoscope* 2006;116:1907-17.
- 11 Robbins KT, Clayman G, Levine PA. *Neck dissection classification update: revisions proposed by the American Head and Neck Society and the American Academy of Otolaryngology-Head and Neck Surgery*. *Arch Otolaryngol Head Neck Surg* 2002;128:751-8.
- 12 Pearson BW. *Subtotal laryngectomy*. *Laryngoscope* 1981;91:1904-12.
- 13 Benninger MS, Ahuja AS, Gardner G, et al. *Assessing outcomes for dysphonic patients*. *J Voice* 1998;12:540-50.
- 14 Hirano M. *Clinical examination on voice*. New York: Springer-Verlag; 1981.
- 15 Chen AY, Frankowski R, Bishop-Leone J, et al. *The development and validation of a dysphagia-specific quality-of-life questionnaire for patients with head and neck cancer: the M.D. Anderson dysphagia inventory*. *Arch Otolaryngol Head Neck Surg* 2001;127:870-6.
- 16 O'Neil KH, Purdy M, Falk JJ, Gallo L. *The dysphagia outcome and severity scale*. *Dysphagia* 1999;14:139-45.
- 17 Simonelli M, Ruoppolo G, de Vincentiis M. *Swallowing ability and chronic aspiration after supracricoid partial laryngectomy*. *Otolaryngol Head Neck Surg* 2010;142:873-8.
- 18 Kandogan T, Sanal A. *Voice Handicap Index (VHI) in partial laryngectomy patients*. *KBB Forum* 2005;4:15-17.
- 19 Makeieff M, de la Breteque A, Guerrier B, et al. *Voice handicap evaluation after supracricoid partial laryngectomy*. *Laryngoscope* 2009;119:746-50.
- 20 So YK, Yun Y-S, Baek C-H, et al. *Speech outcome of supracricoid partial laryngectomy: comparison with total laryngectomy and anatomic considerations*. *Otolaryngol Head Neck Surg* 2009;141:770-5.
- 21 Schindler A, Favero E, Capaccio P, et al. *Supracricoid laryngectomy: age influence on long-term functional results*. *Laryngoscope* 2009;119:1218-25.
- 22 Lewin JS, Hutcheson KA, Barringer DA. *Functional analysis of swallowing outcomes after supracricoid partial laryngectomy*. *Head Neck* 2008;30:559-66.
- 23 Van der Maarel-Wierink CD, Vanobbergen JNO, Bronkhorst

- EM, et al. *Risk factors for aspiration pneumonia in frail older people: a systematic literature review*. J Am Med Dir Assoc 2011;12:344-54.
- ²⁴ Eisenstadt ES. *Dysphagia and aspiration pneumonia in older adults*. J Am Acad Nurse Pract 2010;22:17-22.
- ²⁵ Frederick MG, Ott DJ, Grishaw K, et al. *Functional abnormalities of the pharynx: a prospective analysis of radiographic abnormalities relative to age and symptoms*. Am J Roentgenol 1996;166:353-7.
- ²⁶ Alicandri-Ciufelli M, Piccinini A, Grammatica A. *Voice and swallowing after partial laryngectomy: Factors influencing outcome*. Head Neck 2013;35:214-9.

Received: April 20, 2013 - Accepted: June 27, 2013

RHINOLOGY

External vs. endonasal dacryocystorhinostomy: has the current view changed?

Dacriocistorinostomia esterna ed endonasale a confronto: si è modificata l'opinione comune?

G. SAVINO¹, R. BATTENDIERI¹, S. TRAINA¹, G. CORBO¹, G. D'AMICO¹, M. GARI¹, E. SCARANO², G. PALUDETTI²

¹ Istituto di Oftalmologia, ² Istituto di Otorinolaringoiatria, Università Cattolica del Sacro Cuore, Rome, Italy

SUMMARY

In past years, external dacryocystorhinostomy has been considered the gold standard in terms of functional outcome for treatment for nasolacrimal duct obstruction. In comparison, interest in the use of the recently developed endonasal dacryocystorhinostomy procedure has been rekindled because of advances in instrumentation. For the past 10 years, differences in the outcomes between the two techniques have been reduced; thus, currently, the choice of the type of surgery is associated with the experience of the surgeon, resources available in the healthcare system and patient preferences.

KEY WORDS: Epiphora • Nasolacrimal duct obstruction • Dacryocystorhinostomy • Endonasal endoscopy

RIASSUNTO

In passato la dacriocistorinostomia per via esterna (EXT-DCR) è stata considerata il gold standard in termini di risultato funzionale nel trattamento delle ostruzioni del dotto naso lacrimale. L'innovazione della strumentazione ha recentemente incrementato l'interesse per la dacriocistorinostomia endoscopica per via endonasale (EES-DCR). Negli ultimi 10 anni le differenze in termini di risultati tra le due tecniche chirurgiche sono andate riducendosi; la scelta del tipo di tecnica chirurgica è attualmente legata all'esperienza del chirurgo, alle risorse economiche del sistema sanitario e alle preferenze del paziente.

PAROLE CHIAVE: Epifora • Ostruzione del dotto naso-lacrimale • Dacriocistorinostomia • Endoscopia endonasale

Acta Otorhinolaryngol Ital 2014;34:29-35

Introduction

Nasolacrimal duct obstruction (NLDO) inhibits the flow of tears from the eye to the nose, leading to symptoms of epiphora. The clinical spectrum of epiphora ranges from the occasionally trickle to chronically irritating overflow of tears. Epiphora results from a disruption in the balance between tear production and drainage¹. NLDO is a disorder in which the symptomatology and objective findings do not often consistently correlate. Chronic dacryocystitis is the permanent obstruction of the nasolacrimal duct.

The usual causes of stenosis of the nasolacrimal drainage system include chronic or acute inflammation, traumatism and congenital malformations²⁻⁴. Tears from the conjunctival sac pass through the lacrimal puncta in the upper and lower lids to the upper and lower lacrimal canaliculi and then to the common canaliculi to empty into the lacrimal sac located in the lacrimal fossa. From the lacrimal sac, tears pass to the nasolacrimal duct along the lateral wall of the nose into the inferior meatus.

Secondary acquired lacrimal drainage obstruction can result from a wide variety of infectious, inflammatory, neoplastic, traumatic or mechanical causes. Bacteria, viruses, fungi and parasites have all been implicated in infectious lacrimal drainage obstruction. Inflammation can also occur through endogenous sources, such as Wegener's granulomatosis, sarcoidosis and sclerodermia or exogenous sources, such as radiation, systemic chemotherapy and bone marrow transplantation. The observed neoplasms include primary growth, secondary spread or metastatic spread. Trauma can be iatrogenic or accidental. Mechanical lacrimal drainage obstruction can result from the presence of intraluminal foreign bodies, such as dacryoliths or casts. Females are affected more than males. The higher incidence of females undergoing DCR has been attributed to social and anatomical factors, as anatomical studies of the nasolacrimal system, using radiological techniques, have shown that its dimensions are smaller in females than in males¹. NLDO is typically treated using external dacryocystorhinostomy (EX-DCR), in which the lacrimal

sac is directly connected to the nose through the removal of the layers of bone and mucosa that separate these two structures.

The development of fine nasal surgical instrumentation has rekindled an interest in the endoscopic endonasal approach (EES-DCR). A review of the literature concerning the outcomes and complications of these surgical techniques is discussed and compared.

Patient clinical evaluation

Patients with a history of tearing, dacryocystitis, or both should be treated through a standard clinical workup that includes the documentation of the tearstrip level, examination of the eyelids for punctual malpositioning, horizontal laxity or orbicularis weakness, compression over the lacrimal sac to observe mucoid or purulent reflux and irrigation through the canaliculi to document the patency of the lacrimal outflow tracts. Dacryocystography can be performed, and the examination of the nasal cavity is recommended^{5,6}. Obstructions observed with on syringing and probing or lacrimal scintigraphy are used for diagnosis of NLDO⁷. Lacrimal scintigraphy is a “physiological” test^{7,8} that is likely to yield abnormal results in patients with FN-LDO (“functional” nasolacrimal duct obstruction).

Treatment

Dacryocystorhinostomy (DCR) involves the creation of an alternative route for the drainage of tears between the lacrimal sac and nasal cavity, bypassing the nasolacrimal duct. This alternative route is generated using an external approach (external DCR) or through the nasal cavity using an endoscope (EES-DCR). Research suggests the use of general anaesthesia⁵ and, more recently, the use of local anaesthesia has also been proposed⁸ for both techniques.

External dacryocystorhinostomy

Addeo Toti first described external DCR in 1904, and with the exception of minor changes, DCR is currently performed in much the same way. Toti suggested that gaining access to the sac using an external approach, where the area of the sac adjacent to the canaliculi is preserved and absorbed into an area of the nasal cavity where the nasal mucosa has been removed¹⁰. Mucosal anastomosis, with suturing of the mucosal flaps, was later described¹⁰.

A 1.2-cm vertical skin incision is typically made at 1 cm from the medial canthus to reduce the risk of scars and avoid the angular vessels (Fig. 1). A nasal tamponade is applied to induce vasoconstriction using a gauge soaked in adrenaline, diluted (1:100,000) or (1:200,000), for 10 min. The periosteum at the anterior lacrimal crest is incised using a Traquair’s periosteal elevator and subsequently the lacrimal fossa is entered. The lacrimal and maxillary bones are removed using Kerrison rongeurs to create a large rhinostomy (Fig. 2)⁹. The lacrimal sac and nasal mucosa are opened longitudinally, the sac contents are examined, and a silicone stent is routinely inserted and tied loosely to prevent cheese wiring of the canaliculi. Patency of the internal punctum is confirmed. Some surgeons remove the nasal mucosa entirely to the margins of the osteotomy window using monopolar needle-tip cautery and the edge of the lacrimal sac anterior flap is sutured to the periosteum of the lip at the osteotomy site⁵. Other surgeons¹² open the nasal mucosa longitudinally and suture the posterior and anterior mucosal flaps to the flaps of the lacrimal sac. Still other surgeons create an anastomosis between the anterior flaps and remove the posterior flaps (Fig. 3)⁹. In a recent study, Turkcu showed that there was no statistically significant difference between DCR using both anterior and posterior flap anastomosis and DCR using only anterior flap anastomosis¹³. Subsequently, a running 6-0 polypropylene skin suture is

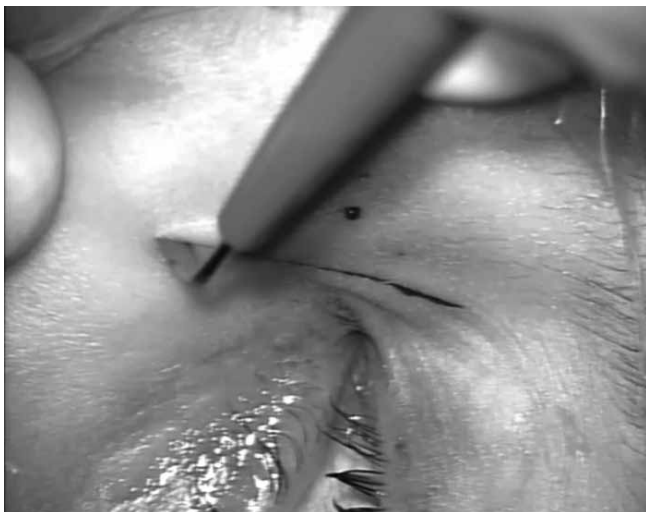

Fig. 1. Vertical skin incision at medial canthus.

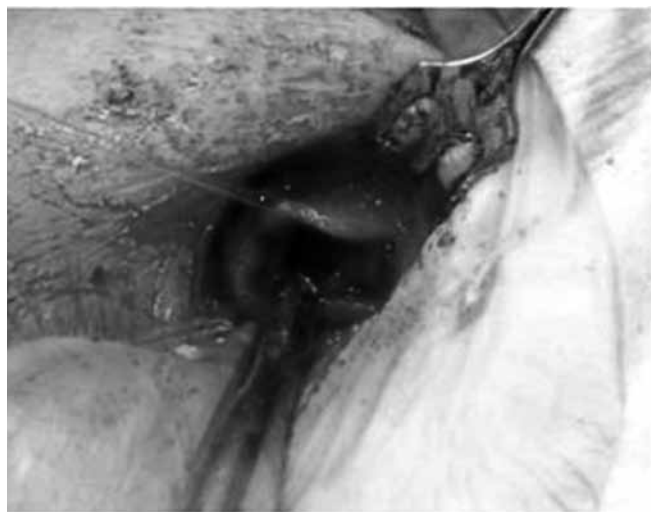

Fig. 2. Rhinostomy.



Fig. 3. Anastomosis between the anterior flaps.

applied. A large bony resection of 15-20 mm in external DCR is required to ensure a large anastomosis and high success rate¹⁴.

Lindberg studied a series of 22 external DCR and found no statistically significant correlation between the size of the bony opening and the final outcome of the resection¹⁵.

Regarding silicone tube removal, Karim left the tubes in situ for 1-2 months⁷, while Cheung proposed that intubation with silicone tubes should remain for only 3-4 weeks¹⁻⁷.

The role of antimetabolites for the maintenance of patency in external DCR is currently being studied. Intraoperative mitomycin C (MMC) application is a safe adjuvant for reduction of the closure rate of the osteotomy site after primary EX-DCR¹⁶.

Shine reported a significantly higher success rate in the MMC group compared with the control group¹⁷. In two randomized, controlled clinical trials (RCTs), the mean osteotomy size at 6 months postoperatively was significantly larger in the MMC group than in the control group (approximately 27 mm in the MMC group vs. and 12 mm in the control group in the first study, and approximately 22 mm in the MMC group and 18 mm in the control group in the second study; $p < 0.005$). No intraoperative or postoperative complications were recorded in the MMC group, except for two cases with delayed healing of the external skin wound (Table II)¹⁶.

Endoscopic endonasal dacryocystorhinostomy

Caldwell first described the endonasal approach in 1893¹⁸; however, the use of this method lost popularity because of the difficulty in accessing the narrow nasal cavity using the instrumentation available. The endoscopic procedure has become more popular in last decade due to the advancement of the nasal endoscope and familiarity of endonasal treatment for surgeons with experience in the endoscopic anatomy of the nasal cavity¹⁹.

EES-DCR facilitates the accurate identification of the intranasal causes of DCR failures, such as adhesions, an enlarged middle turbinate, or an infected ethmoid sinus. EES-DCR plays a definitive role in failed external DCR and revision cases²⁰. Most studies have reported good results and excellent patient acceptability¹².

Many surgeons prefer to operate under general anesthesia^{7 21 22}. However, the procedure can also be performed under sedation and local anaesthesia^{12 19}. To induce local vasoconstriction, a nasal tamponade in a mixture

Table I. Studies reporting results of external and endoscopic endonasal dacryocystorhinostomy.

Study	Year	Endonasal success	External success	Prospective/Retrospective	Comparative
Dolman ⁵	2003	89.1%	90.2%	Retrospective	Yes
Zaidi ⁹	2011	86%	100%	Prospective	Yes
Karim ⁷	2011	93.2%	91%	Retrospective	Yes
David ²³	2000	100%	93.8%	Prospective	Yes
Saroy ¹²	2010	90%	95%	Prospective	Yes
Harugop ²⁴	2008	93.3%		Prospective	No
Sinha ¹⁹	2008	96%		Retrospective	No
Gupta ⁴⁰	2011	97%		Retrospective	No
Deviprasad ⁸	2009	92%		Retrospective and prospective	No
Mikito ⁴¹	2011		90.5%	Prospective	No
Preechawai ⁴²	2012	74.7%		Retrospective	No
Leong ⁴³	2010	86%	94%	Review	Yes
Sharma ⁴⁴	2008	88.5%	90.5%	Retrospective	Yes
Ben Simon ⁴⁵	2005	84%	70%	Retrospective	Yes
Cokkeser ⁴⁶	2000	88.2%	89.8%	Prospective	Yes
Agarwal ⁴⁷	2009	94%		Retrospective	No
Sonkhya ⁴⁸	2009	92%		Prospective	No

Table II. Studies reporting results of intraoperative use of mitomycin C in dacryocystorhinostomy.

Study	Year	EXT/EES	% Success MMC group	% Success control group	Randomized	Retrospective/prospective	Comparative
Prasannaraj ³⁵	2010	EES	82.30%	85.70%	Yes	Prospective	Yes
Camara ³⁹	2000	EES	99.20%	89.60%	No	Retrospective	Yes
Gorgulu ⁴⁹	2012	EES	90%		No	Prospective	No
Penttila ³⁸	2011	EES	93%	60%	Yes	Prospective	Yes
Shine ¹⁷	1997	EXT	100%	87.50%	No	Prospective	Yes
Yldirim ⁵⁰	2007	EXT	95%	60%	Yes	Prospective	Yes

of lidocaine and adrenaline at various concentrations (1:200,000, 1:100,000, 1:30,000, 1:10,000) is used^{8 12 23}. The anaesthetic is administered before the starting procedure in accordance with the surgeon performing the procedure^{12 21 23 24}. A 20-gauge vitrectomy light probe was introduced through the upper canaliculus until reaching the bony medial wall of the lacrimal sac and subsequently turned downward. A right-handed surgeon takes position on the right side of the patient for both right- and left-sided EES-DCR and directly views the transilluminated target area through a nasal speculum with 7.5-cm long blades and a fibre optic light carrier (Fig. 4)²¹.

Ordinarily, a 0° nasal endoscope is used²³; however, in cases of nasal septum deviation towards the obstructed side, a 30° nasal endoscope is preferred to enhance visualization of the lacrimal sac area, and the endoscope is negotiated gently beyond the point of maximum deviation¹⁹. A Freer periosteum elevator is used to incise the nasal mucosa using the light probe in the lacrimal sac as a guide. The incision was made vertically or in a curvilinear fashion down to the bone²¹.

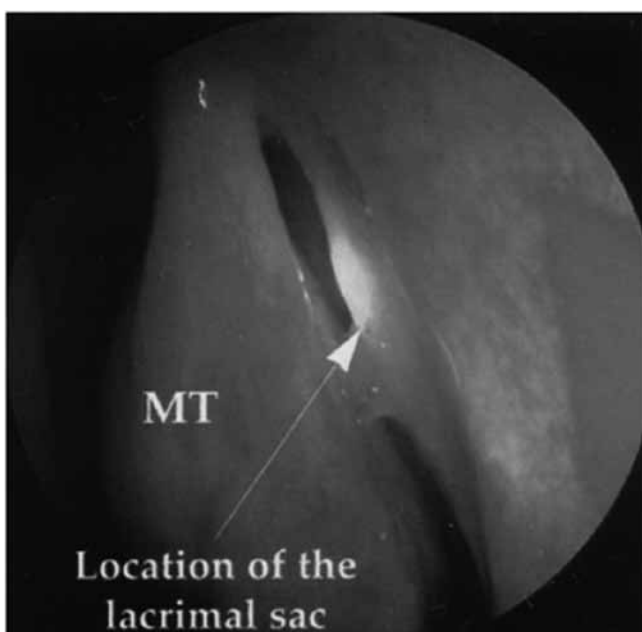


Fig. 4. A light probe introduced through the upper canaliculus. (MT: middle turbinate).

The incision line should extend above the anterior end of the middle turbinate, as the sac typically extends above the middle turbinate (Fig. 5). Restricting the incision to the anterior end of the middle turbinate can result in the incomplete exposure of the sac and compromise long-term results¹².

A variety of lasers with different wavelengths have recently been used to incise the mucosa, including high-powered blue argon, potassium titanyl phosphate and carbon dioxide. These lasers require safety precautions and generate char around the ostium site, requiring frequent lavage and debridement during the postoperative period²⁵⁻²⁹.

Currently, most surgeons remove 1 to 1.5 cm of the nasal mucosa using Blakesley or Takahashi forceps²¹. Hajek's bone punch can also be used to remove the lacrimal bone. The thick region of the frontal process of the maxilla is drilled using a 3-mm burr to expose the entire medial wall of the lacrimal sac⁸. The tented medial wall of the sac is then removed. Once the sac wall is removed the lumen of the sac can be inspected.

When preserving the nasal submucosal injection in the presumed lacrimal fossa during opening of the sac, marsupialization can occur in the opposing nasal mucosa⁷.

As in an open technique, a posterior based mucoperiosteal flap is created and positioned at the end of the procedure

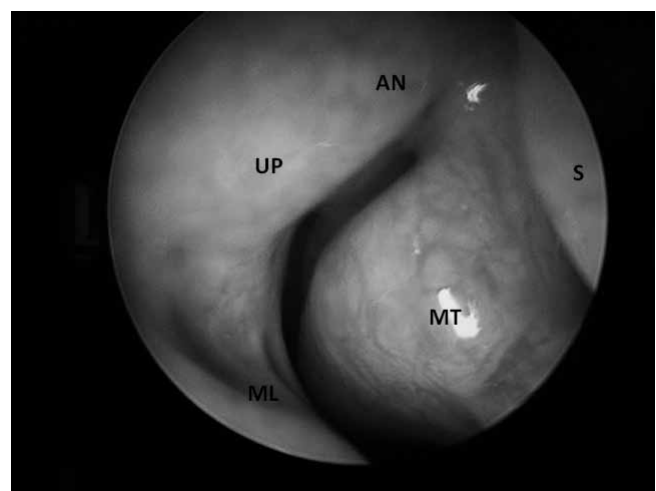


Fig. 5. The incision line above the anterior end of the middle turbinate. (AN: aggrer nasi, MT: middle turbinate, S: septum, PU: uncinat process, LM: maxillary line).

to keep the two mucosal layers in contact and ensure patency³⁰. Some surgeons do not prefer to advocate creation of mucosal flaps at the bony window area to reduce the risk of postoperative fibrosis and obstruction³¹. Furthermore, the creation of mucosal and nasal flaps should not increase the success rate of EES-DCR³².

Bicanalicular silicone tubes are introduced into both canaliculi and retrieved from the nasal cavity using a haemostat^{21,33}. Nonetheless, some studies have reported good results without the need of nasolacrimal stenting³⁴.

There are few controlled trials in which MMC has been used as an adjunct to EES-DCR. MMC is generally applied using a cotton ball soaked in 0.2 mg/ml of solution and placed over the raw edges of the stoma for 10 min. The use of mitomycin does not influence the occurrence of granulations, synechiae, or obliterative sclerosis, and the success rate is not significantly altered³⁵⁻³⁷.

However, other studies have suggested significant advantages in using MMC³⁸. Camara conducted a study using 171 patients, of which 123 received adjuvant topical MMC intraoperatively in laser-assisted EES-DCR. These patients were observed for an average period of 51 months. The success rate was 99.2% when MMC was used and 89.6% when MMC was not used (Table II)³⁹.

Surgical outcomes

We compared various studies published in the last 15 years (1997-2012), and with respect to the definition of surgical success, we observed differences among the articles reviewed (Table I). There were no randomized studies in the literature.

The major outcomes used to define surgical success included subjective success based on the patient's symptoms and objective success based on assessment of the patency through syringing. In a retrospective study, Dolman reported⁵ complete success in 90.2% of patients using EXT-DCR and in 89.1% patients using EES-DCR.

Complete success was considered when the tearing under normal conditions had been resolved, with no recurring infection and minimal or no reflex through the opposite canaliculus after lacrimal irrigation⁵. To our knowledge, Dolman's report is the largest combined EES-DCR and EX-DCR analysis, which included a sufficient number of subjects to demonstrate equivalent surgical outcomes between the two techniques.

In prospective studies, Zaidi⁹ showed a 100% success rate for EXT-DCR and an 86% success rate for EES-DCR. Success was based on the degree of epiphora after 6 months and assessment of patency through syringing.

Others prospective studies¹² suggest comparable results for both procedures. Harugop²⁴ recorded a success rate of 93.3% in EES-DCR without intubation and 96% in EES-DCR with intubation, evaluating the degree of epiphora and the size of the rhinostomy.

Discussion and conclusions

External DCR remains the gold standard in terms of functional outcome in the treatment of nasolacrimal duct obstruction. In comparison, interest in the recently developed EES-DCR technique has been rekindled because of advances in instrumentation, notably the introduction of the rigid nasoendoscope, FESS and laser surgery. The advantages of external DCR include high predictability and the direct visualization of anatomy, which is highly relevant for sac tumours. This technique facilitates accurate anastomosis between the lacrimal sac and nasal mucosa. However, external DCR has some disadvantages, including facial scarring, lacrimal pump dysfunction resulting from the interruption of medial canthal anatomy and the orbicularis oculi muscles, and limitations in acute dacryocystitis patients with abscess formation.

An endoscopic approach reduces the risk of interfering with the medial canthal tendon and lacrimal pump physiology. This approach also reduces scarring, which is cosmetically important for certain patient groups, particularly young individuals. EES-DCR also has a shorter postoperative recovery time and reduced rates of postoperative complications, such as haemorrhage and cerebrospinal fluid rhinorrhoea. Serious complications, including orbital and subcutaneous emphysema, retrobulbar haemorrhage, medial rectus paresis and orbital fat herniation, are rarely observed in either form of DCR surgery.

An endoscopic approach facilitates diagnosis and management of the associated conditions, including septal deviation, sinus disease and turbinate hypertrophy.

Endoscopic endonasal DCR plays an established role in the revision DCR surgery. In the case of cicatricial obstruction at the osteotomy site, it is easier to perform endoscopic revision, and the patient is more likely to accept such a revision without visible external cuts.

Compared with external DCR, endoscopic DCR is more expensive, with high equipment costs. Endoscopic DCR is also technically more difficult to learn, and the learning curve for the endoscopic procedure has been reported in several studies.

However, it is difficult to compare the success rate for primary surgery between external DCR and endoscopic endonasal procedures, as there are few comparative studies. Few studies have standard outcome measures, with some defining success as patency to irrigation, whereas others have focused on symptom resolution. The results of EES-DCR are not as good as those with EX-DCR, presumably reflecting the fact that most surgeons traditionally create a smaller rhinostomy when performing an EES-DCR, although the use of this technique varies.

In the last 10 years, the differences in outcomes between the two techniques have been reduced because of advances in technology, and we affirm that the choice of the type of surgery is currently based on the experience of the surgeon, available resources and the patient preferences.

References

- 1 Cheung LM, Francis IC, Stapleton F. *Symptom assessment in patients with functional and primary acquired nasolacrimal duct obstruction before and after successful dacryocystorhinostomy surgery: a prospective study*. Br Ophthalmol 2007;91:1671-4.
- 2 Duggal P, Chakravorty S, Azad RK, et al. *An epidemiological study on patients undergoing dacryocystorhinostomy*. Indian J Otolaryngol Head Neck Surg 2006;58:349-51.
- 3 Berlucchi M, Tomenzoli D, Trimarchi M, et al. *Dacryocystocele in the adult: etiology, diagnosis and treatment*. Acta Otorhinolaryngol Ital 2001;21:100-4.
- 4 Piane R, Romano L, Nuti D, et al. *Endonasal dacryocystorhinostomy: a personal experience*. Acta Otorhinolaryngol Ital 1999;19:255-9.
- 5 Dolman PJ. *Comparison of external dacryocystorhinostomy with nonlaser endonasal dacryocystorhinostomy*. Ophthalmology 2003;110:78-84.
- 6 Presutti L. *Endonasal dacryocystorhinostomy*. Acta Otorhinolaryngol Ital 1995;15:449-53.
- 7 Karim R, Ghabrial R, Lynch TF, et al. *A comparison of external and endoscopic endonasal dacryocystorhinostomy for acquired nasolacrimal duct obstruction*. Clin Ophthalmol 2011;5:979-89.
- 8 Deviprasad D, Mahesh SG, Pujary K, et al. *Jain. Endonasal endoscopic dacryocystorhinostomy: our experience*. Indian J Otolaryngol Head Neck Surg 2009;61:223-6.
- 9 Zaidi FH, Symanski S, Olvera JM. *Clinical trial of endoscopic vs external dacryocystorhinostomy for partial nasolacrimal duct obstruction*. Eye 2011;25:1219-24.
- 10 Toti A. *Nuovo metodo conservatore di cura radicale delle suporazioni croniche del sacco lacrimale*. Clin Mod Firenze 1904;10:385-9.
- 11 Dupuy-Dutemps L, Bourguet J. *Procede plastique de dacryocystorhinostomie et ses resultats*. Ann Ocul 1921;158:241-61.
- 12 Saroj G, Rashmi G. *Conventional dacryocystorhinostomy versus endonasal dacryocystorhinostomy a comparative study*. Indian J Otolaryngol Head Neck Surg 2010;62:296-8.
- 13 Turkcu FM, Oner V, Tas M, et al. *Anastomosis of both posterior and anterior flaps or only anterior flaps in external dacryocystorhinostomy*. Orbit 2012;31:383-5.
- 14 Shun-Shin GA, Thurairajan G. *External dacryocystorhinostomy – an end of an era?* Br J Ophthalmol 1997;81:716-7.
- 15 Lindberg JV, Anderson RL, Bumsted RM, et al. *Study of intranasal ostium external dacryocystorhinostomy*. Arch Ophthalmol 1982;100:1758-62.
- 16 Feng YF, Yu JG, Shi JL, et al. *A meta-analysis of primary external dacryocystorhinostomy with and without mitomycin C*. Ophthalmic Epidemiol 2012;19:364-70.
- 17 Kao SC, Liao CL, Tseng JH, et al. *DCR with intraoperative mitomycin*. Ophthalmology 1997;104:86-91.
- 18 Caldwell GW. *Two new operations for obstruction of the nasal duct, with preservation of the canaliculi and an incidental description of a new lacrimal probe*. NY Med J 1893;57:581-2.
- 19 Sinha V, Gupta D, Prajapati B, et al. *Endoscopic dacryocystorhinostomy with conventional instruments: results and advantages over external dacryocystorhinostomy*. Indian J Otolaryngol Head Neck Surg 2008;60:207-9.
- 20 Puxeddu R, Nicolai P, Bielamowicz S, et al. *Endoscopic revision of failed external dacryocystorhinostomy*. Acta Otorhinolaryngol Ital 2000;20:1-5.
- 21 Razavi ME, Noorollahian M, Eslampoori A. *Non endoscopic mechanical endonasal dacryocystorhinostomy*. J Ophthalmic Vis Res 2011;6:219-24.
- 22 Muscatello L, Giudice M, Spriano G, et al. *Endoscopic dacryocystorhinostomy: personal experience*. Acta Otorhinolaryngol Ital 2005;25:209-13.
- 23 David S, Raju R, Job A, et al. *A Comparative study of external and endoscopic endonasal dacryocystorhinostomy- A Preliminary report*. Indian J of Otolaryngol Head Neck Surg 1999;52:37-9.
- 24 Harugop S, Mudhol RS, Rekha BK, et al. *Endonasal dacryocystorhinostomy: a prospective study*. Indian J Otolaryngol Head Neck Surg 2008;60:335-40.
- 25 Massaro BM, Gonnering RS, Harris GJ. *Endonasal laser dacryocystorhinostomy. A new approach to nasolacrimal duct obstruction*. Arch Ophthalmol 1990;108:1172-6.
- 26 Hartikainen J, Grenman R, Puukka P, et al. *Prospective randomized comparison of external dacryocystorhinostomy and endonasal laser dacryocystorhinostomy*. Ophthalmology 1998;105:1106-13.
- 27 Gonnering RS, Lyon DB, Fisher JC. *Endoscopic laser-assisted lacrimal surgery*. Am J Ophthalmol 1991;111:152-7.
- 28 Woog JJ, Metson R, Puliafito CA. *Holmium: YAG endonasal laser dacryocystorhinostomy*. Am J Ophthalmol 1993;116:1-10.
- 29 Seppa H, Grenman R, Hartikainen J. *Endonasal CO₂-Nd: YAG laser dacryocystorhinostomy*. Acta Ophthalmol 1994;72:703-6.
- 30 Emanuelli E, Pagella F, Danè G, et al. *Posterior lacrimal sac approach technique without stenting in endoscopic dacryocystorhinostomy*. Acta Otorhinolaryngol Ital 2013;33:324-8.
- 31 Saratziotis A, Emanuelli E, Gouveris H, et al. *Endoscopic dacryocystorhinostomy for acquired nasolacrimal duct obstruction: creating a window with a drill without use of mucosal flaps*. Acta Otolaryngol 2009;129: 992-5.
- 32 Masegur H, Trias E, Adema JM. *Endoscopic dacryocystorhinostomy: modified technique*. Otolaryngol Head Neck Surg 2004;130:39-46.
- 33 Nuhoglu F, Gurbuz B, Eltutar K. *Long-term outcomes after transcanalicular laser dacryocystorhinostomy*. Acta Otorhinolaryngol Ital 2012;32:258-62.
- 34 Pittore B, Tan N, Salis G, et al. *Endoscopic transnasal dacryocystorhinostomy without stenting: results in 64 consecutive procedures*. Acta Otorhinolaryngol Ital 2010;30:294-8.
- 35 Prasannaraj T, Praveen Kumar BY, Narasimhan I, et al. *Significance of adjunctive mitomycin C in endoscopic dacryocystorhinostomy*. Am J Otolaryngol 2012;33:47-50.
- 36 Zilelioglu G, Ugurbas SH, Anadolu Y, et al. *Adjunctive use of mitomycin C on endoscopic lacrimal surgery*. Br J Ophthalmol 1998;82:63-6.
- 37 Ragab SM, Elsherif HS, Shehata EM, et al. *Mitomycin C-enhanced revision endoscopic dacryocystorhinostomy: a prospective randomized controlled trial*. Otolaryngol Head Neck Surg 2012;147:937-42.

- ³⁸ Penttilä E, Smirnov G, Seppä J, et al. *Mitomycin C in revision endoscopic dacryocystorhinostomy: a prospective randomized study*. Am J Rhinol Allergy 2011;25:425-8.
- ³⁹ Camara JG, Bengzon AU, Henson RD. *The safety and efficacy of mitomycin C in endonasal endoscopic laser assisted dacryocystorhinostomy*. Ophthal Plast Reconstr Surg 2000;16:114-8.
- ⁴⁰ Gupta N. *Improving Results in Endoscopic DCR*. Indian J Otolaryngol Head Neck Surg 2011;63:40-4.
- ⁴¹ Mitiko P, Akaishi S, Borges Mano J, et al. *Functional and cosmetic results of a lower eyelid crease approach for external dacryocystorhinostomy*. Arq Bras Oftalmol 2011;74:283-5.
- ⁴² Preechawai P. *Results of nonendoscopic endonasal dacryocystorhinostomy*. Clin Ophthalmol 2012;6:1297-301.
- ⁴³ Leong SC, Macewen CJ, White PS. *A systematic review of outcomes after dacryocystorhinostomy in adults*. Am J Rhinol Allergy 2010;24:81-90.
- ⁴⁴ Sharma BR. *Non-endoscopic endonasal dacryocystorhinostomy versus external dacryocystorhinostomy*. Kathmandu Univ Med J 2008;6:437-42.
- ⁴⁵ Ben Simon GJ, Joseph J, Lee S. *External versus endoscopic dacryocystorhinostomy for acquired nasolacrimal duct obstruction in a tertiary referral center*. Ophthalmology 2005;112:1463-8.
- ⁴⁶ Cokkeser Y, Evereklioglu C, Er H. *Comparative external versus endoscopic dacryocystorhinostomy: result in 115 patients (130 eyes)*. Otolaryngol Head Neck Surg 2000;123:488-91.
- ⁴⁷ Agarwal S. *Endoscopic dacryocystorhinostomy for acquired nasolacrimal duct obstruction*. J Laryngol Otol 2009;123:1226-8.
- ⁴⁸ Sonkhya N, Mishra P. *Endoscopic transnasal dacryocystorhinostomy with nasal mucosal and posterior lacrimal sac flap*. J Laryngol Otol 2009;123:320-6.
- ⁴⁹ Görgülü O, Ozdemir S, Görgülü FF. *Adjunctive use of mitomycin C in endoscopic revision dacryocystorhinostomy*. B-ENT 2012;8:123-6.
- ⁵⁰ Yildirim C, Yaylali V, Esmé A, et al. *Long-term results of adjunctive use of mitomycin C in external dacryocystorhinostomy*. Int Ophthalmol 2007;27:31-5.

Received: March 18, 2013 - Accepted: May 20, 2013

RHINOLOGY

Allergic and non-allergic rhinitis: relationship with nasal polyposis, asthma and family history

Riniti allergiche e non allergiche. Correlazioni con poliposi nasale, asma e storia familiare

M. GELARDI¹, L. IANNUZZI¹, S. TAFURI², G. PASSALACQUA³, N. QUARANTA¹

¹ Section of Otolaryngology, Department of Basic Medical Science, Neuroscience and Sensory Organs, University of Bari, Italy; ² Department of Biomedical Science and Human Oncology, University of Bari, Italy; ³ Allergy and Respiratory Diseases, University of Genoa, Italy

SUMMARY

Rhinitis and rhinosinusitis (with/without polyposis), either allergic or non-allergic, represent a major medical problem. Their associated comorbidities and relationship with family history have so far been poorly investigated. We assessed these aspects in a large population of patients suffering from rhinosinusitis. Clinical history, nasal cytology, allergy testing and direct nasal examination were performed in all patients referred for rhinitis/rhinosinusitis. Fibre optic nasal endoscopy, CT scan and nasal challenge were used for diagnosis, when indicated. A total of 455 patients (60.7% male, age range 4-84 years) were studied; 108 (23.7%) had allergic rhinitis, 128 (28.1%) rhinosinusitis with polyposis, 107 (23.5%) non-allergic rhinitis (negative skin test); 112 patients had associated allergic and non-allergic rhinitis, the majority with eosinophilia. There was a significant association between non-allergic rhinitis and family history of nasal polyposis (OR = 4.45; 95%CI = 1.70-11.61; $p = 0.0019$), whereas this association was no longer present when allergic rhinitis was also included. Asthma was equally frequent in non-allergic and allergic rhinitis, but more frequent in patients with polyposis. Aspirin sensitivity was more frequent in nasal polyposis, independent of the allergic ($p = 0.03$) or non-allergic ($p = 0.01$) nature of rhinitis. Nasal polyposis is significantly associated with asthma and positive family history of asthma, partially independent of the allergic aetiology of rhinitis.

KEY WORDS: Allergic rhinitis • Non-allergic rhinitis • Nasal polyposis • Nasal cytology • Family history • Atopy

RIASSUNTO

Le riniti allergiche e non allergiche, le rinosinusiti (con / senza poliposi), rappresentano un importante problema medico. La loro comorbidità, e il rapporto con la familiarità sono stati finora poco studiati. Abbiamo valutato questi aspetti in un'ampia popolazione di pazienti affetti da patologie rino-sinusali. Tutti i soggetti sono stati sottoposti ad indagini anamnestica, citologia nasale, test allergologici, rinomanometria anteriore attiva (RAA) ed endoscopia nasale a fibre ottiche. Quando indicata è stata eseguita TC naso-sinusale. Sono stati studiati 455 pazienti (60,7% maschi, di età compresa tra i 4 e 84 anni). 108 di essi (23,7%) presentavano rinite allergica, 128 (28,1%) avevano rinosinusite con poliposi, 107 (23,5%) rinite non allergica. 112 pazienti avevano una rinite allergica associata ad una forma non allergica (riniti "sovrapposte"), prevalentemente a cellularità eosinofila. Abbiamo riscontrato una significativa associazione tra le forme di riniti non allergiche "cellulari" e la familiarità per poliposi nasale (OR = 4,45, 95%CI = 1,70-11,61, $p = 0,0019$), mentre questa associazione non è stata rilevata nelle forme allergiche. L'asma era ugualmente frequente nella rinite allergica e non allergica, maggiore nei pazienti con poliposi. La sensibilità all'aspirina era più frequente nella poliposi nasale, indipendente dalla presenza di associate allergie ($p = 0,03$) o riniti non allergiche ($p = 0,01$). Infine, la poliposi nasale è significativamente associata ad asma e familiarità per asma, indipendentemente dalla rinite allergica.

PAROLE CHIAVE: Rinite allergica • Rinite non allergica • Poliposi nasale • Citologia nasale • Familiarità • Atopia

Acta Otorhinolaryngol Ital 2014;34:36-41

Introduction

Allergic and non-allergic rhinitis, rhinosinusitis (with/without nasal polyposis, NP) and other associated diseases (i.e. asthma, hearing disorders, sleep disorders) severely impair the quality of life of patients, and represent important challenges to the physician both from diagnostic and therapeutic points of view¹⁻⁴. For years, scientific efforts have been made to identify and distinguish the pathophysiology of these diseases, but to date many aspects still

remain unclear. In fact, if for allergic rhinitis (AR) and chronic rhino-sinusitis without nasal polyposis, the epidemiology and immunological mechanisms are relatively well known⁵⁻¹⁰, but few data are available for non-allergic rhinitis (NAR), in particular for the forms called "cellular", which include non-allergic rhinitis with neutrophils (NARNE), non-allergic rhinitis with eosinophils (NARES), non-allergic rhinitis with mast cells (NARMA), non-allergic rhinitis with eosinophils and mast cells (NARES-MA) (Fig. 1A-D)¹¹⁻¹⁴. and the overlapping forms¹⁵.

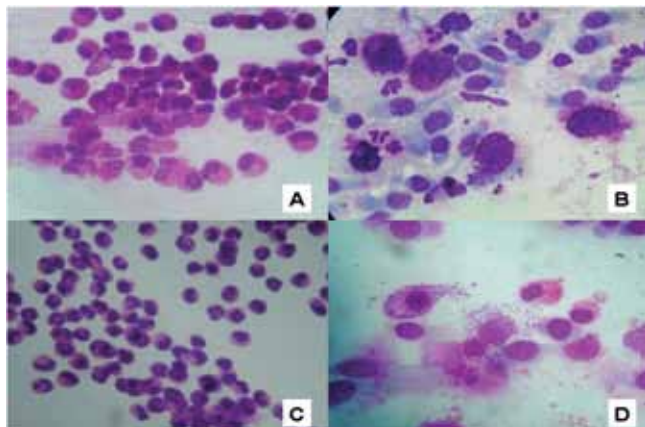


Fig. 1. Nasal cytology: A) non-allergic rhinitis with eosinophils (NARES); B) non-allergic rhinitis with mast cells (NARMA); C) non-allergic rhinitis with neutrophils (NARNE); D) non-allergic rhinitis with eosinophils and mast cells (NARESMA) May-Grünwald-Giemsa staining, original magnification $\times 1,000$.

To date, no precise pathogenic link among these diseases has been demonstrated, although it would be of enormous benefit in establishing appropriate medical/surgical management, and to prevent the onset of complications.

In this study, we evaluated a large number of patients suffering from nasal disorders (AR, NAR, NP, overlapping rhinitis), assessing the occurrence of selected comorbidities (allergy, asthma, aspirin sensitivity), and their possible correlation with family history of atopy, asthma and nasal polyposis.

Materials and methods

Patients referred to our ENT unit for nasal diseases between January 2010 and December 2012 were evaluated. Thorough medical history was always obtained, and all patients underwent skin prick test, flexible nasal endoscopy and nasal cytology.

The family history primarily focused on asthma, aspirin sensitivity, nasal polyposis and atopy, investigating at least four degrees of relationship (1st degree: parents and children; 2nd degree: siblings, grandparents and grandchildren, 3rd degree: aunts and uncles; 4th degree: cousins). This aspect was detailed as best as possible, since the usual response to the question “Do any of your family members and/or relatives suffer from nasal polyposis, asthma or atopy?” was vague or negative.

Nasal endoscopy was carried out by mean of a flexible fiberscope (Vision Science ENT 2000, diameter 3.4 mm). None of the patients received local anaesthesia or nasal decongestion. Allergic sensitization was assessed by a skin prick test that was carried out and read according to guidelines. Results were considered positive if the major wheel diameter was 3 mm or greater¹⁶. The panel of commercial allergens used (Stallergenes, Milan, Italy) included: house dust mite (*Dermatophagoides farinae* and *pteronyssinus*), cat, dog, grass mix, *Compositae* mix, *Parietaria judaica*, birch, hazelnut, olive, *Alternaria tenuis*,

Cladosporium and *Aspergilli* mix. A CAP-RAST assay (Phadia, Uppsala, Sweden) was carried out as a second line test when indicated, and a specific IgE concentration > 0.35 kU/l was considered positive.

Nasal cytology was performed obtaining a nasal scraping from the middle portion of the inferior turbinate, using a Rhino-Probe[®]^{17,18}. Samples were placed on a glass slide, fixed by air drying and stained by May-Grünwald Giemsa method (Carlo Erba[®], Milan, Italy). The slides were read under a Nikon E600 light microscope (Nikon, Canada) equipped with a digital camera. For the rhinocytogram analysis, 50 microscopic fields were read at a magnification of 1,000 \times to assess the presence of normal and abnormal cellular elements, or other pathologic microscopic features. Cell count was carried out by a semi-quantitative grading, as proposed by Meltzer and Jalowayski¹⁹. In particular, bacteria and fungal spores were quantified as follows: Grade 0 (not visible); Grade 1+ (occasional groups); Grade 2+ (moderate number); Grade 3+ (easily visible); Grade 4+ (entire field).

Patients were classified as having AR or NAR based on skin prick test results. The cellular forms of rhinitis were further subdivided based on their cytotype into NARNE (neutrophils $> 50\%$ with absent spores and bacteria); NARES (eosinophils $> 20\%$); NARMA (mast cells $> 10\%$); NARESMA (eosinophils $> 20\%$ and mast cells $> 10\%$)²⁰. All data were recorded in a dedicated database (FileMaker Pro) and analyzed using STATA software MP11. For proportions, the chi-square test was used. To evaluate the association between the disease and the investigated determinants, the OR with confidence intervals was calculated and the chi-square test was performed. For all tests, a $p < 0.05$ was considered statistically significant.

Results

In the present study, 455 patients (60.7% male, mean age 38.7 ± 18.3 years, age range 4-84 years) were studied. Of these, 108 (23.7%) had AR (30.5% monosensitized), 128 (28.1%) had nasal polyposis (32.8% with concomitant allergy), 107 (23.5%) had cellular rhinitis, of which 53 (49.5%) NARES, 54 (50.5%) NARESMA. Finally, 112 (24.6%) patients were classified as “overlapping” AR+NAR, of whom 39 (34.8%) with NARES, 8 (7.1%) with NARMA and 65 (58%) with NARESMA. These overlapping patients had a positive skin test/IgE assay, but also positive cytology for eosinophils and/or mast cells outside the pollen season.

Within IgE positive patients, the most frequent sensitizations were for mite (57.4%) followed by cypress (46.3%), olive (44.4%), grasses (38.9%), *Parietaria* (36.1%), dog/cat epithelium (30.5%) and fungi (6.5%). The distribution of patients by gender was not different for any of the diseases (chi-square = 4.12, $p = 0.38$). Table I summarizes the occurrence of the various diseases, the frequency of positive family history for allergy/

asthma, nasal polyps and acetylsalicylic acid sensitivity.

Positive family history for allergy had the same prevalence in AR and NAR groups ($p = 0.79$), and in the AR and NP groups ($p = 0.37$). A positive family history of allergy was more frequent in the overlapping forms of rhinitis compared to the pure AR group ($p = 0.03$), and when compared with NAR ($p = 0.02$) and nasal polyposis patients ($p = 0.002$). Table II shows the frequencies for family history of allergy at different degrees of relationships.

Table I. Occurrence of family history of atopy, asthma, nasal polyps and clinical signs such as: allergies, asthma and acetylsalicylic acid (ASA) sensitivity.

	AR n = 108	NAR n = 107	AR+NAR n = 112	NP n = 128
Family history of allergy	9 (8.3%)	10 (9.3%)	22 (19.6%)	8 (6.25%)
Family history of asthma	21 (19.4%)	26 (24.3%)	43 (38.4%)	21 (16.4%)
Family history of nasal polyposis	5 (4.7%)	19 (17.8%)	22 (19.6%)	21 (16.4%)
Allergy	-	-	-	42 (32.8%)
Asthma	16 (14.8%)	8 (7.5%)	29 (25.9%)	42 (32.8%)
Sensitivity to acetylsalicylic acid (ASA syndrome)	5 (4.6%)	4 (3.7%)	5 (4.5%)	16 (12%)

AR: allergic rhinitis; NAR: non-allergic rhinitis; NP: nasal polyposis.

Table II. Frequency of family history of allergy, asthma and nasal polyposis in different degrees of relationship.

	DEGREE OF RELATIONSHIP		
	1 st DEGREE Parents and offspring	2 nd DEGREE Brothers, grandparents/ grandchildren	3 rd /4 th DEGREE Aunts, uncles and cousins
FAMILIARITY FOR ALLERGY			
Allergic rhinitis (n = 12)	7 (58.3%)	4 (33.3%)	1 (8.3%)
Non-allergic rhinitis (n = 11)			
NARES	2 (18.1%)	2 (18.1%)	-
NARMA	-	-	-
NARESMA	6 (54.5%)	-	1 (9%)
Allergic rhinitis + non-allergic rhinitis (c.n. 24)			
NARES	5 (20.8%)	2 (8.3%)	3 (12.5%)
NARMA	1 (4.1%)	1 (4.1%)	-
NARESMA	6 (24%)	4 (16.7%)	2 (8.3%)
Nasal polyps (n = 9)	4 (44.4%)	4 (44.4%)	1 (11.1%)
FAMILIARITY FOR ASTHMA			
Allergic rhinitis (n = 21)	10 (47.6%)	6 (28.6%)	5 (23.8%)
Non-allergic rhinitis (n = 30)			
NARES	8 (26.7%)	8 (26.7%)	2 (6.7%)
NARMA	-	-	-
NARESMA	5 (16.7%)	4 (13.3%)	3 (10%)
Allergic rhinitis + non-allergic rhinitis (n = 45)			
NARES	4 (8.9%)	2 (4.4%)	4 (8.9%)
NARMA	1 (2.2%)	2 (4.4%)	-
NARESMA	12 (26.7%)	11 (24.4%)	9 (20%)
Nasal polyps (n = 22)	12 (54.5%)	6 (27.3%)	4 (18.1%)
FAMILIARITY FOR NASAL POLYPS			
Allergic rhinitis (n = 6)	2 (33.3%)	3 (50%)	1 (16.7%)
Non-allergic rhinitis (n = 20)			
NARES	-	1 (5%)	3 (15%)
NARMA	-	-	-
NARESMA	9 (45%)	4 (20%)	3 (15%)
Allergic rhinitis + non-allergic rhinitis (n = 25)			
NARES	2 (8%)	3 (12%)	5 (20%)
NARMA	-	1 (4%)	-
NARESMA	5 (20%)	4 (16%)	5 (20%)
Nasal polyps (n = 22)	10 (45.5%)	7 (31.8%)	5 (22.7%)
TOTAL (n = 247)	111 (44.9%)	79 (31.9%)	57 (23%)

A positive family history for asthma was found with the same prevalence in the AR group and NP ($p = 0.54$), in AR and NAR ($p = 0.41$) and in NAR and NP ($p = 0.68$). In contrast, overlapping rhinitis showed a higher frequency of familiarity both for AR ($p = 0.002$) and for NP ($p = 0.02$). Comparing NAR and overlapping rhinitis, asthma was associated with a greater risk for the overlapping forms ($OR = 1.96$, $95\%CI = 1.06-3.68$, $p = 0.02$) (Table II). Comparing the frequency of family history for nasal polyps in NAR and AR patients, a statistically significant association emerged in favour of NAR ($OR = 4.45$, $95\%CI = 1.70-11.61$, $p = 0.0019$). No significant difference in the frequency of family history of nasal polyps between NAR and NP ($p = 0.46$), and between overlapping rhinitis and NP ($p = 0.31$) was found (Table II). The difference in the frequency of asthma in the AR and NAR groups remained borderline ($p = 0.06$). In addition, asthma had a comparable frequency between overlapping rhinitis and NP groups ($p = 0.15$), but asthma was more common in the NP group compared with the AR group ($p = 0.001$) and the NAR group ($p < 0.0001$). ASA sensitivity had the same prevalence in the AR vs. NAR group ($p = 0.5$), in the AR group vs. overlapping rhinitis group ($p = 0.6$) and in the NAR vs. overlapping group ($p = 0.5$). ASA sensitivity resulted more frequent in

the NP group than in AR ($p = 0.03$), as compared to NAR ($p = 0.01$) and overlapping rhinitis ($p = 0.02$).

Discussion

In daily clinical practice of an ENT-Allergy centre, different forms of rhinitis, such as allergic, non-allergic, rhinosinusitis with or without nasal polyposis are seen. Therefore, the specialist must adopt increasingly complex diagnostic and instrumental methods for diagnosis and management. In fact, only a detailed diagnosis allows to characterize and optimally treat nasal diseases. Nonetheless, the identification of more complex and less characterized entities still poses diagnostic and therapeutic challenges^{15 17 21}. To receive the most accurate diagnosis, the patient should undergo thorough diagnostic work-up, where family history must not be excluded, and accompanied by imaging, functional and immunological evaluations (Fig. 2). By performing a broad investigational procedure, in the present study we observed that there was a high “global” familial incidence of allergy, asthma and nasal polyposis, not only between first and second degree relatives (44.9 and 31.9%), but also in third and fourth degree ones (23%). These data confirm the fact that, for some diseases, genetic background plays a crucial role and should be taken into consideration.

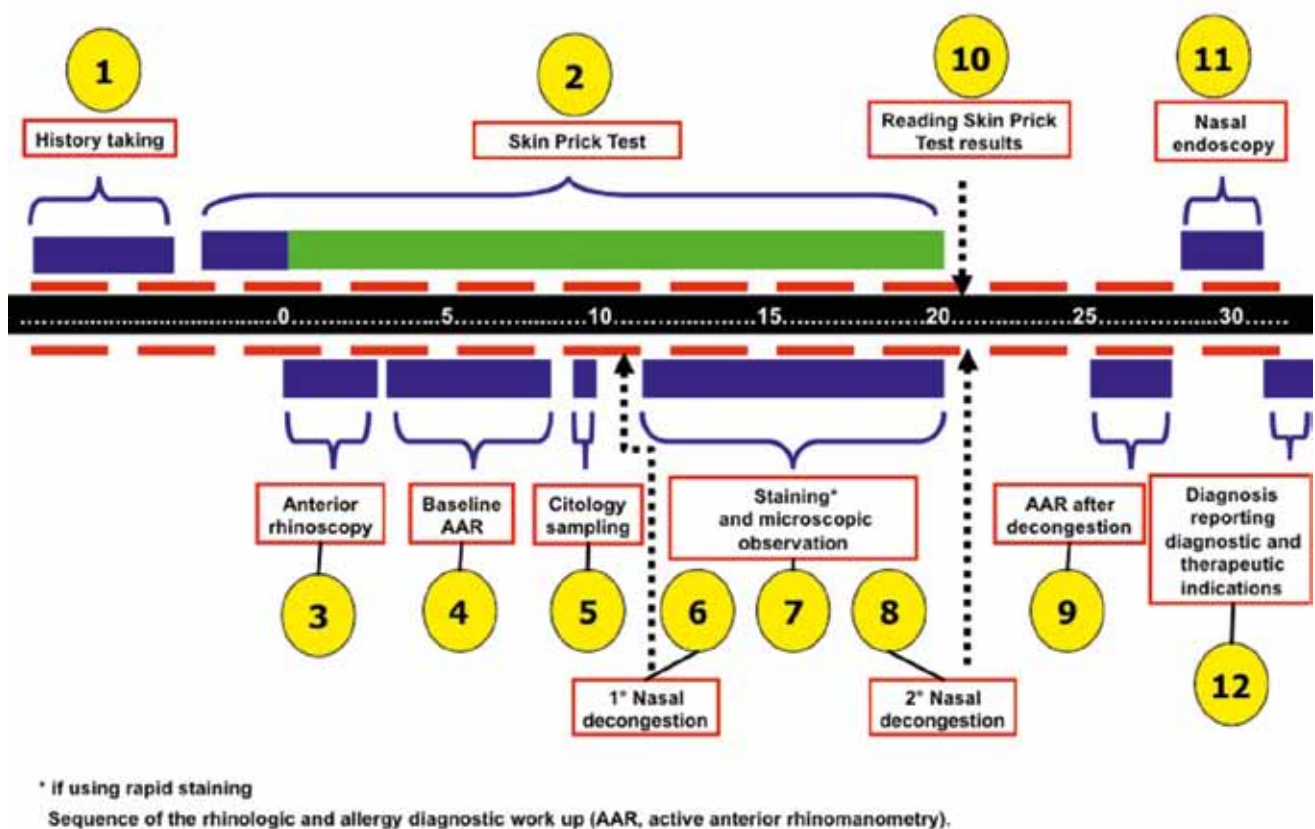


Fig. 2. For more accurate diagnosis, the rhinologic patient must be able to follow a precise diagnostic work-up, where family history must not be excluded, in addition to careful and thorough clinical history, and at least four levels of analysis should be provided: “macroscopic” investigation (by anterior rhinoscopy and nasal endoscopy); “microscopic” investigation (by nasal cytology); allergy investigation (by skin prick tests) and “functional” investigation (by basic active anterior rhinomanometry and after decongestion).

Table III. When to suspect “overlapping” of different rhinopathies (allergic rhinitis+NARES, NARMA or NARESMA).

When to suspect “overlapping” of different rhinopathies (allergic rhinitis + NARES, NARMA or NARESMA)
Clinical criteria
<ul style="list-style-type: none"> • Chronic “vasomotor” rhinitis symptoms (nasal congestion, rhinorrhoea, volley of sneezing) present even outside the pollen season, in a patient skin prick test and/or RAST test positive. • Increased “vasomotor”- type nasal reactivity to non-specific stimuli [sudden changes in temperature, light stimuli, strong smells, cigarette smoke, exposure to chlorine (swimming), etc.]. • Disturbances of taste and smell (suspect onset of nasal polyposis). • Positive family history of nasal polyposis, NARES, NARMA, NARESMA, asthma, sensitivity to acetylsalicylic acid, hypo-anosmia, vasomotor rhinitis labelled “non-specific”, previous turbinate surgery for nasal congestion which gave poor medium- to long – term results. • Recurrent use of nasal decongestants. • Little or no clinical benefit following turbinate surgery for nasal congestion. • Little or no clinical benefit following a cycle of specific immunotherapy (SIT).
Cytologic criteria
<ul style="list-style-type: none"> • In the forms with “persistent” symptoms, overlapping should be suspected in all patients with rhinocytogram showing a cell profile different from that associated with “persistent minimal inflammation” (i.e. different from that characterized by numerous neutrophils, some lymphocytes and occasional eosinophils, with rare signs of degranulation), where there are eosinophils > 20% and/or mast cells > 10%. • In the forms with “intermittent” symptoms, overlapping should be suspected in all patients with a positive rhinocytogram (eosinophils > 20% and/or mast cells > 10%.) outside the pollen season for the allergen/s identified by allergy testing (skin prick test and/or RAST test). • In rhinocytology, November tends to be preferred for “unravelling” overlapping rhinopathies, as this is the month in which most airborne pollens are absent. • The presence of immuno-inflammatory cells (eosinophils and/or mast cells) associated with rhinitis symptoms confirms the presence of overlapping diseases.

In particular, “cellular” rhinitis such as NARES, NARMA and NARESMA had a high percentage of positive family history for asthma and nasal polyposis, similar to patients with NP (24.3 vs. 16.4% and 17.8 vs. 16.4%); while allergic rhinitis (although with a familial incidence of asthma slightly higher than in patients with NP [19.4 vs. 16.4%]) presented a lower positive family history for nasal polyposis (4.7 vs. 16.4%), approaching the epidemiological data of the general population²².

Patients with “overlapping” rhinitis (AR+NAR) showed a familial incidence of asthma and nasal polyps greater than the NAR forms, of 38.4 and 19.6%, respectively. The data describing the familial incidence of NP, both in “cellular” and “overlapping rhinitis” (17.8 and 19.6%, respectively) demonstrate a clear link between these diseases and NP (OR = 4.45; 95%CI = 1.70-11.61, p = 0.0019), further confirming the confusion of numerous aetiopathogenetic theories on the formation of nasal polyps described in the last 20 years²³, and from time to time the denial of the theory of “epithelial breaking”²⁴, fungal aetiology²⁵, superantigens, etc.²⁶ We propose a hypothesis based on “familial-inheritance” that leads to the formation of nasal polyps as the “hyperplastic” evolution of a vasomotor cellular type rhinopathy. If this occurs in association with allergy, the IgE component would seem not determinant to lead to hyperplasia. Nonetheless, longitudinal studies of patients with NARES, NARMA and NARESMA are necessary to confirm this hypothesis.

Concerning AR, our data confirm those of the available literature²⁹ that exclude a common aetiology with NP, with an incidence of 32.8% in the group of patients with NP, similar to that found in the general population. Concerning the prevalence of asthma in rhinitis, our data are also consistent with that reported in epidemiological studies for both AR (14.8%) and NP (32.8%)¹⁶. On the other hand, our find-

ing of a large difference in incidence of asthma between cellular NAR (7.5%) and “overlapping” rhinitis (22.3%) is more difficult to interpret. Undoubtedly, the presence of two diseases (AR + NAR) in the same patient could justify an increased damage to respiratory epithelium^{31 32 34-36}.

Remaining within the rhino-allergic diagnostic realm, we suggest that “overlapping” rhinitis should always be diagnosed, since it has a different clinical evolution from the “pure” forms of AR. Its diagnosis would also avoid erroneous epidemiological estimates, such as: i) indicating that AR increases the incidence of asthma, or increases comorbidities such as sinusitis, otological diseases, sleep disorders and nasal polyps; ii) treatment failures (e.g. the failure of specific immunotherapy), and iii) preventing complications such as asthma, nasal polyps, etc.).

In this regard, the important role of nasal cytology is paramount, as it is the only laboratory investigation capable of diagnosing “cellular” NAR, to expose “overlapping” rhinitis (Table III), and to confirm the IgE-mediated rhinitis and monitor treatment. Therefore, although little used and valued, in our opinion this very useful method should systematically be used as a tool for diagnosis of rhinitis.

Rhino-allergic diagnosis is an articulate and complex procedure, and detailed patient history is mandatory. The instrumental diagnostic tools play a crucial role in clinical diagnosis, especially in the “cellular” forms of non-allergic vasomotor rhinitis and “overlapping” rhinitis, diseases that are not always diagnosed correctly and for many still unknown. Our results reasonably suggest the existence of a direct link between non-allergic rhinitis and nasal polyposis, based on hereditary-familial aspects. More systematic and larger cohort studies will be of help in understanding the pathogenetic mechanisms of both nasal polyposis and its comorbidities.

References

- ¹ Bousquet PJ, Demoly P, Devillier P, et al. *Impact of allergic rhinitis symptoms on quality of life in primary care*. *Int Arch Allergy Immunol* 2012;160:393-400.
- ² Bhattacharyya N. *Functional limitations and workdays lost associated with chronic rhinosinusitis and allergic rhinitis*. *Am J Rhinol Allergy* 2012;26:120-2.
- ³ Gelardi M, Maselli Del Giudice A, Fiorella ML, et al. *Quality of life in non-allergic rhinitis depends on the predominant inflammatory cell type*. *J Biol Regul Homeost Agents* 2008;22:73-81.
- ⁴ Arens R, Marcus CL. *Pathophysiology of upper airway obstruction: a developmental perspective*. *Sleep* 2004;27:997-1019.
- ⁵ Osguthorpe JD. *Pathophysiology of and potential new therapies for allergic rhinitis*. *Int Forum Allergy Rhinol* 2013;3:384-92.
- ⁶ Kavut AB, Kalpaklıoğlu F, Atasoy P. *Contribution of neurogenic and allergic ways to the pathophysiology of nonallergic rhinitis*. *Int Arch Allergy Immunol* 2012;160:184-91.
- ⁷ Sedaghat AR, Gray ST, Wilke CO, et al. *Risk factors for development of chronic rhinosinusitis in patients with allergic rhinitis*. *Int Forum Allergy Rhinol* 2012;2:370-5.
- ⁸ Kennedy DW. *The role of biofilms in the pathogenesis of chronic rhinosinusitis*. *Editorial*. *Int Forum Allergy Rhinol* 2011 Sep-Oct;1(5):Fmx. doi: 10.1002/alf.20099.
- ⁹ Seiberling KA, Church CA, Herring JL, et al. *Epigenetics of chronic rhinosinusitis and the role of the eosinophil*. *Int Forum Allergy Rhinol* 2012;2:80-4.
- ¹⁰ Van Crombruggen K, Zhang N, Gevaert P, et al. *Pathogenesis of chronic rhinosinusitis: inflammation*. *J Allergy Clin Immunol* 2011;128:728-32.
- ¹¹ Jacobs RL, Freedman PM, Boswell RN. *Non-allergic rhinitis with eosinophilia (NARES syndrome): clinical and immunologic presentation*. *J Allergy Clin Immunol* 1981;67:253-7.
- ¹² Connell JT. *Nasal mastocytosis*. *J Allergy* 1969;43:182-9.
- ¹³ Gelardi M, Maselli Del Giudice A, Fiorella ML, et al. *Non-allergic rhinitis with eosinophils and mast cells (NARESMA) constitutes a new severe nasal disorder*. *Int J Immunopathol Pharmacol* 2008;23:325-331.
- ¹⁴ Hsu J, Peters AT. *Pathophysiology of chronic rhinosinusitis with nasal polyp*. *Am J Rhinol Allergy* 2011;25:285-90.
- ¹⁵ Gelardi M, Russo C, Fiorella ML, et al. *When allergic rhinitis is not only allergic*. *Am J Rhinol Allergy* 2009;23:312-5.
- ¹⁶ Bousquet J, Heinzerling L, Bachert C, et al.; Global Allergy and Asthma European Network; Allergic Rhinitis and its Impact on Asthma. *Practical guide to skin prick tests in allergy to aeroallergens*. *Allergy* 2012;67:18-24.
- ¹⁷ Gelardi M. *Atlas of nasal cytology*. Milano: Edi Ermes; 2012.
- ¹⁸ Gelardi M, Fiorella ML, Russo C, et al. *Role of nasal cytology*. *Int J Immunopathol Pharmacol* 2010;23(1 Suppl):45-9.
- ¹⁹ Meltzer EO, Jalowayski AA. *Nasal cytology in clinical practice*. *Am J Rhinol* 1988;2:47-54.
- ²⁰ Gelardi M, Incorvaia C, Passalacqua G, et al. *The classification of allergic rhinitis and its cytological correlate*. *Allergy* 2011;66:1624-5.
- ²¹ Settipane RA, Lieberman P. *Update on nonallergic rhinitis*. *Ann Allergy Asthma Immunol* 2001;86:494-507.
- ²² Fokkens WJ, Lund VJ, Mullol J, et al., PJ.EPOS 2012: European position paper on rhinosinusitis and nasal polyps 2012. *A summary for otorhinolaryngologists*. *Rhinology* 2012;50:1-12.
- ²³ Pietruszewska W, Olejniczak I, Józefowicz-Korczyaska M, et al. *Etiology of nasal polyps: an update*. *Otolaryngol Pol* 2006;60:551-7.
- ²⁴ Tos M. *The pathogenetic theories on formation of nasal polyps*. *Am J Rhinol* 1990;4:51-5.
- ²⁵ Ponikau JU, Sherris DA, Kern EB, et al. *The diagnosis and incidence of allergic fungal sinusitis*. *Mayo Clin Proc* 1999;74:877-84.
- ²⁶ Bachert C, Zhang N, Patou J, et al. *Role of staphylococcal superantigens in upper airway disease*. *Curr Opin Allergy Clin Immunol* 2008;8:34-8.
- ²⁷ Bürger J, Macek M Jr, Stuhmann M, et al. *Genetic influences in the formation of nasal polyps*. *Lancet* 1991;337:974.
- ²⁸ Molnar-Gabor E, Endreffy E, Rozsari A. *HLA-DRB1, DQA1 and DQB1 genotypes in patients with nasal polyposis*. *Laryngoscope* 2000;110:422-5.
- ²⁹ Bernstein JM, Gorfien J, Noble B. *Role of allergy in nasal polyposis: a review*. *Otolaryngol Head Neck Surg* 1995;113:724-32.
- ³⁰ Gelardi M, Quaranta N, Passalacqua G. *When sneezing indicates the cell type*. *Int Forum Allergy Rhinol* 2013;3:393-8.
- ³¹ Shaw JL, Ashoori F, Fakhri S, et al. *Increased percentage of mast cells within sinonasal mucosa of chronic rhinosinusitis with nasal polyp patients independent of atopy*. *Int Forum Allergy Rhinol* 2012;2:233-40.
- ³² Tiddens H, Silverman M, Bush A. *The role of inflammation in airway disease: remodeling*. *Am J Respir Crit Care Med* 2000;162(2 Pt 2):S7-10.
- ³³ Amorim MM, Araruna A, Caetano LB, et al. *Nasal eosinophilia: an indicator of eosinophilic inflammation in asthma*. *Clin Exp Allergy* 2010;40:867-74.
- ³⁴ Pohunek P, Warner JO, Turzíkóvá J, et al. *Markers of eosinophilic inflammation and tissue re-modelling in children before clinically diagnosed bronchial asthma*. *Pediatr Allergy Immunol* 2005;16:43-51.
- ³⁵ Mauad T, Bel EH, Sterk PJ. *Asthma therapy and airway remodeling*. *J Allergy Clin Immunol* 2007;120:997-1009.
- ³⁶ Holgate ST. *Pathogenesis of asthma*. *Clin Exp Allergy* 2008;38:872-9.

Received: March 20, 2013 - Accepted: March 22, 2013

Address for correspondence: Matteo Gelardi, Unit of Rhinology, Section of Otolaryngology, Department of Basic Medical Science, Neuroscience and Sensory Organs, University of Bari, Italy. Tel. +39 080 5023966. Fax +39 080 5593315. E-mail: gelardim@inwind.it

AUDIOLOGY

Cochlea size variability and implications in clinical practice

Variabilità delle dimensioni cocleari e sue implicazioni nella pratica clinica

P. PELLICCIA^{1,2}, F. VENAIL¹, A. BONAFÉ³, M. MAKEIEFF¹, G. IANNETTI², M. BARTOLOMEO¹, M. MONDAIN¹

¹ ENT Department, CHU, Montpellier, France; ² Department of Maxillo-Facial Surgery, University of Rome La Sapienza, Rome, Italy; ³ Department of Neuroradiology, CHU, Montpellier, France

SUMMARY

The objectives of this study were: 1) study cochlea size variability among age and degree of deafness; 2) calculate the length of the cochlear implant electrode needed to obtain the optimal final insertion depth angle of 270°. A total of 241 patients (482 ears) that underwent high resolution computed tomography (HRCT) of the ear in our Institution between 2003 and 2008 were included to collect temporal bone data, and were divided in 3 groups: 97 (194 ears) patients with bilateral severe or profound sensorineural hearing loss (Group A), 70 patients (140 ears) with bilateral moderate sensorineural hearing loss (Group B), 74 patients (148 ears) without sensorineural or mixed hearing loss (Group C). In each of the 3 groups, 5 subgroups were identified with the following age criteria: 1) subgroup 1: subjects ≤5 years old; 2) subgroup 2: subjects 6-10 years old; 3) subgroup 3: patients 11-15 years old; 4) subgroup 4: patients 16-20 years old; 5) subgroup 5: subjects > 20 years old. The length of the cochlea, height of the cochlea, basal turn lumen diameter (BTLD) and volume of the cochlea were measured. The Mann-Whitney test was used to assess the alternative hypothesis that a statistically significant difference in size exists between the different groups and subgroups. The following equation was adopted to calculate the length of a straight electrode which follows the outer wall of the scala tympani required to obtain the ideal insertion depth angle of 270° (L_{IC}): $L_{IC} = 2.62 \times L \times \log_e (1 + 270^\circ/235)$. We found that the cochlea is completely developed and has reached adult size at birth. The degree of deafness does not affect the length or volume of the cochlea, while it can affect the height and BTLD. To assist the surgeon to calculate the ideal insertion depth angle of 270° in order to preserve residual hearing, it is useful to propose a straight electrode with 3 landmarks on the array (the first at 16.635 mm from the tip, the second at 17.987 mm and the third at 19.34 mm).

KEY WORDS: Cochlear implant • Cochlea size • Degree of deafness • Age • Length of cochlea • Height of cochlea • Basal turn lumen diameter • Volume of cochlea • Residual hearing preservation • Insertion depth angle

RIASSUNTO

Gli obiettivi di questo studio sono stati: 1) lo studio della variabilità delle dimensioni cocleari in relazione all'età e al grado di ipoacusia; 2) calcolare la lunghezza dell'elettrodo dell'impianto cocleare richiesta per ottenere l'angolo ideale d'inserzione profonda di 270°. Per raccogliere i dati riguardanti le ossa temporali sono stati inclusi nello studio 241 pazienti (482 ossa temporali) che hanno ricevuto una Tomografia Computerizzata a alta risoluzione (HRCT) dell'orecchio nel nostro Policlinico Universitario tra il 2003 e il 2008; i pazienti sono stati divisi in 3 Gruppi: 97 (194 orecchie) aventi una ipoacusia neurosensoriale severa o profonda bilaterale (Gruppo A), 70 (140 orecchie) aventi una ipoacusia neurosensoriale moderata bilaterale (Gruppo B), 74 pazienti (148 orecchie) senza ipoacusia neurosensoriale o mista (gruppo C). In ciascuno dei 3 gruppi, sono stati identificati 5 sottogruppi in base all'età: 1) sottogruppo 1: soggetti ≤ 5 anni, 2) sottogruppo 2: soggetti da 6 a 10 anni; 3) sottogruppo 3: pazienti da 11 a 15 anni, 4) sottogruppo 4: pazienti da 16 a 20 anni, 5) sottogruppo 5: soggetti > 20 anni. Sono stati misurati la lunghezza della coclea (L), l'altezza della coclea (H), il diametro del lume del giro basale (BTLD) e il Volume della coclea (V). Il Test di Mann-Whitney è stato utilizzato per verificare l'ipotesi alternativa che a livello di queste dimensioni esiste una differenza statisticamente significativa tra i differenti gruppi e sottogruppi. La seguente equazione è stata adottata per calcolare la Lunghezza di un elettrodo rettilineo che segue la parete esterna della scala timpani necessaria per ottenere l'angolo ideale di inserzione profonda di 270° (LIC): $L_{IC} = 2,62 \times L \times \log_e (1 + 270^\circ/235)$. Secondo i nostri risultati alla nascita la coclea è completamente sviluppata e ha già raggiunto le dimensioni dell'adulto. Il Grado di ipoacusia non influenza la Lunghezza (L) e il Volume (V) della coclea, mentre può influenzare la sua altezza (H) e il diametro del lume del giro basale (BTLD). Per aiutare il chirurgo a ottenere l'angolo di inserzione profonda ideale di 270° nell'intento di preservare l'udito residuo sarebbe utile proporre un elettrodo rettilineo con 3 punti di riferimento: il primo a 16.635 mm dalla punta, il secondo a 17.987 mm, il terzo a 19,34 mm)

PAROLE CHIAVE: Impianto cocleare • Dimensioni cocleari • Grado d'ipoacusia • Età • Lunghezza della coclea • Altezza della coclea • Diametro del giro basale della coclea • Volume della coclea • Preservazione dell'udito residuo • Angolo d'inserzione profonda dell'impianto cocleare

Introduction

By the middle of gestation, the cochlea is completely developed and has reached adult size; no further gain in size or change in shape is expected after birth¹⁻³. At present, there is anatomic⁴⁻⁵ and radiological⁶⁻¹⁶ evidence that the size of the cochlea presents some degree of variation between normal hearing subjects. Such evidence, on the one hand, prompted different authors to look radiologically for the existence of differences in cochlea size between normal hearing subjects and subjects with sensorineural hearing loss having a normal inner ear^{7-11 16 17}, and on the other hand have raised awareness regarding the cochlea size related variability of insertion depth angles for cochlear implant electrodes, making cochlear measurements and prediction of insertion depth angles for cochlear implant electrodes two important prerequisites to develop a next generation of implants that are more suited to cochlear size and therefore less traumatic^{6 12}.

The aims of the current study were: 1) study cochlea size variability considering age and degree of deafness in 3 groups of subjects: patients with bilateral severe or profound sensorineural hearing loss (group A), patients with bilateral moderate sensorineural hearing loss (group B), patients without sensorineural or mixed hearing loss (group C); 2) calculate the length of the cochlear implant electrode needed to obtain a final insertion depth angle of 270°, which in our opinion is the optimal insertion depth angle in the modern soft surgery era, since it allows to preserve most residual hearing without significant loss in hearing performances after cochlear implantation.

Methods

Patients

A total of 241 patients (482 ears) were included in this study to collect HRCT temporal bone data, and were divided in 3 groups: 97 (194 ears) patients with bilateral severe or profound sensorineural hearing loss (Group A), 70 patients (140 ears) with bilateral moderate sensorineural hearing loss (Group B), 74 patients (148 ears) without sensorineural or mixed hearing loss (Group C).

The 97 patients with bilateral severe or profound sensorineural hearing loss were selected between all patients who received a cochlear implant and had a preoperative HRCT in our institution between 2003 and 2008. The 70 patients with bilateral moderate sensorineural hearing loss were selected between all patients with bilateral moderate sensorineural hearing loss that received a hearing aid device who had been screened in our institution for middle and/or inner ear anomaly in the same period. The 74 patients without sensorineural or mixed hearing loss were selected between all patients with cholesteatoma sched-

uled for tympanoplasty who had a preoperative HRCT in our institution during the same period. The criteria for inclusion were: 1) HRCT performed in our institution and still available on the PACS; 2) slice thickness of 0.6 mm or less 3) radiologically undetectable abnormalities of the inner ear.

In each of the 3 groups, 5 subgroups were identified following age criteria: 1) subgroup 1: subjects ≤5 years old; 2) subgroup 2: subjects 6-10 years old; 3) subgroup 3: patients 11-15 years old; 4) subgroup 4: patients 16-20 years old; 5) subgroup 5: subjects > 20 years old (Table I).

Images processing

The images were treated with the Myrian® Expert 1.2 software developed by Intrasure® in order to obtain the following measures: 1) cochlear length (L); 2) cochlear height (H); 3) basal turn of cochlea lumen diameter (BTLD); 4) cochlear volume (V).

A view of the basal turn of the cochlea was developed as shown in Figure 1 to obtain L, H and BTLD, in accordance with the method described by Fraysse et al.^[6]

The aim was to view the lateral wall from the round window to one full turn (360°). The entire basal turn cannot be viewed using a single two-dimensional plane and thus a reconstruction was performed using a 1.1 mm layer with minimum intensity projection. This layer captures the extremity of the cochlear canal and either the scala tympani or scala vestibuli. The viewing angle was adjusted with the aid of the perpendicular sections to obtain a view that gave the largest area of dark pixels. In one view, one can visualize round window, oval window, basal turn of the cochlea, vestibule and the anterior branches of the lateral and superior semicircular canals.

The view developed allowed the largest distance L from the inferior lip of the round window niche, through the modiolar axis, to the lateral wall and the perpendicular distance H to be measured as in Figure 1. The same view also allowed BTLD to be measured: it was arbitrarily decided to measure BTLD in the bisector of the second quarter of the cochlea as in Figure 1.

To measure the volume (V), the software required encompassing the limits of the cochlea in multiple contiguous axial slices. The accuracy of the measurement V was checked by visual inspection of the area obtained in the view of the basal turn of the cochlea developed to obtain the other measures and in the axial, coronal and sagittal view, as shown in Figure 2.

Statistical analysis

The Mann-Whitney test was used to assess the alternative hypothesis that a statistically significant difference in size exists between the different groups and subgroups. The same test was used to assess the alternative hypothesis that a statistically significant difference in size exists between the left ear and the right ear.

Table I. Distribution of patients in the 3 groups among the age-related subgroups.

Subgroup	1 (<5 years-old)	2 (6-10 years-old)	3 (11-15 years-old)	4 (16-20 years-old)	5 (>20 years- old)	Total
A (bilateral severe or profound sensorineural hearing loss)	24	7	5	5	57	97
B (bilateral moderate sensorineural hearing loss)	15	29	16	7	3	70
C (no sensorineural or mixed hearing loss)	2	11	14	10	37	74

CI array optimal length determination

According to Fraysse et al,^[6] the following equation was adopted to calculate the length of a straight electrode which follows the outer wall of the scala tympani required to obtain the ideal insertion depth angle of 270° (L_{IC}):
 $L_{IC} = 2.62 \times L \times \log_e (1 + 270^\circ/235)$.

Results

Cochlear measurements in group A (bilateral severe or profound sensorineural hearing loss)

The median, mean, range and the standard deviation for each measurement in group A was, respectively:

1. cochlear length (L): 9 mm, 9.0623 mm, 7.4-11.4 mm, 0.7036 mm;
2. cochlear height (H): 6.9 mm, 6.9247 mm, 4.8-8.5 mm, 0.6101 mm;
3. Basal Turn Lumen Diameter (BTLD): 2.2 mm, 2.1814 mm, 1.5-2.8 mm, 0.2266 mm;

4. cochlear volume (V): 0.1415 ml, 0.1504 ml, 0.067-1.112 ml, 0.0963 ml.

Table II summarizes the results of the cochlear measurements in group A.

Cochlear measurements in group B (bilateral moderate sensorineural hearing loss)

The median, mean, range and standard deviation for each measurement in group B was, respectively:

1. cochlear length (L): 8.95 mm, 8.9642 mm, 7.4-11 mm, 0.5481 mm;
2. cochlear height (H): 6.8 mm, 6.7678 mm, 5.3-7.7 mm, 0.4143 mm;
3. Basal Turn Lumen Diameter (BTLD): 2.1 mm, 2.1264 mm, 1.8-2.8 mm, 0.2306 mm;
4. cochlear volume (V): 0.1335 ml, 0.1460 ml, 0.094-1.101 ml, 0.117 ml.

Table III summarizes the results of the cochlear measurements in group B.

Cochlear measurements in group C (patients without sensorineural or mixed hearing loss)

The median, mean, range and standard deviation for each measure in group C was, respectively:

1. cochlear length (L): 9.1 mm, 9.125 mm, 7.7-11.9 mm, 0.6806 mm;
2. cochlear height (H): 6.85 mm, 6.8128 mm, 4.8-8.2 mm, 0.502 mm;
3. Basal Turn Lumen Diameter (BTLD): 2.2 mm, 2.2263 mm, 1.5-2.7 mm, 0.2322 mm;
4. cochlear volume (V): 0.152 ml, 0.1854 ml, 0.084-2.01 ml, 0.2309 ml.

Table IV summarizes the results of the cochlear measurements in group C.

Influence of the side on cochlear measurements

No statistical difference was found between the length (L), the height (H), BTLD and volume (V) of the right and left cochlea in any of the three groups (p > 0.05).

Statistical analysis of the influence of age on cochlear size

In all groups, there was no increase in length (L), height (H), BTLD or volume (V) after birth (Figs. 3-5).

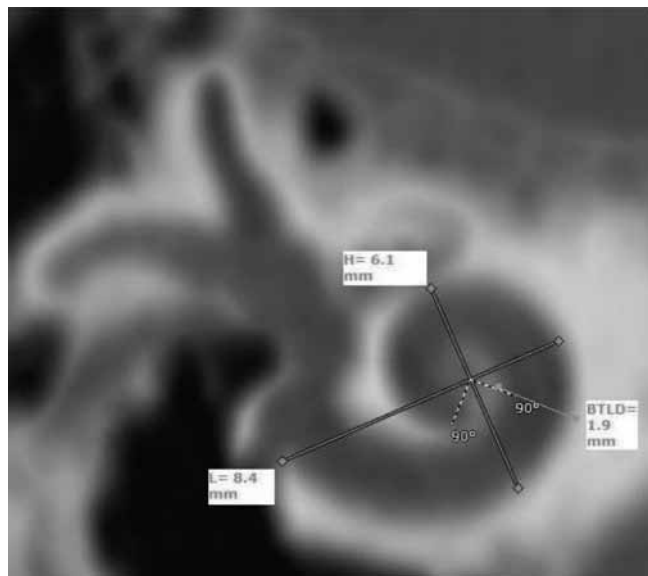


Fig. 1. Two-dimensional reconstruction from HRCT data of the basal turn of the cochlea using a 1.1 mm layer, minimum intensity projection. Distance L (cochlear length), here 8.4 mm, perpendicular distance H (cochlear height), here 6.1 mm, and distance BTLD (basal turn lumen diameter), here 1.9 mm, are measured using the scanner system.

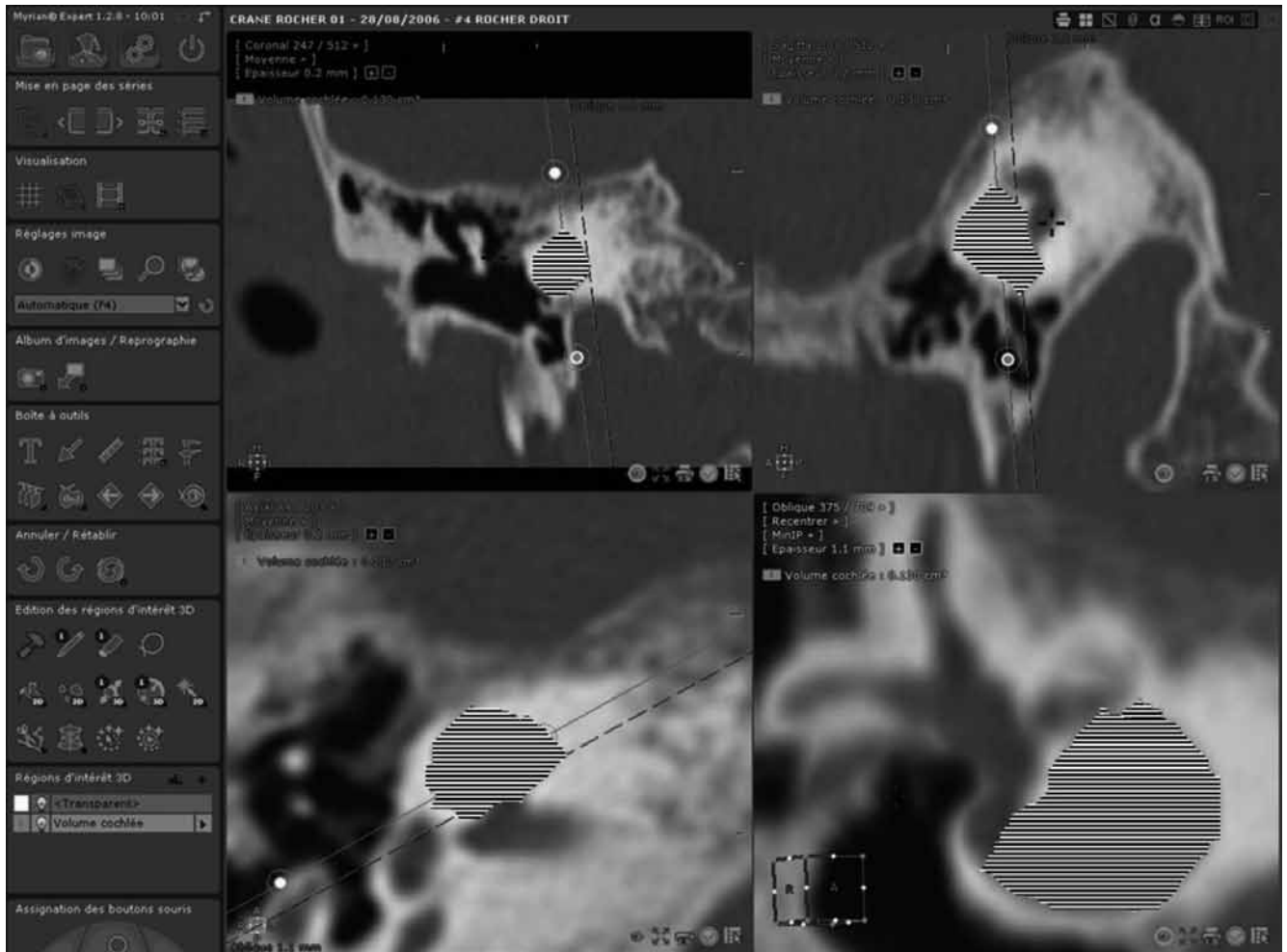


Fig. 2. The accuracy of the manually defined volume was checked by visual inspection of the coloured area obtained in four planes: coronal (upper left), sagittal (upper right), axial (lower left) and reconstructed view (lower right). Cochlea should only be defined by the striped area.

Table II. Cochlear measurement results in group A (bilateral severe or profound sensorineural hearing loss): length (L), height (H), basal turn lumen diameter (BTLD), volume (V).

	L (mm)	H (mm)	BTLD (mm)	V (ml)
Mean	9.0623	6.9247	2.1814	0.1504
Median	9	6.9	2.2	0.1415
Min	7.4	4.8	1.5	0.067
Max	11.4	8.5	2.8	1.112
Range	7.4-11.4	4.8-8.5	1.5-2.8	0.067-1.112
Standard deviation	0.7036	0.6101	0.2266	0.0963

Table III. Cochlear measurement results in group B (bilateral moderate sensorineural hearing loss): length (L), height (H), basal turn lumen diameter (BTLD), volume (V).

	L (mm)	H (mm)	BTLD (mm)	V (ml)
Mean	8.9642	6.7678	2.1264	0.1460
Median	8.95	6.8	2.1	0.1335
Min	7.4	5.3	1.8	0.094
Max	11	7.7	2.8	1.101
Range	7.4-11	5.3-7.7	1.8-2.8	0.094-1.101
Standard deviation	0.5481	0.4143	0.2306	0.1170

Tab. IV. Cochlear measurements results in group C (patients without sensorineural or mixed hearing loss): length (L), height (H), basal turn lumen diameter (BTLD), volume (V).

	L (mm)	H (mm)	BTLD (mm)	V (ml)
Mean	9.125	6.8128	2.2263	0.1854
Median	9.1	6.85	2.2	0.152
Min	7.7	4.8	1.5	0.084
Max	11.9	8.2	2.7	2.01
Range	7.7-11.9	4.8-8.2	1.5-2.7	0.084-2.01
Standard deviation	0.6806	0.502	0.2322	0.2309

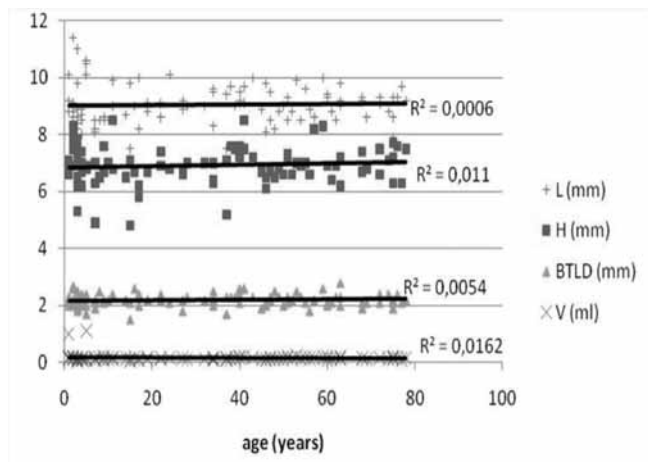


Fig. 3. Group A (bilateral severe or profound sensorineural hearing loss): measurement obtained in left ear versus age for L, H, BTLD and V.

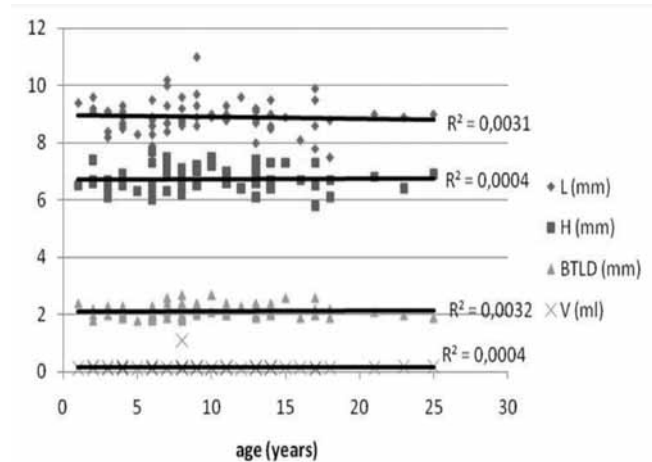


Fig. 4. Group B (bilateral moderate sensorineural hearing loss): measurement obtained in left ear versus age for L, H, BTLD and V.

Statistical analysis of the influence of the degree of deafness on cochlear length (L), cochlear height (H), BTLD and cochlear volume (V)

No statistically significant difference was found between the L of the different groups ($p > 0.05$) (Fig. 6). A statistically significant difference was found between the H in group A (bilateral severe or profound sensorineural hearing loss) and group B (bilateral moderate sensorineural hearing loss) ($p \leq 0.02308$), although no statistically significant difference was found between the H of group A and group C (patients without sensorineural or mixed hearing loss) ($p > 0.05$) or between the H of group B and group C ($p > 0.05$) (Fig. 6).

A statistically significant difference was found between the BTLD of the group B (bilateral moderate sensorineural hearing loss) and group C (patients without sensorineural or mixed hearing loss) ($p \leq 0.02373$), but no statistically significant difference was found between the BTLD of group A (bilateral severe or profound sensorineural hearing loss) and group B ($p > 0.05$) or between the BTLD of group A and group C ($p > 0.05$) (Fig. 6).

No statistically significant difference was found between the V between groups ($p > 0.05$) (Fig. 6).

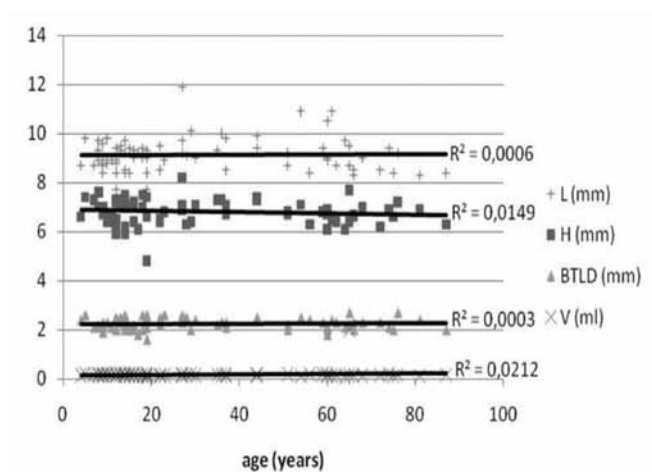


Fig. 5. Group C (patients without sensorineural or mixed hearing loss): measurement obtained in left ear versus age for L, H, BTLD and V.

Statistical analysis of the influence of age in each group

We defined 5 age related subgroups for group to analyze the influence of age in each group: 1) subgroup 1: subjects ≤ 5 years old; 2) subgroup 2: subjects 6-10 years old; 3) subgroup 3: patients 11-15 years old; 4) subgroup 4: pa-

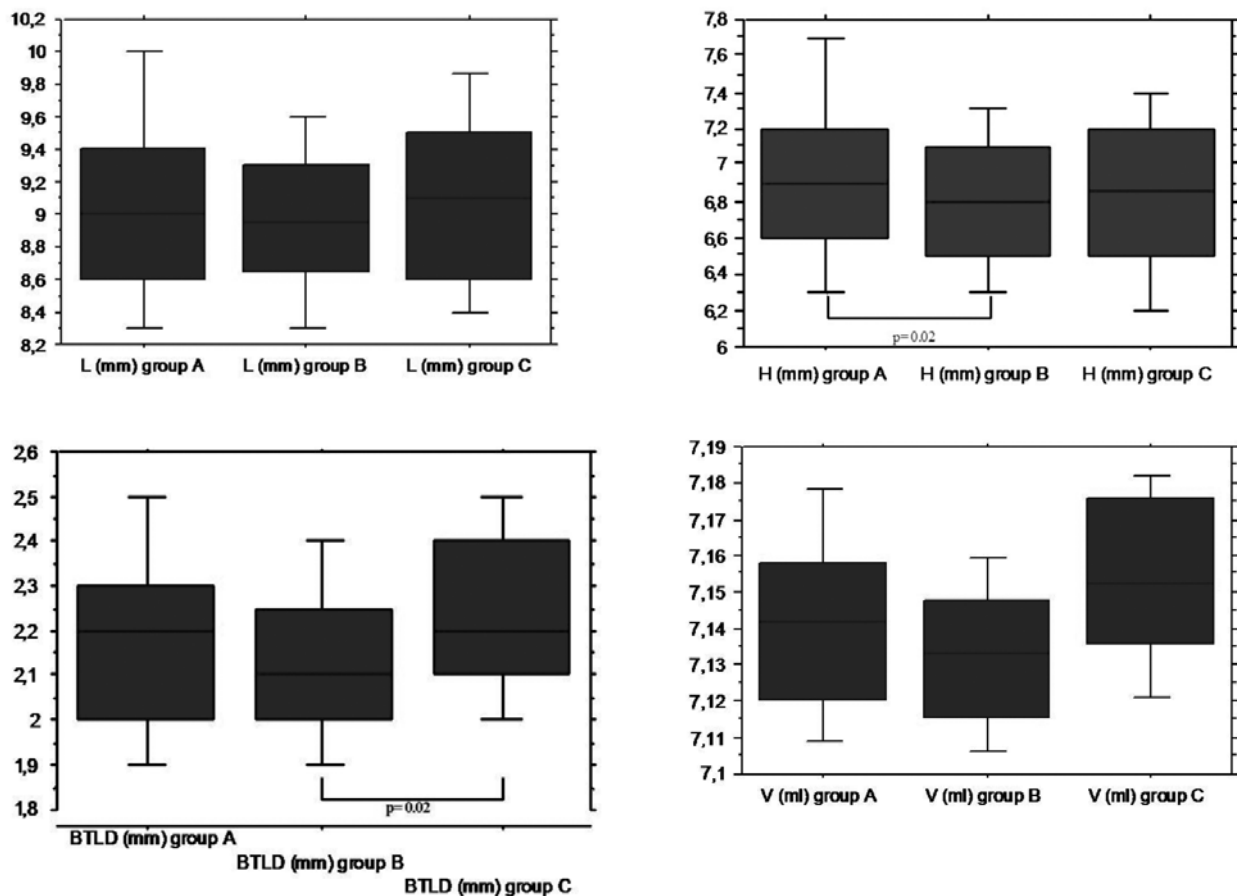


Fig. 6. Box-plots illustrating the influence of the degree of deafness on the length of the cochlea (L) (upper-left), height of the cochlea (H) (upper-right), basal turn lumen diameter (BTLD) (lower-left) and volume of the cochlea (V) (lower-right). Group A: bilateral severe or profound sensorineural hearing loss; group B: bilateral moderate sensorineural hearing loss; group C: patients without sensorineural or mixed hearing loss.

tients 16-20 years old; 5) subgroup 5: subjects > 20 years old (tab 1). Comparing the L, H, BTLD and V of the different subgroups a statistically significant difference was found in 2 cases:

1. H between subgroup A1 (48 ears) and subgroup B1 (30 ears) ($p \leq 0.02417$);
2. H between subgroup A5 (112 ears) and subgroup C5 (74 ears) ($p \leq 0.03517$).

Length of a straight electrode required to obtain the ideal insertion depth angle of 270° (L_{IC})

The length of a straight electrode that follows the outer wall of the scala tympani required to obtain the ideal insertion depth angle of 270° (L_{IC}) was calculated for the cochlea of all groups (482 ears), and not just for the patients in group A, as no statistical difference was found between the L of the different groups. The mean, standard deviation and range of L_{IC} we found was, respectively, 18.144 mm, 1.316 mm, 14.831-23.85 mm. The histogram in Figure 7 shows the distribution of L_{IC} in the three groups. L_{IC} ranged between 16.635 and 19.34 mm in more than 75% of inner ears.

Discussion

The current investigation was designed to study cochlea size variability considering age and degree of deafness in 3 groups of subjects, and assist in the conception of cochlear implants designed to preserve residual hearing by calculating the length of the straight (e.g. not preformed) cochlear implant electrode needed to obtain a final insertion depth angle of 270° .

The L and H obtained in the current investigation were similar to those obtained by Dimopoulos and Muren from 95 plastic casts⁴ and to those obtained by Fraysse et al. from HRCT of 42 patients.⁶ The latter had already shown the L and H measurement method to be reliable at least to within the resolution of the HRCT scan⁶.

The measurement of BTLD was similar to that obtained by Purcell et al. from the HRCT of 15 patients⁷. The BTLD measurement method, different from the L and H measurement method, showed obvious limits related to the voxel resolution of the images, but a more accurate method is not possible with current technology.

The measure of V was not similar to that obtained by Ken-

Distribution of L_{IC} (mm) in patients of all groups (482 ears)

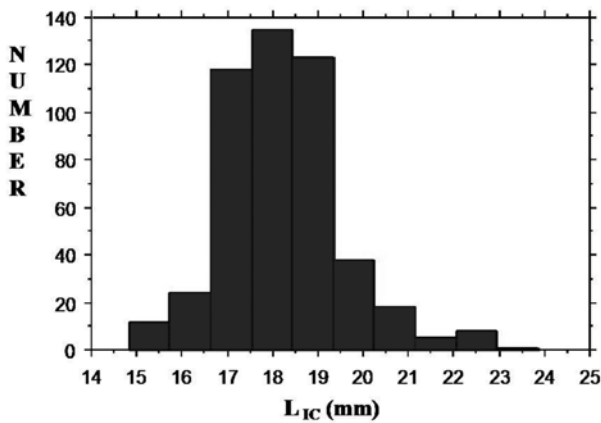


Fig. 7. Histogram illustrating the distribution of the calculated length of a straight electrode required to obtain the ideal insertion depth angle of 270° (L_{IC}) in the subjects of all group.

di et al. from the MR of 29 healthy volunteers¹⁸; in fact, we found a considerably higher mean value for V, but an obvious explanation can be suggested. We measured the volume of the anterior bony labyrinth on HRCT images, while Kendi et al. measured the volume of the anterior inner ear fluids on MR images, i.e. we obtained a measure of the container while Kendi et al. measured the content. Nonetheless, the V measurement method showed obvious limits related to the necessity of manually encompassing the limits of the cochlea in multiple axial slices and to the necessity of subjectively distinguishing the limit between the cochlea and other anatomical structures of the inner ear in multiple axial slices. This difficulty could represent another explanation for the discordance from results of Kendi along with the use of MRI. Also in the case of the V measurement method, a more accurate method is not possible with current technology. The interobserver variability was not calculated in the current investigation, but it was clearly felt that it is expected to be important for volume and especially for BTLD.

Our results confirm that cochlear size variability exists, and that this variability is not related to either age or side. The degree of deafness does not affect the length or volume of the cochlea, while it can affect height and the BTLD.

We found that the degree of deafness can affect the height of the cochlea, and the age-related subgroups analysis showed that this measure is also influenced by the age in each group. A statistically significant difference for H was found for the following:

1. between group A (bilateral severe or profound sensorineural hearing loss) and group B (bilateral moderate sensorineural hearing loss) ($p \leq 0.02308$). The H of group B seems to be smaller;
2. between subgroup A1 (bilateral severe or profound sensorineural hearing loss, ≤ 5 years old) and subgroup

B1 (bilateral moderate sensorineural hearing loss, ≤ 5 years old) ($p \leq 0.02417$). The H of group B1 seems to be smaller;

3. between subgroup A5 (bilateral severe or profound sensorineural hearing loss, > 20 years old) and subgroup C5 (patients without sensorineural or mixed hearing loss, > 20 years old) ($p \leq 0.03517$). The H of group C5 seems to be smaller.

Interestingly, other authors have previously noted that the degree of deafness affects the height of the cochlea, even if they performed measurements of H on coronal or axial temporal bone CT, so that it is missing the real axis of the cochlea and underestimating H. Purcell et al. have suggested routine measurement of H on HRCT coronal images to improve the sensitivity of HRCT in detecting inner ear malformations when very subtle abnormalities are involved, and established a normative measurement to aid in the diagnosis of inner ear malformations (4.27 mm to 6.35 mm)⁷. Moreover, performing measurements of the inner ear structures on axial temporal bone CT scans of 45 ears with congenital SNHL and grossly normal temporal bone CT scans and 45 ears with normal inner ear structures and normal hearing, Lan found that there were significant differences in the measurements of the maximal height of cochlea between the two groups (the maximal height of cochlea in the SNHL group was larger than the control group: 4.79 vs. 4.46 mm)¹¹.

The BTLD measurement method showed obvious limits related to the voxel resolution of images, thus making our results unreliable; however, we found a statistically significant difference between the BTLD of the 70 patients (140 ears) with bilateral moderate sensorineural hearing loss (Group B) and the BTLD of the 74 patients (148 ears) without sensorineural or mixed hearing loss (Group C). Interestingly, measuring BTLD on HRCT axial slice Purcell et al. found that the lumen of the basal turn in a group of 15 congenital SNHL with grossly normal temporal bone CT scans was smaller than the control group composed of 15 patients with normal hearing⁸.

In the modern cochlear implantation era, there is growing interest in developing an atraumatic surgical technique designed to preserve cochlear function, minimize cochlear damage and allow easy, possibly repeated reimplantation¹⁹⁻²¹. We used the data collected herein to optimize the length of the electrode array to preserve residual hearing by obtaining a final insertion depth angle of 270° . We calculated the length of a straight electrode which follows the outer wall of the scala tympani required to obtain the ideal insertion depth angle of 270° (L_{IC}) for the cochlea of subjects in all groups (482 ears) and found that the mean L_{IC} was 18.144 mm with a SD of 1.316 mm. L_{IC} ranged from 16.635 to 19.34 mm in more than 75% of inner ears, so we propose to place 3 landmarks on the array, the first at 16.635 mm from the tip, the third at 19.34 mm, and the second between the first and the third, at 17.9875 mm.

These 3 landmarks could help to obtain a 270° insertion depth angle if preoperative measurement of cochlear length on HRCT has been performed, and could replace fluoroscopy. These conclusions only apply to straight electrodes that follow the outer wall of the scala tympani.

Conclusions

Cochlear size variability exists, and this variability is not age-related; the cochlea has already reached adult size at birth. The degree of deafness does affect the length or volume of the cochlea, while it can affect height and BTLD. In order to preserve residual hearing it seems reasonable to propose a straight electrode with 3 landmarks on the array (the first at 16.635 mm from the tip, the second at 17.987 mm, the third at 19.34 mm) to assist the surgeon in obtaining the ideal insertion depth angle of 270° when a preoperative measurement of cochlear length (L) by HRCT has been performed. These landmarks might be an alternative to fluoroscopy to assist array insertion, and could be an interesting subject for future research.

Acknowledgments

We acknowledge Intrasense® for making available Myrian® Expert 1.2 software to obtain cochlear measurements.

References

- 1 Jackler RK, Luxford WM, House WF. *Congenital malformations of the inner ear: a classification based on embryogenesis*. Laryngoscope 1987;97:2-14.
- 2 Pappas DG, Simpson LC, McKenzie RA, et al. *High-resolution computed tomography: determination of the cause of pediatric sensorineural hearing loss*. Laryngoscope 1990;100:564-9.
- 3 Nemzek WR, Brodie HA, Chong BW, et al. *Imaging findings of the developing temporal bone in fetal specimens*. AJNR Am J Neuroradiol 1996;17:1467-77.
- 4 Dimopoulos P, Muren C. *Anatomic variations of the cochlea and relations to other temporal bone structures*. Acta Radiol 1990;31:439-44.
- 5 Hardy M. *The length of the organ of Corti in man*. Am J Anat 1938;62:291-311.
- 6 Escude B, James C, Deguine O, et al. *The size of the cochlea and predictions of insertion depth angles for cochlear implant electrodes*. Audiol Neurootol 2006;11:27-33.
- 7 Purcell DD, Johnson J, Fischbein NJ, et al. *Establishment of normative cochlear and vestibular measurements to aid in the diagnosis of inner ear malformations*. Otolaryngol Head Neck Surg 2003;128:78-87.
- 8 Purcell DD, Fischbein NJ, Lalwani AK. *Identification of previously "undetectable" abnormalities of the bony labyrinth with computed tomography measurement*. Laryngoscope 2003;113:1908-11.
- 9 Chen JL, Gittleman A, Barnes PD, et al. *Utility of temporal bone computed tomographic measurements in the evaluation of inner ear malformations*. Arch Otolaryngol Head Neck Surg 2008;134:50-6.
- 10 Purcell DD, Fischbein NJ, Patel A, et al. *Two temporal bone computed tomography measurements increase recognition of malformations and predict sensorineural hearing loss*. Laryngoscope 2006;116:1439-46.
- 11 Lan MY, Shiao JY, Ho CY, et al. *Measurements of normal inner ear on computed tomography in children with congenital sensorineural hearing loss*. Eur Arch Otorhinolaryngol 2009;266:1361-4.
- 12 Shim HG, Shin JE, Chung JW, et al. *Inner ear anomalies in cochlear implantees: importance of radiologic measurements in the classification*. Otol Neurotol 2006;27:831-7.
- 13 Kawano A, Seldon HL, Clark GM. *Computer-aided three-dimensional reconstruction in human cochlear maps: measurement of the lengths of organ of Corti, outer wall, inner wall, and Rosenthal's canal*. Ann Otol Rhinol Laryngol 1996;105:701-9.
- 14 Ketten DR, Skinner MW, Wang G, et al. *In vivo measures of cochlear length and insertion depth of nucleus cochlear implant electrode arrays*. Ann Otol Rhinol Laryngol 1998;175:1-16.
- 15 Xu J, Xu SA, Cohen LT, et al. *Cochlear view: postoperative radiography for cochlear implantation*. Am J Otol 2000;21:49-56.
- 16 Melhem ER, Shakir H, Bakthavachalam S, et al. *Inner ear volumetric measurements using high-resolution 3D T2-weighted fast spin-echo MR imaging: initial experience in healthy subjects*. AJNR Am J Neuroradiol 1998;19:1819-22.
- 17 Connor SE, Bell DJ, O'Gorman R, et al. *CT and MR imaging cochlear distance measurements may predict cochlear implant length required for a 360° insertion*. AJNR Am J Neuroradiol 2009;30:1425-30.
- 18 Kendi TK, Arıkan OK, Koc C. *Volume of components of labyrinth: magnetic resonance imaging study*. Otol Neurotol 2005;26:778-81.
- 19 Paludetti G, Conti G, Di Nardo W, et al. *Infant hearing loss: from diagnosis to therapy Official Report of XXI Conference of Italian Society of Pediatric Otorhinolaryngology*. Acta Otorhinolaryngol Ital 2012;32:347-70.
- 20 Forli F, Arslan E, Bellelli S, et al. *Systematic review of the literature on the clinical effectiveness of the cochlear implant procedure in paediatric patients*. Acta Otorhinolaryngol Ital 2011;31:281-98.
- 21 Berrettini S, Baggiani A, Bruschini L, et al. *Systematic review of the literature on the clinical effectiveness of the cochlear implant procedure in adult patients*. Acta Otorhinolaryngol Ital 2011;31:299-310.

Received: September 9, 2013 - Accepted: September 23, 2013

Address for correspondence: Pierfrancesco Pelliccia, Service ORL et Chirurgie Cervico-Faciale CHU Montpellier, 80, Avenue Augustin Fliche, 34295 Montpellier, France. Tel. +33650071394. Fax +33490492682. E-mail: pierfrancesco.pelliccia@hotmail.it

AUDIOLOGY

Quantitative enhancement of speech in noise through a wireless equipped hearing aid

Miglioramento della percezione verbale attraverso apparecchi acustici dotati di sistema wireless

A. CIORBA, S. ZATTARA, G. LORONI, S. PROSSER

ENT and Audiology Department, University Hospital of Ferrara, Italy

SUMMARY

The development of new hearing aid technology can improve speech understanding in complex listening environments. The purpose of this study is to evaluate the benefit offered by the use of wireless technology applied to hearing aids. Participants were fit with binaural hearing instruments and underwent speech-in-noise tests. The signal was transmitted either by a speaker or wirelessly directly to the hearing aid. In our experience, hearing aids with wireless systems have an advantage in two particular conditions. The first can be achieved while listening wirelessly with microphones excluded (recommended when listening in noisy environments), while the second is in conditions of asymmetric listening; the wireless signal perception remains effective, but at the same time it allows the patient to receive environmental signals. Hearing aids equipped with wireless systems may be particularly useful when listening to people talking even in noisy environments and/or receiving other sound sources such as TV and landline or cell phones.

KEY WORDS: Sensorineural hearing loss • Hearing aids • Rehabilitation • Wireless technology

RIASSUNTO

Lo sviluppo di nuove tecnologie audioprotesiche potrebbe migliorare la comprensione del parlato in particolari condizioni di ascolto ambientale. Scopo di questo studio è stato valutare i benefici offerti dall'utilizzo della tecnologia wireless applicata agli apparecchi acustici. I partecipanti sono stati sottoposti a test di percezione verbale nel rumore dopo aver indossato apparecchi acustici binaurali. Il segnale è stato trasmesso sia da un altoparlante sia in modalità wireless direttamente all'apparecchio acustico. Nella nostra esperienza, gli apparecchi acustici con sistemi wireless risultano utili soprattutto in due situazioni. La prima è l'ascolto wireless a microfoni esclusi (particolarmente raccomandato in ambienti rumorosi), mentre la seconda è in condizioni di ascolto asimmetrico; la percezione del segnale via wireless rimane efficace, ma allo stesso tempo anche la percezione dei segnali ambientali rimane buona. Concludendo, gli apparecchi acustici dotati di sistemi wireless risultano particolarmente utili per una buona percezione verbale anche in ambiente rumoroso, e/o per la ricezione di altre sorgenti sonore come la TV o telefoni di rete fissa o cellulare.

PAROLE CHIAVE: Ipoacusia neurosensoriale • Apparecchi acustici • Riabilitazione • Tecnologia wireless

Acta Otorhinolaryngol Ital 2014;34:50-53

Introduction

Sound is an integral part of our daily experience as it conveys relevant acoustic information that contributes to communication and mapping the environment where we live. Hearing impaired subjects, by means of amplification, may compensate only partially for the loss of acoustic information. In fact, hearing aid users are always searching for a kind of “auditory clearness”, either in situations in which communication is corrupted by ambient noise, or in situations in which verbal message comes from electronic devices such as television, computer and mobile phone. Several studies have already reported speech perception as the single most important aspect of hearing that attributes to hearing aid success¹⁻⁵.

The continuous search for solutions to improve hearing aid efficacy in listening to electroacoustic sources has led to the implementation of wireless technology in hearing instruments.

The purpose of this study is to evaluate the benefit offered by the use of wireless technology applied to hearing aids. In particular, we measured the aided reception threshold for speech stimuli as emitted by a loudspeaker within a room contaminated by a composite cocktail party and traffic noise. This acoustic condition is intended to simulate listening to a radio or TV in a noisy room full of people speaking together and with a window open on a busy road. Speech reception threshold (SRT) was thus compared in condition of free-field air-conducted speech,

and wireless-conducted signal. Changes in signal to noise ratio was the parameter that was evaluated.

Materials and methods

Subjects

A total of 9 subjects aged between 21 and 27 years were included in this study (3 males and 6 females). All participants had normal hearing (≤ 15 dB HL at 250, 500, 1000, 2000, 4000 Hz).

Hearing aid

For the time of experience, each subject was binaurally fitted with Gn-Resound Alera hearing aids using a standard soft earmold. The instruments were programmed for a linear gain of 16 dB, omnidirectional microphone and noise reduction system excluded. In addition, they were set up to operate in the following modalities: wireless off/on (P1, P2) and microphone on/off (mic+, mic-). It is notable that while in the wireless mode, the Alera may be programmed to operate either with mic- or mic+. With microphone excluded (mic-), only the wirelessly transmitted signals reach the subject's ear. With microphone open (mic+), wireless signals from the electroacoustic source and acoustic signals processed by the hearing aid mix together within the external ear canal.

Gn Resound uses a proprietary wireless technology operating in a frequency range of 2.4 GHz that allows communication between the hearing aids and other devices up to a distance of 7-10 m. The main feature of these devices is the ability to connect wirelessly to any electroacoustic source. The communication between the sound source and the hearing aid is operated through an interface-device ("Unite TV Streamer" for TV or an audio-system, or "Unite Phone Clip" for mobile phones). Using a remote control, the hearing aid user can manually choose among the available listening programme, enable or disable the wireless connection, or modify the volume (range 0-40 dB) of the wireless transmitted sounds. For the present experience, the volume control was fixed halfway, corresponding to 20 dB of extra-output.

Examination room

Subjects were examined in a sound-attenuated 3 × 4 m room, with a reverberation time of 0.4 sec. A noisy diffuse sound-field was obtained by using four loudspeakers horizontally arranged (placed at 0°, 90°, 180° and 270°, height 1.20 m) each at distance of 1 m around the subject. A fifth loudspeaker delivering the speech message was placed frontally.

A PC was programmed to play the sound files containing the stimuli, activate the loudspeakers via a MOTU board and control the sound levels. The fifth speaker, devoted to speech signal delivery, was also connected to the United

TV streamer; in this way, the speech message could also reach the hearing aids wirelessly.

Stimuli

Background noise consisting of cocktail party was delivered from the 0°, 90°, 180°, 270° speakers, with the addition of traffic noise on the 90° and 270° speakers. The overall background noise level as measured after balancing the single speaker output, and at the subjects' head position was kept at 55 dB SPL(A). Speech signal consisted of 13 lists, each of 20 Italian meaningful sentences (speech audiometry by GNResound Italia, 2000). The speech delivered from the fifth speaker at 0°, was calibrated as rms level with reference to the overall background noise level.

Measurements

Speech reception threshold (SRT), corresponding to 50% of correct responses, was recorded through a simple up-down 2 dB step adaptive procedure going on up to 7-8 reversals. Usually, each SRT measure needed 14-18 sentences. SRT was thus obtained in free field, in the following aided conditions:

1. both hearing aids in P1 and mic+ (reference condition);
2. both hearing aids in P2 and mic-;
3. both hearing aids P2 and mic+;
4. both hearing aids in P2, mic- in one ear and mic+ contralaterally.

The first condition was taken as a reference to evaluate the effect of wireless transmission compared to the usual condition. Moreover, while the first three conditions realize a symmetrical listening condition, the fourth realizes a condition of asymmetrical listening.

Results

The results corresponding to the SRT in noise are expressed in terms of s/n ratio. Recall that more negative values of s/n ratio indicate higher performance. To better appreciate the effect of listening through the different setting of the hearing aids, data from all the aided conditions were normalized with reference to those obtained in the unaided condition (unaided = 0 dB s/n).

Figure 1 reports the means and standard deviation values of the s/n ratio as obtained from the nine subjects across the tested conditions.

Listening with hearing aids in normal mode (Woff/M.on)

If compared to unaided condition, the performance worsens, since the SRT requires a higher signal (3.7 dB). This is due to the lack of the effect of the pinna and the location of the hearing aid's microphones at the head side: they directly collect the masking from the speakers at 90° and 270° at some expense of the speech signal coming from the speaker at 0° (Fig. 1).

Listening in wireless mode: Won/M.off

In this condition, the primary speech signal is directly transferred to the ear canal from the electroacoustic source; as microphones are off, the effect of masking noise within the ear canal should be consistently reduced, at least to the minor portion overpassing the earmold. The Won/M.off condition improves the s/n ratio by about 23 dB when compared to the unaided condition, or 27 dB if compared to the aided condition in normal mode (Woff/M.on) (Fig. 1).

Listening in wireless mode: W.on/M.on

In this “hybrid” condition, the hearing aid output contains both the wirelessly received speech signal, and the masking noise collected by the open microphones. The SRT requires a s/n of -4.5 dB, corresponding to a better performance of 7 dB compared to the normal mode condition (Woff/M.on), but a worsening of about 18.5 dB, if compared to the W.on/M.off condition. To explain these data, the output of the hearing aid was measured while operating in this hybrid condition. The measurement revealed that the gain for external source was lowered of 5 dB and the gain volume for the wireless source was incremented of 5 dB. Even if the purpose of these adjustments was to maintain a favourable s/n ratio, the result seems quite faraway from that seen with microphones excluded (Fig. 1).

Listening in wireless mode: Won/M.on-Moff

In this condition, both the hearing aids are working in wireless mode, but the microphones, open in one ear and closed in the other, realize an asymmetric acoustic condition. As shown by the above results, this asymmetry is remarkable as the SRTs require s/n ratios definitely different when microphones are kept both excluded or opened. In this particular condition, the SRT is measured at a s/n ratio close to that observable with microphones excluded, indicating that the ear with the best S/N ratio actually drives the speech recognition (Fig. 1).

Discussion

A noisy environment is invariably more challenging for most hearing aid users. The primary reasons for decline in hearing aid use include difficulties in communicating in a noisy environment or difficult listening situations. In particular, elderly users of hearing aids often complain

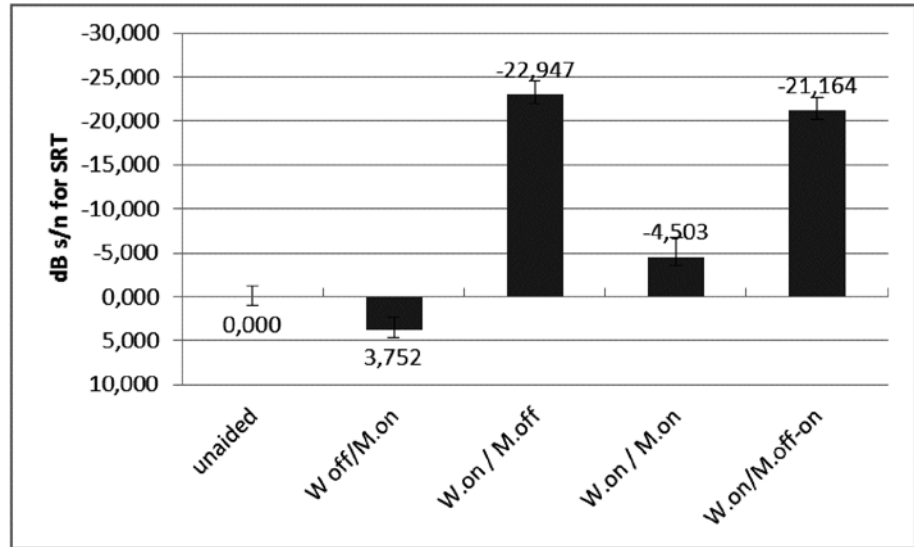


Fig. 1. Mean s/n ratios for SRT (50% correct responses) obtained in the different hearing aid settings. Vertical bars represent standard deviation. W: wireless; M: hearing aid microphone.

that listening to television is a major problem. Other than ambient noise, this may be due to speakers of low quality and non-ideal room acoustics. Naturalness and clarity of sound have been reported to be the strongest attributes for successful use of amplification⁴. The development of new hearing aid technology should improve speech understanding in complex listening environments, especially in the presence of competing talkers⁴⁻¹⁰. In particular, with the advent of wireless communication systems linking the hearing aids to different devices, it is necessary to understand the possible advantages of these tools in complex listening environments.

While the effect of these devices could be physically measured, their impact on everyday listening conditions is more elusive. This is explainable considering the numerous variables, partly attaining the nature of hearing impairment and partly the environmental acoustics. The present experience, by using normal hearing subjects, excluded the influence of factors due to hearing loss. Hence, the results may be regarded as the effect of the different set-up of a hearing aid type, while tested in a particular sound-field. Of note, laboratory conditions are difficult to reproduce in everyday life, as, for instance, noise is mostly temporary fluctuating in terms of spectral content, level, direction, with speech-when present, and changing accordingly.

We analyzed the speech reception thresholds in noise obtained by hearing aids equipped with a wireless device linked to electro-acoustic sources. The advantage of the modern hearing aid that can also manage wireless signals is that they can easily shift across a number of listening programs. The user may choose among different configurations, wireless or normal mode, also including microphones on or off, and how the source level has to be set

when transmitted wirelessly. These features allow a flexible use of hearing aids with wireless systems that can be very helpful when listening to electroacoustic sources.

Compared to the hearing aid in normal mode, the wireless mode as set up in this test allows for a very consistent improvement of SRT, which is close to 30 dB in terms of higher signal or lower masker. This is due to the combined effect of attenuation of the external noise exerted by the earmolds, and the extra-gain of 20 dB given to the transmitted signal.

While listening in wireless mode, some difficulty could arise in perceiving other environmental sounds, as for example, warning signal, or other people talking. For this reason, we tested the “hybrid” condition of listening a wirelessly transmitted source, while maintaining the hearing aid with microphones open. Although an improvement of 7 dB was measurable compared to the hearing aid in normal mode, the result was decisively below the use with microphones excluded. However, the data showed a return to a significant improvement of the S/N if one of the two microphones is off.

This realizes a condition of asymmetric hearing, where the performance is mainly driven by the ear with the better s/n ratio. In addition, other factors may also contribute to the advantage, such as the perception of spatially separated sources¹¹⁻¹⁶ and effects related to selective attention.

The use of the newest technologies may be difficult for elderly people with some cognitive impairment. However, the substantial improvement of the s/n ratio as shown by our results is expected to decisively facilitate the listening to acoustic sources like TV, one of the commonest habits in the elderly.

Conclusion

In conclusion, the examined situation demonstrates that hearing aids incorporating wireless systems can consistently improve the perception of signal emitted by a loudspeaker even within extremely noisy environments. In such challenging conditions, the wireless mode with excluded microphones can be recommended. An alternative setting may be one that exploits a condition of asymmetric listening: the wireless signal perception remains effective, while allowing for other environmental signals to also be perceived.

References

- ¹ Meister H, Lausberg I, Kiessling J, et al. *Determining the importance of fundamental hearing aid attributes*. *Otol Neurotol* 2002;23:457-62.
- ² Meister H, Lausberg I, Walger M, et al. *Using conjoint analysis to examine the importance of hearing aid attributes*. *Ear Hear* 2001;22:142-50.
- ³ Walden TC, Walden BE. *Predicting success with hearing aids in everyday living*. *J Am Acad Audiol* 2004;15:342-52.
- ⁴ Kreisman BM, Mazevski AG, Schum DJ, et al. *Improvements in speech understanding with wireless binaural broadband digital hearing instruments in adults with sensorineural hearing loss*. *Trends Amplif* 2010;14:3-11.
- ⁵ Singh Rana R, Bin T, Liang Z, et al. *Wireless hearing aid system simulations using advanced design system: a behavioral modeling approach*. *Conf Proc IEEE Eng Med Biol Soc* 2005;1:1016-9.
- ⁶ Stelmachowicz PG, Lewis DE, Choi S, et al. *Effect of stimulus bandwidth on auditory skills in normal-hearing and hearing-impaired children*. *Ear Hear* 2007;28:483-94.
- ⁷ Kuk F, Baekgaard L. *Considerations in fitting hearing aids with extended bandwidths*. *Hear Rev* 2009;16(11):32-38.
- ⁸ Best V, Carlile S, Craig J, et al. *The role of high frequencies in speech localization*. *J Acoust Soc Am* 2005;118:353-63.
- ⁹ Valente M, Mispagel KM, Tchorz J, et al. *Effect of type of noise and loudspeaker array on the performance of omnidirectional and directional microphones*. *J Am Acad Audiol* 2006;17:398-412.
- ¹⁰ Stelmachowicz PG, Lewis DE, Choi S, et al. *Effect of stimulus bandwidth on auditory skills in normal-hearing and hearing-impaired children*. *Ear Hear* 2007;28:483-94.
- ¹¹ Groth J, Anthonsen F, Wires F. *Less complexity, and more connections: the new challenge for wireless hearing instruments*. *Hear Rev* 2010;17(6):28-36.
- ¹² Galster JA. *A new method for wireless connectivity in hearing aids*. *The Hearing Journal* 2010;63:36-9.
- ¹³ Laugesen S, Schmidtke T. *Improving on the speech-in-noise problem with wireless array technology*. *News from Oticon*, January 2004.
- ¹⁴ Sandrock C, Schum DJ. *Wireless transmission of speech and data to, from, and between hearing aids*. *The Hearing Journal* 2007;60:12-16.
- ¹⁵ Bronkhorst AW. *The cocktail party phenomenon: a review of research on speech intelligibility in multiple-talker conditions*. *ACUSTICA - Acta Acustica* 2000;86:117-28.
- ¹⁶ Cherry E.C. *Some experiment on the recognition of speech, with one and with two ears*. *J Acoust Soc Am* 1953;25:975-9.

Received: December 11, 2012 - Accepted: March 18, 2013

Address for correspondence: Andrea Ciorba, ENT and Audiology Department, University Hospital of Ferrara, via Aldo Moro 8, 44124 Ferrara (Cona), Italy. Tel. +39 0532 239745. Fax +39 0532 237447. E-mail: andrea.ciorba@unife.it

BASIC RESEARCH IN OTOLARYNGOLOGY

Mitochondrial DNA (mtDNA) haplotypes and dysfunctions in presbycusis

Correlazioni tra gli aplotipi del DNA mitocondriale (mtDNA) e la presbiacusia

H. MOSTAFA¹, M. SAAD¹, A. EL-ATTAR¹, G. AHMED², S. BERRETTINI³, F. FORLI³, G. SICILIANO⁴, M. MANCUSO⁴

¹ Audiology Unit, ENT Department, Faculty Of Medicine, Assiut University, Egypt; ² Department of Genetics, Faculty of Agriculture, Assiut University, Egypt; ³ Department of otolaryngology, Faculty of Medicine, University of Pisa, Italy; ⁴ Department of Neurosciences, Faculty of Medicine, University of Pisa, Italy

SUMMARY

The aim of this study was to investigate the presence of mitochondrial DNA (mtDNA) alterations and metabolic dysfunctions in patients with presbycusis, and to discover correlations between presbycusis and the degree of hearing loss and mitochondrial damage. Seventy patients with presbycusis were examined, including 40 Egyptian patients and 30 Italian patients. Forty eight normal subjects were included as control group, including 24 Egyptians and 24 Italians. There was no common point mutation, and A1555G, A3243G, A7445G not were detected in any patients or controls. Haplogroup U was significantly common in patients in comparison to controls. Mutation of antioxidant genes (GSTT1, GSTM1) were significantly present in only Italian patients compared to Italian controls.

KEY WORDS: Presbycusis • Mitochondria • Haplogroup • Antioxidant genes

RIASSUNTO

Lo scopo dello studio è stato quello di indagare la presenza di alterazioni del DNA mitocondriale (mtDNA) in pazienti affetti da presbiacusia e di evidenziare eventuali correlazioni tra la presbiacusia, il grado di deficit uditivo e le alterazioni mitocondriali. Sono stati esaminati settanta pazienti affetti da presbiacusia, tra cui quaranta pazienti egiziani e trenta italiani. Quarantotto soggetti normoacusici sono stati utilizzati come gruppo di controllo, tra cui ventiquattro soggetti egiziani e ventiquattro italiani. In nessun paziente, né nei controlli, abbiamo identificato le mutazioni puntiformi A1555G, A3243G, A7445G. L'aplogruppo U era significativamente più comune nel gruppo di pazienti in confronto al gruppo dei controlli. La mutazione dei geni Antioxidant (GSTT1, GSTM1) sono state riscontrate più comunemente nei pazienti italiani rispetto ai controlli italiani, in maniera significativa.

PAROLE CHIAVE: Presbiacusia • Mitochondria • Aplotipi • Geni antiossidanti

Acta Otorhinolaryngol Ital 2014;34:54-61

Introduction

Presbycusis is a complex disorder, influenced by genetic, environmental/lifestyle and stochastic factors. Approximately, 13% of those over age 65 show advanced signs of presbycusis. By the middle of 21st century, the number of people with hearing impairment will have increased by 80%, partly due to an aging population, and partly to the increase of social, military and industrial noise¹.

According to Portmann and Portmann², presbycusis is a biologic phenomenon that no one can escape, starting at 20-30 years of age, and becomes socially bothersome when the person reaches 40-50 years. Early diagnosis and intervention in presbycusis are paramount to provide the elderly with a good quality of life.

Even though all individuals show a steady decline in hearing ability with ageing, there is a large variation in age of onset, severity of hearing loss and progression of disease,

which results in a wide spectrum of pure-tone threshold patterns and word discrimination scores. Presbycusis has always been considered to be an incurable and an unpreventable disorder, thought to be part of the natural process of ageing, but nowadays, it is recognized as a complex disorder, with both environmental and genetic factors contributing to its aetiology. This also means that it is not an inevitable disorder, and presbycusis should be considered as any other complex disease with a possible treatable and/or preventable nature. Scientific research should aim at the elucidation of the contributing factors³. Forward genetic examination is a promising approach. Isolating all the genes in the human genome, as well as identifying and cataloguing the functional variants within them in the human population, will allow assessment of the impact of genotype on phenotypic outcome of interest. Additionally, complementary strategies, based on

functional genomics technology involving microarrays and proteomics, can be used to develop predictors of disease susceptibility based on biological pathways physiologically relevant to presbycusis. Nevertheless, choices in study designs will still be a major factor in the probability of success. Determination of the genetic variants involved in presbycusis should provide new insights into the disorder mechanism, which may uncover new leads for pharmaceutical intervention and could result in the development of screening kits to identify individuals at increased risk⁴.

To date, genetic analysis of presbycusis has been limited. However, with recent major advances in hearing research, the human genome sequence completed and a comprehensive map of human genetic variation (Hap Map) available, together with a growing awareness of the importance of healthy ageing as global populations begin to age, a search for susceptibility alleles for presbycusis can be justifiably undertaken⁵.

Screening of cochlear tissue from blood of patients with presbycusis have identified mtDNA mutations, which could be related to age-related hearing loss. Many mitochondrial mutations cause defects in mitochondria from tissues such as lymphocytes and fibroblasts, yet the only phenotype associated with these mutations is hearing loss⁶. This tissue specificity may be the result of environmental factors. Tissue-specific patterns of gene expression are also likely to influence the effect of mtDNA mutations, with several examples of nuclear background affecting the defect caused by a mutation of the mtDNA⁷. The A3243G mutation, a variant located in the mitochondrial tRNA^{Leu} (UUR) gene and also known as MTTL1, is one of the most frequent heteroplasmic mitochondrial mutation⁸. Individuals carrying the A3243G mutation may manifest either as syndromic or non-syndromic mitochondrial disorders, and others may be asymptomatic. The most frequent syndromic manifestation of this mutation is mitochondrial encephalopathy, lactic acidosis and stroke-like episodes syndrome (MELAS)⁹. The original disorder in which the mutation was found is MELAS, but the majority of patients with the A3243G mutation show other clinical symptoms such as maternally inherited diabetes and deafness (MIDD), progressive external ophthalmoplegia (PEO) or other symptoms which include presbycusis, kidney disease, cardiomyopathy, neuropathy or endocrinopathies different from diabetes¹⁰.

The A7445G mutation, identified as T7445C in some earlier papers, was first described in a Scottish family and confirmed and established in two unrelated pedigrees from New Zealand and Japan¹¹. The penetrance of this mutation in the Scottish pedigree is quite low, while in the New Zealand and Japanese pedigrees is very high. Thus, mutation of A7445G itself may not be sufficient to cause hearing loss, but requires additional genetic or environmental factors, which seem to be rare in the Scottish

pedigree and common in the New Zealand and Japanese pedigrees¹².

The A1555G mutation in the mitochondrial 12S rRNA gene is one of the most common causes of sensorineural hearing loss and aminoglycoside-induced deafness. This mutation was first discovered in a large Arab-Israeli family, and subsequently found in various ethnic groups from Europe, Asia and Africa, with a variable prevalence. In the absence of aminoglycoside exposure, the phenotype observed is extremely variable in terms of the severity of hearing loss and age of onset. Moreover, a significant portion of individuals has normal hearing for their entire life. In many families with the A1555G mutation, a mild and progressive hearing loss occurs even in the absence of exposure to aminoglycosides. The hearing loss in affected cases shows a varied age of onset and severity, whereas others show a slow, progressive hearing loss beginning in their 40s, often preceded by tinnitus¹³.

Mitochondrial DNA (mtDNA) "polymorphisms" are maternally transmitted and typically reflect different ethnic backgrounds. Specific mtDNA polymorphisms have now been classified into a number of specific mitochondrial haplogroups. MtDNA haplogroups, determined by polymorphisms that occurred tens of thousands of years ago, are today high-prevalence population-specific substitutions. mtDNA has been used for a couple of decades as a molecular marker in population genetics¹².

Certain mtDNA haplogroups may increase the risk of presbycusis in some individuals, and mtDNA haplogroups are genetic markers for presbycusis. The mtDNA haplogroups U and K are independent genetic markers for moderate to severe presbycusis and may modify susceptibility associated with some known risk factors, but the precise mechanism underlying how mtDNA haplogroups increase genetic risk for presbycusis remains to be clarified. If these findings are confirmed, introduction of preventive strategies to minimize environmental causes could be implemented to reduce the overall risk of a genetically susceptible individual of developing presbycusis¹⁴.

Enzymes involved in glutathione metabolism (glutathione S-transferase, glutathione peroxidase, glutathione reductase) and enzymes involved in the breakdown of superoxide anions (catalase) have been suggested to be linked with presbycusis¹⁵. Glutathione S-transferase comprises several gene classes including GSTM and GSTT that show genetic variability in humans. Individuals who have null genotypes for GSTM1 and GSTT1 cannot conjugate metabolites specific for these enzymes. These individuals are thus thought to be more prone to damage caused by oxidative stress and possibly more susceptible to presbycusis¹⁶. In this study, the aim was to detect the presence of mtDNA alterations and mitochondrial metabolic dysfunctions in patients with presbycusis, and to discover any correlations between presbycusis and the degree of hearing loss and mitochondrial damage.

Materials and methods

Patients

Seventy patients with presbycusis were examined, including 40 Egyptian patients and 30 Italian patients. The Egyptian patients were examined in the clinic of Audiology Unit, ENT Department, Assiut university Hospital, Egypt. Italian patients were examined in the clinic of the Audiology Unit, ENT Department, Pisa University, Italy. Each patient had to fulfil the following criteria: Age above 40 years; bilateral more or less symmetrical sensorineural hearing loss, pure tone hearing threshold poorer to the normative values per age, determined by international committees; absence of any known cause of sensorineural hearing loss; absence of exposure to ototoxic drugs, otologic diseases, cranial trauma, acoustic trauma, chronic exposure to noise; and absence of any other pathology potentially correlated to sensorineural hearing loss¹⁷.

Forty eight normal individuals were included as control group, including 24 Egyptians and 24 Italians, with the following criteria: age above 40 years; pure tone hearing threshold within normal values per age as determined by international committees.

Informed consent was obtained from personal participants.

Audiological evaluation

All individuals in the study and control groups were subjected to:

- full medical history, including pedigree chart;
- ENT examination;
- pure tone audiometry with speech audiometry and tympanometry with measurement of the stapedial reflex. Of those volunteers who passed medical exclusion criteria, air conduction thresholds were measured at 250, 500, 1000, 2000, 3000, 4000 and 8000 Hz and bone conduction thresholds at 500, 1000, 2000 and

4000 Hz, according to clinical standards (ISO 8253-1, 1989).

All audiograms were categorized according to severity of hearing loss into five categories: mild, moderate, moderately severe, severe and profound hearing loss; according to the mean of thresholds at 500,1000,2000 and 4000 Hz¹⁷ (Table I).

Molecular evaluation

Peripheral blood was obtained from all participants. About 5 ml blood were obtained in suitable EDTA tubes. DNA was isolated from blood using a Nucleospin©Tissue kit (2006). mtDNA point mutations were determined by PCR-RFLP analysis. A set of primers, that amplifies all the tRNA coding regions for screening of A1555G, A3243G and A7445G point mutations were used. Reactions are performed in 25 µl of 10 mM Tris-HCl (pH 8.9) containing 0.4 µM each of the forward and reverse primers, 1.5 mM MgCl₂, 0.2 mM each of dATP, dGTP, and dTTP, 0.02 mM dCTP, 1 µCi of α-32[P] dCTP, and 1.25 U of Taq DNA polymerase (Roche, Indianapolis, IN). PCR conditions were: 94°C for 3 min, followed by 35 cycles of 94°C for 1 min, 55°C for 1 min, 72°C for 30 sec, and a final extension step at 72°C for 7 min. Samples were denatured and separated on a 6% MDE polyacrylamide gel (BME, Rockland, ME) with 5% glycerol, according to the manufacturer's protocol. Confirmations of single-stranded DNA are visualized by autoradiography using BioMax film (Kodak, Rochester, NY). Samples with abnormal patterns were directly sequenced using the ABI PRISM Big Dye Terminator Cycle Sequencing Ready Reaction Kit and a 310 Automatic Sequencer (Applied Biosystems, Foster City, CA).

Eleven mtDNA haplogroups (H, T, J, U, K, V, I, W, X, O, L) were categorized by the presence or absence of the well-defined restriction enzyme recognition sites as determined by PCR and RFLP analysis, in all patients and controls¹⁸, (Revised Cambridge Reference Sequence "rCRS").

Table I. Categories of the audiogram according to configuration.

Category	Definition
Flat	Audiogram where the difference between the mean of 250/500 Hz thresholds, the mean of 1/2 kHz thresholds and the mean of 4/8 kHz thresholds, is less than 15 dB
High frequency gently sloping (HFGS)	Audiogram where the difference between the mean of 500 Hz/1 kHz thresholds and the mean of 4 kHz/8 kHz thresholds is greater than 15 dB and less than 29 dB
High frequency steeply sloping (HFSS)	Audiogram where the difference between the mean of 500 Hz/1 kHz thresholds and the mean of 4 kHz/8 kHz thresholds is greater than 30 dB
Low frequency ascending (LFA)	Audiogram where the difference between the poorer low frequency thresholds and better high frequency ones is greater than 15 dB
Mid frequency U-shape (MFU)	Audiogram where the difference between the poorest thresholds in the mid-frequencies and those at higher and lower frequencies is greater than 15 dB
Mid frequency reverse U-shape (MFRU)	Audiogram where the difference between the best thresholds in the mid-frequencies and those at higher and lower frequencies is greater than 15 dB

The genetic polymorphism analysis for the GSTM1 and GSTT1 genes was determined using the multiplex PCR procedure of Abdel-Rahman¹⁹. Isolated DNA (40 ng) was amplified in a 25 µl reaction mixture containing 25 pmol of each of the following: GSTM1 primers of 5'-GAA CTC CCT GAA AAG CTA AAG C-3', 5'-GTT GGG CTC AAA TAT ACG GTG G-3' and GSTT1 primers of 5'-TTC CTT ACT GGT CCT CAC ATC TC-3', 5'-TCA CCG GAT CAT GGC CAG CA-3'. As an internal control exon 7 of the CYP1A1, genes were co-amplified using the primers 5'-GAA CTG CCA CTT CAG CTG TCT-3' and 5'-CAG CTG CAT TTG GAA GTG CTC-3' in the presence of 200 µmol dNTP (deoxynucleotide triphosphate), 25 µl 10 × PCR buffer, 1.5 mM MgCl₂, and 1 U Taq polymerase. The PCR conditions consisted of an initial melting temperature of 94°C (5 min) followed by 35 cycles of melting (94°C, 2 min) and annealing (59°C, 1 min), and an extension step (72°C) for 10 min terminated the process. The PCR products were then analyzed electrophoretically on an ethidium bromide stained 1.5% agarose gel.

Data were analyzed by using the SPSS-11 statistics programme to detect haplogroup distribution and differences between patient and control groups for point mutations and antioxidant defects.

Results

The study included 70 patients with presbycusis. Forty patients were Egyptian and 30 were Italian. The study included also 48 subjects as a control group; 24 were Egyptian and 24 were Italian.

Thirty-six patients were male, and 34 were female. Twenty-four patients had positive history of consanguinity between their parents, and they were all Egyptian patients. Twenty-nine patients had familial history of presbycusis; 25 were Egyptian, and only four were Italian. Fig. 1 shows distribution of the patient group according to age. Mean (± SD) age for Egyptian patients was 61.2 ± 9.0 years, while the mean age for Italian patients was 69.1 ± 7.5 years. Mean (± SD) age for Egyptian controls was 54 ± 6.8 years, and the mean age for Italian controls was 60.1 ± 7.5 years. There was no statistically significant difference between the mean age in Egyptian and Italian patients.

Audiological results

Patients were classified according to the degree of hearing loss into five categories: mild, moderate, moderately severe, severe and profound hearing loss (Fig. 2). The mean (± SD) hearing threshold for Egyptian patients was 62.7 ± 4.7 dB HL, while the mean hearing threshold for Italian patients was 67.1 ± 8.2 dB HL. There was no statistical significant difference between the mean hearing threshold in Egyptian and Italian patients.

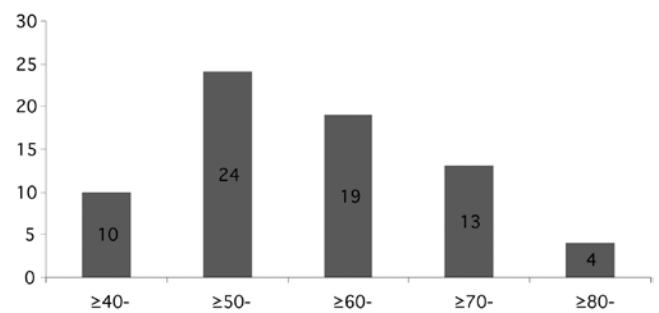


Fig. 1. Distribution of patients according to age.

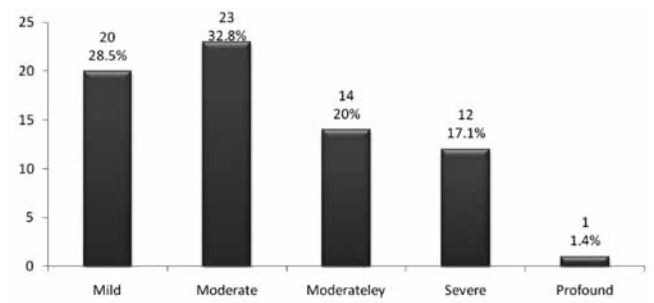


Fig. 2. Classification of patients according to degree of hearing loss.

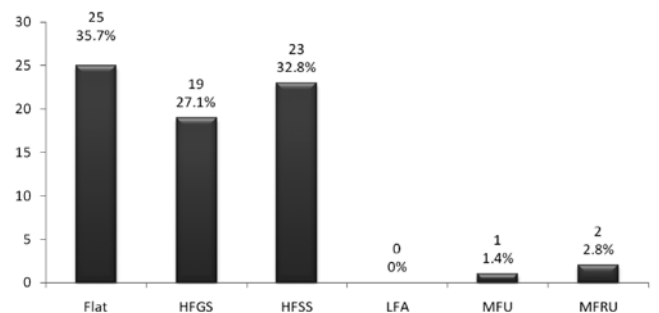


Fig. 3. Classification of patients according to shape of audiogram.

The control groups including Egyptians and Italian subjects had normal peripheral hearing.

Patients were also classified according to the shape of audiograms into five categories: flat, HFGS, HFSS, LFA, MFU and MFRU (Fig. 3).

Molecular results

Point mutations in A1555G, A3243G, and A7445G were not detected in any subject in either the study or control groups.

After identification of haplogroup distribution, the haplogroup U was the most common haplogroup (32.5%) among Egyptian patients, followed by haplogroup H (27.5%), haplogroup I (20%) and haplogroup T (7.5%). In Italian patients, haplogroup H was the most common haplogroup (30%), followed by haplogroup U (23.3%) hap-

Table II. Distribution of haplogroups in the study and control groups.

Group	H	T	J	U	K	V	I	W	X	O	L
Eg patients	11 (27.5%)	3 (7.5%)	1 (2.5%)	13 (32.5)	0 (0%)	0 (0%)	8 (20%)	0 (0%)	1 (2.5%)	2 (5%)	1 (2.5%)
It patients	9 (30%)	4 (13.3%)	1 (3.3%)	7 (23.3%)	0 (0%)	0 (0%)	4 (13.3%)	0 (0%)	1 (3.3%)	4 (13.3%)	0 (0%)
Eg controls	5 (20.8%)	5 (20.8%)	0 (0%)	3 (12.5%)	0 (0%)	0 (0%)	1 (4.1%)	1 (4.1%)	0 (0%)	1 (4.1%)	8 (33.3%)
It controls	14 (58.3%)	2 (8.3%)	0 (0%)	1 (4.1%)	0 (0%)	1 (4.1%)	2 (8.3%)	2 (8.3%)	0 (0%)	2 (8.3%)	0 (0%)

logroups T, I and O (13.3% each). In Egyptian controls, haplogroup L was the most common haplogroup (33.3%), followed by haplogroups H and T (20.8% each) and haplogroup U (12.5%). In Italian controls, haplogroup H was the most common (58.3%), followed by haplogroups T, I, W and O (8.3% each) (Table II).

Genetic polymorphism analysis for the GSTM1 and GSTT1 genes was performed in all patients and control subjects. The polymorphism analyzed in the GSTM1 and GSTT1 genes was the null genotype. For GSTM1, this mutation was identified in 25 patients (35%) (10 Egyptians, 15 Italians). Only four subjects in the control group (8.3%) had this mutation, and they were all Egyptians. There was a statistically significant difference ($p < 0.001$) between the patient and control groups, and between the Italian patient and control groups, but no statistically significant difference was detected between Egyptian patients and control groups (Table III, Fig. 4).

For GSTT1 gene, this mutation was identified in 21 patients (30%) (10 Egyptian patients, 11 Italian patients).

Table III. GSTM1 gene mutation in study groups.

Group	Positive GSTM1 in patients	Positive GSTM1 in controls	p value
Total	25/70 (35%)	4/48 (8.3%)	< 0.001
Egyptian	10/40 (25%)	4/24 (16.6%)	Not significant
Italians	15/30 (50%)	0/24 (0%)	< 0.001

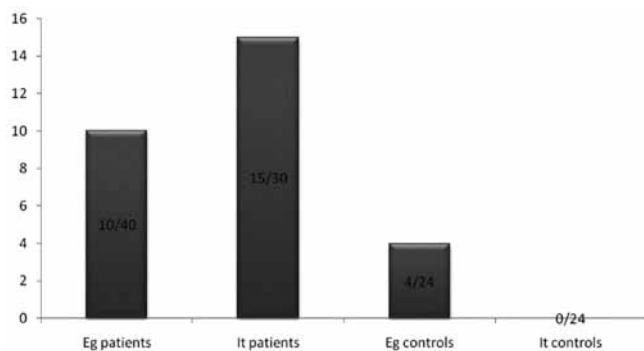


Fig. 4. Genetic polymorphism analysis for GSTM1.

Only nine control individuals (18.75%) had this mutation (six Egyptians and three Italians). There was statistically significant difference between both patient and control groups in total, and between the Italian patient and control groups, but no significant difference was detected between the Egyptian patients and control groups (Table IV, Fig. 5).

Table IV. GSTT1 gene mutation in study groups.

Group	Positive GSTT1 in patients	Positive GSTT1 in controls	p value
Total	21/70 (30%)	9/48 (18.75%)	< 0.001
Egyptians	10/40 (25%)	6/24 (25%)	Not significant
Italians	11/30 (36.6%)	3/24 (12.5%)	< 0.001

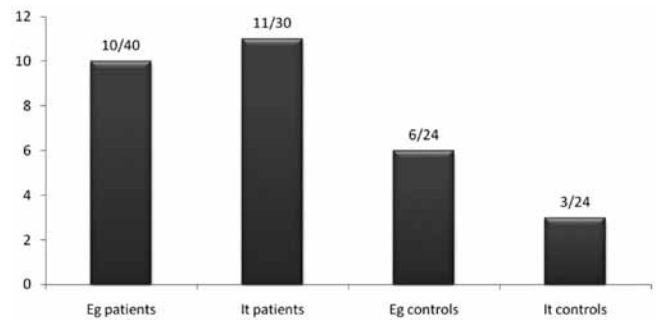


Fig. 5. Genetic polymorphism analysis for GSTT1.

After statistical analysis of the results with a One Way Anova test, no statistical significance was detected between groups (one way Anova > 0.05)

After analysis there was no correlation between separate groups, and no significant correlations were identified between any audiological or molecular variables including age, degree of hearing loss, shape of audiogram, haplogroup distribution, GSTM1 and GSTT1 mutations among Egyptian, Italian and all patients (Table V).

Table V. Correlation between audiological and molecular variables in the study group.

Variable	Age	Degree of hearing loss	Shape of audiogram	Haplogroup distribution	GSTM1 mutation	GSTT1 mutation
Age		NS ($p > 0.05$)	NS ($p > 0.05$)	NS ($p > 0.05$)	NS ($p > 0.05$)	NS ($p > 0.05$)
Degree of hearing loss	NS ($p > 0.05$)		NS ($p > 0.05$)	NS ($p > 0.05$)	NS ($p > 0.05$)	NS ($p > 0.05$)
Audiogram shape	NS ($p > 0.05$)	NS ($p > 0.05$)		NS ($p > 0.05$)	NS ($p > 0.05$)	NS ($p > 0.05$)
Haplogroup distribution	NS ($p > 0.05$)	NS ($p > 0.05$)	NS ($p > 0.05$)		NS ($p > 0.05$)	NS ($p > 0.05$)
GSTM1 mutation	NS ($p > 0.05$)	NS ($p > 0.05$)	NS ($p > 0.05$)	NS ($p > 0.05$)		NS ($p > 0.05$)
GSTT1 mutations	NS ($p > 0.05$)	NS ($p > 0.05$)	NS ($p > 0.05$)	NS ($p > 0.05$)	NS ($p > 0.05$)	

Discussion

The aim of epidemiological and genetic studies is to identify risk factors for presbycusis, such as environmental factors or genetic factors. Presbycusis is defined as a disorder, often quantified by a certain degree of hearing loss. In genetic terms, any study uses only 'one' phenotype to define the presence/absence of hearing impairment due to ageing, and to determine possible risk factors or causes²⁰. Most patients with presbycusis have mild (28.5%) or moderate (32.8%) SNHL, and the 'flat-configuration' was most dominantly represented (35.7%), followed by HFSS (32.8%), while the 'LFA', 'MFU' and 'MFRU' configurations were very rare (together less than 1%). These data agree with previous studies evaluating audiometric data on presbycusis²¹⁻²³. As animal studies have shown that aging alone does not cause outer hair cell loss, some Authors have emphasized that in humans, typically associated with a HFSS audiometric configuration, this has little to do with age.

It has been well documented that mutations in the 12S rRNA gene are hot spots that are antibiotic-induced and/or associated with presbycusis, and several deafness-associated mtDNA mutations have been identified in this gene. These mutations in a highly conserved decoding site of 12S rRNA could associate with both aminoglycoside treatment and presbycusis hearing loss in families with different ethnic backgrounds. The most common mutations in 12S rRNA causing presbycusis are A1555G, A3243G and A7445G. These gene mutations have also been involved in aminoglycoside-induced hearing impairment¹⁵. The progressive breakdown of mitochondrial function with age might result in presbycusis. Fischel-Ghodsian²⁴ reported mutations in the mitochondrially encoded cytochrome oxidase II gene in the auditory system of five patients with presbycusis with large individual variability in both quantity and cellular location of these mutations.

However in our study, these mutations were not detected in any patient. Recent studies indicate that the phenotypic expression of mtDNA mutations is highly variable, which indicates that these mutations may not be present, and some differences in either the nuclear gene content or activity appears to contribute significantly to the biochemical defect²⁵. Because of heteroplasmy, the proportion of

mutant mtDNA varies in cells/tissues of an individual, and affected organs can be variable in patients with the 12S rRNA gene mutation²⁶.

We found a significantly higher prevalence of presbycusis in subjects with mtDNA haplogroups U and I in Egyptian patients in comparison with Egyptian controls, while haplogroup H was not statistically significant between Egyptian patients and controls. The Egyptian controls had significantly high prevalence of haplogroups L and T compared to Egyptian patients.

In Italian patients, haplogroup H is not statistically greater, while haplogroup U was significantly higher in comparison to Italian controls who had a significantly high prevalence of haplogroup H.

Different mtDNA haplogroups may cause mild deleterious bioenergetic abnormalities. Impairment in mitochondrial function due to mutations in the mitochondrial genome is associated with an insidious decline in physiologic and biochemical performance that contributes to the aging process and to the ultimate death of the organ. There is a growing body of evidence to suggest that presbycusis may be associated with a reduction in mitochondrial function. In keeping with this, mutations in mtDNA and reduced mitochondrial function have been reported in human models of presbycusis²⁷.

Our findings suggest that haplogroup U may be used as a genetic marker for presbycusis susceptibility. Our results further support the concept that certain mtDNA haplogroups may cause mild deleterious bioenergetic abnormalities rather than merely representing the "neutral" polymorphisms reflecting different ethnic backgrounds. It is possible that genetic variants in specific mtDNA haplogroups may impair respiratory chain function within the cochlea to increase the risk of developing presbycusis.

A number of studies have suggested associations between various mtDNA haplogroups and a variety of medical conditions, including Parkinson's disease, Alzheimer's disease, occipital stroke in migraine, Leber hereditary optic neuropathy and multiple sclerosis. Of particular interest, haplogroup U has previously been associated with occipital stroke, azoospermia and Alzheimer's disease²⁸.

In many population studies, the prevalence of mtDNA haplogroup U, reported from studies of European and North American populations^{29,30}, was similar to our data,

suggesting that our results would likely be applicable to other populations.

Several antioxidant enzymes have been demonstrated to be active in the adult cochlea, for instance, enzymes involved in glutathione metabolism and enzymes involved in the breakdown of superoxide anions. The GSTM1 and GSTT1 genes show genetic variability in humans. Genotypes can be classified as null genotypes, heterozygotes, or wild type on the basis of whether they are homozygotes or heterozygotes. Approximately half of the white and black population are homozygotes for the deletion (null genotype). However, the percentage of the population carrying the null genotype varies in different geographic regions and ethnicities³¹. Individuals who are null genotypes for GSTM1 and GSTT1 cannot conjugate metabolites specific for these enzymes. These individuals are thus thought to be more prone to damage caused by oxidative stress and possibly more susceptible to presbycusis³².

The present study highlights the genotypic variability of antioxidant enzymes among different ethnic populations. This study emphasizes ethnic discrepancies and how they relate to presbycusis. These ethnic variabilities may play a role in genotype-phenotype associations, antioxidant enzymes and presbycusis. This study demonstrated an increased risk of presbycusis among Italian subjects carrying the GSTM1 and GSTT1 null genotype, but no increased risk was demonstrated in Egyptian patients. Of clinical importance, recent studies in animals have shown the potential importance of antioxidant enzyme supplementation in the prevention of presbycusis. Bared³³ showed an increased risk of presbycusis among white subjects, and presbycusis was more prevalent in white Hispanics than in white non-Hispanics.

These results are in contrast with previously published data. In a study of 68 white subjects of Turkish descent, Ates¹⁶ did not find a statistically significant correlation between individuals with a GSTM1 or GSTT1 null genotypes and presbycusis. Similarly, Unal³⁴ found no association between the GSTT1 and the GSTM1 null genotypes and presbycusis in white subjects of Turkish descent. However, In contrast to these studies, Bared³³, showed a clinically significant correlation for the development of presbycusis among subjects with the GSTT1 mutant allele and the GSTM1 mutant allele.

In conclusion, our findings suggest that mtDNA haplogroups U are independent genetic markers for presbycusis and may modify susceptibility associated with some known risk factors. Mitochondrial DNA may play a role in the pathogenesis of presbycusis, but our findings need to be corroborated by future studies to confirm the prevalence of mtDNA haplogroups in other populations of individuals affected with presbycusis. The precise mechanism underlying how mtDNA haplogroups increase genetic risk for presbycusis remains to be clarified. If these findings are confirmed, the introduction of preven-

tive strategies to minimize environmental causes could be implemented to reduce the overall risk in a genetically-susceptible individual of developing presbycusis.

References

- Lee F, Matthews L, Dubno J, et al. *Longitudinal study of pure-tone thresholds in older persons*. *Ear Hear* 2005;26:1-11.
- Portmann M, Portmann C. *Tratado de Audiometria Clínica*. 6^a ed. São Paulo: Roca; 1993. p. 135.
- Van Eyken E, Van Camp G, Van Laer L. *The complexity of age-related hearing impairment: contributing environmental and genetic factors*. *Audiol Neurotol* 2007;12:345-58.
- Van Laer L, DeStefano A, Myers R, et al. *Is DFNA5 a susceptibility gene for age-related hearing impairment?* *Eur J Hum Genet* 2002;10:883-8.
- Garringer H, Pankratz N, Nichols W, et al. *Hearing impairment susceptibility in elderly men and the DFNA18 locus*. *Arch Otolaryngol Head Neck Surg* 2006;132:506-10.
- Xing, G, Chen Z, Cao X. *Mitochondrial rRNA and tRNA and hearing function*. *Cell Res* 2007;17:227-39.
- Jacobs H, Hutchin P, Koppi T. *Mitochondrial DNA mutations in patients with postlingual, nonsyndromic hearing impairment*. *Eur J Hum Genet* 2005;13:26-33.
- Finsterer J. *Genetic, pathogenesis, and phenotypic implications of the mitochondrial A3243G tRNA^{Leu} (UUR) mutation*. *Acta Neurol Scand* 2007;116:1-14.
- Schapira A. *Mitochondrial disease*. *Lancet* 2006;368:70-82.
- Maa Y, Fang F, Yang Y, et al. *The study of mitochondrial A3243G mutation in different samples*. *Mitochondrion* 2009;9:139-43.
- Guan M, Fischel-Ghodsian N, Attardi G. *A biochemical basis for the inherited susceptibility to aminoglycoside ototoxicity*. *Hum Mol Genet* 2000;9:1787-93.
- Pyle A, Foltynie T, Tiangyou W. *Mitochondrial DNA haplogroup cluster UKJT reduces the risk of PD*. *Ann Neurol* 2005;57:564-67.
- Hutchin T, Cortopassi G. *Mitochondrial defects and hearing loss*. *Cell Mol Life Sci* 2000;57:1927-37.
- Manwaring N, Jones MM, Wang JJ, et al. *Mitochondrial dna haplogroups and age-related hearing loss*. *Arch Otolaryngol Head Neck Surg* 2007;133:929-33.
- Liu X, Yan D. *Ageing and hearing loss*. *J Pathol* 2007;211:188-97.
- Ates N, Unal M, Tamer L. *Glutathione S-transferase gene polymorphisms in presbycusis*. *Otol Neurotol* 2005;26:392-7.
- Demeester K, Wieringen A, Hendrickx J, et al. *Audiometric shape and presbycusis*. *Int J Audiol* 2009;48:222-32.
- Andrews R, Kubacka I, Chinnery P, et al. *Reanalysis and revision of the Cambridge reference sequence for human mitochondrial DNA*. *Nat Genet* 1999;23:147.
- Abdel-Rahman S, El-Zein R, Anwar W, et al. *A multiplex PCR procedure for polymorphic analysis of GSTM1 and GSTT1 genes in population studies*. *Cancer Lett* 1996;107:229-33.
- Seidman M, Ahmad N, Joshi D. *Age-related hearing loss and its association with reactive oxygen species and mitochondrial DNA damage*. *Acta Otolaryngol* 2004;552:16-24.

- ²¹ Cruickshanks K, Wiley T, Tweed T, et al. *Prevalence of hearing loss in older adults in Beaver Dam, Wisconsin. The Epidemiology of Hearing Loss Study.* Am J Epidemiol 1998;148:879-86.
- ²² Ohlemiller K. *Age-related hearing loss: The status of Schuknecht's typology.* Curr Opin Otolaryngol Head Neck Surg 2004;12:439-43.
- ²³ Wiley T, Torre P, Cruickshanks K, et al. *Hearing sensitivity in adults screened for selected risk factors.* J Am Acad Audiol 2001;12:337-47.
- ²⁴ Fischel-Ghodsian N, Bykhovskaya Y, Taylor K, et al. *Temporal bone analysis of patients with presbycusis reveals high frequency of mitochondrial mutations.* Hear Res 1997;110:147-54.
- ²⁵ Somayeh R, Zohreh A, Marzieh A, et al. *Molecular investigation of mtDNA A1555G, A3243G and A7445G mutations among the non syndromic hearing loss cases in Fars, Iran.* Kaums Journal 2011;14:447-52.
- ²⁶ Nagata H, Kumahara K, Tomemori T, et al. *Frequency and clinical features of patients with sensorineural hearing loss associated with the A3243G mutation of the mitochondrial DNA in otorhinolaryngic clinics.* J Hum Genet 2001;46:595-9.
- ²⁷ Dai P, Yang W, Jiang S. *Correlation of cochlear blood supply with mitochondrial DNA common deletion in presbycusis.* Acta Otolaryngol 2004;124:130-6.
- ²⁸ Van der Walt J, Dementieva Y, Martin E. *Analysis of European mitochondrial haplogroups with Alzheimer disease risk.* Neurosci Lett 2004;365:28-32.
- ²⁹ Majamaa K, Finnila S, Turkka J, et al. *Mitochondrial DNA haplogroup U as a risk factor for occipital stroke in migraine.* Lancet 1998;352:455-56.
- ³⁰ Seidman M, Ahmad N, Bai U. *Molecular mechanisms of age-related hearing loss.* Ageing Res Rev 2002;1:331-43.
- ³¹ Blum M, Demierre A, Grant D. *Molecular mechanism of slow acetylation of drugs and carcinogens in humans.* Proc Natl Acad Sci U S A 1991;88:5237-41.
- ³² Le T, Keithley E. *Effects of antioxidants on the aging inner ear.* Hear Res 2007;226:194-202.
- ³³ Bared A, Ouyang X, Angeli S, et al. *Antioxidant enzymes, presbycusis, and ethnic variability.* Otolaryngol Head Neck Surg 2010;143:263-8.
- ³⁴ Unal M, Tamer L, Dogruer Z. *N-acetyltransferase 2 gene polymorphism and presbycusis.* Laryngoscope 2005;115:2238-41.

Received: May 30, 2012 - Accepted: February 8, 2013

VESTIBOLOGY

Epigone migraine vertigo (EMV): a late migraine equivalent

Vertigine emicranica epigona (VEE): un equivalente emicranico tardivo

P. PAGNINI, P. VANNUCCHI, B. GIANNONI, R. PECCI

Department of Surgical Sciences and Translational Medicine, Unit of Audiology, Careggi Hospital, University of Florence, Italy

SUMMARY

Migrainous headache is determined by pathogenetic mechanisms that are also able to affect the peripheral and/or central vestibular system, so that vestibular symptoms may substitute and/or present with headache. We are convinced that there can be many different manifestations of vestibular disorders in migrainous patients, representing true different clinical entities due to their different characteristics and temporal relationship with headache. Based on such considerations, we proposed a classification of vertigo and other vestibular disorders related to migraine, and believe that a particular variant of migraine-related vertigo should be introduced, namely “epigone migraine vertigo” (EMV): this could be a kind of late migraine equivalent, i.e. a kind of vertigo, migrainous in origin, starting late in the lifetime that substitutes, as an equivalent, pre-existing migraine headache. To clarify this particular clinical picture, we report three illustrative clinical cases among 28 patients collected during an observation period of 13 years (November 1991 - November 2004). For all patients, we collected complete personal clinical history. All patients underwent standard neurotological examination, looking for spontaneous-positional, gaze-evoked and caloric induced nystagmus, using an infrared video camera. We also performed a head shaking test (HST) and an head thrust test (HTT). Ocular motility was tested looking at saccades and smooth pursuit. To exclude other significant neurological pathologies, a brain magnetic resonance imaging (MRI) with gadolinium was performed. During the three months after the first visit, patients were invited to keep a diary noting frequency, intensity and duration of vertigo attacks. After that period, we suggested that they use prophylactic treatment with flunarizine (5 mg per day) and/or acetylsalicylic acid (100 mg per day), or propranolol (40 mg twice a day). All patients were again recommended to note in their diary the frequency and intensity of both headache and vertigo while taking prophylactic therapy. Control visits were programmed after 4, 12 and 24 months of therapy. All patients considerably improved symptoms with therapy: 19 subjects (68%) reported complete disappearance of vestibular symptoms, while 9 (32%) considered symptoms very improved. The subjective judgement was corroborated by data from patients diaries. We conclude that EMV is a clinical variant of typical migraine-related vertigo: a migraine-associated vertigo, headache spell independent, following a headache period, during the lifetime of a patient.

KEY WORDS: Headache • Migraine vertigo • Epigone migraine vertigo • Motion sickness • Aura

RIASSUNTO

La cefalea emicranica è determinata da meccanismi patogenetici che possono interessare anche il sistema vestibolare, periferico e/o centrale, quindi la sintomatologia vestibolare può sostituire e/o manifestarsi insieme alla cefalea. Nei pazienti emicranici ci possono essere diverse manifestazioni di natura vestibolare, che rappresentano delle vere entità cliniche, diverse tra loro per le differenti caratteristiche e relazioni temporali con la cefalea. Su questa base abbiamo proposto una classificazione dei disturbi vestibolari correlati all'emicrania, e tra questi dovrebbe essere introdotta una variante particolare, la “vertigine emicranica epigona” (VEE): questa potrebbe essere un equivalente emicranico tardivo, cioè una vertigine di origine emicranica, che comincia tardivamente nella vita e che sostituisce, come equivalente, una cefalea emicranica preesistente. A questo proposito, riportiamo tre casi esemplificativi, scelti tra 28 pazienti selezionati durante un periodo di 13 anni (novembre 1991 – novembre 2004). Per tutti i pazienti è stata raccolta una dettagliata storia clinica. Tutti sono stati sottoposti ad un esame otoneurologico standard, per la ricerca del nistagmo spontaneo-posizionale, evocato da manovre oculari e provocato da stimolazione termica, usando una video-camera a raggi infrarossi. Abbiamo eseguito anche un head shaking test (HST) e un head thrust test (HTT). È stata valutata l'oculomotricità, con lo studio dei saccadici e dello smooth pursuit. Per escludere altre patologie neurologiche, è stata effettuata una risonanza magnetica nucleare (RMN) dell'encefalo con gadolinio. Durante i tre mesi dopo la prima visita, i pazienti sono stati invitati a compilare un diario, annotandovi la frequenza, l'intensità e la durata degli attacchi vertiginosi. Al termine di tale periodo, gli abbiamo consigliato di usare una terapia di profilassi con flunarizina (5 mg/die) e/o acido acetilsalicilico (100 mg/die), o con propranololo (40 mg x 2/die). Ancora una volta, abbiamo chiesto ai pazienti di annotare sul loro diario la frequenza e l'intensità sia della vertigine che della cefalea durante il trattamento. Le visite di controllo sono state programmate a 4, 12 e 24 mesi dall'inizio della terapia. In tutti i pazienti si è avuto un miglioramento considerevole della sintomatologia: 19 soggetti (68%) hanno riportato la scomparsa completa della sintomatologia vestibolare, mentre 9 (32%) consideravano i loro sintomi notevolmente migliorati, anche se non completamente risolti. Il giudizio soggettivo era supportato dai dati ricavati dai diari dei pazienti. Possiamo concludere che la VEE è una variante clinica della vertigine correlata all'emicrania: una vertigine emicranica, indipendente dalle crisi algiche, che segue il periodo della cefalea, nel corso della vita del paziente.

PAROLE CHIAVE: Cefalea • Vertigine emicranica • Vertigine emicranica epigone • Cinetosi • Aura

Introduction

Headache and vertigo are both very common complaints among internal medicine, neurological and neuro-otological patients; nevertheless, the frequency of the clinical association of vertigo and headache among migraine patients is too high to be justified only by chance ¹. It is a common opinion ² that migrainous headache is determined by pathogenetic mechanisms that are also able to affect peripheral and/or central vestibular structures: the consequence is that vestibular disturbances may substitute and/or present with headache.

Therefore, the hypothesis that migraine vertigo (MV) may be a real clinical entity seems, by now, confirmed ³. In fact, during the last decades some sorts of vertigo and dizziness associated with clinical syndromes typical of migrainous patients have been identified.

In 1961 Bickerstaff ⁴, for first, collected a series of young females complaining of vertigo, staggering and gait ataxia associated with other neurological disturbances like dysarthria, visual symptoms in both eyes, acroparesthesia, cranial nerve impairment and altered sensorium. In such a group of patients, the latter symptoms were followed by severe, occipital, throbbing headache associated with vomiting. This particular clinical picture was called "basilar artery migraine": it is the expression of functional disturbance of the brainstem, cerebellum and occipital cortex as a probable effect of a transient ischaemia in the distribution area of the basilar artery in migrainous subjects.

Basser, in 1964 ⁵, detected a kind of vertigo, typical of childhood, that he named "benign paroxysmal vertigo of childhood". It is characterized by sudden, recurrent brief vertigo attacks associated with nausea and pallor making the patient unable to move, with a serious inability to stand. Vertigo attacks are not associated with headache or impairment of consciousness. Paediatric patients usually have a clear family history for migraine and often develop true migraine headache after adolescence. Precocious vestibular symptoms are therefore considered as "precursors" of a migrainous headache (precocious canalar equivalent).

A similar manifestation is "benign torticollis of infancy", a clinical picture described by Snyder in 1969 ⁶, that develops during the first four years of life in some subjects with a clear family history of migraine. This manifestation seems to represent a "crisis" of the otolithic system induced by biochemical mechanisms of migrainous origin (precocious otolithic equivalent).

In 1979, Slater ⁷ described a "benign recurrent vertigo of adults", a vestibular syndrome characterized by recurrent spells of sudden and intense vertigo or unsteadiness associated with vagal symptoms. Such vertigo attacks occur in adults with migraine alternating with headache spells. In such patients, therefore, vertigo substitutes headache as migraine without headache, as described by Whitty ⁸, during the florid period of recurrent painful spells.

The International Headache Society (IHS), in the classification of the "ad hoc committee" of 1988 ⁹, took in account the practical issue of "migraine related vertigo". Vestibular disturbances occurring in patients suffering from migraine are separated in two groups: neuro-otological disorders that are "due" to migraine and those that are "associated" with it. The first group includes: (1) benign paroxysmal torticollis of infancy, (2) benign paroxysmal vertigo in childhood, (3) basilar artery migraine, (4) benign recurrent vertigo in adults and (5) migrainous infarct resulting in vertigo. The second group includes: (1) motion sickness, (2) Menière's disease and (3) benign paroxysmal positional vertigo. On the other hand, both the IHS and the international literature did not overcome this simple subdivision and did not propose an actual classification of vestibular symptoms that can occur in persons with migraine. In the IHS classification of 2004 ^{10 11} only two vestibular syndromes are listed: basilar type migraine and benign paroxysmal vertigo of childhood.

We are convinced that there are many different manifestations of vestibular disorders in patients with migraine, representing true different clinical entities due to their different characteristics and temporal relationship with headache. Based on such characteristics, our group has proposed a classification of vertigo and other vestibular disorders related to migraine ¹². Based on clinical experience acquired while evaluating and treating vestibular disorders occurring in patients with migraine, we believe that a particular variant of migraine-related vertigo should be introduced.

In November 1993, a woman affected by migraine without aura that suffered by intense and frequent headache spells since many years came to our attention. She referred that, during her lifetime, headaches began to decrease, while recurrent vertigo developed. In the patient's history, the temporal sequence of the two symptoms was so striking that it came to our immediate attention. During the following years, we encountered other patients complaining of recurrent vertigo after a period of headache had ceased, or that headache was markedly decreased in frequency and intensity.

To obtain a group of patients that was as clinically homogeneous as possible, we adopted rigorous selection criteria to include such patients in our case study.

The similarity of temporal succession of symptoms, typology of headache and vertigo spells, habitus, absence of any other definite vestibular pathology and negativity of general and neurological investigations that we noticed among our patients, lead us to consider such patients homogeneous enough to be grouped into a new nosological entity that we called "*Epigone migraine vertigo*" (EMV), from "epigonous" a term that means "borne after".

Such a pathology could therefore represent a type of late migraine equivalent that can be defined as a "*recurrent vestibular disorder occurring in migrainous subjects, ap-*

pearing late in their lives, substituting headache spells when the latter disappear or considerably reduce in frequency and strength, when (for women) patients are still in their fertile age or sometimes at menopause”.

To clarify this particular clinical picture we report three illustrative clinical cases.

Case 1: GS, female, 41 years old, date of visit 10.02.1995
Motion sickness since the age of 4 years, partially improved after puberty. Springtime vasomotorial rhinitis. No general disorders in personal pathological history. Mother and grandmother with migraine without aura, maternal aunt with migraine with aura.

Headache. Migraine headache without aura since the age of 20 years. Acute headache spells lasting from 3 to 8 hours, often throbbing, unilateral, with periorbital pain, always with phono/photophobia and nausea. Frequency: 3-5 episodes each month, always during pre-menstrual period. Headache got only partially better using common analgesics, more often ceasing spontaneously with sleep. Maximal intensity and frequency between 20 and 25 years. When the patient was 28, at the time of her first pregnancy, her headache completely disappeared.

Vertigo. Immediately after her pregnancy, during the 13 years before the visit, the patient started complaining of postural disturbances associated with instability in the upright position and nausea; each episode lasted from 6 to 48 hours, had an acute onset and a complete resolution, without any residual symptoms. Frequency: 2-4 episodes each year. During the month prior to the visit she had 5 episodes of imbalance, associated with nausea and vomiting and inability to stand, lasting 6-12 hours. Such episodes were just a little bit shorter but more intense than the former, and symptoms were worsened by any movement. Postural symptoms often improved with sleep. She came to visit because of worsening of symptoms.

Investigations. Cerebral magnetic resonance imaging (MRI), high resolution computed tomography (CT) scan, epiaortic Doppler sonography, electroencephalogram (EEG) and serologic tests were normal as were audiometric, vestibular and neurological exams. Audiological and vestibular tests remained negative during the follow-up period.

Therapy. Vestibular symptoms completely disappeared using migraine prophylactic drugs (acetylsalicylic acid 100 mg plus flunarizine 5 mg per day) during 4 years follow up.

Comments. Patient suffers from migraine without aura with high familial history. Headache disappeared with pregnancy and vestibular symptoms (imbalance and subjective rotatory vertigo) started immediately after it. The nine months of pregnancy represent, therefore, the free interval during which both symptoms were absent. After this period, migraine headache evolved into migraine-associated vertigo (late equivalent). Absence of other defi-

nite vestibular pathologies that could explain symptoms, negativity of audio-vestibular investigations and disappearance of symptoms with migraine prophylaxis confirmed diagnosis of EMV.

Case 2: ER, female, 47 years old, date of visit 24.03.1995
Motion sickness started during early childhood, hypotension since adolescence; no other significant subsequent pathology. Mother and maternal aunt suffered from migraine without aura; a son who suffered from paroxysmal torticollis of infancy at the age of 28 months.

Headache. Migraine headache since the age of 10 years; acute, throbbing headache crisis, with phono/photophobia and vomiting. Headache worsened with physical activity, it was rarely unilateral, it lasted from 2 to 48 hours and the maximal frequency of spells (2-3 per week) was between the age of 20 and 30 years. Only few episodes were preceded by visual aura involving both eyes (scotomata and flickering lights). Since June 1992 headaches became milder, very rare, only sometimes related with menstrual cycle.
Vertigo. July 1992: first rotational vertigo with vomiting and inability to stand, lasted 10 hours, started acutely and rapidly ceased without signs. A similar rotational attack, 6 hours long, occurred one month later. Since September 1992, 2-4 episodes per month of marked dizziness associated with nausea and intolerance to standing, lasting from 2 to 4 hours. Nearly half of vestibular crises were preceded by visual aura lasting 10-15 minutes.

Investigations. Cerebral MRI, epiaortic colour Doppler sonography, EEG and serological tests were normal. Neurologic examination and audiometry were normal. First vestibular testing showed a small amplitude down-beating nystagmus that was more pronounced in the sitting position. With the patient on a left lateral position, there was a small amplitude, persistent, right beating nystagmus. During follow up, after therapy, down-beating nystagmus was even less pronounced, while right-beating positional nystagmus disappeared.

Therapy. During 2 years prophylactic treatment with acetylsalicylic acid 100 mg plus flunarizine 5 mg, daily, recurrent postural disturbance was no longer present.

Comments. Patient had migraine with aura (fulfilling IHS criteria) with a clear familial component. She did not suffer from any other otologic or general pathology. Vestibular disturbances appeared immediately after the headache period was almost completely over; between the two symptoms there was no, therefore, any free interval. It has to be remarked that visual aura was more frequent before vertigo than before headache. Using migraine prophylactic treatment, dizziness and postural instability disappeared.

Case 3: AMG, female, 45 years old, date of visit 18.07.1996
Two normal pregnancies in patient's history; marked motion sickness during childhood; hypotension, as a current general pathology. Father suffering from migraine with

aura, paternal grandmother and a daughter suffering from migraine without aura.

Headache. Since puberty the patient suffered from migraine headache, often intense, unilateral and with a periorbital localization; pain was throbbing, accompanied by nausea and photophobia, exacerbated by physical activity.

Headache spells lasted 5-6 hours and were resistant to common analgesics, sometimes withdrawing with vomiting. When headache occurred during the menstrual period it was associated with bilateral aural fullness and tinnitus. Only a few headache spells lasted more than 12 hours. Frequency of attacks: 1-3 episodes each month. Only between the ages of 19 and 25 years did the patient have more than one spell per month. Eighteen months before the visit, at the beginning of the menopausal period, the patient referred a gradual reduction of headache intensity and frequency, until its disappearance.

Vertigo. Since 18 months, patient suffered from rotational vertigo that, during the first 3 months, were of the subjective type, associated with nausea and lasted from 30 min to 2 hours; vertigo spells occurred more than once a week and were followed by light and diffuse headache that could last many hours.

Investigations. Cerebral MRI with gadolinium, colour Doppler sonography, serological tests, neurologic examination were negative. Audiometry and vestibular exams were normal both at the first visit and during the follow-up period.

Therapy. During 3 years of prophylactic treatment with flunarizine 5 mg BID (she did not receive acetylsalicylic acid because of gastric intolerance) vestibular symptoms practically disappeared; only a light and rare sense of instability, during the menstrual period, persisted.

Comments. Patient suffered from migraine without aura and had a clear familial component for migraine. She did not suffer from any definite vestibular pathology that could explain vestibular symptoms. Headache gradually decreased at the beginning of the menopausal period, with the appearance of vestibular disturbances. Only during the first three months from the appearance of vertigo were vestibular symptoms followed by light headache. Afterwards, with the worsening of vertigo, the residual headache disappeared. Both headache and vertigo improved with vomiting. The effectiveness of prophylactic treatment confirmed a diagnosis of EMV.

Materials and methods

To have a higher probability to include in our case study only patients suffering from migraine-related vertigo, we adopted the following selection criteria:

1. subject suffering from migraine as identified by IHS criteria;
2. recurrent vertigo and/or postural disturbances;

3. onset of vestibular symptoms after the disappearance (or remarkable reduction) of headache;
4. absence of audiological and vestibular symptoms and signs having reference to definite neuro-otological pathologies;
5. negative neurological examination and cerebral MRI;
6. absence of any vascular pathology or vascular risk factor;
7. effectiveness of migraine prophylactic treatment (disappearance or marked reduction of vestibular symptoms);
8. at least 2 years of follow-up.

Considering these standards for inclusion, we collected 28 patients during an observation period of 13 years, roughly November 1991- November 2004.

Inclusion criteria and purpose of the study were already determined since the first cases, and were maintained during the entire collection period. Therefore, our study was prospective. We collected a homogeneous group of patients sharing some characteristics that are specific for such a pathology.

The strict selection criteria allows us to affirm that patients with a different vestibular pathology would not have been included in the present case study.

For all patients we collected complete personal clinical history, including family, remote and near pathological history. Particular attention was given in collecting the history regarding headache and vestibular disturbances.

We looked into the migrainous habitus searching for migrainous manifestations in infancy (benign vertigo, paroxysmal torticollis and motion sickness).

Firstly, we made us sure that patients suffered from headache fulfilling migraine criteria as stated by the IHS. Afterwards, concerning headache, we determined: a) age of onset, duration and frequency; b) presence or absence of aura; c) family history.

Regarding vestibular symptoms, we determined: a) age of onset; b) type of vestibular symptom (rotational objective or subjective vertigo or postural troubles); c) duration, intensity and frequency of spells; d) presence or absence of associated vagal symptoms; e) temporal trend of symptoms.

Afterwards, we defined the temporal relationships between headache and vertigo periods over the patient's lifetime; we asked patients to point out one of the following possible temporal relationships: a) between headache and vertigo periods there was a symptom free interval; b) the two symptoms came one after the other, without any interval; c) vertigo gradually took place together with headache. Moreover, we asked to females if the passage of one symptom into the other coincided with the menopausal period.

Furthermore, we asked all patients if at the time of the beginning of the period of vertigo their headache was: a) completely vanished; b) residual but reduced; c) only fairly reduced; d) nearly unchanged.

The persistence of a moderately reduced or unchanged headache lead us to exclude such patients from the study. Finally, during follow-up, we asked patients if, using prophylactic treatment, their vestibular symptoms were: a) completely vanished, b) residual but reduced; c) only fairly reduced; d) unmodified. The persistence of an unmodified (or only partially reduced) vertigo led to exclusion from the study.

We also asked patients if they had ever had audiological symptoms such as hearing loss, unilateral or bilateral tinnitus or fullness, together with vertigo or independently of from it.

Oto-microscopy was performed for all patients in addition to pure tone audiometry and impedance testing.

All patients underwent standard neurotological examination. Vestibular spontaneous-positional nystagmus was checked in seven positions (sitting, supine, right side, left side, head hanging, right and left Dix-Hallpike's) using an infrared video camera. Gaze evoked nystagmus was also checked with the same modalities. Moreover, we performed a head shaking test (HST) and a horizontal head thrust test (HTT) to test vestibulo-ocular reflex (VOR) to higher frequencies with respect to caloric stimuli.

Caloric induced nystagmus was investigated using Fitzgerald-Hallpike's technique. To calculate labyrinthine and directional preponderance, we applied Jongkeens' formulae considering, as a reference parameter, the slow phase angular velocity of caloric-induced nystagmus. Reference normative data were those indicated by Baloh¹³. Ocular motility was tested looking at horizontal and vertical saccades velocity, accuracy and latency and horizontal and vertical smooth pursuit gain¹⁴. Both ocular motility and caloric nystagmus were recorded using computed electronystamography.

All patients underwent a neurological visit to exclude other significant neurological pathologies that could justify both headache and vertigo. Moreover, for all patients, we carried out haematological workup, especially concerning vascular risk factors, as well as colour Doppler sonography of carotid and vertebral arteries and brain MRI with gadolinium.

During the three months after the first visit, patients were asked to keep a diary noting frequency, intensity and duration of vertigo attacks. In case of crises they should use only symptomatic drugs (antiemetics, anxiolytics).

After that period, we prescribed prophylactic treatment with flunarizine and acetylsalicylic acid. The suggested doses for flunarizine and acetylsalicylic acid were, respectively, 5 mg and 100 mg per day.

If patients could not take acetylsalicylic acid for a gastric or other pathology, they were prescribed only flunarizine at 10 mg per day. On the other hand, if patients had some contraindications to flunarizine (obesity, depression) and/or significant side effects (i.e. drowsiness), they were treated only with acetylsalicylic acid at 100 mg BID.

Moreover, if patients could not take either drug, we prescribed, as prophylactic therapy, propranolol at 40 mg BID. All patients were again asked to record in their diary the frequency and intensity of both headache and vertigo while taking prophylactic therapy.

Control visits were programmed after 4, 12 and 24 months of therapy. Informed consent was obtained from all patients.

Results

Subjects

Our case study of patients affected by EMV includes 28 subjects (23 females and 5 males): their mean age, at the first visit to our clinic, was 43 years, with a minimal age of 18 and a maximal age of 64 (SD: 11.9, mode: 45). The mean age at the onset of headache was 18 years (min: 8, max: 38; SD 7.4, mode 15); the mean age at the onset of vestibular symptoms was 38 years (min: 16; max 55; SD: 11, mode: 46). Thus, EMV occurs after a mean headache period of 20 years. In more of 70% of patients vertigo started between 26 and 46 years, but among them, in half of cases, its onset peak is concentrated into the fourth decade (40-46 years). There was no difference between females and males concerning the age of onset of headache and vertigo or the interval between the periods of the two symptoms.

Headache

Twenty-two patients (78%) had migraine without aura and 6 (22%) suffered from migraine with aura. No patient suffered from any other type of migraine included in the definitions of the IHS. Among the 6 patients affected by migraine with aura, in one patient visual aura anticipated EMV spells more often than those of headache. In another patient migraine with aura first changed into migraine without aura (roughly along a period of 2 years) and was then substituted by EMV (without aura). Among the remaining 4 patients, as vertigo began headache disappeared together with the aura in three, and it markedly decreased in one.

Twenty-two of 28 patients affirmed to have or to have had motion sickness during their lifetime, at least during infancy. Twenty-five subjects out of 28 had a clear family history of migraine.

Vertigo and dizziness

Vestibular disturbances in our patients were very different in terms of type, duration and frequency. We found that patients suffered both from objective and subjective rotational vertigo and postural imbalance. Vestibular symptoms were very different among subjects, while in the same patient they presented more similar in terms of quality, varying only in duration and intensity. In fact, 17 patients (61%) always reported the same type of vertigo:

10 subjects (36%) had only objective rotational vertigo, 4 (14%) had only postural disturbances and 3 (11%) had only subjective crises of rotational vertigo. In the remaining 11 patients (39%), at least two types of vestibular symptoms were associated; only in three patients did vestibular disturbances manifest with all the three kinds of vestibular symptoms (objective and subjective vertigo and postural disturbance). In any case, objective rotational vertigo, alone or associated, was referred by more than half of patients: in fact, true objective vertigo was reported by 18 patients: vertigo alone, in 10 patients, vertigo alternating with subjective crises or postural imbalance, was seen in 8 subjects.

The duration of the individual crisis was highly variable (Fig. 1): objective vertigo lasted, on the average, 15 hours (min 1/2 hour - max 3 days), while postural disturbances usually were longer, with a mean duration of 73 hours (min 1 hour - max 10 days). The mean duration of postural spells was reached by only a few subjects who had particularly prolonged crises. In individual patients also, duration of crises was variable, and was always shorter for objective spells compared to subjective ones. Accompanying vagal symptoms were present in all patients together with stronger crises; they were less severe in 11 patients (only nausea) and more pronounced (nausea and vomiting) in 18 of the 28 subjects.

Almost all patients reported that head movements worsened both vestibular and neurovegetative symptoms. Most patients returned to a relative well-being after the attack had ceased; a few subjects (7 of 28) had transient residual unsteadiness for a few days.

The mean frequency of spells (considering period of maximum incidence) varied from a minimum of one crisis every 6 months to a maximum of 5 spells each month.

Only 2 patients were diagnosed as having a possible vestibular migraine, whether the other 26 had a diagnosis of Menière's disease, vestibular neuritis, benign paroxysmal positional vertigo and psychogenic vertigo. Twenty of 28 patients complained of kinetosis during adult life, childhood or both, and 17 suffered from hypotension.

Headache versus vertigo

In our case studies, the shift of headache into vestibular symptoms, over a patient's lifetime, occurred according to three different patterns (Fig. 2): 1) with a variable free interval from both patterns; 2) headache shifted directly into vertigo without a free interval; 3) headache gradually changed into vertigo with a period during which both symptoms are present.

Transition with a free interval was reported by 8 patients (28.5%); in one case, the free interval coincided with pregnancy and, in other two, with menopause. Twelve patients (43%) reported the second modality of transformation, i.e. direct transformation of headache into vertigo: in 4 cases transformation occurred during menopause. Finally, 8 patients (28.5%) referred the gradual shift of the two symptoms, sensing a partial overlap. These patients therefore noticed a gradual reduction of headache and, at the same time, the worsening of vestibular disturbances until there persistence (or clear prevalence) of vertigo. Half of these patients noticed that the shift of the two symptoms occurred during menopause.

Among the 23 females in our case study, in 10 cases (43.5%) headache shifted into vertigo at menopause or immediately after it. In one case, such a shift occurred after pregnancy and in the remaining 12 cases (52%) it occurred during the fertile age.

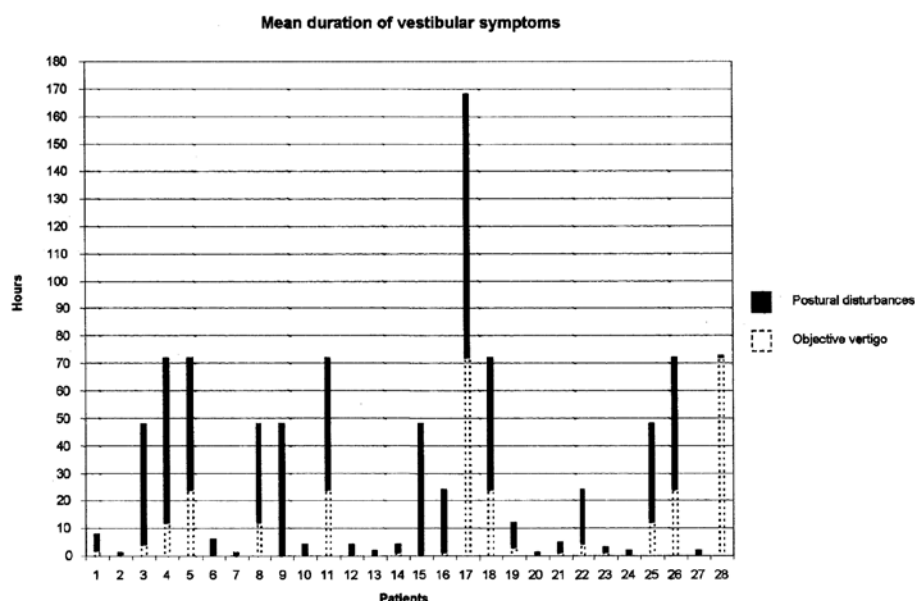


Fig. 1. Reported duration of vestibular crisis in our case study: for each patient, the mean duration of postural disturbances (black histogram) and objective vertigo (dotted histogram) is given.

Residual headache

Once headache changed into vertigo, 16 patients (57%) reported that headache completely ceased, while 12 subjects (43%) noticed substantial improvement of this headache (only a light headache often limited to menstrual period) that became a minor disturbance compared with vertigo.

It should be noted that while in the group of patients with gradual transformation of the two symptoms, a light headache was still present in 6 of 8 subjects; in the group of patients with a symptom-free interval, such a residual symptom was present in only 6 of 20 cases.

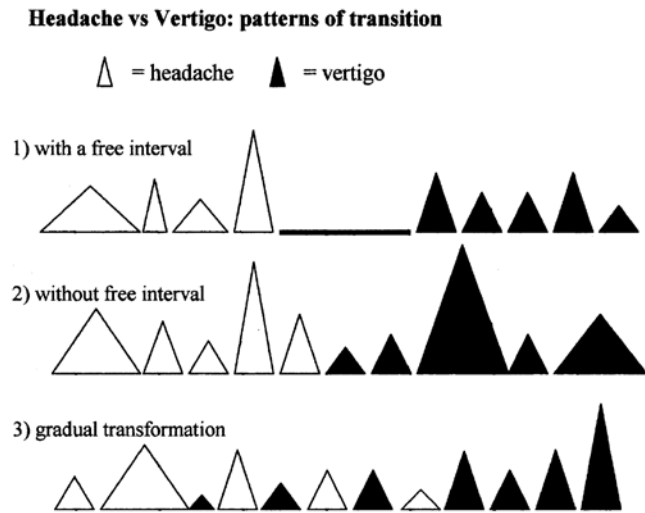


Fig. 2. Headache vs. vertigo: patterns of transitions of the two symptoms over the course of a lifetime. Height and width of triangles indicate, respectively, the strength and duration of headache or vertigo spells.

Audiological symptoms

Bilateral (6) or unilateral (2) fullness was reported by 8 patients, during almost all vertigo attacks; these symptoms ceased as vertigo disappeared. Five patients reported tinnitus that also continued after a vertigo spell in only one case. Three patients had associated tinnitus and fullness.

Audiometry and impedance testing

Twenty-one of 28 patients had normal audiometric and impedance exams. Three subjects had mild conductive hearing loss (1 tympanosclerosis, 2 myringosclerosis) and three had a high frequency sensorineural hearing loss.

Vestibular testing

Only 4 patients had a spontaneous-positional nystagmus. One patient, at the first visit, had a pluri-positional down-beating nystagmus associated with a right-beating nystagmus in the left lateral position: at follow-up visits, during prophylactic treatment, right horizontal nystagmus disappeared while down-beating nystagmus remained, even if reduced in amplitude. One patient had down-beating nystagmus in all clinical positions that remained unchanged during follow-up. Another subject had a slight geotropic, persistent nystagmus on the left and right lateral positions: this sign disappeared after one year of follow-up (this patient also had unilateral labyrinthine weakness). One patient had a horizontal spontaneous left beating nystagmus only on the right lateral position that decreased in amplitude with time. Moreover, during caloric tests 19 patients (68%) showed a significant vagal reaction with nausea and vomiting. Only one patient had a unilateral labyrinthine failure (associated with a spontaneous nystagmus of the central type) and one subject had unilateral

labyrinthine weakness, without spontaneous-positional nystagmus. None of our patients was evaluated during the acute phase of vertigo.

Pharmacological prophylaxis

All 28 patients were treated using a prophylactic regimen: 22 took acetylsalicylic acid 100 mg per day and flunarizine 5 mg per day; 3 patients took propranolol 40 mg BID, because of contraindication to both acetylsalicylic acid and flunarizine; 3 patients took only flunarizine at a dose of 5 mg BID because of contraindication to acetylsalicylic acid.

Symptoms considerably improved in all patients with therapy (failed improvement was an exclusion criteria). Nineteen subjects (68%) reported the complete disappearance of vestibular symptoms, while 9 (32%) considered their symptoms very much improved even if not completely resolved.

Subjective judgement was corroborated by data extracted from diaries during the three months before and after the beginning of prophylactic therapy. Four patients were excluded from the case series due to unsatisfactory response to therapy (therapeutic failure was considered as a marker of a diagnostic error).

Discussion and conclusions

In the literature there is no mention of the existence of a structured survey of EMV: a type of vertigo, migrainous in origin, starting late in lifetime that substitutes, as an equivalent, a pre-existing migrainous headache. On the other hand, several authors have noted that some migraine patients, suffering from headache in a young or adult age, also suffered from recurrent vertigo later in their lives.

In 1985, Hood and Kayan¹⁵ stated: "we have recently seen a number of patients at the National Hospital Queen Square of London, whose migrainous attacks ceased after middle age, giving way to recurrent attacks of vertigo". A belated transformation of headache into vertigo in migrainous women at menopause was also reported by Harker in 1996¹⁶; the author wrote: "many older women, who had severe migraine headache earlier in their lives that had become much milder after menopause, postmenopausally, however, begin to experience episodic vertigo, sometimes with accompanying mild headache".

Similarly, in 1961 Atkinson¹⁷ observed a temporal relationship between migraine headache and Menière's disease: "a frequent story told by the Menière's patient is that he suffered from migraine all his life, but that when the dizzy attacks began, his headache ceased". Such a correlation was confirmed by Toglia in 1981¹⁸: "attacks of vertigo typical of Menière's disease may replace, usually later in life, the attacks of migraine".

Even if occasional and brief, these literature annotations prompted us to look for such patients in daily clinical

activity: subjects suffering from vestibular migraine in which vertigo could represent a late equivalent of their migraine headache. The first patient satisfying these criteria was found in November 1993.

Examining the previous reports of patients in our survey, not only was no temporal relationship noted between headache and vertigo, but a diagnosis of vestibular migraine was not presumed in 26 of 28 cases.

The extended suffering of these patients lead us to two considerations: 1) the diagnosis of vestibular migraine is too often neglected by general practitioners and, sometimes, by neuro-otologists as well; 2) patients with vestibular migraine do not have improvement of symptoms with drugs other than those indicated in migraine prophylaxis. Therefore, also for EMV, we agree with Dieterich and Brandt¹⁹ when they state that in subjects suffering from vestibular migraine there are “difficulties in defining the disease and frustrating attempts to treat these patients”. During 9 years of EMV case selection, we never encountered patients suffering from any type of primary headache (cluster, tension or occasional headache) other than migraine and whose vestibular symptoms manifested in substitution of headache. Hence, EMV could represent a typical manifestation solely of primary migraine headache.

Particularly interesting is the clinical fact that in spite of the long duration of vestibular symptoms before diagnosis (at least 10 years in 6 patients and three years in 16 cases), none of our patients had another transformation of the vestibular disturbance into headache or into another migraine equivalent; therefore, vestibular symptoms of patients with EMV appear to represent the last delayed manifestation of their migrainous habitus. Hence, EMV does not seem to be a temporary conversion, but rather a definite conversion of migrainous symptoms.

With the intent of comparing benign paroxysmal vertigo of childhood and EMV, we can affirm that the former is the first kind of migrainous vertigo that will often give rise, later, to migraine headache²⁰, whereas the latter is the last manifestation of a migrainous vertigo that will substitute migraine headache. Therefore, the two forms of vertigo could be, respectively, the first and the last migraine equivalent, as shown in migraine classification that we proposed in 2003¹².

In our EMV survey we collected 25 cases of migraine without aura and 3 with aura: such a distribution seems to represent the reported prevalence of the two forms in migraine population. Thus, the presence or absence of an aura does not seem to favour the evolution towards EMV. Moreover, among our patients there was a clear prevalence of females over males, thus reflecting the female prevalence of migraine headache.

Ten of 23 females (43.5%) in our case study had transformation of migraine headache into EMV during or immediately after menopause; in the remaining 13 women,

such a transformation manifested during the fertile age. Menopause therefore seems to be a facilitating and not a decisive factor for the transformation of migraine headache into EMV. Almost all patients experienced recurrent attacks of vertigo, belatedly and unexpectedly manifested, as more severe and disabling than the previous headache. In patients with EMV, current or pre-existing motion sickness, hypersensitivity to rapid head movements and an intense vagal reaction to vestibular instrumental stimuli (caloric and rotational) were very common complaints; they showed particular hypersensitivity and, consequently, intolerance to vestibular stimulation. When not experiencing a crisis, in spite of the large number of attacks of vertigo or postural disturbances that patients referred, neuro-otologic investigation was, very often, negative.

Among our patients we found a remarkable polymorphism of vestibular symptoms (objective and subjective vertigo, dizziness); various types of symptoms were also reported also by the same patients in different occasions. Many of the characteristics of EMV are thus very similar to those reported by Dieterich and Brandt¹⁹ for 90 patients with vertigo related to migraine.

In young patients suffering from migraine, recurrent episodes of vertigo, both quantitatively and qualitatively polymorphic, also long-lasting and without associated relevant clinical cochleo-vestibular signs, diagnosis of migraine-associated vestibulopathy is very probable, in agreement with Baloh's statement²¹: “when recurrent attacks begin at an early age in a patient with normal hearing and migraine there are a few diagnosis other than migraine that need to be considered”; the same consideration goes for EMV.

We conclude that EMV is a clinical variant of typical migraine-related vertigo: a migraine-associated vertigo, headache spell independent, following the headache period, over the course of a lifetime.

References

- Lempert T, Neuhauser H. *Epidemiology of vertigo, migraine and vestibular migraine*. J Neurol 2009;256:333-8.
- Cutrer FM, Baloh RW. *Migraine-associated dizziness*. Headache 1992;32:300-4.
- Neuhauser H, Lempert T. *Vertigo and dizziness related to migraine: a diagnostic challenge*. Cephalalgia 2004;24:83-91.
- Bickerstaff ER. *Basilar artery migraine*. Lancet 1961;1:15-7.
- Basser LS. *Benign paroxysmal vertigo of childhood*. Brain 1964;87:141-52.
- Snyder CH. *Paroxysmal torticollis in infancy*. Am J Dis Child 1969;117:458-60.
- Slater R. *Benign recurrent vertigo*. J Neurol Neurosurg Psychiatry 1979;42:363-7.
- Whitty CWM. *Migraine without headache*. Lancet 1967;2:283-5.

- ⁹ Headache Classification Committee of the International Headache Society. *Classification and diagnostic criteria for headache disorders, cranial neuralgias and facial pain*. Cephalalgia 1988;8(suppl 7):1-96.
- ¹⁰ Headache Classification Subcommittee of the International Headache Society. *The international classification of headache disorders*. Cephalalgia 2004;24(suppl 1):1-160.
- ¹¹ Farri A, Enrico A, Farri F. *Headaches of otolaryngological interest: current status while awaiting revision of classification. Practical considerations and expectations*. Acta Otorhinolaryngol Ital 2012;32:77-86.
- ¹² Pagnini P, Verrecchia L, Giannoni B, et al. *La vertigine emicranica (VE)*. Acta Otorhinolaryngol Ital 2003;23:19-27.
- ¹³ Baloh RW, Honrubia V. *Clinical Neurophysiology of the Vestibular System*. New York: Oxford University Press; 2001. p. 152-71.
- ¹⁴ Tirelli G, Rigo S, Bullo F, et al. *Saccades and smooth pursuit eye movements in central vertigo*. Acta Otorhinolaryngol Ital 2011;31:96-102.
- ¹⁵ Hood JD, Kayan A. *Neurotology and migraine*. In: Blau NJ ed. *Migraine*. Philadelphia: FA Davis Company; 1985. p. 597-624.
- ¹⁶ Harker LA. *Migraine-Associated Vertigo*. In: Baloh RW, Halmagyi GM, editors. *Disorders of the Vestibular System*. New York: Oxford University Press; 1996. p. 407-417.
- ¹⁷ Atkinson M. *Migraine and Menière's disease*. Archives of Otolaryngology 1962;75:46-51.
- ¹⁸ Toglia JU, Thomas D, Kuritzky A. *Common migraine and vestibular function: electronystagmographic study and pathogenesis*. Ann Otol Rhinol Laryngol 1981;90:267-271.
- ¹⁹ Dieterich M, Brandt T. *Episodic vertigo related to migraine (90 cases): vestibular migraine?* J Neurol 1999;246:883-92.
- ²⁰ Lanzi G, Balottin U, Fazzi E, et al. *Benign paroxysmal vertigo of childhood: a long-term follow-up*. Cephalalgia 1994;14:458-60.
- ²¹ Brantberg K, Trees N, Baloh RW. *Migraine-associated vertigo*. Acta Otolaryngologica 2005;125:276-9.

Received: August 4, 2013 - Accepted: September 23, 2013

Address for correspondence: Rudi Pecci, Department of Surgical Sciences and Translational Medicine, Unit of Audiology, Careggi Hospital, University of Florence, largo Brambilla 3, 50134 Florence, Italy. Tel. +39 055 411076. Fax +39 055 430253. E-mail: rudi-pecci@infnito.it

CASE SERIES

Can lateral semicircular canal dysplasia play a role in the genesis of hyperacusis?

La displasia del canale semicircolare laterale può avere un ruolo nella genesi dell'iperacusia?

G.C. MODUGNO, C. BRANDOLINI

Department of Experimental, Diagnostic and Specialty Medicine, University of Bologna

SUMMARY

Hyperacusis can be a prominent and disabling symptom of superior semicircular canal dehiscence associated with autophony and the Tullio phenomenon. We report three clinical cases characterized by disabling hyperacusis in which semicircular canals dehiscence was excluded by temporal bone high-resolution computed tomography. The images disclosed lateral semicircular canal dysplasia, characterized by a small bony island, and dilatation of both the anterior and the posterior arms of the lateral semicircular canal. Cochleo-vestibular examinations (pure tone audiometry, infra-red videonystagmoscopy, vibration-induced nystagmus test, vestibular evoked myogenic potentials) will also be described. To verify the transtympanic ventilation tube effect, bilateral myringotomies tubes were performed in one patient but no long lasting subjective benefit was noted. Concerning the pathophysiology of this condition, we hypothesized that the increased volume of inner ear liquid can modify the micromechanical function of the cochlea and the labyrinthine hydrodynamics. In conclusion, in the case of specific symptoms, such as hyperacusis, it is important to consider the possibility of an inner ear morphological alteration involving the lateral canal and vestibule structures, as well as the existence of bony semicircular canal dehiscence.

KEY WORDS: Hyperacusis • Inner ear malformation • Lateral canal dysplasia • Semicircular canal dehiscence • Vestibular aqueduct

RIASSUNTO

L'iperacusia può rappresentare un importante ed invalidante sintomo della deiscenza del canale semicircolare superiore, associato ad autofonia ed al fenomeno di Tullio. Riportiamo tre casi clinici caratterizzati da iperacusia invalidante in cui deiscenze dei canali semicircolari furono escluse dallo studio TAC ad alta risoluzione delle rocche petrose. Lo studio radiologico rilevò una displasia del canale semicircolare laterale, caratterizzata da una isola ossea ridotta e dilatazione sia del braccio anteriore che di quello posteriore. Descriveremo gli elementi provenienti dalle indagini cocleo-vestibolari effettuate (esame audiometrico tonale liminare, videoculosopia, test vibratorio mastoideo, studio dei potenziali evocati vestibolari miogeni). In un paziente è stato tentato un trattamento con drenaggio transtimpanico bilateralmente senza alcun beneficio duraturo. Per quanto concerne la fisiopatologia del fenomeno, noi ipotizziamo che l'aumento di volume dei liquidi dell'orecchio interno possa modificare la micromeccanica della coclea e l'idrodinamica labirintica. Concludendo, in caso di un sintomo specifico come l'iperacusia, è importante considerare la possibilità di una malformazione che coinvolga il canale semicircolare laterale e il vestibolo tanto quanto una deiscenza della capsula otica.

PAROLE CHIAVE: Iperacusia • Malformazione dell'orecchio interno • Displasia del canale laterale • Deiscenza del canale semicircolare • Acquedotto vestibolare

Acta Otorhinolaryngol Ital 2014;34:71-74

Introduction

Hyperacusis is an auditory condition characterized by hypersensitivity and decreased tolerance to sounds, frequently concerning a definite range of frequencies¹. Patients with hyperacusis are also disturbed by low daily sounds, such as normal conversation, running water, flipping through pages, cooking, etc. Hyperacusis is frequently associated with tinnitus and emotional distress (above all anxiety)².

Although hyperacusis can be due to several pathologic conditions, some of which affect the neurological path-

way (head injury, migraine, Lyme Disease, Williams syndrome) or the psychological/psychiatric apparatus (autistic spectrum disorders, chronic fatigue syndrome, fibromyalgia), it can also be part of the clinical spectrum of auditory and vestibular disorders^{1,2}. For example, it is a symptom described in acoustic shock injury, Meniere's disease, otosclerosis, perilymphatic fistula and Bell's Palsy, and can represent a prominent and disabling symptom of superior semicircular canal dehiscence (SSCD) associated with autophony and the Tullio phenomenon³. No other inner ear malformations associ-

ated with hyperacusis have been described in the English literature.

In the present report, three clinical cases characterized by disabling hyperacusis in which SSCD was excluded by temporal bone high-resolution computed tomography (HRCT) will be described. The images disclosed lateral semicircular canal (LSC) dysplasia, characterized by a small bony island, and dilatation of both the anterior and the posterior arms of the LSC.

Patients

Brief case histories of three patients with hyperacusis are herein presented. Standard clinical neuro-otological assessment was normal in all three patients. Otoscopy, pure-tone audiometry and acoustic reflexes established the existence of normal hearing function (no evidence of sensorineural, conductive or mixed hearing loss). Infra-red videonystagmoscopy did not reveal either spontaneous or evoked nystagmus (head pitch test, Hallpike manoeuvre, bilateral mastoid 100 Hz-vibration, head shaking test and Valsalva manoeuvre with pinched nostrils).

Each patient was screened to exclude central nervous system and VIII cranial nerve enhancing lesions using contrast-enhanced brain MRI.

The temporal bone HRCT, performed on a multi-slice GE Medical Systems scanner, was completed by reformatted images (at 0.3 mm increments) along the Pöschl plane (parallel to the superior semicircular canal) and Stenver plane (perpendicular to the superior semicircular canal).

Patient 1

A 39-year-old man presented to our hospital complaining of a continuous sensation of hyperacusis of three years' duration, following an acoustic trauma (disco music exposition). Auditory symptoms, including left tinnitus, were also present. The anamnesis disclosed interesting elements, such as considerable intolerance to low sounds and vibrations, such as traffic, rain, background office noise, humming from the refrigerator, etc. He denied having had any notable cranial trauma in the past or a history of migraine headaches. In extreme situations, even the use of earplugs failed to bring relief and the patient had been spending his life trying to avoid all sounds and just staying at home. No vestibular symptom was present in his clinical history. Medical therapy was ineffective in relieving the tinnitus and hyperacusis. Pure tone audiometry established a normal hearing function in absence of negative bone conduction thresholds bilaterally.

The cochleo-vestibular evaluation was completed by cervical air-conducted vestibular evoked myogenic potentials (C-AC-VEMPs) testing which showed a normal threshold bilaterally (120 dB SPL). A very recent bithermal caloric test showed right canalar hypofunction.

Visual inspection of the temporal bone HRCT images dis-

closed a normal inner ear. However, careful analysis of the CT images excluded SSCD while disclosing the presence of bilateral dysplasia of the LSC (Fig. 1a). Both the cochlea and the vestibular aqueducts appeared normal in shape.

Patient 2

A 70-year-old man presented to our hospital with a history of recurrent benign positional paroxysmal vertigo (BPPV) following a mild cranial trauma that occurred five years earlier; the BPPV involved the left posterior semicircular canal. The patient also described bilateral fullness, but pure tone audiometry established a slight age-related hearing loss bilaterally.

When he had undergone vestibular examination, particularly during bone conduction VEMPs testing (500 Hz TB, 6 msec, 1.0 V – delivered to each mastoid by a hand-held minishaker with an attached perspex rod [type 4810, Bruel and Kjaer P/L, Denmark]), he had vertigo and subsequent dizziness for some days thereafter. Since then, he had experienced disabling autophony resulting in difficulties in holding conversations, and hyperacusis associated with bilateral tinnitus and fullness. No other symptoms were reported. A normal threshold bilaterally (120 dB SPL on the right side and 115 dB SPL on the left side) was observed with C-AC-VEMPs testing. A bithermal caloric test was attempted, but the patient was unable to tolerate it.

Temporal bone HRCT scans excluded the presence of dehiscence of the otic capsule, even if we noted a thinning of the cortical bone at the right arcuate eminence. Additional careful analysis of axial CT images disclosed the presence of bilateral LSC dysplasia (Figs. 1b, c). In order to relieve the hyperacusis and tinnitus, a bilateral myringotomy with ventilation tube insertion was carried out, after which the patient immediately noted relief from the tinnitus. However, the original condition returned a few months later, with bilateral fullness and intense hyperacusis.

Patient 3

A 47-year-old female presented with a five-year history of transitory pulsating left tinnitus without hearing loss or vestibular symptoms. She described a long episode of acute and intense hyperacusis after having flown in the past. Pure tone audiometry established normal hearing function in the absence of negative bone conduction thresholds bilaterally.

A C-AC-VEMPs study showed normal inner ear impedance (115 dB SPL threshold bilaterally). A bithermal caloric test was attempted, but the patient was unable to tolerate it.

Temporal bone HRCT excluded inner ear malformations. However, a detailed axial CT study analysis carried out at our institution disclosed bilateral LSC dysplasia, in the absence of cochlear malformations. Moreover, the right high-riding jugular bulb showed slight dehiscence towards the vestibular aqueduct (Fig. 1d).

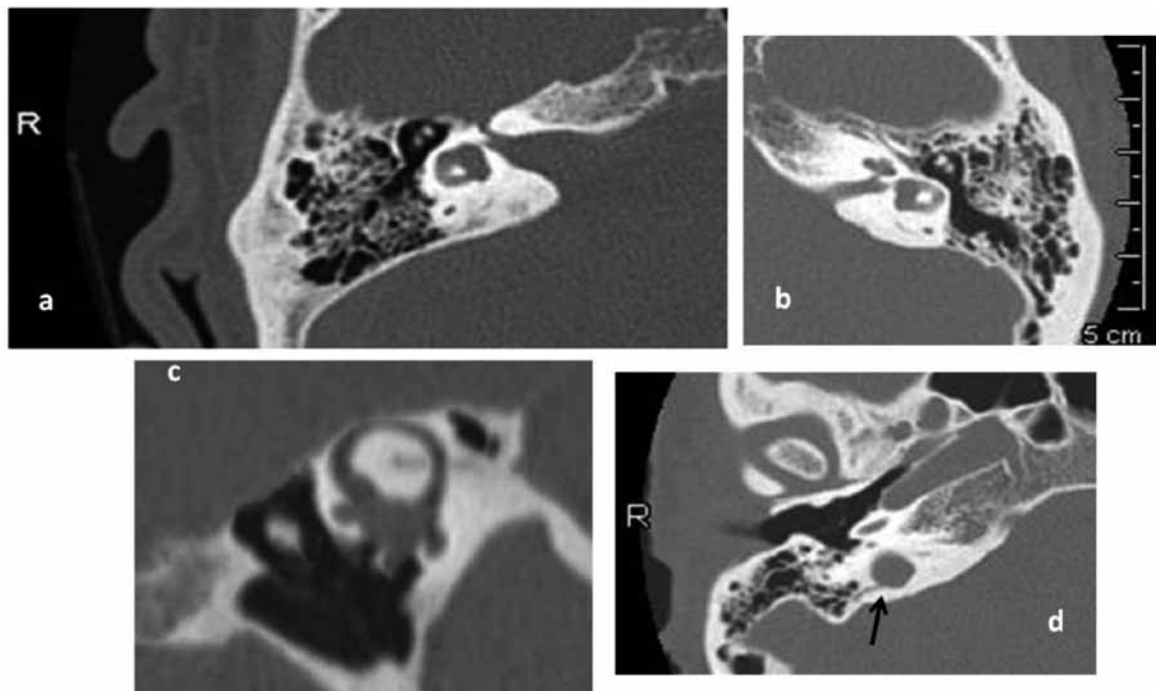


Fig. 1. Temporal bone HRCT showing inner ear in of our series.

a) The axial CT sections of the right temporal bone of case 1, at the level of the internal auditory canal, show the LSC dysplasia; the small LSC bony island and the wide vestibule are clearly evident. b) The axial CT sections of the left temporal bone of case 2, at the level of the basal cochlear turn, show the LSC dysplasia: the lumen of the LSC anterior arm, like that of the posterior arm, is dilated. c) Temporal bone reformatted oblique CT images in the Pöschl plane (parallel to the right superior semicircular canal) of case 2, demonstrating the integrity of the cortical bone at the right arcuate eminence, even if thinner than normal. d) The axial CT sections of the right temporal bone of case 3, at the level of the basal cochlear turn, show the vestibular aqueduct erosion by the jugular bulb (black arrow).

Discussion

Hyperacusis, especially in the case of somatosounds, is a typical finding of SSCD in association with a Tullio phenomenon and autophony³. Over the past 10 years we have identified 176 cases of SSCD, of which about 48% of patients had hyperacusis together with their cochlear symptoms. As a result, every time a patient describes hyperacusis in his/her clinical history, we recommend a temporal bone HRCT completed with reformatted images along the superior and posterior semicircular canals planes to look for the presence of a “third mobile window”, such as SSCD.

Apart from SSCD, to our knowledge, there are no reports in the literature describing other inner ear malformations that are responsible for hyperacusis. We have identified three cases of disabling hyperacusis in which radiologic exam excluded the presence of semicircular canal dehiscence (superior, posterior and lateral canals) and vestibular aqueduct enlargements, allowing the detection of bilateral dysplasia of the LSC canal and vestibule. As for patient 2, we actually identified a thinning of the cortical bone overlying the right superior semicircular canal, which could not be completely excluded as being responsible for both the long history of left posterior semicircular canal involvement by BPPV (positioning nystagmus very similar to SSCD) and the hyperacusis⁴.

In the CT images of patient 3, we identified a small erosion of the right vestibular aqueduct by an enlarged jugular bulb, a condition which has been described to have features similar to SSCD, such as conductive hearing loss associated with normal C-AC-VEMPs⁵. However, patient 3 had normal hearing function and a normal C-AC-VEMPs threshold; therefore, the third window effect could be excluded.

In any case, the radiologist reported LSC malformation. Through a later T2-MR images analysis, we confirmed the LSC malformation in spite of any description by radiologists.

We therefore confirm, as has already been stated by other authors, that LSC dysplasia may be missed by simple visual inspection of radiologic images, especially if cochlear or vestibular aqueduct malformations, frequently associated findings, are absent⁶. In the axial CT images, the LSC bony island diameter, the lumen of the anterior and the posterior arms and the vestibular shape should always be examined carefully⁷. In cases of dilation both the anterior and the posterior arms, the LSC is called dysplastic (or hypoplastic) whereas, in cases of absent or rudimental LSC, it is called aplastic. However, the possibility of a partial malformation with dilation involving only one canal arm (anterior or posterior) has also been described; in these cases, the cochlea is normal while, in case of posterior

arm dilation the vestibular aqueduct, is often enlarged^{8,9}. According to Sennaroglu and Saatci¹⁰, LSC dysplasia is considered a minor dysmorphology belonging exclusively to vestibular labyrinthine malformations.

The results of several studies have not shown any consistent relationship between LSC bony island hypoplasia and hearing loss. Indeed, hearing function can be normal or impaired by pure sensorineural or pure conductive or mixed hearing loss⁸⁻¹³, similar to the absence of a direct correlation between a large vestibular aqueduct and hearing loss¹⁴. As for vestibular function, few reports have examined the vestibular symptoms of these patients, but similar to hearing function, no correlation between the severity of the canal and the vestibule malformations and vestibular impairing exists¹⁵. Nevertheless, no study in the literature has reported cases of hyperacusis associated with LSC aplasia and/or dysplasia. Concerning the pathophysiology of this condition, we hypothesized that the increased volume of inner ear liquid can modify the micromechanical function of the cochlea. The presence of LSC dysplasia is thought to allow larger-than-normal fluid motion, thereby producing an increased response in the basal turn of the cochlea, resulting in high frequency sound intolerance. Regarding this aspect, the study of otoacoustic emissions could be a useful tool to carry out a more in-depth analysis of cochlear function. Moreover, the increased volume of the LSC could affect labyrinthine hydrodynamics and the driving force for the base-to-apex travelling wave along the basilar membrane, producing stationary waves capable of stimulating the neighbouring saccular receptors, which are responsive to low frequency stimuli¹⁶, and are thus responsible for low frequency tone discomfort in patients. In our opinion, the use of HRCT segmentation images could be helpful in verifying the actual increase in vestibular liquid volume. In the future, additional studies are required to follow the clinical evolution of patients, to complete the study of cochlear function with an otoacoustic emissions study, electrocochleography and, above all, to carry out HRCT segmentation images of the inner ear.

References

- 1 Katzenell U, Segal S. *Hyperacusis: review and clinical guidelines*. Otol Neurotol 2001;22:321-7.
- 2 Baguley DM. *Hyperacusis*. J R Soc Med 2003;96:582-5.
- 3 Minor LB, Solomon D, Zinreich JS, et al. *Sound- and/or pressure-induced vertigo due to bone dehiscence of the superior semicircular canal*. Arch Otolaryngol Head Neck Surg 1998;124:249-58.
- 4 Manzari L. *Multiple dehiscences of bony labyrinthine capsule. A rare case report and review of the literature*. Acta Otorhinolaryngol Ital 2010;30:317-20.
- 5 Friedmann DR, Le T, Pramanik BK, et al. *Clinical spectrum of patients with erosion of the inner ear by jugular bulb abnormalities*. Laryngoscope 2010;120:365-72.
- 6 Chen JL, Gittleman A, Barnes PD, et al. *Utility of temporal bone computed tomographic measurements in the evaluation of inner ear malformations*. Arch Otolaryngol Head Neck Surg 2008;134:50-56.
- 7 Lan MY, Shiao JY, Ho CY, et al. *Measurements of normal inner ear on computed tomography in children with congenital sensorineural hearing loss*. Eur Arch Otorhinolaryngol 2009;266:1361-4.
- 8 Johnson J, Lalwani AK. *Sensorineural and conductive hearing loss associated with lateral semicircular canal malformation*. Laryngoscope 2000;110:1673-9.
- 9 Jackler RK, Luxford WM, House WF. *Congenital malformations of the inner ear: a classification based on embryogenesis*. Laryngoscope 1987;97:2-14.
- 10 Sennaroglu L, Saatci I. *A new classification for cochleovestibular malformations*. Laryngoscope 2002;112:2230-41.
- 11 Dallan I, Berrettini S, Neri E, et al. *Bilateral, isolated, lateral semicircular canal malformation without hearing loss*. J Laryngol Otol 2008;122:858-60.
- 12 Purcell DD, Fischbein NJ, Patel A, et al. *Two temporal bone computed tomography measurements increase recognition of malformations and predict sensorineural hearing loss*. Laryngoscope 2006;116:1439-46.
- 13 Yamashita K, Yoshiura T, Hiwatashi A, et al. *Sensorineural hearing loss: there is no correlation with isolated dysplasia of the lateral semi-circular canal on temporal bone CT*. Acta Radiol 2011;52:229-33.
- 14 Berrettini S, Forli F, Bogazzi F, et al. *Large vestibular aqueduct syndrome: audiological, radiological, clinical, and genetic features*. Am J Otolaryngol 2005;26:363-71.
- 15 Walther LE, Nath V, Krombach GA, et al. *Bilateral posterior semicircular canal aplasia and atypical paroxysmal positional vertigo: a case report*. Acta Otorhinolaryngol Ital 2008;28:79-82.
- 16 Todd NP, Rosengren SM, Colebatch JG. *Tuning and sensitivity of the human vestibular system to low-frequency vibration*. Neurosci Lett 2008;444:36-41.

Received: November 29, 2012 - Accepted: March 18, 2013

Address for correspondence: Cristina Brandolini, "S. Orsola-Malpighi" Hospital, ENT Unit, via Massarenti 9, 40138 Bologna, Italy. Tel. +39 051 6363266. Fax +39 051 6363525. E-mail: cribrandolini@libero.it

Calendar of events – Italian and International Meetings and Courses

Acta Otorhinolaryngol Ital 2014;34:75-78

Information, following the style of the present list, should be submitted to the Editorial Secretariat of Acta Otorhinolaryngologica Italica (actaitalicaorl@rm.unicatt.it).

In accordance with the Regulations of S.I.O. and Ch.C.-F. (Art. 8) Members of the Society organising Courses, Congresses or other scientific events should inform the Secretary of the Association (A.U.O.R.L., A.O.O.I.) within the deadlines set down in the respective Statutes and Regulations.

JANUARY-DECEMBER 2014

RHINOPLASTY INTERNATIONAL COURSE • March 11-12, 2014 • Milan – Italy

Course Director: Mario Bussi. Organizing Secretariat: San Raffaele Congress Centre, via Olgettina 58, 20132 Milan, Italy. Tel. +39 02 2643 6227 – Fax +39 02 2643 3754 – E-mail: isella.linda@hsr.it Website: www.entcourses.it

CORSI DI DISSEZIONE CHIRURGICA IN OTORINOLARINGOIATRIA – SEGMENTO DI CHIRURGIA LARINGEA ENDOSCOPICA LASER E OPEN • March 12-14, 2014 • Milan – Italy

Organizing Secretariat: linda.isella@spr.it – Website: www.entcourses.it

11th RHINOCAMP WINTER • March 12-16, 2014 • Saint Moriz – Switzerland

Website: www.rhinocampwinter.org

CORSI DI VIDEOCHIRURGIA ENDOSCOPICA NASO-SINUSALE E DEL BASICRANIO • Milan – Italy

March 17-21, 2014 (corso base)

June 9-13, 2014 (corso intermedio)

October 27-31, 2014 (corso avanzato)

Course Director: Alberto Dragonetti – Scientific Secretariat: Gabriella Mantini, Valentina Casoli- Tel. +39 02 64444545 – Fax +39 02 64444003 – E-mail: gabriella.mantini@ospedaleniguarda.it. Organizing Secretariat: Eurocompany Srl, via Canova 19, 20145 Milano. Tel. +39 02 315532 – Fax +39 02 33609213 – E-mail: corsieconvegni@eurocompany.mi.it

UP DATE ON SLEEP APNEA THERAPY - DALLA SLEEP ENDOSCOPY ALLA SCELTA TERAPEUTICA

March 19-20, 2014 • Bologna – Italy

Course Director: Giovanni Sorrenti. Scientific Secretariat: Ottavio Piccin – E-mail: ottavio.piccin@gmail.com

4th INTERNATIONAL RHINOPLASTY COURSE IN LEUVEN 'EXCELLENCE IN RHINOPLASTY'

March 19-21 2014 • Leuven – Belgium

Website: www.excellenceinrhinoplasty.be

CORSO DI ANATOMIA E CHIRURGIA CERVICO-FACCIALE • March 19-21, 2014 • Nîmes – France

Information: Pierfrancesco Pelliccia, E-mail: pierfrancesco.pelliccia@hotmail.it

RONCOCHIRURGIA 3D E BARBED SNORE SURGERY • March 21, 2014 • Milan – Italy

Coordinatori: F. Salamanca, E. Colombo. Scientific Secretariat: Alessandro Bianchi, Andrea Zani, Tel. +39 02 69516442 – E-mail: orl.spiox.plv@camilliani.net. Organizing Secretariat: Erica Monese, via G. Passeroni 1, 20135 Milano. Tel. /Fax +39 02 58319743 – Infoline: 3392168235 –E-mail: ericamonese@yahoo.it

AMERICAN ACADEMY OF AUDIOLOGY AAA ANNUAL CONVENTION

March 26-29, 2014 • Orlando, Fla – USA

Website: www.audiologynow.org

CURSO DE MICROCIRUGÍA DEL OÍDO Y DISECCIÓN DEL HUESO TEMPORAL - TEMPORAL BONE SURGICAL DISSECTION COURSE**March 26-28, 2014 – July and November 2014, date to be announced • Barcelona – Spain**

Instituto de Otolología García-Ibáñez, Conchi Castilla, C/ Dr. Roux, 91, 08017 – Barcelona. Tel. 93 205 02 04 – Fax 93 205 43 67 – E-mail: iogi@iogi.org

11th INTERNATIONAL COURSE IN ADVANCED SINUS SURGERY TECHNIQUES**March 27-28, 2014 • Amsterdam – The Netherlands**

Course secretariat: AMC, ENT Dept., P.O. Box 22660, Location D2-312, 1100 DD Amsterdam, The Netherlands. Tel. 00 31 20 5668586 – Fax 00 31 20 56 69 573 – E-mail: M.B.vanhuiden@amc.uva.nl – Website: www.sinuscourse.nl

ASOHNS ASM 2014 MODERN APPROACHES TO ENT**March 29-April 1, 2014 • Brisbane Queensland – Australia**

Website: www.asohns.consec.com.au

10th CONGRESS OF THE EUROPEAN LARYNGOLOGICAL SOCIETY – 2nd JOINT MEETING OF ABEA & ALA**April 9-12, 2014 • Antalya – Turkey**

Website: www.els2014.org

RINITE ALLERGICA E PATOLOGIE RESPIRATORIE: IX CORSO TEORICO-PRATICO**April 10-11, 2014 • Rome – Italy**

Responsabile dell'Evento: Lino Di Rienzo Businco, Coordinatore Scientifico: Andrea Di Rienzo Businco. Segreteria Organizzativa: Scuola Medica Ospedaliera, borgo S. Spirito 3, Roma. Tel. +39 06 68802626 – 06 68352411; E-mail: segreteria@smorrl.it

18th INTERNATIONAL VOICE WORKSHOP 2014 • April 11-12, 2014 • Paris – France

Information to: Jean Abitbol, 1, Rue Largillière – 705016 Paris. E-mail: voice.abitbol@gmail.com

SINO-NASAL & SKULL BASE DISSECTION COURSE • April 12-13, 2014 • Milan – Italy

Organizing Secretariat: San Raffaele Congress Centre, via Olgettina 58, 20132 Milan, Italy. Tel. +39 02 2643 6227 – Fax +39 02 2643 3754 – E-mail: isella.linda@hsr.it – Website: www.entcourses.it

4th MIDDLE EAST CONGRESS ON RHINOLOGY AND FACIAL PLASTIC SURGERY (MERC2014)**April 12-14, 2014 • Tehran – Iran**

Website: www.merc2014.com

XVIII CORSO RESIDENZIALE DI MEDICINA DEL SONNO • April 12-16, 2014 • Bertinoro (FC) – Italy

Organizing Secretariat: Centro Residenziale Universitario di Bertinoro, Monica Michelacci. Tel. +39 0543 446555 – E-mail: mmichelacci@ceub.it

18th WCBIP/WCBE**18th WORLD CONGRESS FOR BRONCHOLOGY AND INTERVENTIONAL PULMONOLOGY****18th WORLD CONGRESS FOR BRONCHOSOPHAGOLOGY****April 13-17, 2014 • Kyoto – Japan**

Website: www2.convention.co.jp/wcbipwcbe2014/

THE FOURTH MIDDLE EAST CONGRESS ON RHINOLOGY & FACIAL PLASTIC SURGERY**April 23-25, 2014 • Tehran – Iran**

Website: www.merc2014.com

3rd INTERNATIONAL SYMPOSIUM ON OTOSCLEROSIS AND STAPES SURGERY**April 24-26, 2014 • Siófok – Hungary**

President of the Congress: I. Sziklai – Secretary of the Congress: T. Karosi. Website: www.otosclerosis2014.com

SKIN CANCER OF THE HEAD AND NECK COURSE • May 1, 2014 • Utrecht – The Netherlands**INTERCONTINENTAL RHINOPLASTY • May 2-3, 2014 • Utrecht – The Netherlands**

Websites: http://reconstruction-skin-cancer.com – http://intercontinental-rhinoplasty.nl

V INTERNATIONAL WORKSHOP ON ENDOSCOPIC EAR SURGERY • May 5-7, 2014 • Modena – Italy

Course Directors: Livio Presutti, Daniele Marchioni. Website: http://www.meetandwork.it/livesurgerymodena

**2nd ANNOUNCEMENT OTOTOLOGY JUBILEE: 150 YEARS OF THE ARCHIV FÜR OHRENHEILKUNDE
Past-Present-Future in Otology & Neurology • May 7-10, 2014 • Halle/Saale – Germany**

Website: www.otology-jubilee.com

BALBUZIE - IL TRATTAMENTO TRA STUDIO E HOMEWORK • May 9-10, 2014 • Turin – Italy

Coordinatore Scientifico: Mario D'Ambrosio. Organizing Secretariat: Centro Congressi Internazionale Srl, via San Francesco da Paola 37, 10123 Torino. Tel. +39 011 2446911 – Fax +39 011 2446950 – E-mail: info@congressiefiere.com – Website: www.congressiefiere.com

GIORNATA DI AGGIORNAMENTO AICEF - 6^a edizione • May 10, 2014 • Ravenna – Italy

Scientific Secretariat: Domenico Minghetti, E-mail: minghetti@tin.it – Patrizia Schiavon, E-mail: patrizia.schiavon@gmail.com. Website: www.lopezcongressi.it

**3rd IRANIAN CONGRESS ON COCHLEAR IMPLANT & RELATED SCIENCE
May 10-12, 2014 • Tehran – Iran**

IRANCI 2014 Secretariat: Tel. - Fax 098-21-8860-0006 – E-mail: info@irancochlear.com – Website: www.irancochlear.com

**101° CONGRESSO NAZIONALE SIO – Società italiana di Otorinolaringoiatria e Cervicofacciale
May 28-31, 2014 • Catania – Italy**

President: A. Serra. Website: www.sio2014.org – www.eac.it

**CURSO DE DISECCIÓN ENDOSCÓPICA DE LOS SENOS PARANASALES - ENDOSCOPIC SINUS
SURGICAL DISSECTION COURSE • May 29-31, 2014 • Barcelona – Spain**

Instituto de Otolología García-Ibáñez, Isabel, C/ Dr. Roux, 91, 08017 Barcelona. Tel. 93 205 02 04 – Fax 93 205 43 67 – E-mail: gi.fundacion@gmail.com, fundacion@iogi.org

**HEAL 2014 (HEaring Across the Lifespan): “EARLY INTERVENTION: THE KEY TO BETTER HEARING CARE”
June 5-7, 2014 • Cernobbio (Lake Como) – Italy**

Website: <http://www.heal2014.org>

TEMPORAL BONE DISSECTION COURSES 2014 • June 10-13, December 9-12, 2014 • Brazil

Website: www.forl.org.br/courses

**4th HANDS ON DISSECTION ADVANCED COURSE: “FROM REMOVAL TO RECONSTRUCTION IN HEAD
AND NECK CANCERS” • June 17-20, 2014 • Paris – France**

Directors: Marco Benazzo, Department of Otolaryngology HN Surgery, University of Pavia, Italy; Fausto Giuseppe Chiesa, Department of Otolaryngology HN Surgery, IEO Milan, Italy. Organizing Secretariat: Bquadro Congressi srl, via S. Giovanni in Borgo 4, 27100 Pavia. Tel. +39 0382 302859 – Fax +39 0382 27697 – E-mail: bolla@bquadro-congressi.it.

**24th CONGRESS OF EUROPEAN RHINOLOGIC SOCIETY (ERS) and 32nd INTERNATIONAL
SYMPOSIUM OF INFECTION AND ALLERGY OF THE NOSE. THE NOSE AS INTERFACE
June 22-26, 2014 • Amsterdam – The Netherlands**

President: W.J. Fokkens. Website: www.ers-isian2014.com – E-mail: ers-isian2014@kenes.com

**5th WORLD CONGRESS OF THE INTERNATIONAL FEDERATION OF HEAD AND NECK ONCOLOGIC
SOCIETIES (IFHNOS) – ANNUAL MEETING OF THE AMERICAN HEAD AND NECK SOCIETY (AHNS)
July 26-30, 2014 • New York – USA**

Congress Chairman: Jatin Shah. Program Chairman: Bevan Yueh. Websites: www.ifhnos2014.org, www.ahns2014.org

**4th INTERNATIONAL COURSE ON ENDOCRINE SURGERY - INTRAOPERATIVE MONITORING OF
LARYNGEAL NERVES IN THYROID SURGERY • June 27, 2014 • Stresa (Lake Maggiore, VB) – Italy**

Organizing Secretariat: Summeet Srl, via P. Maspero 5, 21100 Varese. Tel. +39 0332 231416 – Fax +39 0332 317748 – E-mail: mb.calveri@summeet.it – Website: www.summeet.it

BEST EVIDENCE ENT 2014 • August 2-5, 2014 • Wisconsin – USA

Course Directors: John S. Rhee, David R. Friedland, Charles J. Harkins. Department of Otolaryngology 9200 West Wisconsin Avenue Milwaukee, WI 53226

40° CONGRESSO CONVENTUS SOCIETAS ORL LATINA • September 1-5, 2014 • Baía de Luanda – Angola

Info: Departamento de ORL da Faculdade de Medicina da Universidade Agostino Neto Hospital Josina Machel-Maria Pia Av. 1° Congresso do MPLA. Tel. 00244-923784901/914381304 – E-mail: mfilipe@snet.co.ao, drmatuba@gmail.com

XL CONVENTUS SOCIETAS ORL LATINA CONGRESSO • September 3-5, 2014 • Luanda – Angola

Website: www.conventusocietasorllatina-luanda2014.org

ORL ENDO 2014 • Modena – Italy

Chirurgia endoscopica dell'orecchio medio (Middle ear endoscopic surgery) • September 9-10, 2014

Chirurgia endoscopica dei seni paranasali (Endoscopic sinus surgery) • November 11-12, 2014

Course Director: Livio Presutti. Scientific Secretariat: Angelo Ghidini, Daniele Marchioni. Tel. +39 059 4222402 - 4223022 – E-mail: Ghidini.angelo@policlinico.mo.it, Marchioni.daniele@policlinico.mo.it - Website: www.meetand-work.it/orl-endo2014

7th INSTRUCTIONAL WORKSHOP – CONSENSUS IN AUDITORY IMPLANTS “EUROPEAN GUIDELINES IN OTOLOGY AND NEURO-OTOLOGY” • September 13-16, 2014 • Siena – Italy

Website: www.eaono2014.org

IV CORSO TEORICO-PRATICO DI AUDIOLOGIA E VESTIBOLOGIA

September 22-24, 2014 • Benevento – Italy

Course Director: L. Califano. Scientific Secretariat: Luigi Califano, Maria Grazia Melillo – E-mail: luigi.califano@tin.it, vertigobn@hotmail.com

EUROPEAN UNION OF HEARING AID ACOUSTICIANS (EUHA) 59th INTERNATIONAL CONGRESS OF HEARING AID ACOUSTICIANS (EUHA) • October 15-17, 2014 • Hanover – Germany

Website: www.euha.org

5th ASIAN FACIAL PLASTIC SURGERY SOCIETY CONGRESS • October 15-19, 2014 • Cappadocia – Turkey

Website: www.afpss2014.org

JANUARY-DECEMBER 2015**3rd CONGRESS OF CE ORL-HNS • June 7-11, 2015 • Prague – Czech Republic**

Website: Congress secretariat: GUARANT International Na Pankraci 17, 14021 Prague4, Czech Republic. Website: www.CEOrl-hnsprague2015.com

22nd INTERNATIONAL CONGRESS ON THE EDUCATION OF THE DEAF • July 6-9, 2015 • Athens – Greece

Website: www.iced2015.com

WORLD CONGRESS ON LARYNX CANCER 2015 • July 26-30, 2015 • Queensland – Australia

Website: www.wclc2015.org