

CASE REPORT

Palliative combined treatment for unresectable cutaneous basosquamous cell carcinoma of the head and neck

Trattamento palliativo combinato di un carcinoma basosquamoso cutaneo non resecabile del distretto testa-collo

A. DEGANELLO¹, G. GITTI¹, B. STRUIJS², F. PAIAR³, O. GALLO¹

¹ Clinic of Otolaryngology/Head and Neck Surgery, Department of Surgical Sciences, University of Florence, Italy; ²Department of Otolaryngology Head and Neck Surgery, VU Medical Center, Amsterdam, The Netherlands; ³Department of Radiotherapy, University of Florence, Italy

SUMMARY

A case is presented of a patient with a skin basosquamous cell carcinoma of the frontal region infiltrating the cerebral tissue and with a widespread unresectable regional metastatic ulceration of the left parotid region. The patient underwent combined palliative treatment: surgical coverage of the ulceration by means of a *pectoralis mayor* flap transposition and radiotherapy. After 18 months of follow-up, no signs of tumour progression were noted, the patient is currently free from pain, no increase in trismus was seen, and a slight gain in weight was recorded. Unresectable cancer is mainly treated by concurrent chemoradiation; radiotherapy, however, is contraindicated in deep neoplastic ulcerations with exposure of large vessels. The data reported suggest that surgical coverage of an unresectable neoplastic ulcer is feasible, and combined with early administration of radiation permits a palliative approach in an otherwise untreatable condition.

KEY WORDS: Basosquamous cell carcinoma • Palliative surgery • Palliative radiotherapy • Head and neck cancer

RIASSUNTO

Presentiamo il caso di un paziente con carcinoma basosquamoso della regione frontale arrivato alla nostra osservazione avendo già sviluppato un'estesa infiltrazione del tessuto cerebrale ed un'ampia ulcera metastatica laterocervicale sinistra non resecabile. Per poter offrire un trattamento palliativo al paziente abbiamo eseguito una copertura dell'ulcera neoplastica attraverso la trasposizione di un lembo miocutaneo di gran pettorale a cui ha fatto seguito radioterapia palliativa. Dopo 18 mesi di follow-up non sono stati riscontrati segni di progressione di malattia a livello loco-regionale, il paziente non ha dolore, il trisma non è aumentato e si è registrato un guadagno ponderale. Le forme tumorali non resecabili vengono trattate con protocolli chemio-radioterapici; questi tuttavia sono controindicati in caso di ulcere profonde con esposizione dei grandi vasi. Il nostro caso clinico suggerisce che è tecnicamente possibile coprire efficacemente ulcere neoplastiche non resecabili ai fini di poter eseguire ulteriori trattamenti palliativi che devono necessariamente essere tempestivi.

PAROLE CHIAVE: Carcinoma squamocellulare • Chirurgia palliativa • Radioterapia palliativa • Tumore cutaneo • Cancro del distretto testa-collo

Acta Otorhinolaryngol Ital 2013;33:353-356

Introduction

Basosquamous cell carcinoma (BSCC) is a rare malignancy with features of both basal cell carcinoma (BCC) and squamous cell carcinoma (SCC) (Fig. 1). The recent World Health Organization (WHO) classification of head and neck tumours¹ defines BSCC as an aggressive subtype of SCC. The incidence of BSCC among BCC has been estimated to be 0.4-12%² and its higher metastatic propensity compared to SCC, is clearly highlighted in the literature^{3,4}. Rare cases of BSCC with either leptomenin-

geal carcinomatosis⁵ or infiltrating cerebral tissue⁶ have been reported. Disease onset usually occurs between the sixth and seventh decade, with the skin of the head and neck being the sites most involved. A more aggressive behaviour has been recorded in patients with recurrence, and male sex has been statistically correlated with likelihood of recurrence⁷.

Palliative treatment in head and neck cancer aims to improve the patient's quality of life. In some cases, palliative treatment can prevent life-threatening complications (such as rupture of vessels) thus prolonging patient survival.

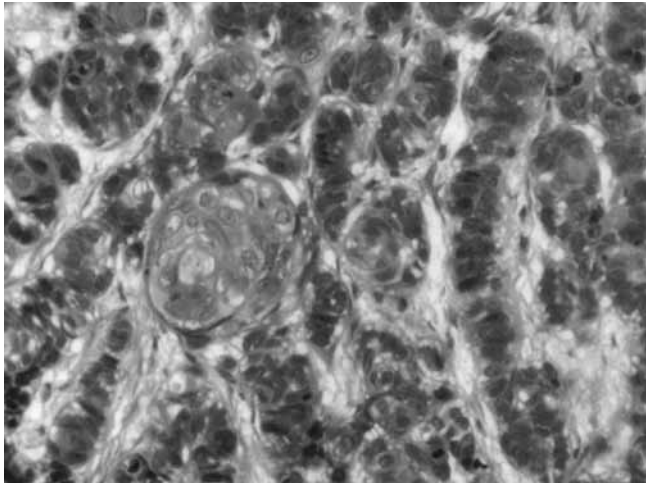


Fig. 1. Photomicrograph of the biopsy specimen (haematoxylin/eosin staining), showing basaloid cells and focal areas of squamous differentiation with keratinization.

Herewith the case is presented of a patient with BSCC of the supraorbital skin, infiltrating the cerebral tissue and with widespread regional metastatic ulceration of the left parotid region. The patient underwent palliative treatment with surgical coverage and radiotherapy.

Case report

A 54-year-old male patient consulted our first aid unit on account of moderate bleeding from the neck. Upon physical examination, on the left side, a 3 × 2 cm non-bleeding ulceration of the frontal skin was found and a wide (approximately 10 × 5 cm) ulcer involving the left parotid area from the zygomatic arch to the level of the hyoid bone, eroding the external ear canal, disrupting most of the pavilion and causing complete peripheral facial nerve paralysis (Fig. 2). The patient also presented a moderate trismus with 1.5 cm maximal mouth opening. Upon visual inspection, it was possible to clearly perceive the carotid pulse at the jugulo-digastric level.

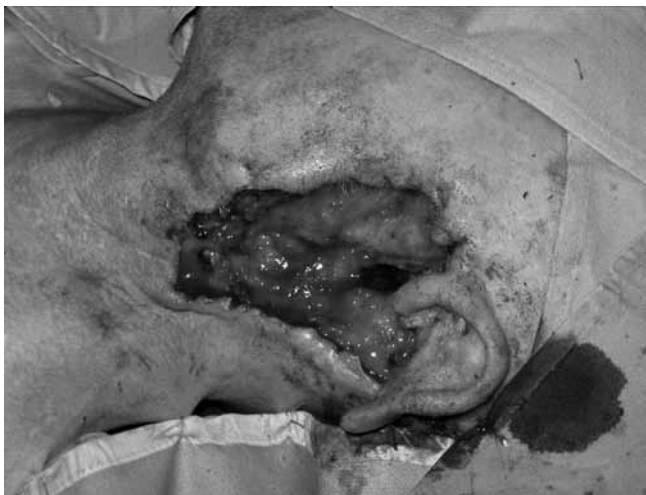

Fig. 2. Pre-operative aspect of the left parotid region.

Laboratory tests revealed a haemoglobin value of 12 mg/dl with normal electrolytes.

Discussing the medical history, the patient reported having undergone surgery abroad (Albania) for BCC of the frontal skin. Unfortunately, earlier detailed charts were not available, and relatives could not provide exhaustive information about previous surgical treatment. It was certain, however, that the patient had never received either radiotherapy or chemotherapy and that, abroad, no further treatment options were advised besides pain control. From these findings, it was assessed that the disease appeared 2 years before as a left-sided frontal skin lesion for which the patient had undergone local excision. Six months later, the patient developed a left parotid-cervical mass that was treated with parotidectomy and lymph-node excision (no codified type of neck dissection was performed). Furthermore, 6 months after parotid-cervical surgery, a non-healing ulceration, which became progressively enlarged, appeared in the parotid region with concomitant facial paralysis. Moreover, a necrotic sore developed from the operated frontal skin. Since then the patient experienced progressive fatigue with consistent limitation in his daily activities, increasing pain that required morphine patches, and weight loss (8 kg in the last 6 months). He never experienced either seizure or any other kind of cerebral symptom.

Contrast enhanced CT scan of the head and neck and thorax showed infiltration of the meningeal and cerebral tissue of the left frontal lobe, infiltration of the mastoid middle ear, complete encasement of the left internal and external carotid arteries with involvement of the pterygoid muscles and skull base (Fig. 3). No evidence of distant lung metastasis was observed. After appropriate counseling and multidisciplinary evaluation, the patient underwent surgery. Extensive biopsies of the parotid ulceration's borders were submitted for frozen section analysis that revealed BSCC (tumour staging rT4N1M0⁸). The edges of the skin were resected until macroscopic healthy tissue was found. A generous undermining of the cervical skin, reaching the superior border of the clavicle, was carried out in order to avoid further incisions in the neck. A *pectoralis major* flap with a skin paddle of 20 × 8 cm

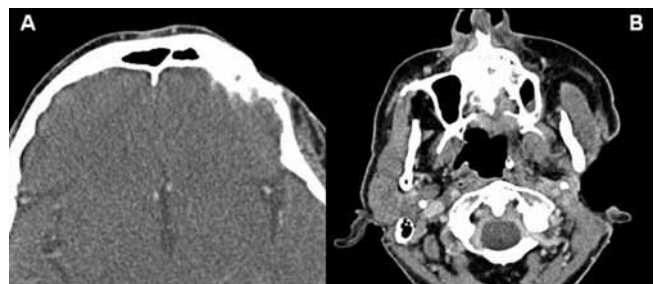


Fig. 3. Pre-operative CT scan. A: infiltration of the frontal bone and cerebral tissue. B: Involvement of the lateral pterygoid plate, tumour extension to the parapharyngeal space with encasement of the styloid process and internal carotid artery that lie close to the bottom of the ulcer.

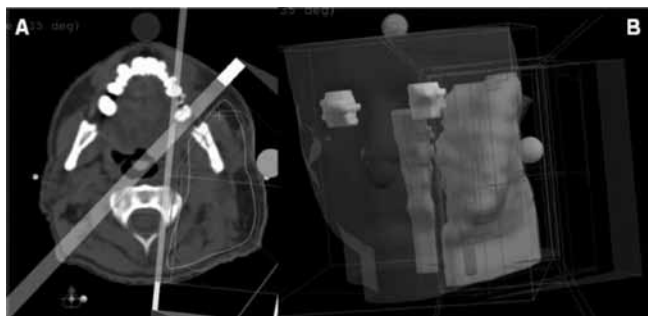


Fig. 4. A: Planning CT scan, transversal dose distribution for three-dimensional conformal radiation therapy, three wedged fields. B: Organs at risk and treatment volumes, three-dimensional three fields isodose reconstruction.

was transposed to cover the defect. The external auditory canal was obliterated.

The post-operative course was uneventful, flap viability was optimal and no wound dehiscences occurred. The patient was discharged on the 4th post-operative day having been advised to undergo palliative radiotherapy that was started on the 15th day. External beam three-dimensional conformal radiotherapy was carried out using 6-MV photons (linear accelerator) equipment. Planning CT scan was performed in treatment position with a customized head mask. The gross tumour volume (GTV), the clinical target volume (CTV), the planning target volume (PTV) and the organs at risk (spinal cord, lens, eyes, etc.) were delineated on each slice. Radiotherapy was delivered to the cervicoparotid region with standard fractionation (2 Gy per day, 5 days a week) using three coplanar converging wedged beams (Fig. 4) and was stopped, at a total dose of 44 Gy, when a neck abscess developed at the operated neck side. The abscess was treated with surgical evacuation by means of simple pen rose drain introduction and antibiotic administration. Since GTV, at this site, was strictly related to the spinal cord, it was not possible to achieve a higher total dose. The supraorbital frontal skin recurrence was treated with electron beam radiotherapy with standard fractionation until a total dose of 44 Gy was reached.

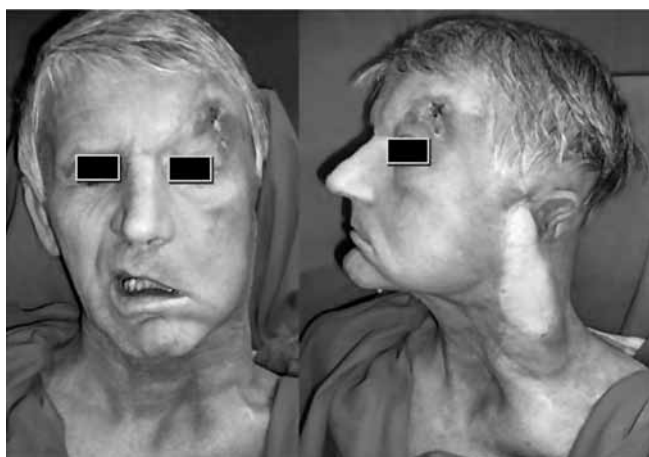

Fig. 5. Post-operative result 18 months after palliative treatment.

Adjuvant chemotherapy was planned and advised, after the end of radiation, but the patient refused.

After 18 months of follow-up, no signs of tumour progression were noted, the patient is currently pain free, no increase in trismus was observed, and a slight gain in weight was recorded (4 kg since the end of radiation) (Fig. 5).

Discussion

In the literature, there are no reports giving guidelines for the management of unresectable neoplastic head and neck ulcerations with vessel exposure.

Unresectable cancer is mainly treated by radiotherapy with comitant chemotherapy, the setting of which is designed for a curative or a palliative intent based on the realistic chances of tumour control. Several host/tumour factors must be taken into consideration in treatment planning: patient's general conditions (performance status) and specific comorbidities that might prevent withstanding of the treatment, the possibility of delivering curative doses of radiation without damaging vital structures, the locoregional volumetric extension of the disease, the presence or absence of distant metastases.

In the present case, due to cerebral involvement, it was not possible to offer the patient a chemoradiation protocol with curative intent.

In the case presented, the need for surgical coverage arose from the evidence that radiotherapy is contraindicated in deep neoplastic ulcerations with exposure of great vessels, on account of the serious risk of blow-out with fatal haemorrhage. Regional and distant tissue transfer techniques have increased the possibility of covering vital organs with well vascularised tissue allowing otherwise impossible radiation delivery. Nevertheless, we were unable to predict whether flap transposition would have efficiently covered the defect without dehiscence and without an immediate neoplastic colonization of the transposed tissue from the neoplastic recipient. This was our major concern, but we had to face the fact that no other options were available and that carotid rupture is such a catastrophic event that its exposure represents a surgical priority in itself⁹. We felt that the transposition of a *pectoralis major* flap was more appropriate than reconstruction with a microvascular free flap, since the quality of the donor vessels for microvascular anastomosis was questionable.

In head and neck cancer, it is recommended to start post-operative adjuvant radiation, within 4-6 weeks after surgery¹⁰ to maximize loco-regional control. Our prompt onset of post-operative radiation within 2 weeks after surgery, despite the development of a neck abscess, might have been a crucial factor in successful palliation.

Even if, however, we obtained a pathologic assessment only of the parotid-neck ulceration, we believe that the frontal lesion had to be considered the primary tumour, while the parotid ulceration was the regional metastatic extension.

Since the frontal ulceration appeared as a non-bleeding necrotic sore, we felt that it was not appropriate to take biopsies that could have worsened the local status and delayed the possibility of radiation delivery. In fact, necrotic tissue frequently hides cancer proliferation, therefore thus preventing the diagnosis. This slight likelihood of obtaining the correct diagnosis with a single bite biopsy leads the surgeon physician to perform multiple biopsies that could jeopardize the clinical condition. Furthermore, confirmation histology of the primary lesion would not have changed our treatment strategy in this particular patient. In the sixth edition of the TNM classification⁸ (the only one available at the time the patient was treated), a giant unresectable metastatic involvement of the neck and parotid was classified N1 like a single small lymph node metastasis. Recently, in the seventh edition of the TNM classification¹¹, a more accurate N classification for non-melanoma skin cancer has been introduced, accordingly our case would now be classified N3.: N0 no lymph node metastasis; N1 single < 3 cm; N2 single ≥ 3 to 6 cm, multiple ≤ 6 cm; N3 > 6 cm. These changes certainly improve the hazard consistency (homogeneity within the group) and hazard discrimination (heterogeneity between the groups) of the classification. However, we feel that a further discrimination between resectable and unresectable regional neck disease might be

helpful, considering that treatment and prognosis of these conditions differ consistently. Furthermore, parotid disease, facial nerve involvement and tumour size greater than ≥ 6 cm within the parotid, had less favourable prognosis in terms of survival in several studies¹²⁻¹⁴.

Based on this concept, several years ago, a new staging system was introduced that separates parotid involvement from cervical lymph node involvement¹⁰⁻¹². Parotid disease was more prognostic of poor survival than neck involvement; in particular, facial nerve involvement and tumour size ≥ 6 cm within the parotid^{11 13}. These studies were conducted on cutaneous SCC but probably the same findings might be valid also for BSCC.

Conclusions

In cases of unresectable neoplastic head and neck ulceration, the combination of surgical coverage with post-operative radiation radiotherapy offers a valid treatment option to achieve a palliation in an otherwise untreatable situation. This report indicates that surgical coverage of vital organs with well vascularised tissue is feasible even in the case of neoplastic recipient ulceration; the authors believe that, in these conditions, early administration of palliative radiation radiotherapy is mandatory.

References

- Barnes L, Eveson JW, Reichart P, et al. *Pathology and genetics of head and neck tumors*. Lyon: IARC Press; 2005.
- Kirkham N. *Tumors and cysts of the epidermis*. In: Elder DE, editor. *Lever's Histopathology of the Skin*, 8th edn. Philadelphia, PA: Lippincott William & Wilkins; 1997. p. 728-9.
- Lopes de Faria J, Nunes PH. *Basosquamous cell carcinoma of the skin with metastases*. *Histopathology* 1988;12:85-94.
- Bowman PH, Ratz JL, Knoepp TG, et al. *Basosquamous carcinoma*. *Dermatol Surg* 2003;29:830-2.
- Pena YM, Bason MM, Grant-Kels JM. *Basosquamous cell carcinoma with leptomeningeal carcinomatosis*. *Arch Dermatol* 1990;126:195-8.
- Sendur N, Karaman G, Dikicioglu E, et al. *Cutaneous basosquamous carcinoma infiltrating cerebral tissue*. *J Eur Acad Dermatol Venereol* 2004;18:334-6.
- Martin RC 2nd, Edwards MJ, Cawte TG, et al. *Basosquamous carcinoma: analysis of prognostic factors influencing recurrence*. *Cancer* 2000;88:1365-9.
- Sobin LH, Wittekind Ch, editors. *TNM classification of malignant tumors*, 6th ed. International Union Against Cancer. New York: Wiley-Liss; 2002.
- Deganello A, Gallo O, De Cesare JM, et al. *Surgical management of surgery and radiation induced peristomal neck ulcerations*. *B-ENT* 2008;4:169-74.
- Huang J, Barbera L, Brouwers M, et al. *Does delay in starting treatment affect the outcomes of radiotherapy? A systematic review*. *J Clin Oncol* 2003;21:555-63.
- Sobin LH, Gospodarowicz M, Wittekind Ch, editors. *TNM classification of malignant tumors*. 7th ed. International Union Against Cancer. New York: Wiley-Liss; 2009.
- Palme CE, O'Brien CJ, Veness MJ, et al. *Extent of parotid disease influences outcome in patients with metastatic cutaneous squamous cell carcinoma*. *Arch Otolaryngol Head Neck Surg* 2003;129:750-3.
- Audet N, Palme CE, Gullane PJ, et al. *Cutaneous metastatic squamous cell carcinoma to the parotid gland: analysis and outcome*. *Head Neck* 2004;26:727-32.
- Andruchow JL, Veness MJ, Morgan GJ, et al. *Implications for clinical staging of metastatic cutaneous squamous carcinoma of the head and neck based on a multicenter study of treatment outcomes*. *Cancer* 2006;106:1078-83.

Received: September 29, 2010 - Accepted: March 15, 2011

Address for correspondence: Alberto Deganello, Clinic of Otolaryngology, Head and Neck Surgery, Department of Surgical Sciences, University of Florence, viale Morgagni 85, 50134 Florence, Italy. Fax +39 055 435649. E-mail: adeganello@hotmail.com