

CASE REPORT

Intramuscular haemangioma of the levator anguli oris: a rare case

Angioma intramuscolare del muscolo elevatore dell'angolo della bocca: un raro caso clinico

P. KOLTSIDOPOULOS, M. TSEA, S. KAFKI, C. SKOULAKIS

Department of Otolaryngology, General Hospital of Volos "Achilloupolio", Volos, Greece

SUMMARY

Intramuscular haemangiomas are benign malformations of blood vessels occurring in skeletal muscles. Because of the rarity of these lesions, their deep location and variable clinical presentation, they often pose diagnostic difficulties. We herein present the first reported case of intramuscular haemangioma occurring in the levator anguli oris muscle. A 26-year-old man was referred to our Department for evaluation and management of a progressive swelling of the right cheek. Based mainly on the imaging findings, a preoperative diagnosis of intramuscular haemangioma was made and surgery was performed. During intervention, a highly vascular soft tissue mass was identified within the levator anguli oris muscle. The lesion was completely removed via an intraoral approach, and histopathological examination showed an intramuscular haemangioma.

KEY WORDS: Intramuscular haemangioma • Levator anguli oris

RIASSUNTO

Gli emangiomi intramuscolari sono malformazioni benigne di origine vascolare che si localizzano all'interno della muscolatura scheletrica. A causa della rarità di queste lesioni, la loro profonda localizzazione e la loro variabilità nella presentazione clinica, pongono spesso delle difficoltà diagnostiche. Il caso presentato in questo articolo è il primo emangioma intramuscolare del muscolo elevatore dell'angolo della bocca, riportato in letteratura. Trattasi di un uomo di 26 anni valutato presso la nostra clinica per progressiva tumefazione in corrispondenza della guancia destra. Sulla base dei reperti clinico-radiologici, è stata posta diagnosi pre-operatoria di emangioma intramuscolare e per tale motivo è stato sottoposto a exeresi chirurgica. Durante l'intervento, è stata identificata una massa altamente vascolarizzata di tessuto molle all'interno del muscolo elevatore dell'angolo della bocca. La lesione è stata completamente escissa tramite approccio intraorale e l'esame istopatologico ha confermato la diagnosi di emangioma intramuscolare.

PAROLE CHIAVE: Emangioma intramuscolare • Muscolo elevatore dell'angolo della bocca

Acta Otorhinolaryngol Ital 2013;33:350-352

Introduction

Intramuscular haemangiomas (IMHs) are relatively uncommon angiomatous malformations. They appear most often in the trunk and extremities, while their occurrence in the head and neck region is rare. In the head, the masseter muscle is the most frequently involved site. Clinically, diagnosis of IMHs is difficult. As a result, inappropriate treatment planning is a common problem that can lead to incomplete excision and unnecessary risk to the facial nerve. IMHs usually present in childhood or early adult life, are treated by complete surgical excision and carry an excellent prognosis.

To the best of our knowledge, the present case is the first intramuscular haemangioma within the levator anguli oris reported in the literature.

Case report

A 26-year-old man was referred to our Department for evaluation and management of a painless swelling of the right cheek (Fig. 1). The lesion had been present for 10 years and had gradually increased in size. The patient complained of cosmetic deformity. Clinical examination showed a diffuse mass situated about 2 cm superior to the right side of the upper lip. The lesion was soft, compressible, mobile and not adherent to skin. The overlying skin was slightly erythematous. No pulsation, bruits or thrills were noted. There was no evidence of neck lymphadenopathy.

A subsequent computerized tomography (CT) scan revealed a 4.6 × 1.9 cm soft tissue mass of the same density as muscle, arising from within the muscles of the cheek (Fig. 2). There was no underlying bone involvement of the

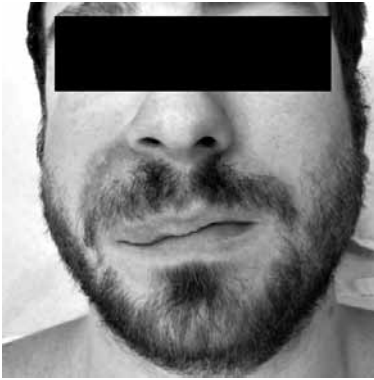

Fig. 1. Clinical appearance of the lesion.

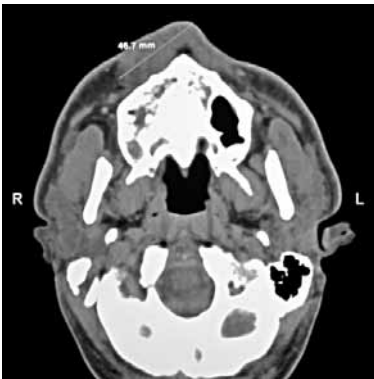


Fig. 2. Axial CT showed the presence of a soft tissue mass arising within the muscles of the right cheek.

upper jaw. Magnetic resonance imaging (MRI) showed heterogeneous, intramuscular lesion at the same location (Fig. 3). The mass was hyperintense to the masseter muscle on T2-weighted images. The imaging findings, history of long duration of the swelling and the clinical finding of discolouration of the overlying skin raised suspicion of a vascular lesion. On that basis, angiography was performed, and the patient underwent bilateral common carotid arteriography via the right femoral artery that confirmed the vascular nature of the lesion. In particular, the right common carotid injection showed that the mass consisted of a collection of tortuous vessels of varying calibre. Two main feeding vessels were detected, one originating from the right facial artery and another from the right internal maxillary artery (Fig. 4). Based on these findings, a provisional diagnosis of intramuscular haemangioma was made and surgery was scheduled. The lesion was removed via an intraoral approach under

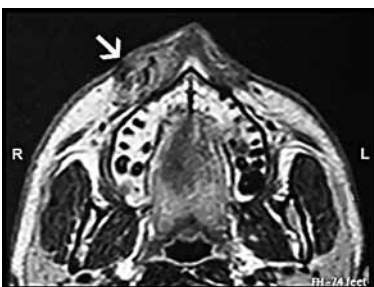

Fig. 3. Coronal T2-weighted MRI revealing a heterogeneous, intramuscular lesion.

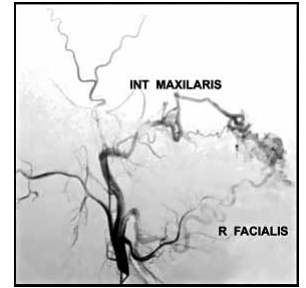


Fig. 4. Arteriogram of right external carotid artery showing the two feeding vessels of the lesion.

general anaesthesia. During intervention, a highly vascular soft tissue mass was identified within the levator anguli oris muscle. The lesion was excised together with a margin of the normal surrounding muscle to prevent recurrence. Several small feeding vessels were individually ligated by bipolar diathermy. Blood loss during the procedure was minimal, allowing for complete excision. The postoperative period was uneventful. The histopathological examination showed small vessels growing between fibres of skeletal muscle, consistent with a diagnosis of intramuscular haemangioma of small vessel (capillary) type. The patient remains free of symptoms and there is no evidence of postoperative recurrence at 6 months (Fig. 5).

Discussion

Intramuscular haemangioma is an uncommon vascular malformation, accounting for less than 1% of all haemangiomas¹. It affects mainly the trunk and extremities where the muscle volume is larger. Approximately 13% of these lesions present in the head and neck region². In the head,

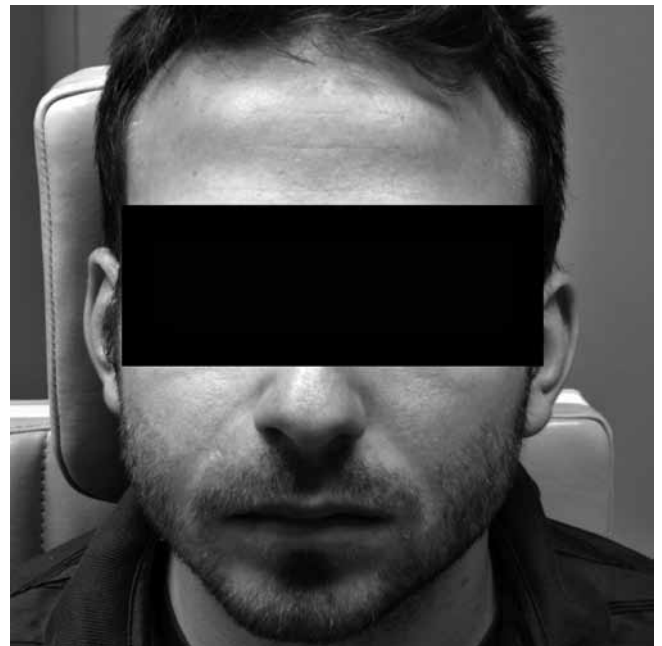

Fig. 5. Appearance of the patient at 6 months after surgical excision of the tumour mass.

the masseter muscle is the most frequently involved site³. Rarer sites include the orbicularis oris^{4,5}, depressor anguli oris⁶ and orbicularis oculi muscle⁷. To the best of our knowledge, our case is the first reported of IMH within the levator anguli oris muscle.

Intramuscular haemangiomas generally present as progressively enlarging and often painful lesions. Because of their deep location, they rarely display any clinical signs or symptoms that suggest a vascular nature, such as pulsations, thrills or bruits. Overlying skin discolouration is also uncommon. The absence of pathognomic clinical findings and the rare incidence of these lesions make accurate pre-operative diagnosis difficult^{8,9}. Namely, only 8% of all cases of intramuscular haemangioma are diagnosed before surgical intervention². A variety of muscle neoplasms, benign muscular hypertrophy, congenital cysts and lymphadenopathies are commonly confused in differential diagnosis⁹. In our case, the discolouration of the overlying skin in combination with the imaging findings led to the presumptive diagnosis of intramuscular haemangioma.

For preoperative diagnosis of intramuscular hemangioma, plain radiographs, CT scan, MRI and angiography may be helpful. Plain soft tissue x-ray views occasionally demonstrate phleboliths within the lesion¹⁰. MRI is thought to be more helpful than CT as it provides better detection and delineation of the extent of the IMH¹¹. The lesions are characteristically much brighter on T2- than T1-weighted imaging due to the increased free water present within stagnant blood in the vessels¹². Angiography usually clarifies the vascular nature of the lesion, demonstrates feeding vessels and identifies its extent⁴. In our case, pre-operative diagnosis of IMH was strongly guided by the findings of arteriography. However, angiography should be performed if there is a strong suspicion of a vascular deformity.

Various treatment methods have been used in the management of intramuscular haemangioma including steroid injections, radiation therapy, injection of sclerosing agents, cryotherapy and electrocoagulation. However, the optimal management is the surgical resection with wide margins of surrounding normal muscle because of the infiltrative nature of the IMH¹³. The choice of surgical approach depends on the extent and location of the lesion. In our case, intraoral excision was used to achieve the best possible cosmetic result. Preoperative embolisation is indicated for large tumours with multiple or large calibre feeding vessels to minimize blood loss¹⁴.

In conclusion, the possibility of an IMH should be included in the differential diagnosis of any facial mass. The appropriate radiologic examinations can enhance accurate preoperative diagnosis and optimal treatment planning. Surgical resection, well beyond the gross limits of the lesion, is generally considered the ideal therapeutic approach for IMH.

References

- 1 Barnes L. *Tumors and tumor like lesions of the soft tissue*. In: Barnes L, editor. *Pathology of the head and neck*. 2nd Ed. New York: Marcel Dekker; 2001. pp. 900-1.
- 2 Scott JES. *Haemangioma of skeletal muscle*. Br J Surg 1957;44:496-501.
- 3 Allen PW, Enzinger FM. *Hemangioma of skeletal muscle. An analysis of 89 cases*. Cancer 1972;29:8-22.
- 4 Ivey DM, Delfino JJ, Sclaroff A, et al. *Intramuscular hemangioma. Report of a case*. Oral Surg Oral Med Oral Pathol 1980;50:295-300.
- 5 Nam YS, Hwang K. *Intramuscular hemangioma of the lower lip*. J Craniofac Surg 2007;18:958-9.
- 6 Chatterjee R, Blackburn TK, Boyle MA. *Intramuscular haemangioma within depressor anguli oris*. Br J Oral Maxillofac Surg 2007;45:234-5.
- 7 Skoulakis C, Maistrou D, Drivas E, et al. *Intramuscular haemangioma of the orbicularis oculi muscle of the orbit*. Acta Otorhinolaryngol Ital 2007;27:263-5.
- 8 Avci G, Yim S, Misirliogolu A, et al. *Intramaseteric hemangioma*. Plast Reconstr Surg 2002;109:1748-9.
- 9 Demir Z, Oktem F, Celebioglu S. *Rare case of intramaseteric cavernous hemangioma in a three-year-old boy: a diagnostic dilemma*. Ann Otol Rhinol Laryngol 2004;113:455-8.
- 10 Mandel L. *Intramuscular hemangioma with phleboliths or choristoma?* J Oral Maxillofac Surg 2001;59(12):1511-2.
- 11 Buetow PC, Kransdorf MJ, Moser RP, et al. *Radiographic appearance of intramuscular haemangioma with emphasis on MR imaging*. Am J Roentgenol 1990;154:563-7.
- 12 Kanaya H, Saito Y, Gama N, et al. *Intramuscular hemangioma of masseter muscle with prominent formation of phleboliths: a case report*. Auris Nasus Larynx 2008;35:587-91.
- 13 Ichimura K, Nibu K, Tanaka T. *Essentials of surgical treatment for intramaseteric hemangioma*. Eur Arch Otorhinolaryngol 1995;252:125-9.
- 14 Haughton VM. *Hemoclip-Gelfoam emboli in the treatment of facial arteriovenous malformations*. Neuroradiology 1975;10:69-71.

Received: December 20, 2011 - Accepted: May 5, 2011

Address for correspondence: Petros Koltsidopoulos, Department of Otolaryngology, General Hospital of Volos "Achillopoulio", Poulimeri 134, 38222 Volos, Greece. Fax +30 24210 25462. E-mail: petkoltsid@yahoo.gr