

Innovative technique for large septal perforation repair and radiological evaluation

Tecnica innovativa per la riparazione delle perforazioni settali e valutazione radiologica

S. MOCELLA¹, F. MUIA², P.G. GIACOMINI³, D. BERTOSI⁴, E. RESIDORI⁵, S. SGROI⁶

¹ ENT Department, East Garda Bussolengo (VR), Italy; ² Surgery Staff Asl TO5 Chieri (TO), Italy; ³ Tor Vergata University Rome, Italy; ⁴ Maxillo-Facial Department, University of Verona, Italy; ⁵ Radiological Department, East Garda Bussolengo (VR), Italy; ⁶ Department of Radiology, Casa di cura Pederzoli, Peschiera (VR), Italy

SUMMARY

Perforation of the nasal septum may have multiple causes: traumatic, iatrogenic, infectious, degenerative, overuse of vasoconstrictors, abuse of cocaine and more recently chemotherapy agents. Perforations are also classified according to their size and type of cartilaginous or osteocartilaginous deficit, as well as location (front, middle and rear). Many surgical techniques have been proposed to repair the perforation, although the results are often unsatisfactory for perforations of small and medium size; in large perforations permanent obliteration of the defect cannot always be ensured. It is often necessary to use tissues from inside the nasal turbinates or cartilage from other donor sites such as the ear or rib, and various techniques are discussed in light of the recent literature. The perforations observed in the last eight years and surgical approaches performed in open or closed approaches are taken into account. The authors propose a new technique that has been used with success in many types of septal perforation regardless of aetiology, and in particular large perforations, which allows for the use of the osteocartilaginous donor site as a hump. It is also useful in reductive rhinoseptoplasty, which targets selection to easily obtain mucoperichondral flaps with an extramucosal technique and to obtain also an aesthetic improvement.

KEY WORDS: Nasal septal perforation • Reductive rhinoseptoplasty • Osteocartilaginous hump • Diagnostic radiological nasal work-up

RIASSUNTO

La perforazione del setto nasale ha cause molteplici: traumatiche, iatrogene, infettive, degenerative, da abuso di vasocostrittori, da uso di cocaina e di recente anche da chemioterapici antineoplastici. Le perforazioni sono altresì classificate in funzione delle dimensioni e della tipologia del deficit cartilagineo o osteocartilagineo e della sede anteriore, mediana e posteriore. Molteplici tecniche di riparazione chirurgica del danno sono state proposte nel tempo e vengono riassunte nel presente lavoro per tipologia di approccio; i risultati conseguiti, sono soddisfacenti per le perforazioni di piccole e medie dimensioni, ma nelle grandi perforazioni non garantiscono sempre la permanente oblitterazione del difetto. Spesso si rende necessario l'utilizzo di tessuti prelevati all'interno delle fosse nasali come i turbinati o il prelievo di cartilagine da altre sedi donatrici come l'orecchio o la costa; le varie tecniche vengono illustrate alla luce della più recente letteratura. Gli Autori hanno valutato i pazienti osservati negli ultimi 8 anni e i risultati chirurgici conseguiti in particolare considerando, gli approcci chirurgici effettuati in approccio aperto o chiuso, endoscopico ed i materiali impiegati. Gli autori propongono tra le varie tecniche impiegate in questa serie di pazienti, una tecnica innovativa utilizzabile con successo in molti dei casi considerati di perforazione settale iatrogena che prevede l'utilizzo del gibbo osteocartilagineo quale sede donatrice, nonché la rinosettoplastica riduttiva quale scelta mirata per ottenere agevolmente lembi di scorrimento mucopericondrile e talora produrre anche un miglioramento estetico morfologico.

PAROLE CHIAVE: Perforazione del setto nasale • Rinosettoplastica riduttiva • Gibbo osteocartilagineo • Valutazione diagnostica radiologica nasale

Acta Otorhinolaryngol Ital 2013;33:202-214

Introduction

Closure of nasal perforation is one of the most fascinating and exciting of all procedures in nasal reconstructive surgery. It is a challenge for both the surgeon and patient, with the primary goal of restoring aesthetic aspects and recovering anatomical and functional integrity in the same procedure.

Surgical success is based on a precise definition of aetiology; location and the method employed during the intervention along with particular attention to pre- and post-operative care. The authors report their long-standing experience with the definition and treatment of perforations of the nasal septum, which in reality is not an infrequent pathology.

Aetiology and clinical features

The causes of nasal perforation may be local or systemic; in addition, various systemic illnesses may be responsible for the pathology, but there are limited data available regarding the frequency of the different causes of nasal septal perforation¹⁻⁴. A broad investigation in a Swedish population revealed a prevalence of septal perforation of 0.9%⁵.

One of the first documented descriptions of perforation, an anatomopathological specimen, is conserved in the Hunterian Museum of The Royal College of Surgeon in London (n. 1228). In the sagittal section, it is possible to see an important septal perforation of 1.5 cm with a round defined precise configuration in a patient suffering from syphilitic infection who died in the 17th century. Not only is the straight septum around the perforations visible, but it also possible to define margins and a certain degree of depression of the dorsal profile, which is a typical characteristic of the disease. To date, we have not personally observed such a disease as syphilis has now largely disappeared, although other systemic diseases have been seen

Table I. Aetiopatolgy of nasal septal perforations.

Traumatic causes	
Previous surgery ⁷⁻¹¹	
Cauterization or embolization for epistaxis ^{12,13}	
Nasal packing ^{14,15}	
Nasogastric tube placement	
Septal haematoma from blunt trauma	
Battery or other foreign body in nose ¹⁶⁻²⁴	
Chronic nasal cannula use	
Turbulent airflow	
Inflammatory or infectious causes	
Sarcoidosis ^{25,26}	ACE >
Wegener granulomatosis ^{27,28}	ANCA >
Systemic lupus erythematosus ²⁹⁻³⁶	
Tuberculosis ^{37,38}	POSITIVE TEST
AIDS ^{39,40}	
Crohn's disease ⁴¹⁻⁴⁴	HISTOPATOLOGY
Autoimmune diseases ⁴⁵⁻⁵⁰	
Leishmaniasis ⁵¹⁻⁵³	
Cryoglobulinaemia ^{54,55}	
Celiac disease ⁵⁶	POSITIVE TEST
Invasive fungal sinusitis ^{57,58}	
Mycobacterium Kansas infection ⁵⁹	
Neoplastic causes	
Carcinoma	
T-cell lymphomas	HISTOPATOLOGY
Other causes	
Inhaled substances (e.g., cocaine, topical corticosteroids, long-term oxymetazoline or phenylephrine use) ⁶⁰⁻⁷⁵	
Chronic acid fumes ⁷⁶⁻⁷⁹	
Renal failure ⁸⁰	
Use of targeted/biologic therapies in the treatment of malignant and non-malignant diseases (bevacizumab) ⁸¹⁻⁸⁸	
Use of methotrexate or docetaxel in the treatment of malignant disease ^{89,90}	

during recent years which must be detected by biopsy⁶ to better plan adequate treatment.

Table I lists the aethiopathology and causes of septal perforations, specific diagnostic tests of the different diseases and recent observations of septal perforations during the use of antineoplastic pharmacological treatment.

Table II provides some suggestions and precautions that should be adopted to prevent and avoid septal perforations in different circumstances⁹¹⁻⁹³.

Classification and diagnostic endoscopic features

Septal perforations are classified according to site and topography: cartilaginous, osteocartilaginous or intermediate, bone or posterior; according to size: small (< 1 cm in diameter), medium (1-2 cm) and large (> 2 cm). Often, the size of cartilage or bone perforation is greater than that of the mucosa, and therefore instrumental techniques for high-precision measurement of the perforation have been proposed⁹⁴⁻⁹⁶.

Physical examination of the nose begins with an evaluation of the external nose. Large perforations may result in loss of support to the dorsum of the nose and subsequent saddle nose deformity with occasional lateral deviation of the anterior part of the pyramid.

Table II. Suggestions and precautions in nasal septal perforations (from Batniji 2012)⁹⁷.

Prescribe heated, humidified continuous positive airway pressure devices for patients with obstructive sleep apnoea.
Minimize steroid use in patients.
During septoplasty, minimize resection of cartilage and use meticulous technique to avoid bilateral tears in the mucosa.
Minimize nasal trauma during the insertion of nasogastric tubes by (1) decongesting the nose with oxymetazoline or phenylephrine prior to nasogastric tube insertion, (2) inserting the nasogastric tube along the floor of the nose parallel to the hard palate and perpendicular to the plane of the face, and (3) lubricating the tip of the nasogastric tube.
Modify the nasal cannula in patients on long-term supplemental oxygen and humidify the supplemental oxygen. Taping 2 wooden toothpicks to the hub of the cannula (the thickened plastic part where the prongs are attached) modifies the nasal cannula. This directs the oxygen straight into the nose and away from the nasal septum.
When cauterizing the nasal septum for epistaxis, avoid cauterizing both sides simultaneously.
Stop cocaine use.
Stop or minimize use of topical nasal decongestants.
Run a humidifier in the bedroom.
Frequently use nasal saline sprays.
Use nasal emollients (especially before bedtime).
Decrease digital nasal trauma. Parents may want to place mittens on their young children's hands at night.
Discontinue the use of aspirin or non-steroidal anti-inflammatory drugs.

Anterior endoscopic rhinoscopy is essential in initial examination of the patient, and may reveal the configuration of the perforation, the presence of crusting and irregularities of mucosal structure (Figs. 1, 2). Topical nasal decongestants may be utilized for intranasal inspection of the entire septum. Nasal endoscopy provides more information on the evaluation of the entire septum. Palpation of the septum with a cotton-tipped applicator provides valuable information regarding the integrity of the quadrangular cartilage in the remainder of the septum. Some clinical cases are shown in the Figures 3-6.

Diagnostic work-up

In diagnostic work up of septal perforation, several detailed laboratory investigations can be performed that are especially useful to detect medical causes of septal perforations.

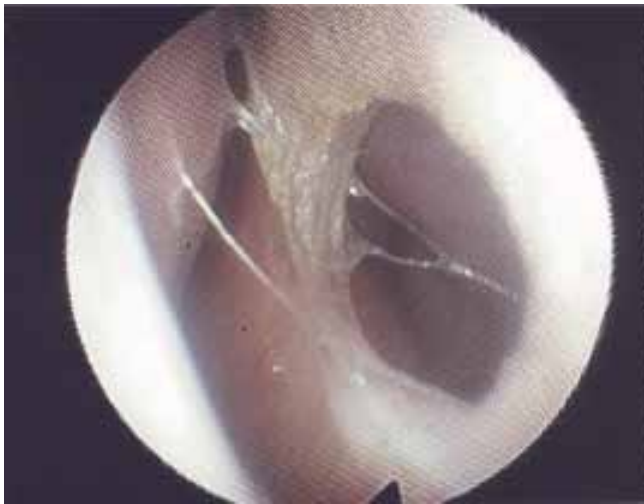

Fig. 1. Septal perforation of one cm in a cocaine user. It is possible to note the circular configuration, infection and the ischaemic aspect of mucosa near the margin of the lesion.

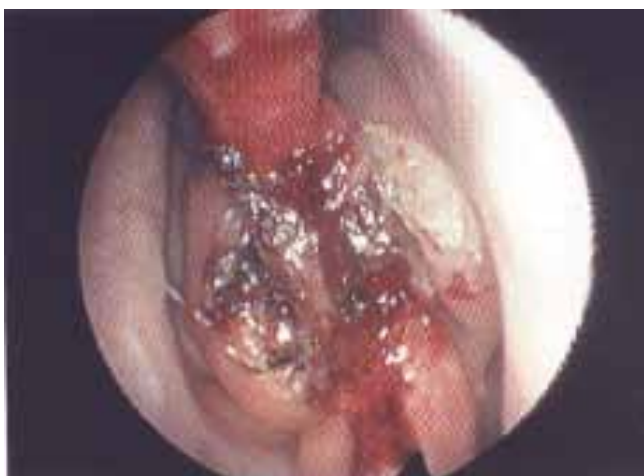

Fig. 2. Patient with a large septal perforation due to chronic acid exposure. The superior part of perforation is visible near the middle turbinate showing important vascularisation near the edges.

an algorithm such as that recently proposed by Batniji may be used, but for patients who use cocaine (often not admitted) is absolutely mandatory to identify on their urine the presence of cocaine catabolites in urine, or if possible and from hair; in these patients, it is advisable to not to perform surgery until after one year of cocaine cessation.

Diagnostic management of the nasal septum perforation is shown in the flow chart in Fig. 7, according to that proposed by Rami K. Batniji in 2012⁹⁷.

Surgical procedures

Many surgical procedures have been proposed to repair the defect, either by endonasal approaches using mucoperichondrial⁹⁸⁻¹¹⁵ or combined flaps with interposition of the graft using septal cartilage, uncinat process, middle turbinate, auricular or costal cartilage and temporal fascia¹¹⁶⁻¹³⁹, also utilizing a backwards extraction-reposition technique of the quadrangular cartilage¹⁴⁰ or using other non-autologous tissues or synthetic materials¹⁴¹⁻¹⁴⁷.

In large perforations, four authors have suggested the use of labial and oral flaps¹⁴⁸⁻¹⁵¹.

The open approach is considered more likely to dominate the edges of the perforation and to ensure routine surgical dissection and reconstruction of the defect¹⁵²⁻¹⁶⁵.

However, it is often not possible to obtain flaps that are large enough to cover the defect. To overcome this, some authors have suggested combining reductive rhinoseptoplasty to use the excess of mucosa that arises as a fabric to repair the septal perforation¹⁶⁶⁻¹⁶⁹. Other authors have also proposed the use of expanders positioned under the mucoperichondrium to achieve the same result¹⁷⁰⁻¹⁷².

Radiological work-up

In many of our surgical cases, radiological specific work-up and elaboration techniques of imaging was performed before and after surgery for septal perforation to obtain as much information as possible regarding nasal structure and framework; the method was applied to identify the loss of bone and mucosal layers, and to quantify and obtain exact measures of the defect to help in planning reconstruction. Some anatomic structures of the paranasal sinuses, and especially nasal septum which is of main interest in our cases, are not optimally visualized to plan surgical procedures by computed tomography (CT) and 2D MRI (Magnetic Resonance Imaging) with standard image reconstruction in the axial and coronal planes.

Elaboration of CT scans was performed, in addition to virtual 3D endoscopy (Fig. 8) using a work station furnished by the CT or MRI manufacturer. Multidetector CT scanners with 16 detector rows (or more) allow the acquisition of volumetric data sets that can be electronically reconstructed in any plane. Recent 1.5T (or 3.0T) MRI scanners equipped with new 3D acquisition sequences al-

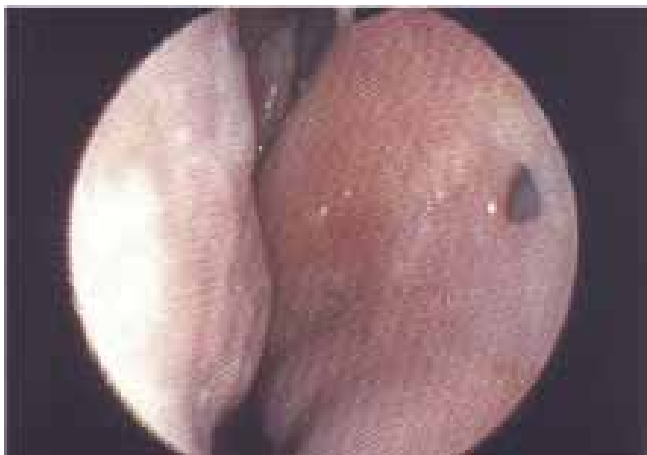

Fig. 3. Patient with a small perforation due to previous surgery with the contemporary presence of nasal atrophia and secretions.

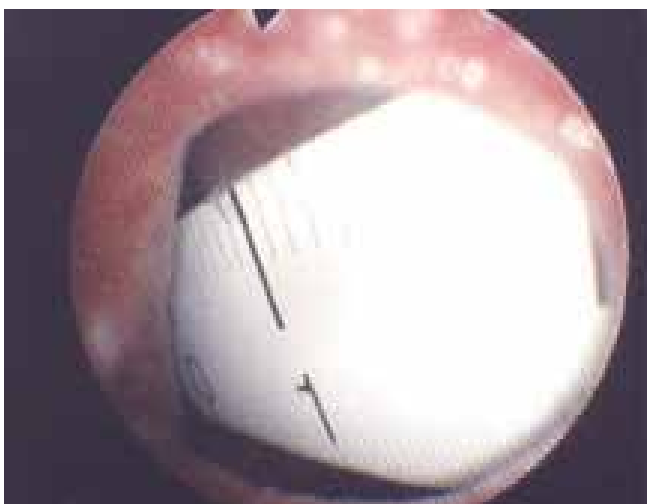


Fig. 4. The perforation's size is detected during endoscopic examination.

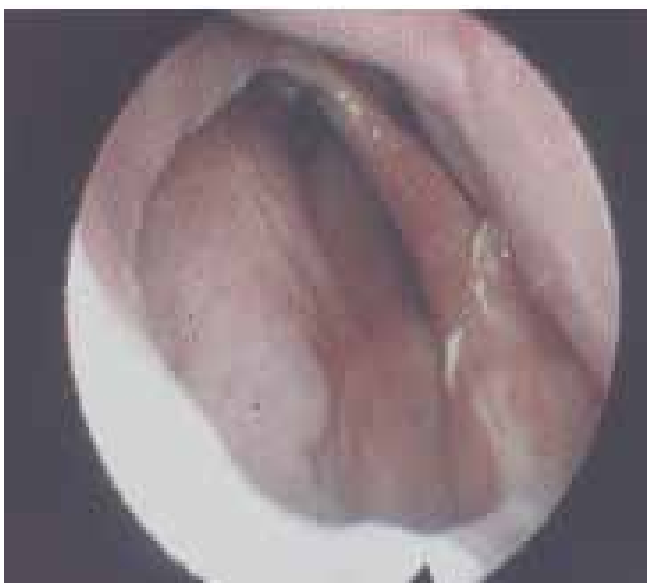

Fig. 5. Patient with a septal perforation of almost 2 cm with irregularities of margins due to previous iatrogenic surgery.

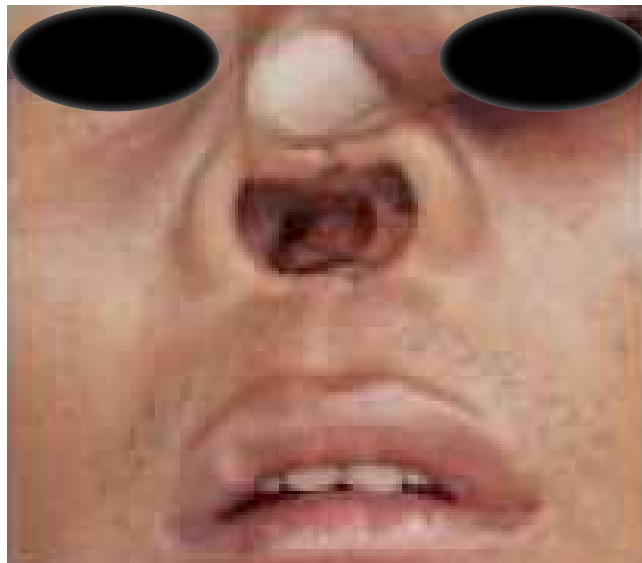

Fig. 6. Patient with perforation of septum and destruction of the columella.

low the acquisition of volumetric data sets as well, with the advantage (compared to CT) of better visualization of soft tissues with no radiation exposure.

These techniques give radiologists and surgeons the opportunity to visualize anatomic structures in greater detail and may help increase diagnostic accuracy and therapeutic planning of diseases of the paranasal sinuses and nasal septum.

Multidetector CT

CT examination of the paranasal sinuses is performed at our institution using a multidetector scanner (Sensation 16; Siemens, Erlangen, Germany). The scanner is equipped with 16 rows of detectors. Scanning is performed in the standard axial plane with a helical technique (120 kV, 100 Eff. mAs, pitch of 0.55, rotation time of 0.75 second, section thickness of 0.75 mm, and a 512 × 512 matrix).

The subject's head is placed in a neutral position, without chin tilt. The image data set is reconstructed with an individual voxel size of 0.75 × 0.75 × 0.75 mm.

The images included in the present article were reconstructed at a standard workstation (Wizard; Siemens) and at a standard PACS Workstation (Synapse, Fujifilm Medical Systems, equipped with Voxar 3D 6.3 software). The time required for multiplanar reconstruction of the CT image data set was about 3-5 min per reconstruction.

Purpose

Each reconstruction was tailored to better depict the structure of clinical interest, namely the nasal septum and paranasal sinuses. The anatomic location and orientation of the structures to be evaluated were confirmed on images in three orthogonal (axial, coronal, and sagittal) planes of

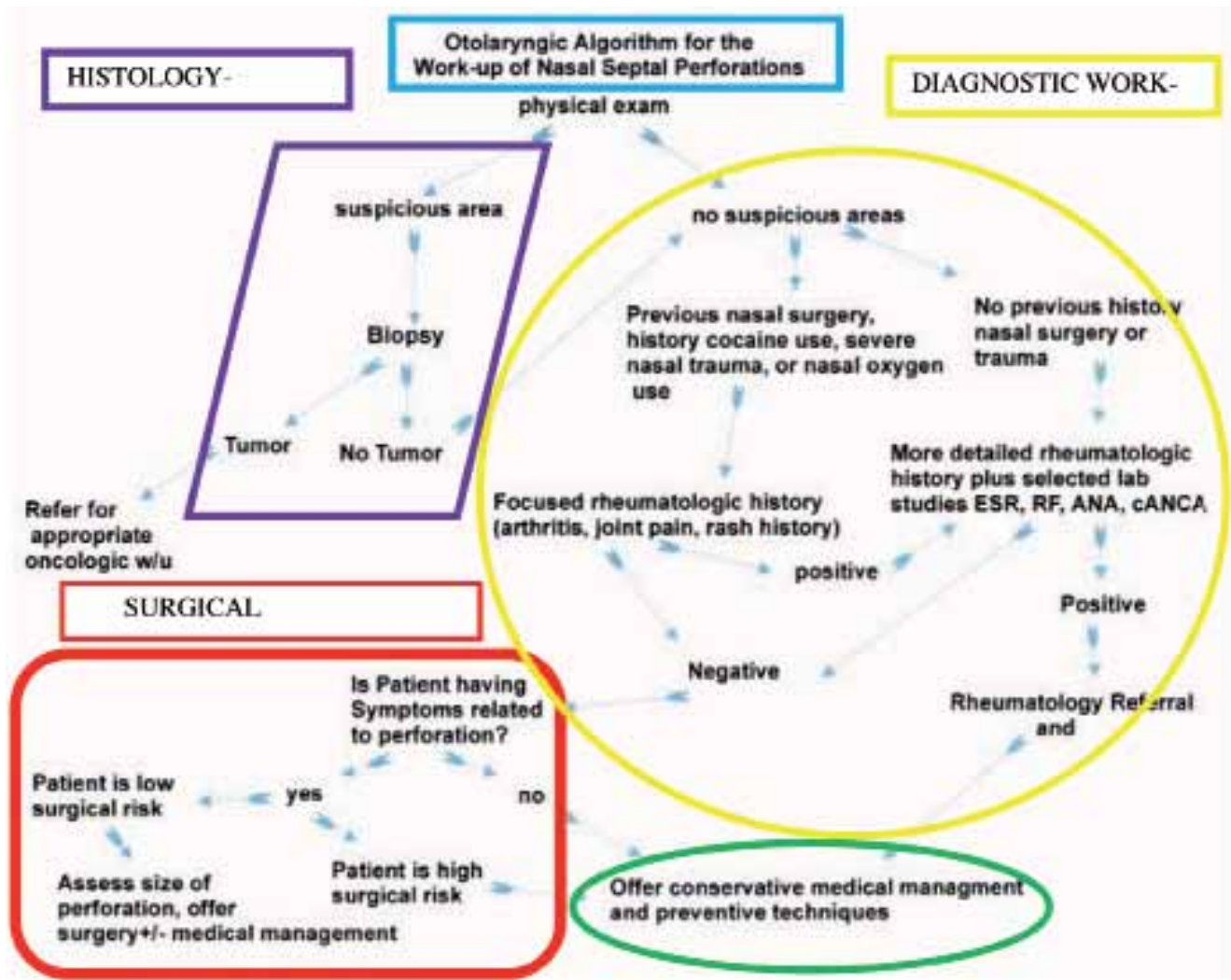


Fig. 7. Proposed algorithm modified by Rami K. Batniji⁹⁷ for a systematic evaluation of newly diagnosed septal perforation with the surgical indications in red and diagnostic work-up in yellow.

reference. Moreover, 3D VRT (volume rendering technique) and animated three3D reformatting images were obtained to achieve the best overview of morphology and local anatomy, integrating 2D information, thus providing an excellent preoperative “road map” and planning tool. Oblique and curved planes of section were defined to optimally depict any given structure (Figs. 9-10).

Surgical technique

According to Foda 1999¹⁵⁷, the major goal in septal perforation surgery is not only to repair the perforation, but also to restore normal form and function to the nose. The increased surgical exposure provided by an open approach not only facilitates repair of large and posterior perforations, but also allows contemporary rhinoplasty. On the basis of these observations, in a large series of our patients (14 patients of the 87 observed over 8 years), reductive rhinoseptoplasty was performed with the principal aim to

obtain more tissue in the same operatory field and to have the possibility of increasing the transfer and movement of flaps to cover the defect.

In 1995, Kridel affirmed that the possibility of correcting septal perforation and nasal external deformities in a unique set presents technical difficulties, and only challenging cases in which perforation is small and a dorsal hump can be removed are appropriate for synchronous correction.

In our opinion, due to the general features of the perforation, an oval form (Fig. 11) with a cranio-caudal diameter is generally less important than the antero-posterior one. It is thus more useful to reduce the perforation with contemporary reductive rhinoseptoplasty.

In the cases we present herein, an open external approach was adopted in the majority of cases with an extramucosal internal technique and removal of the hump; extracorporeal treatment of the septum was performed with modelling and reconstruction using the

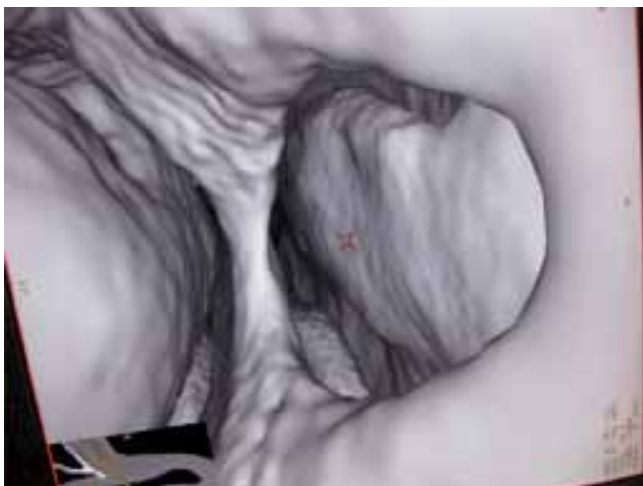


Fig 8. Virtual 3D endoscopy of a patient with septal perforation with a high resolution image of the nasal fossa, turbinates and margins of perforation.

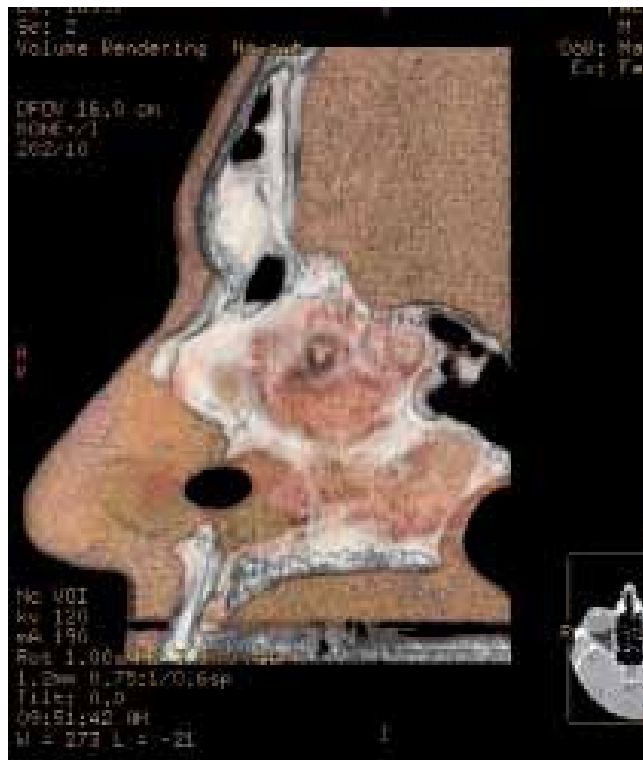

Fig. 10. Lateral sagittal selected view of a patient with a middle perforation; the exact location of perforation is visible along with the relationship with other bone structures.

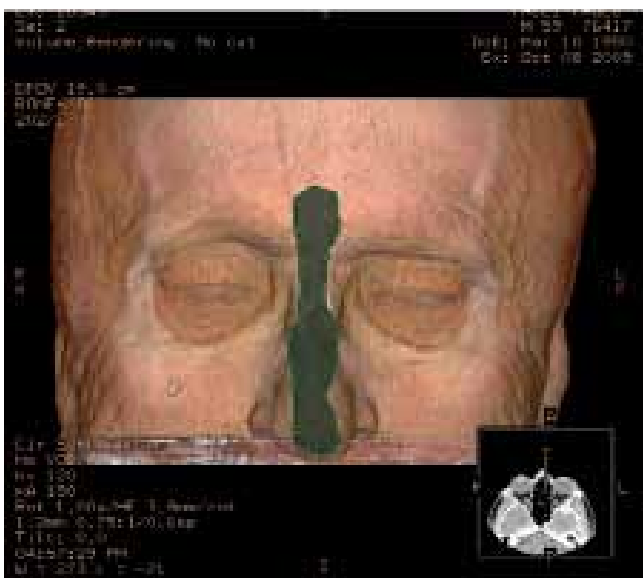


Fig. 9. Selection of reconstruction on a facial rendering.

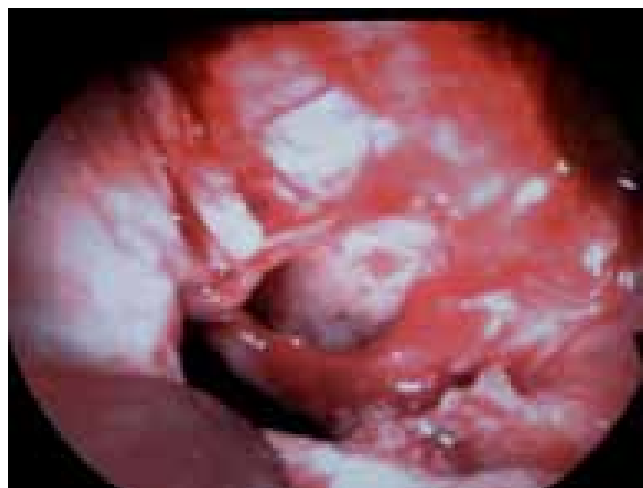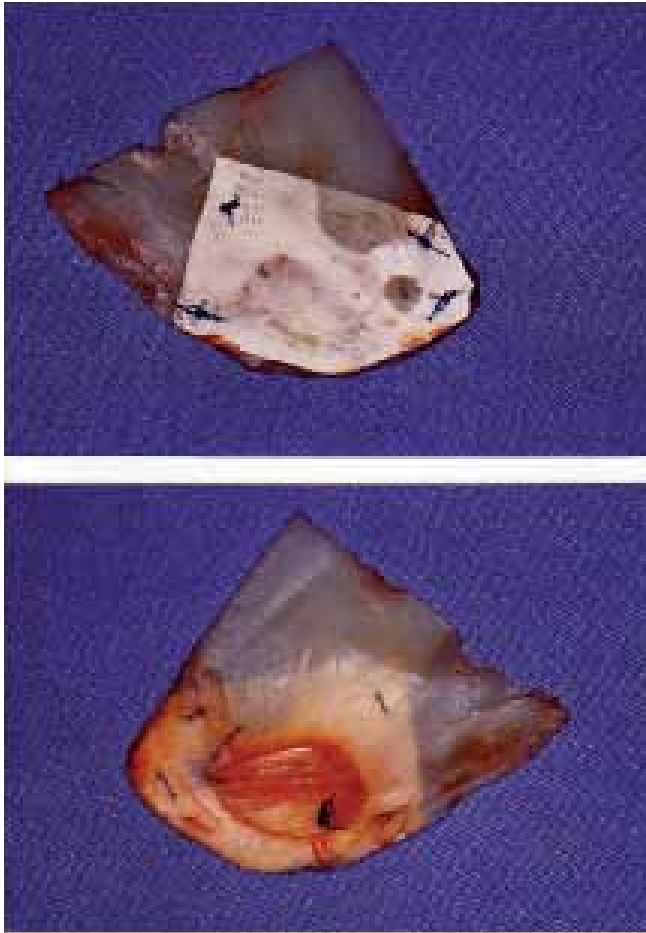


Fig. 11. Endoscopic view after complete removal of the septum with suture perforation of the mucopericondrial layers performed beginning posteriorly and advancing anteriorly in each side.

hump crushed and the covering of the obtained graft with fascia of compatible biological origin (pericardial fascia) or membrane obtained by heterologous auricular biocompatible cartilage. If the hole was completely covered with the graft, we employed the fascia (Figs. 12-13). Otherwise, we utilized the cartilaginous membrane which is more consistent, and in our opinion provides a higher possibility of success.

In some cases from our experience, we used an endonasal approach with a reductive rhinoseptoplasty. In these cases, the septal was reassembled with an extracorporeal technique and repositioned inside between the two sutured layers (Fig. 14) of mucosa.

After the initial experience, an open approach was routinely performed to obtain better exposition. In the sequence of Figures 15-20 is presented a clinical case with a large posterior perforation repaired and the radiological work-up.



Figs. 12, 13. The hump removed is placed in the place of perforation during extracorporeal septoplasty, the septum is reassembled and modelled and covered with fascia.

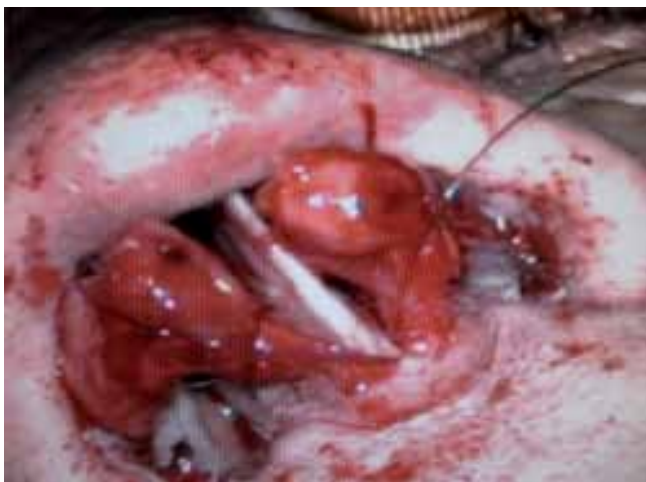

Fig. 14. The septum is inserted in the middle during an open approach and fixed at the spine perichondrium and dorsal vault.

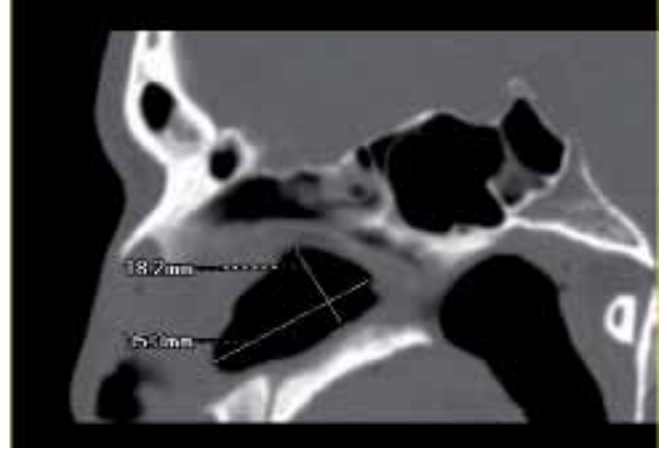
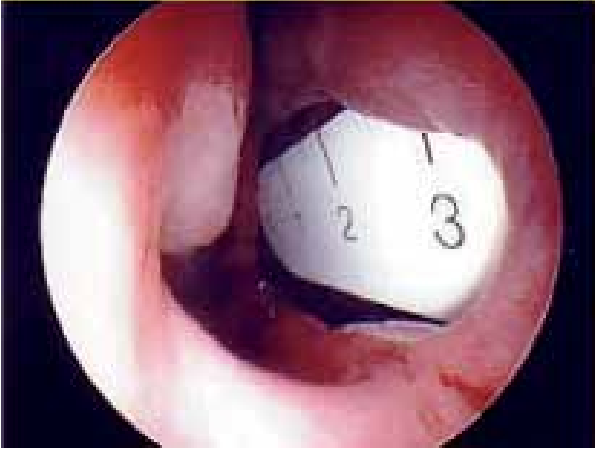Conclusions

The main objective in management of septal perforations is to restore the nasal framework and to close the defect to obtain complete healing of mucosa, and consequently less crusting and bleeding, which in some cases may persist despite the surgical effort.

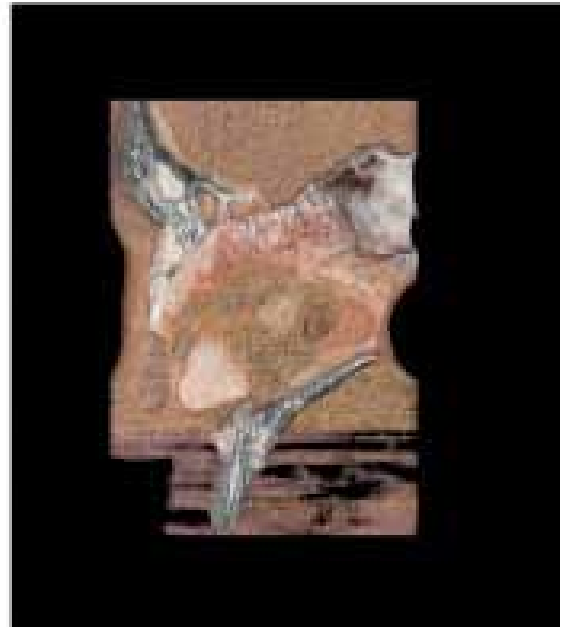
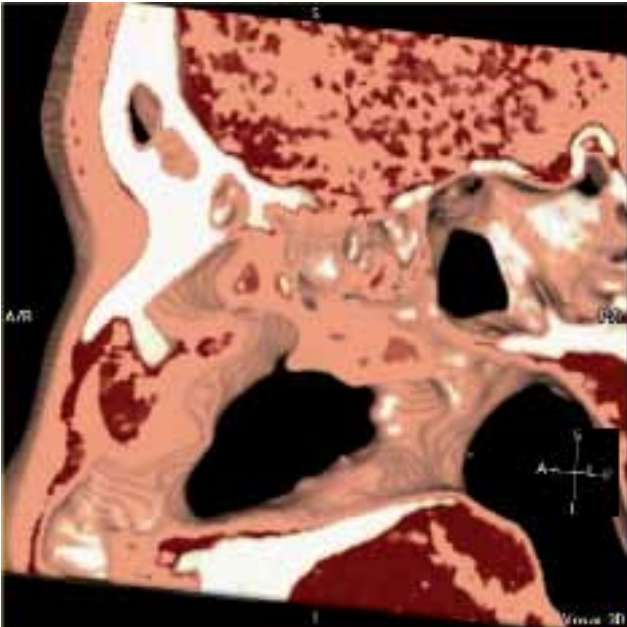
Our aim was to repair the largest perforations by mainly utilizing the tissue present in the nasal field, and for this reason we began employing the hump to reassemble the septal defect; it is true that on occasion only transfer of mucosa and interpositioning of fascia may be successful, but for large defects we prefer a more consistent tissue to create more favourable healing and migration of epithelium. As affirmed by Foda¹⁵⁷, the disadvantages of surgery are that the difficulties in effectively closing a septal perforation are directly proportional to the size of perforation. Nonetheless, we also believe that the relative dimension of the external nose is important, regardless of the presence or absence of the hump that could be used for reconstruction.

For better surgical planning a precise diagnostic work up with laboratory exams is useful if the perforation may have a medical origin or if cocaine use is suspected or confirmed; regarding radiological work-up, we have long-standing collaborations with radiologists that have provided excellent results. Additional applications and developments could further improve both results and future simulations.

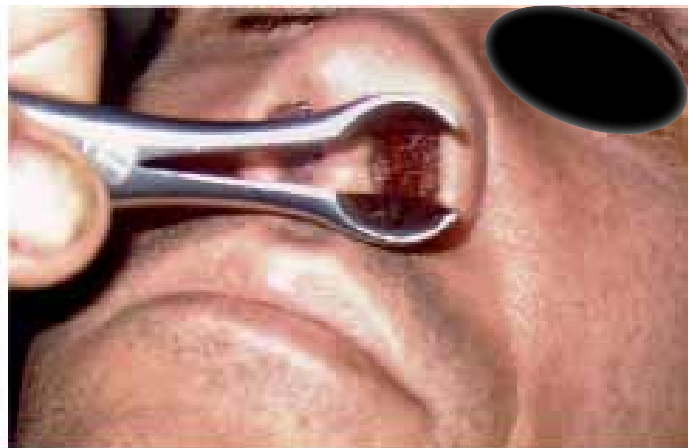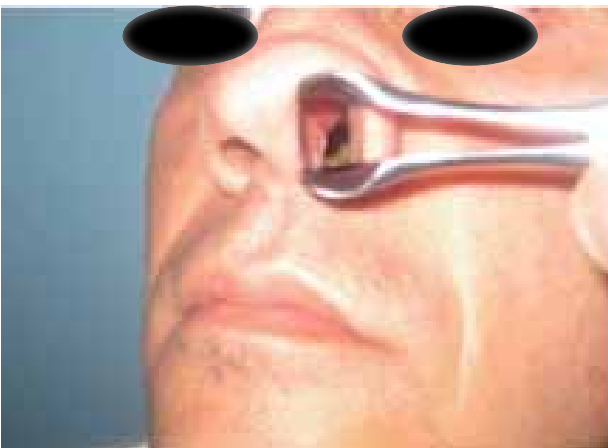Repair of septal perforation is now a challenging lengthy procedure, and only few expert surgeons have dedicated themselves to such procedures. To better understand the actual efficacy of these procedures, more experienced surgeons should share their results to improve knowledge and to obtain larger study groups, with particular attention to the use of biological material utilized, which will increase the safety, efficacy and ease of the procedures for repair of septal perforations.



Figs. 15, 16. Endoscopic view of an iatrogenic septal perforation of a perforation larger than 3 cm, and a normal sagittal view with measures of perforation.



Figs. 17, 18. Elaborated CT reconstruction with the method described in the text, and post-operative reconstruction with repair of the perforation. The biological material utilized in reconstruction and repair of the perforation is visible.



Figs. 19, 20. Pre- and post-operative anterior rhinoscopy of the same patient in the previous figures.

References

- 1 Lanier B, Kai G, Marple B, et al. *Pathophysiology and progression of nasal septal perforation*. *Ann Allergy Asthma Immunol* 2007;99:473-9;quiz 480-1,521.
- 2 Younger R, Blokmanis A. *Nasal septal perforations*. *J Otolaryngol* 1985;14:125-31.
- 3 Diamantopoulos II, Jones NS. *The investigation of nasal septal perforations and ulcers*. *J Laryngol Otol* 2001;115:541-4.
- 4 Vignes S, Chaillet M, Cabane J, et al. [*Nasal septal perforation and systemic disease*]. *Rev Med Interne* 2002;23:919-26.
- 5 Døsen LK, Haye R. *Nasal septal perforation 1981-2005: changes in etiology, gender and size*. *BMC Ear Nose Throat Disord* 2007;7:1.
- 6 Murray A, McGarry GW. *The clinical value of septal perforation biopsy*. *Clin Otolaryngol Allied Sci* 2000;25:107-9.
- 7 Stoksted P, Vase P. *Perforations of the nasal septum following operative procedures*. *Rhinology* 1978;16:123-38.
- 8 Schönsted-Madsen U, Stoksted PE, Outzen KE. *Septorhinoplastic procedures versus submucous resection of the septum, using septum perforation as an indicator*. *Rhinology* 1989;27:63-6.
- 9 Li Y, Xu G. [*Complications of nasal endoscopic surgery*]. *Zhonghua Er Bi Yan Hou Ke Za Zhi* 1998;33:142-5.
- 10 Ketcham AS, Han JK. *Complications and management of septoplasty*. *Otolaryngol Clin North Am* 2010;43:897-904.
- 11 Topal O, Celik SB, Erbek S, et al. *Risk of nasal septal perforation following septoplasty in patients with allergic rhinitis*. *Eur Arch Otorhinolaryngol* 2011;268:231-3.
- 12 Amin M, Glynn F, Phelan S, et al. *Silver nitrate cauterisation, does concentration matter?* *Clin Otolaryngol* 2007;32:197-9.
- 13 Bent JP 3rd, Wood BP. *Complications resulting from treatment of severe posterior epistaxis*. *J Laryngol Otol* 1999;113:252-4.
- 14 von Schoenberg M, Robinson P, Ryan R. *Nasal packing after routine nasal surgery--is it justified?* *J Laryngol Otol* 1993;107:902-5.
- 15 Dowley AC, Strachan DR. *Allergy to Merozel nasal packs causing septal perforation and inferior turbinate necrosis*. *J Laryngol Otol* 2001;115:735.
- 16 Bundgaard N, Tveterås K. [*Perforation of the nasal septum caused by a miniature battery*]. *Ugeskr Laeger* 1989;151:3323-4.
- 17 Kharoubi S. *Rhinolithiasis associated with septal perforation. A case report*. *Acta Otorhinolaryngol Belg* 1998;52:241-5.
- 18 García Callejo FJ, Martínez Beneito MP, Ortega Navarro MC. [*Body piercing complications in otorhinolaryngology*]. *Acta Otorrinolaringol Esp* 1998;49:338-9.
- 19 Umariya N, Chavda SV, Pahor AL. *An unusual cause of nasal septum perforation*. *J Laryngol Otol* 1999;113:1020-1.
- 20 Karkos PD, Karagama YG, Manivasagam A, et al. *Magnetic nasal foreign bodies: a result of fashion mania*. *Int J Pediatr Otorhinolaryngol* 2003;67:1343-5.
- 21 Lehman DA, Roy S. *Septal perforation caused by nasal magnetic foreign bodies*. *Ear Nose Throat J* 2005;84:266-7.
- 22 Greenberg M, Magit A. *Magnetic nasal foreign bodies in a 9-year-old male: opposites attract when it comes to nasal foreign bodies*. *Int J Pediatr Otorhinolaryngol* 2005;69:981-2.
- 23 Shermetaro C, Charnesky M. *Pediatric nasal septal perforation secondary to magnet misuse: a case report*. *Ear Nose Throat J* 2007;86:675-6.
- 24 Bao XL, Cai KM. [*One case with perforation of nasal septum and palate caused by iatrogenic foreign body in nose and rhinolith*]. *Zhonghua Er Bi Yan Hou Tou Jing Wai Ke Za Zhi* 2010;45:559.
- 25 Baum ED, Boudousquie AC, Li S, et al. *Sarcoidosis with nasal obstruction and septal perforation*. *Ear Nose Throat J* 1998;77:896-8, 900-2.
- 26 Patey O, Bonnieux P, Roucayrol AM, et al. *Sarcoidosis of the nose: report of a case with nasal perforation*. *Sarcoidosis* 1990;7:123-4.
- 27 Mann W, Bumb P, Märker-Hermann E. [*Chronic rhinosinusitis with septal perforation. Differential diagnostic considerations*]. *HNO* 2008;56:1129-34.
- 28 Kasifoglu T, Cansu D, Korkmaz C. *Clinical images: perforation of the nasal septum and palate due to Wegener's granulomatosis*. *Arthritis Rheum* 2008;58:2564.
- 29 Vachtenheim J., Grossmann J. *Letter: Nasal-septum perforation in systemic lupus erythematosus*. *N Engl J Med* 1974;291:51.
- 30 Snyder GG 3rd, McCarthy RE, Toomey JM, et al. *Nasal septal perforation in systemic lupus erythematosus*. *Arch Otolaryngol* 1974;99:456-7.
- 31 Bach GL. [*Nasal septum perforation in disseminated lupus erythematosus, case report and literature review*]. *Z Rheumatol* 1980;39:22-7.
- 32 Lerner DN. *Nasal septal perforation and carotid cavernous aneurysm: unusual manifestations of systemic lupus erythematosus*. *Otolaryngol Head Neck Surg* 1996;115:163-6.
- 33 Rahman P, Gladman DD, Urowitz MB. *Nasal-septal perforation in systemic lupus erythematosus--time for a closer look*. *J Rheumatol* 1999;26:1854-5.
- 34 Mascarenhas R, Tellechea O, Oliveira H, et al. *Nasalseptum perforation as the presenting sign of lupus erythematosus*. *Dermatol Online J* 2005;11:12.
- 35 Matsumoto FY, Clivati Brandt HR, Costa Martins JE, et al. *Nasoseptal perforation secondary to lupus vulgaris*. *J Dermatol* 2007;34:493-4.
- 36 Garg A, Wadhwa R, Gulati SP, et al. *Lupus vulgaris of external nose with septal perforation--a rarity in antibiotic era*. *Indian J Tuberc* 2010;57:157-9.
- 37 Lai TY, Liu PJ, Chan LP. *Primary nasal tuberculosis presenting with septal perforation*. *J Formos Med Assoc* 2007;106:953-5.
- 38 Trinidade A, Shakeel M, Majithia A, et al. *Tuberculosis with secondary vasculitis presenting as a nasal septal perforation*. *J Coll Physicians Surg Pak* 2011;21:631-3.
- 39 Rejali SD, Simo R, Saeed AM, et al. *Acquired immune deficiency syndrome (AIDS) presenting as a nasal septal perforation*. *Rhinology* 1999;37:93-5.
- 40 Colebunders R, De Roo A, Benimadho S, et al. *A nasal septum perforation caused by a Varicella zoster infection in an AIDS patient*. *Acta Otorhinolaryngol Belg* 1997;51:49-50.

- 41 Bachmeyer C, Laurette F, Coutarel P, et al. [Perforation of the nasal septum in hemorrhagic rectocolitis]. *Presse Med* 1996;25:1890.
- 42 Kryssia RC, Henry ZB. *Nasal septum perforation: rare manifestation of Crohn's disease*. *Indian J Gastroenterol* 2006;25:214.
- 43 Sari S, Dalgic B, Yilmaz M, et al. *Nasal septal perforation in an adolescent girl with Crohn's disease: a rare extraintestinal manifestation*. *Dig Dis Sci* 2007;52:1285-7.
- 44 Goral V. *Rare and new extraintestinal complication of ulcerative colitis: nasal septal perforation*. *Inflamm Bowel Dis* 2012;18:E397-8.
- 45 Mathews JL, Ward JR, Samuelson CO, et al. *Spontaneous nasal septal perforation in patients with rheumatoid arthritis*. *Clin Rheumatol* 1983;2:13-8.
- 46 El Biaz S, Naji Y, Tijani A, et al. [Nasal septum perforation: initial presentation in a patient with rheumatoid arthritis]. *Presse Med* 2010;39:982-3.
- 47 Akar S, Dogan E, Goktay Y, et al. *Nasal septal perforation in a patient with Takayasu's arteritis; a rare association*. *Intern Med* 2009;48:1551-4.
- 48 Banerjee SS, Lammin K, Carpentier J. *Nasal septal perforation and antiphospholipid syndrome (Hughes syndrome)*. *J Laryngol Otol* 2007;121:1197-200.
- 49 Tsuda T, Nakajima A, Baba S, et al. *A case of relapsing polychondritis with bilateral sensorineural hearing loss and perforation of the nasal septum at the onset*. *Mod Rheumatol* 2007;17:148-52.
- 50 Avcin T, Silverman ED, Forte V, et al. *Nasal septal perforation: a novel clinical manifestation of systemic juvenile idiopathic arthritis/adult onset Still's disease*. *J Rheumatol* 2005;32:2429-31. Erratum in: *J Rheumatol* 2006;33:199-200.
- 51 Amini J. [Perforation of the nasal septum caused by leishmaniasis]. *Ann Otolaryngol Chir Cervicofac* 1976;93:691-4.
- 52 Vellin JF, Russier M, Mougeot G, et al. [Nasal leishmaniasis: a case report]. *Ann Otolaryngol Chir Cervicofac* 2005;122:100-4.
- 53 Brahn E, Pegues DA, Yao Q, et al. *Mucocutaneous leishmaniasis masquerading as Wegener granulomatosis*. *J Clin Rheumatol* 2010;16:125-8.
- 54 Vignes S, Chaillet M, Cabane J, et al. [Nasal septal perforation and systemic disease]. *Rev Med Interne* 2002;23:919-26.
- 55 Smith I, Smith M, Mathias D, et al. *Cryoglobulinaemia and septal perforation: a rare but logical cause*. *J Laryngol Otol* 1996;110:668-9.
- 56 Medina-Banegas A, Pastor-Quirante FA, Osete-Albaladejo J, et al. *Nasal septal perforation in a patient with subclinical celiac disease: a possible new association*. *Eur Arch Otorhinolaryngol* 2005;262:928-31.
- 57 Ruiz N, Fernandez-Martos C, Romero I, et al. *Invasive fungal infection and nasal septum perforation with bevacizumab-based therapy in advanced colon cancer*. *J Clin Oncol* 2007;25:3376-7.
- 58 Kuo WT, Lee TJ, Chen YL, et al. *Nasal septal perforation caused by invasive fungal sinusitis*. *Chang Gung Med J* 2002;25:769-73.
- 59 Bennett AM, Patel N, Kotecha B, et al. *Septal perforation secondary to Mycobacterium kansasii infection*. *J Laryngol Otol* 2003;117:992-4.
- 60 Vilensky W. *Illicit and licit drugs causing perforation of the nasal septum*. *J Forensic Sci* 1982;27:958-62.
- 61 Schwartz RH, Grundfast KM. *Nasal septal perforation from illicit drug use*. *Am Fam Physician* 1986;34:187-8.
- 62 Gendeh BS, Ferguson BJ, Johnson JT, et al. *Progressive septal and palatal perforation secondary to intranasal cocaine abuse*. *Med J Malaysia* 1998;53:435-8.
- 63 Yewell J, Haydon R, Archer S, et al. *Complications of intranasal prescription narcotic abuse*. *Ann Otol Rhinol Laryngol* 2002;111:174-7.
- 64 Goodger NM, Wang J, Pogrel MA. *Palatal and nasal necrosis resulting from cocaine misuse*. *Br Dent J* 2005;198:333-4.
- 65 Blaise G, Vanhooteghem O, De La Brassinne M. [Perforation of the nasal septum in cocaine abusers]. *Rev Med Liege* 2005;60:845-8.
- 66 Simsek S, de Vries XH, Jol JA, et al. *Sino-nasal bony and cartilaginous destruction associated with cocaine abuse, S. aureus and antineutrophil cytoplasmic antibodies*. *Neth J Med* 2006;64:248-51.
- 67 Harper SJ, Jones NS. *Cocaine: what role does it have in current ENT practice? A review of the current literature*. *J Laryngol Otol* 2006;120:808-11.
- 68 Medina R, Espinós MA, Bartumeus P, et al J. [Septal perforation in cocaine abusers: utility of the computed tomography]. *Radiologia* 2009;51:90-2.
- 69 Miller FF. *Occurrence of nasal septal perforation with use of intranasal dexamethasone aerosol*. *Ann Allergy* 1975;34:107-9.
- 70 Soderberg-Warner ML. *Nasal septal perforation associated with topical corticosteroid therapy*. *J Pediatr* 1984;105:840-1.
- 71 Isaksson M, Bruze M, Wihl JA. *Contact allergy to budesonide and perforation of the nasal septum*. *Contact Dermatitis* 1997;37:133.
- 72 Cervin A, Andersson M. *Intranasal steroids and septum perforation--an overlooked complication? A description of the course of events and a discussion of the causes*. *Rhinology* 1998;36:128-32.
- 73 Deepak D, Panjabi C, Gudwani S, et al. *Nasal septal perforation in a patient with allergic bronchopulmonary aspergillosis and rhinitis on long term corticosteroids*. *Asian Pac J Allergy Immunol* 2001;19:287-90.
- 74 Chiang MY, Shah P. *Nasal septal perforation enlargement related to topical ocular steroids*. *Br J Clin Pharmacol* 2005;60:664-5.
- 75 Keyserling HF, Grimme JD, Camacho DL, et al. *Nasal septal perforation secondary to rhinitis medicamentosa*. *Ear Nose Throat J* 2006;85:376,378-9.
- 76 Sanz P, Moline JL, Sole D, et al. *Nasal septum perforation in chromate-producing industry in Spain*. *J Occup Med* 1989;31:1013-4.
- 77 Lin SC, Tai CC, Chan CC, et al. *Nasal septum lesions caused by chromium exposure among chromium electroplating workers*. *Am J Ind Med* 1994;26:221-8.
- 78 Williams N. *Nasal septal ulceration and perforation in jiggers*. *Occup Med (Lond)* 1998;48:135-7.

- 79 Castano R, Thériault G, Gautrin D. *Categorizing nasal septal perforations of occupational origin as cases of corrosive rhinitis*. *Am J Ind Med* 2007;50:150-3.
- 80 Adler D, Ritz E. *Perforation of the nasal septum in patients with renal failure*. *Laryngoscope* 1980;90:317-21.
- 81 Fakih MG, Lombardo JC. *Bevacizumab-induced nasal septum perforation*. *Oncologist* 2006;11:85-6.
- 82 Traina TA, Norton L, Drucker K, et al. *Nasal septum perforation in a bevacizumab-treated patient with metastatic breast cancer*. *Oncologist* 2006;11:1070-1.
- 83 Burkart CM, Grisel JJ, Hom DB. *Spontaneous nasal septal perforation with antiangiogenic bevacizumab therapy*. *Laryngoscope* 2008;118:1539-41.
- 84 Bengrine-Lefevre L, Afchain P, Chibaudel B, et al. [*Nasal septum perforation and bevacizumab*]. *Rev Med Interne* 2011;32:e43-5.
- 85 Marín AP, Sánchez AR, Arranz EE. *Nasal septum perforation in a breast cancer patient treated with bevacizumab*. *Ann Oncol* 2009;20:1901-2.
- 86 Power DG, Kemeny NE. *Nasal septum perforation and bevacizumab*. *Med Oncol* 2011;28:89-93.
- 87 Ramiscal JA, Jatoi A. *Bevacizumab-induced nasal septal perforation: incidence of symptomatic, confirmed event(s) in colorectal cancer patients*. *Acta Oncol* 2011;50:578-81.
- 88 Petrelli F, Cabiddu M, Barbara C, et al. *A patient presenting nasal septum perforation during bevacizumab-containing chemotherapy for advanced breast cancer*. *Breast Cancer* 2011;18:226-30.
- 89 Lee SL, Neskey D, Mouzakes J. *Potential predisposition for nasal septal perforation with methotrexate use: report of 2 cases and literature review*. *Ear Nose Throat J* 2009;88:E12-4.
- 90 Tan TH, Stevenson B, Yip D. *Docetaxel-induced nasal septal perforation*. *Intern Med J* 2006;36:471-2.
- 91 Fairbanks DN, Fairbanks GR. *Nasal septal perforation: prevention and management*. *Ann Plast Surg* 1980;5:452-9.
- 92 Eng SP, Nilssen EL, Ranta M, et al. *Surgical management of septal perforation: an alternative to closure of perforation*. *J Laryngol Otol* 2001;115:194-7.
- 93 Kridel RW. *Considerations in the etiology, treatment, and repair of septal perforations*. *Facial Plast Surg Clin North Am* 2004;12:435-50,vi.
- 94 Tanuma F, Mishima H, Kase Y, et al. [*A clinical treatise upon the nasal septal perforation*]. *Nihon Jibiinkoka Gakkai Kaiho* 1999;102:878-82.
- 95 Rettinger G, Hosemann W. *Measuring the size of nasal septal perforations. A simple radiological method*. *Rhinology* 1988;26:157-9.
- 96 Frank DA, Kern EB, Kispert DB. *Measurement of large or irregular-shaped septal perforations by computed tomography*. *Radiol Technol* 1988;59:409-12.
- 97 Rami K Batniji. *Septal Perforation - Medical Aspects Treatment & Management*. Medscape Reference Feb. 2012 - emedicine.medscape.com
- 98 Virte M, Tisserant J, Simon C, et al. [*Current status of the treatment of nasal septal perforations*]. *Ann Otolaryngol Chir Cervicofac* 1986;103:603-7.
- 99 Jahn AF. *How I do it: a simple eversion flap for repair of small septal perforations*. *J Otolaryngol* 1994;23:69-70.
- 100 Schultz-Coulon HJ. *Experiences with the bridge-flap technique for the repair of large nasal septal perforations*. *Rhinology* 1994;32:25-33.
- 101 Woolford TJ, Jones NS. *Repair of nasal septal perforations using local mucosal flaps and a composite cartilage graft*. *J Laryngol Otol* 2001;115:22-5.
- 102 Ayshford CA, Shykhon M, Uppal HS, et al. *Endoscopic repair of nasal septal perforation with acellular human dermal allograft and an inferior turbinate flap*. *Clin Otolaryngol Allied Sci* 2003;28:29-33.
- 103 Zhang Q, Zhang J, Li S. *Endoscope-assisted repair of large nasal septal perforation using a complex mucoperichondrial flap and free tissue graft*. *Chin Med J (Engl)* 2003;116:157-8.
- 104 Friedman M, Ibrahim H, Ramakrishnan V. *Inferior turbinate flap for repair of nasal septal perforation*. *Laryngoscope* 2003;113:1425-8.
- 105 Huang Q, Zhou B, Han DM, et al. [*Endoscopic surgery for nasal septal perforation*]. *Zhonghua Er Bi Yan Hou Tou Jing Wai Ke Za Zhi* 2005;40:579-81.
- 106 Tasca I, Compadretti GC. *Closure of nasal septal perforation via endonasal approach*. *Otolaryngol Head Neck Surg* 2006;135:922-7.
- 107 André RF, Lohuis PJ, Vuyk HD. *Nasal septum perforation repair using differently designed, bilateral intranasal flaps, with nonopposing suture lines*. *J Plast Reconstr Aesthet Surg* 2006;59:829-34.
- 108 Lee HR, Ahn DB, Park JH, et al. *Endoscopic repairment of septal perforation with using a unilateral nasal mucosal flap*. *Clin Exp Otorhinolaryngol* 2008;1:154-7.
- 109 Islam A, Celik H, Felek SA, et al. *Repair of nasal septal perforation with "cross-stealing" technique*. *Am J Rhinol Allergy* 2009;23:225-8.
- 110 Islam A, Felek S, Celik H, et al. [*Repair of nasal septal perforation with different intranasal flap techniques and their outcomes*]. *Kulak Burun Bogaz Ihtis Derg* 2009;19:232-8.
- 111 Teymoortash A, Werner JA. *Repair of nasal septal perforation using a simple unilateral inferior meatal mucosal flap*. *J Plast Reconstr Aesthet Surg* 2009;62:1261-4.
- 112 Neumann A, Morales-Minovi CA, Schultz-Coulon HJ. [*Closure of nasal septum perforations by bridge flaps*]. *Acta Otorrinolaringol Esp* 2011;62:31-9.
- 113 Raol N, Olson K. *A Novel technique to repair moderate-sized nasoseptal perforations*. *Arch Otolaryngol Head Neck Surg* 2012;16:1-3.
- 114 Yousef-Mian M. *Repair of nasal septal perforation*. *Am J Rhinol* 1997;11:35-40.
- 115 Castelnuovo P, Ferrel F, Khodaei I, et al. *Anterior ethmoidal artery septal flap for the management of septal perforation*. *Arch Facial Plast Surg* 2011;13:411-4.
- 116 Lopatin AS, Ovchinnikova EV. [*Peculiarities of the surgical treatment of nasal septum perforations*]. *Vestn Otorinolaringol* 2012;2:13-7.
- 117 Matton G. *Re: Ohlsén: Closure of nasal septal perforation with a cutaneous flap and a perichondrocutaneous graft*. *Ann Plast Surg* 1990;24:98.
- 118 Meyer R, Mayer B, Perko D. [*Concept and technique for*

- closure of septum defects*]. *Handchir Mikrochir Plast Chir* 1991;23:296-300.
- ¹¹⁹ Meyer R. *Nasal septal perforations must and can be closed*. *Aesthetic Plast Surg* 1994 Fall;18:345-55.
- ¹²⁰ Nuñez-Fernández D, Vokurka J, Chrobok V. *Bone and temporal fascia graft for the closure of septal perforation*. *J Laryngol Otol* 1998;112:1167-71.
- ¹²¹ Mobley SR, Boyd JB, Astor FC. *Repair of a large septal perforation with a radial forearm free flap: brief report of a case*. *Ear Nose Throat J* 2001;80:512.
- ¹²² Pedroza F, Patrocinio LG, Arevalo O. *A review of 25-year experience of nasal septal perforation repair*. *Arch Facial Plast Surg* 2007;9:12-8.
- ¹²³ Presutti L, Alicandri Ciuffelli M, Marchioni D, et al. *Nasal septal perforations: our surgical technique*. *Otolaryngol Head Neck Surg* 2007;136:369-72.
- ¹²⁴ Li F, Liu Q, Yu H, et al. *Pedicled local mucosal flap and autogenous graft for the closure of nasoseptal perforations*. *Acta Otolaryngol* 2011;131:983-8.
- ¹²⁵ Ma YX, Tao AZ, Lu C, et al. [*Endoscopic repair of nasal septal perforation with acellular dermal matrix and pedicled mucoperichondrial flap*]. *Zhonghua Er Bi Yan Hou Tou Jing Wai Ke Za Zhi* 2011;46:455-8.
- ¹²⁶ Dosen LK, Haye R. *Surgical closure of nasal septal perforation. Early and long term observations*. *Rhinology* 2011;49:486-91.
- ¹²⁷ Kazkayasi M, Yalcinozan ET. *Uncinate process in the repair of nasoseptal perforation*. *Aesthetic Plast Surg* 2011;35:878-81.
- ¹²⁸ Vuyk HD, Versluis RJ. *The inferior turbinate flap for closure of septal perforations*. *Clin Otolaryngol Allied Sci* 1988;13:53-7.
- ¹²⁹ Friedman M, Ibrahim H, Ramakrishnan V. *Inferior turbinate flap for repair of nasal septal perforation*. *Laryngoscope* 2003;113:1425-8.
- ¹³⁰ Stoor P, Grénman R. *Bioactive glass and turbinate flaps in the repair of nasal septal perforations*. *Ann Otol Rhinol Laryngol* 2004;113:655-61.
- ¹³¹ Liu B, Zhao R, Kong W. [*To repair perforation of nasal septum with free mucosa of inferior turbinate*]. *Lin Chuang Er Bi Yan Hou Ke Za Zhi* 2004;18:468-9.
- ¹³² Kazkayasi M, Tuna E, Kilic C. *Bullous middle turbinate flap for the repair of nasal septal perforation*. *J Otolaryngol Head Neck Surg* 2010;39:203-6.
- ¹³³ Mansour HA. *Repair of nasal septal perforation using inferior turbinate graft*. *J Laryngol Otol* 2011;125:474-8.
- ¹³⁴ Tastan E, Aydogan F, Aydin E, et al. *Inferior turbinate composite graft for repair of nasal septal perforation*. *Am J Rhinol Allergy* 2012;26:237-42.
- ¹³⁵ Martins M. [*A contribution to the closing of perforations of the nasal septum (author's transl)*]. *HNO* 1978;26:183-4.
- ¹³⁶ Chua DY, Tan HK. *Repair of nasal septal perforations using auricular conchal cartilage graft in children: report on three cases and literature review*. *Int J Pediatr Otorhinolaryngol* 2006;70:1219-24.
- ¹³⁷ Taskin U, Yigit O, Sisman SA. *Septal perforation repairing with combination of mucosal flaps and auricular interpositional grafts in revision patients*. *Otolaryngol Head Neck Surg* 2011;145:828-32.
- ¹³⁸ Guyuron B, Afrooz PN. *Correction of cocaine-related nasal defects*. *Plast Reconstr Surg* 2008;121:1015-23.
- ¹³⁹ Giacomini PG, Ferraro S, Di Girolamo S, et al. *Large nasal septal perforation repair by closed endoscopically assisted approach*. *Ann Plast Surg* 2011;66:633-6.
- ¹⁴⁰ Sarandeses-García A, Sul senti G, López-Amado M, et al. *Septal perforations closure utilizing the backwards extraction-reposition technique of the quadrangular cartilage*. *J Laryngol Otol* 1999;113:721-4.
- ¹⁴¹ Chhabra N, Houser SM. *Endonasal repair of septal perforations using a rotational mucosal flap and acellular dermal interposition graft*. *Int Forum Allergy Rhinol* 2012;2:392-6.
- ¹⁴² Parry JR, Minton TJ, Suryadevara AC, et al. *The use of fibrin glue for fixation of acellular human dermal allograft in septal perforation repair*. *Am J Otolaryngol* 2008;29:417-22.
- ¹⁴³ Ambro BT, Zimmerman J, Rosenthal M, et al. *Nasal septal perforation repair with porcine small intestinal submucosa*. *Arch Facial Plast Surg* 2003;5:528-9.
- ¹⁴⁴ Jasso-Victoria R, Olmos-Zuñiga JR, Gutierrez-Marcos LM, et al. *Usefulness of bovine pericardium as interpositional graft in the surgical repair of nasal septal perforations (experimental study)*. *J Invest Surg* 2003;16:209-17.
- ¹⁴⁵ Deng C, Li R, Yang J, et al. [*Repairing large perforation of nasal septum with titanium membrane and local pedicled mucoperiosteum flap*]. *Lin Chuang Er Bi Yan Hou Ke Za Zhi* 2006;20:358-9.
- ¹⁴⁶ Daneshi A, Mohammadi S, Javadi M, et al. *Repair of large nasal septal perforation with titanium membrane: report of 10 cases*. *Am J Otolaryngol* 2010;31:387-9.
- ¹⁴⁷ Boenisch M, Nolst Trenité GJ. *Reconstruction of the nasal septum using polydioxanone plate*. *Arch Facial Plast Surg* 2010;12:4-10.
- ¹⁴⁸ Rettinger G, Masing H, Heidl W. [*Management of septal perforations by rotationplasty of the septal mucosa*]. *HNO* 1986;34:461-6.
- ¹⁴⁹ Heller JB, Gabbay JS, Trussler A, et al. *Repair of large nasal septal perforations using facial artery musculomucosal (FAMM) flap*. *Ann Plast Surg* 2005;55:456-9.
- ¹⁵⁰ Kogan L, Gilbey P, Samet A, et al. *Nasal septal perforation repair using oral mucosal flaps*. *Isr Med Assoc J* 2007;9:373-5.
- ¹⁵¹ Hirshowitz B, Moscona R, Eliachar I. *Closure of septal perforation in Osler-Weber-Rendu's disease by bilateral labial-buccal flaps*. Case report. *Plast Reconstr Surg* 1978;62:296-9.
- ¹⁵² Romo T 3rd, Foster CA, Korovin GS, et al. *Repair of nasal septal perforation utilizing the midface degloving technique*. *Arch Otolaryngol Head Neck Surg* 1988;114:739-42.
- ¹⁵³ Goodman WS, Strelzow VV. *The surgical closure of nasoseptal perforations*. *Laryngoscope* 1982;92:121-4.
- ¹⁵⁴ Kridel RW, Foda H, Lunde KC. *Septal perforation repair with acellular human dermal allograft*. *Arch Otolaryngol Head Neck Surg* 1998;124:8.
- ¹⁵⁵ Romo T 3rd, Sclafani AP, Falk AN, et al. *A graduated approach to the repair of nasal septal perforations*. *Plast Reconstr Surg* 1999;103:66-75.
- ¹⁵⁶ Kridel RW. *Septal perforation repair*. *Otolaryngol Clin North Am* 1999;32:695-724.

- ¹⁵⁷ Foda HM. *The one-stage rhinoplasty septal perforation repair*. J Laryngol Otol 1999;113:728-33.
- ¹⁵⁸ Li Z, Zhang S. [With periosteal "sandwich" suturing and repairing septonasal perforation by nasal columella degloving]. Lin Chuang Er Bi Yan Hou Ke Za Zhi 1999;13:483-4.
- ¹⁵⁹ Newton JR, White PS, Lee MS. *Nasal septal perforation repair using open septoplasty and unilateral bipediced flaps*. J Laryngol Otol 2003;117:52-5.
- ¹⁶⁰ Kridel RW. *Considerations in the etiology, treatment, and repair of septal perforations*. Facial Plast Surg Clin North Am 2004;12:435-50,vi.
- ¹⁶¹ Watson D, Barkdull G. *Surgical management of the septal perforation*. Otolaryngol Clin North Am 2009;42:483-93.
- ¹⁶² Wong S, Raghavan U. *Outcome of surgical closure of nasal septal perforation*. J Laryngol Otol 2010;124:868-74.
- ¹⁶³ Rokkjær MS, Barrett TQ, Petersen CG. *Good results after endonasal cartilage closure of nasal septal perforations*. Dan Med Bull 2010;57:A4196.
- ¹⁶⁴ Yildirim G, Onar V, Sayin I, et al. *The reconstruction of nasal septal perforation with high density porous polyethylene covered with fascia lata: an experimental study on rabbit model*. Clin Exp Otorhinolaryngol 2011;4:137-41.
- ¹⁶⁵ Yenigun A, Meric A, Verim A, et al. *Septal perforation repair: mucosal regeneration technique*. Eur Arch Otorhinolaryngol 2012;269:2505-10.
- ¹⁶⁶ Strelzow VV, Goodman WS. *Nasoseptal perforation--closure by external septorhinoplasty*. J Otolaryngol 1978;7:43-8.
- ¹⁶⁷ Kridel RW, Appling WD, Wright WK. *Septal perforation closure utilizing the external septorhinoplasty approach*. Arch Otolaryngol Head Neck Surg 1986;112:168-72.
- ¹⁶⁸ Foda HM, Magdy EA. *Combining rhinoplasty with septal perforation repair*. Facial Plast Surg 2006;22:281-8.
- ¹⁶⁹ Ribeiro JS, da Silva GS. *Technical advances in the correction of septal perforation associated with closed rhinoplasty*. Arch Facial Plast Surg 2007;9:321-7.
- ¹⁷⁰ Romo T 3rd, Jablonski RD, Shapiro AL, et al. *Long-term nasal mucosal tissue expansion use in repair of large nasoseptal perforations*. Arch Otolaryngol Head Neck Surg 1995;121:327-31.
- ¹⁷¹ Van Damme PA. *Long-term nasal mucosal tissue expansion use*. Arch Otolaryngol Head Neck Surg 1996;122:898.
- ¹⁷² Romo T. III : *Septal Perforation – Surgical Aspects*. Medscape Reference Jun 2012 emedicine.medscape.com

Received: December 15, 2012 - Accepted: January 7, 2013