

Surgical correction of “rhinoplastic look”

Correzione chirurgica del “rhinoplastic look”

S. SCIUTO¹, N. BIANCO²

¹ Casa di Cura Nostra Signora della Mercedes, Roma, Italy; ² Casa di Cura Santa Rita, Atripalda (AV), Italy

SUMMARY

A pointed, narrow and exaggeratedly upturned nasal tip and concave dorsal profile can give the nose an unnatural and artificial appearance that is the unmistakable hallmark of plastic surgery. As a result of changes in social attitudes, noses that have evidently been operated on are no longer acceptable and requests are made for correction. While a more natural dorsal profile can be obtained with camouflage grafts of autologous cartilage or alloplastic material (EPTFE), autologous grafts alone are used to reconstruct the tip. The most complex correction regards an obtuse nasolabial angle, for which the extension graft technique is used. Particular care must be taken during preoperative planning, where the aid of computer simulation and agreement with the patient are essential.

KEY WORDS: Rhinoplasty • Saddle nose • Short nose • Pinched nose • Rhinoplastic look

RIASSUNTO

Un profilo dorsale incavato, una punta stretta, sottile ed esageratamente all'insù possono essere tali da conferire al naso quell'aspetto innaturale ed artefatto che costituisce l'inconfondibile stigma di un naso operato. L'evoluzione del costume ha fatto sì che questo aspetto palesemente “chirurgico” del naso non sia accettato e ne venga richiesta la correzione. Il ripristino di un profilo dorsale più naturale viene ottenuto con innesti di camouflage di cartilagine autologa o di materiale alloplastico (EPTFE), mentre la ricostruzione della punta è affidata esclusivamente a innesti autologhi. La correzione più complessa è quella dell'angolo naso-labiale troppo aperto che viene effettuata attraverso la tecnica dell'extension graft. Particolare cura deve essere posta nel planning pre-operatorio da effettuarsi con l'aiuto della simulazione al computer e attentamente concordato con il paziente.

PAROLE CHIAVE: Rinoplastica • Naso a sella • Naso corto • Naso pinzato • Naso chirurgico

Acta Otorhinolaryngol Ital 2013;33:177-182

Introduction

“Doctor, I want a nose that looks natural, not one that has obviously been operated on”.

This is the first thing every patient always says today on first meeting a surgeon with a view to rhinoplasty. Ever since the 1990s, both surgeons and patients have in fact developed increasingly sophisticated tastes when considering operative results. As a result of the same evolution, the cute little turned-up nose is no longer considered an aesthetic model by the overwhelming majority of individuals wishing to alter the shape of their nose^{1,2}.

In many cases, the fact that an otherwise by no means unattractive nose that has a “rhinoplastic look” will prompt patients to undergo revision surgery to eliminate or at least attenuate this undesired result.

The rhinoplastic look

The major characteristics that make a nose look unnatural and artificial after surgery can be identified on the basis of patients' complaints as follows:

- concave dorsal profile;
- over-rotation of the tip;
- narrow, pointed tip.

Concave dorsal profile

The correction of slight concavity of the nasal dorsum is carried out at the strictly sub-muscular level using a camouflage graft, the selection and creation of which require particular care. The aim is in fact to improve an initial situation that is by no means disastrous, and patients will show little tolerance for errors in estimating the degree of elevation obtained, which falls within a narrow range where 1 or 2 mm can make all the difference. Computer simulation proves very useful indeed in planning these operations and helps to establish the thickness of the graft required for an optimal result in the preoperative stage. When available, autologous grafts of septal cartilage can be used as long as they are free from curving and irregularity, whereas cartilage from the auricular concha, which is curved and variable in thickness, is unsuitable for camouflage of the dorsum precisely where the nasal skin is thinnest.

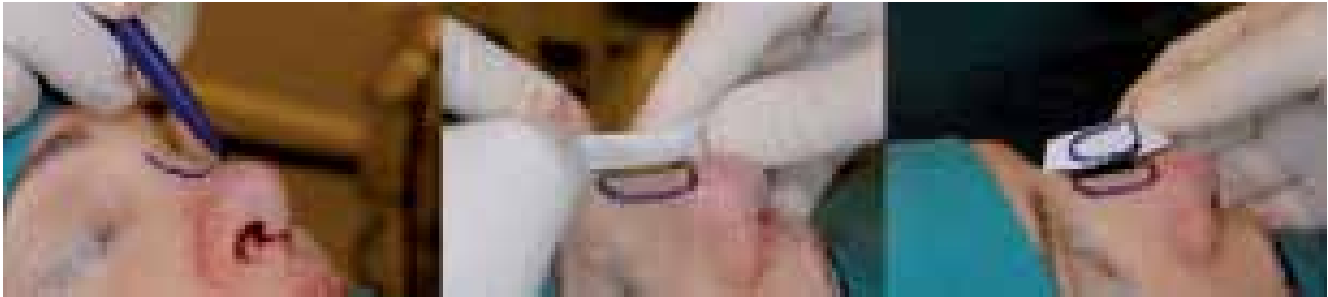


Fig. 1. The shape and size of the Gore-Tex (EPTFE) graft are obtained from the outline drawn on the ridge of the nose in methylene blue.

A valid alternative is the use of EPTFE (Gore-Tex), which is available in sheets of 1 mm in thickness for cutting to shape (Fig. 1), and can be applied in two or three layers where necessary. The greatest advantage of EPTFE is its softness, which means that it moulds itself to the shape of the nasal dorsum and is undetectable by touch even in cases where the skin is particularly thin.

Where greater thickness is required, it is possible to use a composite graft with autologous cartilage below and a layer of EPTFE on top. While the cartilage provides volume, the Gore-Tex ensures overall uniformity and conceals potentially visible irregularities. The two layers are stitched together with 6-0 nylon before insertion.

Over-rotation of the nasal tip

Over-rotation of the tip is frequently caused by excessive resection of the caudal septum, often related to the surgeon's practically unquantifiable view that "*in any case, the tip always drops a little after...*".

The correction of over-rotation often presents serious difficulties. If only slight adjustment is required, a Sheen-type shield graft may prove sufficient³. If the upper part of the shield shows a tendency to rotate upwards, a buttress graft will provide further support and strengthening to keep it in the desired position⁴. In the comparatively frequent cases where slight over-rotation is combined with saddle nose, surgeons can also take advantage of the fact that correction of the latter produces an optical effect that makes the tip look less rotated than it actually is. When a greater degree of correction is required, an extension graft⁵ to reconstruct the missing caudal septum must be used.

The monolateral or bilateral septal extension graft is sutured (with 6-0 nylon) between the dorsal border of the septum and the upper lateral cartilages. Unlike a spreader graft, it projects beyond the anterior septal angle in proportion to the degree of elongation required. An intercruar graft is secured to the end to serve in the same way as a columellar strut for attachment of the medial crura of the alar cartilages (Fig. 2).

The septal cartilage is the ideal material for these grafts when present in straight and sufficiently long segments.

In cases where it is not available, there are two alternatives, namely the auricular concha and rib cartilage. The former is, however, insufficient for the purpose to exert caudal pressure on the complex of the alar cartilages and hence the nasal tip due to its curved and insufficiently rigid character. At the same time, using rib cartilage involves an additional scar and makes the operation more invasive. In my experience, insertion of alloplastic materials such as EPTFE or Medpor in a mobile structure like the nasal tip can lead to complications in the form of rejection or extrusion.

Narrow, pointed tip

This is nearly always caused by interruption of the domes of the alar cartilages, a technique widely used in the 1960s and 1970s. While giving excellent results when performed by expert surgeons⁶, in less expert hands this can lead to collapse of the lateral crura of the alar cartilages with both aesthetic and functional consequences, namely a pinched nose with an unnaturally narrow tip and insufficiency of the external nasal valve. The same effects can also be observed when the alar cartilages are not actually cut across the domes, but markedly weakened by excessive resection of their cephalic border.

The surgeon must seek to restore the continuity of the arch of each alar cartilage by identifying the residual stumps so that they can be joined together again with non-absorbable sutures. Excessively weakened lateral crura must be strengthened with lateral crural onlay grafts or strut grafts⁷ (Fig. 3). Where this is not sufficient, the lateral crus must be rebuilt with autologous cartilage (Fig. 4). While septal cartilage can be used for this purpose, cartilage from the concha can also be used, which proves very suitable in this case because its natural convexity recreates the shape of the lateral crura of the alar cartilages.

A Sheen-type shield graft provides the tip with shape, volume and projection. Moreover, being secured to the alar cartilages with non-absorbable sutures, it also serves a functional purpose by making the structures of the external nasal valve more compact and stable (Fig. 5).



Fig. 2. Septal extension graft.

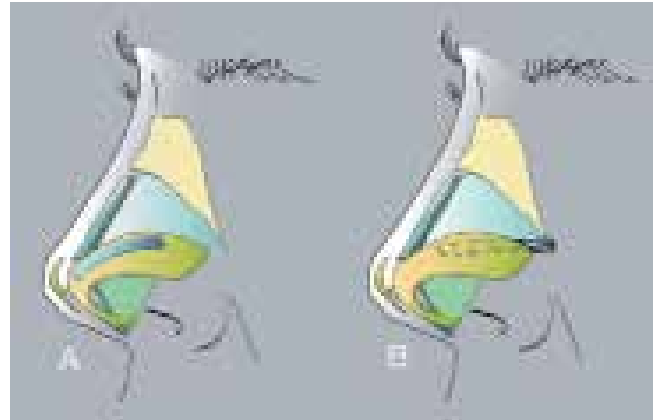


Fig. 3. Lateral crural onlay graft (A) and lateral crural strut graft (B).

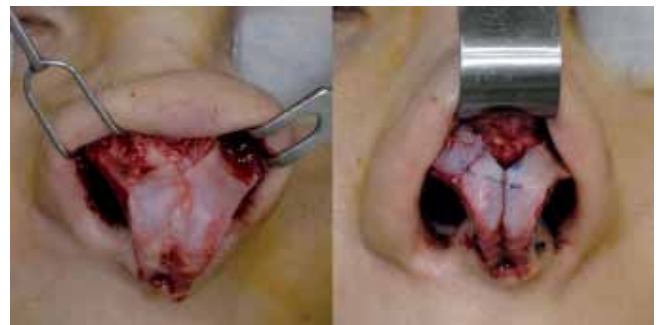

Fig. 4. Left: right lateral crus severed and absent. Right: reconstruction with autologous cartilage.

Clinical cases

Case 1: male patient with surgically-shaped nose

FD, age 23 years, who underwent rhinoseptoplasty two years earlier subsequent to trauma, complained of the surgical appearance of his nose and difficulty in respiration. Objective examination showed slight concavity of the nasal dorsum and a hint of inverted-V deformity. The nasolabial angle is slightly obtuse and some septal deviation remains.

Surgical procedures: exposure of nasal structures with an open approach.

Findings: presence of a bony spur of the septum reducing the respiratory space, absence of the lower part of the septal cartilage, and absence of the dorsal border of the upper lateral cartilages, which were retracted from the dorsal border of the septum.

Reconstruction involved resection of the bony spur of the septum and repositioning of the septal cartilage; bilateral spreader grafts; insertion of a 1 mm graft of Gore-Tex on the dorsum to raise the dorsal profile and camouflage the inverted-V deformity; no work on the tip; no osteotomies (Fig. 6).

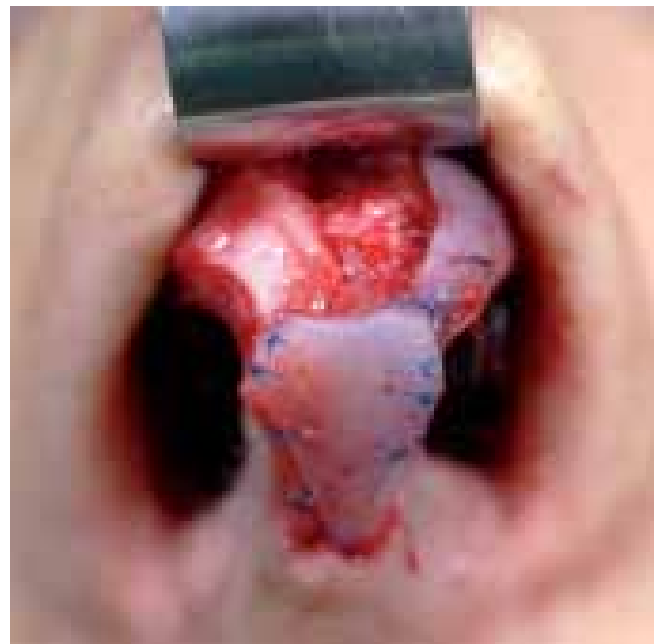


Fig. 5. Shield graft secured to the complex of the alar cartilages with non-absorbable sutures (6-0 nylon).

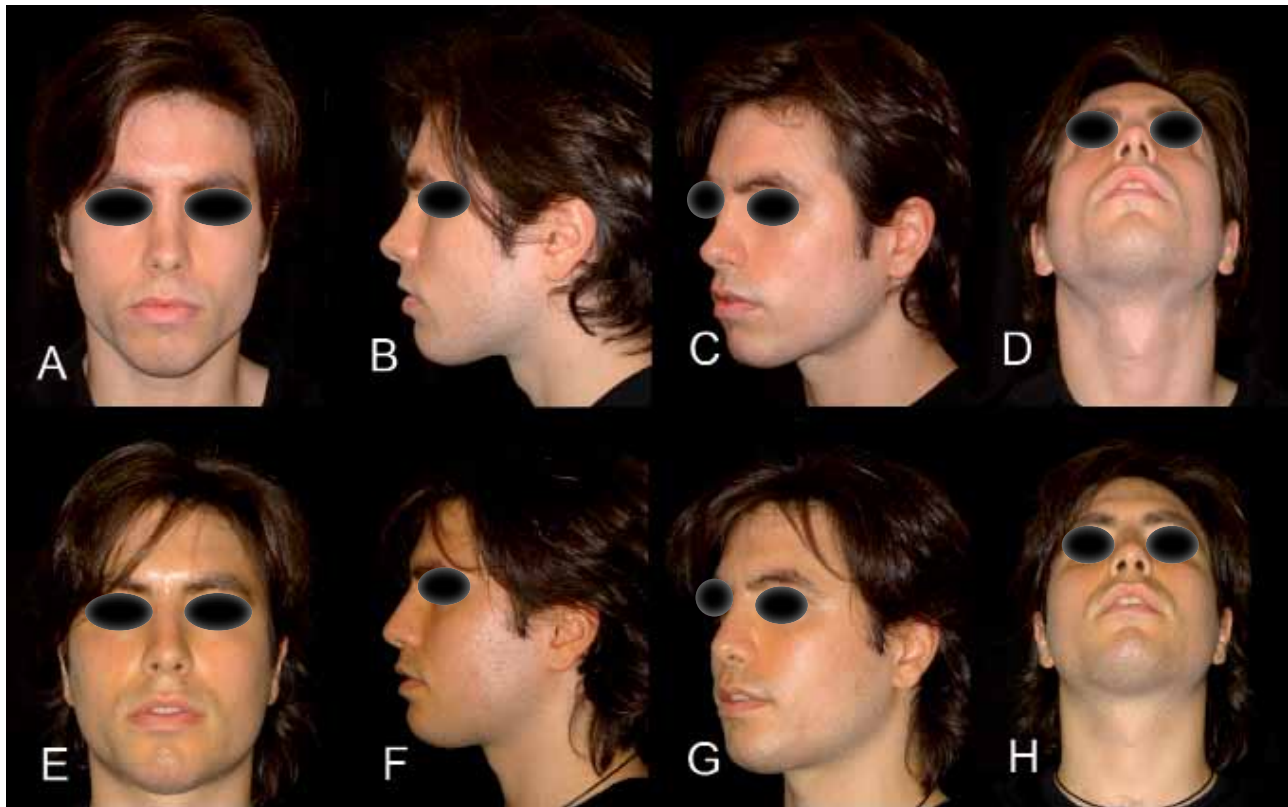


Fig. 6. Case 1, male patient with slight dysmorphism caused by rhinoplasty giving the nose an artificial, surgical appearance. Photographs taken prior to the operation (A, B, C, D) and 15 months later (E, F, G, H).

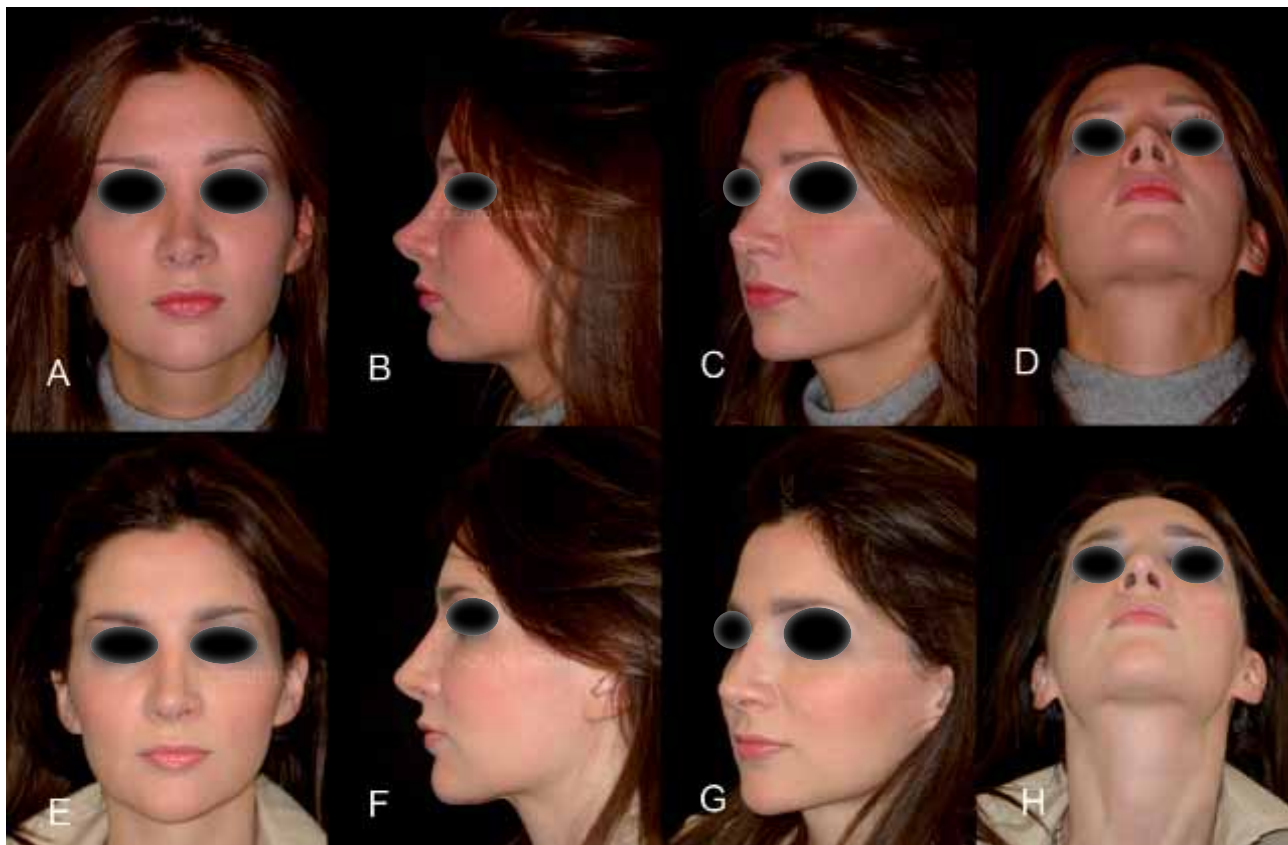


Fig. 7. Case 2, female patient with results of rhinoplasty with unfavourable outcome consisting in slightly concave nose with over-rotation of the tip. Unmistakable surgical appearance. Photographs taken prior to the operation (A, B, C, D) and 12 months later (E, F, G, H).

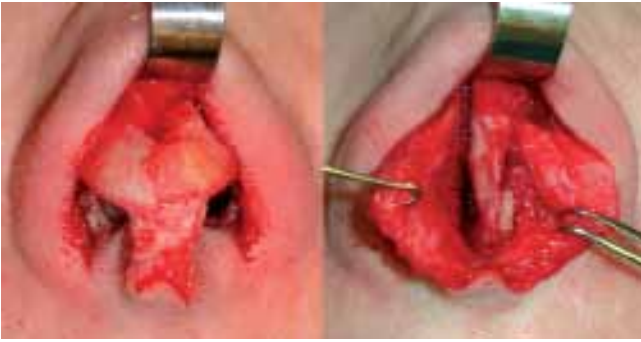


Fig. 8. Case 2, intraoperative photographs. Left: the stump of the left lateral crus covering the right dorsum. Right: extension graft of septal cartilage.

Case 2: concave dorsum and over-rotation of the tip

FF, female age 30 years, who underwent primary rhinoplasty at the age of 18 years, complained of the excessively surgical appearance of her nose. Objective examination showed concave dorsum and over-rotation of the tip with a columellar double break as well as some asymmetry of the tip.

Surgical procedures: exposure of the nasal structures with an open approach.

Findings: asymmetrical interruption of the domes of the alar cartilages with the stump of the left lateral crus overlapping the right and absence of the caudal portion of the septal cartilage due to excessive resection.

Reconstruction involved resection of the surplus part of the left lateral crus; extension graft sutured to the dorsal border of the septum and secured to a columellar strut; attachment of the medial crura to the columellar strut to push the tip forward; interdomal sutures to establish symmetry; camouflage graft on the dorsum consisting of a layer of cartilage below a 2 mm layer of Gore-Tex (Figs. 7 and 8).

Case 3: concave dorsum and narrow tip

SA, female age 37 years, subjected to primary rhinoplasty at 17 years and revision at 30, complained of the surgical appearance of her nose. Objective examination showed a concave dorsum and unnaturally narrow tip with a certain degree of columellar retraction, more evident at the level of the nasal spine.

Surgical procedures: exposure of the nasal structures using an open approach.

Findings: cartilaginous graft out of position over the domes of the nasal tip. Interruption of the domes.

Reconstruction involved harvesting of ear cartilage; removal of supradomal graft; creation of a columellar strut before the spine; Sheen-type shield graft with posterior buttress to provide the tip with shape and volume; camouflage graft on the dorsum consisting of a layer of cartilage below a 2 mm layer of Gore-Tex (Figs. 9 and 10).

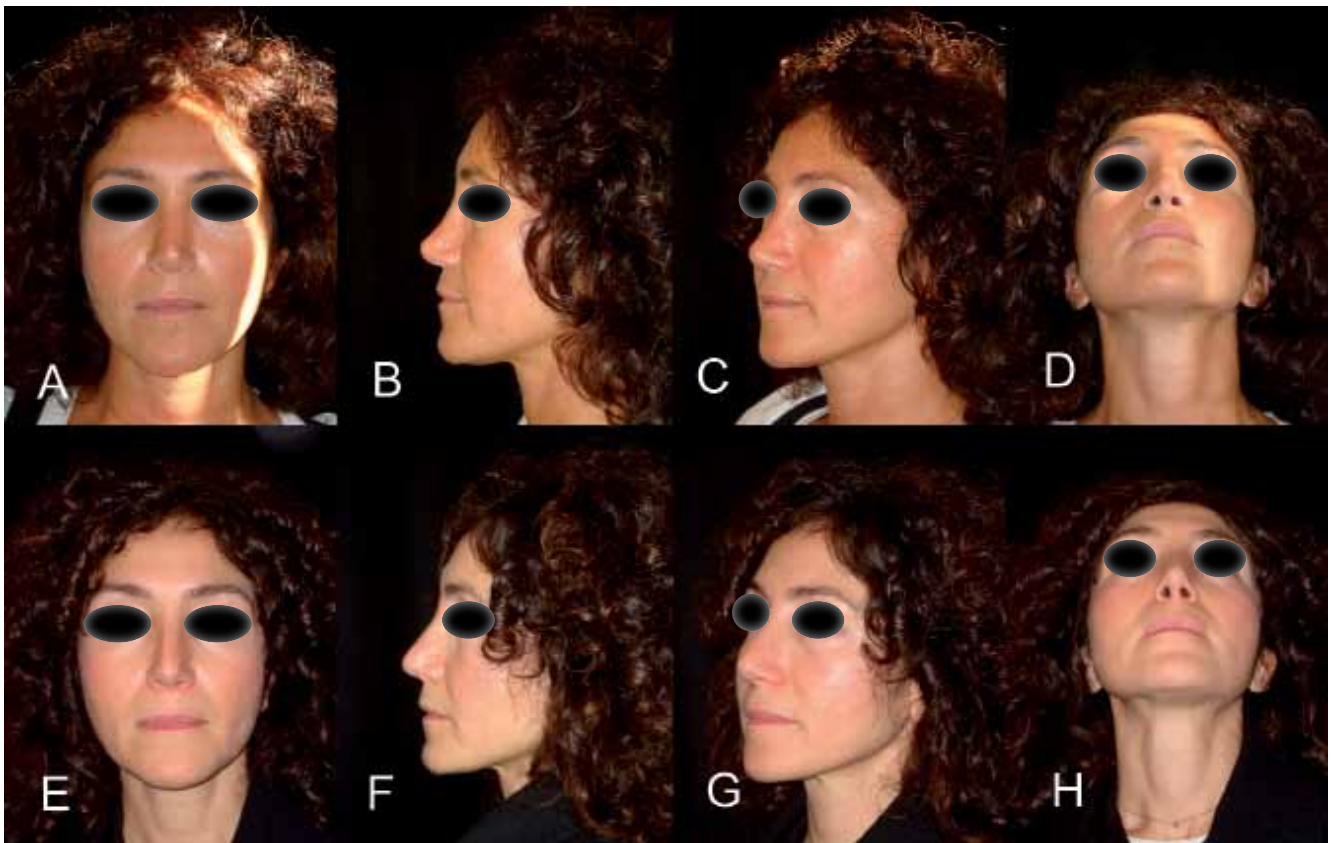


Fig. 9. Case 3, female patient with undesired results of rhinoplasty consisting in slightly concave dorsum, narrow, pointed tip and retraction of the columella. Photographs taken prior to the operation (A, B, C, D) and 15 months later (E, F, G, H).

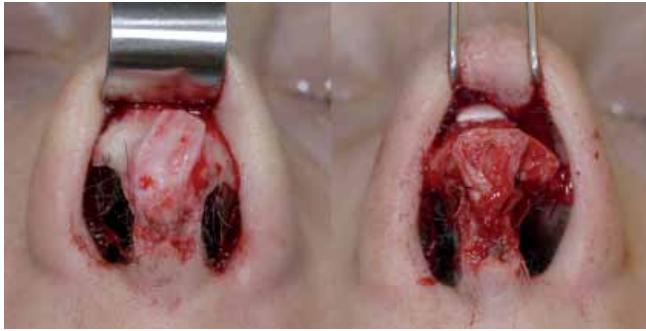


Fig. 10. Case 3, intraoperative photographs. Left: graft inserted during the previous operation. Right: Sheen-type shield graft and camouflage graft of EPTFE on the dorsum.

Conclusions

In this type of secondary rhinoplasty involving modifications of the dorsum that are only apparently minimal, the margin of error is very broad indeed. One initial difficulty lies precisely in interpreting the patient's wishes correctly. Use of the computer to simulate the result is extremely useful in this regard. It is advisable to decide on the thickness of the dorsal graft before the operation with measurements carried out on the simulated computer image and agreed upon with the patient.

The use of EPTFE offers undeniable advantages, the first of which is its absolute stability over time without the slightest degree of resorption. Other advantages include availability, solidity and rapidity of use. A recent review⁸ compared complications (specifically: infection, resorption, warping and extrusion) of autologous cartilage from the septum or ear and EPTFE with very similar results: 1.5-5% for cartilage and 1-3% for EPTFE. A minimum rate of extrusion for Gore-Tex is balanced by the absence of resorption.

A narrow nasal tip, another hallmark of rhinoplasty, often also involves incompetence of the external nasal valve and is hence both an aesthetic and a functional problem. While batten grafts or lateral crural strut grafts are clearly effective in functional terms, a shield graft sutured to the alar cartilages also makes the complex of the tip more compact and thus strengthens the nasal valve. An open approach is particularly indicated in this type of operation, above all for the precision and ease it offers in the positioning of grafts.

References

- ¹ Pearson DC, Adamson PA. *The ideal nasal profile: rhinoplasty patients vs general public.* Arch Facial Plast Surg 2004;6:257-62.
- ² Boccheri A. *The surgical approach to the Mediterranean nose.* Facial Plast Surg 2010;26:119-30.
- ³ Sheen JH. *Tip graft: a 20-year retrospective.* Plast Reconstr Surg 1993;91:48-63.
- ⁴ DeRosa J, Watson D, Toriumi DM. *Structural grafting in secondary rhinoplasty.* In: Gunter JP, Rohrich RJ, Adams WP. *Dallas Rhinoplasty*, 2nd Ed. St Louis: QMP Ed; 2007.
- ⁵ Bird HS, Andochick S, Copit S, et al. *Septal extension graft: a method of controlling tip projection shape.* Plast Reconstr Surg 1997;100:999-1010.
- ⁶ Micheli-Pellegrini V, Ponti L, Ponti G. et al. *Interrupted and continuous strip technique for tip surgery during traditional rhinoplasty.* Facial Plast Surg 1996;12:347-55.
- ⁷ Gunter JP, Friedman RM. *Lateral crural strut graft: technique and clinical applications in rhinoplasty.* Plast Reconstr Surg 1997;99:943-52.
- ⁸ Lee MR, Unger JG, Rohrich RJ. *Management of the nasal dorsum in rhinoplasty: a systematic review of the literature regarding technique, outcomes, and complications.* Plast Reconstr Surg 2011;128:538-50.

Received: December 15, 2012 - Accepted: January 7, 2013