

CASE SERIES

Vacuum-assisted closure therapy in reconstructive surgery

“Vacuum-assisted closure therapy” nella chirurgia ricostruttiva

A. BENECH, F. ARCURI, G. POGGIO, M. BRUCOLI, R. GUGLIELMETTI¹, M.C. CRESPI¹, F. PIA¹

Maxillofacial Unit, Piemonte Orientale University, Novara, Italy; ¹ Otorhinolaryngology Clinic, Piemonte Orientale, University, Novara, Italy

SUMMARY

In 1997, supported by experimental work, Argenta published a clinical report describing a variety of complicated wounds whose treatment responded successfully to negative pressure dressings using a vacuum-assisted closure system (VAC) (Kinetic Concepts Inc., San Antonio, TX). This system has been successfully used in the fields of orthopaedics and traumatology, general surgery, plastic and reconstructive surgery and gynaecology/obstetrics for a large variety of complicated wounds located in several regions, particularly in the torso and extremities. To the best of our knowledge, the use of the VAC therapy in treating free flaps surgical wounds has not been discussed in the literature. Since 2009 at the Novara Major Hospital, we have been using the VAC therapy in selected cases for difficult and complicated wounds of the maxillofacial region. The purpose of this study is to describe and discuss three cases undergoing VAC therapy followed by loco-regional flaps in the management of exposed bone after fibular free flap. The advantages and disadvantages of VAC therapy in treating complicated wounds have been reported by several studies; compared with conventional wet-to-dry dressings, this system eliminates interstitial oedema, exudates and debrides while increasing blood perfusion leading to a more rapid promotion of wound healing with less bacterial loading. Although surgical debridement, wet-to-dry dressing changes and antibiotic treatment are the mainstay in managing maxillofacial wounds, VAC therapy can be used to obtain primary closure or to prepare the wound bed until definitive reconstruction is carried out. In our opinion, the VAC technique is an innovative therapy, and at our institution represents the standard of care for the majority of complicated wounds.

KEY WORDS: Fibular free flap • Subatmospheric pressure • Maxillofacial wound • VAC therapy

RIASSUNTO

Nel 1997 Argenta, basandosi su uno studio sperimentale, pubblicò un clinical report descrivendo una serie di ferite complicate trattate con successo con medicazioni applicanti una pressione negativa a livello della ferita stessa (Vacuum Assisted Closure System – VAC); Kinetic Concepts Inc., San Antonio, TX). Questo sistema è stato successivamente utilizzato in diversi settori della medicina (ortopedia e traumatologia, chirurgia generale, chirurgia plastica e ricostruttiva, ginecologia ed ostetricia) per il trattamento di una grande varietà di ferite complicate, localizzate in diverse sedi, ma in particolare di quelle localizzate a livello del tronco e delle estremità. Attualmente in letteratura non è stato ancora discusso nei dettagli l'utilizzo della “VAC Therapy” nel trattamento delle ferite complesse successive alla chirurgia ricostruttiva con lembi liberi. Sin dal 2009, presso l'Ospedale Universitario di Novara, è stato introdotto l'uso, in casi selezionati, della “VAC therapy” per il trattamento delle ferite complicate della regione maxillo-facciale. L'obiettivo del nostro studio è quello di descrivere e discutere l'utilizzo della “VAC therapy” nella gestione di ferite complicate mandibolari (esposizione di osso e di placche ricostruttive) successive alla chirurgia ricostruttiva con lembo libero osteomiocutaneo di fibula. Rischi e benefici dell'utilizzo della “VAC therapy”, nel trattamento di ferite complesse, sono stati riportati da diversi studi in letteratura; in confronto alle medicazioni convenzionalmente utilizzate, questo sistema innovativo elimina l'edema e l'essudato interstiziale, incrementa la perfusione dei tessuti e riduce la carica batterica, conducendo ad una più rapida restituzione ad integrum della ferita stessa. Tuttavia, sebbene il debridement chirurgico, il rinnovo frequente della medicazione e la terapia antibiotica rappresentino, tutt'ora, il perno nella gestione delle ferite della regione maxillo-facciale, la “VAC therapy” potrebbe essere utilizzata per ottenere una guarigione primaria della ferita oppure per preparare il tessuto ai fini di una ricostruzione chirurgica definitiva.

PAROLE CHIAVE: Lembo libero di fibula • Pressione subatmosferica • Ferite maxillo facciali • VAC therapy

Acta Otorhinolaryngol Ital 2012;32:192-197

Introduction

Although there has been an increase in new treatment modalities to expedite wound healing including several types of dressings, topical growth factors, hyperbaric oxygen and systemic and local antiseptic agents, treatment of chronic wounds remains a clinical dilemma¹. In 1993, Fleischmann²

introduced the first use of subatmospheric pressure to manage chronic wounds; in 1997 Argenta^{3,4}, supported by experimental work, expanded this method by publishing a clinical report of a variety of complicated wounds of the torso and extremities that responded successfully to negative pressure dressings; this system is known as the vacuum-assisted closure system (VAC) (Kinetic Concepts Inc., San Antonio, TX, USA).

Data from animal models have shown the lesions treated by subatmospheric pressure have an increase of dermal and subdermal blood perfusion to the wound, a decreased bacterial loading and an high rate of vital granulation tissue growth without interstitial fluid, exudates and debris compared to controls^{5,6}.

Since its introduction, the vacuum-assisted closure (VAC) system has been successfully used in the fields of orthopaedics and traumatology, general surgery, plastic and reconstructive surgery and gynaecology/obstetrics for a large variety of complicated wounds located in several regions, particularly in the torso and extremities. The VAC system is formed by a central therapy unit controlled by a computer, canister, tube and foam and drape dressing; the foam dressing is secured into the lesion that is sealed by the drape. One side of the plastic tube is connected to the dressing; the other is attached to a canister that is connected to the control unit; negative subatmospheric pressure (125 mm Hg below the ambient pressure) is applied to the wound through the tube⁷.

Compared to other specialities, there are very few clinical reports of the VAC system for treating head and neck wounds and, to the best of our knowledge, the use of the VAC therapy in treating free flaps has not been discussed in detail in the literature. In 2006, Schuster⁸ published the first successful case of VAC therapy used on a complicated facial lesion. In the same year, Andrews⁹ treated complex head and neck wounds with VAC, which included exposed calvarium and split-thickness skin grafts. Recently, Byrnside¹⁰ used VAC to treat a mandibular plate exposition, a necrotizing cervico-facial fasciitis and a gunshot injury.

Case series

We retrospectively reviewed the records of 3 patients affected by complex head and neck wounds treated by VAC and a specialized wound dressing Granufoam™ (resilient, open cell foam surface that promotes the formation of granulation tissue) (Kinetic Concepts, Inc, San Antonio, TX, USA) between May 2009 and April 2011 at the Department Head and Neck Surgery of Novara University Hospital.

VAC therapy was started during hospitalization and continued at home after the discharge; dressing changes were performed every 2 days until the end of therapy. The purpose of our study is to describe and discuss the application of VAC therapy in patients affected by complicated mandibular wounds (Table I and Table II). The clinical histories of each patient included are described in detail.

Case 1

In June 2010, a 50-year-old woman was referred to the Maxillofacial Surgery Unit of Novara Major Hospital for definitive reconstruction of an extensive defect involving the mandible as a consequence of squamous cell carcinoma of the left tonsil (pT3N1Mx) treated surgically by a left hemi-mandibulectomy associated with homolateral

modified radical neck dissection Type II (MRDN-II) followed by radiotherapy (total of 70 Gy for 35 applications) performed three years before in the ENT Unit of Novara Major Hospital. The patient referred hypertension for almost 20 years controlled by drug therapy (Fig. 1A).

In July 2010, after discussion of the case in terms of risks and benefits such as exposition of the plate and necrosis of the irradiated flap versus reconstruction of mandibular integrity with restoration of a fair deglutition and re-establishment of acceptable cosmesis, we decided to use a fibular free flap to reconstruct the mandible.

After completion of a temporary tracheostomy and elevation of a cervical flap, the fibular bone was grafted, osteotomized and placed to repair the mandibular defect; the osteosynthesis was performed with a 2.4 mm reconstruction plate. The anastomosis was performed with microsurgical technique and the neck wound was primarily closed after the placement of suction drains.

On day 10 after intervention, cutaneous exposition of the reconstruction plate was observed (Fig. 1B). We decided to use VAC with GranuFoam™ dressings which was trimmed to the wound size of the lower jaw, secured by an occlusive drape and changed 3 times a week for 20 days (Fig. 1C). Unfortunately, primary closure was not achieved and the patient underwent a second procedure (August 2010) by a rotational flap with a full thickness skin graft to cover the residual bone and the hardware. The follow-up showed the closure of the wound and adequate reconstruction of the lower jaw with an acceptable morphology of the head and neck region (Fig. 1D).

Case 2

In May 2009, a 41-year-old man originally from Senegal was referred to the Maxillofacial Surgery Department of Novara for an advanced mandibular osteoradionecrosis after radiotherapy for an unknown carcinoma of the oral cavity non-surgically treated in his country two years earlier. He presented an extensive composite 3-dimensional defect of the lower jaw involving the oral mucosa, mandibular bone, external skin and soft tissues, with a clear communication between the oral cavity and the exterior. No previous health problems were referred.

In June 2009, after discussion of the case in terms of reconstruction of the bony scaffold, restoration of the oral deglutition, obliteration of dead space and reestablishment of acceptable cosmesis, we planned a subtotal mandibulectomy with resection of intraoral lining, masticator muscles, buccal fat pad and cheek skin with a simultaneous fibula osteomyocutaneous free flap to reconstruct the extensive composite defect.

After completion of a temporary tracheostomy and wide surgical demolition (ENT and maxillofacial surgeons), the fibular bone was osteotomized to reconstruct the mandibular defect and osteosynthesis was performed with a

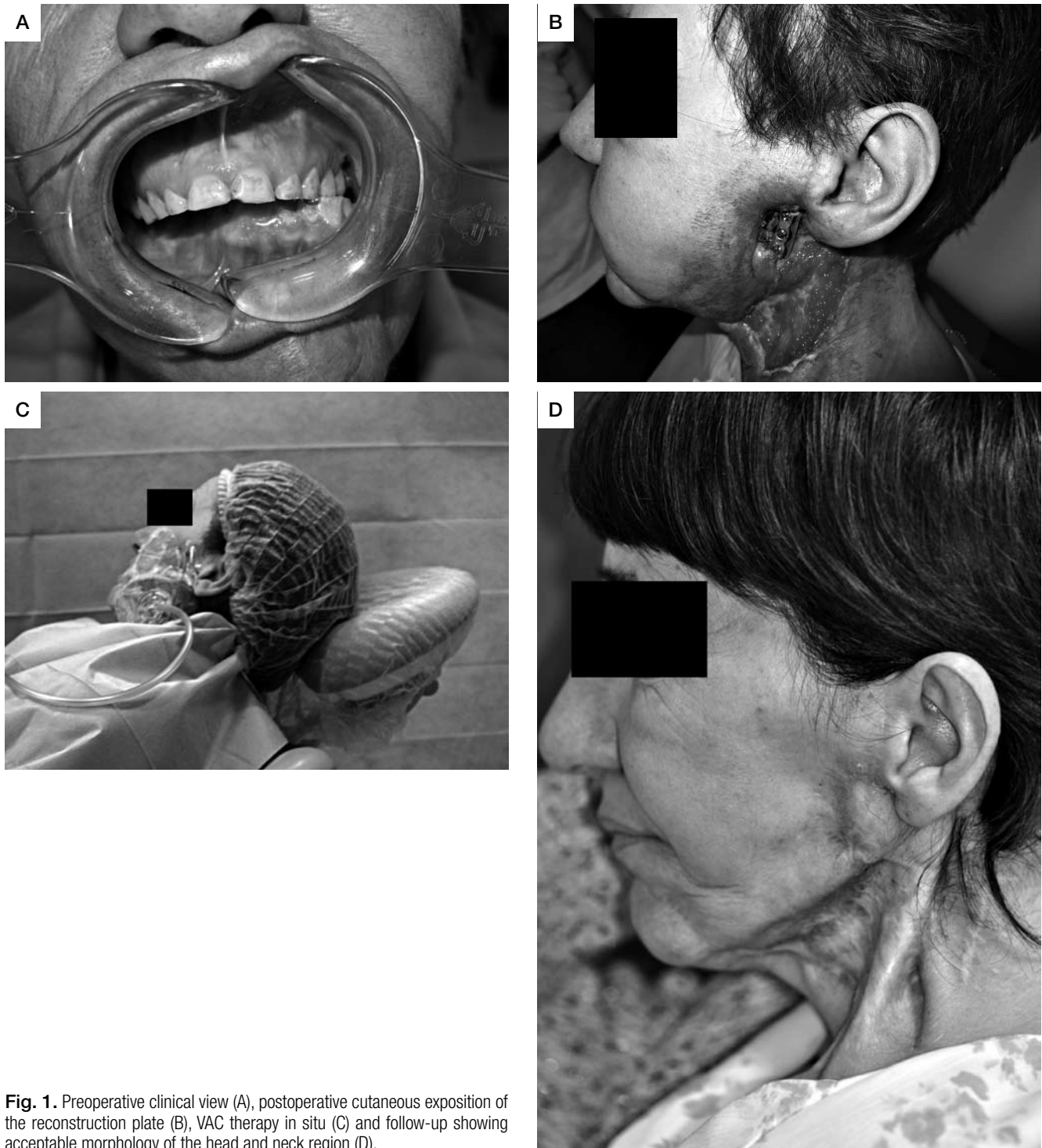


Fig. 1. Preoperative clinical view (A), postoperative cutaneous exposition of the reconstruction plate (B), VAC therapy in situ (C) and follow-up showing acceptable morphology of the head and neck region (D).

2.4 mm reconstruction plate with and a titanium condyle prosthesis. The skin paddle was used to repair the external defect. The anastomosis was performed with a microsurgical technique and the neck wound was primarily closed after the placement of suction drains.

One month after surgery, although with a good seal of the mucosal layer, the patient presented exposition of a segment of the fibula and the reconstruction plate with partial necrosis of the skin paddle (Fig. 2A). The patient was put

on VAC therapy with Granufoam™ Dressings for 20 days (Fig. 2B).

Six months later, after wide debridement of the wound, a definitive reconstruction was performed with a pedicle pectoralis major musculocutaneous flap to cover the residual bone and hardware. Follow-up showed successful anatomic reconstruction of the lower jaw with fair morphology of the head and neck region and acceptable symmetry of the lower third of the face (Fig. 2C).

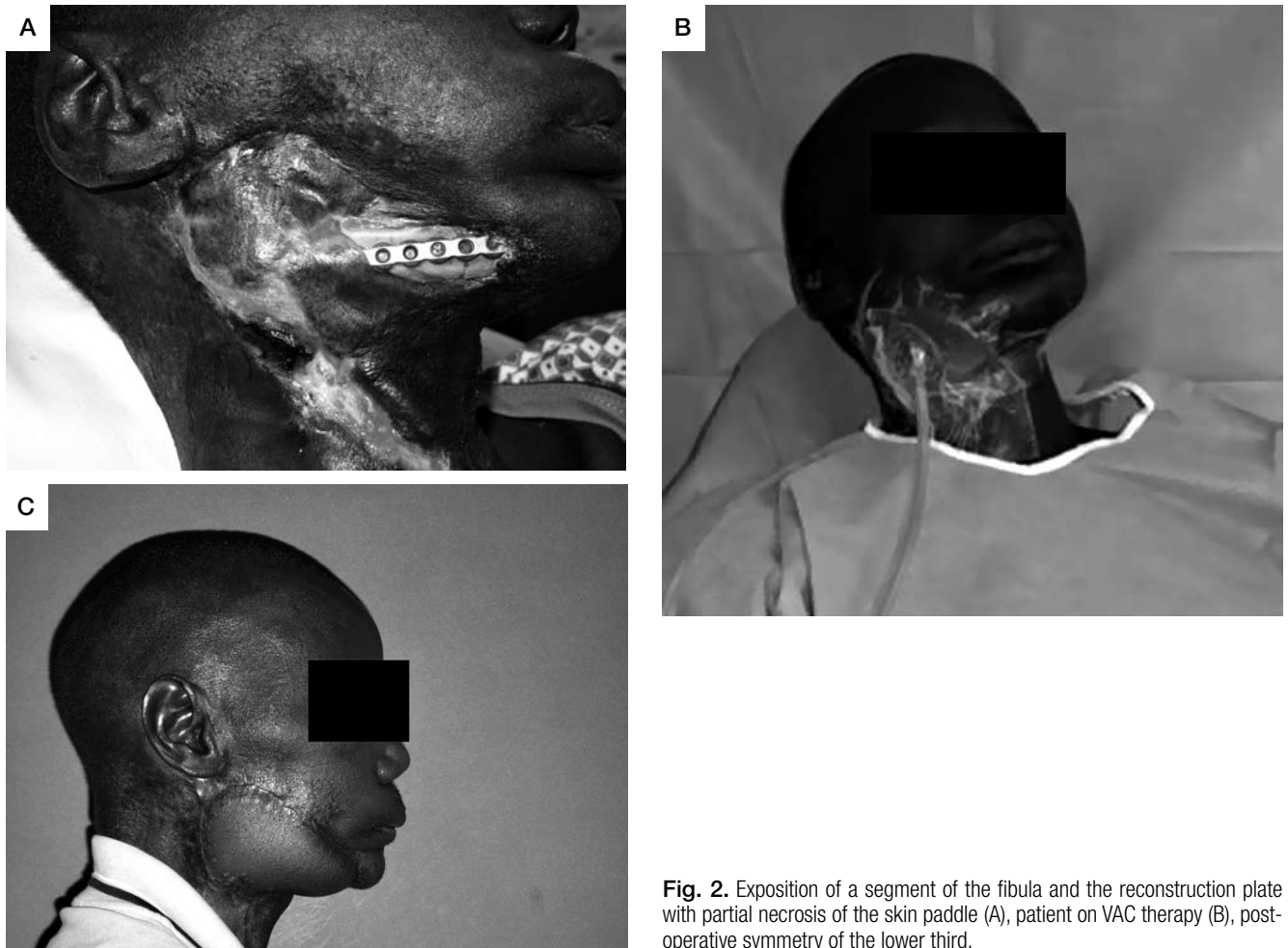


Fig. 2. Exposition of a segment of the fibula and the reconstruction plate with partial necrosis of the skin paddle (A), patient on VAC therapy (B), post-operative symmetry of the lower third.

Case 3

In July 2010, a 57-year-old man was referred to the ENT and maxillofacial Department for a suspect lesion 3 cm in diameter of the buccal mucosal nearby the right mandible (retromolar region) that was diagnosed, after an incisional biopsy, as squamous cell carcinoma. No previous health problems were reported. After combined ENT/ maxillofacial clinical and radiological evaluation, we decided for a surgical approach of the lesion that included right hemipelvi-glossomandibulectomy (horizontal branch of the mandible) and homolateral functional neck dissection removal of the lymph node levels (I to V according to Robbins) and selective contralateral neck dissection (level I according to Robbins), preceded by the execution of a temporary tracheostomy (pT2-NoMx). No postoperative radiotherapy was performed.

In April 2011, the patient returned to our observation because of functional defects from previous surgical treatment: microstomia (2.5 cm) and ankyloglossia (by anchorage of the residual tongue to the inferior gingival fornix to close the lack of substance of the pelvis caused by tumour resection). After careful clinical and radiological evaluation and exclusion of local and systemic residual or recurrent disease, the patient underwent surgical reconstruction with a fibula osteomyocutaneous free flap.

Fifteen days after the operation, cutaneous exposition of the reconstruction plate was observed (Fig. 3A); the patient was put on VAC with Granufoam™ dressings for 40 days (Fig. 3B). Two months later, definitive reconstruction was performed with a pedicle pectoralis major musculocutaneous flap. Follow-up showed acceptable functional and aesthetic results.

Discussion

Wounds located in the head and neck region are technically difficult to treat in terms of cosmesis and functionality for a multitude of issues such as poor vascularity of residual tissue after surgical demolitions, failed reconstructive techniques, radiotherapy and chemotherapy. VAC works by both macrostrain and microstrain. Macroscopically it stretches the foam, leading to closure of the wound edges with a uniform pressure around the bed. Microscopically, it stretches cells, increasing proliferation and cell migration¹¹⁻¹⁵.

The wound must be prepared by surgical debridement to promote a well vascularised area prior to the application VAC. The VAC system can be used over any type of tissue or material including fascia, muscle, tendon, bone, der-

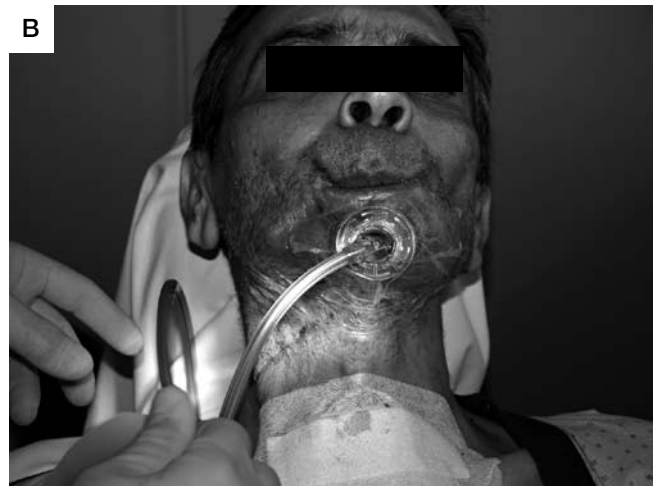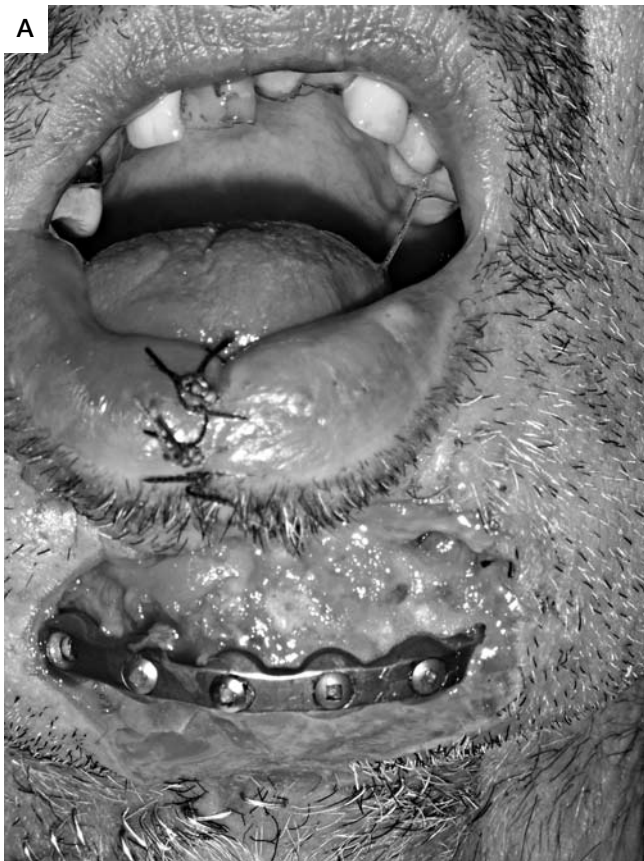


Fig. 3. Cutaneous exposition of the reconstruction plate (A), VAC therapy (B).

mis, fat, vascular synthetic grafts, orthopaedic hardware or synthetic mesh. Contraindications to VAC therapy are fragile skin, ischaemic tissue and malignancy: however, in our patients, there was no clinical or instrumental evidence of residual or recurrence disease^{13-15 17 18 20}.

Complications are infrequent with low morbidity: due to the removal of large volumes of fluid, haemodynamic instability has been cited in the literature as a potential complication: less serious consequences are pain, skin irritation or maceration, bleeding, tissue necrosis and infection⁹. There are no clinical reports of massive bleeding due to VAC while treating head and neck wounds; however, placement of this device over large blood vessels or any vessels that can bleed must be avoided^{6 7 19}.

We adopted the VAC therapy to assist wound healing over exposed bone and hardware as complications of free flap surgery; our application was analogous to the use of VAC in wounds of extremities. We have efficiently used the VAC device placed directly over the exposed bone and reconstruction plate with satisfactory wound healing in terms of vital granulation tissue in the bed and at the periphery of the wounds without infection.

The head and neck region contains a variety of moist contours and orifices; accordingly, it is often technically difficult to obtain an airtight seal around the dressing. Benzoin (KCI, USA) or similar substances can be used as an adhesive to facilitate the airtight seal. Moreover, an occlusive

film such as Tegaderm (3M Health Care, Minneapolis, MN, USA) can be helpful to maintain the seal. The negative pressure can be used constantly or intermittently, and the foam can be used as a bridge between two wounds using a single device^{13 14}. However, it is always necessary to use negative pressure because the majority of studies have demonstrated that this system is necessary for the functionality of VAC and wound healing^{12 16 21}.

However, based on our clinical experience in management of head and neck wounds with VAC, it is a safe tool and can be applied over the majority of lesions located over soft tissue and bones of the maxillofacial region. Although we achieved a satisfactory result in terms of profuse and vital granulation tissue around the wound in all three cases described, we could not achieve primary closure and salvage surgical reconstruction was required for a final result that was acceptable.

With this method, until a second procedure is performed, it is possible to prepare the wound bed with tissue perfusion and granulation, without interstitial fluid, exudates, debris and bacterial load; consequently, the area to be covered is reduced and the secondary reconstructive procedure can be more conservative with less morbidity, faster recovery and a higher probability of success. Although VAC therapy has high costs (\$100-\$200 a day), there are fewer dressing changes and the faster wound healing can potentially lead to a shorter hospitalization times¹⁸⁻²⁰.

VAC therapy pose some problems when considering intricate sites of the head and neck region, painful dressing changes and high costs, it can be very useful in complicated head and neck wounds from either traumatic or surgical origin. Although surgical debridement, wet-to-dry dressing changes and antibiotic treatment are the mainstay in managing head and neck wounds, VAC can be used to obtain a primary closure or to prepare the wound bed until definitive reconstruction is performed.

Although the subatmospheric pressure technique is gaining popularity among surgeons, there is a lack of well designed and adequately powered randomized controlled trials evaluating its effectiveness. According to the Cochrane Collaboration Review, only one trial reported a statistically significant reduction in wound volume in patients managed by this method²¹.

Conclusions

In our experience, VAC therapy is an excellent modality for treating complex head and neck wounds. There were no complications related to this therapy and reconstructive procedures on a prepared wound were greatly facilitated. However, at the moment there is a low level of evidence to justify the use of VAC therapy in the treatment of chronic head and neck wounds; therefore, further clinical trials should be conducted to better understand the utility of this system for head and neck surgery.

References

- Ubbink DT, Westerbos SJ, Evans D, et al. *Topical negative pressure for treating chronic wounds (Review)*. The Cochrane Collaboration 2011.
- Fleischmann W, Strecker W, Bombelli M, et al. *Vacuum sealing as treatment of soft tissue damage in open fractures*. Unfallchirurg 1993;96:488-92.
- Morykwas MJ, Argenta LC, Shelton-Brown EI, et al. *Vacuum-assisted closure: a new method for wound control and treatment: animal studies and basic foundation*. Ann Plast Surg 1997;38:553-62.
- Argenta LC, Morykwas MJ. *Vacuum-assisted closure: a new method for wound control and treatment: clinical experience*. Ann Plast Surg 1997;38:563-77.
- Greer SE, Duthie E, Cartolano B, et al. *Techniques for applying subatmospheric pressure dressing to wounds in difficult regions of anatomy*. J Wound Ostomy Continence Nurs 1999;26:250-3.
- Miller Q, Bird E, Bird K, et al. *Effect of subatmospheric pressure on acute wound healing*. Curr Surg 2004;61:205-8.
- Morykwas MJ, Simpson J, Pungner K, et al. *Vacuum-assisted closure: State of basic research and physiologic foundation*. Plast Reconstr Surg 2006 (suppl.);117:121S.
- Schuster R, Moradzadeh A, Waxman K. *The use of vacuum assisted closure therapy for the treatment of a large infected facial wound*. Am Surg 2006;72:129.
- Andrews BT, Smith RB, Goldstein DP, et al. *Management of complicated head and neck wounds with vacuum-assisted closure system*. Head Neck 2006;28:974.
- Byrnside V, Glasgow M, Gurunluoglu R. *The vacuum-assisted closure in treating craniofacial wounds*. J Oral Maxillofac Surg 2010;68:935-42.
- McNulty AK, Schmidt M, Feeley T, et al. *Effects of negative pressure wound therapy on fibroblast viability, chemotactic signaling, and proliferation in a provisional wound (fibrin) matrix*. Wound Repair Regen 2007;15:838-46.
- Argenta LC, Morykwas MJ, Marks MW, et al. *Vacuum-assisted closure: State of clinic art*. Plast Reconstr Surg 2006 (suppl9);117:127S.
- Philbeck TE Jr, Whittington KT, Millsap MH, et al. *The clinical and cost effectiveness of externally applied negative pressure wound therapy in the treatment of wounds in home healthcare Medicare patients*. Ostomy/Wound Manage 1999;45:41.
- DeFranzo AJ, Argenta LC, Marks MW, et al. *The use of vacuum assisted closure therapy for the treatment of lower extremity wounds with exposed bone*. Plast Reconstr Surg 2001;108:1184.
- Parrett BM, Matros E, Pribaz JJ, et al. *Lower extremity trauma: Trends in the management of soft tissue reconstruction of open tibia fibula fractures*. Plast Reconstr Surg 2006;117:1315.
- Loree S, Domp martin A, Penven K, et al. *Is vacuum-assisted closure a valid technique for debriding chronic leg ulcers?* J Wound Care 2004;13:249-52.
- Fabian TS, Kaufman HJ, Lett ED, et al. *The evaluation of subatmospheric pressure and hyperbaric oxygen in ischemic full-thickness wound healing*. Am Surg 2000;66:1136-43.
- Weed T, Ratliff C, Drake DB. *Quantifying bacterial bioburden during negative pressure wound therapy: does the wound VAC enhance bacterial clearance?* Ann Plast Surg 2004;52:276-9.
- Hopf HW, Humphrey L, Puzifferri N, et al. *Adjuncts to preparing wounds for closure: hyperbaric oxygen, growth factors, skin substitutes, negative pressure wound therapy*. Foot Ankle Clin 2001;6:661-82.
- Dhir K, Reino AJ, Lipana J. *Vacuum assisted closure therapy in the management of head and neck wounds*. Laryngoscope 2009;109:54-61.
- Saxena V, Hwang CW, Huang S, et al. *Vacuum assisted closure: microdeformation of wounds and cell proliferation*. Plast. Reconstr Surg 2004;114:1086-10.

Received: July 25, 2011 - Accepted: November 11, 2011

Address for correspondence: Francesco Arcuri, S.C.D.U. di Chirurgia Maxillo-Facciale, Ospedale Maggiore della Carità, Corso Mazzini 18, 28100 Novara, Italy. Tel. +39 0321 3733893/3733783/3733895. Fax +39 0321 3733893. E-mail: fraarcuri@libero.it