

RHINOLOGY

Diode laser in the treatment of epistaxis in patients with hereditary haemorrhagic telangiectasia

Il laser a diodi nel trattamento dell'epistassi dei pazienti affetti da teleangectasia emorragica ereditaria

M.L. FIORELLA, L. LILLO, R. FIORELLA

Department of Ophthalmology and Otolaryngology, Cervico-Facial Division, Phoniatrics and Rhinology, University of Bari "Aldo Moro", Bari, Italy

SUMMARY

Periodic and spontaneous nosebleed is the most common clinical manifestation of hereditary haemorrhagic telangiectasia (HHT), present in 95% of patients suffering from this syndrome. The purpose of this retrospective study was to evaluate the effectiveness and safety of diathermocoagulation of telangiectasia on the nasal mucosa with a diode laser in the treatment of epistaxis in patients with HHT. From 2005 to 2010, 24 patients diagnosed with HHT and with mild-severe nosebleed were treated in our hospital with diode laser. Patients were given a pre- and post-operation evaluation questionnaire to determine the frequency and severity of nosebleed, the recurrence-free period of time after treatment and quality of life. We compared the pre- and post-operation haemoglobin values three months after the last treatment. After treatment, a decrease in the weekly frequency and entity of nosebleed was observed, together with substantial improvement in the quality of life and an increase in haematic haemoglobin. Diode laser treatment of telangiectasia on nasal mucosa represents a valuable, safe, effective and repeatable therapeutic option in treating mild and severe nosebleed, and it is associated with improvement in quality of life from psychological, social and clinical points of view.

KEY WORDS: Epistaxis • HHT • Diathermocoagulation • Diode laser • Nasal endoscopy • Quality of life • Haemoglobin • Psychological functionality

RIASSUNTO

L'epistassi spontanea e ricorrente è la più comune manifestazione clinica della teleangectasia emorragica ereditaria (HHT), presentandosi infatti nel 95% dei pazienti affetti dalla malattia. Lo scopo di questo studio retrospettivo è stato quello di valutare la validità e la sicurezza della diatermocoagulazione delle teleangectasie mucose nasali con laser a diodi nel trattamento delle epistassi dei pazienti affetti da teleangectasia emorragica ereditaria. Dal 2005 al 2010, 24 pazienti con diagnosi certa di HHT e con epistassi di grado moderato e severo sono stati trattati nella nostra U.O. con laser a diodi. I pazienti sono stati sottoposti ad un questionario di valutazione pre- e post-operatoria per determinare la frequenza e l'entità delle epistassi, il tempo libero da recidiva in seguito al trattamento e la qualità della vita. Sono stati confrontati i valori pre- e post-operatori di emoglobina a distanza di tre mesi dal trattamento. In seguito al trattamento abbiamo riscontrato una riduzione della frequenza e dell'entità settimanali delle epistassi, un sostanziale miglioramento della qualità della vita dei pazienti e un aumento della concentrazione ematica di emoglobina. Il trattamento con laser a diodi delle teleangectasie mucose nasali rappresenta una valida, sicura, efficace e ripetibile opzione terapeutica in caso di epistassi di grado moderato e severo, consentendo di migliorare sia da un punto di vista psicologico che sociale oltre che clinico la qualità della vita dei pazienti trattati.

PAROLE CHIAVE: Epistassi • HHT • Diatermocoagulazione • Laser a diodi • Endoscopia nasale • Qualità della vita • Emoglobina • Funzionalità psicologica

Acta Otorhinolaryngol Ital 2012;32:164-169

Introduction

Hereditary haemorrhagic telangiectasia (HHT) or Rendu-Osler-Weber syndrome is a rare genetic disease with autosomal dominant inheritance characterized by an angiogenesis disorder that consists of vascular malformations in mucocutaneous tissues, internal organs and the central nervous system. In 1896, Rendu described this syndrome for the first time, defining it as a hereditary syndrome

characterized by nosebleed and red-violescent cutaneous lesions, different from haemophilia. Later on, Osler and Weber defined the clinical aspects of this syndrome. The prevalence of HHT ranges from 1:5000 to 1:8000 cases¹. This syndrome equally affects males and females without racial or ethnic preference.

Angiodysplasia, typical of HHT, can be distinguished in arteriovenous malformations or AVM, when large calibre

Table I. Pre- and post-operation assessment questionnaire in patients with HHT-associated epistaxis (non-validated questionnaire).

PRE- AND POST-OPERATION ASSESSMENT QUESTIONNAIRE IN PATIENTS WITH HHT-RELATED EPISTAXIS

1) Before surgery, how many times a week did you have epistaxis?

- 0-1
- 2-4
- 5-6
- More than 6
- Many times a day

2) Before surgery, how severe was the nosebleed?

- Dripping
- Mild
- Copious
- Gushing

3) Before surgery, how did you consider your epistaxis?

- Very mild
- Mild
- Moderate
- Severe
- Life-threatening

4) After surgery, how long have you been free from epistaxis?

- Within one month
- 1-2 months
- 3-4 months
- More than 4 months

5) Since epistaxis started again, how many episodes have you experienced?

- 0-1/week
- 2-4/week
- 5-6/week
- More than 6/week
- Many times a day

6) Since epistaxis started again, how severe is the nosebleed?

- Dripping
- Mild
- Copious
- Gushing

7) How do you qualify your epistaxis compared to that before the operation?

- Much worse
- Worse
- Equivalent
- Better
- Much better

8) Before surgery, how do you define your life-quality choosing on a scale of 1 (poor) to 7 (excellent)?

Poor							Excellent
1	2	3	4	5	6	7	

9) After surgery, how do you define your life-quality choosing on a scale of 1 (poor) to 7 (excellent)?

Poor							Excellent
1	2	3	4	5	6	7	

10) Was your quality of life improved by laser diode treatment, even if temporarily?

- No, it went worse
- No, it did not change
- Yes, briefly
- Yes, for a long time

11) Was the treatment useful?

- No
- Yes, briefly
- Yes, absolutely

12) On a scale of 1 (poor) to 7 (excellent), how do you define your quality of life at present?

Poor							Excellent
1	2	3	4	5	6	7	

vessels are affected, and in telangiectasias, when small calibre vessels are affected. The arteriovenous malformations may be present at the cerebral, hepatic, gastroenteric and pulmonary levels. Telangiectasias can be present at the mucocutaneous level as skin-deep points or star-shaped red-violescent dilations, single or multiple, localized in different body areas including the lips, tongue, palate, fingers, face, conjunctiva, torso, arms, nail bed, and above all, nasal mucosa.

The most common symptom is epistaxis, which is spontaneous and frequently recurrent, and sometimes is so severe as to require iron administration and several blood transfusions due to the severe degree of anaemia consequent to bleeding. The onset of recurrent nosebleed can occur before the age of 10 years, progressively increasing in frequency and severity in the second decade, with a major rate in the fourth and fifth decades².

Therefore, diagnosis relies on anamnestic data and targets defined Curaçao criteria, established in June 1999 by the Scientific Advisory Board of the HHT Foundation International Inc.: spontaneous and recurrent nosebleed; multiple telangiectasias at lips, oral cavity, fingers and nose; visceral arteriovenous malformations; positive family anamnesis (first-degree siblings diagnosed with HHT, corresponding to the above-mentioned criteria). Diagnosis of HHT is certain if three criteria are met; it is possible or suspect if two criteria are met; it is unlikely if less than two criteria are met.

At present, there are no curative or preventative treatments specific for HHT, and it is only possible to intervene with a "symptomatic" approach by adopting different therapeutic choices on the basis of symptom severity.

The present report describes a case-series of patients suffering from HHT, with recurrent and spontaneous epistaxis and undergoing diathermocoagulation with a diode laser during nasal endoscopy at the Otolaryngology Operative Unit of the University of Bari. The goals intended for this retrospective study are: long- and short-term evaluation of post-operative clinical outcome focused on the recurrence-free period, frequency and intensity of epistaxis, change in haemoglobin haematic concentration, global evaluation of social and psychological functionality and quality of life before treatment compared to the peri- and post-operative phases.

Materials and methods

We collected data concerning patients with HHT and spontaneous and recurrent epistaxis over the period from October 2005 to December 2010 in a retrospective manner. Patients were treated with diathermocoagulation using a diode laser (Ceralas D15/810 nm Biolitec) during rigid nasal endoscopy under general anaesthesia. The diode laser wavelengths are selectively absorbed by haemoglobin, allowing the coagulation of telangiectasias on

nasal mucosa without damaging the vessel wall or the mucosal coating epithelium². Data concerning treatments and clinical outcome were completed by the results of a pre- and post-operation evaluation questionnaire (Table I) submitted to patients by telephone interview. We also compared the pre-operative haemoglobin values to the post-operation values three months after the last treatment; statistical analysis was performed using a two-ended Student's t-test, with statistical significance set at $p < 0.05$. A total of 24 patients diagnosed with HHT according to Curaçao criteria and with mild and severe epistaxis were included (15 males [62.5%], 9 females [37.5%]), 6 underwent a second treatment for a total of 30 interventions. The interval between the repeated treatments was calculated over 16 months (range 3 to 40 months). We did not observe any peri- or post-operative complications. Patient age ranged from 21-70 years, with an average of 52.5 years. The most represented age range, within the case series of this study, was the fourth and sixth decades (75%; $n = 18$). All treatments were carried out on patients that were haemodynamically stable. Among the 24 patients treated, 4 (16.6%) were missing at follow-up (2 males and 2 females), one of whom underwent a second treatment. For this reason, functional-clinical outcome evaluation was made on 20 patients (13 males and 7 females). The clinical outcome evaluation questionnaire was performed to detect not only the present clinical condition of patients, but also psychological and social functionality, assessing the quality of life over the pre- and post-operative period in the short- and long-term.

Results

After diode laser treatment, improvement in symptoms was observed, expressed as an increase in the number of patients having one or no bleeding event per week compared to the period before intervention (from 5% to 40%; from 1 to 8 patients) (Fig. 1), and a decrease (46.6%) in the number of patients reporting copious nosebleed (from 15 to 8) (Fig. 2). 40% of treated patients ($n = 8$) did not

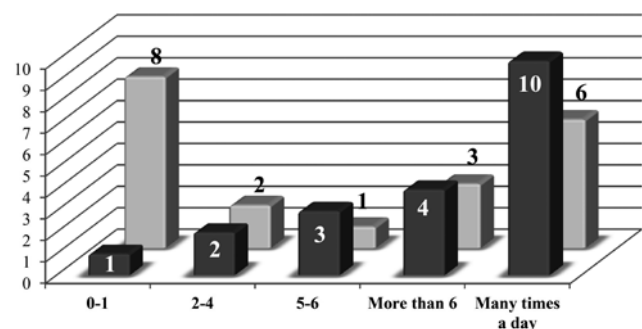


Fig. 1. Weekly frequency of epistaxis: in dark grey pre-intervention; in light grey post-intervention.

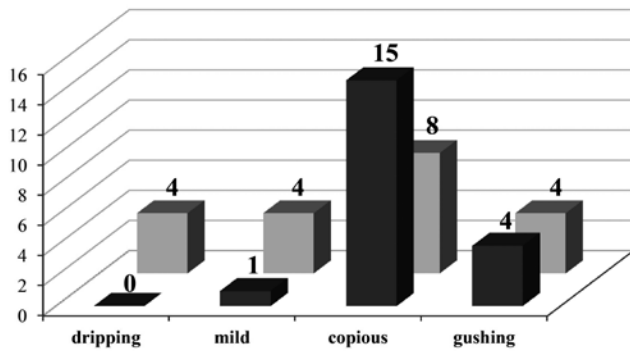


Fig. 2. Severity of epistaxis: in dark grey pre-intervention; in light grey post-intervention.

experience any recurrence for more than 4 months after treatment (range 6-8 months); 35% ($n = 7$) had a recurrence within one month, although showing a decrease in both frequency and intensity (Fig. 3).

On a scale of 1 to 7, where 1 corresponds to poor and 7 to excellent quality of life, half of patients ($n = 10$) defined their quality of life very good or even excellent after treatment, while none of them had stated this prior to treatment (Fig. 4). Photocoagulation of nasal telangiectasias by diode laser was considered useful over time by 75% of patients ($n = 15$).

A reliable and objective factor for assessment of improvement of symptoms is the concentration of peripheral venous blood haemoglobin, expressed in g/dl, since it compares patient conditions before and after intervention. Before treatment, the 20 patients had an average haemoglobin value of 11.75 g/dl (range 8-15.7 g/dl), which at three months after treatment was 14.04 g/dl (range 11-16 g/dl) (Fig. 5). Comparison of the mean pre- and post-intervention values using Student's t-test affirmed that this difference was statistically significant ($p < 0.05$).

Discussion

HHT is a genetic disease where an angiogenesis disorder reveals itself as telangiectasias and arteriovenous malformations of mucocutaneous tissues, internal organs and the central nervous system. Epistaxis, due to telangiectasias on the nasal mucosa, is the most common symptom. The severity of bleeding differs from patient to patient, and some may need frequent hospitalization and blood transfusions; all this substantially affects the quality of life. The most suitable treatment of nosebleed requires a non-invasive approach that can be repeated and eliminate possible iatrogenic damages of the lesioned mucosa³. Several therapeutic strategies have been proposed, but none are reported to be without side-effects or definitive over a long period of time. The proposed treatments can be distinguished in medical and surgical approaches.

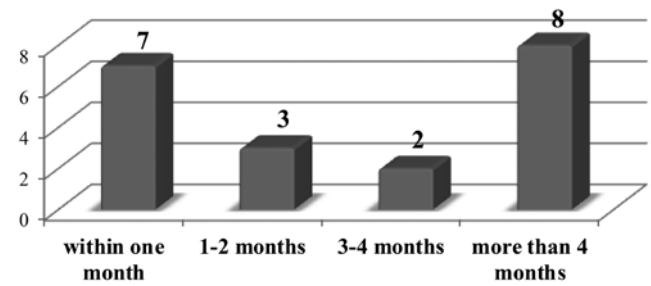


Fig. 3. Recurrence-free period after treatment.

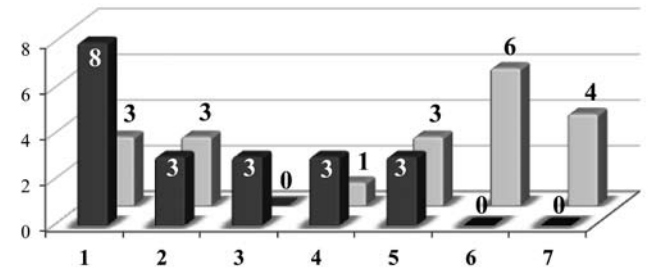


Fig. 4. Quality of life: in dark grey pre-intervention; in light grey post-intervention.

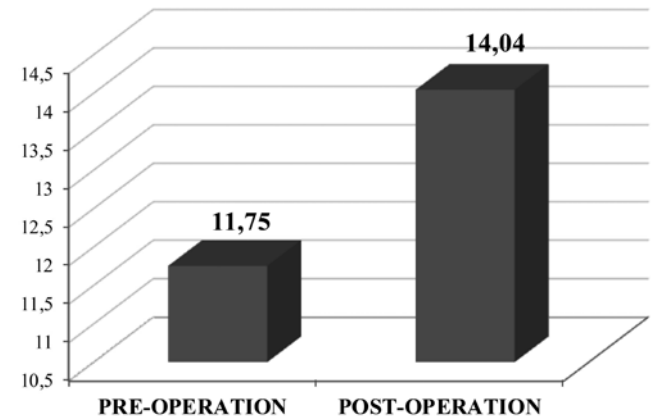


Fig. 5. Comparison between pre- and post-intervention average haemoglobin values expressed in g/dl.

The former include hormonal and anti-hormonal therapies based on oestrogens, progesterone, androgens and tamoxifene⁴, administration of antifibrinolytic agents such as aminocaproic acid and tranexamic acid⁵, as well as the use of monoclonal antibody bevacizumab whose target is VEGF^{6,7}. The latter include endovascular embolization of the internal maxillary artery⁸, septodermoplasty⁹, modified Young's technique¹⁰ (anterior closure of nasal pits), microdebridement¹¹, bipolar electrocautery¹², photocoagulation using different types of laser (pulsed dye^{13,14}, CO₂, Nd:YAG¹⁵⁻¹⁷, argon^{18,19}, KTP^{20,21}, diode). As an alternative to Young's technique, the use of a removable silastic nasal obturator has been proposed²².

Over the last 30 years, laser treatments have been very successful and can be considered a valid choice in treatment of mild and severe epistaxis in patients with HHT. The recurrent feature of bleeding requires the possibility of carrying out repeated and specific treatments without damaging the nasal mucosa and without complications. Lasers act specifically on the vascular target, thanks to the capability of the emitted rays to be absorbed by specific components, such as haemoglobin, obtaining photocoagulation of telangiectasias without any damage to vessel walls and the epithelial coating; moreover, this technique is not associated with peri- and post-operative complications. These features make the laser treatment repeatable, when needed.

In our case series, similar to literature data², we found an increase of HHT-related epistaxis following the fourth decade of life. Of 24 patients who underwent diathermocoagulation by diode laser, 6 (25%) had recurrences that needed a second treatment after an average of 16 months from the first. The therapeutic strategy examined cannot be considered definitive, due to the recurrent feature of telangiectasias, but it has the advantage of being repeatable and it has no long-term peri- or post-operative complications and is well tolerated by patients. The repeatability, absence of complications and its level of tolerability make this procedure a valuable and safe therapeutic choice.

In our case series, patients underwent an operation under general anaesthesia, in order to control any possible intra-operative bleedings that would otherwise require treatment withdrawal and nasal tamponage. Literature data confirms the use of general anaesthesia in most cases^{13 15-21} due to the need for a safe procedure, considering that many patients will have anaemia.

The effectiveness of treatment is demonstrated by the increase in patients with one or no bleeding event per week, compared to pre-operative values (from 5% to 40%), though some patients still experience more bleeding events per week (50% pre-operative and 40% post-operative); in the last occurrence, patients were referred for septodermoplasty. This result cannot be due to a procedure failure, but to the recurrent feature of telangiectasias and the severity of the phenotype in those patients. As for the severity of bleeding, it should be highlighted that there was a substantial decrease in the number of patients reporting copious bleedings, by 46.6%. These results are important because the severity and frequency of epistaxis may endanger the quality of life from social and employment points of view. For this reason, the purpose of treatment should be to decrease the frequency and severity of bleeding events, since it is unable to stop them definitively considering the recurrent feature of telangiectasias. Half of patients defined their quality of life as very good or excellent after diode laser treatment, whereas none expressed this prior to treatment. This shows that chosen procedure is effective in improving psychological and social status, in addition to symp-

tomatology. 40% of patients did not have any recurrence 4 months after the treatment, whereas 35% had a recurrence within one month, showing nonetheless a decrease in the frequency and severity of bleeding events and making a second treatment unnecessary at least until the end of the study period. Indeed, photocoagulation of telangiectasias by diode laser was useful over time in 75% of patients. At present, their quality of life has remarkably improved, confirming the effectiveness of treatment.

The increase in the average haemoglobin concentration 3 months after the operation during follow-up was statistically significant. The haemoglobin value is strictly linked to the level of anaemia whose cause is blood loss. We chose our patients considering the absence of gastroenteric bleeding, another event causing anaemia. In our case series, a considerable decrease in frequency and severity of bleedings helped to improve the haemato-chemical picture, as well as anaemia of patients. In clinical practice, this means fewer admissions and blood transfusions, reflecting the improved clinical and social condition of patients. The increase in haemoglobin concentration confirms the validity of treatment by diode laser in controlling HHT-associated epistaxis.

Photocoagulation of mucosal lesions using a diode laser has demonstrated an efficacy, in some series, comparable to a KTP laser^{20 21} or Nd:YAG laser^{16 17}, considering improvement in symptoms, relapse free-time, safety and absence of complications.

Furthermore, our results compare positively to series in which argon laser treatment had to be repeated in all patients¹⁸ or was not possible because of severe epistaxis¹⁹, and to other series using treatment with Nd:YAG laser in which mild or moderate epistaxis required two or more re-treatments¹⁵. In fact, our study has highlighted the effectiveness of diode laser treatment of moderate and severe epistaxis, and only six (20%) re-treatments were performed during the follow-up period.

Our results show the effectiveness even if compared with series in which patients, treated with a pulsed dye laser, obtained benefits only after an average of three courses of treatment¹³. One case report¹⁴, in which treatment was performed by pulsed dye laser, had shown a limit related to the implementation of the procedure under local anaesthesia in an outpatient setting, with the consequence of an ineffective post-operative follow-up, affecting the possibility of control of short-term complications, unlike our patients who were hospitalized and followed more closely. However, it should be underlined that in our series no short-term complications were observed.

Conclusions

The procedure of diathermocoagulation by diode laser in treatment of nasal telangiectasias in patients suffering from HHT is an effective therapeutic method with a good

safety profile. It acts selectively on vascular tissues without damaging the surrounding epithelium, has no side-effects and no peri- or post-operation morbidity, is well tolerated and can be repeated when needed. The technique contributed to reducing the frequency and severity of bleedings, thus improving the quality of life from clinical, social and psychological points of view.

Further prospective studies with a longer follow-up and a larger number of patients will be necessary to better understand the actual effectiveness of diode laser in the treatment of HHT-associated epistaxis.

References

- ¹ Albinana V, Sanz-Rodriguez F, Recio-Poveda L, et al. *Immunosuppressor FK506 increases endoglin and ALK1 expression and modulates TGF- β 1 signalling in endothelial cells.* Mol Pharmacol 2011;79:833-43.
- ² Fiorella ML, Ross DA, White RI, et al. *Hereditary haemorrhagic telangiectasia: state of the art.* Acta Otorhinolaryngol Ital 2004;24:330-6.
- ³ Kühnel TS, Wagner BH, Schurr CP, et al. *Clinical strategy in hereditary hemorrhagic telangiectasia.* Am J Rhinol 2005;19:508-13.
- ⁴ Jameson JJ, Cave DR. *Hormonal and antihormonal therapy for epistaxis in hereditary hemorrhagic telangiectasia.* Laryngoscope 2004;114:705-9.
- ⁵ Morales-Angulo C, Pérez del Molino A, Zarrabeitia R, et al. *Treatment of epistaxes in hereditary haemorrhagic telangiectasia (Rendu-Osler-Weber disease) with tranexamic acid.* Acta Otorrinolaringol Esp 2007;58:129-32.
- ⁶ Simonds J, Miller F, Mandel J, et al. *The effect of bevacizumab (Avastin) treatment on epistaxis in hereditary hemorrhagic telangiectasia.* Laryngoscope 2009;119:988-92.
- ⁷ Davidson TM, Olitsky SE, Wei JL. *Hereditary hemorrhagic telangiectasia/avastin.* Laryngoscope 2010;120:432-5.
- ⁸ Andersen PJ, Kjeldsen AD, Nepper-Rasmussen J. *Selective embolization in the treatment of intractable epistaxis.* Acta Otolaryngol 2005;125:293-7.
- ⁹ Levine CG, Ross DA, Henderson KJ, et al. *Long-term complications of septal dermoplasty in patients with hereditary hemorrhagic telangiectasia.* Otolaryngol Head Neck Surg 2008;138:721-4.
- ¹⁰ Hitchings AE, Lennox PA, Lund VJ, et al. *The effect of treatment for epistaxis secondary to hereditary hemorrhagic telangiectasia.* Am J Rhinol 2005;19:75-8.
- ¹¹ Bublik M, Sargi Z, Casiano RR. *Use of the microdebrider in selective excision of hereditary hemorrhagic telangiectasia: a new approach.* Otolaryngol Head Neck Surg 2007;137:157-8.
- ¹² Ghaheri BA, Fong KJ, Hwang PH. *The utility of bipolar electrocautery in hereditary hemorrhagic telangiectasia.* Otolaryngol Head Neck Surg 2006;134:1006-9.
- ¹³ Harries PG, Brockbank MJ, Shakespeare PG, et al. *Treatment of hereditary haemorrhagic telangiectasia by the pulsed dye laser.* J Laryngol Otol 1997;111:1038-41.
- ¹⁴ Hartnick CJ, Dailey S, Franco R, et al. *Office-based pulsed dye laser treatment for hemorrhagic telangiectasias and epistaxis.* Laryngoscope 2003;113:1085-7.
- ¹⁵ Karapantzos I, Tsimpiris N, Goulis DG, et al. *Management of epistaxis in hereditary hemorrhagic telangiectasia by Nd:YAG laser and quality of life assessment using the HR-QoL questionnaire.* Eur Arch Otorhinolaryngol 2005;262:830-3.
- ¹⁶ Kluger PB, Shapshay SM, Hybels RL, et al. *Neodymium-YAG laser intranasal photocoagulation in hereditary hemorrhagic telangiectasia: an update report.* Laryngoscope 1987;97:1397-401.
- ¹⁷ Kühnel TS, Wagner BH, Schurr CP, et al. *Clinical strategy in hereditary hemorrhagic telangiectasia.* Am J Rhinol 2005;19:508-13.
- ¹⁸ Haye R, Austad J. *Hereditary hemorrhagic teleangiectasia-argon laser.* Rhinology 1991;29:5-9.
- ¹⁹ Lennox PA, Harries M, Lund VJ, et al. *A retrospective study of the role of the argon laser in the management of epistaxis secondary to hereditary haemorrhagic telangiectasia.* J Laryngol Otol 1997;111:34-7.
- ²⁰ Vickery CL, Kuhn FA. *Using the KTP/532 laser to control epistaxis in patients with hereditary hemorrhagic telangiectasia.* South Med J 1996;89:78-80.
- ²¹ Harvey RJ, Kanagalingam J, Lund VJ. *The impact of septodermoplasty and potassium-titanyl-phosphate (KTP) laser therapy in the treatment of hereditary hemorrhagic telangiectasia-related epistaxis.* Am J Rhinol 2008;22:182-7.
- ²² Woolford TJ, Loke D, Bateman ND. *The use of a nasal obturator in hereditary haemorrhagic telangiectasia: an alternative to Young's procedure.* J Laryngol Otol 2002;116:455-6.

Received: October 5, 2011 - Accepted: December 9, 2011