

RHINOLOGY

Endoscopic transnasal dacryocystorhinostomy without stenting: results in 64 consecutive procedures

Dacriocistorinostomia endoscopica transnasale senza stenting: risultati in 64 procedure consecutive

B. PITTORE¹, N. TAN¹, G. SALIS², P.A. BRENNAN³, R. PUXEDDU^{1,4}

¹ Department of Otorhinolaryngology, Head and Neck Surgery, Queen Alexandra Hospital, Portsmouth, UK;

² Department of Otorhinolaryngology, "Paolo Dettori" Hospital, ASL 2, Olbia, Italy; ³ Department of Oral and Maxillofacial Surgery, Queen Alexandra Hospital, Portsmouth, UK. ⁴ University of Cagliari, Italy

SUMMARY

Dacryocystorhinostomy allows by-passing saccal and post-saccal stenoses and has traditionally been performed via an external approach, namely, external dacryocystorhinostomy. Over the past two decades, advances in endoscopic equipment have led to the widespread use of the endoscopic transnasal approach to the lacrimal pathway. A retrospective evaluation has been made of personal success rates in endoscopic dacryocystorhinostomy without stenting in 56 patients (15 male, 41 female) treated for nasolacrimal duct obstruction (48 unilateral, 8 bilateral). Of these, 53 were primary endoscopic dacryocystorhinostomy and 11 procedures were revisions of external dacryocystorhinostomy. A total of 64 endoscopic dacryocystorhinostomies were performed. Mean follow-up was 37.3 months (range 12-84 months). The success of surgery was defined by resolution of signs (epiphora and dacryocystitis) and objectively by endoscopic evaluation of the rhinostomy on routine follow-up. Results from patients undergoing primary endoscopic dacryocystorhinostomy were better than those for revision of external dacryocystorhinostomy with overall anatomical and functional results of 94.3% and 90.9%, in our series. The present study confirms that endoscopic dacryocystorhinostomy without stenting is effective for the treatment of nasolacrimal duct obstruction. The endoscopic approach allows simultaneous treatment of associated anatomic anomalies and sino-nasal disorders. Results obtained confirm that a functionally patent dacryocystorhinostomy can be achieved without the need for routine nasolacrimal stenting.

KEY WORDS: Dacryocystorhinostomy • Silicone stent • Lacrimal pathway • Endoscopic surgery

RIASSUNTO

La dacriocistorinostomia (DCR) è un intervento chirurgico che consente di by-passare una stenosi saccale e post-saccale e viene tradizionalmente eseguita con approccio esterno (ExDCR). Nelle ultime due decadi, i miglioramenti della chirurgia endoscopica nasale hanno consentito il suo utilizzo nella patologia delle vie lacrimali. Abbiamo valutato, retrospettivamente, i nostri risultati in 56 pazienti (15 maschi, 41 femmine) affetti da ostruzione del dotto naso-lacrimale (48 unilaterali, 8 bilaterali) e sottoposti ad intervento chirurgico di dacriocistorinostomia endoscopica (EnDCR) senza l'utilizzo dello stent naso-lacrimale. Di questi 53 erano EnDCR primarie e 11 erano revisioni di ExDCR, per un totale di 64 EnDCR. Il follow-up medio è stato di 37,3 mesi (range 12-84 mesi). Il successo dell'intervento chirurgico è stato definito dalla risoluzione dei segni (epifora e dacriocistiti) ed obiettivamente dalla valutazione endoscopica del rinostoma durante il follow-up. Nella nostra serie, i risultati nei pazienti sottoposti a EnDCR primaria sono stati migliori rispetto a quelli sottoposti a revisione di ExDCR con un complessivo risultato anatomico e funzionale del 94,3% e 90,9%. Il presente studio conferma che anche senza l'utilizzo dello stent naso-lacrimale a seguito di un intervento di EnDCR, si possono ottenere dei buoni risultati nel trattamento delle ostruzioni del dotto naso-lacrimale. Inoltre, l'approccio endoscopico, consente di trattare contemporaneamente anomalie anatomiche e patologie rinosinusalì. Noi crediamo che un dacriocistorinostoma funzionale può essere ottenuto senza la necessità di inserire routinariamente uno stent naso-lacrimale.

PAROLE CHIAVE: Dacriocistorinostomia • Stent in silicone • Vie lacrimali • Chirurgia endoscopica

Acta Otorhinolaryngol Ital 2010;30:294-298

Introduction

Lacrimal pathway obstruction can be idiopathic or secondary to chronic infections, tumours, trauma or iatrogenic factors, and may occur at any point along the

tract, being more frequent, however, at the level of the nasolacrimal duct. Obstruction can be pre-saccal (usually common canaliculus), saccal and post-saccal (nasolacrimal duct). Bilateral nasolacrimal duct obstruction is much less common than unilateral obstruction

and sometimes this is associated with nasal and sinus diseases¹.

Dacryocystorhinostomy (DCR) is indicated for saccal and post-saccal stenosis and is traditionally performed externally by Ophthalmologists². Over the past two decades, advances in endoscopic equipment have led to a spread of the endoscopic transnasal approach by Otorhinolaryngologists with results comparable to the external approach and the potential for less morbidity^{3,4}.

The advantages of Endoscopic Dacryocystorhinostomy (EnDCR) with respect to External Dacryocystorhinostomy (ExDCR) include the lack of skin incision, short operating time, and lower risk of interfering with the physiological lacrimal pump mechanism, minimal blood loss and the possibility to correct associated intra-nasal pathological conditions during the same procedure³.

Naso-lacrimal silicone stenting is performed by many surgeons as a routine step in ExDCR and EnDCR³. The function of the stent is thought to be useful in keeping the neo-ostium patent in the initial stages of healing and thus decreasing the chance of early failure. Personal experience is reported in 64 consecutive cases submitted to EnDCR without stenting.

Material and methods

Between March 1996 and September 2008, 56 patients (15 male, 41 female) were treated for naso-lacrimal duct obstruction by the same surgeon (RP). Mean age was 59.2 years (range 13-86). Of these patients, 54 had an idiopathic obstruction, one was post-traumatic and one secondary to fibrosis following radiotherapy for carcinoma of the nasal cavity. Patients presented with only epiphora in 32 cases (50%), recurrent dacryocystitis in 25 cases (39%), lacrimal abscess in 6 cases (9.3%), and a combination of symptoms (epiphora, purulent secretion from the canalicula, nasal obstruction and nasal discharge) in one (1.6%). Patients underwent clinical evaluation consisting of ophthalmologic and otorhinolaryngological examinations (including nasal endoscopy using 0° and 45° rigid endoscopes). Each patient had a routine antero-posterior and lateral dacryocystography with Lipiodol (iodinated, radio-opaque contrast solution), Laboratoire Guerbet, Paris, France, to determine the level of the obstruction.

Computed Tomography (CT) sinus scan was performed to assess the anatomy and possible cause of obstruction. This also allowed to identify the extent of concomitant sino-nasal pathology or anatomical changes (i.e., *aggen nasi*) that could be managed upon at the same time.

Overall, there were 64 EnDCRs of which 53 were primary EnDCR (25 right, 28 left). A total of 11 procedures were revisions of ExDCR (8 right, 3 left) and one of these was a revision of an EnDCR performed in another centre. Thus a total of 8 bilateral and 48 unilateral procedures were performed (Table I).

Septoplasty or access septal surgery was performed in 3 cases. Middle turbinoplasty was required in 7 patients, for better exposure of the surgical area, 4 middle meatal anastomies for maxillary sinusitis and 1 nasal polypectomy, were also performed. All procedures were performed in day surgery.

Mean follow-up was 37.3 months (range 12-84 months).

Surgical technique

All procedures were performed under general anaesthetic, using 0° and 45° rigid endoscopes (Karl Storz, Tuttlingen, Germany) connected to a high-resolution video system (Endovision, Tricam SL II, Karl Storz, Tuttlingen, Germany). Neurosurgical patties soaked with 1:1000 adrenaline or xylometazoline hydrochlorate were placed in the nose for 5 minutes to achieve local vasoconstriction. Submucosal injection of Lignospan (2% lignocaine, 1:80.000 adrenaline) anterior to the axilla of the middle turbinate was performed to produce hydro dissection and vasoconstriction of the mucosal flap. The introduction of a 0.7 mm diameter light lacrimal probe via the inferior punctum allowed accurate endonasal identification of the medial sacral wall. The mucosal incision was made 5 to 10 mm anterior to the attachment of the middle turbinate with a sickle knife. A posteriorly based mucosal flap was elevated and the bone corresponding to nasal projection of the lacrimal sac was removed. The thick bone from the frontal process of the maxilla was removed with Smith-Kerrison forceps. When it was too difficult to use the forward blade of the forceps, we used a cutting or diamond drill burr to complete the bone removal and exposure of the medial sac wall. Once the sac was exposed, a posterior vertical incision of the wall of the sac was performed with a Beaver

Table I. Procedures (total number = 64) performed.

Procedure	Unilateral	Bilateral	Eyes		Second procedure
			L	R	
Primary EnDCR	37	8	28	25	2 (with stent)
EnDCR Revision of ExDCR*	11*	0	3	8	1
Total	48	8	31	33	3

EnDCR: Endoscopic Dacryocystorhinostomy; ExDCR: External Dacryocystorhinostomy; * 1 Revision EnDCR performed in another Department.

angle knife. This creates anteriorly large, and posteriorly, small based flaps, thereby marsupialising the sac and covering the exposed bone as much as possible. The mean duration of the procedure was 40 minutes. When possible, the sac was widely marsupialised and the flaps kept in place with a gelatine based absorbable haemostat, namely, Spongostan® (Ferrosan, Soeborg, Denmark).

Sino-nasal pathology was corrected when necessary and in cases of significant bleeding, nasal packing for < 24 hours was used.

Post-operative care

The post-operative treatment included oral antibiotics, usually Co-amoxiclav (Amoxicillin and Clavulanic Acid) 625 mg three times daily for 7 days and topical eye drops

(betamethasone 0.2 g and chloramphenicol 0.5 g) 2-3 drops, 3 times daily, for 7 days. Nasal douching with isotonic sterile solution, three times a day, was prescribed. In the postoperative period, the patients underwent regular rigid nasoendoscopy examinations for debridement of fibrinous exudates, normally every 4-5 days for the first two weeks, thereafter, patients were examined on a monthly basis for the first 3 months and then every six months for the second year. Complete epithelialisation of the rhinostomy occurred within two months (Fig. 1), but the final diameter of the rhinostomy was only considered stable at 8-12 months after surgery (Fig. 2).

Results

Surgical success was defined by resolution of signs and symptoms, rhinostomy stabilization and free lacrimal drainage. A modified 5-point Likert Scale⁵ was used to assess subjective changes in symptoms.

The patients were asked about the degree of the epiphora and improvement of the symptoms. Declaration of improvement, on the modified Likert Scale, with a score of 1 to 3 was considered successful. Functional success was observed in 60/64 cases (93.7%). Of these, 58 were without epiphora and 2 reported an improvement in symptoms (Table II). Our anatomical success, including revision surgery, showed that, in 60/64 cases, the rhinostomy was patent leading to an overall anatomical success rate of 93.7% (Table III). Results in patients undergoing primary EnDCR were better than those for revision of ExDCR, with an anatomical and functional success rate of 94.3% (Tables II, III). Results following revision of ExDCR were 90.9% including one patient who was submitted to a second procedure (Tables II, III).

Complications

No major complications occurred intra-operatively. One post-operative septal haematoma occurred, that was treat-

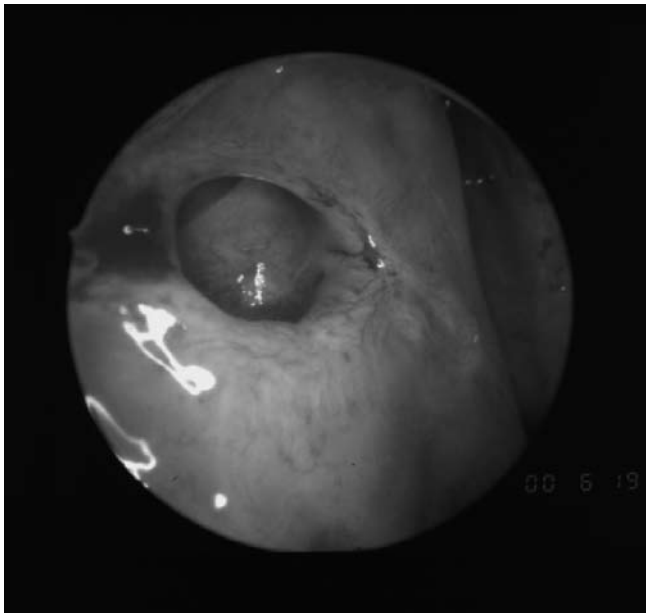


Fig. 1. Dacryocystorhinostoma 2 months after the procedure. Presence of some granulation tissue at the anterior margin of the stoma.

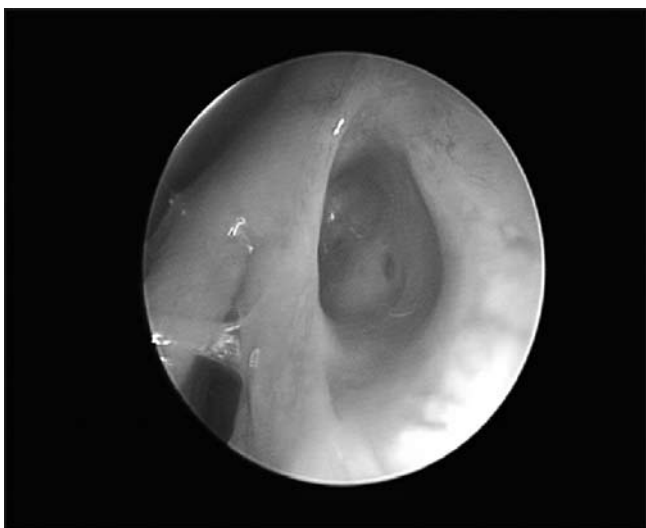


Fig. 2. Dacryocystorhinostoma 6 months after the procedure. Patient previously treated with radiotherapy for naso-sinusal carcinoma.

Table II. Subjective (functional) results: modified Likert Scale.

Likert Scale	Primary EnDCR	EnDCR Revision of ExDCR*
Score 1 (No symptoms)	48	10
Score 2 (Significant improvement)	2	0
Score 3 (Slight improvement)	0	0
Score 4 (No improvement)	3	1
Score 5 (Worsening of symptoms)	0	0
Results	50/53 (94.3%)	10/11 (90.9%)
Total results	60/64 (93.7%)	

* 1 Revision EnDCR performed in another Department.

Table III. Total anatomical results.

Patency	Primary EnDCR	EnDCR Revision of ExDCR*
Rhinostomy open	50	10
Rhinostomy closed	3	1
Results	50/53 (94.3%)	10/11 (90.9%)
Total results	60/64 (93.7%)	

* 1 Revision EnDCR performed in another Department.

ed with incision and drainage, one epistaxis, treated conservatively, and 4 cases of latero-septal synechia which, however, did not interfere with functional outcome or require further treatment.

Discussion

ExDCR, originally described by Toti in 1904⁶ has a successful rate, when performed by properly trained ophthalmologists, of about 90%^{3,4}. Endo-nasal DCR was described prior to this, in 1893 by Caldwell⁷, but poor equipment and subsequent good results from the external approach led it to being abandoned. McDonogh and Meiring were the first modern surgeons credited with introducing endoscopic transnasal DCR in the late 1980s⁸.

EnDCR has a success rate of 83-94%^{9,10}, and has been demonstrated to offer similar outcomes when compared to ExDCR, with low complication rates^{3,4}. EnDCR is a good option for the treatment of primary nasolacrimal duct obstruction but it is also considered an acceptable procedure for the treatment of failure of ExDCR¹¹.

The advantages of EnDCR with respect to ExDCR include avoiding an external scar, less interference on the lacrimal pump mechanism and the possibility to treat sino-nasal disorders and anatomical abnormalities in the same operation¹². In the present series, we performed 15 ancillary procedures (3 septoplasty or access upper septal surgery, 7 middle turbinoplasty, 4 middle meatal antrostomies and in one nasal polypectomy) that would not have been possible if an ExDCR had been performed.

Pre-operative evaluation has been standardized with ophthalmologic evaluation and diagnosis including a dacryocystography with contrast medium to confirm the site of the obstruction. Endoscopic evaluation is performed at the same time as the ENT evaluation and the need for CT is discussed on the basis of the clinical findings at rhinoscopy. We performed a CT scan in 48 patients (85.7%) in order to better assess the anatomy and, if present, the degree of sino-nasal polyposis. In our opinion, CT should be considered a useful tool in the pre-operative planning of the procedure whether for the endoscopic or external approach, in the latter allowing the ophthalmologist to involve a rhinologist in the event of sinonasal pathology or anatomical changes that can have an effect upon the sur-

gical results. In the early years of the present experience, a CT scan was not routinely performed pre-operatively, whereas it is now our policy to obtain a CT scan pre-operatively in order to correctly define the cause of the obstruction of the lacrimal pathways.

In our department, different types of mucosal flaps were used over time. We believe that the posterior mucosal flap offers the best possibility for easy access to the bone overlying the sac, allowing wide and complete exposure of the medial wall of the sac that can thus be marsupialised. This represents a key point in the procedure that assists in the creation of a large rhinostomy that obviates the need for silicone stenting.

Inadequate bone removal is also a common cause of failure⁹. Various instruments can be used to remove the bone including drill (cutting or diamond burr), curette, Smith-Kerrison forceps or laser (KTP, Diode, Argon, Holmium: YAG, CO₂)^{13,14}. Smith-Kerrison forceps are a safe and effective tool to obtain a wide DCR although, in some instances, it is not adequate, for the easy removal of the superior aspect of the frontal process of the maxillary bone for anatomical reasons, since the forceps can not incarcerate the bone in these cases we would favour powered drills.

The size of the lacrimal sac, at the time of the surgery, has a direct influence on the success of the procedure as described in the literature¹⁵. In a group of 49 patients undergoing EnDCR, Mann reported that the neo-ostium was reduced in size in the first 4 weeks after surgery, thereafter, the ostium dimensions appear to be stable¹⁵. We now tend to expose and marsupialize the sac entirely and to keep the flaps in place with Spongostan[®], a gelatine-based absorbable haemostat (Ferrosan, Soeborg, Denmark).

The use of silicone stents is considered routine in many institutions³. Although controversial, silicone stents are used to keep the neo-ostium open after the procedure and are thought to maintain the patency of the ostium by preventing circular stenosis of the neo-ostium in the post-operative healing period. Prolonged silicone intubation adds to the risk of granulation tissue formation at the neo-ostium, and has been described as a cause of failure^{9,16}. There is no general agreement regarding the duration of the stenting. Recommendations range from 4 weeks to 3 months. Prolonged intubation has been recommended in the treatment of functional failure of ExDCR or EnDCR. The bicanalicular tubes are used as long-standing stenting. The efficacy seems to be related to the passage of the tears in the nose for micro-capillarity¹⁷. Clearly, this is an area that could benefit from further investigation.

In recent years, a number of Authors have described EnDCR without silicone stenting^{10,18-20}. Smirnov demonstrated in a prospective randomized trial of patients undergoing primary EnDCR that silicone stenting is unnecessary, giv-

ing an overall success rate with and without silicon tubes of 78% and 100% respectively¹⁰. This trial showed statistically significant results favouring non-stenting. This has been confirmed recently in another randomised trial by Unlu et al. showing results in the stented and non-stented groups of 84.2% and 94.7%. Although there was no statistical difference showing one technique to be superior to another, the Authors recommended that silicone intubation was not a mandatory requirement following EnDCR²⁰. In the present series, the silicone stent was never inserted thus allowing the opportunity of reducing the costs of the procedure and minimizing the discomfort for the patient, without negatively affecting the outcome.

References

- ¹ Wong RJ, Gliklich RE, Rubin PAD, et al. *Bilateral nasolacrimal duct obstruction managed with endoscopic techniques*. Arch Otolaryngol Head Neck Surg 1998;124:703-6.
- ² Tarbet KJ, Custer PL. *External dacryocystorhinostomy. Surgical success, patient satisfaction, and economic cost*. Ophthalmology 1995;102:1065-70.
- ³ Yigit O, Samancioglu M, Taskin U, et al. *External and endoscopic dacryocystorhinostomy in chronic dacryocystitis: comparison of results*. Eur Arch Otorhinolaryngol 2007;264:879-85.
- ⁴ Feretis M, Newton JR, Ram B, et al. *Comparison of external and endonasal dacryocystorhinostomy*. J Laryngol Otol 2009;123:315-9.
- ⁵ Likert R. *A technique for the measurement of attitudes*. Arch Psychol 1932;140:1-55.
- ⁶ Toti A. *Nuovo metodo conservatore di cura radicale delle suppurazioni croniche del sacco lacrimale*. Clinica Moderna 1904;10:385.
- ⁷ Caldwell G. *Two new operations for obstruction of the nasal duct, with preservation of the canaliculi, and with an incidental of a new lacrymal probe*. Am J Ophthalmol 1893;10:189-93.
- ⁸ McDonogh M, Meiring JH. *Endoscopic transnasal dacryocystorhinostomy*. J Laryngol Otol 1989;100:585-7.
- ⁹ Onerci M, Orhan M, Ogretmenoglu O, et al. *Long-term results and reasons for failure of intranasal endoscopic dacryocystorhinostomy*. Acta Otolaryngol 2000;120:319-22.
- ¹⁰ Smirnov G, Tuomilehto H, Terasvirta M, et al. *Silicone tubing is not necessary after primary endoscopic dacryocystorhinostomy: A prospective randomized study*. Am J Rhinol 2008;22:214-7.
- ¹¹ Demarco R, Strose A, Araujo M, et al. *Endoscopic revision of external dacryocystorhinostomy*. Otolaryngol Head Neck Surg 2007;137:497-9.
- ¹² Nussbaumer M, Schreiber S, Yung MW. *Concomitant nasal procedures in endoscopic dacryocystorhinostomy*. J Laryngol Otol 2004;118:267-9.
- ¹³ Umopathy N, Kalra S, Skinner DW, et al. *Long-term result of endonasal laser dacryocystorhinostomy*. Otolaryngol Head Neck Surg 2006;135:81-4.
- ¹⁴ Ajalloueyan M, Fartookzadeh M, Parhizgar H. *Use of laser for dacryocystorhinostomy*. Arch Otolaryngol Head Neck Surg 2007;133:340-3.
- ¹⁵ Mann BS, Wormald PJ. *Endoscopic assessment of the dacryocystorhinostomy ostium after endoscopic surgery*. Laryngoscope 2006;116:1172-4.
- ¹⁶ Allen K, Berlin AJ. *Dacryocystorhinostomy failure: association with nasolacrimal silicone intubation*. Ophthalmic Surg 1989;20:486-9.
- ¹⁷ Kim NJ, Kim JH, Hwang SW, et al. *Lacrimal silicone intubation for anatomically successful but functionally failed external dacryocystorhinostomy*. Kor J Ophthalmol 2007;21:70-3.
- ¹⁸ Unlu HH, Aslan A, Toprak B, et al. *Comparison of surgical outcomes in primary endoscopic dacryocystorhinostomy with and without silicone intubation*. Ann Otol Rhinol Laryngol 2002;111:704-9.
- ¹⁹ Smirnov G, Tuomilehto H, Terasvirta M, et al. *Silicone tubing after endoscopic dacryocystorhinostomy: Is it necessary?* Am J Rhinol 2006;20:600-2.
- ²⁰ Unlu HH, Gunhan K, Baser EF, et al. *Long-term results in endoscopic dacryocystorhinostomy: Is intubation really required?* Otolaryngol Head Neck Surg 2009;140:589-95.

Conclusions

Our results confirm that EnDCR without stenting is effective for the treatment of naso-lacrimal duct obstruction. This procedure gives good anatomic and functional results, with low complication rates. The endonasal endoscopic approach allows simultaneous treatment of associated anatomic anomalies and sino-nasal pathology. In the present series of 64 consecutive procedures, a functionally patent dacryocystorhinostomy was achieved without the need for nasolacrimal stent insertion. Taking into account the added cost and potential morbidity, we suggest that the use of nasolacrimal stents, in EnDCR, can be avoided.

Received: April 12, 2010 - Accepted: September 12, 2010

Address for correspondence: Dr. B. Pittore, Otorhinolaryngology Department, "Queen Alexandra Hospital", Cosham, Portsmouth PO63LY, UK. E.mail: barbarapitt@tiscali.it