

RHINOLOGY

Microdebrider-assisted versus radiofrequency-assisted inferior turbinoplasty: a prospective study with objective and subjective outcome measures

Turbinoplastica con microdebrider versus turbinoplastica con bisturi a radiofrequenze: studio prospettico con valutazioni obiettive e soggettive

C. CINGI, B. URE, H. CAKLI, E. OZUDOGRU

Department of Otorhinolaryngology, Eskisehir Osmangazi University, Eskisehir, Turkey

SUMMARY

In order to relieve the symptoms of nasal obstruction in patients with inferior turbinate hypertrophy, various surgical methods have been used. Aim of this study was to compare post-operative outcome between radiofrequency and microdebrider-assisted partial turbinoplasty. A prospective study was performed in 268 patients with nasal obstruction and hypertrophied turbinate mucosa refractory to medical treatment, from December 2000 to December 2005. Overall, 124 patients were treated with microdebrider (Group 1) and 144 patients with radiofrequency (Group 2). Post-operative changes in the degree of nasal obstruction, nasal discharge, hyposmia and headache were evaluated prospectively on the 7th day, 1st, and 3rd months after the procedure. Rhinomanometric evaluation was also performed for objective comparison. Both procedures were perfectly tolerated by the patients. The nasal obstruction scale improved significantly in Group 1 on day 7, and within the periods of 1st and 3rd months after surgery, while the significant improvement took place in Group 2 only in the 1st and 3rd months after surgery. The comparison between the two groups showed that symptom improvement was statistically significant in Group 1 on the 7th day, 1st and 3rd months after surgery. Severity of nasal discharge, headache and hyposmia grades improved significantly in the first week after the operation both in the microdebrider and radiofrequency group and persisted during the 1st and 3rd months after the operation. Since microdebrider can effectively widen the nasal airway, the rhinomanometric measurements of these patients were found to be lower than in the radiofrequency group. Moreover, patient satisfaction in the microdebrider group was higher than that in the radiofrequency group. In conclusion, this study suggests that microdebrider-assisted partial turbinoplasty is more effective and satisfactory in relieving nasal obstruction.

KEY WORDS: Nasal obstruction • Turbinate hypertrophy • Turbinoplasty • Radiofrequency • Microdebrider

RIASSUNTO

Varie metodologie chirurgiche sono stati utilizzate al fine di alleviare i sintomi da ostruzione nasale in pazienti con ipertrofia dei turbinati inferiori. Scopo di questo studio è stato il confronto tra gli esiti post-operatori da turbinoplastica con microdebrider versus turbinoplastica con bisturi a radiofrequenze. Uno studio prospettico è stato eseguito, dal dicembre 2000 al dicembre 2005, su 268 pazienti con ostruzione nasale e ipertrofia della mucosa dei turbinati refrattaria al trattamento medico. Complessivamente, 124 pazienti sono stati trattati con microdebrider (Gruppo 1) e 144 pazienti con radiofrequenza (Gruppo 2). Modificazioni post-operatorie del grado di ostruzione nasale, secrezione nasale, iposmia e cefalea sono state valutate prospettivamente il 7° giorno ed il 1° e 3° mese dopo l'intervento. La valutazione rinomanometrica è stata effettuata per consentire un confronto oggettivo dei risultati. Entrambe le procedure sono state perfettamente tollerate dai pazienti. La scala di ostruzione nasale risultava migliorata in modo significativo nel gruppo 1, il giorno 7, ed al 1° e 3° mese dopo l'intervento chirurgico, mentre nel Gruppo 2 un miglioramento significativo si è osservato solo al 1° e 3° mese dopo l'intervento. Il confronto tra i due gruppi ha mostrato che il miglioramento dei sintomi è risultato statisticamente significativo nel gruppo 1 al 7° giorno, e al 1° e 3° mese dopo l'intervento chirurgico. La gravità di secrezione nasale, cefalea e iposmia risultava notevolmente migliorata nella prima settimana dopo l'operazione in entrambi i gruppi di pazienti e persisteva durante il 1° e 3° mese dopo l'operazione. Poiché il microdebrider può effettivamente ampliare le cavità nasali, le misurazioni rinomanometriche in questi pazienti sono risultate inferiori rispetto a quelle del gruppo operato con radiofrequenza. Inoltre, la soddisfazione dei pazienti del gruppo microdebrider è stata superiore a quella del gruppo radiofrequenza. In conclusione, questo studio suggerisce che la turbinoplastica con microdebrider è più efficace e soddisfacente nell'alleviare l'ostruzione nasale rispetto alla tecnica con bisturi a radiofrequenze.

PAROLE CHIAVE: Ostruzione nasale • Ipertrofia dei turbinati • Turbinoplastica • Radiofrequenze • Microdebrider

Introduction

Chronic nasal obstruction is one of the most common complaints that an otolaryngologist may face during his/her medical practice. Possible causes may be septal deformities, nasal valve pathologies or mucosal diseases, such as allergic rhinitis and chronic rhino-sinusitis. Inferior turbinate hypertrophy, which is one of the most common causes of nasal obstruction, may be observed in allergic rhinitis, vasomotor rhinitis, chronic hypertrophic rhinitis or, sometimes, compensatory response to an evident septal deformity. Medical treatment options such as anti-histamines, topical decongestants and corticosteroids are commonly prescribed to reduce the size of the turbinate with the aim of restoring nasal function. However, some cases show only slight improvement while some are even refractory to these medical treatments and the patients complain about persistent symptoms. In these cases, surgical reduction of the inferior turbinate can be attempted. Various techniques have been described to reduce the volume of the mucosal and bony parts of the inferior turbinate. Conventional surgical options are total or partial turbinectomy, turbinoplasty, sub-mucosal turbinectomy, electrocautery and cryosurgery^{1,2}. Although these methods may provide better results than medical treatment alone, adverse effects such as bleeding, crust formation, post-operative pain, synechia or atrophy of the inferior turbinate are common^{1,3,4}.

One of the methods that yields satisfactory results with fewer side-effects is radiofrequency of inferior turbinates^{5,6}. Radiofrequency energy is applied to the inferior turbinate causing an ionic chaos at cell level. This ionic change results in local heat increase, thus creating a deep thermal lesion. Healing occurs primarily with fibrosis which shrinks the surrounding tissue, in our case the inferior turbinate. In the late 1990s, a new instrument was introduced in the field of partial inferior turbinoplasty: microdebrider was employed with the hope of achieving satisfactory turbinate reduction without sacrificing normal functions of the turbinate tissue^{7,8}. However, there have been only a few studies comparing the subjective and objective success rates and long-term post-operative results between these two minimally invasive methods: radiofrequency *versus* microdebrider^{9,10}. The aim of the present study with a large patient population was to compare the objective and subjective efficiency and results on symptom relief between the two groups.

Material and methods

Study design

A prospective study was performed on 268 patients who presented nasal obstruction and hypertrophied turbinate mucosa refractory to medical treatment, from December 2000 to December 2005. All of these patients had symptoms and signs of nasal obstruction and stuffiness related to congested turbinate mucosa that did not respond well to medical treatment.

Following routine physical ear-nose-throat examination, focusing on detailed nasal examination, every patient underwent endoscopic nasal evaluation. Patients with prominent mucosal hypertrophy were selected by means of a decongestion test because patients with bony hypertrophy, covered with a thin layer of mucosa, are not good candidates for microdebrider- and radiofrequency-assisted turbinoplasty. Nasal cavities were decongested for 5 minutes with cotton pledgets soaked with adrenaline at a concentration of 1/100,000. Only patients with evident shrinking of their inferior turbinates were included in this study. Patients with no symptom improvement at the end of this procedure were excluded from the study. Patients who had undergone any kind of surgery for treatment of turbinate hypertrophy, septal deviation or nasal polyps were excluded from the study as well as those who were thought to have other causes of nasal obstruction other than inferior turbinate hypertrophy.

Informed consent was obtained from all patients and the study was approved by the Institutional Review Board of the University. 124 patients (44 females, 80 males) were treated with microdebrider (Group 1) and 144 patients (44 females, 100 males) were treated with radiofrequency (Group 2). The mean patient age was 35 ± 12 years for the microdebrider group and 33 ± 11 years for the radiofrequency group.

Surgical procedures

The radiofrequency procedure was performed under local anaesthesia. Sedation was achieved with dormicum 30 minutes before the operation. Cotton pledgets soaked with 4% panthocaine and 0.05% oxymetazoline HCL were applied into both nasal passages of the patients for 10 minutes to achieve vasoconstriction and anaesthesia. A radiofrequency device (Ellman Surgitron FFPF EMC Radiosurgical Device, Ellmann International, New York, USA) was used for coblation of the inferior turbinates. Radiofrequency energy was delivered to anterior, middle and posterior portions of inferior turbinate for 10 seconds, taking great care not to injure the overlying mucosa of the turbinate. The coagulation mode was used and the generator power level was set at grade three. No nasal packaging was applied. Patients were followed up for 3 hours for potential complications such as bleeding and increase in nasal obstruction. Those who did not have any problems were dismissed and scheduled for control visits.

The microdebrider procedure was performed under general anaesthesia. A "Xomed XPS 3000" unit (Medtronic/Xomed, Jacksonville, FL, USA) was used for microdebrider assisted turbinoplasty. After creating an antero-inferior submucosal pocket on the inferior turbinate with a conventional 15 blade, the microdebrider unit was set at 3000-rpm oscillating mode. With an "inferior turbinate 2 mm blade", the inferior turbinate size was reduced especially from the anterior head, taking great care to stay in the submucosal plane. A Meroce[®] nasal pack (Medtronic, Mystic, CY,

USA) was divided into two halves and placed within both nasal passages. Patients were then followed for 24 hours for any potential complications. Those who did not have any problems were dismissed and scheduled for control visits.

Outcome parameters

Subjective symptoms, such as nasal obstruction, nasal discharge, hyposmia and headache, were evaluated on the 7th day, and in the 1st and 3rd months after the procedure using a four-point scale (Tables I-IV).

Rhinomanometric evaluation was also performed as an objective comparison method pre-operatively and 3 months after the procedure. A “Homoth Rhino 2002” (*Homoth Rhino 2002 Rhinomanometry*, Homoth Medizinelektronik, Hamburg, Germany) device was used for rhinomanometric

evaluation. Active anterior rhinomanometry was applied in all patients in accordance with the rhinomanometry standardization committee’s suggestions in 1984. Patients waited in a quiet room setting for 30 minutes prior to the application. After choosing suitable applicators, patients were told to breathe slowly. Great care was taken not to cause deformation of the nostrils and nasal valve angles during the rhinomanometry procedure. After having recorded 5 breaths, mean values were noted. Rhinomanometry results were evaluated mainly at the 150 Pascal pressure point for left and right nasal cavities. Results obtained were recorded for statistical analysis.

The patients’ satisfaction with the procedure was evaluated according to a four-point scale pre-operatively and on the 7th day, and in the 1st, and 3rd months after the procedure (Table V). Patients were contacted by phone at the end of the first year after surgery and were requested to evaluate their “satisfaction with the procedure” as previously pointed out.

Table I. Four-point scale of nasal obstruction.

Nasal obstruction	
0	No nasal obstruction.
1	Mild obstruction (causing no disturbance in patient’s daily life)
2	Moderate obstruction (forcing the patient to breath through the mouth)
3	Severe obstruction (causing sleep disturbances and decrease in voice quality)

Table II. Four-point scale of nasal discharge.

Nasal discharge	
0	No nasal discharge
1	Mild nasal discharge (1 to 4 nose blowing a day)
2	Moderate nasal discharge (5 to 10 nose blowing a day)
3	Severe nasal discharge (continuous nasal discharge)

Table III. Four-point scale of headache.

Headache	
0	No headache
1	Mild headache (not requiring use of any analgesics)
2	Moderate headache (requiring non-narcotic analgesics for relief from headache)
3	Severe headache (requiring narcotic analgesics for relief from headache)

Table IV. Four-point scale of hyposmia.

Hyposmia	
0	No hyposmia
1	Mild hyposmia
2	Moderate hyposmia
3	Severe hyposmia

Table V. Four-point scale of patient’s satisfaction.

Satisfaction with the procedure	
0	I am not satisfied
1	I am a little bit satisfied
2	I am moderately satisfied
3	I am totally satisfied.

Statistical analysis

Symptoms and physical examination findings within groups were compared with Friedman Repeated Measures, Analysis of Variance on Ranks and All Pairwise Multiple Comparison Procedures (Tukey Test). Intergroup comparisons were made using the Mann-Whitney U test. Comparisons of complication rates were analyzed with “Test and CI for Two Proportions”. For each statistical analysis, a P value < 0.05 was considered statistically significant.

Results

Post-operative follow-up and complication rates

Both procedures were perfectly tolerated by the patients. While no crusting or synechia formation was observed, two patients had minor bleeding. The only major complaint reported by the radiofrequency group was the worsening of nasal obstruction during the early days of the operation, sometimes lasting a week and gradually improving over the course of one month. The microdebrider group did not present post-operative major bleeding, crusting and synechia formation, but 7 of them had minor bleeding during the early days after the operation, which was easily controlled with minimal Spongostan® (Ferro-san A/S, Soeborg, Denmark) sponge packaging. Complication rate differences (minor bleeding) between the two groups were not statistically significant (p = 0.086).

Subjective symptom improvements

Severity of nasal obstruction grades improved significantly during the first week after the operation, in the microdebrider group, and persisted 3 months after the operation. However, a statistically significant improvement in nasal obstruction grades was only observed during the first month after the operation in the radiofrequency group. Severity of nasal obstruction grades improved significantly better in the microdebrider group in the first week, the first month and the third month post-operatively, compared with the radiofrequency group ($p < 0.05$) (Fig. 1).

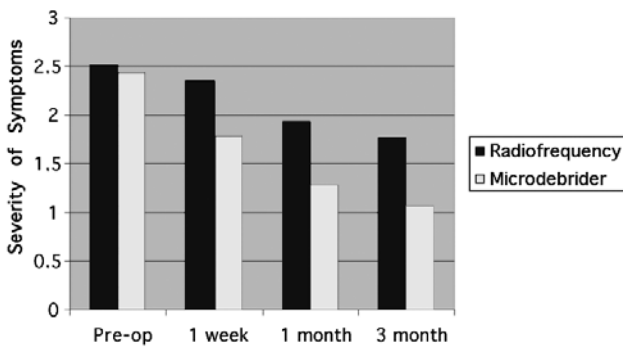


Fig. 1. Comparison of subjective mean nasal obstruction between microdebrider and radiofrequency group.

Severity of nasal discharge, headache and hyposmia grades improved significantly in the first week of the operation both in the microdebrider and radiofrequency group and persisted in the 3rd month of the operation. Intergroup comparisons did not reveal any significant differences between the two methods in the first week, the first and the third months postoperatively ($p < 0.05$). The results are summarized in Figures 2-4.

Objective symptom improvements

The mean total nasal air resistance measured with rhinomanometry, were similar in both groups prior to treatment ($p > 0.05$). The rhinomanometric measurements of the patients in the microdebrider group were found to be lower than radiofrequency applied group ($p < 0.05$) in the second measurements, which were performed 3 months after the applied procedures.

Patient satisfaction

Patient satisfaction levels as obtained from the results of the ‘‘Satisfaction with the procedure’’ questionnaire improved significantly in the first week of the operation in the microdebrider group and persisted in the 3rd month of the operation, however, a slight decrease was noted in the 12th month of the operation. Statistically significant improvement in patient satisfaction levels was only observed

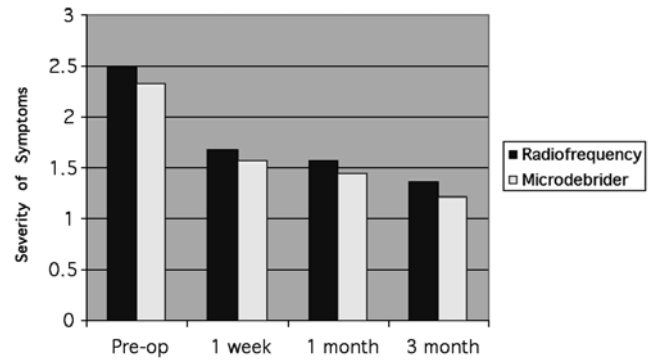


Fig. 2. Comparison of subjective mean nasal discharge between microdebrider and radiofrequency group.

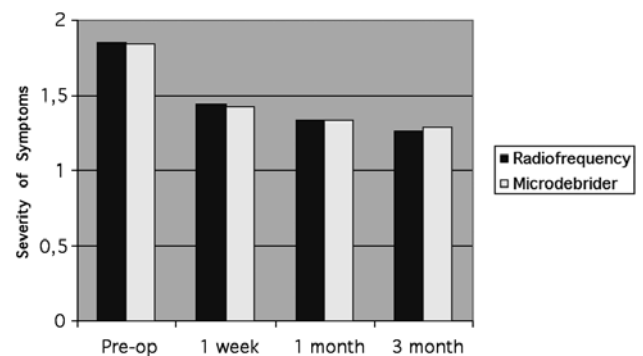


Fig. 3. Comparison of subjective mean headache complaints between microdebrider and radiofrequency group.

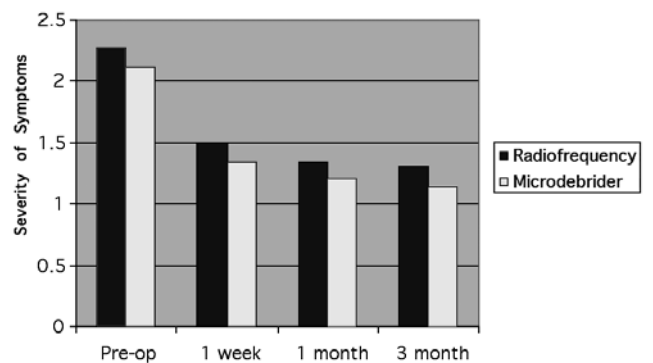


Fig. 4. Comparison of subjective hyposmia complaints between microdebrider and radiofrequency group.

in the first month of the operation in the radiofrequency group. This improvement also persisted in the 3rd month of the operation. The decrease in patient satisfaction levels was more evident in the radiofrequency group in the 12th month of the operation. ‘‘Patient satisfaction with the Procedure’’ levels improved significantly better in the microdebrider group in the first week, the first month and the third month and postoperatively compared with the radiofrequency group ($p < 0.05$). The results are summarized in Figure 5.

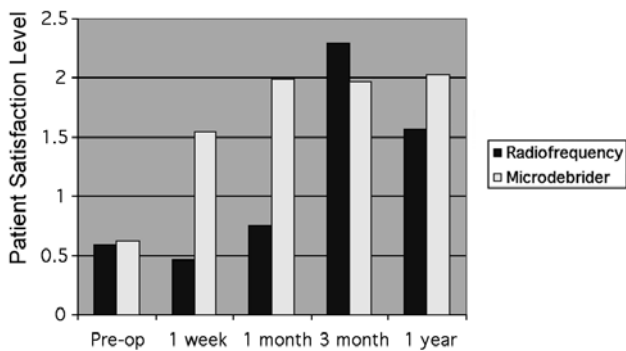


Fig. 5. Comparison of subjective patient satisfaction rates between microdebrider and radiofrequency group.

Discussion

Surgical manipulation of the inferior turbinates has been a widely used procedure for more than a 100 years to improve the nasal airway. Ranging from destructive total turbinectomy to the recently developed microdebrider assisted turbinoplasty, numerous methods have been described for this purpose. Hol et al. reviewed all these procedures and concluded that although many of the methods decrease the size of the turbinates, they also damage the mucosal functions of the turbinates thus creating a secondary cause of nasal obstruction. They therefore concluded that the preferred approach should be “infra-turbinal turbinoplasty”⁴. Two popular methods of “mucosa preserving turbinoplasty” are radiofrequency coblation and microdebrider assisted turbinoplasty. As already mentioned, radiofrequency uses thermal energy to create fibrosis, which causes a decrease in mass of the targeted tissue. Although it is a safe procedure, the desired effects are sometimes seen after a period lasting from days to weeks, because the fibrosis takes some time to shrink the tissue. A relatively recent procedure is microdebrider-assisted turbinoplasty. Although the procedure is referred to as “turbinoplasty”, some surgeons prefer partial turbinectomy, adding resection of the overlying mucosa of the turbinate tissue to the procedure⁸. While nasal obstruction decreases sufficiently, bleeding and mucosal damage are two major disadvantages related to this method. A better approach may be the “submucosal turbinoplasty”, as preferred by some surgeons, in order to preserve mucosal functions of the inferior turbinate^{3,11}. There is no general consensus among surgeons in choosing radiofrequency or microdebrider assisted turbinoplasty, due to the lack of studies comparing these two methods prevents favouring one to the other. In a recent study, Kizilkaya et al. applied radiofrequency and microdebrider-assisted turbinoplasty to 30 patients, choosing one method for one nasal passage and the other for the opposite side. They compared improvements in nasal obstruction, nasal mucociliary function and need for revision surgery for both surgical approaches and found that both methods significantly improved nasal airway pat-

ency without compromising nasal mucociliary function¹⁰. However, they did not find a statistically significant difference between radiofrequency and microdebrider-assisted turbinoplasty, as both methods resulted in a similar degree of improvement in nasal obstruction. The authors then concluded that both approaches are effective and safe methods for treatment of inferior turbinate hypertrophy¹⁰. Lee et al.¹³ treated 60 patients with inferior turbinate hypertrophy, 30 of whom were treated with radiofrequency coblation and the remaining 30 with microdebrider. They evaluated post-operative changes in the degree of nasal obstruction in the 3rd, 6th and 12th months after the procedure. Also acoustic rhinometry was performed 12 months after the operation. In contrast with the first study, after comparing the two groups, symptom improvement scores and acoustic rhinometry results were found to be significantly better in the microdebrider group⁹. Also no difference was found, in the operation time and post-operative crusting, between the two groups. In the present study, we also found that both methods successfully improve nasal airway patency. But microdebrider excels over radiofrequency in decreasing nasal obstruction and improving long-term patient satisfaction. It seems that positive effects of radiofrequency coblation, on the nasal airway, appear later than when the microdebrider method is used. However, with microdebrider turbinoplasty nasal breathing begins to improve starting from the first week after the operation. Although we were not able to perform physical examination of the nose in the first year of the operation, patients were still satisfied with the microdebrider turbinoplasty at that time, with a slight decrease in results compared with those after 3 months. On the other hand, long-term satisfaction rates in the radiofrequency group were not as high as expected. These results can probably be explained by the fact that radiofrequency assisted turbinoplasty may cause oedema in the tissue, which starts a few days after the procedure. Prolonged or latent oedema may also be the factor behind the long term decrease in patient satisfaction of the radiofrequency group, but we cannot be certain about that, as we were not able to perform physical examinations at the first year of the operation as previously pointed out. Another factor that should be borne in mind is that radiofrequency decreases the size of the inferior turbinate, facilitating fibrosis which may have a certain latency period. However, microdebrider directly removes the enlarged submucosal and bony tissue of the turbinate causing instant relief of symptoms. From this point of view, microdebrider turbinoplasty should better be compared with conventional submucosal resection. Chen et al. made this comparison in their study on 120 children and found that both methods are effective in relieving nasal obstruction caused by inferior turbinate hypertrophy. They also concluded that microdebrider turbinoplasty is superior to conventional submucosal resection with regard to preserving the nasal mucosa¹². Whenever research is conducted on evaluation of nasal obstruction, lack of objective criteria often decreases the sci-

entific value of the project. To overcome this, we employed rhinomanometry. This standardized physical examination was performed by only one author as already mentioned. Although no method is completely objective in evaluating success of the procedures, one can clearly see that the results of rhinomanometry correlate with subjective patient feedbacks. Results show that both procedures significantly decrease nasal obstruction, but microdebrider clearly excels with regard to radiofrequency as far as concerns that parameter.

Patients also reported that symptoms, like nasal discharge, hyposmia and headache, did improve after both procedures. Statistically, none of the methods resulted better than the other, both offering relief on this type of symptoms to some degree. One can clearly observe that post-operative improvements of symptoms like nasal discharge, hyposmia and headache are not as significant as the improvements in nasal obstruction. It seems these concomitant symptoms were not related to turbinate hypertrophy alone. One factor that may play a causative role in these symptoms is concomitant mucosal disease. Although we worked hard to spot rhinosinusitis, or similar mucosal diseases, before patients were included in the study, it is always possible that some cases will go unnoticed, especially if the symptoms were not clear at the time of recruitment. This "partial success" of both procedures, on symptoms like headache and hyposmia, led us hypothesize that both procedures treat the mucosa of the turbinates in a similar fashion, which disproves the com-

mon belief that radiofrequency would preserve the nasal mucosa better than microdebrider.

One last aspect that should be kept in mind while comparing these two procedures is the cost effectiveness. In countries where resources are limited, disposable radiofrequency probes cost significantly more. However, one microdebrider blade can be used for several patients, increasing the cost effectiveness of the procedure. Kizilkaya et al. also mentioned the same aspect in their study¹⁰.

Conclusions

Previous studies comparing radiofrequency and microdebrider turbinoplasty stated that the lack of prospective studies, with large patient groups, did not yield useful results to decide which procedure is better than the other. We designed a five-year study with a large patient group. To our knowledge, this study has the largest series of patients, making it unique among others.

Both radiofrequency and microdebrider turbinoplasty are efficient methods for relieving nasal obstruction related to inferior turbinate hypertrophy. Both procedures have similar complication rates. However, microdebrider should be preferred, if available, not only because it is cost effective, but also because subjective and objective nasal obstruction improvement, in the microdebrider group, has been proven to be better than that in the radiofrequency group, both in the short- and the long-term.

References

- Jackson LE, Koch RJ. *Controversies in the management of inferior turbinate hypertrophy: a comprehensive review*. Plast Reconstr Surg 1999;103:300-12.
- Passali D, Lauriello M, Anselmi M, et al. *Treatment of hypertrophy of the inferior turbinate: long-term results in 382 patients randomly assigned to therapy*. Ann Otol Rhinol Laryngol 1999;108:569-75.
- Friedman M, Tanyeri H, Lim J, et al. *A safe, alternative technique for inferior turbinate reduction*. Laryngoscope 1999;109:1834-7.
- Hol MK, Huizing EH. *Treatment of inferior turbinate pathology: a review and critical evaluation of the different techniques*. Rhinology 2000;38:157-66.
- Coste A, Yona L, Blumen M, et al. *Radiofrequency is a safe and effective treatment of turbinate hypertrophy*. Laryngoscope 2001;111:894-9.
- Nease CJ, Krempel GA. *Radiofrequency treatment of turbinate hypertrophy: a randomized, blinded, placebo-controlled clinical trial*. Otolaryngol Head Neck Surg 2004;130:291-9.
- Van delden MR, Cook PR, Davis WE. *Endoscopic partial inferior turbinoplasty*. Otolaryngol Head Neck Surg 1999;121:406-9.
- Gupta A, Mercurio E, Bielamowicz S. *Endoscopic inferior turbinate reduction: an outcomes analysis*. Laryngoscope 2001;111:1957-9.
- Lee JY, Lee JD. *Comparative study on the long-term effectiveness between coblation- and microdebrider-assisted partial turbinoplasty*. Laryngoscope 2006;116:729-34.
- Kizilkaya Z, Ceylan K, Emir H, et al. *Comparison of radiofrequency tissue volume reduction and submucosal resection with microdebrider in inferior turbinate hypertrophy*. Otolaryngol Head Neck Surg 2008;138:176-81.
- Lee CF, Chen TA. *Power microdebrider-assisted modification of endoscopic inferior turbinoplasty: a preliminary report*. Chang Gung Med J 2004;27:359-65.
- Chen YL, Liu CM, Huang HM. *Comparison of microdebrider-assisted inferior turbinoplasty and submucosal resection for children with hypertrophic inferior turbinates*. Int J Pediatr Otorhinolaryngol 2007;71:921-7.

Received: November 11, 2009 - Accepted: April 19, 2010

Address for correspondence: Prof. C. Cingi, Department of Otorhinolaryngology, Eskisehir Osmangazi University, Eskisehir, Turkey.
E-mail: ccingi@ogu.edu.tr