

## CASE REPORT

# Laryngeal adenoid cystic carcinoma

## *Carcinoma adenoidocistico della laringe*

E. ZVRKO, M. GOLUBOVIĆ<sup>1</sup>Clinic for Otorhinolaryngology and Maxillofacial Surgery; <sup>1</sup> Center for Pathology, Clinical center of Montenegro, Podgorica, Montenegro

## SUMMARY

Adenoid cystic carcinomas are malignant tumours and occur in the major and the minor salivary glands. Laryngeal adenoid cystic carcinomas are rare and account for less than 1% of all malignant tumours in the larynx. Adenoid cystic carcinoma is characterised by slow progression, multiple recurrences and late distant metastasis. The aetiology of adenoid cystic carcinoma remains unknown. They usually originate in the supraglottic or subglottic area. Wide-margin surgery alone or in combination with post-operative radiotherapy is the best tumour management. In this article, the case of laryngeal adenoid cystic carcinoma is described in a 55-year-old male patient who presented with a 3-month history of prelaryngeal pain. The patient underwent total laryngectomy and post-operative radiotherapy. For patients with laryngeal adenoid cystic carcinomas, regular and long-term follow-up is mandatory, in order to detect relapses and metastases.

KEY WORDS: Larynx • Malignant tumours • Adenoid cystic carcinoma • Laryngectomy

## RIASSUNTO

*I carcinomi adenoidocistici sono tumori maligni delle ghiandole salivari maggiori e minori. I carcinomi adenoidocistici della laringe sono rari e rappresentano circa l'1% di tutti i tumori maligni della laringe. Il carcinoma adenoidocistico è caratterizzato da una crescita lenta, da ricorrenze multiple e frequenti metastasi a distanza. L'eziologia di questo tumore è a tutt'oggi sconosciuta. In genere la sede di origine è rappresentata dalla regione sopra o sottoglottica. L'ampia asportazione chirurgica da sola o associata a radioterapia post-operatoria rappresenta il trattamento di scelta di questi tumori. In questo articolo presentiamo un caso di carcinoma adenoidocistico della laringe in un uomo di 55 anni che presentava da circa 3 mesi dolore localizzato alla laringe. Il paziente è stato sottoposto a laringectomia totale e a radioterapia post-operatoria. Per i pazienti affetti da carcinomi adenoidocistici della laringe, è necessario un follow-up lungo e regolare, finalizzato alla diagnosi precoce di eventuali recidive o metastasi a distanza.*

PAROLE CHIAVE: Laringe • Tumori maligni • Carcinoma adenoidocistico • Laringectomia totale

Acta Otorhinolaryngol Ital 2009;29:279-282

## Introduction

Squamous cell carcinoma accounts for about 99% of laryngeal malignancies. Non-epidermoid malignancies of the larynx include sarcoma, lymphoma, and salivary gland carcinoma. Salivary gland carcinomas of the larynx are rare, and account for < 1% of laryngeal malignancy<sup>1,2</sup>.

Minor salivary glands are found in various locations, extending from the paranasal sinuses to the larynx. Minor salivary gland tumours are most commonly located in the oral cavity, particularly the hard palate, and less commonly in the nasal cavity, paranasal sinuses, pharynx, and larynx. In contrast to major salivary gland tumours, which are mainly benign, minor salivary gland tumours are more usually malignant.

Adenoid cystic carcinomas, previously known as cylindromas, are the most common malignant tumours that

occur in minor salivary glands. Most tumours present supraglottic or subglottic involvement, possibly because the distribution density of subepithelial glands is higher in the supraglottic and subglottic areas than in the glottic area. Two-thirds of these laryngeal tumours occur in the subglottis<sup>3</sup>; however, they also occur in the supraglottis in the false cords, aryepiglottic folds<sup>4</sup>, and caudal aspect of the epiglottis. In the glottis, they are located in the floor of the sinus of Morgagni and subglottic surface of the anterior commissure.

The aetiology of adenoid cystic carcinomas remains unknown. These tumours are found mainly in the fifth and sixth decades of life with a slight female predominance<sup>5</sup>. Adenoid cystic carcinomas arise from subepithelial glands<sup>1,6</sup> and most commonly present as submucosal masses. Because they spread in a submucosal fashion, they are difficult to detect earlier. This explains why most

patients were diagnosed late, at the advanced stage. They tend to spread by perineural extension and frequently recur after initial treatment. Neck metastasis is rare. The most frequent site of distant metastasis is the lung.

## Case report

A 55-year-old male, non-smoker, was referred to our Clinic with a 3-month history of pre-laryngeal pain. The patient had no history of dyspnoea, hoarseness, dysphagia or cough. The patient's medical history included gastro-oesophageal reflux.

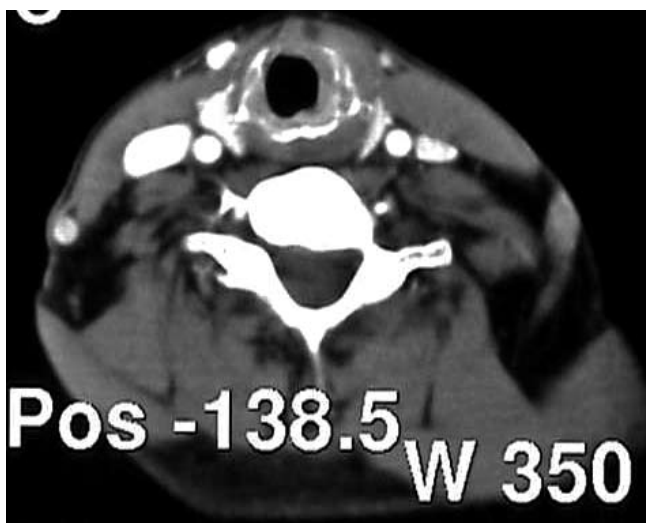
Indirect laryngoscopy detected the anterior left para-median sub-glottic sub-mucosal tumour mass which measured 8 mm in its maximum diameter. The laryngeal mucosa was intact and there was no necrosis in the laryngeal mucosa. The glottic and supra-glottic areas showed a normal appearance. There was no impairment of the laryngeal motion. On physical examination, the patient had no palpable neck mass or lymphadenopathy.

The patient underwent computerized tomography (CT) of the neck with contrast medium which showed the presence of a sub-mucosal mass in the left sub-glottic area which had extended through the thyroid cartilage into the extra-laryngeal soft tissues on the left side of the neck (Fig. 1). Neither the physical examination nor neck CT detected any evidence of node involvement. The findings on chest X-ray were normal.

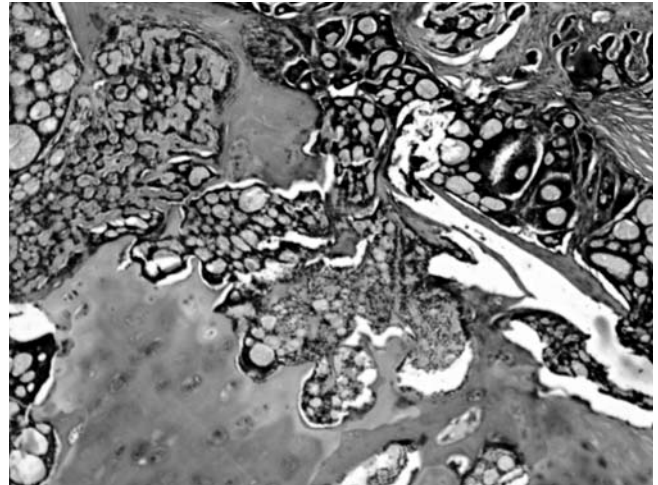
During direct microlaryngoscopy, a biopsy was taken from the tumour and the pathologist reported that the specimen had a cribriform pattern and was consistent with an adenoid cystic carcinoma.

The patient underwent total laryngectomy and isthmectomy without neck dissection. The surgical margins were free of tumour.

The final pathology report showed negative margins. Specimen showed intra-luminal (sub-mucosal) and extra-



**Fig. 1.** CT scan of larynx showing subglottic submucosal mass and destruction at left side of thyroid cartilage.



**Fig. 2.** Histological section of laryngeal adenoid cystic carcinoma (100 x magn., H&E staining).

luminal tumour growth with involvement of thyroid cartilage and muscular invasion (Fig. 2). Although there was no lymphatic spreading, perineural invasion (which is a feature of adenoid cystic carcinoma) was present.

Ten days post-operatively, the patient was discharged. Since this patient had a large tumour with perineural invasion, he was scheduled for adjuvant radiotherapy. At 6-months' follow-up, there was no evidence of recurrence or metastasis.

## Discussion

Minor salivary gland tumours of the larynx are rare and constitute less than 1% of laryngeal tumours. They are usually malignant and the most common type is adenoid cystic carcinoma. This tumour is characterised by slow progression, multiple recurrences and late distant metastasis.

There are no distinct risk factors that predispose patients to this malignancy<sup>5</sup>. Smoking does not affect the incidence. Unlike squamous cell carcinoma, for which more than 90% of patients are smokers, only of patients with minor salivary gland tumours are smokers.

According to Dexemble et al.<sup>3</sup>, 64% of laryngeal adenoid cystic carcinomas occur in the sub-glottis, 25% in the supra-glottis, 5% in the glottis and 6% in the transglottic area.

The signs and symptoms of laryngeal adenoid cystic carcinoma are related to location and size. Tumours of the supra-glottis present with dysphagia. Hoarseness or even dyspnoea is indicative of glottic involvement. Stridor and airway obstruction are more frequently associated with sub-glottic tumours. However, usually, adenoid cystic carcinoma occurs as a large asymptomatic, non-ulcerated sub-mucosal mass. As a result, diagnosis is often delayed and, in the larynx, sub-glottic tumours have the opportunity to invade deeply before they are diagnosed. Our observation that pre-laryngeal pain was the only symptom

in a patient with advanced adenoid cystic carcinoma is an important point to make.

Pre-operative histo-pathological analysis is essential because the symptoms do not differ greatly from squamous cell carcinoma. The histo-pathological pattern of adenoid cystic carcinoma is classified into three distinct subtypes: cribriform, which is the most common; tubular, which has the best prognosis; and solid, which carries the worst prognosis<sup>5</sup>. In our case, adenoid cystic carcinoma contained sheets of small uniform cells arranged in a classic cribriform growth pattern.

Accurate pre-operative mapping and staging are essential. CT is a very useful imaging procedure in adenoid cystic carcinoma. It is highly valuable in the assessment of primary tumour location, extra-luminal extension, regional and distant metastases. It is, therefore, recommended in the pre-operative evaluation. Albeit, CT can underestimate the extent of the tumour because adenoid cystic carcinoma may grow sub-mucosally without producing a distinct mass. In our case, CT with contrast medium showed the presence of a sub-mucosal mass in the left sub-glottic area with extension through the thyroid cartilage into the extra-laryngeal soft tissues on the left side of the neck. Also, these findings correlated with the histopathologic findings in this patient.

The treatment options of laryngeal adenoid cystic carcinoma are still controversial. Surgery with or without post-operative radiotherapy remains the mainstay treatment modality of laryngeal salivary gland carcinomas. Partial laryngectomy is possible in selected patients with small, well-defined tumours and negative surgical resection margins<sup>7</sup>. Because of the risk of sub-mucosal spread and peri-neural and lympho-vascular invasion, total laryngectomy is often required and most Authors agree that the treatment of choice is wide-margin local excision<sup>3</sup>. In the absence of neck metastasis, elective neck dissection is not recommended<sup>8-11</sup>. Neck dissection should be performed in patients who have clinically or histologically confirmed node metastases<sup>3,5,12</sup>.

Radiotherapy alone usually has a minor role in treatment<sup>12</sup>. These tumours have been shown to be radiosensitive but are not usually radiocurable. Therefore, the role of radiotherapy is still open to debate. It may be useful as

an adjuvant modality for adenoid cystic carcinoma with positive surgical margins, perineural spread or high-grade tumours.

Chemotherapy may be useful as adjuvant therapy for high-grade lesions, either in conjunction with surgery to prevent distant metastases or with radiotherapy as palliation for patients with distant metastases at initial presentation. However, in unresectable tumours or those with local recurrence after surgery, no efficient treatment strategy has been developed.

Known clinicopathological factors with an unfavourable effect on survival, in adenoid cystic carcinoma, include old age, advanced stage, solid histological subtype, high grade, major nerve involvement and the presence of perineural invasion or a positive surgical margin. The five-year survival rates for patients with laryngeal adenoid cystic carcinoma have been reported to range from only 12-17%<sup>3,12</sup>. Regular close and long-term follow-up is mandatory, in order to detect relapses and metastases. Since early perineural and haematological spread is common, local recurrences and distant metastases are common and sometimes occur years after the primary tumour has been diagnosed and treated. Distant metastases may occur in the lungs, liver, abdomen, lymph nodes, and bones.

## Conclusions

Laryngeal salivary gland carcinomas are rare and account for < 1% of laryngeal malignancies. Therefore, a high degree of suspicion is essential for early diagnosis. This tumour must be considered when aggressive laryngeal tumours are found, especially if the patient is not at risk for squamous cell carcinomas. They usually originate in the supra-glottic or sub-glottic area with a predominance of old age. Most patients are diagnosed late, at an advanced stage. CT can be used to assess tumour extent and growth patterns. Wide-margin surgery alone or in combination with post-operative radiotherapy for advanced lesions that present peri-neural spread or close or positive margins is the best tumour management. For these patients, regular and long-term follow-up is mandatory, in order to detect relapses and metastases.

## References

- Batsakis JG, Luna MA, El-Naggar AK. *Nonsquamous carcinomas of the larynx*. Ann Otol Rhinol Laryngol 1992;101:1024-6.
- Wang MC, Liu CY, Li WY, Chang SY, Chu PY. *Salivary gland carcinoma of the larynx*. J Chin Med Assoc 2006;69:322-5.
- Dexemble P, Huth J, Rebufy M, Chabrol A. *Carcinome adénoïde kystique du larynx. A propos de deux cas*. Ann Otolaryngol Chir Cervicofac 2003;120:244-8.
- de Kerviler E, Bely N, Laccourreye O, Clément O, Halimi P, Fria G. *The aryepiglottic fold as a rare location of adenoid cystic carcinoma*. AJNR Am J Neuroradiol 1995;16:1375-7.
- Tincani AJ, Del Negro A, Araújo PP, Akashi HK, Martins AS, Altemani AM, et al. *Management of salivary gland adenoid cystic carcinoma: institutional experience of a case series*. Sao Paulo Med J 2006;124:26-30.
- Spiro RH, Koss LG, Hajdu SI, Strong EW. *Tumors of minor salivary origin. A clinicopathologic study of 492 cases*. Cancer 1973;31:117-29.

- <sup>7</sup> Ganly I, Patel SG, Coleman M, Ghossein R, Carlson D, Shah JP. *Malignant minor salivary gland tumors of the larynx*. Arch Otolaryngol Head Neck Surg 2006;132:767-70.
- <sup>8</sup> Alavi S, Calcaterra TC, Namazie A, Blackwell KE. *Glandular carcinoma of the larynx: the UCLA experience*. Ann Otol Rhinol Laryngol 1999;108:485-9.
- <sup>9</sup> Browne JD. *Management of the nonepidermoid cancer of the larynx*. Otolaryngol Clin North Am 1997;30:215-29.
- <sup>10</sup> Veivers D, Vito AD, Luna-Ortiz K, Brasnu D, Laccourreye O. *Supracricoid partial laryngectomy for non-squamous cell carcinoma of the larynx*. J Laryngol Otol 2001;115:388-92.
- <sup>11</sup> Ferlito A, Barnes L, Myers EN. *Neck dissection for laryngeal adenoid cystic carcinoma: is it indicated?* Ann Otol Rhinol Laryngol 1990;99:277-80.
- <sup>12</sup> Olofsson J, van Nostrand AW. *Adenoid cystic carcinoma of the larynx: a report of four cases and a review of the literature*. Cancer 1977;40:1307-13.

Received: October 18, 2008 - Accepted: January 23, 2009