

CASE REPORT

# Lingual thyroid causing dysphagia and dyspnoea. Case reports and review of the literature

## *Tiroide ectopica linguale che provoca disfagia e dispnea: casi clinici e revisione della letteratura*

A. TOSO, F. COLOMBANI<sup>1</sup>, G. AVERONO, P. ALUFFI, F. PIA

Otorhinolaryngology Clinic, Piemonte Orientale University, Novara; <sup>1</sup>Otorhinolaryngology Unit, Infermi Hospital, Biella, Italy

### SUMMARY

Lingual thyroid is a rare embryological anomaly and originates from failure of the thyroid gland to descend from the foramen caecum to its normal eutopic pre-laryngeal site. The ectopic gland located at the base of the tongue is often asymptomatic but may cause local symptoms such as dysphagia, dysphonia with stomatolalia, upper airway obstruction and haemorrhage, often with hypothyroidism. Two cases are presented, one in a 62-year-old female and the other in a 42-year-old female, both of whom complained of sensation of a foreign body and progressive dysphagia and dyspnoea caused by ectopic lingual thyroid. Treatment was performed with a partial endoscopic removal and an external cervical approach, followed by substitutive hormone treatment, respectively. Diagnostic procedures and therapeutic options are discussed and a review has been made of reports of lingual thyroid appearing in the literature.

KEY WORDS: Ectopic thyroid • Lingual thyroid • Dysphagia • Dyspnoea

### RIASSUNTO

*La tiroide ectopica a livello della base lingua è una patologia poco frequente e deriva dalla mancata discesa della ghiandola tiroide dal forame cieco della base della lingua alla sua sede definitiva. Tale condizione è generalmente asintomatica ma può determinare l'insorgenza di disturbi locali quali disfagia, stomatolalia, sensazione di corpo estraneo ed in alcuni casi emorragia, spesso associati ad ipotiroidismo. Descriviamo i casi di due donne di 62 e 42 anni che si sono presentate alla nostra osservazione per una sensazione di corpo estraneo faringeo accompagnato da disfagia e dispnea, soprattutto notturna. Le due pazienti sono state sottoposte a due differenti tipi di intervento chirurgico mediante ablazione parziale per via trans orale e approccio esterno per via faringotomica mediana previa tracheotomia, con successivo trattamento ormonale sostitutivo. Vengono discusse le procedure diagnostiche e terapeutiche con revisione della letteratura.*

PAROLE CHIAVE: Tiroide ectopica • Tiroide linguale • Disfagia • Dispnea

Acta Otorhinolaryngol Ital 2009;29:213-217

### Introduction

Lingual thyroid is a rare developmental anomaly originating from aberrant embryogenesis during the passage of the thyroid gland through the neck. Embryonic development begins about 24 days after fertilization in the floor of the primitive hypopharynx from median endodermal thickening, then the primitive gland descends closely related to the hyoid bone and laryngeal cartilages<sup>1</sup>. The thyroglossal duct is a narrow tube connecting the developing thyroid gland to the tongue and it usually involutes at the sixth or eighth week. The foramen caecum is the opening of the thyroglossal duct in the tongue. The thyroid gland then descends to meet the lateral ultimo-branchial bodies; the fusion of these elements leads to the formation of the functional and

mature thyroid gland by the third foetal month<sup>2</sup>. Lingual thyroid is the most frequent ectopic location of the thyroid gland, although its prevalence varies between 1:100000 and 1:300000 and its clinical incidence is reported to range from 1:4000 to 1:10000. The true incidence is probably underestimated: some Authors reported having found ectopic lingual tissue in 10% of 200 consecutive necropsies<sup>3</sup>. In the literature, approximately 400 cases of symptomatic patients have been reported<sup>1,4</sup>. Ectopic thyroid tissue can also occur between the geniohyoid and mylohyoid muscles (sublingual thyroid), above the hyoid bone (pre-laryngeal thyroid) and in other rare sites such as the mediastinum, precardial sac, heart, breast, pharynx, oesophagus, trachea, lung, duodenum and mesentery of the small intestine, adrenal gland<sup>5-9</sup>.

### Case 1

A 62-year-old female presented with a mass in the tongue base which had been present for many years with the sensation of a foreign body and stomatolalia. The patient also referred to having dysphagia to solid food and dyspnoea, especially at night.

She had no history of either past or present thyroid disease. She had a history of diabetes mellitus and Parkinson's disease.

Upon examination, the patient presented a solid, pink, spherical mass, covered with intact mucosa, located at the base of the tongue, obstructing the visualisation of the larynx.

Examination of the neck revealed no palpable thyroid gland in the normal pre-tracheal position and no cervical adenopathy. Thyroid hormone tests showed elevated thyroid-stimulating hormone (TSH) concentrations and normal FT3 and FT4 concentrations. Ultrasonography (US) and computed tomography (CT) revealed a mass, 41 x 36 x 47 mm in size with distinct margins restricted to the base of the tongue and absence of the thyroid gland (Fig. 1). A thyroid scan with technetium Tc-99m sodium was performed showing marked isotope uptake in the area of the tongue and no uptake in the neck.

Surgical excision of the mass by an external neck procedure or, if possible, by an endoscopic approach was proposed and the patient accepted the endoscopic procedure as first option.

A standard micro-laryngoscopic surgical procedure was performed using a bivalve Weerda-type laryngoscope and a Zeiss microscope. The prominent part of the lingual thyroid was removed trans-orally, using cold instruments and

monopolar coagulation in order to achieve a sufficient airway space. Due to diffuse bleeding, oropharyngeal packing was left in situ and naso-tracheal intubation was maintained for the first 24 hours. The packing was removed on the first day after surgery and the post-operative course was uneventful. The histo-pathological examination revealed ectopic thyroid tissue. By the fifth post-operative day, soft oral feeding was commenced and the patient was discharged.

Substitutive hormone therapy was started in order to maintain the euthyroid state.

At the time of preparing this report, the patient had remained well with no recurrence of the mass or symptoms for over 31 months.

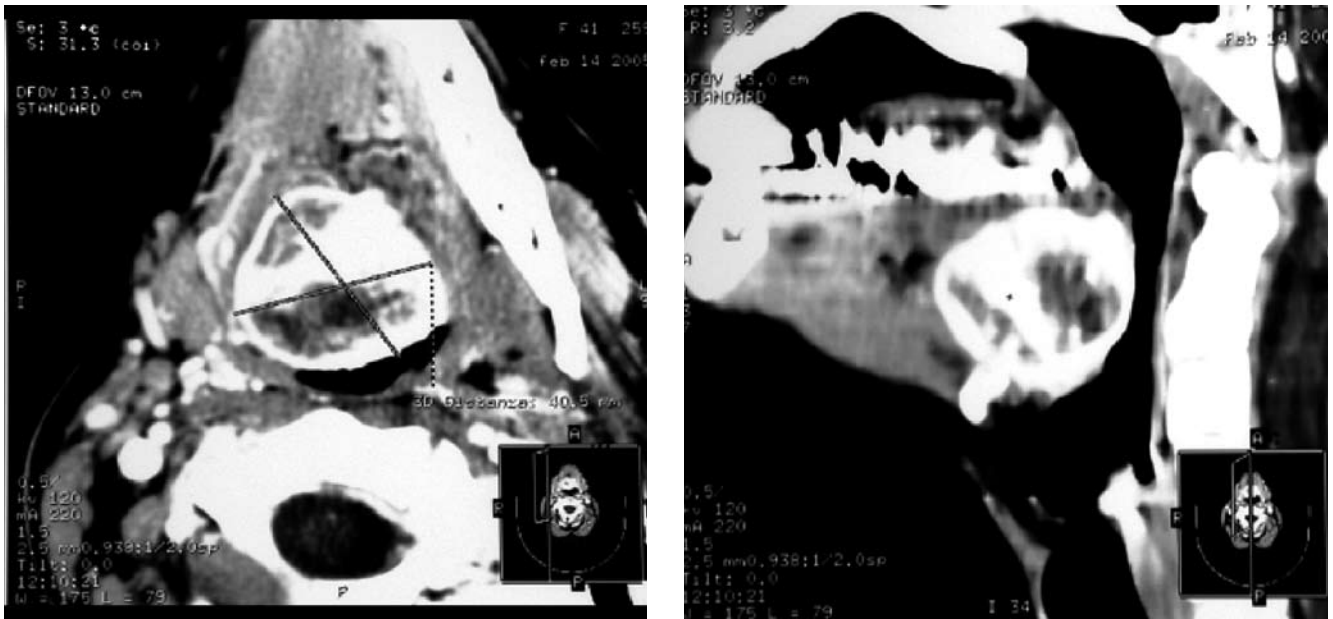
### Case 2

A 42-year-old female was referred to our Department on account of an oro-pharyngeal mass which had appeared 3 months previously. A solid, sessile hyperaemic mass measuring 4 cm in diameter and occupying the oropharynx arising at the base of the tongue was revealed upon clinical examination and using fibre-optic nasopharyngoscopy, in the absence of laryngeal obstruction.

Serum FT3, FT4 and TSH levels were in the normal range. No other pathological findings were detected upon clinical examination. The mass was evaluated by US, CT and scintigraphy. In the cervical US examination, the mass was well defined and heterogeneous/hypoechoogeneous. The thyroid gland was not in the expected cervical location. In addition, CT revealed aberrant thyroid tissue as a high density mass in the region of the tongue.

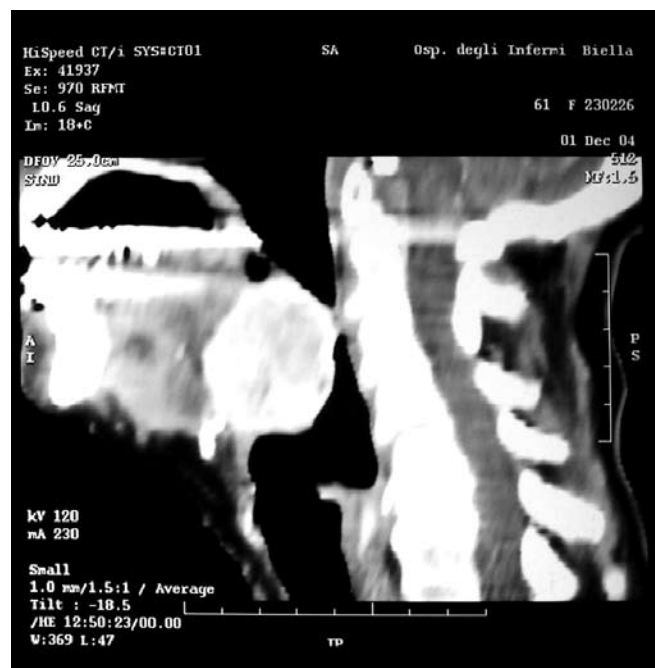
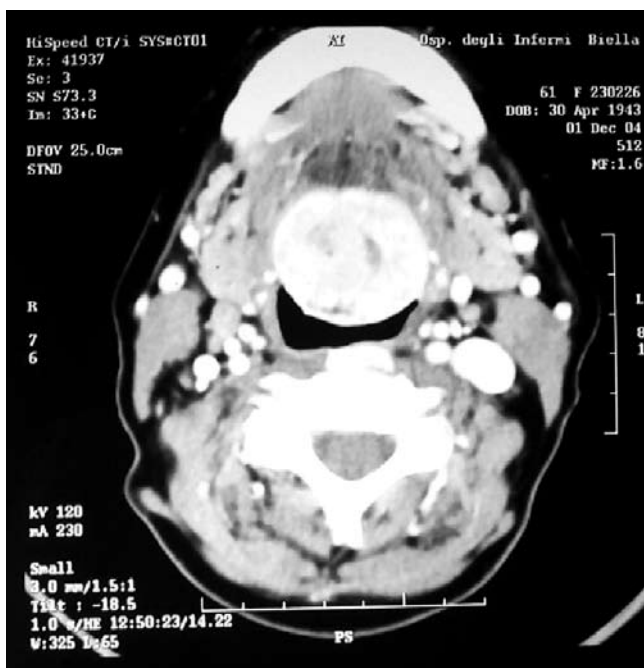
Fig. 1. CT scan with i.v. contrast showing a well-defined mass 41 x 36 x 47 mm in size (Case 1) and with distinct margins localized at base of tongue.



**Fig. 2.** CT scan shows aberrant thyroid tissue as a high density mass in region of tongue (Case 2). Following i.v. injection of iodine material, mass showed homogeneous contrast enhancement.

After intravenous injection of iodine material, the mass showed homogenous contrast enhancement (Fig. 2). Thyroid scintigraphy showed an uptake region at the base of the tongue, representing a lingual thyroid. There was no thyroid uptake in the usual site in the neck.

In this case, an external approach was used, with transhyoid median pharyngotomy: the patient was placed in a supine position with head extended. A 4 cm transverse midline incision was made in the neck under the hyoid bone. The hyoid bone and the suprahyoid muscles were exposed, and the infra-hyoid muscles were freed and retracted. An incision was made in the pharyngeal mucosa and the oro-pharynx was entered. The mass, which could then be visualized at the base of the tongue, was dissected with an undermucosa approach and excised. The tongue wound was sutured in 2 layers, and the pharyngeal opening and the neck incision were closed in 3 layers. A nasogastric tube was introduced for feeding for 9 days. A temporary tracheotomy was performed in order to protect the upper airways: the trachestoma was removed after 9 days. All excised specimens were sent for microscopic examination and were reported as lingual thyroid.

On the 13<sup>th</sup> post-operative day, the patient was discharged and substitutive hormone therapy was commenced to maintain the euthyroid state.

At a 23-month follow-up control, there was no evidence of disease with normal lingual mucosa and no residual uptake was discovered upon thyroid scintigraphy.

## Discussion

Ectopic thyroid is a rare embryological aberration which can occur in any moment of the migration of the thyroid

resulting in lingual (at tongue base), sublingual (below the tongue), prelaryngeal (in front of the larynx), and substernal (in the mediastinum) ectopy. Dual ectopic thyroid has been described<sup>110</sup>, even with the thyroid gland in a normal location<sup>11</sup>.

It occurs more frequently in females, with a female to male ratio 4:1; ectopic thyroid is seen at any age but more commonly during childhood, adolescence and around menopause. This probably occurs when demands for thyroid hormones increase, causing the increase in circulating TSH levels with growth of the ectopic thyroid tissue<sup>612</sup>. About 33-62% of all patients with ectopic thyroid showed hypothyroidism with increased levels of TSH<sup>513</sup>.

Most ectopic thyroids are asymptomatic and no therapy is necessary. Symptoms are related to the growth of the thyroid tissue, causing dysphagia, dysphonia with stomatolalia, bleeding or dyspnoea<sup>41415</sup>. The enlarged lingual thyroid has been described as a cause of difficult intubation during induction of anaesthesia, especially for bleeding<sup>1014</sup>.

Clinically, lingual thyroid presents as a mass at the base of the tongue, pink and firm. The most important diagnostic tool is thyroid scan with technetium Tc-99m sodium, but US, CT and magnetic resonance imaging (MRI) may help in defining the extension and location of the ectopic thyroid gland. Thyroid scan can also reveal whether there are other sites of thyroid tissue; in approximately 75% of patients the ectopic tissue is the only functioning thyroid tissue in the body<sup>16</sup>. Therefore, it is important to observe the patient at follow-up, being aware of the risk of post-operative hypothyroidism. Differential diagnosis includes lymphangioma, minor salivary gland tumours, midline branchial cysts, thyroglossal duct cysts, epider-

mal and sebaceous cysts, angioma, adenoma, fibroma and lipoma<sup>5 10</sup>.

Management of lingual thyroid is still controversial. No treatment is required when the lingual thyroid is asymptomatic and the patient is in an euthyroid state; the patient has to be followed to be aware of development of complications. Malignant transformation has been described<sup>17-24</sup> and, for this reason, some Authors consider complete surgical removal of the gland as appropriate treatment<sup>17 24</sup>. For patients with no, or only mild, clinical symptoms and elevated TSH concentration, substitutive therapy with thyroid hormone may be successful, producing a slow reduction of the mass.

Ablative radioiodine therapy is an alternative approach recommended in older patients or patients who are deemed unfit for surgery. This treatment should be avoided in children and young adults since the systemic doses required have potentially damaging effects on the gonads or other organs<sup>25</sup>. Moreover, the thyroid tissue is often hypoactive and the dose of radioiodine required is generally high<sup>26</sup>.

When medical therapy fails, and in symptomatic or complicated cases, surgery is the treatment of choice. In the literature, several surgical approaches have been described, including surgical removal of the mass with external approaches, such as by trans-hyoid or lateral pharyngotomy, or performing trans-oral ablation of the mass. The trans-oral approach seems to avoid injury to the deep neck structures with possible complications (such as injury of the lingual nerve, fistula formation, deep cervical infection and visible scar) and should be considered as possible treatment for a small mass, while external approaches with temporary tracheotomy can probably better control bleeding and are recommended for bulky masses.

For the trans-oral approach, cold instruments with monopolar coagulation and laser CO<sub>2</sub> have been used<sup>14 27</sup> and laser diode can also be useful.

The possibility that the ectopic thyroid tissue could be the only functioning tissue must be considered; in those cases, transplantation of the excised ectopic tissue is recommended, by some Authors, in order to avoid permanent hypothyroidism<sup>4</sup>. In alternative, substitutive hormone treatment could be started to preserve the euthyroid state. Transplantation is not necessary in cases of partial surgical eradication, while substitutive therapy could be necessary to preserve euthyroid state and avoid recurrence of the mass. In our opinion, the general conditions of the pa-

tient, the size of the lesion and presence of local symptoms or complications, such as haemorrhage, cystic degeneration or malignancies, are the most important conditions for planning the choice of treatment. In symptomatic, older patients, unfit to undergo more aggressive surgical approaches, or in small and anterior lesions, partial trans-oral ablation could be recommended; the partial trans-oral approach is less aggressive but cannot prevent malignant transformation and possible relapse, moreover allows less control as far as concerns bleeding during surgery.

In younger patients, or in the case of large lesions or lesions deeply located in the caudal part of the base of the tongue, total ablation could be the most appropriate choice: in this case, transplantation of the thyroid tissue is, in our opinion, not necessary while substitutive hormone treatment is recommended as following other radical surgical approaches for normal thyroid gland.

Special care should be taken to ensure airway patency; this can usually be achieved by temporary tracheostomy or maintaining the naso-tracheal tube for the first 24 hours after surgery. Tracheostomy or intubation should not be removed until haemostasis and airway patency have been confirmed.

In trans-oral approaches, soft diet is usually tolerated sooner than in external approaches<sup>14 14</sup>.

## Conclusions

Lingual ectopic thyroid is a rare developmental anomaly, the treatment of which is still controversial on account of the rarity of the condition. Treatment could be conservative with substitutive hormone treatment in patients with mild symptoms, while surgery is recommended in cases with airway obstruction. Evaluation of thyroid function is recommended before and after surgery due to the risk of post-operative hypothyroidism.

When complications such as dysphagia or dyspnoea occur, surgery is necessary: the trans-oral approach can be useful, in selected cases (older patients or anterior and small masses), while in younger patients, usually the external approach is the best choice due to the risk of malignant transformation, relapse and for better bleeding control. Transplantation is not recommended, but substitutive hormone treatment is often needed.

Follow-up is recommended to monitor possible recurrence or complications.

## References

- <sup>1</sup> Ulug T, Ulubil SA, Alagol F. *Dual ectopic thyroid: report of a case*. J Laryngol Otol 2003;117:574-6.
- <sup>2</sup> Chanin LR, Greenberg LM. *Pediatric upper airway obstruction due to ectopic thyroid: classification and case reports*. Laryngoscope 1988;98:422-7.
- <sup>3</sup> Sauk JJ. *Ectopic lingual thyroid*. J Pathol 1970;102:239-43.
- <sup>4</sup> Gallo A, Leonetti F, Torri E, Manciooco V, Simonelli M, DeVincentiis M. *Ectopic lingual thyroid as unusual cause of severe dysphagia*. Dysphagia 2001;16:220-3.
- <sup>5</sup> Di Benedetto V. *Ectopic thyroid gland in the submandibular region simulating a thyroglossal duct cyst: a case report*. J Pediatr Surg 1997;32:1745-6.



- <sup>6</sup> Kumar R, Sharma S, Marwah A, Moorthy D, Dhanwal D, Malhotra A. *Ectopic goiter masquerading as submandibular gland swelling: a case report and review of the literature.* Clin Nucl Med 2001;26:306-9.
- <sup>7</sup> Pollice L, Caruso G. *Struma cordis. Ectopic thyroid goiter in the right ventricle.* Arch Pathol Lab Med 1986;110:452-3.
- <sup>8</sup> Porqueddu M, Antona C, Polvani G, Cavoretto D, Pompilio G, Gianolli L, et al. *Ectopic thyroid tissue in the ventricular outflow tract: embryologic implications.* Cardiology 1995;86:524-6.
- <sup>9</sup> Ferlito A, Giarelli L, Silvestri F. *Intratracheal thyroid.* J Laryngol Otol 1988;102:95-6.
- <sup>10</sup> Hazarika P, Siddiqui SA, Pujary K, Shah P, Nayak DR, Balakrishnan R. *Dual ectopic thyroid: a report of two cases.* J Laryngol Otol 1998;112:393-5.
- <sup>11</sup> Huang TS, Chen HY. *Dual thyroid ectopia with a normally located pretracheal thyroid gland: case report and literature review.* Head Neck 2007;29:885-8.
- <sup>12</sup> Steinwald OP Jr, Muehrcke RC, Economou SG. *Surgical correction of complete lingual ectopia of the thyroid gland.* Surg Clin North Am 1970;50:1177-86.
- <sup>13</sup> Yoon JS, Won KC, Cho IH, Lee JT, Lee HW. *Clinical characteristics of ectopic thyroid in Korea.* Thyroid 2007;17:1117-21.
- <sup>14</sup> Hafidh MA, Sheahan P, Khan NA, Colreavy M, Timon C. *Role of CO<sub>2</sub> laser in the management of obstructive ectopic lingual thyroids.* J Laryngol Otol 2004;118:807-9.
- <sup>15</sup> Mussak EN, Kacker A. *Surgical and medical management of midline ectopic thyroid.* Otolaryngol Head Neck Surg 2007;136:870-2.
- <sup>16</sup> Baik SH, Choi JH, Lee HM. *Dual ectopic thyroid.* Eur Arch Otorhinolaryngol 2002;259:105-7.
- <sup>17</sup> Galizia G, Lieto E, Ferrara A, Castellano P, Pelosio L, Imperatore V, et al. *Ectopic thyroid: report of a case.* G Chir 2001;22:85-8.
- <sup>18</sup> Falvo L, Berni A, Catania A, D'Andrea V, Palermo S, Giustiniani C, et al. *Sclerosing papillary carcinoma arising in a lingual thyroid: report of a case.* Surg Today 2005;35:304-8.
- <sup>19</sup> Perez JS, Munoz M, Naval L, Blasco A, Diaz FJ. *Papillary carcinoma arising in lingual thyroid.* J Craniomaxillofac Surg 2003;31:179-82.
- <sup>20</sup> Goldstein B, Westra WH, Califano J. *Multifocal papillary thyroid carcinoma arising in a lingual thyroid: a case report.* Arch Otolaryngol Head Neck Surg 2002;128:1198-200.
- <sup>21</sup> Casella A, Pisano R, Navarro Cuellar C, Llopis P, Mallagray R, Lavorgna G. *Papillary carcinoma of the base of the tongue. Case clinic.* Minerva Stomatol 1999;48:535-8.
- <sup>22</sup> Paludetti G, Galli J, Almadori G, Ottaviani F, d'Alatri L, Maurizi M. *Ectopic thyroid gland.* Acta Otorhinolaryngol Ital 1991;11:117-33.
- <sup>23</sup> Zink A, Raue F, Hoffmann R, Ziegler R. *Papillary carcinoma in an ectopic thyroid.* Horm Res 1991;35:86-8.
- <sup>24</sup> Shah BC, Ravichand CS, Juluri S, Agarwal A, Pramesh CS, Mistry RC. *Ectopic thyroid cancer.* Ann Thorac Cardiovasc Surg 2007;13:122-4.
- <sup>25</sup> Alderson DJ, Lannigan FJ. *Lingual thyroid presenting after previous thyroglossal cyst excision.* J Laryngol Otol 1994;108:341-3.
- <sup>26</sup> Weider DJ, Parker W. *Lingual thyroid: review, case reports, and therapeutic guidelines.* Ann Otol Rhinol Laryngol 1977;86:841-8.
- <sup>27</sup> Puxeddu R, Pelagatti CL, Nicolai P. *Lingual thyroid: endoscopic management with CO<sub>2</sub> laser.* Am J Otolaryngol 1998;19:136-9.

Received: May 26, 2008 - Accepted: June 20, 2008