

TECHNICAL NOTE

A new dynamic endonasal stent for bilateral congenital choanal atresia

Un nuovo stent endonasale dinamico per l'atresia coanale bilaterale

M. MANTOVANI, F. MOSCA¹, M. LAGUARDIA, M. DI CICCIO, L. PIGNATARO

Department of Specialistic Surgical Sciences, ENT Unit; ¹ Neonatal Intensive Care Unit; Fondazione Ospedale Maggiore Policlinico, Mangiagalli e Regina Elena IRCCS, University of Milan, Italy

SUMMARY

The Authors describe a new dynamic endonasal Teflon stent, nick-named "little gun", used after the surgical transnasal endoscopic treatment of bilateral choanal atresia in a 4-day-old male. This Teflon stent, conceived to perfectly fit the new naso-choanal openings and to achieve an "orthopaedic" tutorial function, is made of three portions: "A", the barrel, "B", the breech, "C" the butt. The butt is the active part of the splint and must be rolled up around itself, in order to create a spiral tube, fitting to the new choanal openings, able to expand laterally on account of its intrinsic elastic resilience.

KEY WORDS: Choanal atresia • Endoscopic treatment • Endonasal stent

RIASSUNTO

Gli Autori descrivono un nuovo stent endonasale dinamico, denominato "little gun" (piccola pistola), utilizzato dopo il trattamento endoscopico dell'atresia coanale bilaterale in un neonato a quattro giorni di vita. Questo stent in Teflon, concepito per aderire perfettamente alle neocoane e così ottenere una funzione di espansione ortopedica, è costituito da tre porzioni: "A" la canna, "B" la culatta, "C" il calcio. La porzione "C" è la parte attiva dello stent e dev'essere arrotolata su se stessa al fine di creare un tubo spirale che aderisce perfettamente alla neocoana, capace di espandersi lateralmente in considerazione della resilienza intrinseca del Teflon.

PAROLE CHIAVE: Atresia coanale • Trattamento endoscopico • Stent endonasale

Acta Otorhinolaryngol Ital 2009;29:209-212

Introduction

Choanal atresia (i.e., the partial or complete obliteration of the choanal lumen by fibrous or bony tissue) is a congenital disease that affects one in 7000-8000 newborns (female:male ratio 2:1) and is twice as frequently unilateral. As reported by Flake and Ferguson ¹, this condition was first described by Roderer in 1755 and subsequently better identified by Otto (1830) ², and was first treated surgically by Emmert, in 1853 ³. It is associated with other congenital malformations in 20-50% of cases ⁴.

Bilateral choanal atresia is a medical emergency and requires surgical treatment during the first days of life. The primary surgical approaches are transnasal, transpalatal, transeptal, sublabial-transnasal, and transantral ⁵, although transnasal endoscopic treatment is currently preferred. The need for post-surgical stenting is not universally accepted but often suggested (especially in bilateral cases) although stent material, fixation and care are still a matter of debate. Some Authors ⁴⁻⁹ believe that post-surgical stenting prevents restenosis, whereas others ⁵⁻¹⁰ claim they

are simple foreign bodies that create a high risk of scars, decubitus and infections.

Herein the use is proposed of a new dynamic endonasal stent, designed by the senior Author (M. M.) to favour the progressive physiological expansion and dilatation of new choanae.

Case report

A 4-day-old male newborn was referred to our Clinic because of cyclic cyanosis and stridor. Endoscopy revealed bilateral choanal atresia, which was subsequently confirmed by computerized tomography (CT). The patient underwent surgical transnasal endoscopic treatment under general anaesthesia: after elevating the fibromucosal flaps, a burr cutter was used to open the bony diaphragm bilaterally in order to achieve surgical patency and, after repositioning the fibromucosal flaps, a new endonasal Teflon stent was created.

First of all, the length of the nasal floor was precisely measured using a graduated ear hook in order to be able

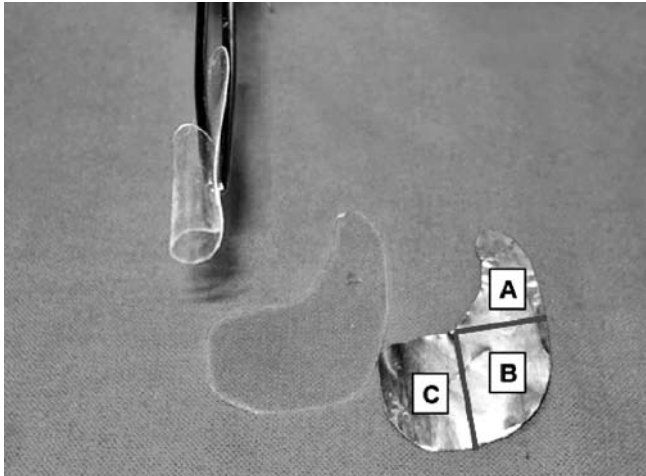


Fig. 1. Customising gun-shaped stent and its three major components.

to trim the Teflon stents in such a way as to fit the nasochoanal cavities perfectly and avoid the occlusion of the Eustachian openings. Each Teflon stent (nick-named “little gun”) consists of three parts: “A”, “B” and “C” (Fig. 1). “A” (or the “barrel”) is designed to cover the septal wall of the anterior part of the nasal cavity and has a smooth perimeter; “B” (the “breech”) must fit the medial wall of the new choanal lumen; and “C” (the “butt”) is the active part of the splint and must be rolled up (clockwise for the right side and anti-clockwise for the left) in order to create a spiral tube that fits into the new choanal opening and then expands laterally as a result of its intrinsic resilience.

The stent was inserted, under endoscopic control, into each nasal cavity in the “closed” position (Fig. 2) with the Teflon spiral serrated, and then attached in the correct position (Fig. 3) by means of a single nylon stitch in order to transfix the “A” portions and the septum just posterior to the valve area. No part of the splint should protrude

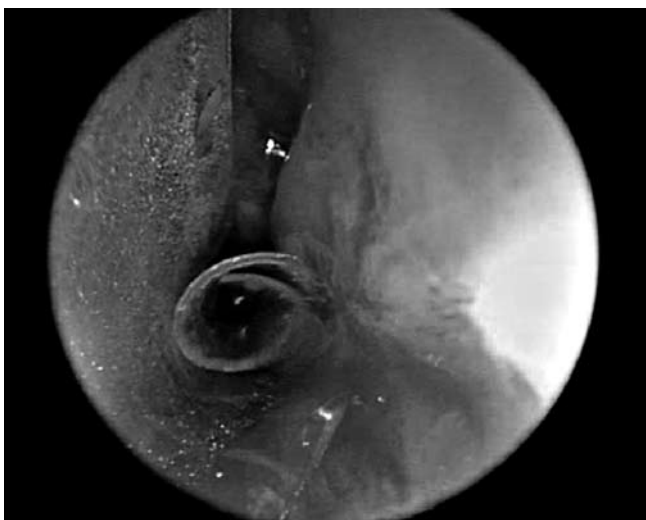

Fig. 2. New stent is inserted into left nasal cavity with Teflon spiral serrated.

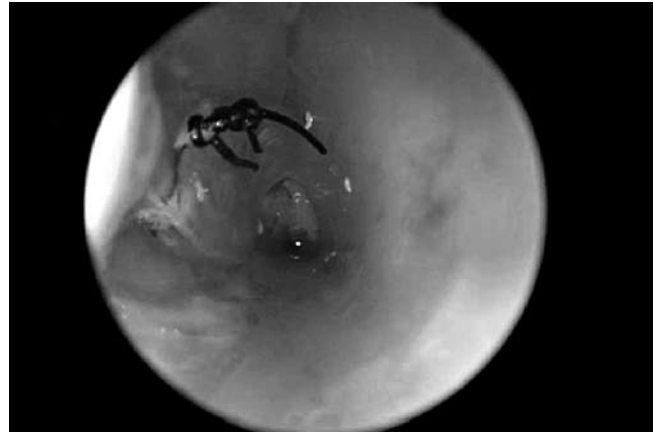


Fig. 3. Single nylon stitch transfixing both “A” portions of splint and septum.

through the nostrils, which must appear to be completely free, or over the tubal opening from the choanal border. Antimicrobial therapy was necessary for only one week after surgery and, during the follow-up, the patient underwent daily saline nasal irrigations and twice-monthly check-up examinations. Two months after the operation, the stents were removed under endoscopic control in order to evaluate the patency of the new choanal lumens and their mucosal walls; although the choanae appeared normal, it was decided to insert a new set of stents of the same type but adjusted to the new size of the nasal cavity. Finally, after one month, the splints were removed, leaving the normal opening of both cavities. Each endoscopic control revealed some crusting over the stents, but this was easily removed by means of aspiration and the use of forceps. Complete patency of both choanae was achieved without any complications or restenosis. After removal of the stents, it was possible to verify their

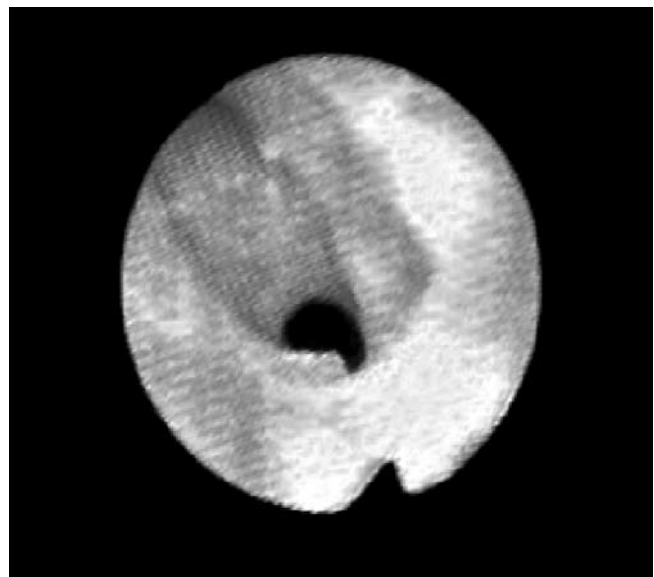


Fig. 4. Patency of choanal lumen 6 months after stent removal.

“orthopedic” function, which was created by the continuous upper and lateral expansion forces of the spiral portion: at the end of stenting, the choanal lumen was about 1 mm wider (Fig. 4).

Discussion

Bilateral choanal atresia is a clinical emergency that requires surgical treatment during the first days of life. Endoscopic surgery is now preferred, and the use of a post-operative stent has been suggested by various Authors, although the proposed stents differ in terms of material, shape and fixation.

Uri and Greenberg⁴, in 2001, proposed a curved sylastic tube adapted to the diameter of the new choanae; Gujrathi et al.⁶, in 2004, described stents made using folded endotracheal tubes that were inserted into each choana through the mouth after endoscopic choanal dilatation using two catheters previously inserted into each nasal cavity as a guide; finally, according to Sharma et al.⁸, in 2006, the same tubes can be inserted through the nostrils and fixed outside the nose. These rigid stents may be more resistant to occlusion than PVC or sylastic tubes, but it has been suggested that soft stents may reduce the risk of granulations and scars that could favour restenosis⁷. Ceylan et al., in 2007, described the use of Nelaton cannulas as stents after repair of bilateral choanal atresia in a 7-day-old child⁹. However, other Authors hold that post-operative nasal stents may actually increase the risk of scars and granulations, and Cedin et al.¹⁰, in 2002, suggested resecting part of the posterior nasal septum and all of the atresic plate after making a bilateral subperichondral and subperiosteal resection that preserves the mucosal tissue.

In our opinion, nasal stenting can avoid traditional major surgical approaches, which generally require positioning of mucosal nasal flaps which are difficult to monitor. Our “little gun” is made of Teflon, a biocompatible material that does not seem to interfere with the physiological mechanism of mucociliary clearance¹¹ and, because of the intrinsic resilience of the material, the spiral portion (C) can expand laterally into the nasal cavity and thus act orthopaedically on the nasal walls and promote their balanced widening. The stents are not rigid and have no sharp edges along their perimeter that might cause mucosal trauma during placement and removal. They are held

by a single nylon stitch that transfixes the “A” portions of the splints and the septum just posterior to the valve area, and can be easily removed without anaesthesia. As the stents are totally intra-nasal, they avoid scars, decubitus and subsequent deformations of the columellar region, and are more acceptable to parents because they are not visible. The precise length of the splints, which is adjusted to each nasal cavity, preserves the Eustachian tube orifices and avoids recurrent tubo tympanitis.

In agreement with other Authors who have suggested stenting for at least 4-12 weeks^{6,8}, in the present series, the stents were maintained in position for 3 months. Although restenting should not be routinely necessary, if the patient is carefully observed at follow-up, in this case, the same kind of stent was repositioned, adjusted to the new size and length of nasal cavity, under general anaesthesia, because of abundant nasal crusting not achieving endoscopic control of patency of the rhinopharyngeal space and because of the difficult management in such a small patient. We suggest twice-monthly fibroendoscopic control examinations with careful aspiration and cleaning of the stent and daily saline nasal irrigations with 15 cc for each nostril 3 times a day to avoid crusting and occlusion of the stent.

Conclusions

The development of granulation tissue is frequently a possible cause of choanal restenosis. The stent described here is made of 0.25 mm thick Teflon, a biocompatible material that does not seem to interfere with the physiological mechanism of mucociliary clearance. It is innovative because it is totally intranasal, dynamic, well-tolerated and custom-shaped. Given its particular shape, we can say that: 1) the absence of any sharp edges along its perimeter allows easy insertion and removal without mucosal trauma; 2) careful measurement of its length by means of a graduated ear-hook is necessary to ensure that it fits the new choana perfectly without occluding the orifice of the Eustachian tube or protruding out of the nostrils; 3) the lateral expansion, created by the C portion, acts orthopaedically on the nasal walls and promotes their balanced widening; and 4) the single nylon stitch transfixing the “A” portions and the septum just posterior to the valve area facilitates care and makes the stent easier to remove than its rigid counterparts.

References

- 1 Flake CG, Ferguson CF. *Congenital choanal atresia in infants and children*. Ann Otol Rhinol Laryngol 1964;73:458-73.
- 2 Otto AW. *Lehrbuch der pathologischen anatomie des menschen und der thiere*, Vol. 1. Berlin: Ruecker; 1830. p. 181-3.

- 3 Emmert C. *Stenochorie und atresia der choannen. Lehrbuch der speciellen chirurgie*, Vol 2. Stuttgart: Dann; 1854. p. 533-8.
- 4 Uri N, Greenberg E. *Endoscopic repair of choanal atresia: practical operative technique*. Am J Otolaryngol 2001;22:321-3.
- 5 Schoem SR. *Transnasal endoscopic repair of choanal atresia: Why stent?* Otolaryngol Head Neck Surg 2004;131:362-6.

- ⁶ Gujrathi CS, Daniel SJ, James AL, Forte V. *Management of bilateral choanal atresia in the neonate: an institutional review*. Int J Pediatr Otorinolaryngol 2004;68:399-407.
- ⁷ Pasquini E, Sciaretta V, Saggese D, Cantaroni C, Macrì G, Farneti G. *Endoscopic treatment of congenital choanal atresia*. Int J Pediatr Otorinolaryngol 2003;67:271-6.
- ⁸ Sharma RK, Lee CA, Gunasekaran S, Knight LC, Bielby M. *Stenting for bilateral congenital choanal atresia. A new technique*. Int J Pediatr Otorinolaryngol 2006;70:869-74.
- ⁹ Ceylan K, Emir H, Kizilkaya Z, Samim E. *Bilateral congenital choanal atresia in a 7-day-old patient: transnasal endoscopic repair with stent*. Eur Arch Otorhinolaryngol 2007;264:837-40.
- ¹⁰ Cedin AC, Peixoto Rocha JF, Deppermann MB, Moraes Manzano PA, Murao M, Shimuta AS. *Transnasal endoscopic surgery of choanal atresia without the use of stents*. Laryngoscope 2002;112:750-2.
- ¹¹ Piatti G, Scotti A, Ambrosetti U. *Nasal ciliary beat after insertion of septo-valvular splints*. Otolaryngol Head Neck Surg 2004;130:558-62.

Received: March 10, 2009 - Accepted: July 20, 2009

Address for correspondence: Prof. L. Pignataro, Dipartimento di Specialità Chirurgiche, Unità Operativa Otorinolaringoiatria, Fondazione Ospedale Maggiore Policlinico, Mangiagalli e Regina Elena IRCCS, Università di Milano, Via Francesco Sforza 35, 20122 Milano, Italy. Fax: +39 02 50320248. E-mail: lorenzo.pignataro@unimi.it