

CASE REPORT

Central nervous system tissue heterotopia of the nose: case report and review of the literature

Eterotopia nasale di tessuto nervoso centrale: presentazione di un caso e rassegna della letteratura

G. ALTISSIMI, S. ASCANI¹, S. FALCETTI, C. CAZZATO, I. BRAVI¹

Institute of Otorhinolaryngology and Head and Neck Surgery; ¹Institute of Pathologic Anatomy, University of Perugia, Pole of Terni, Italy

SUMMARY

The Authors present a case of heterotopic central nervous system tissue observed in an 81-year-old male in the form of an ethmoidal polyp. A review of the literature indicates that this is a rare condition characterised by a connective tissue lesion with astrocytic and oligodendrocytic glial cells, which may be located outside the nasal pyramid in some cases and inside the nasal cavity in others. The most important diagnostic aspect involves differentiating these from meningoencephalocele, which maintains an anatomical connection with central nervous system tissue. Contrast-enhanced imaging is essential for diagnosis, as in cases of heterotopic central nervous system tissue, it will demonstrate that there are no connections with intra-cranial tissue. Endoscopic excision is the treatment of choice.

KEY WORDS: Nasal cavity • Central nervous system tissue heterotopia • Encephalocele

RIASSUNTO

Gli Autori presentano un caso di eterotopia di tessuto nervoso centrale osservato in un uomo di 81 anni sotto forma di polipo etmoidale. Da una revisione della letteratura risulta trattarsi di una patologia rara, caratterizzata da una neoformazione di tessuto connettivo in seno al quale sono reperibili cellule gliali di tipo astrocitario ed oligodendrocitico, a volte localizzata all'esterno della piramide nasale, a volte all'interno delle fosse nasali. L'aspetto diagnostico più importante risiede nella sua differenziazione dai meningoencefaloceli, che mantengono un collegamento anatomico con il tessuto nervoso centrale. Dirimente in tal senso è la diagnostica per immagini con mezzo di contrasto, che in caso di eterotopia di tessuto nervoso centrale dimostrerà l'assenza di connessioni con i tessuti endocranici. L'asportazione con tecnica endoscopica è oggi la terapia di scelta.

PAROLE CHIAVE: Fosse nasali • Eterotopia di tessuto nervoso centrale • Encefalocele

Acta Otorhinolaryngol Ital 2009;29:218-221

Introduction

Heterotopic Central Nervous System Tissue (HCNST) refers to non-cancerous neuroglial tissue at extracranial sites, usually along the central region of the face, inside or near the nasal cavity (nasopharynx, nasal pyramid, upper lip). Also known as nasal gliomas or glial heterotopias, they are generally present at birth or diagnosed in early childhood^{1,2}. The most common clinical form is a subcutaneous extra-nasal mass, whereas intra-nasal polypoid growths resembling inflammatory (allergic) polyps are more rare^{3,4}. There are also mixed forms – intra-nasal and extra-nasal – communicating through a defect in the nasal bones. The exact incidence is unknown. In 1998, Pasquini et al.⁵ referred to 164 cases reported worldwide and, in 1998, Shah et al.⁶ quoted approximately 100 cases; at present, approximately 200 cases have been reported⁷⁻¹⁰. At histological level,

the polypoid masses appear to be composed of astrocytes and neuroglial fibres mixed with a stroma consisting of fibro-vascular connective tissue. These malformations do not usually have any anatomical continuity with central nervous system tissue, a characteristic that distinguishes them from cases of encephalocele^{11,12}.

Herewith, a recent case of HCNST is described, presenting as an intra-nasal polypoid mass, in an 81-year-old patient.

Case report

For approximately two years, R.A., an 81-year-old male, complained of progressive unilateral nasal obstruction on the right side. He did not report rhinorrhoea or nosebleeds. He was being treated for hypertension but presented no other significant pathological conditions. The otolaryngological examination revealed a translucent polypoid mass,

soft and greyish pink, that completely occluded the right nasal cavity, extending into the naso-pharynx through the choana (Fig. 1).

Computed tomography (CT) of the facial bones showed a right antro-choanal mass, resembling a polyp. It occupied the middle and superior nasal turbinates and extended to the floor of the nasal cavity, with erosion of the bony walls of the ethmoidal cells and obstruction of the maxillary ostium, obliterating the antrum due to secretion stasis (Fig. 2). No connection was observed with the meninges or cerebral tissue.

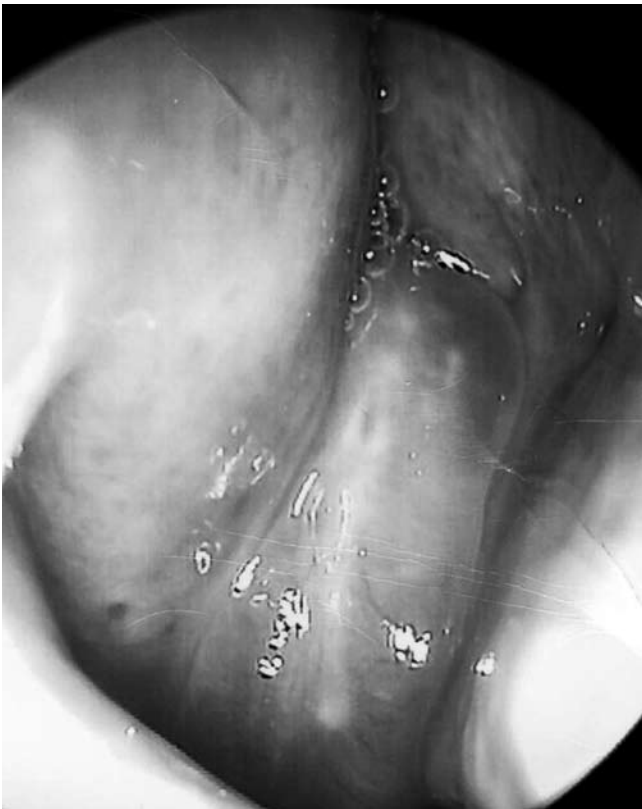


Fig. 1. Macroscopic appearance of intranasal lesion.

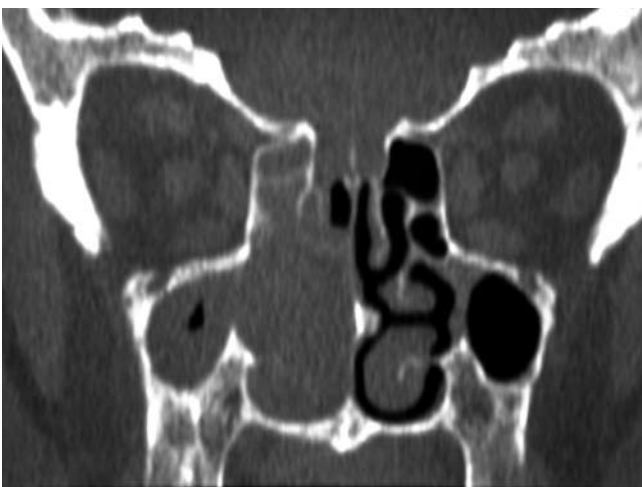

Fig. 2. CT shows unilateral growth that occupies right nasal-paranasal sinuses.

Intra-operative examination revealed that the mass was in the middle nasal turbinate; it was removed endoscopi-

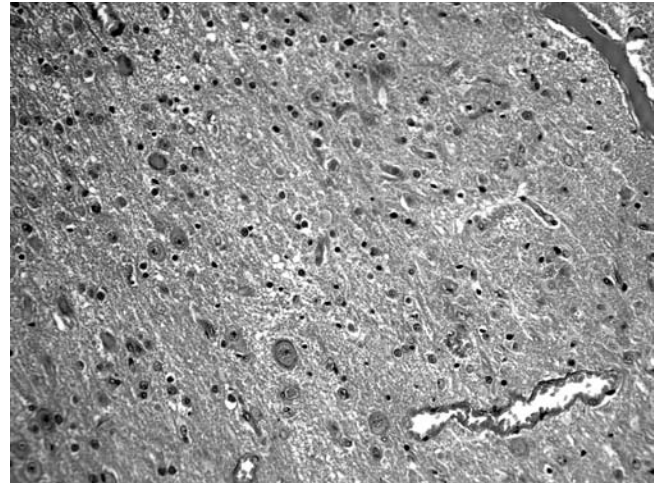


Fig. 3. Histological examination: fibrous tissue with a considerable number of small vessels, astrocytes, oligodendrocytes and occasional neurons. (H&E, 250x.).

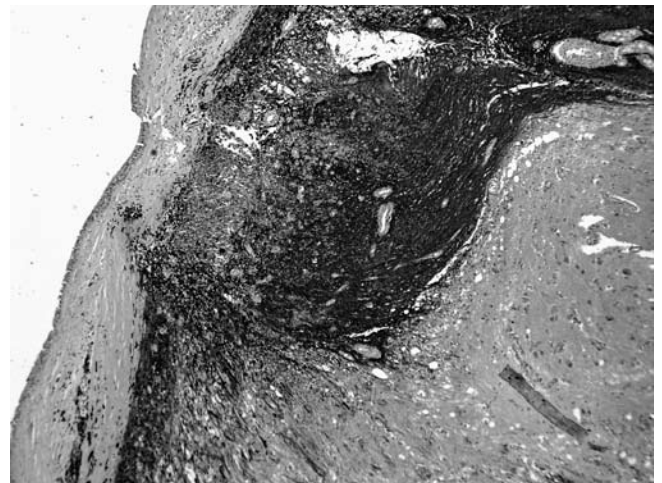


Fig. 4. Intense staining of glial elements in response to glial fibrillary acid protein (GFAP). (Immunoperoxidase-antiperoxidase staining, 50x.).

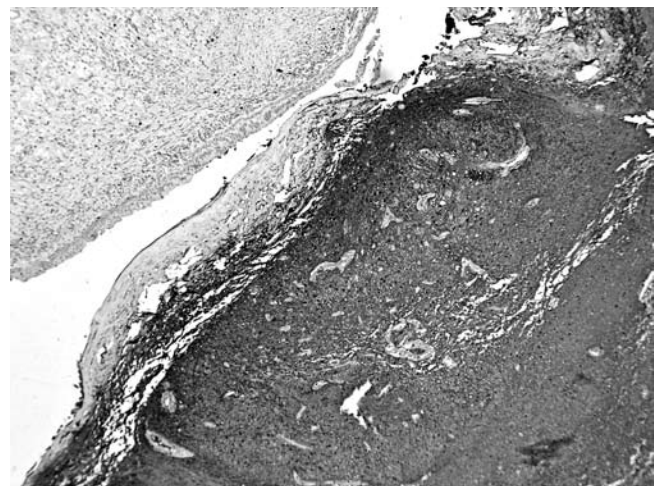


Fig. 5. Expression of S100 protein in glial heterotopic tissue. (Immunoperoxidase-antiperoxidase staining, 50x.).

cally, under general anaesthesia, with Weil forceps and a microdebrider until complete patency of the nasal cavity and maxillary ostium was restored.

Histological examination revealed, under a normal layer of nasal respiratory epithelium, vascularised dense fibrous connective tissue with mature astrocytic and oligodendrocytic glial cells (Fig. 3). Immuno-histochemical typing was performed and the cells were positive for glial fibrillary acid protein (GFAP) and S100 protein (Figs. 4, 5). Several neurons and ependymal cells were also found. There were no mitotic figures or necrotic areas.

At the time of this report (8 months after surgery), the patient is in good health and has shown no signs of recurrence.

Discussion

Despite the fact that glial heterotopias, in or near the nasal cavity, are not true cancers, they clearly show hyperplastic tendencies, since they present as polypoid masses that closely resemble common allergic polyps. Extra-nasal lesions appear as bluish or reddish subcutaneous masses. Mixed intra-nasal and extra-nasal lesions are possible, connected by a kind of isthmus that extends through a dehiscence of the nasal bones^{1 2 13 14}.

Histopathological diagnosis is based on the observation of mature glial cells (astrocytes and oligodendrocytes), in stromal connective tissue, covered by normal respiratory epithelium; neurons and ependymal cells may also be present. When immuno-histochemical typing is performed, the glial cells are positive for glial fibrillary acid protein (GFAP) and S100 protein¹⁵⁻¹⁸.

Intra-nasal masses generally originate in the vault of the nasal cavity, particularly the superior or middle nasal turbinate². Although these can be found at all ages, they are generally diagnosed at birth or in early childhood. The present case is unique due to the advanced age of the patient (81 years), who reported that obstructive symptoms had arisen only two years earlier.

The symptoms reported in the literature, related to these lesions, include not only unilateral nasal respiratory obstruction but also nosebleeds, cerebrospinal fluid leak and meningitis¹⁹.

The most interesting aspect of nasal gliomas involves differential diagnosis with respect to encephalocele. The Furstenberg test, which is typically positive when encephalocele is involved (the mass becomes enlarged and pulsatile when the ipsilateral jugular vein is compressed), is negative in the case of HCNST. Nevertheless, with diagnostic imaging, particularly contrast-enhanced CT or magnetic resonance (MR), it is possible to exclude the suspicion of encephalocele by demonstrating the lack of an anatomical connection between the mass and the central nervous system (CNS). Therefore, these tests are mandatory in the event of a unilateral intra-nasal mass, since the mere suspicion of encephalocele will obviously lead to surgical planning in a specific direction.

Cases of encephalocele associated with nasal glial heterotopia in a same patient have also been reported^{20 21}. According to several Authors, nasal gliomas represent cases of encephalocele, the intracranial connection of which has been lost^{22 23}.

Biopsy is not advisable, since, if there is an intra-cranial connection, it can cause cerebro-spinal fluid leak^{13 24 25}.

Endoscopic excision of intra-nasal HCNST is the treatment of choice^{26 27}. The rate of recurrences, which are related to inadequate primary excision, range from 4 to 10%^{14 21}. No cases of malignant degeneration have been reported.

Conclusions

The presence of glial heterotopia is a possibility to be taken into consideration in the management of unilateral intra-nasal polypoid masses. With reference to this possibility, it seems highly advisable to perform scrupulous pre-operative diagnostic imaging (contrast-enhanced CT or MR) in order to rule out fronto-basal encephalocele.

References

- Herley E. *Pediatric congenital nasal masses*. Ear Nose Throat 1991;70:28-33.
- Morgan DW, Evans JNG. *Developmental nasal anomalies*. J Laryngol Otol 1990;104:394-403.
- Dasgupta NR, Bentz ML. *Nasal gliomas: identification and differentiation from hemangiomas*. J Craniofacial Surg 2003;14:736-8.
- Hirsh LF, Stool SE, Langfitt RW, Schut L. *Nasal glioma*. J Neurosurg 1977;46:85-91.
- Pasquini E, Farneti G, Giausa G, Biavati M. *A rare case of nasal glioma in adult age*. Otolaryngol Head Neck Surg 1998;118:905-6.
- Shah J, Patkar D, Patankar T, Krishnan A, Prasad S, Limdi J. *Pedunculated nasal glioma: MRI features and review of the literature*. J Postgrad Med 1999;45:15-7.
- Al-Ammar AY, Al Noumas HS, Alqahtani M. *A midline nasopharyngeal heterotopic neuroglial tissue*. J Laryngol Otol 2006;120:E25.
- Bhadani PP, Sah SP, Jha AK, Rani S. *Nasal cerebral heterotopia: a case report*. Indian J Pathol Microbiol 2002;45:341-3.
- Pollard K, Carter DA. *A case of nasal glioma and neurofibromatosis*. J Laryngol Otol 1987;101:497-9.
- Taege C, Musil A, Klohs G, Rath FW. *Cerebral heterotopia appearing as an extranasal polyp*. Eur J Pediatr Surg 2001;11:268-70.

- ¹¹ Martinez-Lage JF, Garcia-Contreras JD, Ferri-Niguez B, Sola J. *Nasal cerebral heterotopia: nasal atretic cephalocele*. Neurocirugia (Astur) 2002;13:385-8.
- ¹² Patterson K, Kapur S, Chandra RS. "Nasal gliomas" and related brain heterotopias: a pathologist's perspective. *Pediatr Pathol* 1986;5:353-62.
- ¹³ Gorenstein A, Kern B, Facer W, Laws E Jr. *Nasal gliomas*. *Arch Otolaryngol* 1980;106:536-40.
- ¹⁴ Katz A, Lewis JS. *Nasal gliomas*. *Arch Otolaryngol* 1971;94:351-5.
- ¹⁵ Burger PC, Scheithauer BW. *Tumors of the central nervous system. AFIP Atlas of tumor pathology. Series 4*. Washington, DC: American Registry of Pathology 2007. p. 492-3.
- ¹⁶ Cerdà-Nicolàs M, Sanchez Fernandez de Sevilla C, Lopez-Ginés C, Peydro-Olaya A, Llombart-Bosch A. *Nasal glioma or nasal glial heterotopia? Morphological immunohistochemical and ultrastructural study of two cases*. *Clin Neuropathol* 2002;21:66-71.
- ¹⁷ Chan JK, Lau WH. *Nasal astrocytoma or nasal glial heterotopia?* *Arch Pathol Lab Med* 1989;113:943-5.
- ¹⁸ Penner CR, Thompson L. *Nasal glial heterotopia: a clinicopathologic and immunophenotypic analysis of 10 cases with a review of the literature*. *Ann Diagn Pathol* 2003;7:354-9.
- ¹⁹ Luzi P, Nuti D, Miracco C, Venturi C, Sensini I. *Nasal "glioma" in aged woman presenting with liquororrhea*. *Rev Laryngol Otol Rhinol (Bord)* 1985;106:131-3.
- ²⁰ Fujioka M, Tasaki I, Nakayama R, Yakabe A, Baba H, Toda K, et al. *Both nasal cerebral heterotopia and encephalocele in the same patient*. *Cleft Palate Craniofac J* 2006;43:112-6.
- ²¹ Yeoh GP, Bale PM, de Silva M. *Nasal cerebral heterotopia: the so-called nasal glioma or sequestered encephalocele and its variants*. *Pediatr Pathol* 1989;9:531-49.
- ²² Harrison D, Lund V. *Neuroectodermal lesion*. In: *Tumours of upper jaw*. London: Churchill Livingstone; 1993. p. 295-306.
- ²³ Karma P, Rasanen O, Karaja J. *Nasal gliomas. A review and report of two cases*. *Laryngoscope* 1976;87:1169-79.
- ²⁴ Bradley PJ, Singh SD. *Nasal glioma*. *J Laryngol Otol* 1985;99:247-52.
- ²⁵ Reilly JR, Koopman CF, Cotton R. *Nasal mass in a pediatric patient*. *Head Neck Surg* 1992;4:415-8.
- ²⁶ Agirdir BV, Derin AT, Ozbilim G, Ozçaglar H. *Endoscopic management of the intranasal glioma*. *J Pediatr Surg* 2004;39:1571-3.
- ²⁷ Yokoi H, Wada R, Ichikawa G. *Endoscopic treatment of so-called intranasal glioma*. *Rhinology* 2002;40:217-9.

Received: June 24, 2008 - Accepted: December 2, 2008