

CASE REPORT

Necrotizing fasciitis of the neck associated with Lemierre syndrome

Fascite necrotizzante del collo associata a sindrome di Lemierre

A. DEGANELLO, O. GALLO, G. GITTI, E. DE CAMPORA

Otolaryngology and Head and Neck Surgery Department, University of Florence, Italy

SUMMARY

Necrotizing fasciitis of the head and neck is a rare, life-threatening, soft tissue infection rapidly involving superficial fat and fascia with necrosis of the overlying skin. If septic thrombophlebitis of the internal jugular vein complicates a parapharyngeal abscess, the clinical condition is referred to as Lemierre syndrome, also known as post-anginal sepsis. A lethal case of necrotizing fasciitis of the neck is herewith reported that developed following tooth extraction and was complicated by thrombosis of the internal jugular vein and superior vena cava in an elderly diabetic patient.

KEY WORDS: Neck infections • Necrotizing fasciitis • Lemierre syndrome • Dental extraction

RIASSUNTO

La fascite necrotizzante del distretto testa-collo è una infezione dei tessuti molli rara e potenzialmente mortale che interessa il tessuto adiposo e la fascia superficiale con necrosi della cute sovrastante. La Sindrome di Lemierre (anche definita sepsi post-anginoso) è la condizione in cui un ascesso parafaringeo si complica con una tromboflebite settica della vena giugulare interna. In questo articolo abbiamo riportato un caso mortale di fascite necrotizzante sviluppatasi in seguito ad estrazione dentaria in un paziente anziano e diabetico ed in seguito complicata da trombosi della vena giugulare interna e della vena cava superiore.

PAROLE CHIAVE: Collo • Infezioni • Fascite necrotizzante • Sindrome di Lemierre • Estrazione dentaria

Acta Otorhinolaryngol Ital 2009;29:160-163.

Introduction

Necrotizing Fasciitis (NF) of the head and neck is a rare, life-threatening, soft tissue infection rapidly involving superficial fat and fascia with necrosis of the overlying skin. NF most commonly occurs in extremities, trunk and abdomen after trauma or surgery¹. NF rarely involves the head and neck and is associated with dental infections², peritonsillar and pharyngeal abscesses³, osteoradionecrosis⁴, insect sting⁵, neck surgery⁶, steroid neck injections⁷. NF was first described by Joseph Jones during the American civil war⁸. In 1952, Wilson first used the term “necrotizing fasciitis”⁹.

If septic thrombophlebitis complicates a parapharyngeal abscess the clinical condition is referred to as Lemierre syndrome (LS), also known as post-anginal sepsis. LS was first described in 1936 by a French microbiologist André Lemierre who reported¹⁰ thrombosis of the internal jugular vein as a complication of parapharyngeal abscesses, LS can be associated with distant metastatic infections involving the lungs. An incidence of 0.8 to 1.5 cases of LS per 1 million persons per year has been esti-

mated, leading some to refer to it as the “forgotten foe”¹¹. The case is reported here of a lethal case of NF of the neck that developed after tooth extraction and was complicated by thrombosis of the internal jugular vein and superior vena cava in an elderly diabetic patient.

Case report

A 74-year-old male with a medical history of severe diabetes mellitus, cirrhosis and heart attack was admitted to our Department with a 5-day history of fever and increasing left cheek and submandibular swelling, on the left side, following dental extraction of the 27th dental element. Dental extraction had been conducted 6 days earlier without antibiotic prophylaxis. At ENT examination, the patient presented with dysphagia, trismus and temperature 38 °C. The left tonsillar region appeared to be medialized, the left pyriform sinus was oedematous, purulent secretions were clearly visible emerging from the dental extraction site and a painful hard erythematous swelling of the submandibular region was noted that appeared to extend to the entire left side of the neck.

Blood tests showed a leukocyte count of $12.50 \times 10^9/L$ with neutrophil leukocytosis (75%), a platelet count of $130 \times 10^9/L$, and haemoglobin value of 12.6 g/dL. Prothrombin time and D-dimer were normal. Fibrinogen was 500 mg/d. Daily intravenous treatment with betamethasone 8 mg, clindamycin 1200 mg and ceftriaxone 2 g was empirically started and samples were sent for microbiological analysis. Habitual patient's heparin treatment was maintained and insulin administration was adjusted to the steroid treatment. Computed tomography (CT) scan of the neck showed an initial abscess in the parapharyngeal space on the left hand side, without extension to the neck. The day after admission, the clinical conditions of the patient improved dramatically with regression of the trismus, improvement in swallowing, normal body temperature; at ENT examination, drainage of purulent material through a spontaneous opening in the mucosa of the posterior floor of mouth, in correspondence to the 47th dental element was observed. Fibroscopy showed resolution of the oedema in the left pyriform sinus.

During the next 5 days, the patient's clinical conditions remained stable, with slight improvement. Neutrophil leukocytosis remained elevated ($14 \times 10^9/L$) and a moderate increase of thrombocytopenia was detected. The 6th day after admission, a sudden bilateral increase of the neck swelling appeared with marked tenderness at neck palpation, from the tragus to the upper chest, associated with cutaneous hypoaesthesia and further onset of dysphagia with no pain; venous distension of the neck and upper chest wall was observed; at fibroscopic evaluation, oedema of the left aryepiglottic fold was seen. A new contrast enhanced CT scan (Fig. 1A) showed hydro-aerial levels in the pterygoid fossa, in the laterocervical and anterior neck region (Fig. 1B) with minimal extension to the upper

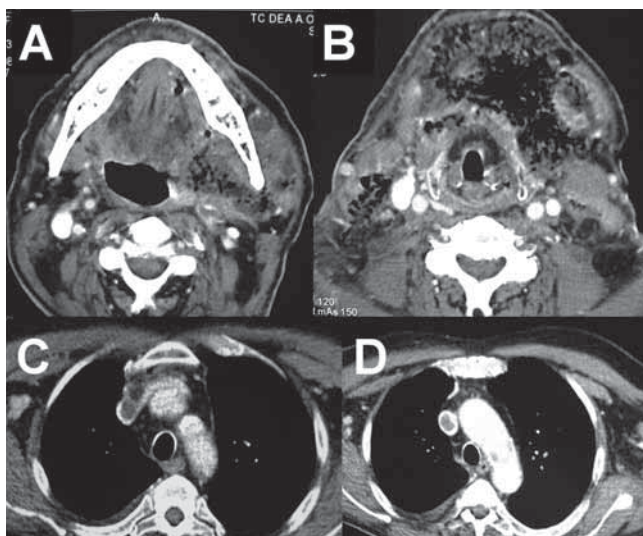


Fig. 1. A: a parapharyngeal abscess with air collection at the left hand side; B: at the level of the hyoid bone where skin thickening is evident and massive air collection in both neck sides; C: evident thrombosis of the left innominate vein; D: thrombosis of the superior vena cava.

mediastinum. The thoracic surgeon gave no indications for mediastinal toilette. Furthermore, thrombosis of the supraclavicular caudal portion of the internal jugular vein, on the left side with extension to the superior vena cava, was diagnosed (Fig. 1C-D). A blood count still showed neutrophil leukocytosis (75%), a lower platelet count ($38 \times 10^9/L$) and haemoglobin (13 g/dL). The D-dimer value was still normal but abnormal coagulation was found (PT 19.2 seconds, PTT 40 seconds). Blood cultures grew *Streptococcus sanguinis*.

The patient underwent immediate surgical exploration of the neck. Bimastoid incision with a superiorly based apron flap was performed to expose all neck levels. Necrosis of the superficial cervical fascia, involving the underlying infra- and supra-hyoid muscles and the sternal portion of the sternocleidomastoid muscles, bilaterally, was found, considered highly suspicious for NF (Fig. 2A-B). On both sides of the neck and in the left parapharyngeal space, debridement of all necrotic material, reaching healthy bleeding tissue, was carried out, together with removal of all purulent secretions. A pus sample was sent for microbiological analysis and all necrotic tissue was sent for pathological examination. The skin appeared to be thickened but vital, therefore primary closure was performed after repeated washes with H_2O_2 solution and saline water. Four aspiration drains were placed in the neck (Fig. 2C). The microbiological analysis showed a *Streptococcus sanguinis* infection, pathological examination was positive for NF. In the post-operative course, despite prompt commencement of adequate anti-thrombosis treatment (dalteparin 200 IU/kg/day) and despite definite improvement in neck findings confirmed by control CT scan (Fig. 2D), venous distension of the neck and chest wall deteriorated until the 7th post-operative day when the patient developed massive pulmonary thrombosis, an oro-tracheal ventila-

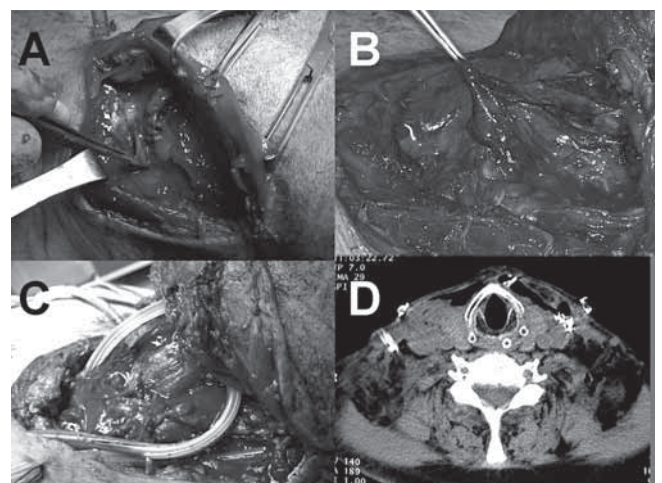


Fig. 2. A: necrosis of the intermediate tendon of the omohyoid muscle; B: necrosis of the fascia overlying the infrahyoid muscles; C: neck field after debridement; D: postoperative CT scan showing no signs of residual infection.

tion tube was introduced, the patient was admitted to the intensive care unit where he died two days later.

Discussion

During the 19th Century, the mortality rate for NF of the head and neck was 20-50% while recent reports suggest that in the post-antibiotic era the mortality rate ranged from 16.5-20%^{12,13}. LS was also a very common disease with a high mortality in the pre-antibiotic era while today, with the advent of penicillin, it is often referred to as the “forgotten disease”. The aetiology of LS is *Fusobacterium necrophorum* in 81.7% and, in the remaining 18.3%, is caused by several (*Streptococcus* not-A, Gram- aerobic micro-organism, anaerobic Gram+ *Cocci* and *Bacterioides*) other organisms¹⁴, some of which are the same recognized aetiological agents of NF. The pathological mechanism of NF is not fully understood. However, bacterial proteolytic enzymes, such as collagenases and hyaluronidases, may lead to the rapid spread of the infection and necrosis along the tissue planes¹⁵. Skin necrosis usually develops later in the course, secondary to thrombosis of nutrient vessels crossing the involved fascia.

If the neck is involved, the NF mortality rate is higher because of the tendency to spread to the mediastinum, chest, and carotid sheath. Reports in the literature indicate that 46% of patients show at least one of the codified risk factors¹⁶: diabetes mellitus, arteriosclerosis, alcoholism, chronic renal failure, malignancy, intravenous drug abuse and the postpartum state^{17,18}.

The diagnosis of NF is not easy due to the rarity of this potentially life-threatening disease that, in early stage, can be mistaken for a more common neck abscess where the clinical course is usually benign. It was highlighted¹⁹ that CT scan can provide constant features characteristic of NF, such as thickening and infiltration of the cutis and subcutis, diffuse enhancement and/or thickening of the superficial and deep cervical fasciae and platysma, fluid collections in multiple compartments. Imaging could be of great help in order to discover unsuspected extensions of the inflammatory process providing information on extent of the disease and confirming the presence or absence of gas. In our case, at presentation, CT scan did not show any of the afore-mentioned findings. Confusion, shock, and poor response to intravenous antibiotics are other frequent features but our patient seemed to respond extremely well to treatment, as is usually the case in patients presenting an oral abscess.

In NF, the onset of symptoms usually occurs 2 to 4 days after the trauma or the surgical procedure²⁰. What differentiates NF from these less lethal infections is the rapidity with which the infection can spread. In NF, the erythema advances rapidly, and the skin can become hardened and elevated within a few hours. At the time of presentation, most patients are septic with high fever and rapidly pro-

gressive, non-fluctuant, swelling of the face and neck. Our patient's clinical conditions significantly improved with antibiotic treatment and with spontaneous drainage in the posterior floor of the mouth. In most neck abscesses, if spontaneous drainage occurs, surgery is not mandatory, so we, therefore, decided to continue with medical treatment that seemed to be highly effective. Reviewing the literature, we found that the antibiotic treatment we administered was adequate; in fact, there is increasing evidence supporting the use of clindamycin in the initial treatment of NF, this antibiotic being effective against slow-growing bacteria in large inocula²¹.

The initial favourable course and a blood count showing only neutrophil leukocytosis (common in most benign disorders) without a significant decrease in platelets until sudden deterioration of the clinical conditions significantly delayed diagnosis which was made once local and general complications occurred.

NF should be suspected if patients complain of pain which is out of proportion at the involved site while there is no pain upon palpation of the surrounding skin that conversely appears numb on account of neural damage. In our patient, skin numbness started a few hours before surgery while pain never occurred.

The clinical conditions of our patient suddenly and dramatically worsened with the appearance of the thrombosis that led to a progressive massive swelling of the neck and upper chest that was immediately evaluated with CT scan. Despite minimal mediastinal involvement and effective surgical debridement of the neck, confirmed by the control CT scan, thrombosis did not respond to treatment, leading to a massive pulmonary thromboembolism with ultimate death. It is interesting to note that, in this case, LS appeared despite the fact that the patient never interrupted heparin habitual treatment and this septic thrombosis did not respond to medical treatment in the post-operative course. To the best of our knowledge, this is the first case described in the literature where NF is further complicated by thrombosis of the cava vein, a finding which highlights the central role that contrast enhanced CT scan play in the early detection of septic thrombosis.

In conclusion, in the present case, we encountered two rare pathological conditions masked by an initial favourable course where typical warning signs and symptoms were lacking and which appeared only a few hours before surgery. Possibly, in elderly patients at risk of presenting a parapharyngeal abscess, it would be advisable to perform serial imaging controls, every 2 days, despite clinical improvement, focusing particular attention on radiological features suggesting NF or thrombosis of major vessels. In our opinion, antibiotic prophylaxis, in high risk patients, should always be prescribed when dental extraction is performed and we certainly recommend it.

References

- ¹ Bahu SJ, Shibuya TY, Meleca RJ, Mathog W, Yoo GM, Stacher RJ, et al. *Craniocervical necrotizing fasciitis: an 11-year experience*. Otolaryngol Head Neck Surg 2001;125:245-52.
- ² Moss RM, Kunpittaya S, Sorasuchart A. *Cervical necrotizing fasciitis: an uncommon sequela to dental infections*. Ann Otol Rhinol Laryngol 1990; 99:643-6.
- ³ Safak MA, Haberal I, Kilic D, Gocmen H. *Necrotizing fasciitis secondary to peritonsillar abscess: a new case and review of eight earlier cases*. ENT J 2001;80:824-33.
- ⁴ Maluf FC, William WN Jr, Rigato O, Menon AD, Parise O Jr, Docema MF. *Necrotizing fasciitis as a late complication of multimodal treatment for locally advanced head and neck cancer: a case report*. Head Neck 2007;29:700-4.
- ⁵ Aimoni C, Cilione AR, Grandi E, Lombardi I, Merlo R, Pastore A. *Cervical necrotizing fasciitis*. Eur Arch Otorhinolaryngol 1999;256:510-3.
- ⁶ Beerens AJ, Strack Van Schijndel RJ, Mahieu HF, Leemans CR. *Cervical necrotizing fasciitis with thoracic extension after total laryngectomy*. J Laryngol Otol 2002;116:639-41.
- ⁷ Harar RP, Cranston C, Warwick-Brown N. *Descending necrotizing mediastinitis: report of a case following steroid neck injection*. J Laryngol Otol 2002;116:862-4.
- ⁸ Jones J. *Investigation upon the nature, causes and treatment of hospital gangrene as it prevailed in the confederated armies*. In: *Surgical memories of the War of Rebellion*. New York: United States Sanitary Commission, 1871.
- ⁹ Wilson B. *Necrotizing fasciitis*. Am Surg 1952;18:416-31.
- ¹⁰ Lemierre A. *On certain septicaemias due to anaerobic organisms*. Lancet 1936;1:701-3.
- ¹¹ Dool H, Soetekouw R, van Zanten M, Grooters E. *Lemierre's syndrome: three cases and a review*. Eur Arch Otorhinolaryngol 2005;262:651-4.
- ¹² Haywood CT, McGeer A, Low DE. *Clinical experience with 20 cases of group A Streptococcus necrotizing fasciitis and myonecrosis: 1995 to 1997*. Plast Reconstr Surg 1999;103:1567-3.
- ¹³ Marty-Anè CH, Berthet JP, Alric P, Pegis JD, Rouviere P, Mary H. *Management of descending necrotizing mediastinitis: an aggressive treatment for an aggressive disease*. Ann Thorac Surg 1999;68:212-7.
- ¹⁴ Chirinos JA, Lichtstein DM, Garcia J, Tamariz LJ. *The evolution of Lemierre syndrome: Report of 2 cases and review of the literature*. Medicine (Baltimore) 2002;81:458-65.
- ¹⁵ Shindo ML, Nalbone VP, Dougherty WR. *Necrotizing fasciitis of the face*. Laryngoscope 1997;107:1071-9.
- ¹⁶ Tovi F, Fliss DM, Zirkin HJ. *Necrotizing soft-tissue infections in the head and neck: a clinicopathological study*. Laryngoscope 1991;101:619-25.
- ¹⁷ Kronish JW, McLeish WM. *Eyelid necrosis and periorbital necrotizing fasciitis*. Ophthalmology 1991;98:92-8.
- ¹⁸ Chelsom J, Halstensen A, Haga T, Hoiby EA. *Necrotising fasciitis due to group A streptococci in western Norway: incidence and clinical features*. Lancet 1994;344:1111-5.
- ¹⁹ Becker M, Zbären P, Hermans R, Becker CD, Marchal F, Kurt AM, et al. *Necrotizing fasciitis of the head and neck: role of CT in diagnosis and management*. Radiology 1997;202:471-6.
- ²⁰ Bahna M, Canalis RF. *Necrotizing fasciitis (Streptococcal gangrene) of the face. Report of a case and review of the literature*. Arch Otolaryngol 1980;106:648-51.
- ²¹ Bisno AL, Stevens DL. *Streptococcal infections of skin and soft tissues*. N Engl J Med 1996;334:240-4.

Received: April 7, 2008 - Accepted: May 29, 2008