

CASE REPORT

# Solitary fibrous tumour of the laterocervical spaces

## *Tumore fibroso solitario a localizzazione laterocervicale*

M. SBROCCA, N. MEVIO, M. MULLACE, M. CAZZANIGA<sup>1</sup>, E. MEVIO

Otorhinolaryngology Unit; <sup>1</sup> Pathology Unit, Fornaroli Hospital, Magenta, Italy

### SUMMARY

Solitary fibrous tumours are rare mesenchymal neoplasms usually arising in the pleura. Extra-pleural locations are uncommon although some cases of head and neck involvement have been reported in the recent literature. In such cases, nose, paranasal cavities and parapharyngeal spaces are the most frequently affected sites. The Authors present a case of a solitary fibrous tumour involving the laterocervical spaces. The histological diagnosis of solitary fibrous tumours gives rise to significant problems since parameters for determining their aggressiveness are still controversial. Immunohistochemical techniques are considered to provide a decisive identification. Follow-up plays a crucial role, as recurrences can occur even after several years. Usually, complete surgical excision is adequate whilst curative and radiochemotherapy may be indicated if complete resection of the tumour mass is impossible.

KEY WORDS: Head and neck neoplasms • Solitary fibrous tumour • Diagnosis • Treatment

### RIASSUNTO

*Il tumore fibroso solitario (SFT) è una rara neoplasia d'origine mesenchimale. La sua localizzazione più comune è a livello pleurico, abbastanza infrequenti sono le localizzazioni in altri distretti. Alcune recenti segnalazioni in letteratura descrivono casi di interessamento del distretto cervico-facciale con coinvolgimento del naso e dei seni paranasali o degli spazi parafaringei. Gli Autori presentano un caso di tumore fibroso solitario interessante gli spazi laterocervicali. Il tumore fibroso solitario solleva una interessante problematica anatomopatologica soprattutto al riguardo dei parametri che possono consentire una valutazione della sua aggressività. Le tecniche immunohistochimiche recentemente adottate si sono rivelate basilari per la diagnostica. Normalmente la completa escissione chirurgica si rivela risolutiva e solo in casi in cui l'asportazione radicale risulti impossibile viene proposta la radio-chemioterapia. Di estrema importanza è un prolungato follow-up per la tendenza del tumore fibroso solitario alle recidive a distanza.*

PAROLE CHIAVE: Tumori testa e collo • Tumore fibroso solitario • Diagnosi • Trattamento

Acta Otorhinolaryngol Ital 2009;29:41-43

## Introduction

Solitary fibrous tumours (SFT) are rare neoplasms of uncertain histogenesis that usually involve the pleura. Extra-pleural locations are less frequent and reports of head and neck involvement are even rarer and most frequently located in the nasal and paranasal cavities or parapharyngeal spaces<sup>1-7</sup>.

Mesenchymal origin of the neoplasm is now commonly accepted, as it is predominantly associated with serosal surfaces (pleura, peritoneum, etc.), shows negativity for epithelial markers and absence of mesothelial elements. Recently, it has been hypothesized that SFTs may originate from CD34-positive, interstitial dendritic cells of connective tissue.

Occurrence of SFTs is comparable in males and females. There is no evidence of particular risk factors, although they may be associated with prior trauma to the tumour site. Clinically, SFT may present symptoms related to the site

of tumour origin (nasal obstruction, sinusitis, otitis, etc), or systemic symptoms such as hypoglycaemia, osteoarthropathy and arthralgia. Due to the slow and silent growth of the neoplasia, SFTs have usually been found incidentally during routine clinical or radiological investigations.

Following complete surgical excision of the SFT, prognosis is usually good. Radio-chemotherapy may be indicated only in the event of incomplete resection. However, long-term follow-up is recommended as late recurrences are frequent.

## Case report

A 68-year-old female came to our clinic with a history of a right laterocervical mass at level L2/L3, which had been growing slowly over the previous 2 years. The patient had no history of previous traumatic events. Ultrasonography of the neck revealed the presence of an isolated and elongated, hypochoic mass (4 x 2.5 cm) in the laterocervical

spaces, near the jugular vein. Fine needle aspiration biopsy revealed the presence of aspecific tumour cells.

Positron emission tomography (PET) showed an increased uptake of tracer limited to this right laterocervical mass (Fig. 1).

Selective neck dissection (L2, L3) was performed with radical excision of the mass. The specimen was well-circumscribed.

The resected tissue consisted of an apparently capsulated,

ovoid mass, measuring 4 x 2.5 cm. Cut sections displayed a prevalently fleshy, grey-white soft tissue and an area of firm, white tissue at one pole of the mass.

Microscopically, the mass showed a range of morphological features: from hypercellular areas to a large, predominantly fibrous, collagenized, hypocellular area containing hyalinised-thickened vessel walls.

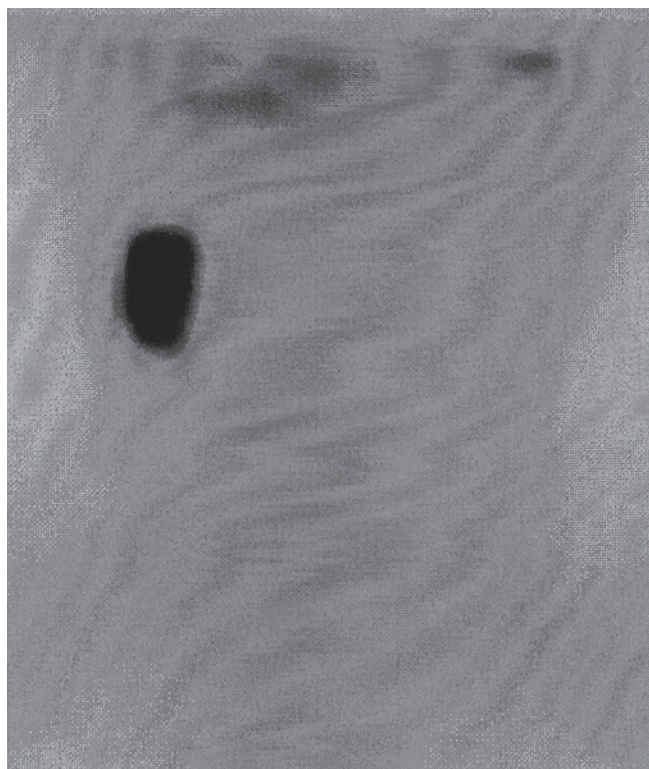
The hypercellular areas (Fig. 2A) were composed of closely packed, round to spindle cells with a vaguely storiform arrangement and minimal collagenous deposits. The cells displayed moderately hyperchromatic nuclei with very little cytoplasm and indistinct cell borders. Mitotic figures were 14 per 10 high-power fields.

The hypocellular fibrous area (Fig. 2B) showed a population of bland, fusiform cells with indistinct cytoplasmic borders arranged around numerous, branching vascular channels lined with a single layer of attenuated endothelium. The intervening vascular channels displayed a striking variation in calibre, ranging from small capillary-sized to large, gaping sinusoidal spaces. Some of the branching sinusoidal vessels exhibited the typical antler or staghorn configuration. Commonly, the vessels, particularly the large ones, were covered with a thick coat of hyalinized collagen that extended into the stroma. There were rare, focal mixoid zones. No mitoses were present.

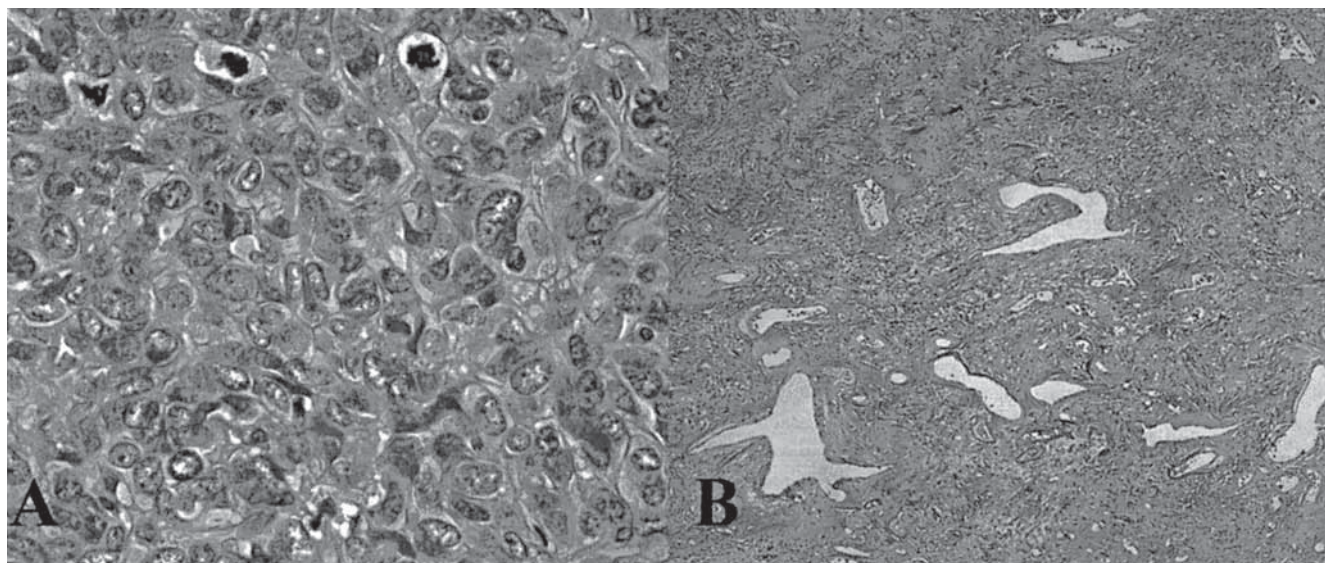
The transition from hypercellular to hypocellular fibrous areas was abrupt. Foci of necrosis and haemorrhage were not seen.

Immunohistochemical stains performed on the paraffin-embedded material showed strong cytoplasmic staining for CD 34, bcl-2 and vimentin in the tumour cells of the hypercellular and hypocellular areas.

Furthermore, the tumour cells were non-reactive for the S-100 protein, actin HHF35, actin 1A4, desmin and cytokeratin AE1/AE3.



**Fig. 1.** PET revealed high metabolic activity related to an isolated right laterocervical mass.



**Fig. 2.** Hypercellular area (A): moderate cytological atypia and brisk mitotic activity (H&E, original x400). Hypocellular area (B): prominent staghorn vessels. Perivascular and stromal hyalinization (H&E, original x40).

The diagnosis of a malignant fibrous solitary tumour was made on the basis of the morphology and immunohistochemical staining pattern.

Histological studies confirmed that the mass had been radically excised, and the absence of lymph node metastases. Therefore, no radio-chemotherapy was planned. Follow-up after two years revealed no evidence of recurrence.

## Discussion

SFT is an uncommon but well-characterized soft tissue tumour initially reported in the pleura but now considered ubiquitous, having been identified in many extra-pleural sites (abdominal cavity, orbit, upper respiratory tract, and oral cavity).

The histogenesis of SFT was controversial for a long time. Initially, it was thought to be of mesothelial origin but the occurrence of these neoplasms in serosal surfaces and recent immunohistochemical studies strongly suggested a mesenchymal origin. In fact, SFTs show a strong positive reaction with the CD34 antigen and vimentine with associated negativity for epithelial and mesothelial markers<sup>8,9</sup>.

Extra-pleural locations of the disease, especially in the head and neck region, require an accurate differential diagnosis compared to other neoplasms with similar histological features (spindle cell and connective tissue areas). Foremost on the exclusion list are haemangiopericytoma, angiofibroma, neurogenous neoplasms and fibrous histiocytoma.

Due to the heterogeneous morphological appearance of SFTs, if sampling of the mass is not scrupulously performed, this may lead to misdiagnosis and inappropriate treatment. Therefore, meticulous histological examination is mandatory, together with the use of appropriate immunostaining<sup>10</sup>.

A carefully prepared surgical approach, with imaging studies, is the first choice in the planning of treatment. Chemoradiotherapy may be considered when complete resection cannot be achieved. A very long follow-up period is essential as recurrences can occur after many years. In this case, imaging findings, indicating a single limited mass, led us to choose a selective surgical approach. Since examination of a specimen confirmed radical excision, a chemo-radiotherapy approach was reserved for eventual delayed disease recurrence.

## References

- <sup>1</sup> Safneck JR, Alguacil-García A, Dort JC, Phillips SM. *Solitary fibrous tumour: report of two new locations in the upper respiratory tract.* J Laryngol Otol 1993;107:252-6.
- <sup>2</sup> sal-Sinawi A, Johns AN. *Parapharyngeal solitary fibrous tumour: an incidental finding at ENT examination.* J Laryngol Otol 1994;108:344-7.
- <sup>3</sup> Gangopadhyay K, Taibah K, Manohar MB, Kfoury H. *Solitary fibrous tumor of the parapharyngeal space: a case report and review of the literature.* Ear Nose Throat J 1996;75:681-4.
- <sup>4</sup> Abe T, Murakami A, Inoue T, Ohde S, Yamaguchi T, Watanabe K. *Solitary fibrous tumor arising in the sphenoidal recess: A case report and review of the literature.* Auris Nasus Larynx 2005;32:285-9.
- <sup>5</sup> Casani AP, Marchetti M, Dallan J, Ciancia E, Moscatello L. *Extensive solitary fibrous tumor of the retropharyngeal space.* Head Neck 2006;28:270-4.
- <sup>6</sup> Laco J, Simáková E, Slezák R, Tucek L. *Extrapleural solitary fibrous tumor mimicking lateral neck cyst – a case report.* Cesk Patol 2007;43:68-72.
- <sup>7</sup> Smith LM, Osborne RF. *Solitary fibrous tumor of the maxillary sinus.* Ear Nose Throat J 2007;86:382-3.
- <sup>8</sup> Vo QT, Wolf JA, Turner JW, Murkis M, Saw D, Shemen LJ. *Solitary fibrous tumor of the parapharyngeal space.* Ear Nose Throat J 2007;86:502-5.
- <sup>9</sup> Lo Muzio L, Mascolo M, Capodiferro S, Favia G, Maiorano E. *Solitary fibrous tumor of the oral cavity: the need for an extensive sampling for a correct diagnosis.* J Oral Pathol Med 2007;36:538-42.
- <sup>10</sup> Ridder GJ, Kayser G, Teszler CB, Pfeiffer J. *Solitary fibrous tumors in the head and neck: New insights and implications for diagnosis and treatment.* Ann Otol Rhinol Laryngol 2007;116:265-70.

Received: January 15, 2008 - Accepted: July 25, 2008