

RHINOLOGY

Congenital dacryocystocele: diagnosis and treatment

Dacriocistocele congenito: diagnosi e trattamento

S. CAVAZZA, G.L. LAFFI, L. LODI, G. TASSINARI, D. DALL'OLIO¹Department of Ophthalmology; ¹ Department of Otorhinolaryngology, "Maggiore" Hospital, Bologna, Italy

SUMMARY

Five children were diagnosed with congenital dacryocystocele; in all cases, the cystic lesion was unilateral; age ranged from 7 to 60 days (mean 29 days). The mean ultrasonography diameter of the cyst, at the time of the diagnosis, was 11.51 mm. Topical and systemic antibiotics and massage were prescribed. One patient had no recurrence of the dacryocystocele but 4 showed no improvement with medical treatment; they were submitted to successful probing in the first months of life under general anaesthesia. Nasal endoscopy revealed a nasolacrimal cyst in one patient. True dacryocystocele is relatively rare: ultrasound is a simple, non-invasive method that can reliably distinguish dacryocystocele from other pathological conditions. Several reports have described a variable natural course of these lesions but there are controversial opinions regarding their management. Initially, we treated this congenital anomaly with digital massage, and topical and systemic antibiotics. Probing under general anaesthesia was performed in the event of dacryocystitis or lack of resolution after a short trial period with digital massage. Particular attention was paid to nasal bilateral endoscopy to exclude a nasal obstruction caused by cystic swelling of the nasolacrimal duct. When performed, the probing procedure was successful in all patients.

KEY WORDS: Nasolacrimal duct • Dacryocystocele • Dacryocystitis • Nasolacrimal duct obstruction • Treatment

RIASSUNTO

Sono venuti alla nostra osservazione 5 bambini affetti da dacriocistocele congenito. In tutti la lesione cistica era unilaterale: l'età era compresa tra i 7 ed i 60 gg, età media 29 gg. L'esame ecografico ha evidenziato un diametro medio delle cisti di 11,51 mm. Il trattamento è stato inizialmente di attesa con somministrazione di antibiotici topici e sistemici associati a massaggio. In una bambina questa terapia ha portato alla completa risoluzione dei sintomi nell'arco di 5-6 gg. Quattro, non rispondendo alla terapia medica, sono stati sottoposti a sondaggio delle vie lacrimali, in anestesia generale, con controllo endoscopico della cavità nasale che ha mostrato in un paziente la presenza di una cisti nasolacrimale che è stata marsupializzata. Il dacriocistocele congenito è un'anomalia non comune delle vie lacrimali. L'ecografia permette una corretta e rapida diagnosi differenziale. In letteratura esistono alcuni articoli a riguardo con controversie sul tipo di trattamento da instaurare. Noi abbiamo preferito un iniziale trattamento attendistico con terapia antibiotica associata a massaggio. Il sondaggio delle vie lacrimali associato a controllo endoscopico nasale bilaterale è stato riservato ai bambini che non rispondevano a tale terapia dopo alcuni giorni di controllo o in caso di dacriocistite. La terapia chirurgica ha riportato una completa guarigione in tutti questi pazienti.

PAROLE CHIAVE: Dotto nasolacrimale • Dacriocistocele • Dacriocistiti • Ostruzione dotto nasolacrimale • Terapia

Acta Otorhinolaryngol Ital 2008;28:298-301

Introduction

Congenital dacryocystocele is an uncommon consequence of congenital nasolacrimal duct obstruction: it is believed to occur as a result of a concomitant upper obstruction of the Rosenmuller valve and lower obstruction of the Hasner valve¹⁻³. This causes accumulation of fluid in the drainage system: the sac is initially filled with mucoid material with a grey-blue cystic swelling just below the medial canthus (Figs. 1, 2). Secondary dacryocystitis frequently develops within days or weeks.

Approximately 25% of patients affected have bilateral lesions¹.

The differential diagnosis includes haemangioma, encephalocele, glioma, dermoid cysts and malignant processes^{1,2,4,5}. Ultrasound (US) is a simple and non-invasive method that can be used without sedation to reliably distinguish dacryocystoceles from other pathological conditions. The sonographic appearance (Fig. 3) of a medial cystic mass, in communication with the dilated nasolacrimal duct, in addition to the typical fluid and debris content, pointed to the diagnosis of dacryocystocele^{4,5}. Other more invasive imaging,

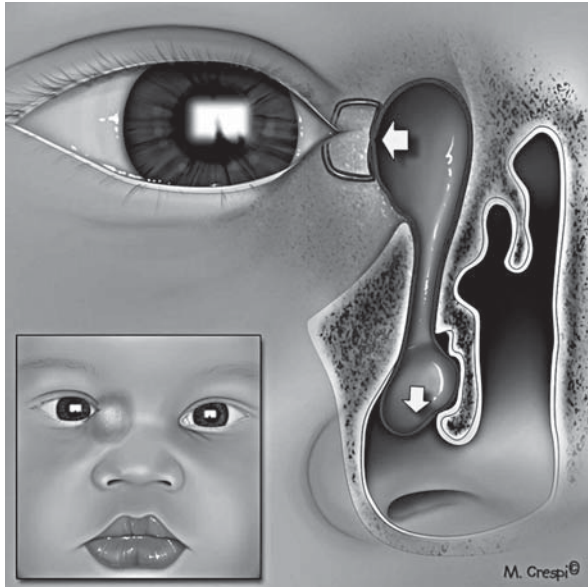


Fig. 1. Schematic drawing of dacryocystocele; arrows indicate occlusion site.

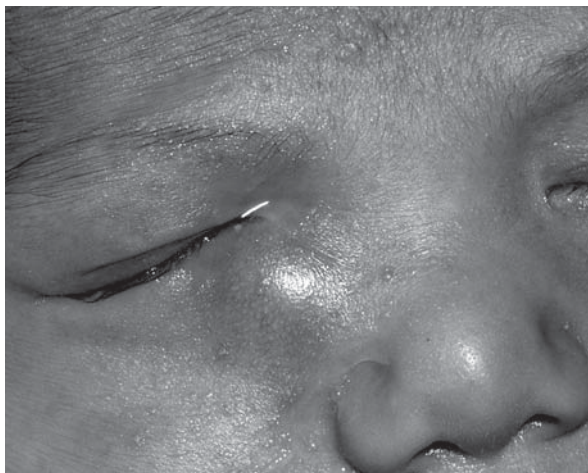

Fig. 2. Right congenital dacryocystocele in neonate of 30 days (P.B.).

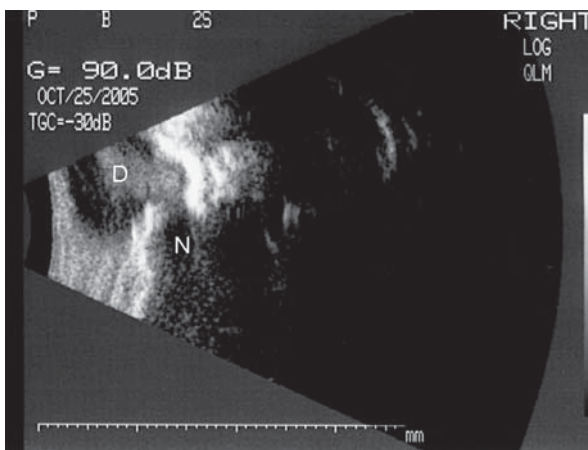


Fig. 3. B-scan of same patient (P.B.) through the dacryocystocele (D) reveals a cavity with an ostium connected to the nasolacrimal duct (N).

such as computed tomography (CT) or magnetic resonance imaging (MRI), is indicated if the US diagnosis is not conclusive: CT has the advantage of detecting bone changes, MRI has the advantage of characterising the cyst contents without exposing the patients to radiation⁶⁻⁸.

The dacryocystocele may extend intra-nasally forming a nasal cyst located in the inferior meatus. The neonates are necessarily nasal breathers so when the nose is obstructed by the cyst these tiny patients will have respiratory distress during feeding and sleeping. Nasal endoscopic examination can reveal the extent of the intra-nasal cyst and assist endo-nasal drainage and marsupialization¹³⁷.

Methods

Five patients diagnosed with dacryocystocele between January 2003 and October 2006 were included in this retrospective study. All patients underwent US imaging: standardised A-scan and contact B-scan examination with a para-ocular approach, with the probe placed in the medial canthal region with a methylcellulose coupling.

Patient management was initially conservative: massage and antibiotics. Failure of this conservative treatment resulted in an endocanalicular and endonasal approach in 4 patients. Informed consent was obtained from the parents in all cases. Under general anaesthesia, after dilation of the superior punctum and the injection of a small amount of a visco-elastic substance, a Bowmann OO probe was passed through the Rosenmuller valve into the lacrimal sac. There was resistance at the sac entry with a reflux of mucoid material: the probe was rotated and directed down the nasolacrimal duct. An obstruction was found at the Hasner valve site. At this point, a 0° rigid endoscope, 2.7 mm in diameter, was placed in the inferior meatus to investigate the nasal extension of the cyst and to monitor the correct placement of the probe and effective syringing.

Prior to endoscopy, topical vasoconstriction was performed with two neurosurgical pledgets soaked in paediatric Otrivine (0.05% xylometazoline hydrochloridine solution).

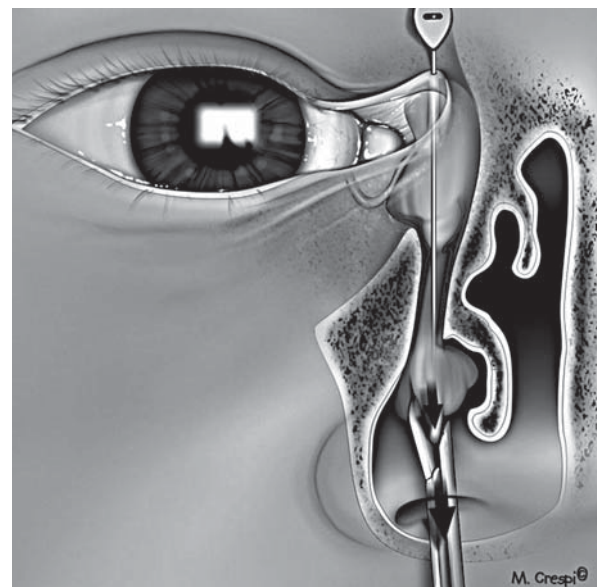


Fig. 4. Schematic drawing of surgical marsupialization of nasolacrimal duct cyst using forceps.

When an intra-nasal cyst was identified, marsupialization with endoscopic excision of the medial wall was performed (Fig. 4). Oral and topical antibiotics were administered for one week after surgery, with massage recommended for one month.

Results

A total of 5 patients (4 female, one male) with unilateral dacryocystocele were treated (Table I).

Age range was 7 to 60 days (mean 29 days). The diameter of the cyst under US ranged from 9.63 to 16.27 mm (mean 11.51 mm). In all cases, US findings confirmed the diagnosis of dacryocystocele: no other imaging was required.

None of the patients showed any symptoms of nasal obstruction. Surgery, under general anaesthesia, was performed in 4 infants with probing and bilateral nasal endoscopy. Surgery was successfully performed in all of these cases.

Associated symptoms: one child had an intra-nasal cyst that required a large endoscopic marsupialization followed by lacrimal duct irrigation, another patient had missed a control visit and developed dacryocystitis.

Follow-up lasted at least 6 months (range 6-36, mean 18.2) no recurrence of symptoms was found.

Discussion

The excretory lacrimal system is first observed in embryos at the 5th week of development and, by the 10th week, formation of a lumen in the lacrimal cord has taken place, coinciding with cavitation of the inferior meatal lamina⁹.

Canalisation of this cord, resulting in communication with the inferior meatus, is the last portion to become patent; this is completed in the period from the sixth foetal month to beyond term¹. If this fails to occur, a membranous barrier frequently forms at the Hasner valve: anatomy studies have reported a 35-73% incidence of imperforate nasolacrimal ducts in the full-term foetus but these resolve spontaneously in 85-95% of cases by the time the patient is a year old^{24,7}. Dacryocystocele is thought to result from the obstruction of two sites in the nasolacrimal system: distal at the Hasner valve, proximal at the Rosenmuller valve. The first obstruction is anatomical, the second is functional and caused by distension of the sac that compresses the canal system causing a trapdoor-type blockage²⁴. In some patients, there is

the co-existence of a functional proximal obstruction and a partial distal obstruction caused by redundant membrane tissue of the Hasner valve, which interferes with, but does not completely obstruct, lacrimal outflow¹⁰. The cyst can be drained rapidly by massage as observed in patient L.D.; however, in some cases, a chronic nasolacrimal system distension can form with subsequent alteration of lacrimal drainage.

A review of the literature showed a predominance of the unilateral lesion and female preponderance, also confirmed in our group of children. We would recommend an initial conservative approach (i.e., warm compresses, massage). Surgical intervention is indicated in the event of dacryocystitis, cellulitis, large cyst causing astigmatism and narrowing of the lid fissure, respiratory difficulty caused by a nasal cyst and non-resolution of the cyst after a short trial period of massage. Nasal examination should be performed in all cases to exclude the coexistence of a nasal cyst responsible for respiratory distress as the infants are necessarily nasal breathers. Both nostrils should be examined, with greater attention being focused on the inferior meatus^{2,10}. The application of topical xylometazoline in the area beneath the inferior turbinate will enhance vision. We also dislocated the inferior turbinate by inserting a Freer elevator in the inferior meatus of the nose and pushing the inferior turbinate medially¹¹. The cystic mass emerged from the inferior turbinate (Fig. 5). Probing alone may not be sufficient for the

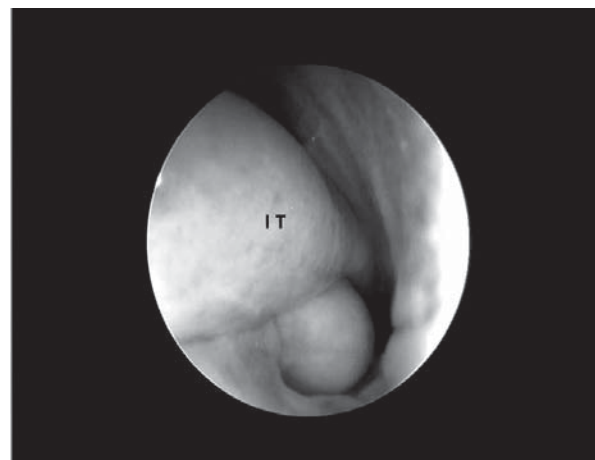


Fig. 5. Endoscopic view of nasolacrimal duct cyst beneath inferior turbinate (IT).

Table I. Congenital dacryocystocele - Patient data.

Patients	Age at onset (days)	Sex	Management	Follow-up (months)	Ultrasound (Horizontal sac diameter) (mm)	Associated symptoms
A.M.	40	M	Probing + nasal endoscopy	24	16.27	None
L.D.	7	F	Massage + antibiotics	36	10.10	None
P.B.	30	F	Probing + nasal endoscopy + marsupialization	16	11.28	Intra-nasal cyst
G.N.	60	F	Massage + antibiotics After 1 month recurrence + fistula Probing + nasal endoscopy	9	10.30	Dacryocystitis with lacrimal sac fistula
S.A.	7	F	Probing + nasal endoscopy	6	9.63	None

treatment of the dacryocystocele associated with nasal cyst: most Authors recommended probing with extensive marsupialization of the cyst to prevent recurrence^{1-3,7,10}. Congenital dacryocystocele with a nasal extension is lined with a pseudo-stratified ciliated mucosa on one side: the inner side is composed of non-ciliated epithelial cells with secretory goblet cells.

US is a rapid and reliable method which can be used to distinguish dacryocystocele from other pathological conditions; sedation is not necessary. B-scan revealed a hollow round cavity with an ostium connected with the nasolacrimal duct (Fig. 3). The A-scan revealed the high reflecting walls and very low internal reflectivity. It is our practice to use an imaging technique if the clinical and US diagnosis are not conclusive. Differential diagnosis included an epidermal dermoid cyst: this is a common lesion of the orbital region which generally becomes apparent during the first decade of life¹². It is quite firm on palpation, located deep in the epidermis and is usually fixed to the underlying bone suture: about 85% of orbital dermoid cysts have bone changes on CT examination. US revealed more internal reflectivity. US imaging may also be useful in the differentiation of vascular lesions that have typically high internal reflectivity. It is crucial to make a conclusive clinical diagnosis of meningo-encephalocele: biopsy is contraindicated due to subsequent cerebrospinal fluid leakage and risk of meningitis⁷⁻¹². Differentiation with non-inflamed dacryocystocele

can be difficult because it characteristically appears at, or shortly after, birth as a pulsating swelling at the medial canthus: careful examination with CT imaging usually highlights the bone defect that causes protrusion of the brain tissue¹².

Once diagnosis has been made, medical treatment is started and after 8-10 days, if the child has not improved, probing is performed. We agree with Becker¹³ that early probing minimizes the risk of dacryocystitis and leads to a greater success rate.

Conclusion

In our cases, the clinical and US appearance of a cystic mass, medial and inferior to the orbit with an ostium connecting with a dilated nasolacrimal duct in addition to the typical content of fluid and debris, indicated a diagnosis of dacryocystocele. Other more invasive imaging, such as CT scan that provides excellent detailed information on the nasal bone anatomy and MRI that offers additional soft tissue delineation, should be considered only if the US diagnosis is not conclusive. Bilateral nasal endoscopy is essential during the work up of all children: in neonatal patients, acute dacryocystitis and cellulitis should give rise to the suspicion of the coexistence of an intranasal cyst¹⁴.

Our study also showed the efficacy of early probing; however, a randomised study is needed to confirm this opinion.

References

- 1 Olver J. *Pediatric lacrimal surgery* In: Olver J, ed. *Colour atlas of lacrimal surgery*. Oxford: Butterworth Heinemann; 2002. p. 70-89.
- 2 Shashy RG, Durairaj V, Holmes JM, Hohberger GG, Thompson DM, Kasperbauer JL. *Congenital dacryocystocele associated with intranasal cysts: diagnosis and management*. Laryngoscope 2003;113:37-40.
- 3 Grin TR, Mertz JS, Stass-Isern M. *Congenital nasolacrimal duct cysts in dacryocystocele*. Ophthalmol 1991;98:1238-42.
- 4 Mansour AM, Cheng KP, Mumma JV, Stager DR, Harris GJ, Patrinely JR, et al. *Congenital dacryocystocele. A collaborative review*. Ophthalmol 1991;98:1744-51.
- 5 Schlenck B, Unsinn K, Geley T, Schon A, Gassner I. *Sonographic diagnosis of congenital dacryocystocele*. Ultraschall Med 2002;23:181-4.
- 6 Teixeira CC, Dias RJ, Falcao-Reis FM, Santos M. *Congenital dacryocystocele with intranasal extension*. Eur J Ophthalmol 2005;145:126-8.
- 7 Roy D, Guevara J, Castillo L. *Endoscopic marsupialization of congenital duct cyst with dacryocystocele*. Clin Otolaryngol 2002;27:167-70.
- 8 Farrer RS, Mohammed TL, Hahn FJ. *MRI of childhood dacryocystocele*. Neuroradiology 2003;45:259-61.
- 9 De la Caudra-Blanco C, Peces-Pena MD, Janez-Escalada L, Merida-Velasco JR. *Morphogenesis of the human excretory lacrimal system*. J Anat 2006;209:127-35.
- 10 Cunningham MJ. *Endoscopic techniques in the management of pediatric nasolacrimal anomalies*. In: Woog JJ, ed. *Manual of endoscopic lacrimal and orbital surgery*. Philadelphia: Butterworth Heinemann 2004. pp. 155-73.
- 11 Ram B, Barras CW, White PS, McEwen CJ, Young JDH. *The technique of nasendoscopy in the evaluation of nasolacrimal duct in children*. Rhinology 2000;38:83-6.
- 12 Shields JA, Shields CL. *Orbital cysts of childhood - classification clinical features, and management*. Surv Ophthalmol 2004;49:281-99.
- 13 Becker BB. *The treatment of congenital dacryocystocele*. Am J Ophthalmol 2006;142:835-8.
- 14 Campolattaro BM, Lueder GT, Tychsen L. *Spectrum of pediatric dacryocystitis: medical and surgical management of 54 cases*. J Pediatr Ophthalmol Strabismus 1997;34:143-53.

Received: August 30, 2007 - Accepted: March 1, 2008