

VESTIBOLOGY

Converting apogeotropic into geotropic lateral canalolithiasis by head-pitching manoeuvre in the sitting position

Conversione apogeotropa-geotropa della canalolithiasi laterale mediante manovra di flessione-estensione cefalica in posizione seduta

L. CALIFANO, M.G. MELILLO, S. MAZZONE¹, A. VASSALLOUnit of Audiology and Phoniatrics, ENT Clinic, "G. Rummo" Hospital, Benevento; ¹ ENT Clinic, "Federico II" University, Naples, Italy

SUMMARY

Liberatory treatment of lateral canalolithiasis is more effective for the geotropic, than for the apogeotropic forms and, therefore, it is worthwhile attempting to convert the apogeotropic forms into the geotropic forms. In 36 cases of apogeotropic lateral canalolithiasis, one to five Head-Pitch Manoeuvres were performed in the sitting position (Head-Pitch Test) in the attempt to transform apogeotropic into geotropic lateral canalolithiasis. The Head Pitch Test was performed by a quick 60° forward-flexion and a slow maximal backward-extension of the head. The Head-Pitch Test was effective in 36.1% of cases, less than the repeated Head-Rolling in the supine position, but it was always well tolerated by patients. The quick 60° forward-flexion of the head can evoke a horizontal nystagmus beating towards the healthy side in apogeotropic lateral canalolithiasis and towards the affected side in geotropic lateral canalolithiasis (Bow Nystagmus). Slow backward-extension of the head can evoke a horizontal nystagmus beating towards the affected side in apogeotropic lateral canalolithiasis and toward the healthy side in geotropic lateral canalolithiasis (Lean Nystagmus). Conversion from apogeotropic to geotropic lateral canalolithiasis by the Head-Pitch Test was effective when Bow and Lean Nystagmus changed directions or when the Head-Pitch Test evoked Bow Nystagmus toward the affected side and Lean Nystagmus toward the healthy side. Conversion occurred in 10 patients during the 60° forward-flexion of the head. In contrast, in 3 patients, it occurred during extension of the head, when a "Lean Nystagmus" toward the healthy side appeared. In addition, Pseudospontaneous Nystagmus and Positioning Nystagmus that arose when the patient moved from the sitting to the supine position changed direction or were evoked ex-novo, both directed toward the healthy side. In all cases, Pagnini-McClure diagnostic manoeuvre confirmed the transformation with a Positional Paroxysmal Horizontal Geotropic Nystagmus, which was more intense when the affected ear was brought down. The Head-Pitch Test can be used as the method of choice to transform apogeotropic into geotropic lateral canalolithiasis. However, anterior flexion of the head in the geotropic forms must be avoided since involuntary and harmful transformations from the geotropic into the apogeotropic form can occur, moving otoliths towards the anterior arm and cupula.

KEY WORDS: Canalolithiasis • Lateral Canalolithiasis • Paroxysmal Nystagmus • Pseudospontaneous Nystagmus • Head Pitch Test

RIASSUNTO

Le forme apogeotrope delle canalolithiasi laterali hanno un peggiore outcome terapeutico rispetto a quelle geotrope. Per tale motivo, è diffusa opinione che sia utile cercare di convertire le forme apogeotrope in forme geotrope. Ciò è ottenibile attraverso la ripetuta esecuzione di manovre di laterorotazione cefalica in posizione supina, rapidamente verso il lato sano, lentamente verso quello malato. Tale manovra, però, è spesso accompagnata da intensi fenomeni neurovegetativi che ne limitano l'esecuzione. Grazie ad un'osservazione inizialmente casuale in un nostro precedente studio sulle canalolithiasi laterali apogeotrope, notammo come l'esecuzione ripetuta di manovre di flessione-estensione del collo in posizione seduta (Head-Pitch Test) potesse determinare la conversione apogeotropa-geotropa. Nel presente studio, abbiamo quindi applicato tale metodica ad una popolazione di 36 canalolithiasi laterali apogeotrope, eseguendo da una a cinque manovre di flessione-estensione della testa in posizione seduta. La geotropizzazione è stata indicata dal cambio di direzione dei nistagmi precedentemente osservati in flessione anteriore di 60° ed in massima estensione del capo (Bow e Lean Nystagmus) o dalla comparsa ex-novo di tali nistagmi, con direzioni compatibili con una forma geotropa: "Bow Nystagmus" verso il lato malato, "Lean Nystagmus" verso il lato sano. Elemento di conferma decisivo è sempre stata la comparsa di nistagmo parossistico biposizionale bidirezionale geotropo evocato dalla manovra diagnostica di Pagnini-McClure. La manovra trasformante di flessione-estensione in posizione seduta, pur con una limitata efficacia (36,1% dei casi), inferiore a quanto riportato in Letteratura per la manovra di laterorotazione ripetuta della testa in posizione supina, probabilmente migliorabile aumentando il numero delle manovre eseguite, è apparsa però molto ben tollerata dai pazienti, provocando scarsi effetti neurovegetativi. Essa, pertanto, appare consigliabile, come primo approccio, in tutti i casi di canalolithiasi laterale apogeotropa per ottenerne la trasformazione nella forma geotropa, riservando l'uso della tecnica di laterorotazione ripetuta della testa in posizione supina alle forme non responsive. La fase di flessione anteriore della testa va invece evitata nelle forme geotrope, in quanto può, al contrario, determinare, la non conveniente conversione della canalolithiasi laterale da geotropa ad apogeotropa.

PAROLE CHIAVE: Canalolithiasi • Canalolithiasi laterale • Nistagmo parossistico • Nistagmo pseudospontaneo • Nistagmo da flessione cefalica • Nistagmo da estensione cefalica

Introduction

Lateral labyrintholithiasis is diagnosed with the supine head roll test (Pagnini-McClure Manoeuvre).

This test evokes a Positional Paroxysmal Horizontal Nystagmus that changes direction depending on the downward ear¹⁻³.

It can occur in the geotropic form, with fast phases directed toward the gravitational field and toward the lowermost ear or in the apogeotropic form, with fast phases opposite to the gravitational field and toward the uppermost ear. In the geotropic form, otoliths are in the posterior arm of the lateral canal, and in the apogeotropic form they are closer to the ampulla, free-floating in the anterior arm (canalolithiasis) or attached to the cupula (cupulolithiasis).

In the geotropic form, the Positional Paroxysmal Horizontal Nystagmus is more intense when the affected side is at the bottom, as this position stimulates an ampullopetal endolymphatic flow, causing an excitatory response, according to Ewald's 2nd law.

When the affected side is at the top, otoliths move in the opposite direction, provoking an inhibitory ampullopugal endolymphatic flow and a less intense nystagmus.

In contrast, in the apogeotropic form, the Positional Paroxysmal Horizontal Nystagmus is more intense when the affected ear is at the top, since this position provokes an ampullopetal, excitatory endolymphatic flow.

The liberatory treatment of lateral canalolithiasis is more effective for the geotropic forms than for the apogeotropic forms⁴.

Moreover, for apogeotropic lateral canalolithiasis, some therapeutic manoeuvres, such as Gufoni's manoeuvre^{4,5} or Vannucchi's "Prolonged Forced Position"⁶, need two-step treatment: the first step is toward the affected side and the second step, when a Positional Paroxysmal Horizontal Geotropic Nystagmus is evoked during the Pagnini-McClure Manoeuvre, is toward the healthy side.

For these reasons, it seems rational to attempt to convert apogeotropic forms of lateral canalolithiasis into geotropic forms to improve responses to therapeutic manoeuvres.

Manoeuvres usually described to transform Positional Paroxysmal Horizontal Apogeotropic Nystagmus are repeated rotation of the head to the right and to the left in the supine position⁷, quickly toward the healthy side and slowly toward the affected ear, and the first step of Gufoni's Manoeuvre^{4,5}.

The quick movement should move otoliths away from the cupula by inertial forces and the slow movement should complete the migration toward the utricle by gravitational forces.

The manoeuvre is effective in approximately 60% of cases⁷, but this effort is often negatively affected by the intense neurovegetative phenomena occurring due to the repeated rotations of the head, which often do not allow the manoeuvre to be carried out.

The clinical observation of patients in the sitting position offered us a possible alternative method to transform apogeotropic forms into geotropic forms of lateral canalolithiasis.

In a previous study on the accessory signs of lateral apogeotropic canalolithiasis⁸, when the Head-Pitch Test (HPT) was performed, in some cases, conversion from apogeotropic to geotropic lateral canalolithiasis was achieved.

HPT was described as a diagnostic procedure by Choung et al.⁹ when searching for "Bow and Lean" Nystagmus and by Asprella-Libonati^{10,11} in the evaluation of Pseudospontaneous Nystagmus.

Aim of the present investigation was to evaluate the apogeotropic to geotropic transformation of the nystagmus using HPT in the sitting position, reducing the patient's burden.

No comparison was made between HPT and other possible methods (Head-Rolling in the supine position; first step of Gufoni's Manoeuvre).

Patients and methods

From August 2007 to April 2008, 36 patients (21 female, 15 male) with apogeotropic lateral canalolithiasis (20 right, 16 left) were enrolled, representing 39.1% of the 92 cases of lateral labyrintholithiasis observed in the same period. Observations were carried out using Infrared Videonystagmography.

A diagnosis of apogeotropic lateral canalolithiasis was made if the Pagnini-McClure diagnostic manoeuvre provoked a Positional Paroxysmal Horizontal Apogeotropic Nystagmus.

The nystagmus was clearly more intense on the healthy side in 29 cases, but in 7 cases, it was necessary to look for the so-called "accessory signs" to identify the affected side: Head-Shaking Induced Nystagmus (HSIN), Bow and Lean Nystagmus⁹, Pseudospontaneous Nystagmus^{10,11}, Head-Bending Nystagmus¹², Positioning Nystagmus from the sitting to the supine position^{13,14}, Null-point^{15,16} and Spontaneous inversion of Paroxysmal Nystagmus.

Once the Positional Paroxysmal Horizontal Nystagmus was identified, patients were again placed in the sitting position and HPT (one to five Head-Pitch manoeuvres) was carried out in the attempt to obtain conversion from apogeotropic to geotropic lateral canalolithiasis. HPT was performed by quick 60°-flexion forwards and slow extension backwards of the head.

The transformation from apogeotropic forms to geotropic forms of lateral canalolithiasis by HPT was effective when:

- the nystagmus changed direction either with the 60° forward-flexion or with the backward extension of the head in the sitting position;
- or HPT evoked, in these positions, the Bow Nystagmus toward the affected side and the Lean Nystagmus toward the healthy side.

In each patient, conversion of apogeotropic to geotropic lateral canalolithiasis was confirmed by the appearance of Positional Paroxysmal Horizontal Geotropic Nystagmus during the Pagnini-McClure Manoeuvre.

In cases non-responsive to HPT, one to five manoeuvres of Head-Rolling in the supine position were performed in the attempt to obtain the transformation.

Results

The Pagnini-McClure Manoeuvre was the definitive diagnostic test for the diagnosis of apogeotropic lateral canalolithiasis, allowing identification of the pathological side in 29/36 cases. The affected side was not identified in the remaining 7 cases, as no clear difference, in nystagmus intensity, was present between the two sides.

Table 1. Accessory signs of laterality

	(%)
Pseudospontaneous Nystagmus	21/36 (58.3)
Bow and Lean Nystagmus	14/36 (38.8)
Head-Bending Nystagmus	22/36 (61.1)
Positional Nystagmus from sitting to supine position	28/36 (77.8)
Null-point in the yaw-plane	16/36 (44.4)
Deficitary HSIN	22/36 (61.1)
Spontaneous inversion of Paroxysmal Nystagmus	13/36 (36.1)

In these patients, it was necessary to look for the accessory signs of laterality (Table I).

These were always concordant in defining the affected ear, except in one case, in which the Nystagmus in the supine position gave a wrong indication as it was directed towards the healthy side.

Pseudospontaneous Nystagmus was observed in 21 cases (58.3%), which was always directed toward the affected side; "Head-Bending Nystagmus" was present in 22 cases (61.1%), and always directed toward the healthy side; the "Bow and Lean" test was positive in 14 cases (38.8%), with the Bow-Nystagmus always directed toward the healthy side and the Lean-Nystagmus always directed toward the affected side.

HSIN (fast phases toward the healthy side) was observed in 22 cases (61.1%).

HPT in the sitting position was effective in transforming apogeotropic into geotropic lateral canalolithiasis in 13 cases (36.1%).

The conversion occurred in 10 patients during the 60° forward-flexion of the head and was indicated by a horizontal nystagmus beating toward the affected side.

In contrast, in 3 patients, this occurred during extension of the head, when a "Lean Nystagmus" toward the healthy side appeared.

Conversion of apogeotropic into the geotropic form was accompanied by the patient's subjective feeling that vertiginous symptoms increased.

Vertigo was always well tolerated and quickly reversible with straightening of patients' heads.

Accessory signs of laterality, if any, changed their direction. The Pseudospontaneous Nystagmus (6 cases) and Nystagmus evoked by positioning from sitting to supine (10 cases) were now directed toward the healthy side.

In 8 cases, Pseudospontaneous Nystagmus appeared ex-novo after HPT: in 5 cases, when the transformation occurred, it was directed toward the healthy side and in 3 cases, when the lateral canalolithiasis remained apogeotropic, it beat towards toward the affected side.

The HSIN always maintained its direction toward the healthy side (22 cases).

In all cases, Positional Paroxysmal Horizontal Geotropic Nystagmus, evoked by the Pagnini-McClure Manoeuvre confirmed the transformation.

When HPT failed (23/36 cases), we performed one to five Head-Rolling manoeuvres in the supine position, quickly toward the healthy side and slowly toward the affected ear. Conversion of apogeotropic forms into geotropic forms of canalolithiasis were obtained in the other 9 out of 23 cases

(39.1%), but in 7 of the 23 cases, attempts were stopped after two to three repetitions on account of onset of intense neurovegetative symptoms.

Discussion

The conversion from apogeotropic to geotropic lateral canalolithiasis is considered a useful step for the treatment since the geotropic form is generally more responsive.

Nevertheless, the frequent onset of intense neurovegetative phenomena limits the manoeuvre usually adopted for this purpose (repeated head rolling in the supine position)⁷, that leads to vertigo during all its repetitions.

New semeiotic signs have recently been described, such as "Bow and Lean" Nystagmus⁹, Head-Bending Nystagmus¹², and Pseudospontaneous Nystagmus^{10 11}.

These can be used as ancillary data for the diagnosis of the affected side in lateral canalolithiasis.

In a previous survey, presented at the XXXI National Congress of the Italian Society of Audiology and Foniatics⁸, we determined the frequency and diagnostic importance of "accessory signs of laterality" and it was observed that, sometimes, the HPT in the sitting position caused the transformation from apogeotropic to geotropic lateral canalolithiasis, which was always confirmed by the Pagnini-McClure Manoeuvre.

This observation prompted us to use HPT in the attempt to transform apogeotropic into geotropic lateral canalolithiasis. Head-Pitching manoeuvres were applied, repeated from 1-5 times in the sitting position in 36 patients, in the attempt to convert the apogeotropic lateral canalolithiasis to the more treatment-responsive geotropic forms.

HPT was effective in 13 cases (36.1%): it changed the direction of the Bow and Lean Nystagmus, if already present, or caused the ex-novo appearance of the Bow Nystagmus directed towards the affected side and of the Lean Nystagmus towards the healthy side.

Also, other accessory signs (Pseudospontaneous Nystagmus and Nystagmus evoked by positioning from the sitting to the supine position), changed their direction or appeared ex-novo, directed towards the healthy side.

HSIN always maintained its direction towards the healthy side, as this sign was not related to the position of otoliths in the canal, but to a reduced response of the lateral canal.

The pathophysiology of Pseudospontaneous Nystagmus (Fig. 1), Bow and Lean Nystagmus (Figs. 2, 3), Positioning

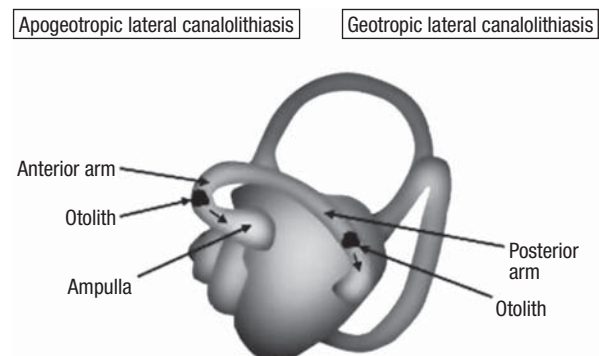


Fig. 1. Possible mechanism of Pseudospontaneous Nystagmus in apogeotropic and geotropic canalolithiasis in sitting position. Straight head (left lateral canal: lateral view).

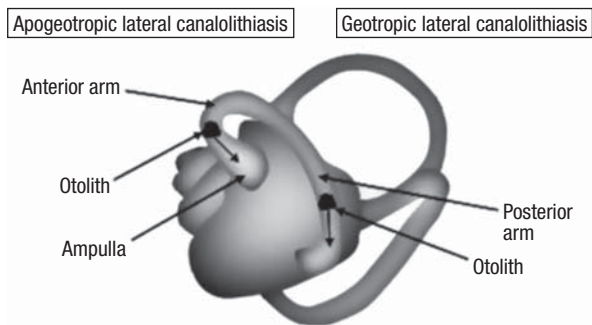


Fig. 2. Mechanism of the Lean Nystagmus in apogeotropic and geotropic canalolithiasis (left lateral canal: lateral view).

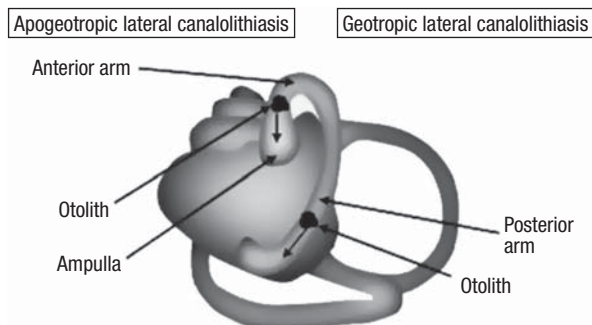


Fig. 4. Mechanism of Positioning Nystagmus from sitting to supine position in apogeotropic and geotropic lateral canalolithiasis (left lateral canal: lateral view).

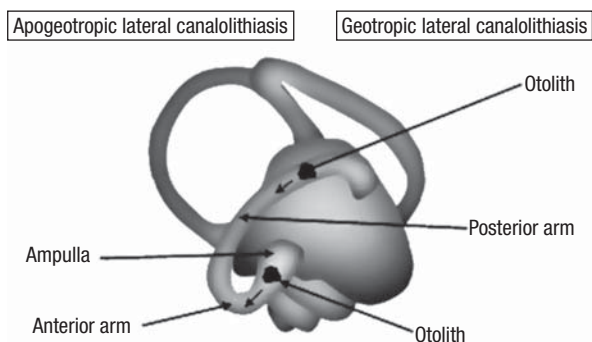


Fig. 3. Mechanism of the Bow Nystagmus in apogeotropic and geotropic canalolithiasis (left lateral canal: lateral view).

movement provokes the Bow Nystagmus towards the healthy side, and the Pseudospontaneous Nystagmus, the Lean Nystagmus and the Positioning Nystagmus from the sitting to the supine position towards the affected side. During the quick 60° forward-flexion, it is possible that otoliths move towards the posterior arm (Fig. 5), like a golf ball hit by a club.

During the slow movement of the backward-extension, gravitational forces cause otoliths to continue their floating along the posterior arm of the lateral canal, like golf balls sliding down towards the hole.

This changes the direction of the Bow-Nystagmus, now directed towards the affected side and of the Lean-Nystagmus and of the Positioning Nystagmus from a sitting to a supine position, which are now directed toward the healthy side.

We would expect the transformation of the apogeotropic, into the geotropic, form to occur during the brisk forward flexion of the head, but in 3 cases this was observed during backward extension.

Perhaps, this depends on the initial position of the otoconia

Nystagmus from sitting to supine position (Fig. 4) and the transformation from apogeotropic to geotropic canalolithiasis, are in keeping with the theory of canalolithiasis. In the apogeotropic form, otoliths are placed in the anterior arm of the lateral canal. They move as if they are on an inclined plane and their



Sitting position
Straight head

The brisk 60° flexion of the head could cause otoliths to move toward the posterior arm

The extension of the head could cause otoliths to complete their shift

Fig. 5. Possible mechanism of transforming apogeotropic into geotropic lateral canalolithiasis by the Head-Pitch manoeuvre (left lateral canal: lateral view).

in the anterior arm of the lateral canal: when closer to the cupula, they need a longer time to arrive in the posterior arm. In these cases, the backward extension of the head, in our opinion, caused otoliths to continue their posterior movement by gravitational forces, but the beginning of their floating would always be during the brisk anterior flexion. It is better to avoid brisk movements in the backward extension of the head, since inertial forces could cause otoliths to move towards the anterior arm.

The manoeuvre may possibly be effective when otoliths are not too close and not attached to the cupula.

We agree with Lee et al.¹² and Steddin et al.¹⁷ that anterior flexion of the head, in the sitting position, should be avoided in geotropic lateral canalolithiasis, because involuntary and harmful transformations from the geotropic, into the apogeotropic, form can occur, moving otoliths toward the anterior arm and the cupula.

Conclusions

The first and most important step remains the diagnosis by means of the Pagnini-McClure Manoeuvre, as it is essen-

tial to know whether a lateral canalolithiasis is geotropic or apogeotropic.

Only in apogeotropic cases, should HPT be performed in the sitting position.

It is a diagnostic tool that is useful in identifying the affected side or to determine whether conversion from apogeotropic lateral canalolithiasis into the geotropic form is needed.

HPT was effective in 36.1%.

Probably its effectiveness would be further increased by increasing the number of attempts.

HPT is less effective than repeated Head-Rolling in the supine position⁷ and than the first step of the Gufoni's Manoeuvre⁵, but it is easy to perform and well tolerated.

Therefore, HPT can be used as the first tool to transform apogeotropic into geotropic lateral canalolithiasis, while we advise performing Head-Rolling only for apogeotropic lateral canalolithiasis not-responsive to HPT.

Acknowledgements

Authors thank Carmina Meola for contributing to English translation and Nazzareno Manzo for illustrations.

References

- Cipparrone L, Corridi G, Pagnini P. *Cupulolithiasi*. In: Boots-Formenti editors. V Giornata Italiana di Nistagmografia Clinica; Milano: 1985; p. 36-53.
- McClure A. *Lateral canal BPV*. J Otolaryngol 1985;14:30-5.
- Pagnini P, Nuti D, Vannucchi P. *Benign paroxysmal vertigo of the horizontal canal*. ORL J Otorhinolaryngol Relat Spec 1989;1:161-70.
- Gufoni M. *Treatment of lithiasis of the lateral semicircular canal*. In: Guidetti G, Pagnini P, editors. *Labyrintholithiasis-related paroxysmal positional vertigo*. Excerpta Medica 2002; p. 103-12.
- Gufoni M, Mastrosimone L. *Trattamento con manovra di riposizionamento per la canalolithiasi orizzontale*. Acta Otorhinolaryngol Ital 1998;18:363-7.
- Vannucchi P, Giannoni B, Giuffreda P, Paradiso P, Pagnini P. *The therapy of benign paroxysmal positional vertigo of the lateral semicircular canal*. In: Versino M, Zambardieri D, editors. *International workshop on eye movements*. Pavia: 1994; p. 321-4.
- Nuti D, Agus G, Barbieri MT, Passali D. *The management of horizontal-canal paroxysmal positional vertigo*. Acta Otolaryngol (Stockh) 1998;118:455-60.
- Califano L, Vassallo A, Melillo MG, Mazzone S. *Segni di lato in 32 canalolithiasi laterali apogeotrope*. Audiologia Newsletter 2007;12:36.
- Choung Y-H, Shin YR, Kahng H, Park K, Choi SJ. "Bow and Lean test" to determine the affected ear of horizontal canal benign paroxysmal positional vertigo. Laryngoscope 2006;116:1776-81.
- Asprella-Libonati G. *Diagnostic and treatment strategy of lateral semicircular canal canalolithiasis*. Acta Otorhinolaryngol Ital 2005;25:277-83.
- Asprella-Libonati G. *Pseudo-spontaneous nystagmus: a new sign to diagnose the affected side in lateral semicircular canal benign paroxysmal positional vertigo*. Acta Otorhinolaryngologica Italica 2008;28:73-8.
- Lee S-H, Choi K-D, Jeong S-H, Oh Y-M, Koo J-W, Kim JS. *Nystagmus during neck flexion in the pitch plane in benign paroxysmal positional vertigo involving the horizontal canal*. J Neurol Sci 2007;256:75-80.
- Nuti D, Vannucchi P, Pagnini P. *Benign paroxysmal positional vertigo of the horizontal canal: a form of canalolithiasis with variable clinical features*. J Vest Res 1996;6:173-84.
- Nuti D, Vannucchi P, Pagnini P. *Lateral Canal BPPV: which is the Affected Side?* Audiol Med 2005;3:16-20.
- Bissdorff AR, Debatisse D. *Localizing signs in positional vertigo due to lateral cupulolithiasis*. Neurology 2001;57:1085-8.
- Bergenius J, Tomanovic T. *Persistent geotropic nystagmus - a different kind of cupular pathology and its localizing signs*. Acta Oto-Laryngol (Stockh) 2006;126:698-704.
- Steddin S, Ing D, Brandt T. *Horizontal canal benign paroxysmal positioning vertigo (h-BPPV): transition of canalolithiasis to cupulolithiasis*. Ann Neurol 1996;40:918-22.

Received: July 17, 2008 - Accepted: October 18, 2008

The work was carried out at the Unit of Audiology and Phoniatrics, ENT Clinic, "G. Rummo" Hospital, Benevento, Italy

Address for correspondence: Dr. L. Califano, via A. Lepore 4 bis, 82100 Benevento, Italy. Fax +39 082 4311467.

E-mail: luigi.califano@tin.it - vertigobn@hotmail.com