

ONCOLOGY

IFHNOS Global Continuing Education Program

Current Concepts in Head & Neck Surgery and Oncology 2008



Introduction

The International Federation of Head and Neck Oncologic Societies (IFHNOS) is offering a global continuing medical education program worldwide in order to offer possibility to as many individuals as possible to meet the Leaders in the specialty of head and neck oncology. They will provide state of the art knowledge and explore its diagnostic and therapeutic frontiers and will underline the multidisciplinary which is typical of head and neck oncology.

This program will cover several part of the world in sequence, and it will offer opportunities of interactive sections between the local faculty, attendees and the travelling faculty. In October 2008 this CME program will make a stop in Rome.

This is the first global medical and oncological enterprise, and *Acta Otorhinolaryngologica Italica* would like to underline the importance and uniqueness of this event publishing the texts of the travelling faculty lectures.

FAUSTO CHIESA, M.D.
Editor, *Acta Otorhinolaryngologica Italica*

Foreword

It is a great pleasure and honour to host in Rome the Region-three step of the I.F.H.N.O.S. World Tour "Current Concepts in Head & Neck Surgery and Oncology", organized under the aegis of the International Federation of Head and Neck Oncology Society.

The meeting wants to present the updated state of the art of the different aspects of head and neck surgery, radiotherapy and medical oncology in the treatment of head and neck cancer, as part of Global Continuing Education Program.

It is composed by nine lectures, delivered by the worldwide well known members of the international touring faculty (J.P. Shah, J.L. Lefebvre, P. Gullane, A. Forastiere, W. Wei, C. O'Brien, K.K. Ang), about the diagnosis and treatment key points of the most relevant items concerning head and neck surgery and oncology. Any lecture will be followed by a round table, whose panellists will be members of Regional Faculty, in which clinical case reports will be presented and discussed.

This present special chapter of *Acta Otorhinolaryngologica Italica* collects all the respective abstracts with the purpose of put together the state-of-the-art knowledge on principal arguments of head and neck surgery and oncology. The scientific value of this chapter is due to the unique professional level of the illustrious Authors. I highly recommended the reading of this one to the trainees and practitioner of head and neck surgery, radiotherapy and oncology to gain up to date knowledge in the management of this items.

GIUSEPPE SPRIANO, M.D.
Chief of Otolaryngology Head and Neck Surgery Department
National Cancer Institute "Regina Elena" Rome, Italy

Oral cancer

J.P. SHAH
Memorial Sloan-Kettering Cancer Center, New York,
U.S.A.

Oral cancer is the sixth most common cancer worldwide and accounts for over a half a million new patients diagnosed each year. The incidence of oral carcinoma has significant geographic variation. Southeast Asia, Brazil, Southern and Eastern Europe and Australia report a significantly high incidence of oral cancer. Alcohol and tobacco consumption are the most common etiologic agents. Chewing tobacco and betel quid are the most common etiologic agents in

Southeast Asia. In the past decade, infection with Human Papillomavirus has emerged as a common associated factor in non-smoking and non-drinking young individuals in both sexes. The gender distribution of oral cancer over the past several decades shows that there is a rising incidence of oral cancer in women.

The treatment goals for oral cancer clearly are to eradicate the cancer, preserve or restore form and function, avoid or minimize the sequelae of treatment and prevent second primary tumors. The treatment modalities available to achieve these goals are surgery, radiotherapy, chemotherapy either alone or in combination.

The factors that influence the choice of initial treatment for

primary carcinomas of the oral cavity are dependent on the characteristics of the primary tumor (tumor factors), such as site, size, location, proximity to bone and the status of cervical lymph nodes. In addition to this, factors related to the patient (patient factors) and those related to the treatment team providing care to the patient (physician factors), are also important. In general, oral cancer is primarily treated with surgery as initial definitive treatment either alone or in combination with radiotherapy or radiochemotherapy.

Tumor factors

The size of the primary tumor has a clear impact on the decision regarding the choice of initial treatment. Small and superficial primary tumors of the oral cavity are easily accessible for surgical resection through the open mouth. On the other hand, larger tumors will require more extensive surgical approaches for exposure and excision. Certain primary sites in the oral cavity are easily amenable to initial treatment with radiotherapy, such as primary tumors of the lip and tongue, in contrast to those which are situated in proximity to bone, such as tumors of the gum and hard palate. Similarly, with increasing size (T stage) of the primary lesion, the risk of regional lymph node metastases increases, bringing into consideration the need for elective treatment of the neck. Also, certain primary sites have a higher risk of nodal metastases compared to other sites in the oral cavity. For example, primary tumors of the oral tongue and floor of mouth have an increased risk of lymph node metastases compared to similar staged lesions of the hard palate or upper gum. Primary tumors located anteriorly in the oral cavity have a lesser risk for dissemination to regional lymph nodes compared to similar staged tumors in the posterior part of the oral cavity and oropharynx. For example, primary tumors of the oral tongue versus base of the tongue. Thus, more posteriorly located lesions require consideration of elective treatment of the clinically negative neck in initial treatment planning.

The histology of the primary tumor is an important parameter which will influence the selection of initial treatment. The histological grade of the lesion generally reflects the aggressiveness of the tumor. Poorly differentiated carcinomas and undifferentiated carcinomas are predictably more aggressive in comparison to well differentiated carcinomas. However the most important histologic feature of the primary tumor which has an impact on selection of treatment and eventual prognosis is its depth of infiltration. Thin and superficially invasive lesions have a lower risk of regional lymph node metastases, are highly curable and offer an excellent prognosis. On the other hand, thicker lesions which are deeply infiltrating the underlying soft tissue have a significantly increased incidence of regional lymph node metastases with its adverse impact on prognosis (Fig. 1). The risk of lymph node metastases and survival in relation to thickness of the primary lesions for T1 and T2 squamous carcinomas of the oral tongue and floor of mouth is shown in Figure 1. While it would be desirable to know the thickness of the lesion prior to surgical intervention, it is clinically impractical to have that information available prior to surgical excision of the primary tumor in most instances. More recent studies suggest that 4 mm is a reasonably good cut off line for low versus high risk of occult regional lymph node metastases. In general, however, thickness of the le-

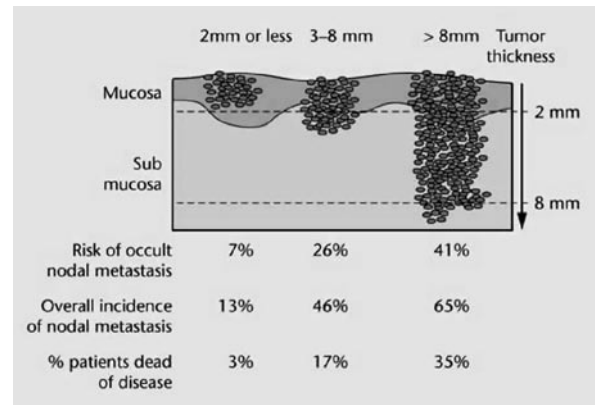


Fig. 1. Tumor thickness and risk of nodal metastases and death for T1 and T2 cancers of the tongue.

sion as appreciated by palpation is a reasonably good indicator of deeply invasive lesions versus superficial lesions to estimate the extent of soft tissue infiltration and the need for elective dissection of regional lymph nodes at risk in the clinically negative neck.

Patients with advanced stage disease, that is those presenting with spread to regional cervical lymph nodes or with large primary tumors (T3 and T4), are candidates for consideration of combined modality treatment. Currently, surgical resection followed by postoperative radiation therapy or postoperative chemoradiotherapy is considered the standard of treatment for patients with Stage III and Stage IV disease. The indications for postoperative chemoradiotherapy are advanced primary tumors resected with positive margins or patients with cervical lymph node metastases manifesting extranodal extension. The increased and intensely acute short term toxicity and significant long term sequelae of adding chemotherapy are clearly much higher than radiation therapy alone.

Patient factors

Several factors related to patient characteristics are important in selection of treatment. The patient's age, general medical condition, co-morbid conditions, lifestyle (smoking and drinking), tolerance to treatment, occupation, acceptance and compliance by the patient and other socio-economic considerations are important 'other' factors. In general, older age is not considered to be a contraindication for implementation of adequate initial surgical treatment for oral carcinoma. However, advancing age, intercurrent disease and debility due to associated cardio-pulmonary conditions add to the co-morbid conditions and make implementation of extensive surgical intervention an increased risk. The ability of the patient to tolerate an optimal therapeutic program is similarly an important facet which can influence the choice of initial treatment. The patient's occupation, acceptance and compliance for the proposed treatment are similarly important considerations in designing optimal treatment for the tumor. The patient's lifestyle, particularly with reference to the habits of smoking and drinking, impacts heavily on the selection and tolerance of treatment offered. Unwillingness on the part of the patient to give up these habits causes further complications of therapy and increased risk of multiple primary tumors. Previous treatment for other lesions in the same area will also influence the

decision regarding selection of therapy. For example, radiation therapy previously delivered to the same area for a different lesion may not be available to treat a second tumor in the same area. Finally, social and economic considerations have started playing an increasing role in the selection of treatment. Allocation of resources clearly has to be judged based upon an outcomes analysis of a particular treatment program.

Physician factors

Several physician-related factors also play an important role in the selection of initial treatment. Assuming the responsibility of care of patients with oral cancers is a multidisciplinary effort and therefore a multidisciplinary team of specialists consisting of head and neck surgeons, radiation oncologists, medical oncologists, rehabilitation specialists, dental and prosthetic experts and psycho-social support services are all essential for delivery of comprehensive care and successful outcome. The role of the multidisciplinary team is not only for delivery of optimal initial care for the treatment of the cancer, but for rehabilitation of the patient from the complications and sequelae of therapy, psycho-social support, nutritional support and counseling for cessation of smoking and alcohol to restore normal lifestyle and occupation. These are all important for a successful outcome.

Selection of initial treatment

Both surgical resection and radiotherapy are applicable either singly or in combination in the treatment of cancer of the oral cavity. At this time the role of chemotherapy is investigational and limited to only high risk cancers. Small and superficial tumors of the oral cavity are equally amenable to curative treatment by surgical resection or radiotherapy. Therefore, a single modality is preferred as definitive treatment in early staged tumors (T1 and T2). When the endpoint of treatment, that is cure of cancer, is comparable, other factors must play a role in the selection of initial treatment for early staged tumors. These factors include complications of treatment, cost, convenience to the patient, compliance by the patient and long term sequelae of therapy (Fig. 2). Patients with advanced staged tumors clearly require combined modality treatment for successful outcome. Surgical resection of the primary tumor with immediate appropriate reconstruction to restore form and function is

central to the initial definitive treatment of advanced staged carcinomas. The availability of microvascular free flaps to achieve aesthetic and functional reconstruction of soft tissue and bone is a single most important advance in the surgical management of oral cancer over the course of the past twenty-five years. Postoperative radiation therapy or chemoradiotherapy is administered following appropriate evaluation of the pathologic features of the resected tumor. Modest gain in local/regional control and overall survival is observed by adding chemotherapy to postoperative radiation therapy. However, the immediate toxicity and long term sequelae are significantly more severe and last longer than that from radiation therapy alone.

Surgical approach

A variety of surgical approaches are available for resection of primary tumors in the oral cavity. The choice of a particular approach depends on the factors such as the site and size of the primary tumor as well as its depth of infiltration and proximity to the mandible and maxilla. Management of the mandible is integral to the surgical treatment planning for tumors which approach or involve the mandible. Mandible sparing approaches, such as marginal mandibulectomy and mandibulotomy, should be considered for tumors that are in proximity to the mandible or show minimal cortical erosion. On the other hand, segmental mandibulectomy is essential when infiltration in the cancellous part of the bone is present. Immediate reconstruction of the mandible with a fibula free flap remains the state of art in reconstructive surgery. Reconstructive surgery following resection of oral cancer is crucial to maintain the function of the oral cavity, such as speech articulation, mastication and swallowing. A large surface defect of the tongue, floor of mouth or buccal mucosa is best repaired with a radial forearm free flap, while composite resection defects requiring mandible resection are best reconstructed using a fibula free flap. In addition to this, there are several other reconstruction methods available to choose from under select circumstances. Involvement of regional lymph nodes by metastatic carcinoma reduces cure by nearly fifty percent. Therefore early diagnosis of micrometastases is important for accurate staging to make a decision regarding the need for adjuvant therapy. Patterns of neck metastases from primary oral carcinomas suggest that dissection of first echelon lymph nodes confined to the supraomohyoid triangle is sufficient in establishing accurate staging of oral cancer. The risk of micrometastases is directly dependent on the T stage, location of the primary tumor and depth of invasion of the primary tumor. Five year tumor control rates of oral cancer in early stages are reported to be between 75 to 94 percent. However, in advanced staged disease five year survival rates are much lower (40-60 percent).

Salivary gland tumors

W.I. WEI

Department of Surgery, University of Hong Kong Medical Centre, Queen Mary Hospital, Hong Kong

Introduction

Salivary gland enlargement is more often caused by inflammatory or nonneoplastic conditions than neoplasia. Salivary

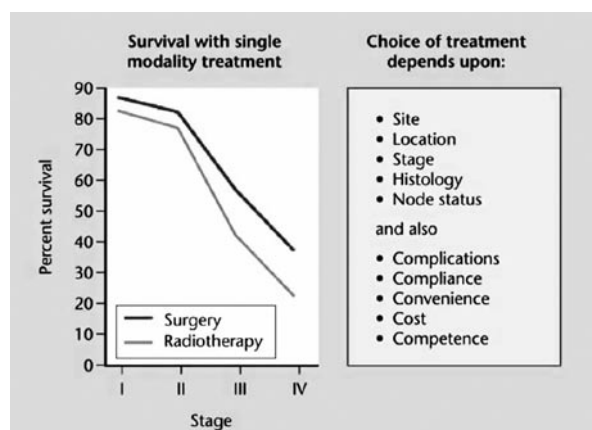


Fig. 2. Factors affecting selection of single modality or multidisciplinary treatment.

gland tumours accounts for around 3 % of all tumors in the head and neck region and around 85% of them occur in the parotid gland. In general, 80% of parotid gland tumors are benign, 50% of submandibular gland and 25% of minor salivary tumors are benign. Tumors arising from the sublingual gland are rare and most of them are malignant. The difficulties encountered with salivary gland tumors, especially the malignant neoplasms are the wide range of histological features with a spectrum of clinical behavior; the different types of classification and the number of patients encountered in individual centers are limited.

Practical classification

Benign neoplasms

1. Adenomas
 - a. Pleomorphic adenoma (Mixed tumor)
 - b. Monomorphic adenoma
 - c. Adenolymphoma (Warthin’s tumor)
2. Oncocytoma
3. Haemangioma etc.

Tumor-like conditions

1. Benign lymphoepithelial lesions
 - a. Mikulicz’s syndrome
 - b. Sjögren’s syndrome
2. Chronic sialadenitis and sialolithiasis
3. Vascular/lymphatic malformation
4. Granulomatous disease

Malignant neoplasms

1. High malignant potential
Adenoid cystic carcinoma, adenocarcinoma, squamous cell carcinoma, high grade mucoepidermoid carcinoma, carcinoma ex-pleomorphic adenoma and undifferentiated carcinoma.
2. Low malignant potential acinic cell carcinoma, low and intermediate grade mucoepidermoid carcinoma
3. Lymphoma
4. Secondary tumors

Clinical features

Both benign and malignant salivary gland present themselves as a painless mass.

Parotid gland: rapid enlarging hard mass, pain, enlarged cervical lymph nodes, skin and facial nerve involvement increases the possibility of malignancy. The oropharynx should be examined for any deep lobe enlargement. The scalp and facial skin should be examined for possible primary skin cancer with metastasis to the intraparotid lymph node. In a southern Chinese, nasopharyngeal carcinoma might be another possible primary.

Submandibular gland: fixation to mandible, weakness or numbness of the tongue, skin infiltration and enlarged cervical lymph nodes are indicative of malignant disease.

Minor salivary gland: the palate is the commonest site followed by sinonasal tract and the adenoid cystic carcinoma is most frequently seen.

Investigations

Both computed tomography (CT) and magnetic resonance imaging (MRI) demonstrate the extent of the tumor which is essential for the planning of treatment. Bone infiltration

including the mandible and skull base is better visualized with CT while MRI gives better resolution of soft tissue and bone marrow involvement. Early perineural infiltration is also better shown on MRI. Positron emission tomography (PET) shows increased F18 fluorodeoxyglucose uptake in malignant tumors but it does not have a high specificity as some benign tumors such as Warthin’s tumor also has high standard uptake values (SUVs)

Fine needle aspiration cytology ± ultrasound guidance
The overall sensitivity 86% to 99%, specificity, 96% to 100%. It has changed the patient management plan in 35% of patients who had clinical evaluation only.

Staging (AJCC 6th edition 2002)

- T1 < 2 cm with no extraparenchymal extension
- T2 2-4 cm with no extraparenchymal extension
- T3 > 4cm or smaller size with extraparenchymal extension
- T4a Tumor invades skin, mandible, ear canal or facial nerve
- T4b Tumor invades skull base, pterygoid plates or encases carotid artery
- N0 No clinical lymph node
- N1 Ipsilateral LN, 3 cm in diameter
- N2 LN 3-6 cm in diameter
- N2a Ipsilateral single LN
- N2b Ipsilateral multiple LNs
- N2c Bilateral or contralateral LNs
- N3 LN > 6 cm in diameter
- M0 No distant metastasis
- M1 Distant metastasis

	T	N	M
Stage I	T1	N0	M0
Stage II	T2	N0	M0
Stage III	T3 T1, T2, T3	N0 N1	M0 M0
Stage IV A	T4a T1, T2, T3, T4a	N0, N1 N2	M0 M0
Stage IVB	T4b Any T	Any N N3	M0 M0
Stage IVC	Any T	Any N	M1

Treatment

The primary treatment modality for salivary gland tumors is surgery as a single treatment modality and in some instances, radiotherapy is employed as adjuvant therapy.

Parotid gland tumours

For benign tumor in the superficial lobe then excision of the tumour with a margin of salivary gland tissue is adequate. If it is in the deep lobe, then a superficial parotidectomy should be carried out first, the facial nerve is dissected and then lifted to allow resection of the tumor in the deep lobe. Cross-sectioning study of a series of benign parotid tumours at 2 mm intervals contributes to the understanding of tumor extension and thus the planning of surgical resection.

Findings for pleomorphic adenoma

- None of the tumours are round, many of them showed lobulations. At the extreme two expanded ends of a tumor may be connected by just a narrow waist.
- Multiple tumors in a gland is rare.

- In spite of formal parotidectomy, in which dissection follows the facial nerve and not on the tumor capsule, the tumors in all specimens show some exposed capsule or “bare area”, indicating that capsular dissection is never totally avoidable.
- Capsular damage is occasionally seen, but minor.
- Capsules are sometimes incomplete and ingrowths of tumor occur at some sites.

Findings for Warthin's tumor

- These tumors are very frequently multifocal. The number of simultaneous tumors in one gland may be up to four.
- Very often small tumors are found inside adjacent lymph nodes.

With these findings, the surgical implications are:

- for a pleomorphic adenoma there is no need to worry about multiple tumors.
- Partial parotidectomy is adequate removal for pleomorphic adenomas.
- If capsular dissection is unavoidable at an operation for a pleomorphic adenoma, risk of recurrence is still low if damage to the capsule is avoided.
- The presence of multiple tumors suggest the diagnosis of Warthin's tumors.
- At an operation for a Warthin's tumor, watch out for multiple tumors, including those within enlarged lymph nodes.

Malignant tumors, for the few patients with small tumors with low malignant potential located in the superficial lobe, superficial parotidectomy is adequate. For more extensive tumors or those in the deep lobe, then total parotidectomy with preservation of the facial nerve should be carried out.

A preoperative intact functioning facial nerve should be preserved if possible. Only when the facial nerve is grossly involved or not functioning then it should be resected and grafted with interpositioning of the sural nerve. The facial nerve stump should be confirmed with frozen section to be free of tumor before nerve graft. Sometimes, a mastoidectomy has to be carried out to deliver the proximal part of the vertical portion of the facial nerve for grafting. Despite all these, the functional recovery following facial nerve graft is on the average around 70%.

Postoperative radiotherapy to the tumor bed is advised for tumor with high malignant potential.

Submandibular gland

When the tumor is localized in the submandibular gland then total submandibular gland resection is enough. When the surrounding tissue such as digastric muscle, the mylohyoid muscle or the mandible is affected, then en bloc resection of these tissues is necessary to effect a curative resection. The hypoglossal, lingual, mandibular branches of the facial nerve should be preserved whenever possible. When nodularity of the nerve is seen, then perineural spread should be eliminated through frozen section.

Minor salivary glands

For localized tumor, wide excision is required for a curative resection and this might include the soft palate or the hard palate. For lesions in the sinonasal tract, then partial maxillectomy might be necessary. When the tumor extends laterally or superiorly, then resection of the tumor in the in-

fratemporal fossa or even the skull base should be carried out to eradicate the disease.

Neck dissection

For patients with clinical palpable neck nodes, a comprehensive neck dissection, modified or radical neck dissection is indicated. For the N0 neck the overall incidence of metastasis in the lymph nodes was around 12% thus elective neck dissection is not indicated. Multivariate analysis however has shown that tumors size and histology are significantly associated with higher incidence of occult metastasis to the lymph nodes. Tumor stage of T3 or T4 has 20% incidence of spread to the lymph nodes and tumors with high malignant potential have 50% incidence of metastasis to the neck nodes.

Elective neck dissection clearing nodes in levels I, II and III should be carried out for these patients as a staging process.

Prognosis

Ten year overall survival was reported to be 83%, 53%, 35% and 24% for patients with stage I through to stage IV. Prognostic factors for malignant salivary gland include, tumor stage, histology i.e. the malignant potential, the type of salivary gland, lymph node metastasis, positive resection margin, facial nerve palsy and may be perineural spread along a named nerve.

Thyroid cancer

J.P. SHAH

Memorial Sloan-Kettering Cancer Center, New York, U.S.A.

The incidence of thyroid cancer is rising worldwide. In the United States, over the course of the past thirty years an increase of 300 percent has been reported. In spite of such a dramatic increase in the incidence of newly diagnosed patients with thyroid cancer, mortality from the disease remains stable. The majority of newly diagnosed cancers are reported in young women with subclinical disease or the so-called incidentally identified “micropapillary carcinomas”. The majority of such tumors are less than 2 cm in diameter.

Biological behavior

Multifocal microscopic foci of differentiated carcinoma of the thyroid gland are quite common, but these lesions do not adversely affect prognosis. Similarly, occult micrometastasis to regional lymph nodes occurs early and often (~50 percent of patients), however they also do not adversely impact upon prognosis. A great majority of patients with papillary carcinomas of the thyroid gland remain at that state of histological differentiation and are cured after initial surgical treatment. However, a small proportion of patients do undergo biological progression from well differentiated carcinoma to a less well differentiated variant and even to anaplastic carcinoma. Differentiated thyroid cancer develops from the follicular cell and may differentiate into a papillary or a follicular carcinoma. A very small proportion of these patients, however, can go on to

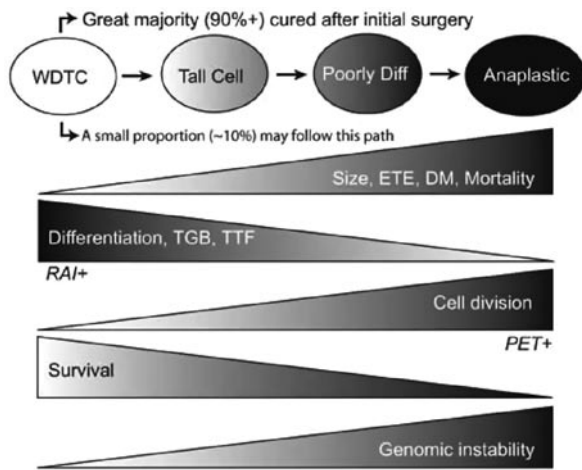


Fig. 1. Tumor progression model for aggressive behavior of a minority of patients with well differentiated thyroid carcinoma. WDTC: well differentiated thyroid cancer ; ETE: extrathyroid extension; DM: distant metastases; TGB: thyroglobulin; TTF: thyroid transcription factor; RAI: radioactive iodine; PET: positron emission tomography.

progress to less well differentiated carcinomas and present as tall cell variant of papillary carcinoma, insular carcinoma, or poorly differentiated carcinoma. Some of these tumors will go on to become anaplastic carcinoma (Fig. 1). Evidence of such progression from a well differentiated carcinoma to anaplastic carcinoma is supported by two observations: 1) Multiple histopathological sections of the primary tumor from a patient with poorly differentiated carcinoma often show areas of well differentiated papillary or follicular patterns. This could imply that the tumor started off as a well differentiated cancer and progressed to a poorly differentiated carcinoma; 2) Review of serial histopathological specimens of patients who develop multiple recurrences show progressive metaplastic changes from an initially well differentiated carcinoma to a progressively less and less well differentiated cancer with each subsequent recurrence. Many of these patients will go on to eventually have recurrent cancer with poorly differentiated features leading to mortality. Fortunately nearly 80 percent of patients at initial presentation will have a well differentiated carcinoma with an excellent outcome. Approximately 15 percent of patients have a less well differentiated or a poorly differentiated carcinoma and about 2 to 3 percent of patients present with anaplastic carcinoma. Cause specific mortality in patients with well differentiated carcinoma is under 2 percent. Mortality with anaplastic carcinoma is over 95 percent and in the less well differentiated or poorly differentiated carcinomas it ranges from 15 to 35 percent.

Common clinical practice

The practice for treatment of differentiated carcinoma of the thyroid at many institutions is to employ a “subtotal thyroidectomy” followed by radioiodine ablation and radioiodine therapy. If these practice patterns are to be followed without understanding the biological behavior of thyroid cancer and without appreciating the importance of prognostic factors and risk group stratification, then an enormous number of patients will get over-treatment with unnecessarily aggressive surgery and unnecessarily em-

ployed adjuvant radioiodine therapy. In any of the major published studies in the literature, the extent of surgery or postoperative radioiodine ablation has not shown any impact on outcome. It is therefore prudent to risk stratify patients based on known prognostic factors and offer selective surgical treatment to reduce morbidity and deliver cost effective therapy.

Prognostic factors and risk group stratification

The importance of prognostic factors in differentiated carcinoma of the thyroid gland has been repeatedly shown to be vitally important to select therapy and assess prognosis. These prognostic factors are the patient’s age, gender, size of the primary tumor, extra thyroid extension, histology of the primary tumor and present of distant metastases. These factors have been shown to be independent parameters of prognosis on multivariate analysis in several studies. Utilizing these independent parameters of prognosis to develop risk group stratification is an important clinical exercise in selection of therapy. Patients classified in the low risk group are young (under 45 years), have a tumor less than 4 cm in diameter with no extra thyroid extension, well differentiated histology and no evidence of distant metastases. Patients in the high risk group category are older (over 45 years), have larger tumors (> 4 cm) or have extra thyroid extension, poorly differentiated histology or presence of distant metastases at initial diagnosis. The intermediate risk group consists of young patients with aggressive primary tumors or older patients with favorable primary tumors. (Fig. 2) Cause specific mortality in the low risk group is under 2 percent, while mortality in the high risk group is nearly 50 percent. Similarly, treatment failure with recurrence occurs in only 13 percent of patients in the low risk group compared to 50 percent of patients in the high risk group. Treatment failure in the low risk group usually occurs in most instances with regional lymph node metastases or recurrence at the primary site both of which are treatable and curable. In contrast, treatment failure in the high risk group occurs in a majority of patients with local recurrence and invasion of vital structures in the neck or with appearance of distant metastasis. These are unlikely to be curable, leading to mortality from cancer.

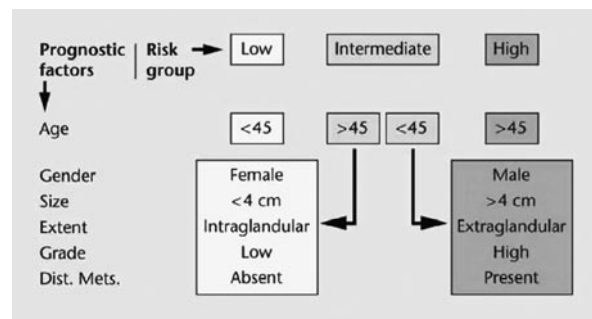


Fig. 2. Prognostic factors and risk group stratification.

Selection of therapy

Employing risk group stratification in selecting initial surgical treatment thus is crucially important. Patients in the low risk group category with a unifocal intraglandular tumor with a normal contralateral thyroid lobe are very likely cured by simple ipsilateral extracapsular thyroid lobectomy. These

patients do not have any added benefit with total thyroidectomy or radioiodine ablation. On the other hand, patients with more aggressive tumors with extra thyroid extension or poorly differentiated histology will require appropriate aggressive surgery. Total thyroidectomy is indicated in patients with diffuse bilobar disease, presence of contralateral thyroid lobe nodules regardless of their histological nature, massive cervical lymph node metastases where there will be the need for radioiodine therapy, and obviously for patients who present with distant metastatic disease to facilitate radioiodine treatment. When total thyroidectomy is performed, it should be a true extracapsular total thyroidectomy without deliberately leaving any thyroid tissue behind. Thus the popular operations of "subtotal thyroidectomy" and "near total thyroidectomy" are to be condemned if the operative procedure is performed for cancer of the thyroid gland. Patients who present with gross extrathyroid extension and involvement of the larynx, trachea, esophagus or recurrent laryngeal nerve need more than total thyroidectomy to achieve gross total tumor resection. Therefore extensive operations with resection of portions of the larynx, trachea, esophagus and adjacent structures maybe necessary to encompass the desired goal of total tumor excision. Such surgical intervention is shown to be curative in young patients who manifest with such adverse tumor features.

Cervical lymph node metastases

The patterns of regional lymph node metastases from differentiated carcinoma of the thyroid gland are well established. Perithyroid lymph nodes in the central compartment and those in the paratracheal and pretracheal region as well in the superior mediastinum are the first echelon lymph nodes for most patients with thyroid cancer. Microscopic or occult metastases maybe present in as many as 50 to 60 percent of patients with papillary carcinoma and a clinically N0 neck. In spite of such a high incidence of occult micrometastases, subsequent clinical metastases appear in fewer than 15 percent of patients. Comprehensive neck dissection done for clinically palpable lymph nodes offers as good a survival outcome as those patients undergoing elective dissection for micrometastases. Therefore in the absence of grossly palpable or radiologically demonstrated metastatic lymph nodes, the elective operation of lymph node excision is not recommended. However, when cervical lymph node metastases are documented by clinical examination or imaging studies, a systematic clearance of regional lymph nodes by a modified neck dissection is recommended. Regional lymph node metastases in the young patient have no impact on prognosis. On the other hand, regional lymph node metastases in the older patient do adversely impact upon prognosis.

Postoperative adjuvant therapy

Routine ablation following total thyroidectomy is advocated with the argument that it destroys remnant thyroid tissue and thus allows the patient to be followed with serial thyroglobulin levels for surveillance. Clearly, ablation of remnant thyroid tissue has never been shown to impact upon prognosis in low risk patients. If, on the other hand, when a true extracapsular thyroidectomy is performed and postoperative thyroglobulin approximately six weeks following surgery is < 1 , then it would be hard to justify employment

of radioiodine ablation following surgery. We therefore do not recommend routine radioiodine ablation unless postoperative thyroglobulin is high. In spite of radioiodine ablation, it is often hard to achieve a thyroglobulin level of zero. However a thyroglobulin value > 1 is acceptable to declare the patient as tumor free.

Adjuvant therapy in high risk patients or patients with poorly differentiated carcinomas requires more aggressive intervention. Many such patients do not have iodine avid cancer and therefore radioiodine therapy is often not indicated. These patients will need external radiation therapy in addition to enhance the chances of local control of thyroid cancer. High risk patients with poorly differentiated carcinoma should be investigated with a PET scan to rule out the presence of residual or metastatic disease to facilitate adjuvant treatment.

Long term follow-up and surveillance

Low risk patients with differentiated carcinoma of the thyroid gland are maintained under clinical surveillance initially at six month intervals and subsequently annually. In addition to clinical examination, serum thyroglobulin is checked periodically. Significant elevations in the values of thyroglobulin trigger the need for further work-up to rule out recurrent disease. Ultrasound examination of the thyroid bed and lateral neck is performed annually for the first five years. A majority of patients who are likely to develop recurrent disease in the thyroid bed or the lateral neck manifest recurrence within the first three to five years. Patients who fall into the high risk category require more stringent surveillance and may need PET scan in addition to ultrasound examination and serum thyroglobulin measurements. Tumor heterogeneity is fairly common in thyroid cancers and some patients may have both PET positive and iodine avid disease at distant sites. In such instances the more aggressive variant of thyroid cancer is shown by PET positivity while the well differentiated component of the metastatic deposit is shown on radioiodine scanning. PET positive metastatic deposits may require surgical intervention or external radiation therapy for symptom control, while iodine avid recurrent or metastatic disease is treated with radioactive iodine.

Over-enthusiastic surveillance of low risk patients with ultra sensitive serum thyroglobulin essays and frequent use of ultrasound examination may be problematic in some patients. Minor fluctuations in thyroglobulin values trigger the need for an ultrasound which may demonstrate a small (under 1 cm) lymph node in the central compartment of the neck. This then leads to the need for an ultrasound guided fine needle aspiration biopsy which may demonstrate metastatic papillary carcinoma in a lymph node. Such minor deposits of metastatic carcinoma in central compartment lymph nodes have little impact on prognosis, however they become a major cause for anxiety, apprehension and concern on the part of the patient who is now obsessed with the fear of recurrent cancer and seeks surgical intervention. Discovery of such small deposits of metastatic papillary carcinoma in regional lymph nodes may occur more than once and every repeated episode of surgical intervention becomes increasingly hazardous from the point of view of injury to the parathyroid glands and recurrent laryngeal nerves. Therefore restraint needs to be exercised in use of ultra sensitive thyroglobulin

and repeated ultrasound examinations in low risk patients. In general we do not propose fine needle aspiration biopsies of lymph nodes less than 1 cm in diameter. We will follow these lymph nodes with serial ultrasound examination and consider fine needle aspiration biopsy only if the identified lymph nodes show increase in size to larger than 1 cm.

Mortality from thyroid cancer

Analysis of cause specific mortality for patients with thyroid carcinoma show that only 2 percent of all thyroid cancers are anaplastic carcinoma, but they have an 85 percent mortality rate. Four percent of all cases are medullary carcinomas, with a 25 percent mortality. Advanced stage (Stage IV) well differentiated carcinomas account for only 1 percent of all thyroid cancers and have a 50 percent mortality. Thus a majority of cause specific deaths in thyroid carcinoma are accounted for by mortality from anaplastic carcinoma, medullary carcinoma, poorly differentiated carcinoma and well differentiated locally aggressive Stage IV thyroid cancer. Mortality in the low risk patients is exceedingly rare. In a consecutive series of patients treated at the Mayo Clinic, 10 year mortality in the low risk group patients was zero. Most patients who ultimately die of thyroid cancer can be identified at the time of initial treatment and thus they should be offered aggressive surgical intervention, aggressive adjuvant therapy and stringent surveillance following initial treatment. Establishing accurate histological diagnosis and understanding biological behavior of thyroid cancer allows one to be selective in the choice of appropriate intervention and proper resource utilization and delivery of cost effective therapy.

Summary

There is a rising incidence of thyroid carcinoma worldwide, but a majority of these are favorable low risk cancers. Accurate pathologic interpretation of the nature of the tumor and its biological behavior are important in overall treatment planning. Appreciating the importance and significance of prognostic factors and risk group stratification is crucial to contemporary management of thyroid carcinoma. Discretion needs to be exercised in selection of surgical treatment and use of adjuvant therapy. Post treatment surveillance strategies require maintaining balance between morbidity of treatment versus benefit to the patient.

Cervical lymph node metastases

J.P. SHAH

Memorial Sloan-Kettering Cancer Center, New York, U.S.A.

The success of the treatment of squamous carcinoma of the head and neck depends on the stage of disease at the time of diagnosis and initial treatment. In spite of significant advances made in diagnostic capabilities and therapeutic combinations for the overall management of squamous cell carcinoma of the upper aerodigestive tract, cure rates drop to nearly half when patients have involvement of regional cervical lymph nodes compared to patients with early stage tumors.

Anatomy and staging

A variety of methods are used to describe several regional groups of lymph nodes in the head and neck area. An ana-

tomically sound and clinically reproducible method to describe the lymph nodes of the neck with particular reference to metastatic spread from primary tumors of the head and neck was introduced by the Head and Neck Service at Memorial Sloan-Kettering Cancer Center over fifty years ago. This simplified classification scheme divides cervical lymph nodes into several Levels. Lymph nodes in the submandibular triangle are called Level I, those in the upper, middle and lower third of the internal jugular chains are Levels II, III and IV respectively and those in the spinal accessory and transverse cervical chains in the posterior triangle are Level V. Lymph nodes in the tracheoesophageal groove and central compartment of the neck are assigned Level VI and those in the superior mediastinum are assigned Level VII. The American Academy of Otolaryngology-Head and Neck Surgery has further subdivided Levels I, II and V into IA and IB, IIA and IIB and VA and VB. These subdivisions have therapeutic implications (Fig. 1).

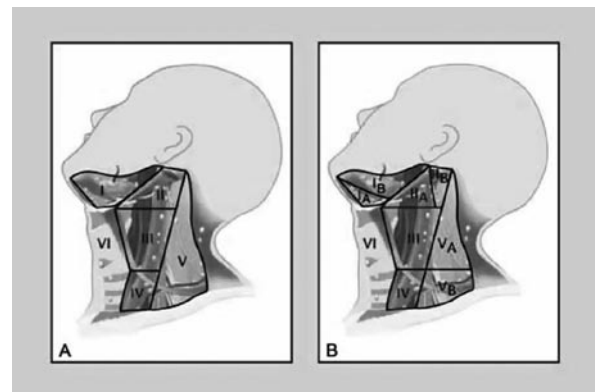


Fig. 1. Levels of lymph nodes in the neck.

A. MSKCC – Original description

B. AAO-HNS – Revision

Over the years it has become increasingly apparent that the tumor burden in cervical lymph nodes represented by the number of lymph nodes, size of the lymph nodes, and unilateral versus bilateral involvement carries a significant impact on prognosis. Thus The American Joint Committee for staging of cancer (AJCC) and the International Union Against Cancer (UICC) have developed a uniform classification of nodal staging. The clinically negative neck is staged as N0, ipsilateral single lymph node less than 3 cm is N1, ipsilateral single lymph node more than 3 but less than 6 cm is N2a, ipsilateral multiple lymph nodes all less than 6 cm in diameter is N2b, and bilateral or contralateral lymph nodes less than 6 cm in diameter are designated N2c. Any lymph node larger than 6 cm is staged N3.

Risk factors for cervical lymph node metastases

Various factors related to the primary tumor in the head and neck area influence the development of regional lymph node metastases. These include the site, size, T stage, grade, depth of infiltration and location of the primary tumor. Certain sites in the oral cavity such as the hard palate have a very low potential for nodal metastases compared to the same staged primary tumor in the floor of mouth or tongue. In general, however, it is safe to say that lesions located in the posterior part of the oral cavity and further along the upper aerodigestive tract (oropharynx, hypopharynx) have

a higher risk for regional lymph node metastases compared to those situated in the anterior aspect of the oral cavity. The risk of regional lymph node metastases increases with increasing size of the primary lesion as well as the increasing T stage of the primary tumor. Poorly differentiated carcinomas carry an increased risk of regional metastases. Tumors with a greater depth of invasion carry a proportionately higher risk of nodal metastases. This information is obviously of vital importance in seeking out those patients who present with a clinically negative neck but in whom consideration should be given to elective treatment of regional cervical lymph nodes that are at risk of having micrometastases. The risk of nodal metastases is highest for primary tumors of the pharynx (nasopharynx, oropharynx and hypopharynx).

Nodal factors affecting prognosis

It is obvious that the patients who present with cervical lymph node metastases have a poor prognosis compared to those in whom regional lymph nodes are not involved. It is also well known that the prognosis worsens as the volume of metastatic cancer in cervical lymph nodes (N Stage) increases. There are clearly other factors that are an indirect reflection of the volume or aggressiveness of metastatic cancer which also influences prognosis. These include the number of lymph nodes involved, level of involvement of lymph node, presence of extracapsular extension of tumor and involvement of soft tissue and perivascular and perineural infiltration by metastatic cancer.

Patterns of cervical lymph node metastases

The initial involvement by only certain regional lymph nodes from a particular primary site is predictable in most instances. Thus the regional lymph node groups at highest risk for most primary sites can be predicted and the elective operative procedure can be appropriately tailored (selective neck dissection). This principle is particularly applicable when the risk of microscopic metastases is high in the clinically negative neck. The patterns of regional lymph node metastases from various primary sites within the upper aerodigestive tract are predictable. In general, regional lymph node groups at highest risk for metastases from primary squamous carcinomas of the oral cavity are confined to the supraomohyoid triangle (Levels I, II and III). The regional lymph node groups at risk from primary tumors of the hypopharynx and larynx involve the deep jugular chain of lymph nodes (Levels II, III and IV), either on the ipsilateral side or bilaterally if the primary tumor crosses the midline. Therefore dissection of these select regional lymph node groups should be adequate for elective surgical treatment of cervical lymph nodes from a given primary site when the neck is clinically negative. Such a surgical procedure gives accurate pathologic staging of the tumor and facilitates decision regarding the need for adjuvant treatment.

Treatment considerations

Historically, the definitive surgical treatment of cervical lymph nodes for primary squamous carcinomas of the head and neck has been a classical radical neck dissection. Unfortunately the operation produces significant aesthetic and functional morbidity. When performed bilaterally and

particularly simultaneously the operative mortality is unacceptable. Long term morbidity of bilateral radical neck dissections is also significant. For these reasons, the concept of classical radical neck dissection for "all patients" with the risk of neck metastases is not warranted. In N0 patients, selective surgical removal of lymph nodes at highest risk of harboring micrometastases has proven to be effective. However when gross palpable metastases are present, local failure in the neck in spite of radical neck dissection is quite high. Therefore in that clinical setting, not only radical neck dissection, but a combination of adjuvant radiation therapy should be employed since this plan offers significant improvement for local regional control of disease.

The concept of sentinel lymph node biopsy, proven to be accurate and successful in cutaneous melanomas, has also been advocated for mucosal cancers. Unfortunately, it is applicable only to primary sites in the oral cavity (tongue and floor of mouth) due to their accessibility. In most instances, 2-3 sentinel lymph nodes are usually identified in the neck. Furthermore, the morbidity of selective neck dissection is minimal. For these reasons, sentinel node biopsy has not gained universal acceptance as a staging procedure in mucosal cancers of the head and neck.

The current philosophy for the management for clinically apparent cervical lymph node metastases is surgical clearance of regional lymph nodes by a comprehensive neck dissection followed by post operative radiation therapy. The debate however continues as to the extent of the operation, particularly in light of the morbidity inflicted by classical radical neck dissection. Studies of distribution of metastatic nodes in the neck have further identified a very low risk of having occult metastases in the clinically negative posterior triangle of the neck. Thus preservation of the accessory nerve during a comprehensive neck dissection is technically feasible and should be considered in patients undergoing therapeutic neck dissection. On the other hand, the studies of patterns of cervical lymph node metastases clearly demonstrate that a selective operation removing only first echelon lymph nodes in patients with clinically negative neck which is at risk of harboring micrometastasis is a satisfactory surgical procedure which offers accurate pathological staging to facilitate the need for adjuvant therapy. Such a surgical undertaking would segregate those patients who have no metastases in the neck and who can safely avoid the need for adjuvant postoperative radiation therapy.

Classification of terminology of neck dissection

Comprehensive neck dissections	Selective neck dissections
Radical neck dissection	Supraomohyoid neck dissection (Levels I, II and III)
Extended radical neck dissection	Anterolateral neck dissection (Levels II, III and IV)
Modified Neck Dissection Type I (XI Nerve)	Posterolateral neck dissection (Levels II, III, IV, V, and Suboccipital Triangle)
Type II (XI nerve and SCM)	Central compartment lymph node dissection (Levels VI and VII)
Type III (XI nerve, SCM and IJV)	

Summary

The presence of cervical lymph node metastases has a significant adverse impact on prognosis, reducing the cure rates by nearly half of that achieved for localized squamous cell carcinomas of the upper aerodigestive tract. The patterns of metastatic spread to regional lymph nodes in the neck are predictable and high risk groups are identifiable. Currently available means for early diagnosis of metastases are inadequate. A selective neck dissection of first echelon lymph nodes is accepted at present for accurate staging of lymph nodes at risk of having micrometastases. A comprehensive neck dissection, preferably preserving the spinal accessory nerve, at present appears to be the most appropriate surgical procedure for clinically apparent gross metastases in the anterior triangle of the neck as long as the spinal accessory nerve is not directly involved by cancer. This operation provides satisfactory comprehensive clearance of gross metastases but retains the functional integrity of the shoulder due to preservation of the spinal accessory nerve. Adjuvant radiation therapy employed postoperatively enhances local control of metastatic disease in the neck but does not seem to significantly improve five year survival. Modifications of neck dissections can be justified for microscopic or minimal metastatic disease in the neck. However, the choice of an appropriate modification of neck dissection, whether it be comprehensive or selective depends on the site of the primary tumor and the regional lymph nodes involved from that primary site. The nomenclature and classification of neck dissections are sufficiently standardized to employ the terminology in a routine fashion. Future research in molecular biology of primary tumors to identify genetic markers for risk of nodal metastases will further simplify clinical management of regional cervical lymph nodes at risk of developing metastatic cancer.

Advances in radiotherapy for head and neck carcinomas

K.K. ANG

University of Texas M.D. Anderson Cancer Center, Houston, U.S.A.

Many biologically sound altered fractionation (AF) regimens have been subjected to phase III clinical trials in the 1980s and 1990s. A thorough meta-analysis (Tab. I) shows that, in aggregate, hyperfractionated and accelerated fractionation without total dose reduction regimens yields better local regional control rate than the conventional 2-Gy daily fraction to a total dose of 66-70 Gy (1). Most commonly used AF regimens are concomitant boost [66-72 Gy given in 1.8-2 Gy per fraction over 6 weeks (twice a day irradiations for 5-12 days)], 6-fractions per week schedule introduced by DAHANCA [66-70 Gy given in 33-35 fractions, 6 fractions per week], and hyperfractionation [79.2-81.6 Gy in 1.2 Gy per fraction over 7 weeks (twice a day irradiation during whole therapy)] regimens.

More recently, advances in computerized radiotherapy planning and delivery technology open the possibility to conform irradiation to an irregular tumor target volume (conformal radiation therapy). Consequently, it is feasible to reduce radiation dose to more of the critical normal tissues surrounding the tumor without compromising dose de-

livery to the intended target volume, resulting in a reduction in morbidity such as xerostomia². Reduced toxicity would in turn permit escalation of the radiation dose or combining radiotherapy with intensive chemotherapy, each of which has the prospect of improving head and neck squamous cell carcinoma control. Basic expertise in anatomy, imaging, and pattern of tumor spread are vital for clinical application of precision radiotherapy.

Such precision radiotherapy can be accomplished by the use of an array of x-ray beams individually shaped to conform to the projection of the target. In addition, technology is also available to modify the intensity of the beams across the irradiation field as an added degree of freedom to enhance the capability of conforming dose distributions in three dimensions. This radiotherapy technique is called intensity-modulated radiation therapy (IMRT). With this technique all target volumes are irradiated during every radiation session but lower dose per fraction is delivered to the electively treated (subclinical disease) volume at each fraction. Consequently, the overall treatment time for subclinical disease is also prolonged from the conventional 5 weeks (50 Gy in 25 fractions) to 6-7 weeks (33 to 35 fractions). Both changes in these radiation dose fractionation parameters result in sparing of late and acute side effects, respectively.

The role of IMRT in reducing morbidity and perhaps improving control of squamous cell carcinoma are being tested in a number of centers. Emerging results already reveal that it is effective in sparing parotid glands from receiving high radiation dose and thereby diminishes radiation-induced permanent xerostomia in selected patients^{3,4}.

Single institutional study testing the role of IMRT in the management of nasopharyngeal carcinoma (NPC) and oropharyngeal cancers yielded exciting results. In patients with NPC, IMRT was given alone or, for locally advanced stage, in combination with chemotherapy consisting of concurrent cisplatin and adjuvant cisplatin plus 5-fluorouracil. In a series of 67 patients⁵ with a median follow up of 31 months, the 4-year estimates of local progression-free, local-regional progression-free, distant metastasis-free, and overall survival rates were 98%, 97%, 66%, and, 88%, respectively. The worst late morbidity was grade 1 in 20 (30%), grade 2 in 15 (22%), grade 3 in 7 (10%), and grade 4 in 1 (2%) patients. The results of several subsequent trials have been published confirming the excellent local-regional control rates. Two randomized clinical trials have been undertaken to assess the value of IMRT relative to the conventional technique in preserving the salivary glands. Both trials showed that patients treated with IMRT had significantly higher recovery of the parotid salivary flow after completion of therapy but it could take up to a year for flow rate to recuperate. One of these studies also showed that patients treated with IMRT had better scores in role-physical, bodily pain, and physical function at 12 months after therapy.

Similar strategy was also used in patients with oropharyngeal carcinoma, i.e. IMRT alone in patients with T1-2N0-1 tumors or IMRT in combination of chemotherapy in patients with more locally advanced carcinoma. The results of the initial series of 51 patients with oropharyngeal carcinoma treated at the M.D. Anderson Cancer Center were reported⁶. With a median follow up of 45 months, the 2-year local-regional control, recurrence-free, and overall survival rates were 94%, 88%, and 94%, respectively. Although a sub-

Tab. I. Absolute benefit and hazard ratios for altered fractionation vs. conventional fractionation for intermediate-stage to locally advanced head and neck squamous cell cancer.

Endpoint	Overall	p-value	HFX	AFX without dose reduction	AFX with dose reduction
Improvement at 5-years					
Overall survival	+3.4%*	0.003	+8.2%	+2.0%	+1.7%
Local-regional control	+6.4%	< 0.0001	+9.4%	+7.3%	+2.3%
Hazard ratios					
Total death	0.92 (0.86-0.97)	0.003	0.78 (0.69-0.89)	0.97 (0.89-1.05)	0.94 (0.84-1.05)
Cancer death	0.88 (0.83-0.94)	0.0002	0.78 (0.68-0.90)	0.91 (0.83-1.00)	0.93 (0.83-1.05)
Local relapse	0.77 (0.71-0.83)	<0.0001	0.75 (0.63-0.89)	0.74 (0.67-0.83)	0.83 (0.71-0.96)
Regional relapse	0.87 (0.79-0.97)	0.01	0.83 (0.66-1.03)	0.90 (0.77-1.04)	0.87 (0.72-1.06)
Local-regional relapse	0.82 (0.77-0.88)	<0.0001	0.76 (0.66-0.89)	0.79 (0.72-0.87)	0.90 (0.80-1.02)
Metastatic relapse	0.97 (0.82-1.15)	0.75	1.09 (0.76-1.58)	0.93 (0.74-1.19)	0.95 (0.68-1.32)

*An 8% reduction in the risk of dying. Modified from Bourhis et al., 2006¹.

stantial proportion of patients treated with IMRT required a gastric feeding tube (40%), its use was brief. Only 10% still required feeding tube 6 months after treatment and all patients were tube-free after 1 year. Only 3 patients had chronic difficulty in swallowing. This series has recently been updated. Of the 259 patients treated, 85% had T1-2 tumors but 87% had clinically involved nodes. The 3-year actuarial local regional control and overall survival rates were 94% and 88%, respectively. In an updated series of 259 patients treated at the MD Anderson Cancer Center, 85% had T1-2 tumors and 87% had clinically involved nodes. The 3-year actuarial local regional control and overall survival rates were 94% and 88%, respectively.

Inspired by encouraging single institutional data, a number of multi-institutional trials addressing the role of IMRT in the treatment of head and neck carcinomas (e.g., RTOG trial 0022 for early stage oropharyngeal carcinoma and trial 0225 for NPC) have been launched after established credentialing and quality-assurance procedures, conducting training orientation, and generating useful atlas for target delineation. The preliminary analysis of trial 0022 showed local-regional recurrence in 3 out of a total of 67 patients enrolled, thus confirming the single institutional data. Based on these results, IMRT has been recently introduced into many clinical trials.

Of note is that more developments are needed to fully benefit from this sophisticated technology. Areas needing improvement to refine margins of coverage include quantification of and correction for day-to-day anatomic variations occurring during the course of radiotherapy due to motion and changes in tumor and normal tissue volume. This type of refinement is referred to as image-guided radiotherapy (IGRT) or adaptive radiation therapy (ART). Advances in topographic and biologic tumor imaging will improve the accuracy of target volume delineation and selection of pa-

tients for specific fractionation regimen or combined therapy modality, etc.

Although results of IMRT encouraging, the observation that most recurrences originated from the high dose region indicates that radiation dose escalation alone will only improve outcome in a subset of patients. Further advances in the treatment of solid tumors would likely come through application of new knowledge on tumor biology, as exemplified by translational research addressing the role of epidermal growth factor receptor in tumor progression and as a target for therapeutic intervention.

References

- Bourhis J, Overgaard J, Audry H, Ang KK, Saunders M, Bernier J, et al. *Hyperfractionated or accelerated radiotherapy in head and neck cancer: a meta-analysis*. Lancet 2006;368:843-54.
- Eisbruch A, Ten Haken RK, Kim HM, Marsh LH, Ship JA. *Dose, volume, and function relationships in parotid salivary glands following conformal and intensity-modulated irradiation of head and neck cancer*. Int J Radiat Oncol Biol Phys 1999;45:577-87.
- Pow EHN, Kwong DLW, McMillan AS, Wong MCM, Sham JST, Leung LHT, et al. *Xerostomia and quality of life after intensity-modulated radiotherapy vs. conventional radiotherapy for early-stage nasopharyngeal carcinoma: Initial report on a randomized controlled clinical trial*. Int J Radiat Oncol Biol Phys 2006;66:981-91.
- Kam MKM, Leung S-F, Zee B, Chau RMC, Suen JJS, Mo F, et al. *Prospective randomized study of intensity-modulated radiotherapy on salivary gland function in early-stage nasopharyngeal carcinoma patients*. J Clin Oncol 2007;25:4873-9.
- Lee N, Xia P, Quivey JM, Sultanem K, Poon I, Akazawa C, et al. *Intensity-modulated radiotherapy in the treatment of nasopharyngeal carcinoma: an update of the UCSF experience*. Int J Radiat Oncol Biol Phys 2002;53:12-22.
- Garden AS, Morrison WH, Wong P-F, Tung SS, Rosenthal DI, Dong L, et al. *Disease-control rates following intensity-modulated radiation therapy for small primary oropharyngeal carcinoma*. Int J Radiat Oncol Biol Phys 2007;67:438-44.

Chemotherapy and radiotherapy in the management of locally advanced head & neck cancers

A.A. FORASTIERE

Johns Hopkins University School of Medicine, Department of Oncology, Baltimore, U.S.A.

Introduction

Cisplatin-based chemotherapy administered concomitant with radiotherapy is the backbone of current combined modality therapeutic strategies. These encompass the treatment of: locally advanced, unresectable squamous cancers of all primary sites, nasopharyngeal cancer, organ preservation for cancers of the oropharynx and larynx, and for post-operative treatment of patients with resected cancer displaying certain adverse pathologic features. Cancer of the hypopharynx is the one site where induction chemotherapy remains the approach for achieving organ preservation based on level 1 evidence.

Rationale for combining chemotherapy and radiotherapy

Induction and adjuvant chemotherapy suppress distant metastases; while no significant effect on local-regional control has been demonstrated in numerous randomized controlled trials. By contrast, the ability of cytotoxics to enhance radiation cell kill, including hydroxyurea, 5-fluorouracil (5-FU), bleomycin, mitomycin, and cisplatin led to trials in the 1970s and 1980s that randomized patients to radiotherapy with or without a concomitant single agent cytotoxic drug. Most studies showed significant improvement in local control or disease-free survival but the effect was generally not sufficient to alter survival. Further investigations of concomitant chemoradiation using two drugs or high dose cisplatin have improved outcomes and defined current standard of care. The mechanisms of radiosensitization for various drugs include:

- halogenated fluoropyrimidines (5-FU, UFT, capecitabine): alteration of nucleotide pools so that DNA damage cannot be repaired; cell cycle redistribution with arrest of cells in G1/S.
- Taxanes (paclitaxel, docetaxel): microtubule polymerization and arrest in G2/M.
- Platinum compounds (cisplatin, carboplatin): inhibition of sublethal damage repair.
- Nucleoside analogs (gemcitabine): alterations of nucleotide pools, cell cycle redistribution, reduction of the apoptotic threshold of radiation damaged cells.

Locally advanced, unresectable disease

The median survival of patients with stage IVB disease (base of skull involvement, fixation to pre-vertebral fascia, encasement of the carotid, or involvement of the pterygoid musculature), treated with radiotherapy alone, is 12 months with 20% alive at 2 years. Two regimens tested in unresectable patients in the 1980s showed promise for survival improvement. The Radiation Therapy Oncology Group (RTOG) evaluated high dose cisplatin (100 mg/m² days 1, 22 and 43) during radiotherapy and reported a 71% complete response rate and 34% 4-year survival rate. The

Eastern Cooperative Oncology Group (ECOG) tested split course radiotherapy (60-70 Gy) with 3 cycles of cisplatin + infusional 5-FU during radiation and optional resection, if feasible, after two cycles of chemotherapy. This resulted in a complete response rate of 77% and an estimated 4-year survival rate of 49%. Subsequently, these two regimens were directly compared with radiotherapy alone in Intergroup trial E1392. A total of 295 patients with unresectable cancers of the oral cavity, oropharynx, larynx or hypopharynx were randomized. The results showed a significant improvement in median and 3-year survival (37% vs 23%, $p = 0.014$) for the comparison of high dose cisplatin and radiotherapy versus to radiotherapy alone. Toxicity (grades 3-4) was more frequent with concomitant treatment than radiotherapy alone (89% vs 52%). These results and those from controlled trials of other cisplatin-based regimens concomitant with radiotherapy provide level I evidence for the current standard of care (high dose cisplatin and radiotherapy 70 Gy) for patients with unresectable disease.

Current research directions for patients with unresectable disease focus on the addition of biologics, specifically the family of epidermal growth factor receptor (EGFR) inhibitors, monoclonal antibodies and tyrosine kinase small molecule inhibitors. A phase II trial in unresectable patients conducted by the ECOG adds cetuximab to cisplatin (75 mg/m² days 1, 22, 43) and radiotherapy 70 Gy in 35 fractions followed by 6 months of maintenance cetuximab. The RTOG is directly comparing radiotherapy and concomitant cisplatin with and without weekly cetuximab employing a concomitant boost altered fractionation radiation schedule.

Nasopharyngeal cancer

The management of nasopharyngeal cancer is influenced by the more frequent and earlier occurrence of distant dissemination of disease, particularly for WHO types II and III, in contrast to other HNSCCs. High dose cisplatin and concurrent radiotherapy followed by adjuvant cisplatin and 5-FU is the standard of care for stages IIB, III, IVA and IVB nasopharyngeal cancer. The landmark US Intergroup 0099 trial of concomitant high dose cisplatin and radiotherapy followed by 3 cycles of adjuvant cisplatin + 5-FU compared with radiotherapy alone established a new standard of care. After a minimum follow-up of five years, overall survival (67% vs 37%, $p < 0.001$) and progression-free survival (58% vs 29%, $p < 0.001$), local-regional and distant disease control were significantly improved. While there was concern that these results might not apply to the treatment of endemic populations, at least four randomized controlled trials in Asian populations and two meta-analyses now confirm the survival advantage for concomitant cisplatin and radiotherapy. The role of adjuvant chemotherapy remains controversial. Current research directions center around the use of intensity modulated radiotherapy. Data from the University of California-San Francisco indicate a 98% local-regional control rate, 66% distant metastasis-free rate, and 88% 4-year survival estimate in 67 patients treated with the standard of care paradigm but using IMRT. The excellent local-regional control suggests that future investigations should focus on improving systemic therapy to lower rates of metastases.

Organ preservation and the management of locally advanced larynx, oropharynx and hypopharynx cancers

Historically, locally advanced cancers of these three primary sites were managed exclusively with surgery and post-operative radiotherapy, if resectable, and radiotherapy alone if unresectable. Conservation laryngeal surgery for selected T3 cancers of the larynx or radiotherapy alone for T3 N0-1 cancers were options for larynx preservation. The Veterans Administration Laryngeal Study Group (VALSG) conducted a landmark trial that directly compared the induction chemotherapy strategy (up to 3 cycles of cisplatin and 5-FU followed by radiotherapy in patients with at least 50% reduction in the laryngeal primary tumor) with laryngectomy and post-op radiotherapy. The larynx was preserved in 64% with no decrement in survival.

To determine the precise contribution of induction chemotherapy and the optimal sequencing of chemotherapy and radiotherapy, the US Intergroup conducted trial R91-11. Three non-surgical treatments were compared: radiotherapy alone (70 Gy); induction cisplatin + 5-FU followed by radiotherapy; and concomitant cisplatin (100 mg/m² days 1, 22 and 43) and radiotherapy, in patients with stage III and IV resectable supraglottic and glottic cancers, excluding T1 and high volume T4 cancers. The best results were achieved with concomitant cisplatin and radiotherapy (43% reduction in laryngectomy rate), and significantly improved local-regional control compared to the other two treatment groups. Importantly, there was no significant difference in larynx preservation rate or local-regional control comparing the induction chemotherapy group with the radiotherapy alone group. Overall survival was not significantly different among the treatment groups (5-year: 59% – induction, 55% – concomitant, 54% – radiotherapy alone). Toxicity was significantly more frequent in both chemotherapy groups compared to radiotherapy alone. These results provide level 1 evidence for concomitant high dose cisplatin and radiotherapy when total laryngectomy would be required and also support the recommendation for radiotherapy alone in patients who may not tolerate the added toxicity of chemotherapy.

The European Organization for Research and Treatment of Cancer (EORTC) compared induction cisplatin + 5-FU followed by radiotherapy with a regimen of alternating cisplatin + 5-FU and radiotherapy for patients with locally advanced cancers of the larynx or hypopharynx. The 5-year results show no significant difference in larynx preservation for patients in the induction vs alternating groups (53.2% vs 59.8%) or overall survival (48.5% vs 51.9%). The lack of a difference in treatment outcome may relate to the heterogeneity of the patient population as larynx and hypopharynx cancers are biologically different diseases. Additionally, there were more interruptions/delays due to chemotherapy toxicity with the alternating regimen (7% of patients vs 24%) and a lower median dose of radiation received (71.5 Gy vs 62.8 Gy).

Larynx preservation for T2-T4 resectable cancers of the hypopharynx has been evaluated in two randomized controlled trials conducted by the EORTC. The recent trial noted above EORTC 24964 and an earlier trial patterned after the VALSG trial (EORTC 24891). This latter trial compared induction cisplatin + 5-FU followed by radiotherapy (in those achieving a clinical complete response at the primary) and the surgery control arm consisting of laryngopharyngectomy

and post-operative radiotherapy. At three years, survival rates were statistically equivalent and there was a 41% rate of preservation of a functional larynx. Distant metastases as a site of first failure was significantly reduced in the group receiving induction chemotherapy. Concomitant chemoradiation is commonly used based on extrapolation of the randomized trial results for larynx cancer. Concomitant chemoradiation to treat hypopharynx cancer does appear to increase the risk of esophageal stricture and feeding tube dependence.

Preservation of speech and swallowing function for locally advanced, resectable cancer of the oropharynx is an evolving topic as the epidemiology of this disease is now changing from primarily tobacco/alcohol-related to virus-related. High-risk oncogenic strains of the human papilloma virus (HPV), a sexually transmitted infection, are found in approximately 60% of cancers arising in the lingual and palatine tonsils in the US and Sweden. These HPV-positive cancers tend to present with cystic nodal metastases and small primaries, and have a better prognosis than tobacco/alcohol-related disease. Separate treatment approaches for HPV-positive and HPV negative cancers will likely evolve due to their differing biology, prognosis and sensitivity to chemotherapy and radiotherapy.

Surgery is the standard of care and the recommendation in published guidelines. For T3-4a or N2 disease, concomitant chemoradiation is the standard of care recommendation due to the increased risk of local-regional and distant failure. No trials directly compare surgery (with reconstruction) to concomitant chemoradiation. There is one randomized controlled trial limited to patients with oropharynx cancer and several non-randomized or mixed site trials that support this recommendation. Investigators in France compared radiotherapy alone (70 Gy) with concomitant carboplatin + infusional 5-FU and radiotherapy in patients with stages III or IV oropharyngeal cancer. This trial of 226 patients reported by the Groupe d'Oncologie Radiothérapie Tête et Cou (GORTEC) found significantly improved overall survival, disease-free survival and local-regional control for the combined treatment group.

The focus of research investigations differs for these three primary sites. For larynx cancer, improvement in disease-free survival and reduction of toxicity are important goals. Alternative low dose weekly chemotherapy schedules and/or biologics combined with radiotherapy may reduce acute and late effects and maintain high rates of organ preservation in the intermediate stage patients (T2N1, T3N0-1). For those with advanced nodal disease or T4 disease, sequential therapy (induction chemotherapy followed by chemoradiation), may afford improvement in disease-free and overall survival. For oropharynx cancer, the areas of most active research are risk stratification of patients based on HPV, p53 and EGFR status of the tumor, the addition of biologic therapies to chemoradiation, and the role of sequential therapy.

Post-operative adjuvant chemoradiation

The US Intergroup and the EORTC compared PORT with and without concomitant cisplatin (100 mg/m² days 1, 22 and 43), in resected patients with high risk pathologic features. The 5-year results of the EORTC trial were positive for overall survival (53% vs 40%, $p = 0.02$) progression-free survival (47% vs 36%, $p = 0.04$), and local-regional control (82% vs 69%, $p = 0.007$). The 2-year analysis of

the US trial was positive for improved disease-free survival and local-regional control; however, the 5-year results now show no significant improvement for any endpoint.

A pooled analysis of data from these two trials showed that the patients in both trials with positive margins or ECS derived survival benefit from chemoradiation. Unplanned subset analyses of the updated 5-year results of the US trial also suggested benefit limited to the presence of these two adverse pathologic features while those patients with multiple involved nodes only did not benefit from added chemotherapy. Thus, current guidelines recommend PORT plus concomitant cisplatin for resected patients with a microscopic positive margin or ECS. Clinical judgement should be used in determining post-operative adjuvant therapy when other adverse risk features are present.

Clinical investigations for patients at high risk of recurrence focus on alternative cytotoxics and combinations with biologics. An example is the RTOG randomized phase II trial of PORT plus concomitant weekly docetaxel and cetuximab or PORT plus concomitant weekly low dose cisplatin and cetuximab in patients with ECS or positive margins.

Sequential therapy: induction chemotherapy followed by concomitant chemoradiation

There is a renewed interest in induction chemotherapy because of randomized controlled trials that demonstrate superiority of a taxane added to cisplatin + 5-FU compared to standard cisplatin + 5-FU. Each study was designed with the same local-regional therapy (concomitant chemoradiation or radiotherapy alone) for all patients randomized to the two or three drug induction regimens. Substantial acute toxicity is associated with the three drug regimens; late effects have not been reported. Past studies of induction chemotherapy showed benefit against occult micrometastatic disease by a reduction in distant metastases. No studies have been completed that directly compare sequential therapy with concomitant chemoradiation although several such studies are in progress. The results of these trials are needed to clarify which patients benefit from this intensification of treatment and whether there are differences in pattern of failure and overall survival. Currently, there is no defined role for this treatment strategy outside of a clinical trial.

Sinus and skull base cancer

P.J. GULLANE
Department of Otolaryngology-Head and Neck Surgery,
University of Toronto, Ontario, Canada

Incidence

- Rare
- 0.5% of all malignancies
- < 3% of all head and neck malignancies
- 23% H&N cancer in Japan
- Annual incidence 0.5-1/100,000 population (USA)
- Males:females ~ 2:1
- Most common in 5th and 6th decade

Incidence by Sinus

- Maxillary sinus: 70-80 %
- Ethmoid sinus: 10-20%

- Frontal sinus: <5%
- Sphenoid sinus: <5%
- Nasal cavity: 20-30%

Etiology

- Unknown
- Evidence of occupational risk
- Inhalation of metal dusts or aerosols
- Exposure:
 - Wood dust – hard wood dust exposure ie. mahogany particles <5µm diameter
 - Industrial fumes, nickel-refining processes, leather tanning, chromium, asbestos, formaldehyde
 - Found in furniture, leather and textile industry
 - Reported increased rate from 20-100x

Etiology – Associations

- Nickel Workers:
 - 250x increased incidence of cancer of the sinus (Scand J Work Environ Health 1983;9:315-26)
- Random biopsy from the middle turbinate showed 21 % incidence of dysplasia (Scand J Work Environ Health 1983;9:315-26)
- Wood/leather dust associated with adenocarcinoma
- Tobacco smoke exposure associated with increased risk of SCC

Histology

SCC: 60-70%

Adenocarcinoma: 10-20%

Epithelial

Epidermoid/Squamous	Carcinoma (spindle cell, verrucous, transitional)
Non-Epidermoid	Adenoid cystic carcinoma Adenocarcinoma Mucoepidermoid carcinoma Acinic cell carcinoma Metastases
Neuroectodermal	Malignant melanoma Olfactory neuroblastoma Neurofibroma Neuroendocrine carcinoma Melanotic neuroectodermal tumor of infancy

Mesenchymal

Vascular	Angioosarcoma Kaposi's sarcoma Haemangiopericytoma
Muscular	Leiomyosarcoma Rhabdomyosarcoma
Cartilaginous	Chondrosarcoma (mesenchymal)
Osseous	Osteogenic sarcoma
Lymphoreticular	Burkitt's lymphoma Non-Hodgkin's lymphoma Extramedullary plasmacytoma Midline destructive lesions (T cell lymphoma) Fibrosarcoma Liposarcoma Malignant fibrous histiocytoma Ewing's sarcoma Alveolar soft part sarcoma

Presentation

- Often do not cause symptoms until they have expanded to a significant size or have extended through the bony confines of the sinus cavity or skull base.
- Tend to present at a more advanced stage.
- Oral symptoms: 25-35%
 - Pain, trismus, swelling of the gingiva or palate with loose teeth
- Nasal findings: 50%
 - Nasal obstruction, epistaxis, pain, episodes of sinusitis
- Ocular findings: 25%
 - Epiphora, diplopia, proptosis
- Facial signs:
 - Visible cheek swelling, numbness from involvement of the infraorbital nerve
- Intracranial – Skull Base:
 - Headache, central nervous system deficits

Clinical Evaluation

- Assessment of the overall facial symmetry
 - Any area of swelling or fullness
- Eye examination
 - Range of extraocular motion, visual acuity, pupillary response, and signs of globe displacement
 - Proptosis: anterior displacement of the globe from a mass impinging on the orbit
- Ear examination
 - to assess middle ear aeration and to evaluate possible eustachian tube dysfunction or obstruction
- Intraoral inspection
 - assess for fullness, signifying an expanding mass within the maxillary sinus or nasal cavity, dental mobility/sensitivity

Clinical Evaluation

- Mandibular excursion
 - Trismus = sign of pterygoid musculature invasion
- Cranial nerves
 - Attention to nerves I through VI
- Intranasal exam
 - Flexible or rigid endoscopy for optimal visualization of the nasal cavity and nasopharynx
- Subtle irregularities in the nasal mucosal lining
- Neck examination:
 - Evaluate for regional disease

Diagnosis

- Index of Suspicion
- Imaging
 - CT
 - MRI
 - PET
- Biopsy
 - Endoscopic Transnasal
 - Occasional open biopsy

Staging

- Ohngren's classification (1933)
- Imaginary line drawn from the angle of the mandible to the medial canthus of the eye
 - Anteroinferior section (infrastructure): better prognosis

- Posterosuperior section (suprastructure): worse prognosis

AJCC TNM System (Sixth Edition 2002)

Maxillary Sinus

- T1 Limited to antral mucosa – no erosion or destruction of bone
- T2 Erosion or destruction of the infrastructure, including the hard palate and/or middle meatus except extension to posterior wall of the maxillary sinus and pterygoid plates
- T3 Tumor invades skin of cheek, bone of posterior wall of the maxillary sinus, subcutaneous tissues, floor or medial wall of orbit, pterygoid fossa and ethmoid sinus
- T4a Tumor invades anterior orbital contents, skin of cheek, pterygoid plates, cribriform plate, sphenoid or frontal sinuses, infratemporal fossa
- T4b Tumor invades orbital apex, dura, brain, middle cranial fossa, cranial nerves other than V2, nasopharynx, clivus

AJCC TNM System (Sixth Edition 2002)

Nasal Cavity and Ethmoid Sinus

- T1 Tumor restricted to one subsite of nasal cavity or ethmoid sinus, with or without bony invasion
- T2 Tumor involves two subsites in a single site or extends to involve an adjacent site within the nasoethmoidal complex with or without bony invasion
- T3 Tumor extends to invade the medial wall or floor of the orbit, maxillary sinus palate, or cribriform plate
- T4a Tumor invades any of the following: anterior orbital contents, skin of nose or cheek, minimal extension to anterior cranial fossa, pterygoid plates, sphenoid or frontal sinuses
- T4b Tumor invades any of the following: orbital apex, dura, brain, middle cranial fossa, cranial nerves other than V2, naopharynx, clivus

Controversies in tumor management

- Treatment dictated by local expertise and consists of combination:
 - Radiation
 - Chemotherapy
 - Surgery
- No randomized control trials.
- Many retrospective series have reported superior outcomes with radical surgical resection followed by postoperative radiation compared to radiation alone.

Controversies in tumor management treatment

Factors influencing treatment depend on:

- Histology
- Stage
- Resectibility
- Reconstructive options
- Technical expertise of oncologists
- Medical comorbidities
- Facilities available
- Patient's acceptance of treatment

Radiation therapy

- Primary Radiation Therapy alone results in poor local control.
 - 40% 5 year local progression free survival (Waldron et al. Int J Radiat Oncol Bio Phys 1998;41:361-9)
 - Salvage surgery for radiation failure resulted in 22% 5 year survival (Curran, Gullane, Waldron, Irish et al. Laryngoscope 1998;108:1618-22)
- Advanced Technology
 - Stereotactic Radiotherapy (SRT)
 - Intensity Modulated Radiation Therapy (IMRT)
 - Tomotherapy
 - Allow radiation to complex targets with very little dose to surrounding tissue
- Advanced Radiation technology combined with chemotherapy may improve the reported 5yr survival

Radiation side effects

- Parsons et al. reported unilateral blindness in 16/48 patients treated with high dose radiation for paranasal and ethmoid sinus cancer
 - 4/48 → bilateral blindness
- Parsons et al. studies the risk of radiation induced optic morbidity
- Radiation retinopathy
 - 0% if exposed to < 45 Gy
 - 50% if exposed to 45-55 Gy
 - 100% if > 65 Gy

Controversies in tumor management

- Treatment dictated by local expertise and consists of combination
 - Radiation
 - Chemotherapy
 - Surgery
- No randomized control trials
- Many retrospective series have reported superior outcomes with radical surgical resection followed by post-operative radiation compared to radiation alone.

Chemotherapy

- Neoadjuvant, adjuvant, maintenance or palliative treatment
- Combined with radiation in a sequential or concurrent fashion
- Seems to enhance local control and disease specific survival (Cancer 2001;92:1495-1503).

Chemotherapy

- Systemic
- Intra-arterial
- Topical

Intra-arterial Cisplatin

- Samant et al. (2004) studied 19 patients with advanced paranasal sinus cancer
- Chemotherapy 2-3/wk
 - Cisplatin transfemoral catheterization of int. maxillary artery (ascending pharyngeal, middle meningeal)
 - Concomitant sodium thiosulfate – neutralizer
- Simultaneous XRT – 50Gy/5wk

- Surgery 8 weeks later
 - Craniofacial resection via frontal craniotomy (resecting F,E,S,M sinuses)
- Actuarial overall survival at 2 and 5 years was 68% and 53%.

Topical fluorouracil

- Knekt et al. (2001) studied 70 adenocarcinoma of the ethmoid sinus 1976-1999
- Surgery
 - Via anterior wall of maxillary sinus (Caldwell-Luc procedure) with removal of lateral nasal wall, medial maxilla, turbinates
- Topical 5% fluorouracil emulsion
- Cavity is then packed with 10 x 10 cm gauze swabs impregnated with 3% tetracycline hydrochloride
- Twice weekly pack changes and necrotomy via anterior antrostomy
- 8 dressing changes in total
- 12-16 wk: endoscopic inspection GA, multiple Bx + surgical removal, fluorouracil application, XRT (70Gy).

Controversies in tumor management

- Treatment dictated by local expertise and consists of combination
 - Radiation
 - Chemotherapy
 - Surgery
- No randomized control trials
- Many retrospective series have reported superior outcomes with radical surgical resection followed by post-operative radiation compared to radiation alone.

Surgery

- Choice of treatment
 - Surgery alone: tumor lacks high risk features such as high grade histology, close margins and perineural or vascular invasion
 - Multimodality therapy
- Type of surgery
 - Anatomic location
 - Extension.

Surgical treatment

- Mainstay in management
- Indication: tumor can be safely resected with clear margins and acceptable morbidity in the absence of metastases.

Endoscopic resection

- Messerklinger et al. (1973) first described endoscopic nasal surgery for inflammatory sinus disease
- Later used as management of benign and malignant tumors of the paranasal sinuses, mainly as an instrument for diagnosis, preoperative biopsy sampling, and post-operative follow-up
- Until recently, the limited exposure and difficulty in obtaining clear margins contraindicate this approach as definitive treatment

- Several small reports (1999) describe endoscopy as an alternative to the lateral rhinotomy approach in the extracranial removal of sinonasal tumor
- True or false?

Open surgery

- For many years, anterior skull base and/or infratemporal fossa involvement have been considered a contraindication to surgery
- In 1956, Conley described “The surgical approach to the pterygoid area”
- In 1963, Ketcham et al. published “A combined intracranial facial approach to the paranasal sinuses”
- In 1969, Terz et al. reported “Craniofacial resection for tumors invading the pterygoid fossa” via a lateral craniofacial resection.
- Since then several approaches have been described.

Prognosis

Gullane P and Conley J reviewed 112 carcinoma of maxillary sinus treated between 1953-1973 at Columbia Presbyterian University, New York (62% SCC).

- 33% 3 yr survival, 16% 10 yr survival
- Adverse outcomes associated with extension into
 - Orbit → 17% 5yr cure rate
 - Infratemporal or pterygopalatine fossa → 0% 5yr cure rate
 - Cervical nodal metastases → 0% 3yr survival

Waldron et al. reviewed 110 maxillary antrum carcinoma between 1976-1993 at PMH (85% SCC).

- 43% 5yr survival
- Multiple regression analysis identified the following adverse predictors
 - Local disease extent
 - Nodal disease at presentation.

Management of the orbit

- The orbit can often be preserved
- Does not compromise overall survival or local control of disease
 - Preoperative radiation therapy and intraoperative frozen section analysis.
 - A globe that has been preserved without the support of the orbital floor is unlikely to retain significant function especially if radiation therapy is used.

Management of the neck

- Cantú et al. (2008), studied 704 consecutive sinus cancer 1968-2003 staged according to AJCC 2002
- Only patients with clinically positive nodes had neck dissection
- At baseline 1.6% and 8.3% of ethmoid and maxillary cancer had nodal diseases
- 5 yr estimates for recurrent nodal disease were 4.3 and 12.5%
- Maxillary sinus SCC had highest incidence of nodal metastasis particularly in T2 cancer
- Conclusion
 - Suggested treatment of N0 neck for T2 maxillary SCC disease because of its location on the floor of the maxilla with possible extension to hard palate and significant potential for nodal disease

- Recommended for all undifferentiated carcinoma in the ethmoid sinus.

Management of the neck

- N+ necks require treatment with surgery ± radiation
- Treatment in N- necks remains controversial
- Nodal recurrence
 - as high as 38% in untreated necks
 - 10-15 % in most large series
- Those who fail in the neck usually have concomitant local failure and for those who don't salvage surgery/radiation are available.
- Witterick et al. (2003) “At this time most evidence suggests against treating the neck prophylactically”.

Maxillary reconstruction-current controversy

- Surgical extreme – no role for prosthetics and all defects can be reconstructed regardless of the cost to the patient and the ultimate functional and aesthetic result
- Prosthetic extreme – surgeons zealously pursue surgical options for personal reasons (financial or ego) with little regard for the aesthetic and functional results and the cost to the patient

Maxillectomy with orbital exenteration – Always reconstruct

Menu

- Palatal obturator
- Free flaps
 - Radial forearm?
 - Scapula
 - Iliac crest
 - Anterolateral thigh flap
 - Latissimus dorsi flap
 - Rectus abdominus
- Temporalis muscle flap?

Outcome and prognosis

- Improved survival with surgery and postoperative radiation therapy
- Chemotherapy and radiation therapy regimens have been reported to show some improvement in survival

Results of skull base surgery

	5 year survival
Ketchum 1963	50%
– 1960's – 1970's	
Cheeseman	50%
– 1970's – 1980's	
Shah 1992	63%
– 1980's – 1990's	
Irish, Gullane 1994	54%
– 1983 – 1992	

International Collaborative Study Group Craniofacial surgery for malignant skull base tumors

- 1541 patients treated between 1956-2000 were accrued
- Exclusions:
 - No pathologic information = 26 (2%)

- No follow-up data = 88 (6%)
- Benign Tumors = 120 (8%)
- 1307 patients eligible for analysis

ICSG for CFS – Predictors of outcome

- Patient and tumor related covariates analyzed for survival outcomes in univariate and multivariate analysis

ICSG for CFS

Conclusions

- CFR is a safe and effective treatment option for malignant skull base tumors
- Histology of the primary tumor, its intracranial extent and status of surgical margins are independent predictors of RFS, OS and DSS
- Future role of endoscopic approaches are still in development and we must be diligent to monitor progress using this approach.

Laryngopharyngeal cancer

J.L. LEFEBVRE

Northern France Comprehensive Cancer Center, Lille, France

Introduction

The laryngopharynx is implicated in vital functions (breathing and swallowing) as well as in social functions (phonation). This explains the impressive clinical research that has been carried out all along the past century for the treatment of cancers of the larynx and the hypopharynx. The surgical research has explored the technical possibilities of avoiding a total laryngectomy (TL). Over the past three decades new radiotherapy (RT) modalities have achieved better local control while chemotherapy (CT) has been definitely integrated in treatments with curative intent.

1. Early stages

There is no major discussion for early diseases (T1 and T2) as the three options (endoscopic laser surgery, open partial surgery and definitive RT) get quite similar results but with different advantages and disadvantages (in terms of overall treatment time and of quality of voice in particular). The most appropriate treatment may be individualized according to the tumor and patient's characteristics. The disease is controlled in about all the cases and the main risk is the appearance of a second primary tumor in particular in the lung. There is no room for chemotherapy. To date there is no convincing data on the role of chemoprevention for these metachronous cancers.

2. Moderately advanced and advanced stages

On the contrary decision-making is less consensual for advanced diseases. For a long period of time patients were treated by either TL with postoperative RT or by definitive RT according to institutional policies. No randomized comparison of these two therapeutic options has been carried out.

2.1. Endoscopic carbon dioxide laser surgery (ELS)

Historically laser surgery was used on one hand for glottic then for supraglottic and after that for hypopharynx cancers

and on the other hand for Tis, for T1 and thereafter for T2 diseases. There is no major discussion for these indications that are well documented. On the contrary carbon dioxide laser surgery is more debated for more advanced cases. There are converging data on ELS for moderately advanced laryngeal cancers but on much selected series. A neck dissection is often required as well as postoperative irradiation (in particular for supraglottic cancers). There are very few reports for hypopharynx cancers.

2.2. Extended partial surgery

Supracricoid partial laryngectomy

Whatever the type of procedure (cricohyoidopexy, CHP or cricohyoidoepiglottopexy, CHEP), this surgery requires a notable expertise of the surgeon, nurses and speech therapists as well as a real motivation of the patients as postoperative courses may last 3 to 4 weeks, sometimes even longer. However this surgery provides excellent results in terms of disease control (around 90 %) and rather good results in terms of function but at the price of a strong selection of patients. This surgery is most often performed on T2 diseases but feasible in much selected cases of moderately advanced larynx SCC. In even more selected cases it may be used for salvage after RT.

Partial laryngopharyngectomies

This surgery may be used for lateral epilarynx tumors or hypopharynx tumors with either the classical technique removing the ipsilateral true vocal cord of a modified technique (supraglottic hemipharyngolaryngectomy). Again this surgery is indicated in T1-2 diseases and in selected T3 diseases. Reported local control ranges between 80 and 90 %.

Near total laryngectomy

This technique removes a large part of the larynx and the entire piriform sinus (the remaining part of the larynx being used to form a vocal shunt). Both survival and disease control are similar to those gained with a conventional total laryngectomy (see below). With this surgery patients may get a fair voice but cannot avoid a permanent tracheotomy. As a result this procedure should be considered as a variant of the conventional total laryngectomy

2.3. Total laryngectomies (with or without partial pharyngectomy)

Most advanced laryngopharyngeal tumors have been treated by radical surgery including a TL. All published data reported locoregional control over 85 % and 5-year survival ranging between 50 % (larynx) and 35 % (hypopharynx). This notable control above clavicles must continue to be taken into account. This clearly means that radical surgery remains a tool among others to be used for the treatment of advanced diseases. After this surgery voice rehabilitation may be achieved in motivated patients by the means of a vibrator, of the so-called esophageal voice or much better with a tracheo-esophageal voice prosthesis.

3. Radiation therapy

In the absence of a randomized trial (TL with postoperative RT versus definitive RT with or without salvage TL) no definitive conclusion may be asserted. However it seems that surgery gets better results than conventional RT for T3-T4

cancers in laryngeal tumors and moreover in hypopharynx tumors. But honestly the patients' selection favors surgical series (resectable diseases in operable patients).

Both altered fractionation (hyperfractionation or concomitant boost) and concurrent CT-RT have been reported as able to improve the local control. But very few studies focused on laryngopharyngeal cancers.

4. Larynx preservation

Clinical research on larynx preservation has been major advance. In the early 80s, cisplatin-based induction chemotherapy (ICT) appeared as able to provide impressive response rates and chemosensitivity appeared to be predictive of radiosensitivity. This was the beginning of this challenging research.

4.1 First generation of larynx preservation trials.

Conventional treatment (TL with postop RT) was randomly compared with ICT followed by irradiation in good responders or by the conventional treatment in poor responders. From the published trials it appeared that survival was unchanged but nearly 60 % of the larynx could be preserved in the experimental arms.

4.2. Second generation of larynx preservation trials

ICT-based protocols were compared to concurrent CT-RT. It appeared that the larynx preservation rate was superior after concurrent CT-RT but the price to be paid was a notable acute and late toxicity that may ultimately compromise the preserved function. However there was no impact on survival.

Discussion and future prospects

Treatment of the so-called advanced laryngopharyngeal cancers remains a permanent challenge, as there are many options. For early diseases, endoscopic or open surgery and irradiation are appropriate approaches. For moderately advanced tumors, laser CO₂ surgery and supracricoid laryngectomies are effective surgical approaches for both controlling locally the disease and preserving the larynx function. But their indications are limited due to a thorough selection of patients and subsequently are suitable for individual clinical use. These tumors are most probably also good candidates for larynx preservation protocols. For advanced diseases the discussion is between TL (the so-called "mutilating surgery) and larynx preservation. Surgery should be reserved for infiltrative glottic, transglottic or subglottic tumors or for tumors with a massive destruction of the preepiglottic space or of the thyroid cartilage. The other cases should be offered a larynx preservation protocol. To date there are two validated options: ICT-based protocol or concomitant CT-RT. New ICT regimens including docetaxel and concurrent administration of targeted therapy (cetuximab) and RT are also parts of this clinical research. The next step could be ICT followed by concurrent CT-RT in good responders.

Conclusions

For early diseases there are three options: endoscopic laser surgery, open partial surgery or irradiation. For (moderately) advanced diseases there are four options: extensive partial surgery in much selected cases (endoscopic or open surgery), radical surgery, definitive RT (alone with conven-

tional or altered fractionation or combined with chemotherapy or molecular targeted therapies), larynx preservation approaches. The quality of the initial work-up and a fair multidisciplinary discussion are the only indisputable golden standards to better select the most appropriate treatment for each particular case and to better design future trials.

Combining radiotherapy with molecular therapeutics

K.K. ANG

University of Texas M.D. Anderson Cancer Center, Houston, U.S.A.

Although concurrent radiation-chemotherapy improves tumor control, the management of its acute toxicities can be complex and labor intensive and its long-term morbidity can be severe. This finding combined with advances in the knowledge of molecular radiation biology provided the foundation for developing rational strategies for combining radiotherapy with molecular therapeutics. Research on epidermal growth factor receptor (EGFR) exemplified such coordinated research efforts. Collectively, laboratory and clinical investigations revealed mechanisms by which a specific receptor tyrosine kinase pathway affect cellular response to radiation, validated the concept of selectively modulating tumor response to radiotherapy by targeting a perturbed signaling pathway, and established a novel combined therapy strategy for the treatment of locally advanced HNSCC. This pivotal success story inspired further investigations in this field. The lecture summarizes relevant findings on EGFR spanning from the bench to the clinic, put into historical perspective and in the context of current and future investigations in radiation oncology. A few examples of combining radiation therapy with other molecular therapeutics are also briefly presented as illustration.

The first clue that EGFR expression might affect intrinsic cellular radiation sensitivity *in vivo* emerged from a study on murine models by Akimoto et al.¹ This showed that exposure to a single dose induced EGFR autophosphorylation and downstream signaling only in tumors with high EGFR expression and this phenomenon was associated with relative resistance of tumor to RT (i.e., higher median tumor control dose, TCD50). Since tumor clonogen repopulation generally plays no or negligible role in determining *in vivo* tumor response to single dose irradiation², these results were interpreted as an indication that EGFR expression contributes to determining the intrinsic cellular radiation sensitivity. This finding is supported by the data of a complementary correlative biomarker study conducted using human HNSCC specimens presented in the next section³. This study revealed that the overall and disease-free survival rates of patients with high EGFR expressing carcinomas (> median) were highly significantly lower ($p = 0.0006$ and $p = 0.0016$, respectively) and the local-regional relapse rate was highly significantly higher ($p = 0.0031$) than those of patients with lower EGFR expressing HNSCC. However, there was no difference in the distant metastasis rates between the two groups ($p = 0.96$). Multivariate analysis showed that EGFR expression was a strong, independent predictor of survival and of local-regional relapse.

A follow up study by the same group revealed evidence for a causal relationship between cellular EGFR expres-

sion and relative radiation resistance. This study showed that transfection of human EGFR expression vectors into a low EGFR-expressing murine ovarian carcinoma cell line, OCA-I, resulted in an EGFR level-dependant increase in resistance to ionizing radiation ⁴. It also demonstrated that exposing EGFR transfectants to antibodies against EGFR, cetuximab (C225, ErbituxTM), reduced the level of EGFR receptors along with the downstream substrates (e.g., Akt and MAPK) and reversed the cellular radiation resistance. The data of a subsequent experiment elucidated the mechanism by which EGFR affects radiation sensitivity ⁵. This thorough study showed that in contrast to cytoplasmic signaling induced by the natural ligand EGF, ionizing radiation triggered EGFR translocation into the nucleus. This process was accompanied by a nuclear influx of the proteins Ku70/80 and the protein phosphatase 1. As a consequence, there was an increase in the activity of DNA-dependent kinase (DNA-PK) in the nucleus and formation of the DNA end-binding protein complexes containing DNA-PK, which are essential for repair of DNA double-strand breaks. Blockade of the EGFR by cetuximab abolished EGFR import into the nucleus, radiation-induced activation of DNA-PK, inhibited DNA repair, and enhanced cellular radiation sensitivity.

The potential modulation of radiation response with EGFR inhibitors came into focus in the late 1990s. Initial

studies examined the effect of cetuximab ⁶⁻⁹ and showed enhanced tumor response to single-dose, and subsequently fractionated, radiation in tumor cell lines and in xenograft models using regrowth delay ^{6,8} and tumor control as the endpoints ¹⁰.

This observation along with impressive results of preclinical studies motivated many investigators in undertaking a multinational randomized trial assessing the efficacy of adding anti-EGFR antibody, cetuximab, to radiotherapy in the treatment of patients with locally advanced HNSCC ¹¹. As shown in Table I, this pivotal trial demonstrated that the addition of only eight doses of cetuximab starting one week before and continuing during radiotherapy resulted in a significant improvement of the local-regional control, progression-free survival, and overall survival without increasing common radiation-induced side effects (Tab. II), including mucositis and dysphagia. However, cetuximab does induce acneiform rash needing attentive care and occasionally infusion reactions requiring discontinuation of the agent.

Taken together, coordinated laboratory and clinical studies have generated strong excitements because in addition to producing a new, less toxic therapy option, it established the proof-of-principle that modulating a signaling pathway that is perturbed in tumors can lead to selective tumor sensitization to radiotherapy and thereby truly improve the therapeutic index. Such selective enhancement of tumor re-

Tab. I. Efficacy of the combination of radiotherapy (RT) with cetuximab (N = 212) versus radiotherapy alone (N = 208) in the treatment of patients with locally advanced HNSCC.

Endpoints	RT alone	RT + cetuximab	Hazard Ratio (95% CI)	P Value
Local-regional control	14.9	24.4	0.68 (0.52-0.89)	0.005
Median duration (mo)	41	50		
Rate at 2 year (%)				
Progression-free survival	12.4	17.1	0.70 (0.54-0.90)	0.006
Median duration (mo)	37	46		
Rate at 2 year (%)				
Overall survival	29.3	49.0	0.74 (0.57-0.97)	0.03
Median duration (mo)	45	55		
Rate at 3 year (%)				
Distant metastasis*	10	8		
Rate at 1 year (%)	17	16		
Rate at 2 year (%)				

* Cumulative Incidence. Modified from Bonner et al. ¹¹.

Tab. II. The incidence (%) of most common adverse events of the combination of radiotherapy with cetuximab (N = 212) versus radiotherapy alone (N = 208) in patients with locally advanced HNSCC.

Side effects	All grades			Grades 3-5		
	RT	RT + C*	P Value	RT	RT + C	P Value
Mucositis	94	93	0.84	52	56	0.44
Dysphagia	63	65	0.68	30	26	0.45
Weight loss	72	84	0.005	7	11	0.12
Dehydration	19	25	0.16	8	6	0.57
Dermatitis	90	86	0.24	18	23	0.27
Xerostomia	71	72	0.83	3	5	0.32
Acneiform rash	10	87	< 0.001	1	17	< 0.001
Infusion reaction	2	15	< 0.001	0	3	0.01

*Cetuximab. Modified from Bonner et al. ¹¹.

sponse has not been accomplished by combining radiation with traditional chemotherapy such as cisplatin, taxanes, etc. The weakness of this trial by the current standard is that the control group received radiotherapy alone rather than concurrent radiochemotherapy, which was recently established as the new standard-of-care based on positive results of several trials. Based on tolerability, however, cetuximab plus radiation therapy could represent the treatment of choice for patients with intermediate-stage disease, when the relatively good outcomes do not justify the toxicity of radiochemotherapy. It may also provide an effective and better tolerated alternative to radiochemotherapy for patients with more extensive HNSCC who are ineligible for chemotherapy or unlikely to complete radiochemotherapy as planned.

Further investigations are underway to elucidating the relative efficacy of cetuximab plus radiation versus radiochemotherapy and patient subset that are appropriate for radiotherapy plus cetuximab relative to radiochemotherapy. Studies are also ongoing to assess the efficacy of combining cetuximab with neoadjuvant therapy or with concurrent radiochemotherapy.

References

- ¹ Akimoto T, Hunter NR, Buchmiller L, Mason K, Ang KK, Milas L. *Inverse relationship between epidermal growth factor receptor expression and radiocurability of murine carcinomas*. Clin Cancer Res 1999;5:2884-90.
- ² Milas L, Akimoto T, Hunter NR, Mason KA, Buchmiller L, Yamakawa M, et al. *Relationship between cyclin D1 expression and poor radioresponse of murine carcinomas*. Int J Radiat Oncol Biol Phys 2002;52:514-21.
- ³ Ang KK, Berkey BA, Tu X, Zhang HZ, Katz R, Hammond EH, et al. *Impact of epidermal growth factor receptor expression on survival and pattern of relapse in patients with advanced head and neck carcinoma*. Cancer Research 2002;62:7350-6.
- ⁴ Liang K, Ang KK, Milas L, Hunter N, Fan Z. *The epidermal growth factor receptor mediates radioresistance*. Int J Radiat Oncol Biol Phys 2003;57:246-54.
- ⁵ Dittmann K, Mayer C, Fehrenbacher B, Schaller M, Raju U, Milas L, et al. *Radiation-induced epidermal growth factor receptor nuclear import is linked to activation of DNA-dependent protein kinase*. J Biol Chem 2005;280:31182-9.
- ⁶ Huang SM, Bock JM, Harari PM. *Epidermal growth factor receptor blockade with C225 modulates proliferation, apoptosis, and radiosensitivity in squamous cell carcinomas of the head and neck*. Cancer Research 1999;59:1935-40.
- ⁷ Huang SM, Harari PM. *Epidermal growth factor receptor inhibition in cancer therapy: biology, rationale and preliminary clinical results*. Invest New Drugs 1999;17:259-69.
- ⁸ Milas L. *Chemoradiation interactions: potential of newer chemotherapeutic agents*. In: Perry MC, editor. *American Society of Clinical Oncology Education Book*. 2000. pp. 207-13.
- ⁹ Saleh MN, Raisch KP, Stackhouse MA, Grizzle WE, Bonner JA, Mayo MS, et al. *Combined modality therapy of A431 human epidermoid cancer using anti-EGFr antibody C225 and radiation*. Cancer Biother Radiopharm 1999;14:451-63.
- ¹⁰ Nasu S, Ang KK, Fan Z, Milas L. *C225 anti-epidermal growth factor receptor antibody enhances tumor radiocurability*. Int J Radiat Oncol Biol Phys 2001;51:474-7.
- ¹¹ Bonner JA, Harari PM, Giralt J, Azarnia N, Shin DM, Cohen RB, et al. *Radiotherapy plus cetuximab for squamous-cell carcinoma of the head and neck*. N Engl J Med 2006;354:567-78.

Molecular therapeutics with chemotherapy

A.A. FORASTIERE

Johns Hopkins University School of Medicine, Department of Oncology, Baltimore, U.S.A.

Cancers of the head and neck have a worldwide annual incidence of approximately 565,000 new cases and an annual mortality rate of nearly 300,000. It is recognized that approximately half of newly diagnosed individuals will succumb to their cancer. Thus, there is a pressing need for improvement in initial curative therapies and also the development of more effective therapies to prolong life in those with incurable recurrent and metastatic disease. This discussion will focus on treatment of the latter group of patients, the role of chemotherapy for palliation and the integration of molecular therapeutics into the management of head and neck cancer.

Prior to the availability of cisplatin in the late 1970s, systemic therapies were limited to methotrexate and bleomycin. The involvement of the medical oncologist came late in the course of the disease which was often a bulky, fungating primary or neck recurrence and the effectiveness of chemotherapy was marginal at best. In the 1980s, clinical trials research in head and neck cancer spearheaded by Muhyi Al-Sarraf and colleagues at the Wayne State University in Detroit, Michigan evaluated cisplatin and infusional 5-fluorouracil (5-FU). The chemotherapy doublet resulted in rapid tumor regression in 35-40% of patients with recurrence and in 75-85% of patients with newly diagnosed squamous cancers and this finding led to subsequent trials of induction chemotherapy as part of initial curative management. Patients with recurrent disease also experienced rapid regression of their cancer and improvement in symptoms such as pain. However, cumulative toxicity such as neuropathy, hearing loss, and renal tubular damage, limited the number of cycles that could be given without substantial negative impact on quality of life. Trials comparing cisplatin-based combination regimens to single agents did show higher response rates and occasional durable clinical complete responses with combination therapy. However, the proportion of patients responding was insufficient to significantly improve overall survival, and toxicity was additive.

The taxanes, a totally new class of drug that caused stabilization of microtubules and accumulation of cells in the G2/M phase of the cell cycle, were found to have activity in head and neck cancer in the early 1990s. A series of trials were conducted in the US utilizing various doses and schedules of paclitaxel as a single agent and in combination with cisplatin or carboplatin. In Europe, docetaxel was the dominant compound in similarly designed clinical trials. Both taxanes appeared to be more active as single agents than 5-FU and pre-clinical data indicated synergistic effects with cisplatin. This led to a head-to-head comparison of cisplatin/5-FU and cisplatin/paclitaxel (ECOG trial 1395) as firstline therapy for patients with recurrence or metastatic squamous cell cancers of the oral cavity, oropharynx, larynx and hypopharynx. Overall survival was the primary endpoint. No significant difference in median (8.7 vs 8.1 mos) and overall survival (41% vs 32% at 1 year) was observed. However, a new survival benchmark for comparative trials was set with the median

survival of the cisplatin/5-FU group of approximately 9 months and a 40% 1-year survival rate. This improvement over prior outcomes of 6 month median and 20% 1-year survival rates was probably due to better supportive care and patient selection factors. Toxicity was substantial in both treatment groups.

In summary, the goals of treatment of the patient with incurable squamous cell carcinoma of the head and neck are palliation of symptoms and prolongation of survival. All patients should be offered the opportunity to participate in clinical trials of new therapeutics. Efforts to effectively treat this population are often complicated by the consequences of tumor location: cranial nerve dysfunction, pain, aspiration, protein-calorie malnutrition, and co-existing chronic hepatic, pulmonary and cardiac disease. The factors associated with poor outcome include poor performance (or functional) status, lack of social support, ongoing tobacco and alcohol use, high volume of disease, hypercalcemia, and multiple prior treatments with minimal response. Thus, treatment guideline recommendations are based on patient performance status (PS). The recommendation for patients who are asymptomatic from their cancer (PS 0) or symptomatic but completely ambulatory and able to work (PS 1) is for either single agent or combination chemotherapy. For those who are symptomatic and not able to work but spend less than 50% of daytime in bed (PS 2), single agent chemotherapy or best supportive care is recommended. Patients with lesser functional status should be managed with best supportive care.

The treatment outcomes that can be expected for a patient with good performance status (0 or 1) are the following: (1) response rate of approximately 35% with fewer than 10% achieving a clinical complete response. Response duration is proportional to the degree of response but for most, the duration is brief, 3-4 months. (2) The median survival time is 7-9 months with 1-year survival rate of 30-40%. (3) Prospective randomized controlled trials show that higher response rates are achieved with combination regimens compared to single agent methotrexate, cisplatin, or 5-FU (~35% vs 10-15%) but overall survival rates are similar. Response and survival outcomes with taxane regimens are not better than cisplatin/5-FU. These factors and the absence of any new cytotoxic therapeutics with novel mechanism on the horizon, coupled with advances in our knowledge of molecular carcinogenesis, have shifted investigations to the exciting area of molecular therapeutics.

A simplistic view of the goal of molecular therapeutics is to block the pathways that are signaling cell proliferation and to restore the pathways of apoptosis and cell senescence that have been affected by the inactivation of tumor suppressor genes in the malignant cell. The various targets include signal transduction pathways from the cell membrane to the nucleus, cell cycle traversal, programmed cell death, transcription regulation, matrix invasion leading to metastases, and angiogenesis. The pathway target that has been the primary focus of studies to date in squamous cancers of the head and neck is the epidermal growth factor receptor (EGFR) and its downstream pathways.

The rationale for EGFR as an ideal therapeutic target is that nearly all squamous cell cancers of the head and neck overexpress the EGFR relative to adjacent normal tissue. The net effect is promotion of tumor proliferation, sur-

vival, angiogenesis, invasion and metastases. Further, it has been established that shortened survival and resistance to radiotherapy directly correlate with the level of receptor expression. Two major pathways dependent on EGFR for activation are the Ras/Raf//MAP kinase pathway that mediates proliferation and the PI3K/AKT pathway that mediates cell survival. Through complex signaling cascades, these activated pathways result in nuclear gene transcription and transition of the cell cycle from G1 to S-phase. The EGFR is a transmembrane receptor belonging to a family of four related proteins. These receptors are composed of an extracellular ligand binding domain, a transmembrane region, and an intracellular tyrosine kinase (TK) binding domain. Ligand binding to a single chain of the EGF receptor initiates dimerization with other ErbB family transmembrane receptors which then activates the intracellular TK domain to undergo autophosphorylation and subsequent activation of the Ras/Raf/MAPK and PI3/AKT downstream signaling pathways.

Two classes of anti-EGF receptor therapies in clinical trials are monoclonal antibodies and small molecule tyrosine kinase inhibitors. There are two antibodies, cetuximab which is a mouse/human chimeric antibody, and panitumumab, a fully humanized antibody. These compounds compete with the natural EGF ligands for binding to the extracellular binding pocket of the EGF receptor and thereby block the steps of dimerization and TK autophosphorylation. The antibodies are highly selective and specific for the EGFR. The small molecule TK inhibitors (erlotinib, gefitinib) reversibly compete with ATP to bind to the intracellular site of the receptor and thereby block autophosphorylation and downstream signaling. Many small molecule TK inhibitors that can target more than one receptor tyrosine kinase are in development and in clinical testing in a variety of tumor types. The TK inhibitors are oral formulations taken daily while the antibodies are administered intravenously at one to two week intervals. The most frequent toxicity, common to both classes of inhibitors, is an acneform rash.

Pre-clinical studies in model systems demonstrated that EGFR inhibitors of both classes had modest activity when used alone but were able to potentiate the anti-tumor efficacy of a number of cytotoxics, including cisplatin, docetaxel and paclitaxel, and of radiotherapy. Clinical trials have subsequently confirmed this finding. For example, the single agent activity of gefitinib in maximal dose of 500 mg per day tested in patients refractory to cisplatin-based chemotherapy is 10-15%, median progression-free survival 3 months and median survival 6-8 months. When gefitinib or erlotinib were combined with cisplatin + docetaxel, the response rate was 65%, median progression-free survival 6 months and median survival 11 months, suggesting enhanced effect. Studies of cetuximab evaluated as a single agent or combined with cisplatin in patients who had previously progressed on platinum-based chemotherapy showed a 10-13% objective response rate with progression-free survival of 2-3 months and median survival in the 5-6 month range. These cetuximab studies taken together demonstrated that EGFR blockade did not overcome cisplatin resistance. However, when cetuximab was combined with platinum + 5-FU in the firstline therapy of patients with recurrent disease, the objective response rate was 36% and median survival 10 months, again suggesting survival prolongation and enhanced effect.

The results from these multiple phase II trials led to two randomized controlled trials of platinum chemotherapy + cetuximab versus chemotherapy alone in the firstline treatment of patients with recurrent or metastatic squamous head and neck cancer. The first trial, reported by B. Burtness for the Eastern Cooperative Oncology Group (ECOG), was a randomized placebo controlled trial of cisplatin + placebo versus cisplatin + cetuximab. With 123 patients randomized, the mature results showed a statistically significant improvement in objective response rate – 10% for the cisplatin/placebo group versus 26% for the cisplatin/cetuximab group ($p = 0.03$). The median progression-free survival was 2.7 versus 4.2 months ($p = 0.09$) and median survival 8 versus 9.2 months ($p = 0.29$). While there was a trend for improvement in progression-free survival, in retrospect, the study was not adequately powered to show a survival difference. The preliminary results of the second randomized trial, the EXTREME study have been reported by J. Vermorken. This trial randomized 442 patients to treatment with platinum (cisplatin or carboplatin) + 5-FU + cetuximab versus platinum + 5-FU. A maximum of six cycles of chemotherapy was given and patients were taken off study for either unacceptable toxicity or progression of disease. The patients in the platinum + 5-FU + cetuximab group continued to receive cetuximab after completing chemotherapy until disease progressed. A statistically significant improvement in response rate – 35.6% (95% CI 29.3, 42.3) versus 19.5% (95% CI 14.5%, 25.4%), $p = 0.0001$; progression-free survival – median 5.6 versus 3.3 months, HR 0.538, $p < 0.0001$; and overall survival – median 10.1 versus 7.4 months, HR 0.797, $p = 0.0362$, was reported. Severe and life-threatening toxicities that were more frequent in the cetuximab group were hypokalemia, hypomagnesemia, vomiting and diarrhea. Acneiform rash and hypersensitivity reactions occurred exclusively in patients receiving cetuximab. This grade of toxicity occurred in $< 10\%$ of patients. In summary, these two randomized controlled trials demonstrate the benefit of EGFR inhibition and safety in combination with cisplatin-based cytotoxic regimens. Furthermore and importantly, for the first time, a regimen has shown significant improvement in survival for patients with recurrent disease. Randomized controlled trials of cisplatin + 5-FU with or without panitumumab, and docetaxel + gefitinib or placebo are in progress.

The other growth factor receptor inhibitor that has been studied extensively and approved for use in several solid tumors is the antibody bevacizumab that targets the vascular endothelial growth factor receptor (VEGF-R). The VEGF protein family (VEGF A, B, C, D, E) bind to specific TK receptors activating signal transduction that is essential for angiogenesis. VEGF production in tumor cells is stimulated in part by a hypoxic microenvironment through production of hypoxia inducing factor (HIF1 α) and other growth factors including EGF, platelet-derived growth factor (PDGF) and insulin-like growth factor (IGF). Multi-targeted small molecule TK inhibitors that can potentially shut down signal transduction by blocking two or more of these targets are in development and in various stages of clinical testing. Studies in head and neck cancer that are currently ongoing include the combination of cetuximab and bevacizumab (targeting both EGFR and VEGFR); cisplatin + docetaxel with or without bevacizumab;

carboplatin + paclitaxel + sorafenib, a multi-targeted antibody (VEGFR, PDGFR, B-RAF) active in renal cell carcinoma; as well as single agent studies of at least a half-dozen other multi-targeted oral small molecule TK inhibitors.

In contrast to the empiric development of cytotoxic therapies in past decades, studies of these targeted therapies are noteworthy for biomarker tissue correlative assays on biopsy material obtained before and during treatment. These analyses enable verification that the molecular agent is hitting the target and whether or not signal transduction via a specific pathway has been affected. This offers the potential for identification of predictive and prognostic factors and treatment selection based on the molecular characteristics of the individual tumor. Given the rapid pace of molecular therapeutics research and development by government and industry, the emergence of new paradigms for individualized treatment is a realistic goal for our patients with head and neck cancer.

Soft tissue & parapharyngeal space tumors

W.I. WEI

Department of Surgery, University of Hong Kong Medical Centre, Queen Mary Hospital, Hong Kong

Soft Tissue Tumors

Introduction

Soft tissue tumor in the head and neck region are grouped as benign or malignant pathologies that originated from various soft tissues. Malignant tumors arising from the soft tissue in the head and neck region are relatively rare and thus are frequently misdiagnosed. The few factors that lead to the clinical suspicion of soft tissue malignant tumors are:

1. patients with neurofibromatosis, as with time some of the benign tumors may undergo malignant transformation.
2. Patients who had previous radiation and they are more prone to develop fibrosarcoma and osteosarcoma, especially in the heavily irradiated area.
3. Immunocompromised patients, patients with HIV infection and those who had organ transplantation and were on immunosuppressive therapy.
4. Children who have rapid growing subcutaneous masses.

Clinical evaluation

A tumor that rapidly increases in size suggests its sinister nature. Sarcoma arising from a nerve usually grows along its long axis and appears as a fusiform mass while liposarcoma or fibrosarcoma often assumes a round or ovoid configuration. A uniformly firm or hard tumour in the soft tissue is considered malignant until proven otherwise. Invasion or infiltration of surrounding tissue such as vessels, nerves, muscle or bone is a sign of poor prognosis.

In children, tumors located at the temporal area, maxilla area or along the lateral margin of the nose should arouse the suspicion of a rhabdomyosarcoma. Sarcomas located in the neck in general have a better prognosis than those found in the head.

Investigations

Most soft tissue tumors in the head and neck region can be adequately assessed by modern imaging modalities. These include high-resolution ultrasound (US), multislice spiral computed tomography (CT) and high-field magnetic resonance imaging (MRI). Both CT and ultrasound imaging can be used to accurately guide biopsy of non-specific soft tissue tumors. Positron emission test is useful in differentiating recurrent or residual soft tissue sarcomas from post-therapy changes and in the detection of distant metastasis.

Diagnosis

In view of the therapeutic implications and prognostic factors, it is essential to obtain adequate tissue from the tumor for histological examination. Fine needle aspiration or trucut biopsy does not provide enough tissue for a proper pathological examination to reach a definite diagnosis. For superficial lesions, an incision biopsy might obtain adequate tissue while for deep-seated lesions, incision biopsy might still be insufficient and this might disrupt the tissue planes. When a sarcoma is suspected, excision biopsy of the lesion should be carried out if anatomically feasible. Sarcomas tend to metastasize by the haematogenous route rather than to the regional lymph nodes. Thus X-ray of the chest or CT of the chest is essential before therapy.

Pathology

Although the histological grading of the sarcoma carries with it prognostic significance, the histological type is important. Dermatofibrosarcoma protuberance is locally aggressive and rarely metastasizes while others may disseminate widely, such as malignant fibrous histiocytoma and angiosarcoma. Rhabdomyosarcoma tend to be localized while Kaposi's sarcoma tends to be multifocal. Malignant schwannoma involves and spreads along nerves. The soft tissue tumors are classified according to their presumed line of differentiation. Hence those soft tissue tumors that show histologic features of smooth muscle are classified as leiomyoma and leiomyosarcoma, depending on whether it is benign or malignant, respectively. Some tumors show no obvious line of differentiation, and are therefore grouped under a category of tumors of unknown histogenesis such as Ewing's sarcoma and synovial sarcoma.

Treatment

The successful management of sarcoma in the head and neck region depends on the conjoint efforts of multiple disciplines such as radiation oncologists, medical oncologists, paediatricians, pathologists and surgeons. Staging of soft tissue sarcoma It is difficult to stage precisely the wide variety of sarcomas and the TNM staging system gives an idea of the severity of the disease.

- T1 Tumor 5 cm or less in the greatest dimension
 T1a superficial tumor
 T1b deep tumor
 T2 Tumor more than 5 cm in the greatest dimension
 T2a superficial tumor
 T2b deep tumor

(Tumors not affecting the superficial fascia are superficial all others are deep)

- N0 No regional lymph node metastasis
 N1 Regional lymph node metastasis
 M1 No distant metastasis
 M2 Distant metastasis

Histology grading is also included in stage grouping

- Grade 1 Well differentiated
 Grade 2 Moderately differentiated
 Grade 3 Poorly differentiated
 Grade 4 Poorly or undifferentiated

Stage grouping

	T	N	M	Histology grading
Stage I	T1,T2	N0	M0	Grade 1-2
Stage II	T1,T2a	N0	M0	Grade 2-3
Stage III	T2b	N0	M0	Grade 3-4
Stage IV	Any T	N1	M0	Any grade
	Any T	N0	M1	Any grade

The practical staging of the Memorial Sloan Kettering Cancer Center assign the tumor favorable and unfavorable features and then stage them according to the number of features.

Favorable factors: tumour size less than 5 cm, superficially located tumor, low grade. Unfavorable factors: size more than 5 cm, deeply situated tumor, high grade.

- Stage 0 3 favorable features
 Stage I 2 favorable features, 1 unfavorable feature
 Stage II 1 favorable feature, 2 unfavorable feature
 Stage III 3 unfavorable features
 Stage IV 3 unfavorable features, distant metastasis

Rhabdomyosarcoma

This tumor constitutes 45% of all sarcomas originating in the head and neck region. The orbit is the commonest site followed by paranasal sinuses, nasal cavity, nasopharynx and middle ear. Rhabdomyosarcoma histologically has 4 types, the embryonal, embryonal with botryoid variation, alveolar and pleomorphic. Prognosis depends firstly on histological typing with botryoid type being the best and secondly the location of the tumor, those in the orbit is most favorable and those in the parameningeal sites worst. The primary treatment is surgery followed by chemotherapy and radiotherapy. For extensive diseases, sometimes induction chemotherapy is employed. The overall cure rate is 55%.

Fibrosarcoma

Constitutes about 10% of all soft tissue sarcomas and 20% of them occur in the head and neck region. These tumours present, as painless and slow growing masses. They are radioresistant and the treatment is radical surgical excision followed by reconstruction.

Malignant fibrous histiocytoma

These are variants of fibrosarcoma, it is the commonest soft tissue sarcoma in adults, although only 1-3 % is located in the head and neck region. There is a male preponderance and is frequently seen around 50-70 yrs of age. About 30% of these tumors involve the sinonasal tract. The treatment of choice is surgical resection of the primary tumor and neck dissection is done for neck metastases. The overall 5-yr survival is 50%. Bad prognostic factors include old age, tumor size greater than 6 cm and extensive involvement.

Osteogenic sarcoma

The malignant spindle cells produce osteoid or primitive bone. Osteogenic sarcoma presents at 20-30 yrs of age, about a decade later than those in the long bones. They

present with a mass in the mandible or the maxilla and this is associated with pain and 50% of them are high-grade tumours. The treatment is surgical resection with adequate margin. Pulmonary metastases are present in 30% of patients.

Adjuvant chemotherapy or radiotherapy is not proven to be of value, although for large tumours, they are usually given postoperatively.

Leiomyosarcoma

Tumor arises from the smooth muscle and presents as a soft tissue mass in the fifth or sixth decade. It comprises only 6% of head and neck sarcomas. The commonest site is in the scalp, superficial tissue and the paranasal sinuses. It is usually well circumscribed and the potential of metastasis is low.

Surgical excision is the treatment of choice. Postoperative radiotherapy is useful for extremity leiomyosarcoma, it is often given even when the pathology is in the head and neck region.

Radiation induced sarcoma

This is an uncommon complication of radiotherapy. It is expected to increase over the years as patients survive longer nowadays following radiation. This sarcoma does not respond to further radiation or chemotherapy and thus surgery is the mainstay of management. The overall five year survival is around 60%. In the head and neck region the radiation sarcoma frequently occurs at the maxilla, mandible and in the neck.

Parapharyngeal Space Tumors

Surgical Anatomy

The parapharyngeal space is a potential space in the form of an inverted pyramid, with the base at the skull base and the tip at the hyoid bone. The medial wall is the pharyngobasilar fascia over the superior constrictor muscle. The lateral wall is formed by the ramus of the mandible while the posterior wall is the prevertebral muscle. The tensor veli palatini muscle and its fascia attaching to the styloid process divide this space into the prestyloid and poststyloid spaces.

Prestyloid space contains fat and the deep lobe of the parotid gland. Poststyloid space contains the carotid vessels, internal jugular vein, the IX to XII cranial nerves. The fascial compartments tend to limit the growth of the benign tumours in the region.

The masticator space is not part of the parapharyngeal space, lies in front of the prestyloid space, contains the internal maxillary artery, the Vth Nerve and the pterygoid muscles. The fascia covering the lateral pterygoid muscle separates the masticator space from the parapharyngeal space, this is attached medial to the foramen ovale, thus the Vth nerve neuroma are within the masticator space.

Pathology

The pathologic nature of parapharyngeal space lesion is reflected through its location. In the prestyloid space the commonest lesion is a tumor arising from the parotid gland, frequently the deep lobe.

In the poststyloid space, it could be a carotid body tumor or neurogenic tumor arising from cranial nerves or the sympathetic trunk. Metastatic tumor or sarcoma although rare, may also present as parapharyngeal space tumor

Diagnosis

Computed tomography (CT) or magnetic resonance imaging (MRI) is essential to define the exact location of the pathology and frequently the nature of the lesion can be determined. Fine needle aspiration (FNA) might be carried out when the mass is palpable in the neck. Otherwise a CT guided FNA can be done. This is important when the lesion is suspected to be malignant. When a vascular lesion is suspected, then an angiogram or magnetic resonance angiogram should be carried out. Excision of the mass should be planned as a definitive treatment while incision biopsy is done only when the lesion is determined to be not resectable. Transoral biopsy is not recommended as this goes through tissue plane and has the possibility of seeding the tumor.

Surgery

Surgical approach to the parapharyngeal space depends on the location and nature of the tumor.

Transcervical approach

This is for pathologies located in the poststyloid space. Through a skin crease neck incision, pathologies such as the neurilemmoma and paraganglioma can be exposed and removed. There is no need to remove any regional structures. Transcervical submandibular approach This is used for lesions in the prestyloid space. Through the incision, the facial artery at the region of the digastric muscle is divided and this allows the retraction of the submandibular gland anteriorly. The digastric tendon may be divided whenever necessary. Pathologies in the parapharyngeal space can be palpated and removed under direct vision with slight retraction of the mandible.

Transcervical transparotid approach

This is employed for the resection of deep lobe parotid gland tumor. A normal parotid gland incision is employed and after removing the superficial lobe of the parotid gland, the facial nerve is dissected. The deep lobe parotid gland pathology can be removed after retracting the submandibular gland and the mandible. The stylomandibular ligament may be divided to give additional exposure. Mandibulotomy is not advised, as this will lead to significant morbidity.

Extended approaches

Mandibulotomy will give additional exposure to the parapharyngeal space but it is associated with some morbidity. It is only employed for extensive vascular tumor. Occasionally for a highly situated recurrent prestyloid tumor, the maxilla might be swung laterally to get adequate exposure. For a paraganglioma extending into the jugular foramen, a mastoidectomy with re-routing of the facial nerve might be necessary for its complete removal.

Specific pathologies

Carotid paraganglioma (Carotid body tumor)

The carotid body represents the largest collection of paraganglionic tissue in the neck. Neoplastic transformation is pathologically named as carotid paraganglioma, chemodectoma or carotid body tumor. The carotid body is normally responsive to changes in arterial pH, oxygen and carbon dioxide tension. Carotid paraganglioma however rarely has vasoactive properties. It however may be associated with pheochromocytoma producing catecholamines, thus evaluation of urinary catecholamines should be done preoperatively.

Clinical features and diagnosis

In 90% of patients, they present with a pulsatile lateral neck mass situated at the level of angle of mandible where bifurcation of the common carotid artery occurs. Large lesions by its pressure on surrounding structures may produce symptoms such as dysphagia, hoarseness and pain. A bruit is apparent in about 50%.

High index of suspicion associated with physical examination frequently leads to the correct diagnosis. The angiographic features of a vascular mass situated between the bifurcation of the carotid artery causing splaying of the external and internal carotid arteries is pathognomonic. Computed tomography with contrast or magnetic resonance angiography contributes to determination of extent of the lesion.

Management

Carotid body tumor when left alone will grow slowly and the patient will be incapacitated by cranial nerve problems and associated pain. Radiotherapy may halt the growth of the tumor but the associated morbidity is not negligible. Surgical excision is the mainstay of treatment. Preoperative embolization contributes to reduce bleeding at the time of surgery and should be carried out within 48 hours prior to surgery.

The intracranial cross circulation is evaluated with bilateral carotid angiography before operation and intraoperative EEG monitoring. Patient lies supine with neck extended. Incision goes along an upper skin crease. The internal jugular vein is dissected off and every effort is used to preserve the vagus, accessory and hypoglossal nerves.

The common carotid, external and internal carotid arteries are identified and slinged for vascular control. The tumour is dissected off the arterial wall in the subadvential plane and haemostasis is carried out during the dissection. The external carotid artery can be divided whenever necessary and replacement of the internal carotid artery is carried out only very exceptionally.

Vagal paraganglioma

The fusiform lesion at the skull base displaces the carotid artery anteriorly. They are not vascular and surgical removal of the tumor with the nerve leads to vocal cord palsy and some degree of dysphagia. Patients with multiple paragangliomas should be screened for the PGL1 gene which is responsible for the familial paraganglioma.

Neurilemmoma (Schwannoma)

This tumor arises from the neuroectodermal sheath of a nerve. In the parapharyngeal space, it may arise from small sensory or motor nerve in the region or from the last four cranial nerves. It may also originate from the sympathetic trunk. It is not vascular and the nerve fibers might be draping on the tumor without passing through it. Thus occasionally the tumor can be dissected off the nerve and even though there is temporary postoperative paresis, some recovery of function is possible. When the sympathetic chain is removed, the patient will develop Horner's syndrome.

Reconstructive surgery

P.J. GULLANE

Department of Otolaryngology-Head and Neck Surgery,
University of Toronto, Ontario, Canada

Goals

The aim of reconstruction is not to simply fill a defect, but rather to restore physiological and social function. These can be separated into several specific objectives:

- ensure primary wound closure and healing
- Restoration of lip-seal and oral continence
- Maintenance of oral pharyngeal swallowing mechanisms
- Protection of the airway
- Maintain speech
- Protect important neurovascular structure
- Conserve appearance

Reconstructive principles

- Simplest reconstruction often the best
- Simplest reconstruction not always the best
- Careful planning
- Flap and vessel Selection
- Anticipate your complications
- Having anticipated them, avoid them
- Pay attention to detail

Problems and limitations in reconstruction

- Colour match
- Hostile wound/irradiated tissue
- Functional sensibility
- Cosmetic deformation
- Donor site defect
- Patient age/physiologic status

Where we have come from – Surgery

Phases of development in reconstruction

- Local and regional flaps ± bone grafts
- Microvascular surgery
- Reinnervation
- Improved esthetics with prosthesis

Reconstruction of the head and neck

- Improved cosmetics
- Improved function
 - Speech
 - Mastication
 - Swallowing
 - Sensation (Reinnervation)
- Improved quality of life

Future: tissue engineering and transplantation

How we have done it (1977-1989)

- Reconstruction of the lip, oral cavity and oropharynx
- Reconstruction of the larynx and hypopharynx
- Reconstruction of major soft tissue defects
- Reconstruction of the skull base
- Through and through defects
- The reconstructive "ladder"

Defects of the Oral Cavity

- Soft tissue alone
- Soft tissue and bone
- Through and through defects
- Total palatal reconstruction

Options for soft tissue oral reconstruction

- Primary closure – Skin grafts

- Local flaps
 - Tongue
 - Nasolabial
 - Submental
- Regional myocutaneous
- Free tissue transfer
 - Forearm
 - Anterolateral thigh
 - Lateral arm
 - Fibular skin

Ideal soft tissue reconstruction

	Flap thickness	Volume adjustment	Sensate
Forearm	++++	++++	++++
Anterolateral thigh	+++	++++	++
Lateral arm	++	++++	++
DIEP	+++	++++	+

Current options for mandibular reconstruction

- Radial forearm flap
- Scapular flap
- Fibula flap (may be reinverted) *
- Iliac crest flap

Current options for maxillary reconstruction

- Free forearm flap
- Free fibular transfer
- Free iliac crest transfer
- Free angular artery tip of scapular flap *

Evolution – Organ preservation strategies

- 1960's Laryngectomy/pharyngectomy
- 1970's Laryngectomy alone
Planned radiation with surgery for salvage
- 1980's Irradiation ± chemo 5FU, mitomycin C
- 1990's VA trial (neoadjuvant chemo/rad or laryngectomy)
- 2000's Adoption of organ preservation approaches

Surgical salvage following organ preservation strategies: a challenge

- Increasing trend over the past decade to adopt organ preservation strategies using either concomitant chemoradiation or accelerated or hyperfractionated radiotherapy.
- While these approaches have increased the likelihood of primary control in certain head and neck mucosal malignancies, when this approach fails and surgical salvage is required the sequelae of the primary treatment creates major challenges for patients and their surgeons

Current options in laryngopharyngeal reconstruction

Phases and development

Regional flaps

- Cutaneous
 - 1877 – Czemy
 - 1942 – Wookey
 - 1965 – Bakamjian
- Myocutaneous
 - 1979 – Ariyan

Viscus

- Gastric pull up
 - 1912 – Jianu
 - 1949 – Ong & Lee
 - 1998 – Wei et al.
- Colonic interposition
 - 1954 – Goligher

Free flaps

- Jejunal graft
 - 1956 – Seidenberg
- Tube radial forearm
 - 1979 – Yang
- Anterolateral thigh
 - 1984 – Song
- Gastro-omental
 - 1979 – Baudet

Reconstructive options following salvage laryngopharyngectomy

- Pectoralis major pedicled flap
- Radial forearm flap
- Free jejunal graft
- Anterolateral thigh flap *
- Gastro-omental flap *
- Gastric transposition

Option in pharyngeal reconstruction – 2008

Flap selection	Speech	Morbidity
Anterolateral thigh +stent	+++	0
Forearm + stent	+++	0
Free gastro-omental	+++	+
Free jejunum	+	+
Gastric pullup	0	++++
IMAP flap	Role to be evaluated	

Major soft tissue defects – Flap selection

- Local flaps
- Regional flaps
- Free tissue transfer
 - Radial forearm flap
 - Anterolateral thigh flap
 - Latissimus dorsi
 - Area/scalp
 - Atropy and advantage
 - Scapula
 - Colour match
 - Position
 - Rectus abdominis
 - Good hole filler
 - Muscle atropy

Current options in skull base reconstruction

- Closure without specific reconstruction
- Local flaps
- Pedicled flaps
- Free flaps

Priorities in tissue regeneration

- Repair of chemo/RT injuries
 - Cell therapy
 - Cell therapy + signal molecules
- Manipulation of wound healing
- Recreation of salivary gland function
 - Cell therapy + signal molecules + scaffolds
- Tissue engineering of mandible maxilla

Conclusions

We still have a lot of work to do

Challenges

- Skin colour match
- Sensory function of the oral cavity
- Movement of reconstructed structure
- Refinements in mandibular reconstruction
- Maxilla
- Role of tissue engineering
- Demonstrates that what we do improves QoL

Skin cancer

P.J. GULLANE

Department of Otolaryngology-Head and Neck Surgery,
University of Toronto, Ontario, Canada

Non melanoma

Non melanoma skin cancer (NMSC) is the most common malignancy in the world, and the head and neck is the most frequently involved site. Incidence rates for BCC and SCC range from 788/100,000 and 321/100,000, respectively, in Australia to SCC; compared to 146/100,000 and 100/100,000, respectively, in US. Risk factors include ultra-violet light exposure, male gender, fair Anglo-Celtic complexion, radiation exposure, and immunosuppression. There are several types of BCC, nodular and superficial being the most common. Other than the basosquamous variant, BCCs are generally low grade malignant tumours. However large or deeply infiltrative tumours may be challenging, particularly in the midface and periorbital region. Metastases are very rare and most of these unusual cases will show some degree of squamous differentiation. SCCs classically occur in elderly males on sun exposed sites especially in the head and neck region and arise from precursor lesions such as actinic keratosis, which has an estimated transformation rate of 5-20% over 10-25 years, compared to < 5% in Bowen's Disease or in situ SCC. Regional metastases occur in 5%, although size > 2 cm, depth > 4 mm, perineural invasion, location (ear and lip), incomplete excision, tumour recurrence, and immunosuppression increase the risk of regional disease^{1,2}. In addition, recent evidence suggests that 25% to 50% of patients with parotid node metastases from SCC will have concurrent cervical nodal disease^{3,4}. Overall mortality for cutaneous SCC is only 3.4% but increases substantially in patients with regional metastases⁵. In a multicentre study of patients with metastatic SCC to the parotid, overall survival was 72% at 5 years and over 25% of patients had concurrent neck disease⁶. The current AJCC staging system stages all patients with cutaneous SCC and nodal metastases to the parotid and neck as N1 regardless of the extent or volume of disease. A proposed revision of the old staging system has demonstrated prognostic value and is more clinically useful for patients with neck or parotid metastases⁶.

Imaging of the primary and regional sites is mandatory for advanced lesions and selected recurrent tumours. High resolution multi-slice computerized tomography (CT) scanning with intravenous contrast allows assessment of the tumour, adjacent soft tissue structures, bone invasion and cranial foramina. Magnetic resonance imaging (MRI) is the modality

of choice to assess neurotropic cancers and tumours with orbital, intracranial or parapharyngeal extension.

Wide surgical excision is the primary treatment approach for NMSC with recommended margins for SCC of 4mm for lesions under 2 cm and 6mm for greater than 2 cm; and BCC's should be excised with a minimum 3 mm margin. Moh's micrographic surgery or complete resection with comprehensive frozen section analysis of all margins can be utilized in difficult areas where wide excision is impractical⁷. Advanced NMSC (T3/T4) require en-bloc resection of tumour incorporating invaded structures (fat, muscle, bone, orbit). These patients should be assessed in a multidisciplinary clinic prior to surgery as many patients will require adjuvant post-operative radiotherapy. Furthermore, the option of definitive radiotherapy with or without concurrent chemotherapy should be considered in select patients where the morbidity of surgery is excessive. Management of sub-clinical nodal disease in advanced NMSC is controversial and there is little high-level evidence to guide surgeons. In many patients the choice as to whether a neck dissection is indicated will be predetermined by the method of reconstruction. There is no doubt that patients with clinical disease should undergo neck dissection, however most selective dissections are based upon evidence for mucosal SCC rather than cutaneous SCC.

At risk nodal groups for tumours of the anterior face/head include the parotid, external jugular nodes and levels I (including submental and peri-facial lymph nodes), II, III and IV. Tumours of the posterior scalp typically metastasise to retroauricular, external jugular, occipital nodes and levels II, III, IV and V. The external jugular node must be removed during lymphadenectomy⁸. Whilst location of the primary tumour predicts nodal fields at risk, recent evidence suggests a variance in clinically predicted drainage in one third of patients⁹. Patients with positive nodes in the parotid have approximately a 30% chance of having metastatic disease in the neck⁸. Elective parotidectomy in patients with cervical disease is not generally employed.

Indications for postoperative radiotherapy include close or positive margins, perineural invasion, two or more positive nodes, extra capsular spread and nodes greater than 3 cm in size, parotid nodal metastases and poorly differentiated tumours. BCCs with close or positive margins are best managed with repeat surgery where feasible. However for advanced tumours with inadequate margins post operative radiotherapy should be considered, particularly if there is calvarial or orbital involvement. Most patients with dural or brain invasion will require adjuvant therapy and there should be a low threshold for treating recurrent BCC's with postoperative radiotherapy. Regional therapy is not indicated in BCC unless there is documented nodal disease which is rare.

Melanoma

Melanoma incidence has undergone an exponential increase in the past 30 years. Australia and New Zealand have the highest rates (35-40/100,000), four times greater than that of the USA and Europe¹⁰ up to 20% of cutaneous melanoma arises in the head and neck¹¹ and approximately 20% of patients develop regional metastases. Risk factors include sun exposure, especially in early life, fair skin, family history, atypical nevi^{12,13}. The mortality for cutaneous

melanoma of the head and neck is high, with overall survival being 66% at 10 years. This falls to 34% for patients with proven nodal metastases and further decreases with an increasing number of positive nodes¹⁴.

Prognosis is mainly dependant on Breslow depth, ulceration, and lymph node status. A 1 cm excision margin for melanoma \leq 1mm, and 2 cm margin for larger tumours is acceptable¹⁵⁻¹⁷.

Elective lymph node dissection has not demonstrated a survival benefit. Sentinel Node Biopsy (SNB) is controversial. The only randomized control trial to date (MSLT 1) shows no overall survival benefit. However, subset analysis showed a 20% survival benefit for SNB positive patients undergoing immediate completion lymphadenectomy compared to neck observation¹⁸. All SNB positive patients should undergo therapeutic node dissection (TND). Patients presenting with palpable metastatic nodes should undergo a comprehensive neck dissection after confirmation with fine needle aspiration biopsy.

Indications for adjuvant irradiation include desmoplastic neurotropic melanomas, which have recurrence rates of up to 50%^{19,20}. Other indications for irradiation include microscopically involved or close surgical margins where further resection is impractical, perineural spread or tumour satellites²¹.

Dacarbazine, temozolamide and fotemustine are the most commonly used single agents for metastatic melanoma. They have a low toxicity profile and easily administered, however response rates are only 18-24% with complete response rates less than 5%²². Despite occasional dramatic responses with vaccines, they remain experimental since no survival benefit has been shown. Interferon alpha 2 B is FDA approved for the treatment of metastatic melanoma, a meta-analysis showed a significant improvement in disease free survival but not overall survival²³.

References

- Veness MJ. *Defining patients with high-risk cutaneous squamous cell carcinoma*. Austral J Dermatol 2006;47:28-33.
- Brian A, Moore BA, Weber RS, Prieto V, El-Naggar A, Holsinger AF, et al. *Lymph node metastases from cutaneous squamous cell carcinoma of the head and neck*. Laryngoscope 2005;115:1561-7.
- O'Brien CJ. *The parotid gland as a metastatic basin for cutaneous cancer*. Arch Otolaryngol Head Neck Surg 2006;131:551.
- O'Brien CJ, McNeil E, McMahon J, Pathak I, Lauer C. *Incidence of cervical node involvement in metastatic cutaneous malignancy involving the parotid gland*. Head Neck 2001;23:744-8.
- Joseph MG, Zulueta WP, Kennedy PJ. *Squamous cell carcinoma of the skin of the trunk and limbs: the incidence of metastases and their outcome*. ANZJS 1992;62:697-701.
- Andruchow JL, Veness MJ, Morgan GJ, Gao K, Clifford A, Shannon KF, et al. *Implications for clinical staging of metastatic cutaneous squamous carcinoma of the head and neck based on a multicentre study of treatment outcomes*. Cancer 2006;106:1078-83.
- Smeets NW, Kuijpers DI, Nelemans P, Ostertag JU, Verhaegh ME, Krekels GA, et al. *Mohs' micrographic surgery for treatment of basal cell carcinoma of the face--results of a retrospective study and review of the literature*. BR J Dermatol 2004;151:141-7.
- O'Brien CJ, McNeil EB, McMahon JD, Pathak I, Lauer CS. *Incidence of cervical node involvement in metastatic cutaneous malignancy involving the parotid gland*. Head Neck 2001;23:744-8.
- de Wilt JH, Thompson JF, Uren RF, Ka VS, Scolyer RA, McCarthy WH, et al. *Correlation between preoperative lymphoscintigraphy and metastatic nodal disease sites in 362 patients with cutaneous melanomas of the head and neck*. Ann Surg 2004;239:544-52.
- Martin RCW, Robinson E. *Cutaneous melanoma in Caucasian New Zealanders: 1995-1999*. ANZ J Surg 2004;74:233-7.
- Myers JN. *Value of neck dissection in the treatment of patients with intermediate-thickness cutaneous malignant melanoma of the head and neck*. Arch Otolaryngol Head Neck Surg 1999;125:110-5.
- Armstrong BK, Kricger A. *The epidemiology of UV induced skin cancer*. J Photochem Photobiol B 2001;63:8-18.
- Thompson JF, Morton DL, Kroon BBR. *Textbook of melanoma*. Martin Dunitz.
- O'Brien CJ, Coates AS, Petersen-Schaefer K, Shannon K, Thompson JF, Milton GW, et al. *Experience with 998 cutaneous melanomas of the head and neck*. Cancer 1993;71:751-8.
- Veronesi U, Cascinelli N, Adamus J, Balch C, Bandiera D, Barchuk A, et al. *Thin stage I primary cutaneous malignant melanoma: comparison of excision with margins of 1 or 3 cm*. N Engl J Med 1988;318:1159-62.
- Balch CM, Soong SJ, Smith T, Ross MI, Urist MM, Karakousis CP, et al. *Long-term results of a prospective trial comparing 2 cm vs. 4 cm excision margins for 740 patients with 1-4 mm melanomas*. Ann Surg Oncol 2001;8:101-8.
- Thomas JM, Newton-Bishop J, A'Hern R, Coombes G, Timmons M, Evans J, et al. *Excision margins in high-risk malignant melanoma*. N Engl J Med 2004;350:757-66.
- Morton DL, Thompson JF, Cochran AJ, Mozzillo N, Elashoff R, Essner R, et al. *Sentinel-node biopsy or nodal observation in melanoma*. N Engl J Med 2006;355:1307-18.
- Quinn MJ, Crotty KA, Thompson JF, Coates AS, O'Brien CJ, McCarthy WH. *Desmoplastic and desmoplastic neurotropic melanoma*. Cancer 1998;83:1128-35.
- Gallardo D, Juillard G. *Efficacy of radiation therapy in the local control of desmoplastic melanoma*. Proceedings of the 36th Annual ASTRO meeting, 1999.
- Stevens G, Thompson J, Firth I, O'Brien CJ, McCarthy W, Quinn M. *Locally advanced melanoma*. Cancer 2000;88:88-94.
- Eggermont AM, Kirkwood JM. *Reevaluating the role of dacarbazine in metastatic melanoma: what have we learned in 30 years?* Eur J Cancer 2004;40:1825-36.
- Wheatley K, Ives N, Hancock B, Gore M, Eggermont A, Suci S. *Does adjuvant interferon-alfa for high-risk melanoma provide a worthwhile benefit? A meta-analysis of the randomised trials*. Cancer Treat Rev 2003;29:241-52.