

CASE REPORT

Hibernoma of the para-glottic space: an unusual tumour of the larynx

Hibernoma dello spazio paraglottico: un tumore raro della laringe

A. MINNI, M. BARBARO, D. VITOLO¹, R. FILIPONeurology and Otolaryngology Department; ¹ Pathology Department, University of Rome "La Sapienza", Rome, Italy

SUMMARY

Hibernoma is an unusual tumour of brown adipose tissue. Brown adipose tissue is common in mammalian hibernating animals and acts as a thermogenic organ. A first case of hibernoma was reported in 1906 by Merkel. This tumour usually arises in the back, shoulder region, mediastinum, retroperitoneum and in the neck. The neck location of hibernomas is rare and only 18 cases of cervical hibernoma have been reported in the English literature. A 48-year-old male with hoarseness and soft voice, present for 8 months, showed a lesion involving the anterior part of the right vocal fold, with no impaired mobility. This is the first case to be reported of laryngeal hibernoma located in a vocal fold, originating from the white fat tissue of the paraglottic space. Moreover, this report could be evidence of the development of hibernoma from white adipose tissue.

KEY WORDS: Larynx • Benign tumour • Soft tissue tumour • Hibernoma

RIASSUNTO

L'ibernoma è un raro tumore che origina dal tessuto grasso bruno. Il grasso bruno è comunemente presente nei mammiferi ed espleta la funzione di organo termogenico. Il primo caso di hibernoma è stato riportato nel 1906 da Merkel³. Di solito questo tumore si riscontra a livello della schiena, delle spalle, nel mediastino, nel retroperitoneo e nel collo. La localizzazione cervicale è rara ed ad oggi riportata solo in 18 casi. Riportiamo il caso di un uomo di 48 anni con disfonia da 8 mesi, all'esame obiettivo si evidenziava una lesione laringea a carico della porzione anteriore della corda vocale vera di destra senza alterazioni della mobilità. Questo è il primo caso riportato di hibernoma della corda vocale ad origine dal grasso bianco dello spazio paraglottico. Proprio questa localizzazione particolare potrebbe aiutare a capire meglio la patogenesi dell'ibernoma.

PAROLE CHIAVE: Laringe • Tumori benigni • Tumori dei tessuti molli • Hibernoma

Acta Otorhinolaryngol Ital 2008;28:141-143

Introduction

Hibernomas are rare, benign, subcutaneous neoplasms originating from immature brown fat. Brown adipose tissue is common in mammalian hibernating animals and acts as a thermogenic organ; in human, it is present at foetal status and decreases with development. Remnants of brown fat may persist in the inter-scapular region, mediastinum, axillae, retroperitoneum and neck.

The neck location of hibernomas is rare, and has been reported as a cervical mass. To date, in the English literature (PUBMED), 18 cases of cervical hibernoma have been reported, and only one of these has been observed in the pre-epiglottic area of the larynx. In this regard, it is worthwhile noting that brown adipose tissue has never been recorded, in this anatomic site before. The present report refers to the first case located in the glottic area, at paraglottic space level.

Case report

A 48-year-old male with an unremarkable medical history was admitted at the ENT Department with an 8 months' his-

tory of hoarseness and soft voice, without dysphagia and dyspnoea. Clinical examinations, including 70° laryngeal endoscopy and computed tomography (CT) scan (Fig. 1), showed a lesion involving the anterior part of the right vocal fold, with no impaired mobility. There was no evidence of masses in the neck.

A direct microlaryngoscopy was performed under general anaesthesia, and a 2 cm nodular and soft tumour, located in the submucosa of the subglottic and glottic region, was completely removed; the vocal ligament was carefully respected. The patient was discharged the same day without complications.

The gross pathology of the tumour was characterized by a homogeneously coloured yellow-brown neoplasm with well-defined borders. The specimen borders were free of disease. The histopathological examination revealed a submucosal tumour consisting of neoplastic cells with large eosinophilic cytoplasm, regular nucleus with small nucleoli (Fig. 2). These neoplastic cells were immunoreactive for S-100 (Fig. 2B) protein and vimentin, and were negative for cytokeratin and actin. A diagnosis of laryngeal hibernoma was made.

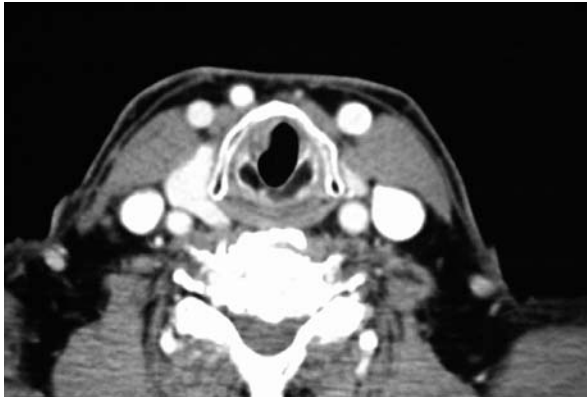


Fig. 1. CT scan shows tumour involving right vocal fold.

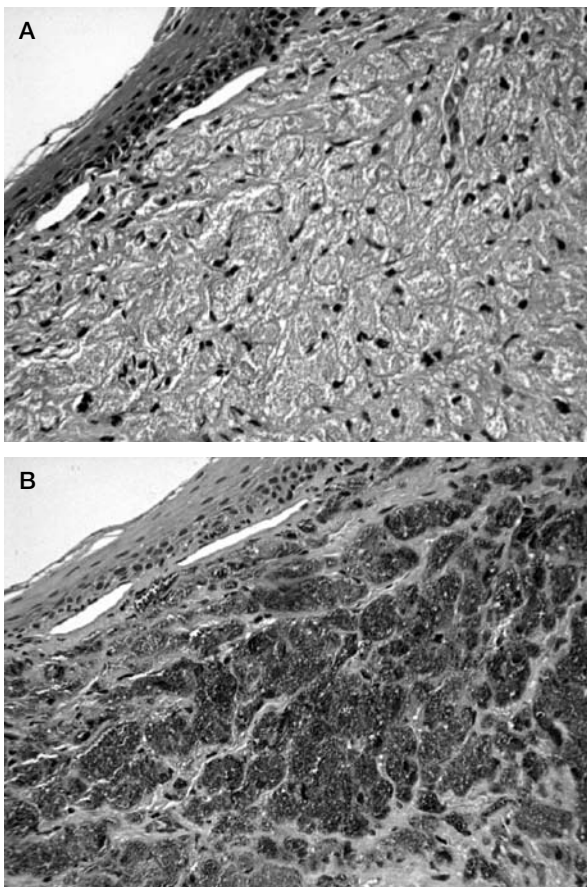


Fig. 2. Tumour consists of diffuse proliferation of large cell characterized by coarsely multi-vacuolated cytoplasm. Neither atypia nor mitotic activity was detected. B: positive test for S100 (A: H&E x 250HPF).

One year after surgery, the patient showed no recurrence, voice was good and stroboscopy showed normal vibration.

Discussion

In 1906, Merkel¹ described the first brown fat tumour as a pseudolipoma of the breast, the term hibernoma was coined in 1914² due to a morphologic resemblance to the brown fat of hibernating mammals. Velsch², in 1670, described, first, a gland structure that he associated with the thymus; Barkow², only in 1846, called it “hibernating gland” and classified it apart from the thymus.

Brown tissue is brown-tan in colour and vascular, the cells are polygonal, multivacuolated, with granular cytoplasm and ovoid nucleus. Brown fat tissue is an important source of non-shivering thermogenesis; accordingly, this fat tissue is rich in blood supply and mitochondria that may increase in size and number. This tissue is present in several mammalian animals, it may also be present in non-hibernating animals, such as mice, rats, monkeys and humans.

In humans, the brown fat tissue observed is mostly in embryos and neonates, where it lies between vessels at the base of the neck or in the inter-scapular region, thigh, arm, axilla, retroperitoneum, mediastinum and perineum. After birth, it decreases, but small islands may persist in the white adipose tissue. Some Authors have suggested that brown tissue represents the early stage of the development of the white fat tissue, whilst others have suggested that brown and white adipose tissue are different types¹⁻³.

Usually, hibernoma is a benign, subcutaneous, freely movable, non tender mass, ovoid in shape. It may produce symptoms by pressure and displacement. Hibernoma is a well-capsulated neoplasm with intense microvasculature. Microscopically, all tumours are composed partly or principally of coarsely multivacuolated fat cells with small, central nuclei and no atypia. Four morphologic variants of hibernoma have been identified: typical, myxoid, spindle cell, and lipoma-like. “Typical” hibernoma, the most common (82.4%), includes eosinophilic cell, pale cell, and mixed cell types based on the tinctorial quality of the hibernoma cells. The myxoid variant (8.2%) contains a loose basophilic matrix. Spindle cell hibernoma (2.4%) presents features of spindle cell lipoma and hibernoma; all occurring in the neck or scalp. The lipoma-like variant (7%) contains only scattered hibernoma cells. Immunohistochemically, 85% of the tumours are positive for S-100 protein⁴⁻⁸. A malignant hibernoma may exist, Enterline et al. described a so-called malignant hibernoma with areas

Table I. Location of head and neck hibernomas.

Author(s)/Year (ref.)	Location
Lacomme/1973 ¹⁰	Neck
Lawson & Biller/1976 ¹²	Supraclavicular fossa
Simon/1950 ²⁰	Neck
Cox/1954 ⁶	Neck, mediastinum
Vetner/1966 ²¹	Carotid sheath
Mesera & Batsakis/1967 ²²	Retromandibular
Kristensen/1985 ¹¹	Supraclavicular fossa
Abemayor et al./1987 ²	Supraclavicular fossa
Worsey et al./1994 ²³	Neck
Hall et al./1988 ¹⁹	Suprahyoid region
Sellari Franceschini et al./1993 ¹⁶	Larynx (pre-epiglottic space)
Monerris Garcia et al./2003 ¹⁵	Neck
Florio et al./2000 ²⁴	Neck
Carinci et al./2001 ²⁵	Neck
Vinayak & Reddy/1993 ¹³	Parotid region
Minic/1992 ¹⁴	Submental space
Attar & Muzzafar/2006 ²⁶	Submandibular region
Minni 2007	Larynx (paraglottic space)

resembling a typical hibernoma and areas like a well-differentiated liposarcoma⁹.

Hibernomas occur, in adults, during the fourth decade of life, more rarely in childhood (youngest at 6 weeks old), no difference between sex has been observed. Tumour size ranges from 1 to 26 cm. Surgery is the standard treatment, and no cases of recurrence have been reported^{10,11}.

So far, to our knowledge, only 18 cases have been reported in the neck (Table I), one of which in the larynx, in the pre-epiglottic area. All presented as a cervical mass and surgical treatment was performed¹²⁻¹⁵.

Two theories have been proposed in order to explain the origin of hibernoma. According to one of these, the tumour

grows starting from some islands of brown adipose tissue that may persist in the white fat tissue; on the contrary, tumoural brown fat cells may develop from white adipose tissue¹⁻⁵.

Brown adipose tissue has never been detected in the larynx; nevertheless white fat tissue is present in the pre-epiglottic and paraglottic space. Therefore, it may be possible to find hibernoma in both these laryngeal subsites¹⁶⁻¹⁸. Bearing in mind this hypothesis, the hibernoma, hereby, reported, located in a vocal fold, may have developed from the white fat tissue of the paraglottic space¹⁹, moreover, as a consequence, this case could be evidence of the development of hibernoma from white fat tissue.

References

- Merkel H. *Über ein Pseudolipon der Mamma*. Beitr Path Anat Allge Path 1906;39:152-7.
- Abemayor E, McLeod PH, Cobb CJ, Hashimoto CH. *Hibernomas of the head and neck*. Head Neck Surg 1987;9:362-7.
- Hatai S. *On the presence in human embryos of an interscapular gland corresponding to the so-called hibernating gland of lower mammals*. Anat Anz 1902;21:369-73.
- Seemayer TA, Kannck J, Wang N, Ahmed MN. *On the ultrastructure of hibernoma*. Cancer 1975;36:1785-93.
- Dardick I. *Hibernoma: a possible model of brown tissue fat histogenesis*. Hum Pathol 1978;9:321-9.
- Cox RW. *Hibernoma: the lipoma of immature adipose tissue*. J Pathol Bact 1954;68:511-24.
- Hashimoto C, Cobb C. *Cytopathology of hibernoma*. Diagn Cytopathol 1987;3:326-9.
- Furlong MA, Fanburg-Smith JC, Miettinen M. *The morphologic spectrum of hibernoma: a clinicopathologic study of 170 cases*. Am J Surg Pathol 2001;25:809-14.
- Enterline HT, Lowry LD, Richman AV. *Does malignant hibernoma exist?* Am J Surg Pathol 1979;3:265-71.
- Lacomme Y. *Hibernome cervical*. Rev Laryngol Otol Rhinol 1973;94:66-70.
- Kristensen S. *Cervical hibernoma. Review of the literature and a new case*. J Laryngol Otol 1985;99:1055-8.
- Lawson W, Biller HF. *Cervical hibernoma*. Laryngoscope 1976;86:1258-67.
- Vinayak BC, Reddy KT. *Hibernoma in the parotid region*. J Laryngol Otol 1993;107:257-8.
- Minic AJ. *Hibernoma: unusual location in the submental space*. J Craniomaxillofac 1992;20:264-5.
- Moneris Garcia E, Ronda Perez JM, Ortega Pastor E, Sancho Mestre M, Talavera Sanchez J. *Hibernoma: a rare case of cervical mass*. Acta Otorrinolaringol Esp 2003;54:143-6.
- Sellari Franceschini S, Segnini G, Berrettini S, Bruschini P, Cagno MC, Testi C. *Hibernoma of the larynx. Review of the literature and a new case*. Acta Otorhinolaryngol Belg 1993;47:51-3.
- Reidenbach MM. *The paraglottic space and transglottic cancer: anatomical considerations*. Clin Anat 1996;9:244-51.
- Heaton JM. *The distribution of brown adipose tissue in human*. J Anat 1972;112:35-9.
- Hall RE, Koonig J, Hartmann L, Del Balso A. *Hibernoma: an unusual tumor of adipose tissue*. Oral Surg Oral Med Oral Pathol 1988;66:706-10.
- Simon HE. *Posterior cervical tumor of brown fat in man; its relationship to the interscapular gland of hibernating animals*. Am J Surg 1950;80:127-30.
- Vetner MO. *Fetal fat cell lipoma (hibernoma)*. Nord Med 1966;76:1338-40.
- Mesera BW, Batsakis J. *Hibernomas of the neck*. Arch Otolaryngol 1967;85:199-210.
- Worsey J, McGuirt W, Carrau RL, Peitzman AB. *Hibernoma of the neck: a rare cause of neck mass*. Am J Otolaryngol 1994;15:152-4.
- Florio G, Cicia S, Del Papa M, Carni D. *Neck hibernoma: case report and literature review*. G Chir 2000;21:339-41.
- Carinci F, Carls FP, Pelucchi S, Grandi E, Hassanipour A, Pastore A. *Hibernoma of the neck*. J Craniofac Surg 2001;12:284-6.
- Attar ZB, Muzzafar S. *An unusual case of benign hibernoma in the pediatric age group*. J Coll Physicians Surg Pak 2006;16:237-8.

Received: March 26, 2007 - Accepted: September 15, 2007