

## CASE REPORT

# Pleomorphic adenoma of the lateral nasal wall: case report

## *Adenoma pleomorfo della parete nasale laterale: caso clinico*

D. SCIANDRA, F. DISPENZA, R. PORCASI<sup>1</sup>, G. KULAMARVA<sup>2</sup>, C. SARANITI

Otorhinolaryngology Department; <sup>1</sup> Human Pathology Department, University of Palermo, Palermo, Italy; <sup>2</sup> ENT Clinic, Nayak's Road, Kasaragod, India

## SUMMARY

Pleomorphic adenoma is the most common tumour of the salivary glands. However, it is extremely rare for these to originate in the nose and even when they do so, it is most commonly in the nasal septum. It is important to be aware of the paucity of presenting symptoms (nasal obstruction and epistaxis), as the lesion may not be recognized immediately. Growth is generally restricted locally and the tumour is not known to spread to the neighbouring structures. Surgical resection is the treatment of choice. Recurrences and evolution to malignancy are not frequent, but long-term follow-up is recommended. The case is presented of pleomorphic adenoma arising from the lateral wall of the right nasal cavity, in a 34-year-old male, which was resected completely, endoscopically. Histological and immunohistochemical evaluation revealed the presence of a pleomorphic adenoma.

KEY WORDS: Nose • Nasal tumour • Pleomorphic adenoma • Diagnosis • Histopathology

## RIASSUNTO

*L'adenoma pleomorfo è il tumore benigno più comune delle ghiandole salivari. Comunque, la sua localizzazione nasale è molto rara e più comunemente origina dal setto. Importante è considerare che i sintomi di presentazione sono molto scarsi (ostruzione nasale e epistassi), per cui la lesione può decorrere a lungo misconosciuta. La crescita è generalmente locale e non sono noti casi di diffusione nelle strutture adiacenti. La resezione chirurgica è il trattamento di scelta. La recidiva e l'evoluzione maligna non sono frequenti, ma un lungo follow-up è da raccomandare. Presentiamo un caso di adenoma pleomorfo ad origine dalla parete laterale della fossa nasale di destra in un paziente di 34 anni, trattato chirurgicamente con resezione endoscopica completa. La valutazione istologica ed immunoistochimica hanno dimostrato la presenza di un adenoma pleomorfo.*

PAROLE CHIAVE: Naso • Tumori nasali • Adenoma pleomorfo • Diagnosi • Anatomia patologica

Acta Otorhinolaryngol Ital 2008;28:150-153

## Introduction

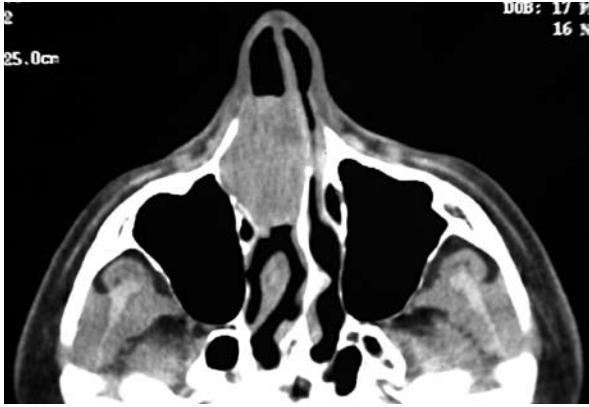
Mixed tumour of the salivary gland or the pleomorphic adenoma is a benign tumour, arising mainly in the major salivary glands (65%), especially in the parotid and, less frequently, in accessory salivary glands (35%)<sup>1</sup>. Rare cases have been reported in the lip<sup>2</sup>, the hard and soft palate<sup>3</sup>, the lacrimal gland<sup>4</sup>, and the external auditory canal<sup>5</sup>. It is extremely rare to find these in the respiratory tract<sup>6-8</sup>. The incidence is even lower in the upper respiratory tract, such as the nasal cavity, maxillary sinus and nasopharynx<sup>8,9</sup>. The largest reported case series of intra-nasal pleomorphic adenomas are those of Spiros et al.<sup>10</sup> with 40 cases, Compagno and Wong<sup>11</sup> with 40 cases and, more recently, Suzuki et al.<sup>4</sup> with 41 cases.

Intranasal pleomorphic adenomas generally arise in the nasal septal mucosa (reported incidence varies between 82.5%<sup>11</sup> and 90%<sup>12</sup>), even though the seromucosal glands are mainly located within the lateral nasal wall, in particular in the turbinates<sup>13,14</sup>.

Various theories have been proposed to explain this observation. According to Stevenson<sup>15</sup>, remnants of the vomeronasal organ, an epithelium-lined duct in the cartilaginous nasal septum degenerated in early foetus, could be the reason for the appearance of these tumours in this particular region. According to Ersner and Saltzman, in 1944, the precursors of the septal pleomorphic adenoma are ectopic embryonic epithelialised cells on the nasal septum mucosa, found during the migration of the nasal buds<sup>16</sup>. According to Evans and Cruikshank, it originates directly from the matured salivary glandular tissue<sup>6</sup>; Dawe, in 1979, proposed a viral aetiology from polyoma virus<sup>17</sup>.

## Case report

A 34-year-old male, non-smoker, presented at our Department, in January 2003, reporting an isolated episode of epistaxis from the right nasal cavity. He also complained of worsening of a right nasal obstruction which had been present

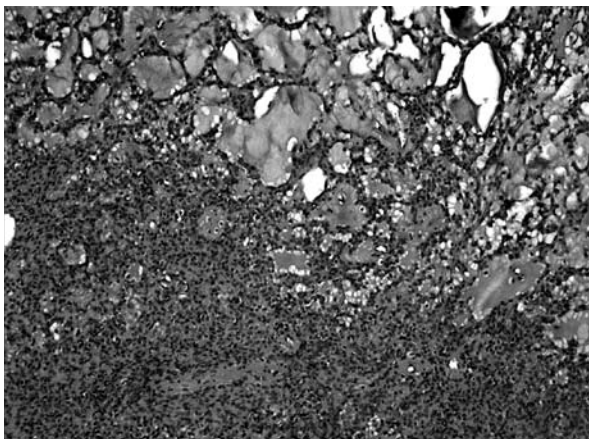


**Fig. 1.** Axial CT scan showing soft density mass in anterior portion of right nasal fossa with thinness of nasal process of maxillary bone.

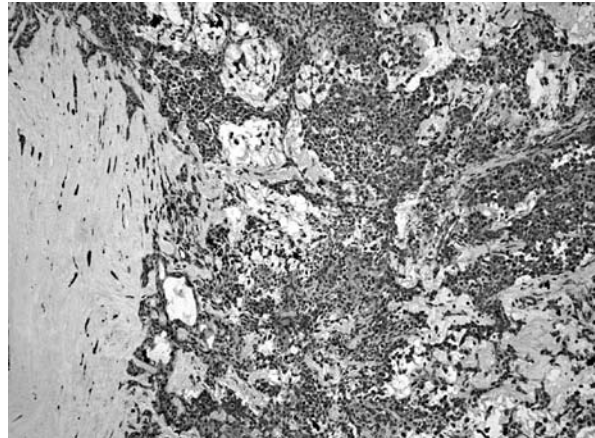
for 10 years, frontal cephalgia and anosmia. External clinical examination showed a mass arising from the lateral wall of the right nasal cavity and filling the naso-facial furrow.

Anterior rhinoscopy revealed a smooth, pink-grey, translucent, painless mass, obstructing the nasal cavity, not bleeding on touch, and a deviated nasal septum to the left. The rest of the ear, nose, and throat examination was normal and there was no evidence of cervical lymphadenopathy. Computed Tomography (CT) scan revealed a soft tissue mass in the right nasal cavity, not involving the paranasal sinuses, with thinning of the nasal process of the maxilla (Fig. 1). Endoscopic surgery, under general anaesthesia, confirmed the mass (2 cm in diameter) to be arising from the lateral wall of the right nasal cavity and extending from the anterior end of the inferior turbinate to the *agger nasi*. We excised the tumour completely, including the sub-periosteal layer and a healthy margin of mucosa.

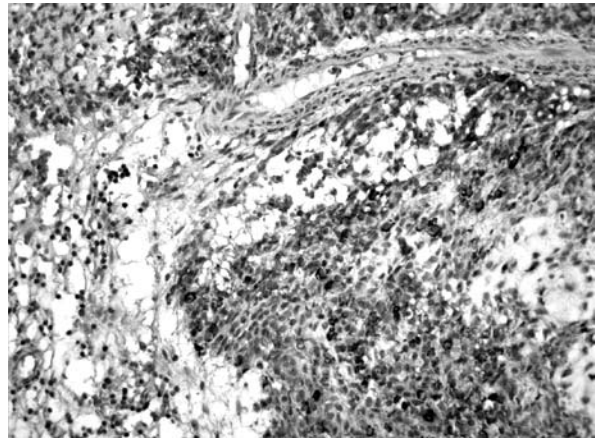
Histopathological analysis of the tumour showed a mixed epithelial and myxoid stromal appearance. Epithelial structures displayed different solid, trabecular and cystic growth patterns (Fig. 2). Immuno-histochemical stainings for smooth muscle actin (Fig. 3) and S100 (Fig. 4) highlighted the presence of an abundant myoepithelial component. The histo-morphological and immunophenotypical features observed were consistent with the diagnosis of pleomorphic adenoma. There is no endoscopic evidence of recurrence after 4 years' follow-up.



**Fig. 2.** Epithelial structures showing solid, trabecular and cystic patterns intermingled with myxoid stroma (H&E, x250).



**Fig. 3.** Immunostaining for smooth muscle actin (x 250).



**Fig. 4.** Immunostaining for S100 protein (x 400).

## Discussion

Nasal pleomorphic adenoma is seen predominantly in females<sup>4-11</sup> usually between the third and fifth decades of life<sup>18</sup>. There is no reported correlation with occupational exposure or inhaled toxic chemical compounds. It is generally known to be a slow-growing tumour and, therefore, clinical symptoms appear after a long silent period. Patients commonly present with gradual worsening of monolateral nasal obstruction and occasional epistaxis. Less commonly, when the tumoural mass reaches a relatively large size, to that of the nasal cavity, external swelling of the nasal pyramid as well as pain may be present.

Clinically, it appears as a polypoid, unilateral, sessile, translucent, pinkish-grey mass, with smooth surface and soft consistency. Tumours can range in size from < 0.7 cm to > 7 cm.

The clinical features, such as absence of superficial ulceration, no bleeding either on touch or spontaneously and lack of invasion of surrounding structures suggest a benign nature of the mass.

Histologically, all pleomorphic adenomas have a collagenous thin capsule, with a clear-cut distinction of the tumour tissue from the surrounding normal connective tissue. The tumours consist of three main structures: tubuloductal structure, solid area, and myxoid area. The tubuloductal structure presents ducts with double cell layers: cuboi-

dal-shaped epithelial cells at the inner layer, and spindle-shaped myoepithelial cells at the outer. Predominantly the solid areas consist of the spindle-shaped cells with high cellularity; the myxoid areas are characterised by their low cellularity<sup>18</sup>.

The intra-nasal pleomorphic adenoma shows a predominance of epithelial rather than stromal elements, as compared with major salivary gland tumours. The epithelial cells are small, oval-shaped and often arranged in cords; sometimes, they are organized in small acinous structures<sup>13</sup>.

Immunohistochemical stains prove positive for various cytokeratins, S100 protein, glial fibrillary acid protein (GFAP), Vimentine, a smooth muscle actine (SMA). This describes the "mixed" nature of the tumour, namely, the stromal and the epithelial line<sup>19</sup>.

Differential diagnosis of intra-nasal pleomorphic adenoma includes both malignant and benign tumours such as squamous cell carcinoma (the most common intra-nasal malignancy), adenocarcinoma, adenoid cystic carcinoma, mucoepidermoid carcinoma, melanoma, olfactory esthesioneuroblastoma<sup>20</sup>, polyps, papillomas (including inverted papilloma), angiofibromas and osteomas.

Differential diagnosis can also be difficult in the presence of a "neuroesthesioepithelioma" (even though the site of origin of such a lesion, i.e., the ethmoid plate, should suggest its nature, since the lateral nasal wall is extremely rare), as, in the early stage, it presents a small cell proliferation organized like a "rosette", positive for S100 protein. Diagnosis is possible on account of the lack of an extracellular neurofibrillar structure, neurotubules, neurosecretive granules and due to the presence of mucinous material and the rarity of malpighian lobules disseminated on the pleomorphic adenoma<sup>21</sup>.

Regardless of where the lesion originates, the main treatment modality should be surgical. While complete excision of the tumour with histologically clear margins is mandatory, the surgical approach will depend upon the size, location and extension. A radical and wide resection lowers the risk of recurrence, especially when the capsule is interrupted and a direct contact with the surrounding normal tissue is present. Approaches include lateral rhinotomy<sup>22-24</sup>, trans-nasal or mid-facial degloving<sup>13-18</sup> and intra-nasal excision. The present patient underwent endoscopic resection since the tumour was small enough to observe under the endoscope. The advantages of endoscopic resection include no

external scar, less blood loss. In the presence of large masses, the mid-facial degloving approach is preferred, since it has the advantage of wide exposure of the mass and direct approach to the nasal cavity.

Recurrences are not frequent, Compagno and Wong reported 3 cases of local recurrences in 40 patients (7.5%)<sup>11</sup>, probably, as they thought, due to the amount of myxoid stroma of the tumour, which could be split into the surgical field.

The potential risk of malignant transformation of the pleomorphic adenoma is about 6% and is predominantly seen in the female patients<sup>25</sup>. The risk is increased by delay in diagnosis.

A histopathologically confirmed case with adenoid cystic and squamous carcinomatous differentiation has been reported<sup>26</sup>.

There has also been a report of metastasis to the submandibular lymph-node, in a recurrent septal pleomorphic adenoma, 17 years after the first diagnosis. Even in this case, the microscopic features of both the primary and metastatic lesion were benign. In this regard, a iatrogenic theory has been proposed. This theory suggests that the metastasis occurs as a result of incomplete excision or inadvertent disruption of the tumour with consequent spread through haematogenous or lymphatic routes. Pulmonary, hepatic and bone metastasis have also been reported<sup>27</sup>.

Long term follow-up is therefore necessary for early diagnosis of loco-regional recurrences by endoscopic examination followed by imaging (CT or MR) in case of clinical evidence of disease.

## Conclusions

In the presence of a slow-growing unilateral mass of the nasal cavity, it is important to consider, among the various diagnoses, the presence of pleomorphic adenoma, even if it is not frequently encountered. Early diagnosis offers the possibility of a more complete excision with adequate care being taken not to disrupt the tumour in order to prevent local and distant spread of neoplastic cells. The endoscopic approach is preferred, as it allows complete control of the margins under direct vision and reduces the post-operative recovery period when compared to open surgery. Long-term follow-up, both endoscopic and radiologic, to exclude malignancy is mandatory, even if the tumour appears to be clinically benign and resected completely.

## References

- Chomette G, Auriol M. *Histopathologie buccale et cervico-faciale*. Paris: Masson; 1986. p. 210-2.
- Trotoux L, Lefebvre B. *Pathologie des glandes salivaires*. Enc Med Chir Orl. Paris: Masson; 1979.
- Campos A, Bagan JV, Zapater E, Martorell M, Basterra J. *Adenoma pleomorfo de glandula salivar accessoria*. Acta Otorrinolaringol Esp 1995;46:331-4.
- Suzuki K, Moribe K, Baba S. *A rare case of pleomorphic adenoma of lateral wall of nasal cavity, with special reference of statistical observation of pleomorphic adenoma of nasal cavity in Japan*. Nippon Jibiinkoka Gakkai Kaiho 1990;93:740-5.
- Lahoz MT, Valerio J, Royo J, Yus C, Camora F. *Tumor mixto de conducto auditivo externo*. Acta Otorrinolaringol Esp 1990;41,1:53-6.
- Evans RW, Cruikshank AH. *Epithelial tumors of the salivary glands*. In: *Major problems in Pathology*. Vol. 1, Philadelphia: WB Saunders; 1970. p. 281-95.
- Frailé Rodrigo JJ, Martínez Berganza Y, Asensio R, Yus Gotor C, García Ortín M, García Ortín J. *Adenoma pleomorfo de tabique nasal*. Revision. Acta Otorrinolaringol Esp 1993;44:239-41.
- Wallace RD. *Pleomorphic adenoma of the nose*. *Clinical and pathologic diagnosis*. Arch Otolaryngol Head Neck Surg 1990;116:486-8.
- Kamal SA. *Pleomorphic adenoma of the nose*. *A clinical case and historical review*. J Laryng Otol 1984;98:917-23.

- <sup>10</sup> Spiro RH, Koss LG, Hadju SL. *Tumors of minor salivary origin. A clinicopathologic study of 492 cases.* Cancer 1973;31:117-29.
- <sup>11</sup> Compagno J, Wong RT. *Intranasal mixed tumors (pleomorphic adenomas): a clinicopathologic study of 40 cases.* Am J Clin Pathol 1977;68:213-8.
- <sup>12</sup> Nonomura N, Nijima H, Kimura O, Karoshi F, Nakano Y, Kimura K. *Immunohistochemical study of pleomorphic adenoma of the nasal septum.* Auris Nasus Larynx 1992;19:125-31.
- <sup>13</sup> Castello E, Caligo G, Pallestrini EA. *Su un caso di adenoma pleomorfo della fossa nasale.* Acta Otorhinolaryngol Ital 1996;16:433-7.
- <sup>14</sup> Carriero E, Almadori G, Cadoni G. *Adenoma pleomorfo del turbinato inferiore: caso clinico e revisione della letteratura.* Acta Otorhinolaryngol Ital 1997;17:377-81.
- <sup>15</sup> Stevenson HN. *Mixed Tumor of the septum.* Ann Otol Rhinol Laryngol 1932;41:563-70.
- <sup>16</sup> Ersner MJ, Saltzman M. *A mixed tumor of the nasal septum. Report of a case.* Laryngoscope 1944;54:287-96.
- <sup>17</sup> Dawe CJ. *Tumors of salivary and lacrimal glands, nasal fossa and maxillary sinus.* IASC Sci J 1979;23:91-113.
- <sup>18</sup> Freeman SB, Kennedy KS, Parker GS, Tatum SA. *Metastasizing pleomorphic adenoma of the nasal septum.* Arch Otolaryngol Head Neck Surg 1990;116:1331-3.
- <sup>19</sup> Hirai S, Matsumoto T, Suda K. *Pleomorphic adenoma in nasal cavity: immunohistochemical study of three cases.* Auris Nasus Larynx 2002;29:291-5.
- <sup>20</sup> Batsakis J. *Tumor of the head and neck.* Baltimore: Williams and Wilkins Publishers; 1984. p. 76-99.
- <sup>21</sup> Couloigner V, Julien N, Molas J, Sterkers O. *Adenome pleomorphe de la cloison nasale. A propos d'un cas.* Ann Otolaryngol Chir Cervicofac 1993;110:230-3.
- <sup>22</sup> Bergstrom B, Biorlund A. *Pleomorphic adenoma of the nasal septum. Report of two cases.* J Laryngol Otol 1981;95:179-81.
- <sup>23</sup> Haberman RS, Stanley DE. *Pleomorphic adenoma of the nasal septum.* Otolaryngol Head Neck Surg 1989;100:610-2.
- <sup>24</sup> Majed MA. *Pleomorphic adenoma of the nasal septum.* J Laryngol Otol 1971;85:975-6.
- <sup>25</sup> Shaheen OH. *Benign salivary glands tumors.* Scott Brown's Otolaryngol 1997;5:1-18.
- <sup>26</sup> Freeman SR, Sloan P, De Carpentier J. *Carcinoma ex-pleomorphic adenoma of the nasal septum with adenoid cystic and squamous carcinomatous differentiation.* Rhinology 2003;41:118-21.
- <sup>27</sup> Wermuth MJ, Mann CH, Odere F. *Metastasizing pleomorphic adenoma arising in the soft palate.* Otolaryngol Head Neck Surg 1988;99:505-8.

Received: May 31, 2007 - Accepted: August 20, 2007