

## RHINOLOGY

# Videoendoscopic adenoidectomy with microdebrider

## *Adenoidectomia endoscopica con microdebrider*

F. COSTANTINI, F. SALAMANCA, T. AMAINA, F. ZIBORDI  
Otorhinolaryngology Unit, "S. Pio X" Clinic, Milan, Italy

## SUMMARY

After evaluating approaches proposed, over the last few years, by several Authors, to make the procedure of adenoidectomy safer and more accurate, we have developed a new procedure based on the combined use of a rigid 70° endoscope with a video attachment and a microdebrider, both introduced through the oral cavity. This procedure offers several advantages: an improved field of vision, continuous suction of blood, and extreme precision in removing the adenoid tissue. Compared with current practices which employ the adenotome or curette, it is possible with our approach to remove adenoid tissue in the most important centres: the choanal and tubaric regions. The validity and safety of this videoendoscopic adenoidectomy with microdebrider has been demonstrated in 201 patients.

KEY WORDS: Adenoidectomy • Endoscopic adenoidectomy • Microdebrider

## RIASSUNTO

*Dopo avere valutato i diversi metodi proposti da vari Autori negli ultimi anni per migliorare l'accuratezza e la sicurezza dell'intervento di adenoidectomia, abbiamo messo a punto una nuova tecnica basata sull'impiego combinato di un'ottica rigida a 70° con collegamento video, e del microdebrider, entrambi introdotti attraverso la bocca. Questa procedura presenta parecchi vantaggi: una visione ottimale del campo operatorio, l'aspirazione continua del sangue e la possibilità di asportare con estrema precisione il tessuto adenoidico. Rispetto alle tecniche correnti, che prevedono l'impiego dell'adenotomo o della curette, il nostro sistema permette di liberare con sicurezza i punti più importanti: la regione sovraoanale e quella peritubarica. La validità e la sicurezza di questa tecnica è stata verificata in 201 pazienti operati negli ultimi 2 anni.*

PAROLE CHIAVE: Adenoidectomia • Adenoidectomia endoscopica • Microdebrider

Acta Otorhinolaryngol Ital 2008;28:26-29

## Introduction

Whether performed alone or in association with tonsillectomy, adenoidectomy is one of the most common surgical operations in paediatric otolaryngological practice.

Various diagnostic means have been employed to explore the nasopharynx and evaluate the volume and position of the adenoid tissue, but, in the majority of cases, surgery

itself has been conducted blindly. After the surgical intervention, surgeons often check the nasopharynx by means of digital palpation or, occasionally, with a laryngeal mirror. The latter method also enables residual tissue to be removed with a curette.

Since 1992, a number of Authors have described visualization of the operating field, during surgery, with a laryngeal mirror, trans-nasal or trans-oral endoscope. These Authors

**Table I.** Surgical technique of adenoidectomy according to various Authors.

|                          | Laryngeal mirror   | Transnasal endoscope              | Transoral endoscope |
|--------------------------|--|-----------------------------------|---------------------|
| Curette                  | Current use  |                                   |                     |
| Forceps for residuals    |  | Cannon et al.                     |                     |
| Suction-cautery          | Owens et al.   | Shin et al.                       | Durr<br>Lo          |
| Transnasal microdebrider |  | Yanagisawa et al.<br>Havas et al. |                     |
| Transoral microdebrider  | Rodriguez et al.<br>Heras et al.<br>Koltai et al.<br>Murray et al. |                                   | Costantini et al.   |

employed curette, suction-coagulator, forceps and trans-nasal or trans-oral microdebrider as surgical tools for the removal of the adenoids (Table I)<sup>1-15</sup>.

For many years, we performed adenoidectomy with the La Force adenotome. Although the long-term results of this procedure were reasonably satisfactory, we began, approximately two years ago, to check the operating field visually with a 70° endoscope after performing surgery. In most cases, residual tissue was found close to the choanas and adjoining the *torus tubarius*. This finding could explain the partial relief of obstructive symptoms obtained in some cases. Such lymphatic piles were very difficult to remove with the La Force adenotome or the curette, even under endoscopic vision.

Given the effectiveness of the microdebrider in removing such tissue, adenoidectomy has been performed in our Centre under endoscopic vision using a microdebrider since January 2004.

Aim of the present report is to describe the level of success of this surgical technique.

## Materials and methods

Between January 2004 and March 2006, 201 patients have been treated with the technique described. Of these patients, 196 were children (mean age 50 months, range 30 months-13 years) and 5 were adults (age range 19 to 31 years, mean 24). Adenoidectomy was performed in association with tonsillectomy in 67% of the cases.

Based on the scale developed by Clemens et al.<sup>5</sup>, distribution of the degree of obstruction was: 8% grade 1 (always in association with tonsillectomy), 33% grade 2, 45% grade 3 and 14% grade 4.

All patients were controlled 7 days after treatment. Adult patients and some of the older children were also checked endoscopically with a nasal fiberscope 3 or 4 weeks after treatment.

Surgery is performed under general anaesthesia with oro-tracheal intubation. The patient is placed in a supine position with his/her neck slightly extended and the surgeon places him/herself in front of and to the right of the patient. A McIvor-type mouth gag, the same as that used for tonsillectomy, is positioned, and two soft catheters are introduced through the nasal passages to apply light upward traction to the soft palate, thereby increasing the forward-back diameter of the hollow. The slight stretching of the palate achieved with this manoeuvre also aids in the recognition of a possible soft palate cleft.

A 70° endoscope with a video attachment is introduced through the mouth to visualize the nasopharyngeal cavity. A microdebrider with a 40° curved blade, the cutting window of which is on the convex side, is also introduced through the mouth. The instrument is connected to an aspirator and is programmed to alternate rotations, with a rotational speed of 1200 rpm (Fig. 1).

Removal of the adenoid tissue starts from the choanal vegetations and proceeds backwards along the vault towards the posterior wall of the nasopharynx.

Generally, the adenoid vegetations appear as a series of parallel cords of tissue with a longitudinal course, more voluminous along the median line and thinner toward the perimeter. The most lateral cord is generally in close contact

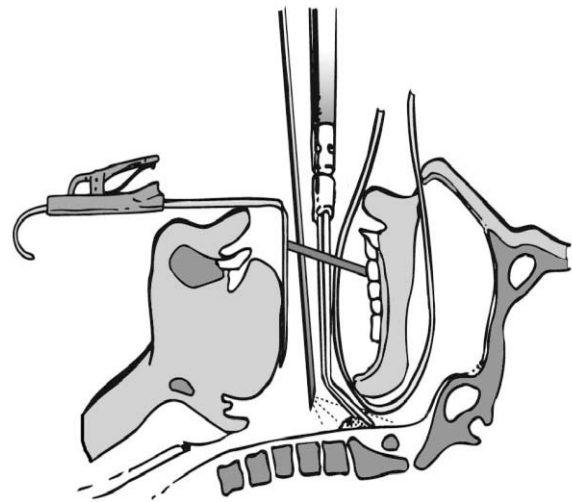


Fig. 1. Schematic representation of position of mouth-gag, catheters, endoscope and microdebrider.

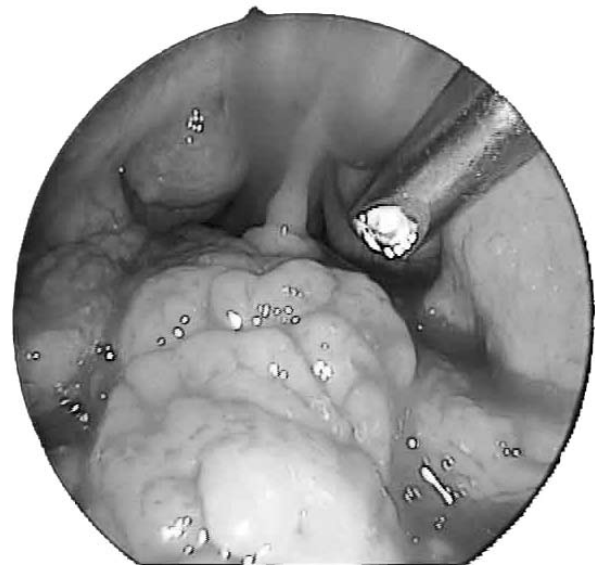

Fig. 2. View of nasopharynx through the 70° endoscope.

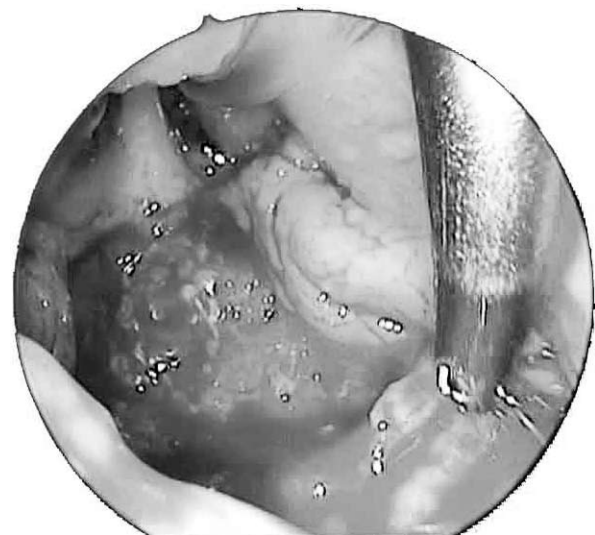

Fig. 3. View of nasopharynx at the end of surgery.

with the *torus* of the *tuba* (Fig. 2). The smooth point of the microdebrider can be introduced into the furrow between the side vegetations and the structures of the tubaric ostium and the tissue can be completely removed without damaging the mucosa covering the *torus tubarius*.

The organization of the tissue becomes less regular and the colour turns progressively darker as one proceeds along the posterior nasopharyngeal wall, at the level of the projection of the floor of the choanal openings. We interrupt resection along this line demarcated by the passage from the regular adenoid vegetations to the more chaotic aspect of the lymphatic tissue in this zone (the Passavant ridge). From a functional point of view, removal can be considered complete at this point. The procedure also prevents transitory velo-pharyngeal insufficiency. It also avoids excessive bleeding that can occur following lesions of the larger vessels present in the lymphatic tissue.

At the end of the resection, a package is placed in the cavity where it is maintained for some minutes. The package is then removed and the cavity is checked for the presence of possible residual tissue and for the absence of bleeding (Fig. 3). In the rare cases of persistent bleeding, it is possible to obtain haemostasis using a curved suction-coagulator, under endoscopic control.

When tonsillectomy is also scheduled, we prefer to perform the adenoidectomy first, but in the case of large tonsillar masses, tonsillectomy may be performed first in order to achieve better vision.

## Results

After > 2 years of systematic use of this technique, no drawbacks have been found, in terms of complications or poor post-operative course. Only one case of slight post-operative bleeding (4 days after surgery) was experienced by a small 5-year-old patient. As a cautionary measure, the child was hospitalized but did not require any treatment as bleeding stopped spontaneously.

The mean operating time, calculated from the surgical records of the last 20 patients treated by adenoidectomy alone, was 12.5 minutes. Hospitalization never exceeded 24 hours.

Blood loss (aspired blood plus differential weight of the packages employed) was measured in the first 10 patients who underwent simple adenoidectomy. The mean blood loss was 28 ml.

No significant difference was found between adult patients and children of various ages.

## Discussion

Although practiced less frequently today than in the past, adenoidectomy is still the appropriate treatment in certain specific applications, especially in children. Given the greater diagnostic effectiveness of the currently available instruments, we felt the need to improve this surgical procedure that has remained unchanged, in many cases, for

30-40 years. Although valid, the traditional methods did not always yield optimum results. Both Cannon et al.<sup>1</sup> and Havas et al.<sup>10</sup> have drawn attention to the high percentage of residual tissue remaining after traditional adenoidectomy with an adenotome or a curette, especially in the choanal and tubaric regions.

A surgical procedure performed blindly with the help, at best, of only palpation is no longer satisfactory. Good vision of the operating field is essential, and, in our opinion, optimal vision of the entire nasopharynx and back choanal edges, with excellent illumination and focus, is obtained with a 70° endoscope with video attachment introduced through the oral cavity. Compared to the image obtained by means of a laryngeal mirror, the quality of the image is unquestionably better.

In some cases, introduction of the catheters for suspending the soft palate can be rather difficult (especially in the presence of a serious choanal obstruction), but they do offer considerable advantages when used.

The safety and precision of the trans-oral curved microdebrider for adenoidectomy is well documented by the many case histories (overall, approximately 1800 patients) described by Rodriguez et al.<sup>11</sup>, Koltai et al.<sup>13</sup>, and Murray et al.<sup>14</sup>. Our experience supports their observations. It seems, in our view, that, with this method, it is possible to remove the lateral (tubaric) adenoidal tissue with a precision that is impossible to achieve with any other instrument, thereby minimizing the risk of collaterally damaging the tubaric structures. If *partial adenoidectomy* is appropriate, it is also possible to perform very selective removal of the adenoid tissue. Moreover, the continuous suction generated by the microdebrider maintains the field free from blood.

Although the technique described may appear more difficult than those traditionally used, it is, in fact, very easy to learn, particularly for the specialist who is familiar with endoscopic nasal surgery. Moreover, it is quite easy to teach using video images; videos may also provide easily accessible documentation to be stored in the archives.

The duration of the procedure is slightly longer than that of adenoidectomy with the adenotome. The organization and preparation times are also longer, while ablation and haemostasis times are substantially the same. However, the slightly longer duration is more than compensated by the greater precision and confidence gained by the surgeon.

## Conclusions

The 2 years of routine use of adenoidectomy with a microdebrider and a 70° endoscope, both introduced through the mouth, have demonstrated that the technique is characterized by a high level of precision and a very low incidence of post-operative bleeding. The precision offered by the improved visual field of the endoscope combined with the extreme manageability of the microdebrider allows the surgeon to control the efficient removal of the adenoid tissue, to the great advantage of the patient.

## References

- <sup>1</sup> Cannon CR, Replogle WH, Schenk MP. *Endoscopic-assisted adenoidectomy*. Otolaryngol Head Neck Surg 1999;121:740-4.
- <sup>2</sup> Becker SP, Roberts N, Coglianese D. *Endoscopic adenoidectomy for relief of serous otitis media*. Laryngoscope 1992;102:1379-84.
- <sup>3</sup> Owens D, Jaramillo M, Saunders M. *Suction diathermy adenoid ablation*. J Laryngol Otol 2005;119:34-5.
- <sup>4</sup> Wynn R, Rosenfeld RM. *Outcomes in suction coagulator adenoidectomy*. Arch Otolaryngol Head Neck Surg 2003;129:182-5.
- <sup>5</sup> Clemens J, McMurray JS, Willging JP. *Electrocautery versus curette adenoidectomy: comparison of postoperative results*. Int J Pediatr Otolaryngol 1998;43:115-22.
- <sup>6</sup> Shin JJ, Hartnick CJ. *Pediatric endoscopic transnasal adenoid ablation*. Ann Otol Rhinol Laryngol 2003;112:511-4.
- <sup>7</sup> Durr DG. *Endoscopic electrosurgical adenoidectomy: technique and outcomes*. J Otolaryngol 2004;33:82-7.
- <sup>8</sup> Lo S, Rowe-Jones J. *How we do it: Transoral suction diathermy adenoid ablation under direct vision using a 45 degree endoscope*. Clin Otolaryngol 2006;31:436-55.
- <sup>9</sup> Yanagisawa E, Weaver EM. *Endoscopic adenoidectomy with the microdebrider*. Ear Nose Throat J 1997;76:72-4.
- <sup>10</sup> Havas T, Lowinger D. *Obstructive adenoid tissue: an indication for powered-shaver adenoidectomy*. Arch Otolaryngol Head Neck Surg 2002;128:789-91.
- <sup>11</sup> Rodriguez K, Murray N, Guarisco JL. *Power-assisted partial adenoidectomy*. Laryngoscope 2002;112:26-8.
- <sup>12</sup> Heras HA, Koltai PJ. *Safety of powered instrumentation for adenoidectomy*. Int J Pediatr Otolaryngol 1988;44:149-53.
- <sup>13</sup> Koltai PJ, Chan J, Younes A. *Power-assisted adenoidectomy: total and partial resection*. Laryngoscope 2002;112:29-31.
- <sup>14</sup> Murray N, Fitzpatrick P, Guarisco JL. *Powered partial adenoidectomy*. Arch Otolaryngol Head Neck Surg 2002;128:792-6.
- <sup>15</sup> Stanislaw P, Koltay PJ, Feustel PJ. *Comparison of power-assisted adenoidectomy vs. adenoid curette adenoidectomy*. Arch Otolaryngol Head Neck Surg 2000;126:845-9.

Received: June 8, 2006 - Accepted: October 10, 2007