

ROUND TABLE S.I.O. NATIONAL CONGRESS

Surgical rehabilitation of dysphagia after partial laryngectomy

La riabilitazione chirurgica della disfagia negli esiti di laringectomia parziale

A. RICCI MACCARINI, M. STACCHINI, D. SALSI¹, D. PADOVANI¹, F. PIERI, D. CASOLINO¹Department of Surgical Specialities, Otorhinolaryngology Unit, "Bufalini" Hospital, Cesena; ¹ Department of Surgical Specialities, Otorhinolaryngology Unit, "S. Maria delle Croci" Hospital, Ravenna, Italy

SUMMARY

Surgical rehabilitation of dysphagia in patients who have undergone partial laryngectomy is aimed at improving the sphincteric action of the larynx, the anatomy and physiology of which are impaired. The interventions indicated for this purpose can be performed either with an external or endoscopic approach. The Authors present early results of their experience employing injection laryngoplasty with autologous fat, bovine collagen (Zyplast[®], McGhan Medical Corporation, Fremont, CA, USA) and PDMS (Vox Implants[®], Uroplasty Inc, Minnetonka, MN, USA), performed by means of fiberoendoscopy, under local anaesthesia, and microlaryngoscopy, under general anaesthesia.

KEY WORDS: Swallowing disorders • Dysphagia • Partial laryngectomy • Surgical rehabilitation of dysphagia • Injection laryngoplasty • Fat injection • Collagen injection

RIASSUNTO

La riabilitazione chirurgica della disfagia nei pazienti operati di laringectomia parziale ha lo scopo di migliorare l'azione sfinterica della laringe, la cui anatomia e fisiologia sono state sovverite. Gli interventi che trovano indicazione per questo scopo possono essere effettuati per via esterna o per via endoscopica. Gli Autori presentano i risultati preliminari della loro esperienza riguardante interventi di laringoplastica iniettiva con grasso autologo, collagene bovino (Zyplast[®], McGhan Medical Corporation, Fremont, CA, USA) e PDMS (Vox Implants[®], Uroplasty Inc, Minnetonka, MN, USA) effettuati in fibroendoscopia in anestesia locale e in microlaringoscopia in anestesia generale.

PAROLE CHIAVE: Disturbi della deglutizione • Disfagia • Laringectomia parziale • Riabilitazione chirurgica della disfagia • Laringoplastica iniettiva • Iniezione di grasso • Iniezione di collagene

Acta Otorhinolaryngol Ital 2007;27:294-298

Introduction

Surgical rehabilitation of dysphagia, after partial laryngectomy, is aimed at improving the sphincteric action of the larynx, the anatomy and physiology of which is completely deranged due to oncologic surgery. After surgical treatment of supraglottic horizontal laryngectomy, swallowing usually recovers spontaneously and completely, while after surgical treatment such as reconstructive laryngectomies with cricothyroidoepiglottopexy, cricothyroidopexy, tracheohyoidoepiglottopexy or tracheohyoidopexy "microinhalations" are unavoidable which decrease with time and particularly with logopaedic rehabilitation. But if, after several weeks, "macroinhalations" are present, which can cause bronchopneumonia *ab ingestis*, then surgical rehabilitation is indicated, in order to avoid gastric tube (percutaneous endoscopic gastrostomy - PEG) or total laryngectomy.

The most frequent anatomic situations which must be treated are:

- an excessively posterior position of the cricoid ring in pexy with hyoid bone;

- a reduced backwards pushing of the tongue base;
- stiffness, reduced motility or improper movements of the arythenoid/s, due to injury of the recurrent laryngeal nerve or to a block of the crico-arythenoid articulation;
- an excessively anterior position of the residual epiglottis;
- a small amount of mucosa covering the cricoid and/or the arythenoid/s cartilage;
- reduced pharyngeal sensitivity, due to injury of the superior laryngeal nerve;
- scarring stenosis of the pyriform sinuses or excess mucosa in the neolarynx which interfere with the bolus progression;
- in outcomes of supraglottic horizontal laryngectomy, surgical rehabilitation is rarely necessary, however, it can be advisable in the event of:
 - a. hypotrophic vocal folds,
 - b. reduced motility or paralysis of one or both vocal folds due to recurrent laryngeal nerve paralysis or crico-arythenoid articulation block,
 - c. intervention enlarged to the tongue base.

These situations can cause bolus inhalation, which is mostly intra-deglutitive, on account of an alteration in the pharynx-

geal phase of swallowing¹, but, sometimes, pre-deglutitive aspiration occurs, caused by an alteration in the oral phase or post-deglutitive aspiration, mostly due to an alteration in the oesophageal phase. The latter is due to spasm of the crico-pharyngeal sphincter, which prevents the entering of bolus into the oesophagus, with consequent stagnation in the pyriform sinuses. This stagnation leads to a post-deglutitive inhalation of bolus if the glottic sphincter is not working well. The problem of the crico-pharyngeal sphincter spasm is not easy to solve, as gastric-oesophageal-pharyngeal reflux is often present in these patients; relaxation of the crico-pharyngeal muscle could be achieved by means of myotomy² or a botulinum toxin injection into the crico-pharyngeal muscle³, but the consequence is lack of protection of the lower airways from acid or alkaline reflux, as the neoglottis is not a valid protective sphincter. Myotomy or infiltration of the crico-pharyngeal muscle with botulinum toxin should be performed only in those patients for whom the presence of gastro-oesophageal reflux has been totally excluded.

Surgical approaches for the treatment of dysphagia can be performed through an external or endoscopic approach.

External surgery techniques:

- revision of the cricothyroidopexy with a more anterior positioning of the cricoid, in order that the tongue base is pushed back to protect the airways;
- fixing of the residual epiglottis in a backwards position;
- fixing of the still arythenoid in an anterior and medial position;
- creation of mucosa flaps covering the cricoid.

Endoscopic approaches:

1) removal of the lesions which interfere with bolus progression, proposed by Piemonte⁴:

- opening of the pyriform sinus with lysis of retractions or scarring adhesions of the ary-epiglottic wall to the lateral wall of the hypopharynx;
- removal of floating muscle-mucosa strips to restore correct travelling of the pharyngeal muscular wave;
- reduction of arythenoid oedema or removal of supra-arythenoideal mucosa;

2) techniques for reducing the glottic or neoglottic insufficiency, which causes food inhalation. These refer to injection laryngoplasty procedures⁵⁻⁹, which can be performed:

- by means of microlaryngoscopy under general anaesthesia, with injection of reabsorbable or non-reabsorbable material;
- by means of fiberendoscopy under local anaesthesia, with injection of reabsorbable or non-reabsorbable materials.

The *reabsorbable materials* mainly used are: autologous fat, bovine collagen. The latter is preferred to fat, in most cases, as a fine needle can be used which is fundamental when the laryngeal mucosa is thin and adheres to the cartilage; otherwise hyaluronic acid can be employed. The most used *non-reabsorbable material* is polydimethylsiloxan (PDMS, Vox Implants®) which is preferred to reabsorbable materials on account of its stability in time¹⁰, but it must be used no sooner than 2 years after oncological treatment. This material is injected preferably through microlaryngoscopy, under general anaesthesia, since it may fall into the lower airways and, if so, in this way removal is easier. The *injection points* are:

- arythenoid/s, in order to create a “valve” effect and a contact with the tongue base or with the residual epiglottis;

- superior face of the cricoid ring, in order to recreate the medial wall of the pyriform sinus;
- tongue base, in order to reduce the “slide” effect that occurs when the tongue base is in an exceptionally anterior position.

Following supraglottic horizontal laryngectomy, the injection points are the middle third of the vocal fold in cases of atrophic vocal folds and the posterior third of the vocal fold in cases of unilateral laryngeal paralysis⁹; in cases of bilateral paralysis of the vocal folds injection laryngoplasty is not recommended, while the recommended surgical procedures are those improving breathing without having a negative effect upon swallowing.

The choice of the most appropriate injection to perform is taken after a careful evaluation of the recorded fiberendoscopic examination during phonation and swallowing; in patients submitted to tracheostomy, laryngeal fiberendoscopy is performed also “from the bottom” through the tracheostomy, with a detailed display of the site and the amount of the eventual intra-deglutitive inhalation of food.

Surgical procedure of injection laryngoplasty

Surgical approach through microlaryngoscopy is performed under general anaesthesia with oro-tracheal intubation. For fat injection, we use a 1 mm calibre needle (Fig. 1). This allows integrity of adipocytes to be preserved, an essential means to avoid massive fat reabsorption.

Fat can be removed by means of lipo-aspiration from the sub-cutis of the peri-umbilical region, using a 10 cc disposable autostatic syringe, connected via luer-lock to a 14 Gauge needle for thoracentesis. Prior to this step, a vasoconstrictor solution is injected into the peri-umbilical region (to reduce blood in the fat sample and to prevent bruise). With “come and go” movements two syringes of 10 cc are filled. Then the needle is removed from the syringe and substituted by a luer-lock plug; the syringe is centrifuged at 3000 turns per minute, for 3 minutes, as described by Coleman¹¹. This procedure separates fat from blood; then blood is eliminated and the concentrated fat is placed in a 5 cc luer-lock syringe with a three-way joint. Contact of the fat with air, during the transfer from one syringe to another, must be avoided, in order not to cause oxidation of the fat. The 5 cc syringe can be directly linked to the endoscopic needle or inserted into a high pressure injection pistol (Fig. 2), offering better control of the injection procedure.

It is always necessary to inject a double quantity of fat in order to correct glottic or neoglottic insufficiency, as




Fig. 1. Endoscopic needles by Storz® (Karl Storz GmbH & Co. KG, Tuttlingen, Germany) for fat injection (below) and injection of collagen, hyaluronic acid, fluids (above)⁹.

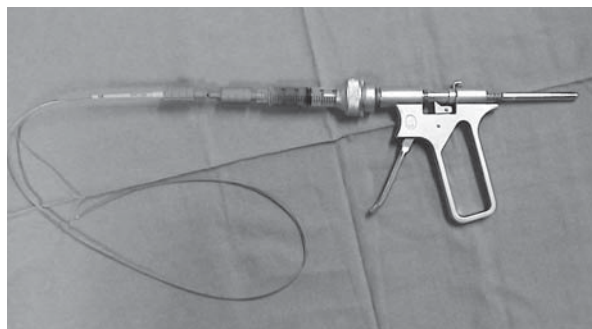


Fig. 2. High pressure injection pistol by BTC, with a 5 cc luer-lock syringe containing fat inside, linked to a 19 Gauge BTC endoscopic flexible needle¹².

part of the injected fat (from 30% to 70%) is reabsorbed. For injection of collagen and hyaluronic acid, a thinner needle can be used (Fig. 1), which is linked to the high pressure syringe, in which the material is placed using a three-way circuit.

It is very important to make a slow and gradual injection, as the material must fill only the chosen point of injection, without lacerating the mucosa with consequent extrusion of the material into the airways.

Surgical approach through fiberendoscopy is performed under local anaesthesia with vaporization of 10% lidocaine into the nose and the pharynx and with instillation of 4% and 10% lidocaine into the larynx. The local anaesthetic is also added to the solution used for subcutaneous infiltration into the site of fat withdrawal. Light sedation with 2-3 mg of Midazolam can be performed intravenously. This technique, called “fiberendoscopic phonosurgery” (FEPS), has been proposed by the CELF group of Santander¹³ and developed in Italy^{6-8,12} with the setting up of specific instrumentation. We use a fiberoptic endoscope with a 2 mm working channel, where endoscopic instruments such as needles, forceps and scissors are inserted. Fiberoptic endoscopes are now substituted by high definition flexible digital endoscopes, with a distal chip camera, which offers high quality images, as in microlaryngoscopy; in these endoscopes, the optic fibers bring only the light to illuminate the visual field. For fat injection, we use a 19 Gauge endoscopic needle 80 cm in length, within a plastic catheter which prevents damage to the endoscope^{6-8,12,14}. For collagen or hyaluronic acid injection, a 23 Gauge needle, 80 cm in length, is used. The endoscopic needle is linked to the high pressure syringe (Fig. 2) manoeuvred by the second operator.

The advantages of the fiberendoscopic, compared to the microlaryngoscopic, procedure are:

- “functional” display of the operative field, with the possibility to check the effect of laryngoplasty on swallowing and phonation;
- chance to perform the intervention even when tracheostomy has already been closed.

On the other hand, disadvantages are:

- need of collaboration on the part of the patient as swallowing must not be effected during the injection;
- a less precise injection, as the needle cannot remain inserted for a long time, since slight movements of the patient, the needle or the endoscope can enlarge the breach or lacerate the mucosa, with consequent leakage of material into the airways.

Patients and methods

In the last 2 years, 7 patients with severe dysphagia, due to partial laryngectomy, have undergone surgical rehabilitation:

- 4 patients with cricothyroidopexy with maintenance of 1 arythenoid;
- 2 patients with cricothyroidopexy with maintenance of 2 arythenoids;
- 1 patient with cricothyroidopexy with maintenance of 1 arythenoid.

All patients were males, aged between 43 and 78 years.

The surgical technique performed was:

- injection laryngoplasty with bovine collagen (Zyplast®, McGhan Medical Corporation, Fremont, CA, USA) through fiberendoscopy under local anaesthesia in 4 cases;
- injection laryngoplasty with autologous fat through fiberendoscopy under local anaesthesia in one case;
- injection laryngoplasty with PDMS (Vox Implants®, Uroplasty Inc, Minnetonka, MN, USA) through microlaryngoscopy in 2 cases.

Clinical evaluation of dysphagia was based on the anamnesis regarding the swallowing problem (Table I) and on endoscopic and radiological dynamic study of swallowing (Table II), which were performed the day before intervention and then one week, one month, 6 months and one year after intervention. In the patients with tracheostomy, fiberendoscopy during swallowing and phonation was performed by the trans-nasal and trans-tracheostomic approach. The most suitable injection points, the material to be used and the surgical procedure to apply were chosen after careful re-examination of the laryngeal endoscopy and of the radiological dynamic study.

Table I. Anamnestic evaluation of dysphagia^{3,10}.

Dysphagia score	
Score	Symptoms
1	Normal deglutition
2	Occasional cough during saliva deglutition, not related to food introduction
3	Occasional cough during food introduction
4	Frequent cough during food introduction
5	Frequent cough not related to food introduction
6	<i>Ab-ingestis</i> pneumonia

Table II. Endoscopic and radiologic evaluation of swallowing¹⁵.

Penetration – Aspiration – Scale	
Score	Criteria
1	Material does not enter airway
2	Material enters airway, contact with glottis, stimulates cough reflex and is ejected completely
3	Material enters airway, contacts glottis, stimulates cough reflex and is not completely ejected
4	Material enters airway, passes below glottis, stimulates cough reflex and is ejected completely
5	Material enters airway, passes below glottis, stimulates cough reflex and is not completely ejected
6	Material enters airway, passes below glottis and no effort is made to reject

Results

In the 7 patients treated, the following results were obtained (Table III):

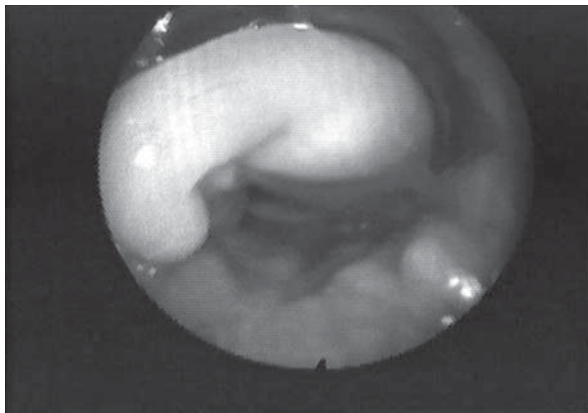
- complete recovery of dysphagia for solids and liquids in 4 patients (57.1%, cases nos. 1, 2, 3, 4); two of them (cases nos. 1, 2) still had tracheostomy, which was closed one week after injection laryngoplasty. Phonation also improved, with better loudness of voice as well as longer duration of voice. The positive result was still maintained one year after intervention (Fig. 3);

- for 2 patients (28.5%, cases nos. 5, 6) only a partial positive result was achieved, as one month after an initial improvement, dysphagia for liquids was again observed; these 2 patients had very difficult anatomic situations, with a wide neoglottic insufficiency. Neither patient had tracheostomy. One patient (case no. 5) was operated of cricothyroidopexy with maintenance of 2 (small) arytenoids; an injection laryngoplasty with PDMS (Vox Implants®) through microlaryngoscopy, under general anaesthesia, was performed, after first re-opening of tracheostomy for the anaesthesiologic intubation.

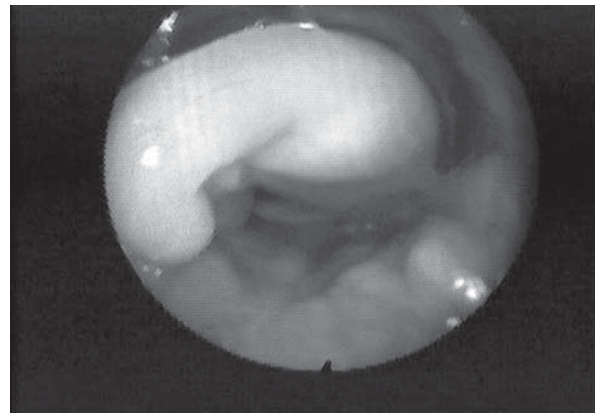
Table III. Results 3 months after injection laryngoplasty.

No.	Patient	Dysphagia score		P-A scale modified	
		Pre-operative	Post-operative	Pre-operative	Post-operative
1	J.M.	4	1	4	1
2	L.S.	4	1	4	1
3	V.C.	3	1	3	1
4	L.C.	3	1	3	1
5	R.G.	4	3	4	1-3
6	E.R.	4	3	4	2-3
7	T.E.	6	5	5	4

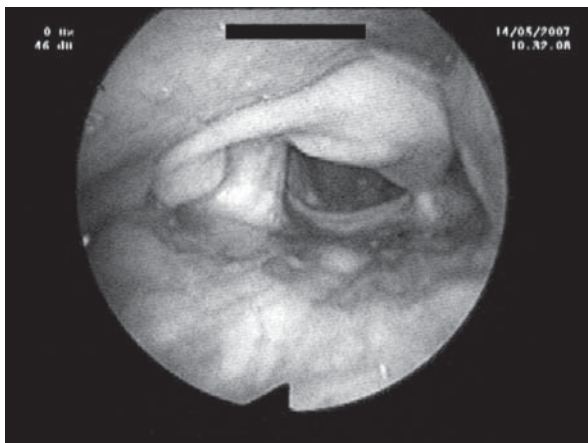
* Result 1 week after intervention



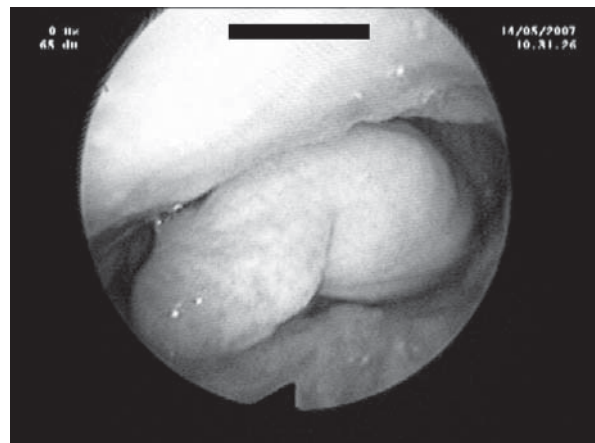
a



b



c



d

Fig. 3. Laryngeal fiberendoscopy in case no.1, operated for partial laryngectomy with crico-hyoidopexy with preservation of right arytenoid; a, b: pre-operative pictures during breathing (a) and phonation (b), c, d: laryngeal fiberendoscopy one year after injection laryngoplasty with bovine collagen (Zyplast®) into arytenoid and cricoid during breathing (a) and phonation (b).

In the other patient (case no. 6), operated upon for cricothyroidopexy with preservation of one arythenoid, an injection laryngoplasty with bovine collagen (Zyplast®) through fiberoendoscopy, under local anaesthesia, was performed. For both patients, a new intervention of injective laryngoplasty with collagen through fiberoendoscopy was performed;

- in one patient (14.4%, case no. 7), positive results were not achieved despite collagen injection through fiberoendoscopy, and followed by PDMS injection through microlaryngoscopy. The patient, a 78-year-old male with tracheostomy, operated for atypical sub-total laryngectomy with maintenance, but with stiffness, of both arythenoids, with a wide “slide” effect on the tongue base and with a spasm of the crico-pharyngeal muscle (revealed by video-fluoroscopy), which created a post-deglutitive stagnation of food with inhalation that caused several bronchopneumonias *ab ingestis*. The patient could not undergo a botulin toxin injection into the crico-pharyngeal muscle, because of a hiatal hernia

with severe gastro-oesophageal reflux, not brought under control with proton pump inhibitors treatment. In this patient, it was necessary to perform total laryngectomy.

Conclusions

These first results, even if referring to a small number of cases, show that injection laryngoplasty through fiberoendoscopy can be considered a good solution for dysphagia after partial laryngectomy. Also the voice can improve with this procedure. Our experience with injection of Vox Implants® through microlaryngoscopy is still in the early stage and it is too early to express judgement, but a recent report by Bergamini et al.¹⁰, on the use of this technique, in 8 patients submitted to partial laryngectomy, leads to encouraging results.

Finally, it is worthwhile stressing that logopaedic rehabilitation is fundamental in order to strengthen the results of surgical treatment of dysphagia.

References

- 1 Schindler O, Ruoppolo G, Schindler A. *Deglutologia*. Torino: Ed. Omega; 2001.
- 2 Bonavina L, Khan NA, De Meester TR. *Pharyngoesophageal dysfunctions. The role of crico-pharyngeal myotomy*. Arch Surg 1985;120:541-9.
- 3 Marchese-Ragona R, De Grandis D, Restivo D, Staffieri A, Marioni G, Pastore A. *Recovery of swallowing disorders in patients undergoing supracricoid laryngectomy with botulinum toxin therapy*. Ann Otol Rhinol Laryngol 2003;112:258-63.
- 4 Piemonte M. *La riabilitazione dopo grande chirurgia del collo*. In: Official Lecture at XII National Congress A.O.O.I.; Anacapri. 1989.
- 5 Remacle M, Marbaix M, Hamoir M, Bertrand B, Van Den Eeckhaut J. *Correction of glottic insufficiency by collagen injection*. Ann Otol Rhino Laryngol 1990;99:434-44.
- 6 Ricci Maccarini A, De Rossi G, Borragan A, Rasi F, Casolino D. *Elettromiografia laringea e impianto intracordale di grasso autologo mediante fibroendoscopia nella diagnosi e nel trattamento della monoplegia laringea*. In: Proceedings of XXXVIII National Congress S.I.F.E.L.; Salsomaggiore. 2004.
- 7 Ricci Maccarini A, De Rossi G, Borragan A, Riancho A, Diaz M, Narne S, et al. *Fat implantation under fiberoendoscopy in the treatment of unilateral paralysis of the vocal fold*. In: Proceedings of the International Symposium of Phonosurgery; Madrid. 2005.
- 8 Ricci Maccarini A, Borragan A, De Rossi G, Stacchini M, Casolino D. *Fat injection and freeing of the mucosa under local or general anaesthesia in the treatment of vocal fold scars*. In: Proceedings of the Round Table on “Treatment of vocal fold scars”. XVIII IFOS World Congress; Roma. 2005.
- 9 Ricci Maccarini A, Pieri F, Magnani M, Fustos R, Casolino D. *Micro-fonochirurgia*. In: Schindler O, editor. *Principi di vocologia*. Torino: Ed. Omega; 2007.
- 10 Bergamini G, Presutti L, Alicandri Ciuffelli M, Molteni G, Luppi MP, Ghidini A, et al. *Surgical swallowing rehabilitation with Vox Implants in patients underwent partial laryngectomy*. Comunicazione preordinata al 94° Congresso Nazionale S.I.O., Lecce 23-26 maggio 2007 (in press).
- 11 Coleman SR. *Facial recontouring with liposuction*. Clin Plast Surg 1997;24:347-67.
- 12 De Rossi G, Ricci Maccarini A, Borragan A, Stacchini M, Narne S. *Fonochirurgia fibroendoscopica*. In: Schindler O, editor. *Principi di vocologia*. Torino: Ed. Omega; 2007.
- 13 Diaz M, Riancho A, Borragan A. *Chirurgia endolaringea fibroscopica (C.E.L.F.); rehabilitation vocal*. Santander: Graficas Salima; 1999.
- 14 Borragan A, Riancho AG, Diaz M, Bascos M, Ricci Maccarini A, De Rossi G, et al. *Iniezione intracordale di grasso autologo mediante chirurgia fibroendoscopica (CELFL)*. In: Proceedings of XXXVI National Congress S.I.F.E.L.; Modena. 2002.
- 15 Rosenbek JC, Robbins JA, Roecker EB, Coyle JL, Wood JL. *A penetration-aspiration scale*. Dysphagia 1996;11:93-8.