

ROUND TABLE S.I.O. NATIONAL CONGRESS

Rehabilitation protocol of dysphagia after subtotal reconstructive laryngectomy

Protocollo di riabilitazione della disfagia dopo laringectomia subtotale ricostruttiva

S. COSCARELLI, L. VERRECCHIA, O. LE SAEC, A. COSCARELLI¹, R. SANTORO², E. DE CAMPORA²
 Phoniatics Unit, University Hospital "Careggi", Florence; ¹ Department of Economics and Statistics,
 University of Calabria; ² ENT Unit, University Hospital "Careggi", Florence, Italy

SUMMARY

Dysphagia is a constant complication of subtotal reconstructive laryngectomy, due to modifications in the anatomy and in sensitivity of the larynx and pharynx. The reduced sphincteric activity of the larynx can enhance aspiration with a higher risk of pneumonia. In our opinion, the presence of the tracheotomy tube in the first weeks after surgery interferes with proper mobility of the laryngo-tracheal axis during swallowing, as it anchors the trachea to the skin. We have conducted swallowing rehabilitation, without the tracheotomy tube, ready to aspirate eventual saliva or food debris dropping into the trachea. This protocol has been applied in 33 patients undergoing subtotal reconstructive laryngectomy and better patient compliance and swallowing performance were observed. The period to recover complete autonomous oral intake is less than one month and none of these patients showed signs or symptoms of aspiration pneumonia during hospitalisation or follow-up. This rehabilitation protocol is, therefore, a valid and effective alternative to other well-known procedures.

KEY WORDS: Swallowing • Dysphagia • Laryngectomy • Rehabilitation

RIASSUNTO

La disfagia è una complicanza costante della laringectomia ricostruttiva subtotale, dovuta ai cambiamenti dell'anatomia e della sensibilità superficiale laringofaringea. La ridotta attività sfinterica della laringe può facilitare l'aspirazione di materiale alimentare o saliva con un aumento del rischio di polmonite ab ingestis. A nostro parere la presenza della pur necessaria cannula tracheale nelle prime settimane del post-operatorio interferisce con una corretta mobilità dell'asse laringo-tracheale durante la deglutizione, in quanto fissa la trachea allo stoma cutaneo. Con questa convinzione, abbiamo condotto la riabilitazione deglutitoria facendo eseguire gli esercizi nel paziente decannulato, con una pronta intercettazione dei detriti alimentari o saliva transitati in trachea mediante aspirazione attraverso lo stoma. Abbiamo applicato questo protocollo in 33 pazienti sottoposti a intervento di laringectomia ricostruttiva subtotale, apprezzando una migliore performance deglutitoria e compliance. Il periodo per la ripresa di un'autonoma alimentazione per os è stato meno di un mese ed in nessun paziente ci sono stati segni o sintomi di polmonite ab ingestis durante il ricovero o nel follow-up. Questi dati confermano che questo nuovo protocollo di riabilitazione è un'efficace alternativa agli altri protocolli già ben noti.

PAROLE CHIAVE: *Deglutizione • Disfagia • Laringectomia • Riabilitazione*

Acta Otorhinolaryngol Ital 2007;27:286-289

Introduction

Dysphagia is a constant complication in patients who have undergone subtotal reconstructive laryngectomy and it is a life-threatening condition. The principal reason for the swallowing impairment, in these patients, is mechanical, consisting in incontinence of the glottic sphincter due to surgery-related anatomical modifications. Moreover, this impairment could be related to specific sensorial or motor deficits of the laryngeal mucosa on account of the lesions of the superior or inferior laryngeal nerve ¹. In subtotal reconstructive laryngectomy, difficult recovery of normal oral intake and aspiration is often possible during the first swallowing attempts immediately after surgery, with the risk of aspiration pneumonia. For this reason, there is a suspension

of oral intake immediately after surgery that can last for a few days or even weeks and, to ensure spontaneous breathing, to prevent aspiration of feeding material and to guarantee adequate alimentation, the patient is assisted with a feeding tube and a tracheotomy tube. The presence of the tracheotomy tube represents a fundamental guarantee for maintenance of respiratory function but, in our opinion, it also represents an important obstacle in the recovery of normal swallowing, since consequences, due to aspiration, can also occur due to a wrong pathway of the bolus in the trachea on account of insufficient up-lifting of the new-glottis plane that, together with the tongue base retraction, takes part to the closure of the respiratory tract during passage of the bolus in the pharynx. Blockage could be due to the presence of the tracheotomy tube that, anchoring the trachea on

a sagittal plane, reduces upward motility of the new larynx (Fig. 1).

Some Authors consider that the tracheotomy tube does not influence swallowing, but these studies concern patients who have not undergone surgery of the larynx^{1,2}. We conduct swallowing rehabilitation without the tracheotomy tube, which will be introduced after the exercises; during the swallowing exercise, with bolus or saliva, constant endo-tracheal trans-stomal aspiration is necessary to intercept the feeding debris passed into the trachea. In our opinion, precise and detailed information should be relayed to the patient concerning the problems related to the recovery of new effective swallowing. This is essential not only for real consensus given by the patient but also to prevent psychological stress and to create possibilities for a positive approach to the difficulties of the recovery period. The phoniatric doctor and the speech therapist must become referral figures for solving swallow impairments, the real keys to the complete success of reconstructive surgery of the larynx. Early rehabilitation ensures the patient of all those capacities essential for rapid recovery of a suitable social swallowing function.

Material and methods

Between April 2005 and October 2006, 33 patients underwent reconstructive laryngectomy at the ENT Clinic of the University of Florence: 15 patients to a crico-hyoid-epiglottopexy (CHEP) and 18 to crico-hyoid-pexy (CHP). Early swallowing rehabilitation was performed in all these patients. The 3 phases of the rehabilitation programme are outlined in Figure 2.

From the 4th day, the patient is followed during the breathing attempts, at first with the closed tracheotomy tube, then taking out the tube and temporarily closing the tracheostomy: in this way, the patient realizes the new-glottic sensibility

during the passage of air. The patient is then instructed to carry out voice exercises with a loud tone which is useful to make the patient aware of his/her new vibratory larynx. All these exercises must be performed in presence of a speech therapist ready to aspirate in the trachea.

After becoming confident with breathing and voice exercises, a standard swallowing protocol, composed of 6 steps, is then commenced (Fig. 3).

The breathing holding should be done acquiring a cervical position which brings the remaining larynx closer to the tongue base. In this way, closure of the air passage permits the patient to maintain a high pressure in the lower airways during the next swallow, that is important to contrast the normal falling down of food debris in the trachea in this procedure. This air pressure can be relieved after the swallow, breathing out and, finally, with a cough act. In the first attempts, the coughing and the swallowing could be ineffective due to incomplete closure of the remaining larynx. For this reason, it is important to acquire a "facilitating" position (turning the head on one side and/or lowering or raising the chin) which can improve closure of the air pathway and passage of the pharynx bolus into the oesophagus. From the 4th to the 7th day, the patient applies this protocol with dry exercises, after one week the same protocol will be repeated every day with saliva and, in the second week after surgery, the exercises will be carried out with semisolid food without the tracheotomy tube and with constant aspiration through the tracheostoma. The nutritional composition used during rehabilitation is outlined in Figure 4.

During recovery of oral intake, swallowing function will be monitored with serial fibro-endoscopy evaluations, in accordance with the worldwide protocols of instrumental evaluation of dysphagia^{1,2}.

With this protocol, the median time for complete recovery of oral intake is 24 days (min 18, max 34) for patients undergoing CHP and 20 days (min 15, max 30) for those

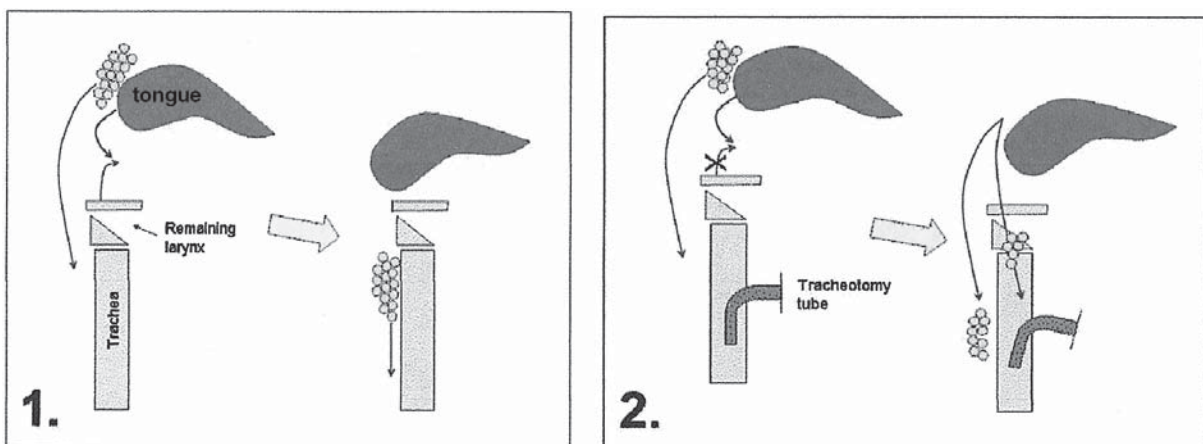


Fig. 1. Swallowing mechanism and tracheotomy tube blockage.

From 4th day after surgery: breathing exercises, voice exercises and empty swallow exercises.
 From 8th day: swallow exercises with semi-solid bolus and densified liquids for a training period of 6-7 days.
 From 14th day: attended feeding.

Fig. 2. Rehabilitation programme.

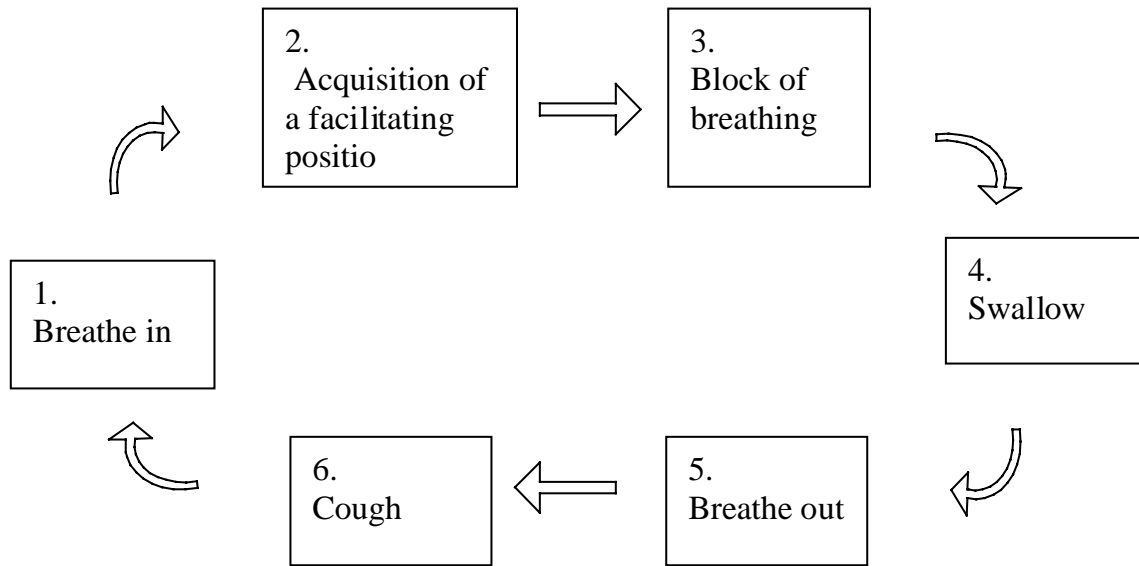


Fig. 3. Swallowing protocol.

Morning	→	pudding or cream caramel
Lunch and dinner	→	dry semi-solid food
	→	whisked beef and ham or whisked trout with vegetables
	→	whisked fruits or milk shake (banana or apple)

Fig. 4. Nutritional scheme.

undergoing CHEP. None of the 33 patients presented aspiration pneumonia during hospitalisation or follow-up (median 13 months, range: 5-23).

Discussion

Swallowing rehabilitation, in patients who have undergone partial laryngectomy, is aimed at close follow-up of the patient during the early post-operative period, supporting him/her in the 2 important functions, namely feeding and breathing. The patient will learn to use the new larynx, with decreased sensitivity and mobility due to the surgery. The larynx represents the main intersection between the air and upper digestive pathways and, in the first days after surgery, the main problems are: 1) dyspnoea due to larynx obstruction (oedema); 2) dysphagia due to lack of laryngo-pharyngeal coordination; 3) aspiration of saliva or food. For these problems, the presence of a tracheotomy tube is essential since it guarantees a normal air exchange and a mechanical blockage to aspiration. At the end of rehabilitation, the patient should be able to eat alone and to use a social effective voice. In our opinion, the first time dysphagia, referred by patients who have undergone this type of surgery, is obviously due to the anatomical modifications of the larynx, but also to the presence of the tracheotomy tube that represents a point of fixation of the laryngo-tracheal axis during swallowing: the limited raising of the residual larynx keeps open

the respiratory tract during the falling down of the bolus in the pharynx. Other Authors have observed that this mechanism contributes to the dysphagia in this type of surgery⁶⁷. Bearing in mind this point of view, we have applied the swallowing protocol removing the tracheotomy tube during the exercises and, in our experience, swallowing without the tube is more comfortable for the patient and improves the swallowing performance: the swallowing action becomes more effective with better closure of the remaining larynx under the retracted tongue base. In fact, none of these patients with this rehabilitation procedure developed aspiration pneumonia during or after hospitalization.

Conclusions

The swallowing rehabilitation program, following subtotal reconstructive laryngectomy, applied at the ENT Unit of the University Hospital of Florence permits recovery of effective swallowing for daily life, in less than one month. In our opinion, the presence of the tracheotomy tube, during rehabilitation exercises, hinders swallowing function, increasing the probability of passage of food into the trachea. Removing temporarily the tracheotomy tube, during the swallowing rehabilitation exercises, clearly improves the swallowing performance without any added risk of aspiration pneumonia.

References

- ¹ Piemonte M. *La riabilitazione dopo grande chirurgia del collo*. (Relazione ufficiale del XIII Convegno Nazionale di Aggiornamento AOOI. Anacapri, 30 September-1 October 1989). Udine: Grafiche Fulvio Ed.; 1989. p. 75-85.
- ² Leder SB, Joe JK, Ross DA, Coelho DH, Mendes J. *Presence of a tracheotomy tube and aspiration status in early, postsurgical head and neck cancer patients*. *Head Neck* 2005;27:757-61.
- ³ Terk AR, Leder SB, Burrell MI. *Hyoid bone and laryngeal movement dependent upon presence of a tracheotomy tube*. *Dysphagia* 2007;22:89-93.
- ⁴ Ruoppolo G. *La valutazione strumentale della disfagia*. In: Relazione del XXXV Congresso Nazionale SIFEL – Corso di Aggiornamento: La Rieducazione Logopedica ed il Recupero Funzionale dopo Laringectomia Subtotale Salerno: Ed. Formenti; 2001. p. 47-53.
- ⁵ Rademaker AW, Logemann JA, Pauloski BR, Bowman JB, Lazarus CL, Sisson GA, et al. *Recovery of postoperative swallowing in patients undergoing partial laryngectomy*. *Head Neck* 1993;15:325-34.
- ⁶ Simonelli M, Ruoppolo G, Suriano M. *Problematiche e complicanze legate all'uso della nutrizione enterale e della tracheotomia*. In: *Deglutologia*. Schindler O, Ruoppolo G, Schindler A, editors. Torino: Ed. Omega; 2001. p. 519-31.
- ⁷ Nash M. *Swallowing problems in the tracheotomized patient*. *Otolaryngol Clin North Am* 1988;21:701-98.