

ONCOLOGY

High resolution magnifying endoscopy: a new diagnostic tool also for laryngeal examination?

Endoscopia ad alta risoluzione e magnificazione: uno strumento diagnostico utile anche nella valutazione laringea?

J. GALLI, G. CAMMAROTA¹, M. RIGANTE, E. DE CORSO, C. PARRILLA, G.C. PASSALI, G. ALMADORI, G. PALUDETTI
Institute of Otolaryngology and Gastroenterology¹, Catholic University of the Sacred Heart, Rome, Italy

SUMMARY

Aim of this report is to introduce the use of a new high resolution magnifying endoscope in the endoscopic examination of the upper aerodigestive tract and discuss the usefulness of this tool in the diagnosis of laryngeal lesions. A total of 26 patients presenting various laryngeal disorders were examined by means of an electronic videoendoscope and a high resolution magnifying endoscope. The images obtained were examined and compared. High resolution high magnification endoscopic examination allowed a better description of the laryngeal lesions (colour, extension and thickness of the lesion, irregularities in surface and borders) with easy characterisation of aspect of neighbouring laryngeal mucosa especially in pre-malignant lesions. Furthermore, the optical magnifying zoom does not require a close approach to the laryngeal mucosa, therefore, local anaesthesia is not required. In conclusion, the high resolution magnified images obtained with this new tool provide important information on the characteristics of the laryngeal structures. This new endoscopic technology, as already occurred in gastric, oesophageal and colorectal disorders, could also be improved by using chromo-endoscopy and other vital stain techniques in order to provide useful information concerning pre-neoplastic lesions of the larynx.

KEY WORDS: Larynx, laryngeal lesions, diagnosis, fibre optic endoscope, high resolution magnifying endoscopy

RIASSUNTO

Scopo del presente lavoro è di proporre l'uso dei nuovi endoscopi ad alta risoluzione ed alta magnificazione nella valutazione endoscopica delle vie aerodigestive e discuterne l'utilità diagnostica nella diagnosi delle lesioni laringee. 26 pazienti con differenti patologie laringee sono stati esaminati mediante videolarinoscopia elettronica e mediante endoscopia ad alta risoluzione ed alta magnificazione. Le immagini ottenute sono state esaminate e messe a confronto. La valutazione mediante endoscopi ad alta magnificazione ed alta risoluzione ha consentito una migliore descrizione delle lesioni laringee in termini cromatici, di estensione e spessore, delle caratteristiche della superficie e dei bordi, permettendo una più semplice caratterizzazione degli aspetti della mucosa circostante in particolare nelle lesioni pre-cancerose. Inoltre, la presenza di un sistema ottico di ingrandimento non rende necessaria una vicinanza eccessiva alla mucosa laringea e quindi riduce l'uso di anestetici locali con una migliore compliance del paziente. In conclusione, l'endoscopia ad alta risoluzione ed alta magnificazione fornisce preziose informazioni per la caratterizzazione delle lesioni laringee e potrebbe essere ulteriormente migliorata mediante le tecniche di cromoendoscopia e con coloranti vitali, come già sta succedendo nello studio della patologia gastrica, esofagea e del colon-retto, in modo da migliorare la diagnosi delle lesioni pre-cancerose.

PAROLE CHIAVE: laringe, lesioni laringee, diagnosi, fibroendoscopia, endoscopia ad alta risoluzione

Acta Otorhinolaryngol Ital 2007;27:233-236

Introduction

The commercial introduction of the first flexible fiberoptic endoscope, in 1961, marked the beginning of a revolution in the diagnosis of upper and lower aero digestive tract disorders. In the last 20 years, there has been a more widespread use, in ENT practice, of fiberoptic flexible endoscopy by means of which it is possible, in the same examination, to inspect and collect information on nasal cavities, naso-oro-hypopharynx and larynx, in a clear and detailed way, especially as far as concerns not easily explorable areas with traditional indirect endoscopy¹. However, constant developments have taken

place in the area of endoscopy and presently fiberoptic (video) endoscopes are widely supported and sometimes replaced by electronic video-endoscopes, a relatively recent endoscopic methodology, first proposed by Cosentino et al.² in otolaryngology clinical practice. Conventional video-endoscopes are equipped with Charged Coupled Devices (CCD) chips of 100K to 300K pixels, pixel density being important for image resolution and hence to discriminate two closely approximated points and the more likely minute lesions. The second generation electronic videoendoscopes are equipped with CCD chips of 400K³ and, recently, gastroscopes and colonoscopes with 850K pixel density, known as high-resolu-

tion endoscopes were introduced. Furthermore, some of these endoscopes are equipped with an optical zooming facility comprising a movable motor driven lens in the tip of the scope that, controlling the focal distance, can move very close to the mucosal surface providing the magnified image⁴. These scopes are referred to as magnifying endoscopes and increase the level of magnification discriminating detail so that suspicious small lesions in the non-magnified overview image can be detected reducing the surface area that is visualized. Actually several studies describe the application of this kind of magnifying endoscopes in oesophageal^{5,6}, gastrointestinal^{6,7}, colorectal⁸ and bronchopneumological pathologies^{9,10}. In previous studies, we already presented our experience by means of electronic videoendoscopy in diagnostic staging and follow-up of phlogistic and, above all, pre-neoplastic and neoplastic laryngopharyngeal pathology¹¹, but nothing, to our knowledge, has been published regarding high-resolution and magnification endoscopy of the upper aerodigestive tract.

Patients and methods

Patients

A total of 26 randomly selected patients (9 female, 17 male, age range 30-72 years), underwent electronic videoendoscopy and high resolution magnifying endoscopy of

the larynx, at the Department of Otolaryngology of the Catholic University of the Sacred Heart (Rome, Italy).

Endoscopy

Electronic videolaryngoscopic examination was performed using a Pentax 2 E 2900 gastroscope, diameter 9 mm and with a videoprocessor Pentax ZPM 3000 (Pentax Europe, Hamburg, Germany). The high resolution magnifying endoscopic examination was performed with the Fuji EG-485ZH video-endoscope (Fuji, Fujinon, Omiya, Japan) used for laryngeal and upper gastro-intestinal (GI) examinations. The characteristics of high-resolution standard video-endoscopy are 850,000 pixel chips and adjustable electronic enlargement of details in a continuous range up to 2.0x. The instrument depths of field are 8-100 mm and 4-7 mm in the wide and narrow position, respectively. The diameter of the endoscope is 10.7 mm, with a working length of 110 cm and 2.8 mm biopsy channel. Tip angulations are slightly less in the upward direction than that of a standard gastroscope (190° vs. 210°), but the downward (90°) and left-right angulations (100°) are the same. The visual field is 120°.

Results

In all patients, high magnification and digital image processing provided a better description of colour, extension and

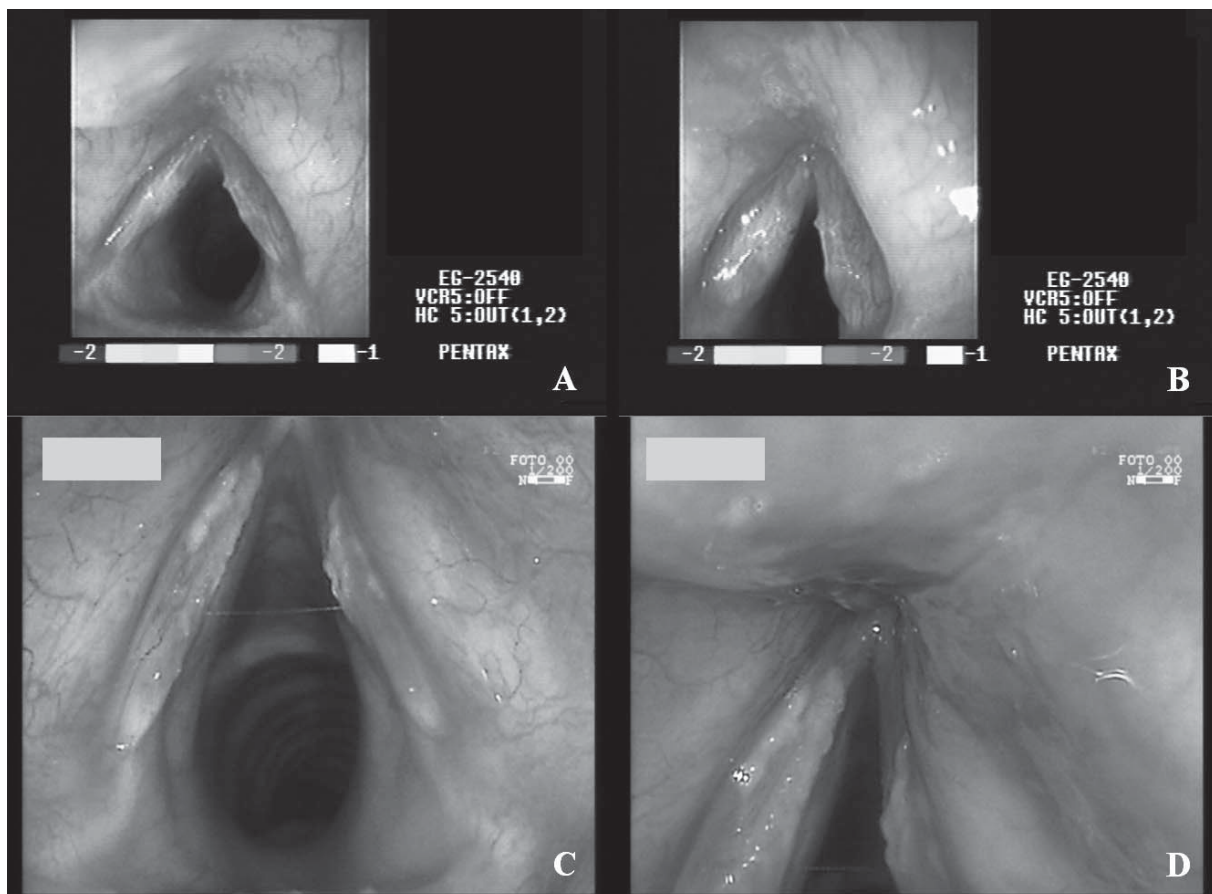


Fig. 1. Endoscopic still images of larynx in 65-year-old male. A and B: obtained with electronic videolaryngoscope (Pentax 2 E 2900 with videoprocessor Pentax ZPM 3000, Pentax Europe, Hamburg, Germany) presence of a bilateral plane leukoplakia of anterior and middle portion of vocal folds is visible. C and D: obtained with high resolution and magnifying endoscope (Fuji EG-485ZH video-endoscope – Fuji, Fujinon, Omiya, Japan), allowed better characterization of leukoplasic lesions and gave good three-dimensional aspect and better colour discrimination of lesion. Magnified detail of anterior commissure (D) obtained with optical zoom without moving tip of instrument.

thickness of the lesions (three-dimensional aspect), surface and border irregularities, easy characterisation of aspect of neighbouring laryngeal mucosa, good definition and localization of oedema, erythema/hyperaemia allowing also to score posterior hypertrophy from mild to severe.

The difference between the images acquired with the electronic video-endoscope and the high resolution magnifying video-endoscope are clearly shown in Figures 1 and 2.

Another important result was that, due to the optical magnification, the tip of the instrument did not need to stay too close to the laryngeal mucosa to obtain a good view of the lesions, thus allowing the examination to be performed using less local anaesthesia with better patient compliance.

Discussion

Introduction of fiberoptic technology has greatly enhanced the clinician's access to the many recesses of the upper aerodigestive tract, in the outpatient setting¹. Video-laryngoscopy and electronic video-laryngoscopy² have further refined the technique by providing permanent documentation of the examination and high quality of images, thus allowing subsequent review, without subjecting the patient to further discomfort, or comparing the images during follow-up. Recently, the possibility is emerging to perform endoscopy with new powerful endoscopes. Newly developed high-resolution and magnification endoscopes offer sig-

nificantly better image quality than that of first-generation video endoscopes or the older fiber-optic systems^{3,4}.

Resolution of an endoscopic image is a different quality from magnification and is defined as the ability to distinguish between two points that are closer together in order to discriminate details, while magnification enlarges the image. In digital video-imaging, resolution is a function of pixel density. By incorporating high-pixel density charged-coupled devices (CCD), high resolution endoscopes provide slightly magnified views with greater mucosal detail^{3,4}. Magnification endoscopy uses a movable lens, controlled by the endoscopist to vary the degree of magnification, which ranges from x 1.5 to x 150. In newly designed magnification endoscopes, these two kinds of technology provide both high-resolution and magnification features allowing detailed inspection of the mucosa that could improve differential diagnosis between non-neoplastic and neoplastic lesions and between benign neoplasms and cancer contributing to further development of the endoscopic diagnosis of various upper aerodigestive tract lesions⁵⁻⁸. In our cases, we confirmed this issue observing that with this kind of endoscopy, it is possible to obtain enhancement of the contours and surface irregularities of the lesions and it would appear to be possible to detect, with precision, irregular laryngeal lesions and to provide valuable information that may be used to guide the selection of optimal treatment and post-operative follow-up.

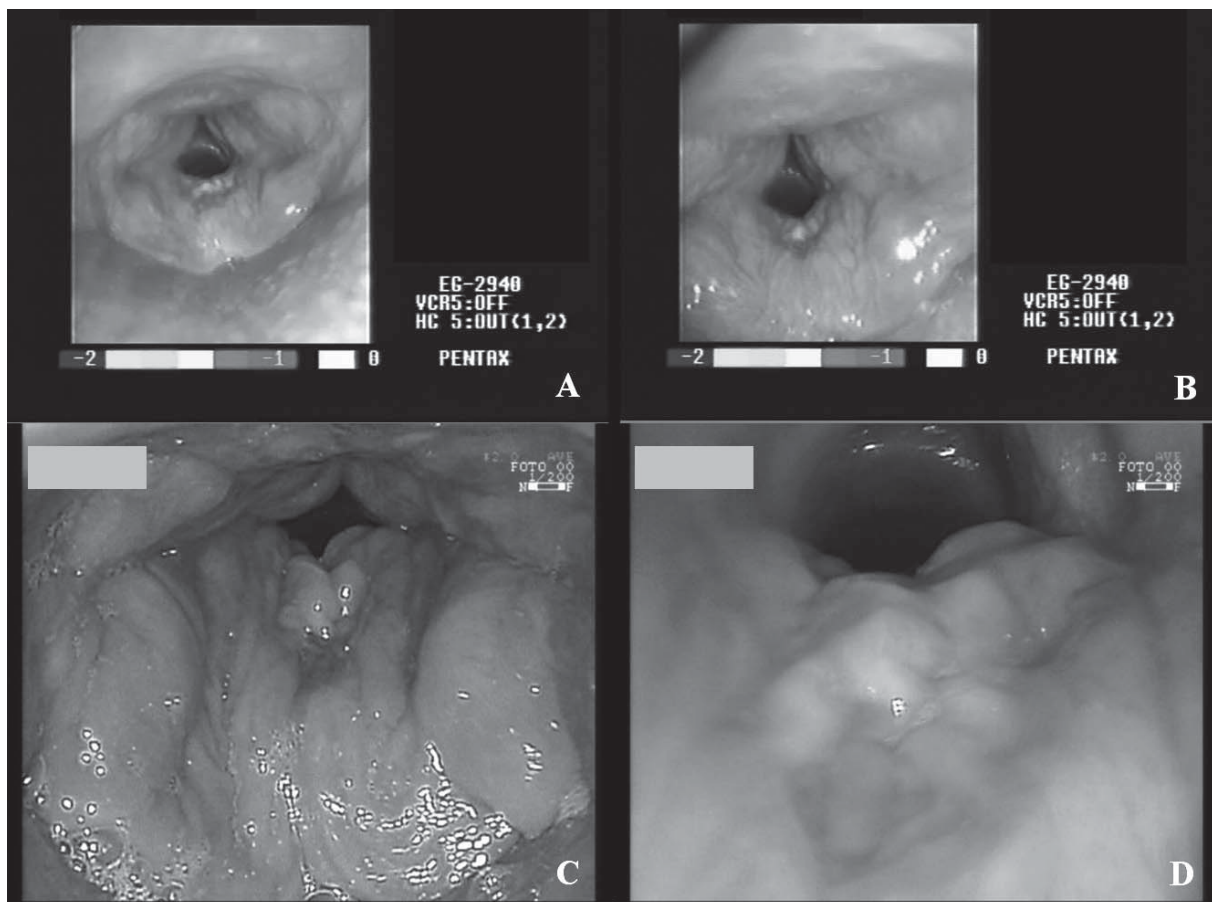


Fig. 2. Still images of 42-year-old male. A and B: obtained by electronic videoendoscopy shows diffuse laryngeal hyperaemia, with hyperplasia and oedema of posterior commissure at level of which a leukoplakia-like lesion is visible. C and D: obtained with magnifying endoscope shows correct extension of hyperplasia and oedema of posterior commissure of severe degree, referred to as elephant skin, the ventricular obliteration and also clarify absence of leukoplakia in posterior commissure (D).

More than 90% of malignant laryngeal tumours are squamous cell carcinomas, almost always developing from pre-cancerous epithelial lesions and this is why early detection and pre-operative assessment are important for curative and functional preservation therapy as early cancer can be completely removed by means of various conservative treatments with an important impact on the quality of life of the patient. Although histopathology by means of micro-laryngoscopy is still the standard method for the diagnosis of pre-malignant lesions and early cancer of the larynx, new technologies have recently been developed to improve the endoscopic information during micro-laryngoscopy, e.g., rigid-angled endoscopes, contact endoscopy^{11 12}, and fluorescence endoscopy¹³ with or without fluorescence-enhancing agents but all these techniques require general anaesthesia and do not allow vocal fold inspection during their movement. A complementary endoscopic diagnostic tool that could help, without general anaesthesia, to distinguish benign from pre-malignant and malignant lesions and to follow patients after conservative oncologic surgery appears to be very useful in clinical practice. Concerning the limits, although visual evaluation of minute detail offered by magnification endoscopy is promising, inflammation can cause a significant disturbance of the image seen when magnifying endoscopy is used to seek minute changes indicative of neoplasia and could determine false-positive results. Inflamed epithelium should be treated pri-

or to the final endoscopic evaluation, whenever possible. These techniques point out a plethora of mucosal detail, the evaluation of which increases the procedure time, at least when the endoscopist is learning the technique.

Peretti et al.¹⁴ proposed a diagnostic work-up in glottic carcinoma, which includes also intra-operative supra-vital staining with 2% toluidine blue to identify the precise surface extent of the tumour and to demonstrate superficial areas of cellular atypia. Furthermore, according to this experience and that on the gastro-intestinal district¹⁵, chromoendoscopy could be proposed also on the upper aerodigestive tract to enhance the diagnostic field of intra-epithelial neoplasia as compared with conventional endoscopy and biopsy techniques differentiating non-neoplastic from neoplastic lesions with high overall sensitivity and specificity. In conclusion, high resolution magnifying endoscopy, even though still referring to expensive technology, appears to be a new valid tool improving the endoscopic diagnostic field of upper aerodigestive tract disease. There are few limits and doubts and probably these can be overcome by training and increased experience. These newly developed high-resolution and magnification endoscopes offer features that allow more and new mucosal details to be observed. In accordance with gastrointestinal and broncho-pneumological experience, the possibility to utilize this technique combined with broncho-chromo-endoscopy needs to be evaluated also on the upper aerodigestive tract.

References

- Maurizi M, Paludetti G, Galli J, Corina L. *Electronic fibrovideolaryngoscopy in the diagnosis and surgical treatment of laryngeal pathology*. In: Motta G, editor. *The new frontiers of Otorhinolaryngology in Europe*. Bologna: Monduzzi Ed., 1992. p. 183-6.
- Cosentino F, Morandi E, Rubis Passoni G, Tuccimei S, Carnevale Ricci PM. *Therapeutic videolaryngoscopy*. *Acta Endoscopica* 1990;20:328-31.
- Kawaida M, Fukuda H, Kohno N. *Digital image processing of laryngeal lesions by electronic videoendoscopy*. *Laryngoscope* 2002;112:559-64.
- Bruno MJ. *Magnification endoscopy, high resolution endoscopy, and chromoscopy; towards a better optical diagnosis*. *Gut* 2003;52(Suppl 4):7-11.
- Connor MJ, Sharma P. *Chromoendoscopy and magnification endoscopy in Barrett's esophagus*. *Gastrointest Endosc Clin N Am* 2003;3:269-77.
- Sharma P, Weston AP, Topalovski M, Cherian R, Bhattacharyya A, Sampliner RE. *Magnification chromoendoscopy for the detection of intestinal metaplasia and dysplasia in Barrett's oesophagus*. *Gut* 2003;52:24-7.
- Dinis-Ribeiro M, da Costa-Pereira A, Lopes C, Lara-Santos L, Guilherme M, Moreira-Dias L, et al. *Magnification chromoendoscopy for the diagnosis of gastric intestinal metaplasia and dysplasia*. *Gastrointest Endosc* 2003;57:498-504.
- Hurlstone DP, Cross SS, Adam I, Shorthouse AJ, Brown S, Sanders DS, et al. *Efficacy of high magnification chromoscopic colonoscopy for the diagnosis of neoplasia in flat and depressed lesions of the colorectum: a prospective analysis*. *Gut* 2004;53:284-90.
- Shibuya K, Hoshino H, Chiyo M, Iyoda A, Yoshida S, Sekine Y, et al. *High magnification bronchovideoscopy combined with narrow band imaging could detect capillary loops of angiogenic squamous dysplasia in heavy smokers at high risk for lung cancer*. *Thorax* 2003;58:989-95.
- Tanaka H, Yamada G, Saikai T, Hashimoto M, Tanaka S, Suzuki K, et al. *Increased airway vascularity in newly diagnosed asthma using a high-magnification bronchovideoscope*. *Am J Respir Crit Care Med* 2003;168:1495-9.
- Carriero E, Galli J, Fadda G, Di Girolamo S, Ottaviani F, Paludetti G. *Preliminary experience with contact endoscopy of the larynx*. *Eur Arch Otorhinolaryngol* 2000;257:68-71.
- Andrea M, Dias O, Santos A. *Contact endoscopy during microlaryngeal surgery. A new technique for endoscopic examination of the larynx*. *Ann Otol Rhinol Laryngol* 1995;104:333-9.
- Malzahn K, Dreyer T, Glanz H, Arens C. *Autofluorescence endoscopy in the diagnosis of early laryngeal cancer and its precursor lesions*. *Laryngoscope* 2002;112:488-93.
- Peretti G, Nicolai P, Redaelli De Zinis LO, Berlucchi M, Bazzana T, Bertoni F. *Endoscopic CO₂ laser excision for T1, and T2 glottic carcinomas: cure rate and prognostic factors*. *Otolaryngol Head Neck Surg* 2000;123:124-31.
- Kiesslich R, Jung M, Di Sario JA, Galle PR, Neurath MF. *Perspectives of chromo and magnifying endoscopy: how, how much, when, and whom should we stain?* *J Clin Gastroenterol* 2004;38:7-13.

Received: April 30, 2007 - Accepted: July 30, 2007