

CASE REPORT

Two anomalous localizations of mucocele: Clinical presentation and retrospective review

Due anomale localizzazioni di mucocele: presentazione clinica e revisione della letteratura

S. CAVAZZA, C. BOCCIOLINI¹, P. LAUDADIO¹, G. TASSINARI, D. DALL'OLIO¹Department of Ophthalmology, ¹ Department of ENT, Head-Neck Surgery, Maggiore Hospital, Bologna, Italy

SUMMARY

Two Caucasian males (57 and 70 years old) were referred to our attention with paranasal mucoceles, maxillary and frontal mucocele, respectively, that had eroded the orbital rim and caused swelling of the eyelids and brow. Invasion of the orbital space caused several ophthalmic symptoms such as diplopia, proptosis, ptosis, and the formation of a palpable mass. Ophthalmic involvement was the first sign of the mucocele. The mucoceles were completely excised through a skin incision and the diseased mucosa of the sinuses was removed: endonasal fibre optic surgery and the Caldwell-Luc procedure were used in the patient with maxillary mucocele. The cases are described with retrospective review.

KEY WORDS: Maxillary sinus • Frontal sinus • Mucocele • Secondary cyst • Surgical treatment

RIASSUNTO

Due uomini caucasici (di 57 e 70 anni) sono giunti alla nostra osservazione per mucocele dei seni paranasali, rispettivamente mucocele mascellare e frontale, con erosione del bordo orbitale e tumefazione palpebrale e del sopracciglio. L'invasione della cavità orbitale aveva causato molti disturbi oftalmici quali diplopia, proptosi, ptosi e la formazione di una massa palpabile. Il coinvolgimento oftalmico è stato il primo segno del mucocele. I mucoceci sono stati completamente asportati mediante un'incisione cutanea e la mucosa patologica dei seni è stata rimossa chirurgicamente: nel paziente affetto da mucocele mascellare le procedure chirurgiche sono state una chirurgia per via endoscopica mediante l'uso di fibre ottiche e tecnica tipo Caldwell-Luc. Vengono descritti i casi con una revisione della letteratura.

PAROLE CHIAVE: Seno mascellare • Seno frontale • Mucocele • Cisti secondaria • Terapia chirurgica

Acta Otorhinolaryngol Ital 2007;27:208-211

Introduction

Cystic lesions of the orbit include a broad spectrum of cysts: of the surface epithelium, teratomatous, neural, secondary and inflammatory in addition to non cystic lesions with a cystic component¹. The most important secondary cyst is mucocele^{1,2}: this is a cystic lesion originating from the paranasal sinuses: it expands slowly, eroding bone and extending into the adjacent orbital cavity. Obstruction of the sinus ostium, by inflammation, trauma or polyposis, leads to the cyst which fills with a mucinous secretion and this exerts pressure on the surrounding bone: the cyst must be completely removed by surgery and normal drainage re-established^{2,3}. Mucoceles account for 4-8.5% of expanding orbital lesions⁴, anterior palpable mass is a rare feature^{4,5}: two cases of this condition are presented with discussion of the retrospective review.

Case report 1

A 57-year-old Caucasian male complained of epistaxis, rhinorrhea and a round mass in the right inferior lid (Fig. 1) measuring approximately 3 cm. It was compressible, and

non-pulsatile: it could not be trans-illuminated, and there was little associated pain. The mass had been progressively increasing in size for several days and was associated with right maxillary sinus disease. On magnetic resonance imaging (MRI), the mass appeared well-encapsulated and homo-

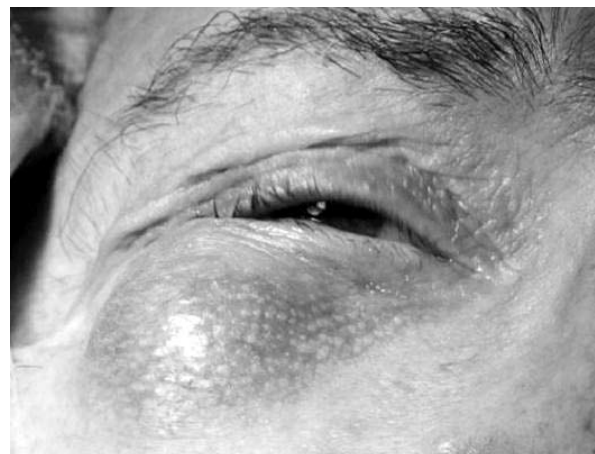

Fig. 1. Patient 1: a large cyst appeared under lower lid.

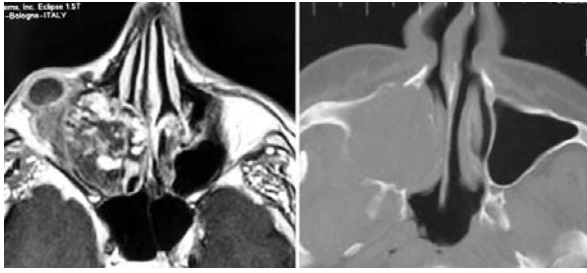


Fig. 2. Patient 1: (left) T1-weighted MRI revealed a well-encapsulated right cyst homogeneously filled with liquid and an extensive heterogeneous lesion measuring approximately 5 cm involving the ipsilateral maxillary sinus; (right) axial CT shows a clearer picture of the maxillary bone with a better outline. Bone of medial and anterior wall appeared eroded and displaced by the tumour inside.

ogeneously filled: the ipsilateral maxillary sinus contained heterogeneous material (Fig. 2 left). Computed tomography (CT) of the maxillary bone provided a better picture and the bone appeared eroded and displaced by the tumour inside (Fig. 2 right). By means of fine needle aspiration, 10 cc of yellowish mucinoid liquid was removed which proved negative for bacterial culture. The patient underwent an ophthalmologic examination consisting of visual acuity, funduscopy, exophthalmometry and oculomotor function. No alterations in these parameters were observed. Management of this complex sinus-orbital disorder required different approaches in conjunction with the standard endoscopic techniques⁶⁷: under general anaesthesia, the mass was removed through a subciliary skin incision extended to the temporal canthus. The cyst was detected below the orbicular muscle (Fig. 3) and was closely adhering to the infra-orbital foramen. We completed ablation by endo-nasal fibre optic surgery and Caldwell-Luc procedure, a technique used to remove infection and diseased mucosa from the maxillary sinus via the canine fossa⁸: we removed the cystic lining from the maxillary sinus and from the orbit floor. Histology revealed an inflammatory mucocele: no fungal hyphae were detected. Post-operatively, the patient exhibited a right inferior lid ectropion. Two months later, we corrected the lid ectropion, caused by a lack of anterior lid lamella. First, we

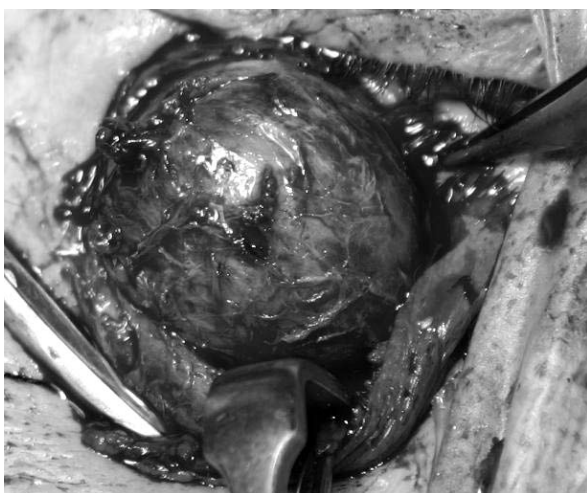


Fig. 3. Patient 1: wall of the cyst appeared under the orbicularis muscle.

released the cicatricial force by cutting the scar tissue, then performed a lateral tarsal strip operation⁹. The sensitivity of the inferior lid and of the cheek were preserved. There was no evidence of recurrence at 24 months' follow-up.

Case report 2

A 70-year-old Caucasian male affected by *myasthenia gravis*, presented diplopia in up-gaze and a painless swelling of the left upper lid and brow with minimal ptosis and proptosis. His neurologist had initially commenced treatment with Tensilon, but, as the symptoms remained unchanged, the patient was referred to an ophthalmologist. A complete ophthalmic examination revealed: visual acuity 20/20 with correction in both eyes, the intra-ocular pressure and automated perimetry were normal. Hertel readings right eye 17 mm, left eye 23 mm, mean reflex distance (MRD1): right 4 mm, left 2 mm. The retinal fundus revealed striae. Ocular motility showed paresis of the superior rectus muscle. CT (Fig. 4) and MRI showed a mucocele localized lateral in the frontal sinus and extending inferiorly into the orbit, with erosion of the anterior and posterior walls of the frontal sinus (Fig. 5). The patient underwent lateral craniotomy: the skin incision beginning superiorly and laterally at the brow and continuing posteriorly along the zygomatic bone. Erosion of the frontal bone was observed below the fronto-temporalis fascia, the mucocele was well isolated, the lining excised and the bone smoothed with a drill to remove any crevices that may have been lined by epithelium. During exeresis of the mucocele, we discovered osteolysis with cerebro-spinal

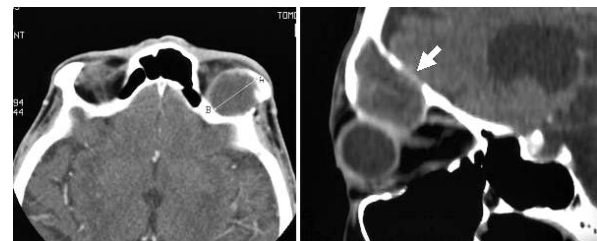

Fig. 4. Patient 2: (left) axial CT showing a large homogeneous mass, with max diameter 3.5 cm, involving left frontal sinus and extending into the orbital cavity; (right) sagittal scan: NB relationship between sinus cavity and brain (arrow) with eggshell bone erosion.

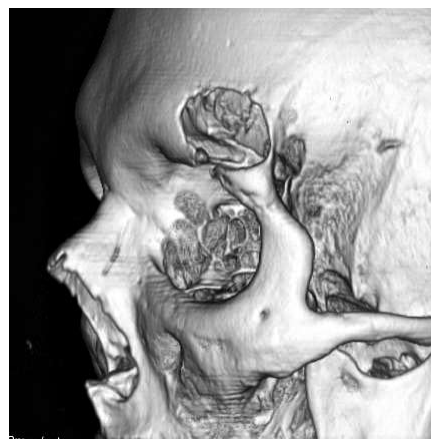


Fig. 5. Patient 2: 3D reconstruction with well-defined erosion of orbital roof.

fluid leakage from the posterior wall of the frontal sinus: this defect was closed with a patch of bovine pericardium (TutoPatch) and a fragment of temporalis muscle. The mucocele was also dissected from the periorbita that was left intact. The sinus was obliterated with fat and the defect of the orbital rim was repaired with bovine pericardium (TutoPatch). Ten months later no recurrence was noted and the diplopia was markedly reduced. The striae had disappeared from the retinal fundus, Hertel readings were: right eye 17 mm, left eye 19 mm.

Discussion

Paranasal sinus mucoceles are most commonly found in the frontal sinus, with less frequent involvement of the other sinuses^{2,4,5}. There are numerous theories concerning the origin and development of maxillary sinus mucoceles: they may be of congenital, retention, infectious, traumatic and inflammatory aetiology². In a series of nine maxillary sinus mucoceles examined by Marks et al.¹⁰, 2 patients had trauma, 2 had previously been subjected to the Caldwell-Luc procedure, and one was affected by allergy; in 4 cases the cause was unknown. Likewise, 12 out of 16 patients with maxillary sinus mucoceles, in the series examined by Butugan et al.¹¹, had previously been subjected to surgery or affected by trauma, and it was presumed that in 4 out of the 16 patients, the conditions resulted from repeated sinusitis. Mucoceles that develop following Caldwell-Luc operations are presumed to be the result of entrapped sinus mucosa. The aetiology of the mucoceles observed by Busaba and Salman¹² was not clear: only 2 out of 13 subjects treated for maxillary sinus mucopyoceles had a history of environmental allergies and none had nasal polyps. In addition, there were no ipsilateral concha bullosa or Haller cells that could potentially obstruct the ostiometal complex region: 10 patients had nasal septal deviation, but the deviation was ipsilateral to the mucocele only in 6 of these patients.

Frontal and fronto-ethmoidal mucoceles account for approximately 60% of the paranasal sinus mucoceles^{2,5}. Obstruction of the fronto-nasal duct can lead to the development of a frontal mucocele, the cause of which could be the abnormal density of mucus, for example in patients affected by cystic fibrosis, or a mechanical obstruction of the channel due to previous trauma, nasal polyposis, a post-operative reaction of scarring and neoplasm^{13,14}. The other more important factor in the pathogenesis of mucocele is mucosal inflammation. The orbit is often affected by frontal sinus mucocele and the most common sign of orbital invasion is the exophthalmus. This mucocele grows slowly and orbital invasion can occur several months or even years later: simultaneous erosion of the posterior, or the upper wall of the frontal sinus with an intracranial invasion is common (Fig. 4). In the literature, the percentage of intra-cranial infiltration from the frontal mucocele varies between 27% and 61%¹³.

The mean age of patients affected by mucocele is 50.3 years²: the incidence of this disease varies between 3-4% of all orbital patients², the maxillary sinus being the structure which is least likely to be involved, with the frontal and fronto-ethmoidal being the most common origin^{2,4,5}. Case 1 presented a round palpable mass on the orbital rim: this caused facial pain, possibly due to irritation of the infra-

orbital nerve. In case 2, the mucocele had eroded the roof of the anterior orbit leading to a swelling of the brow, proptosis and diplopia. More functional abnormalities are found in posterior mucoceles^{4,5,15} due to their relationship with the optic, oculomotor and sensory nerves and the globe. The ophthalmologist's role is important, even in the initial stages, because ophthalmic involvement may be the first sign of mucocele, and his/her role is fundamental in the joint management with the ENT specialist.

In our two cases, the coexisting sinus disease and imaging of its relationship with the cyst strongly indicated a secondary lesion that had migrated along the disrupted bones into the anterior orbital spaces.

CT and MRI are both considered the gold standard for the diagnosis of these lesions^{2,3,5}.

CT scans are used to evaluate the amount of expansion and erosion of the bone and define a typically space-occupying lesion from the paranasal sinus with surrounding bone erosion (eggshell bone erosion) (Figs. 4, 5). MRI is used mainly to identify the relationship of the mucocele with the brain, orbit and soft tissue.

Historically, the recommended treatment for maxillary sinus mucoceles was complete excision through an open approach that involves the Caldwell-Luc sinusotomy, the creation of an inferior naso-antral window, and removal of the mucocele lining¹¹. The endoscopic approach has recently gained popularity¹⁶. Some Authors still express reservations regarding endoscopic treatment of maxillary sinus mucoceles, especially when the mucocele extends outside the sinus into the soft facial tissues: they are concerned that trapping the extra-sinus extension could lead to recurrences¹⁰. The patient with orbital mucocele (Fig. 1) was treated with endoscopic surgery and the Caldwell-Luc approach to evacuate the mucocele contents and create aeration/drainage of the mucocele cavity through a wide middle meatal antrostomy. There was no evidence of recurrence at 24 months' follow-up. The Caldwell-Luc approach was required for mucocele as the medial maxillary sinus wall had been eroded and evacuation using intra-nasal endoscopic surgery did not produce satisfactory results (Fig. 2). Moreover, for fronto-orbital mucoceles, the aim is to completely remove the mucocele lining, to re-establish normal drainage or obliterate the sinus. Some surgeons prefer "open surgery" and this can be performed with an osteoplastic frontal flap, through a coronal incision or an arcuate trans-cutaneous incision over the supero-medial orbital area, known as the Linch approach¹³. For ophthalmic surgeons, the trans-circular approach provides safe access for the management of fronto-ethmoidal mucoceles⁵. Choice of this "open surgery" must be determined by the location and extension of the lesion³. To avoid direct orbital surgery and secondary skin scarring, disinsertion of the medial canthal tendon and possible damage to the lacrimal sac^{3,5} ENT specialists can perform endoscopic sinus surgery with marsupialization of the mucocele into the nose: this improves ophthalmic signs and symptoms associated with mucocele^{4,7,17}. Endoscopic complications, such as medial rectus damage or optic nerve injury, have sometimes been described⁵.

In conclusion, orbital mucoceles can produce a variety of symptoms: some patients, especially those with a history of sinus surgery, chronic sinusitis or headache, may be referred to an ENT specialist. Patients with proptosis, diplopia or the more uncommon manifestations described in this arti-

cle, such as anterior orbital palpable mass, may be referred to an Ophthalmologist. The cases discussed here were initially referred for treatment of ophthalmic symptoms, but CT and MRI evaluation revealed a more extensive diffusion that required multiple surgical interventions, thus patients

need to be fully informed concerning these potential difficulties in the pre-operative period. The collaboration between Ophthalmologists and ENT specialists is fundamental for early diagnosis and treatment of orbital mucoceles to avoid further complications and permanent injury.

References

- ¹ Shields JA, Shields CL. *Orbital cysts of childhood – classification, clinical features, and management*. *Surv Ophthalmol* 2004;49:281-99.
- ² Rootman J, Chang W, Jones D. *Distribution and differential diagnosis of orbital disease*. In: Rootman J, editor. *Disease of the orbit. A multidisciplinary approach*. Philadelphia: Lippincott, Williams and Wilkins; 2003. p. 53-84.
- ³ Schick U, Hassler W. *Neurosurgical management of orbital inflammations and infections*. *Acta Neurochir* 2004;146:571-80.
- ⁴ Khong JJ, Malhotra R, Wormald PJ, Selva D. *Endoscopic sinus surgery for paranasal sinus mucocoele with orbital involvement*. *Eye* 2004;18:877-81.
- ⁵ Wang TJ, Liao SL, Jou JR, Lin LK. *Clinical manifestation of orbital mucocele: the role of Ophthalmologists*. *Jpn J Ophthalmol* 2005;49:239-45.
- ⁶ Batra PS, Citardi MJ, Lanza DC. *Combined endoscopic trephination and endoscopic frontal sinusotomy for management of complex sinus pathology*. *Am J Rhinol* 2005;19:435-41.
- ⁷ Bockmul U, Kratzch B, Benda K, Draf W. *Surgery for paranasal sinus mucocoeles: efficacy of endonasal micro-endoscopic management and long-term results of 185 patients*. *Rhinology* 2006;44:62-7.
- ⁸ Matheny KE, Duncavage JA. *Contemporary indications for the Caldwell-Luc procedure*. *Curr Opin Otolaryngol Head Neck Surg* 2003;11:23-6.
- ⁹ Nerad JA. *Diagnosis and treatment of ectropion*. In: Nerad JA, editor. *Oculoplastic surgery. The requisites in ophthalmology*. St Louis: Mosby; 2001. p. 71-88.
- ¹⁰ Marks SC, Latoni JD, Mathog RH. *Mucoceles of the maxillary sinus*. *Otolaryngol Head Neck Surg* 1997;117:18-21.
- ¹¹ Butugan O, Minoru Takeuti M, Ganz Sanchez T, Rezende de Almeida E, Medicis da Silveira JA, Miniti A. *Maxillary sinus mucocele*. *Rev Laryngol Otol Rhinol* 1996;117:11-3.
- ¹² Busaba NY, Salman SD. *Maxillary sinus mucoceles: clinical presentation and long-term results of endoscopic surgical treatment*. *Laryngoscope* 1999;109:1446-9.
- ¹³ Rinna C, Cassoni A, Ungari C, Tebaldi M, Marianetti TM. *Fronto-Orbital mucoceles: our experience*. *J Craniofac Surg* 2004;15:885-9.
- ¹⁴ Koudstaal MJ, Van der Wal GH, Bijvoet HVC, Vincent AJPE, Poulblon RMI. *Post-trauma mucocele formation in the frontal sinus; a rationale of follow-up*. *Int J Oral Maxillofac Surg* 2004;33:751-4.
- ¹⁵ Johnson LN, Hepler RS, Yee RD, Batzdorf U. *Sphenoid sinus mucocele (anterior clinoid variant) mimicking diabetic ophthalmoplegia and retrobulbar neuritis*. *Am J Ophthalmol* 1986;102:111-5.
- ¹⁶ Benninger MA, Marks S. *The endoscopic management of sphenoid and ethmoid mucoceles with orbital and intranasal extension*. *Rhinology* 1995;33:157-61.
- ¹⁷ Chiu AG, Vaughan WC. *Management of the lateral frontal sinus lesion and the supraorbital cell mucocele*. *Am J Rhinol* 2004;18:83-6.

Received: July 17, 2006 - Accepted: November 15, 2006