

CASE REPORT

Sebaceous lymphadenoma of the parotid gland: report of two cases and review of the literature

Linfoadenoma sebaceo della ghiandola parotide: presentazione di due casi e revisione della letteratura

D. HAYASHI, J.R. TYSOME, E. BOYE¹, P. GLUCKMAN, C. BARBACCIADepartment of Otorhinolaryngology and Head and Neck Surgery; ¹ Department of Histopathology, Medway Maritime Hospital, Gillingham, Kent, UK

SUMMARY

Sebaceous lymphadenoma is an unusual salivary gland neoplasm which is rarely correctly diagnosed pre-operatively in the parotid gland. Two cases of sebaceous lymphadenoma are presented in which, in common with most cases reported in the literature, the correct pre-operative diagnosis was not made. Sebaceous lymphadenoma rarely transforms into a malignant tumour. Fine needle aspiration cytology identifies a benign process in the majority of patients who receive appropriate treatment on this basis. Although an uncommon tumour, it should be taken into consideration in the differential diagnosis of a solitary parotid mass.

KEY WORDS: Parotid gland • Benign tumour • Sebaceous lymphadenoma • Diagnosis • Fine needle aspiration cytology

RIASSUNTO

Il linfoadenoma sebaceo è un'insolita neoplasia delle ghiandole salivari che è raramente diagnosticata pre-operatoriamente, quando localizzata nella ghiandola parotide. Noi presentiamo due casi di linfoadenoma sebaceo nei quali, in accordo con la maggioranza dei casi riportati in letteratura, non era stato possibile eseguire una corretta diagnosi pre-operatoria. Il linfoadenoma sebaceo raramente si trasforma in tumore maligno. L'agoaspirato conferma una neoplasia benigna nella maggioranza dei pazienti che ricevono sulla base di questo dato un adeguato trattamento. Sebbene si tratti di un tumore non comune, dovrebbe essere considerato nella diagnosi differenziale in tutti i casi di nodulo solitario della parotide.

PAROLE CHIAVE: Parotide • Tumori benigni • Linfoadenoma sebaceo • Diagnosi • Citologia da agoaspirato

Acta Otorhinolaryngol Ital 2007;27:144-146

Introduction

Sebaceous differentiation in salivary glands was first described by Hamperl¹ in 1931 and has been reported in 11 to 28% of normal parotid glands^{2,3} and in 6% of normal submandibular glands². Neoplasms of sebaceous derivation, in the major salivary glands, are rare and include sebaceous lymph-adenoma, sebaceous carcinoma, sebaceous adenoma and sebaceous lymph-adenocarcinoma.

Sebaceous lymph-adenoma is a rare, benign tumour of the parotid gland⁴⁻¹⁵. It is characterized histologically by islands of epithelium showing sebaceous differentiation distributed in hyperplastic lymphoid tissue. This tumour must be differentiated from more common benign tumours, although this may be difficult based on fine needle aspiration cytology (FNAC). Two cases of sebaceous lymph-adenoma are described, in which, as with most cases reported in the literature, the correct pre-operative diagnosis was not made.

Case reports

Case 1

A 72-year-old male presented with a 4-week history of a painless swelling in the right upper neck. Physical exami-

nation showed a 2.5 x 1.5 cm firm, non-tender mass in the lower pole of the right parotid gland which was confirmed by ultrasound (US). There was no facial paralysis. FNAC revealed a few lymphocytes, foamy macrophages and an occasional cluster of oncocyctic epithelial cells. No fibrillary or myxoid material was present. Appearances were suggestive of Warthin's tumour. Right superficial parotidectomy was performed without complications and there was no recurrence at 16 months follow-up.

The gross specimen showed a 1.8 x 1.1 cm solid, lobulated tumour with a nodular cream-coloured cut surface (Fig. 1). Microscopically, the tumour was well circumscribed, composed of cords and islands of epithelium with sebaceous differentiation, associated with lymphoid tissue including germinal centres (Fig. 2). The features were those of a benign sebaceous lymph-adenoma.

Case 2

This 57-year-old male presented with a 4-week history of a painless swelling in the left upper neck. Physical examination revealed a 2 x 2 cm firm mass in the tail of the left parotid gland which was confirmed by US. FNAC was inconclusive, but, on clinical and radiological grounds, the most likely diagnosis was thought to be pleomorphic adenoma. A

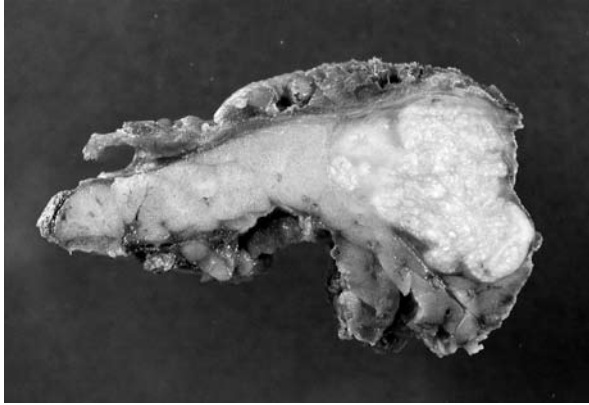


Fig. 1. Gross specimen of sebaceous lymphadenoma of parotid gland.

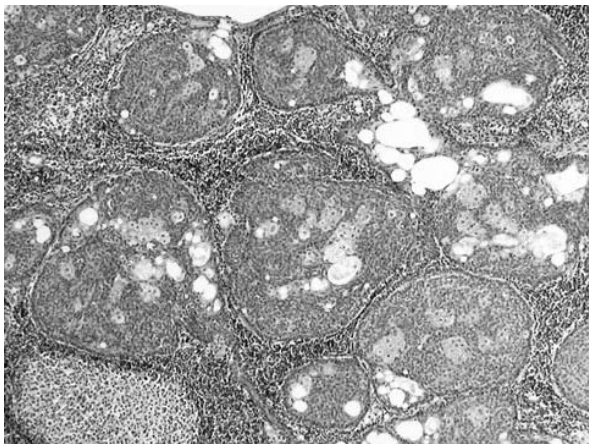


Fig. 2. Sebaceous lymphadenoma showing lymphoid follicles and epithelial tumour (Low power, H&E).

left superficial parotidectomy was performed without complications and there was no recurrence of the tumour at 12 months follow-up.

Macroscopic examination revealed a well-circumscribed tumour measuring 3.5 x 2.5 cm with surrounding fibro-fatty tissue. Microscopy revealed lymphoid tissue with solid and cystic components containing variably sized islands of benign basaloid epithelium showing sebaceous differentiation. The lymphoid tissue showed focal hyperplasia. Cystic spaces were lined by multilayered epithelium including sebaceous and squamous cells. A diagnosis of benign sebaceous lymphadenoma was made.

Discussion

Sebaceous lymphadenoma is a rare benign tumour which is histologically characterized by islands of epithelium showing sebaceous differentiation distributed in hyperplastic lymphoid tissue. Rawson and Horn¹⁶ first described this benign neoplasm in 1950 and the name "sebaceous lymphadenoma" was given by McGavran et al. in 1960¹⁷. The majority of these lesions occur in the parotid glands or periparotid lymph nodes¹⁸.

Sebaceous lymphadenoma of the parotid gland typically presents as a painless mass in patients over 50 years of age. Although it is known to occur equally in both sexes^{10,12} both of our cases were male. Published case reports of sebaceous lymphadenoma do not often give a pre-operative diagnosis. In those cases where a pre-operative diagnosis was made on clinical, radiological or cytological grounds, they are found to be varied (Table I).

Sebaceous lymphadenoma was not correctly identified by pre-operative investigations in the majority of cases. Boyle and Meschter¹², in a single case report, suggested that the FNAC findings in a sebaceous lymphadenoma were dis-

Table I. Examples of case reports with documented pre-operative diagnosis and final diagnosis of sebaceous lymphadenoma of parotid gland.

Pre-operative diagnosis	Age (yrs)/ Sex	Author	Pre-operative investigation	Surgery	Follow-up
Sebaceous lymphadenoma	56/F	Firat et al. (2000)	FNAC & CT scan	Superficial parotidectomy	NER at 12 months
Sebaceous lymphadenoma	75/M	Boyle & Meschter (2004)	FNAC	Excision (unspecified)	Not stated
Warthin's tumour	72/M	Case 1	FNAC	Superficial parotidectomy	NER at 16 months
Pleomorphic adenoma	57/M	Case 2	FNAC	Superficial parotidectomy	NER at 12 months
Pleomorphic adenoma	53/F	Kwon et al. (2002)	CT scan	Superficial parotidectomy	Not stated
Pleomorphic adenoma*	68/F	Shukla & Panicker (2003)	FNAC	Total conservative parotidectomy	Not stated
Acinic cell adenocarcinoma†	78/F	Mayorga et al. (1999)	FNAC	Superficial parotidectomy	NER at 13 months
Mucoepidermoid carcinoma	65/F	Assor (1970)	Needle biopsy (unspecified)	Total parotidectomy	NER at 6 months

* Final diagnosis was synchronous ipsilateral sebaceous lymphadenoma and squamous cell carcinoma

† Final diagnosis was synchronous ipsilateral sebaceous lymphadenoma and acinic cell adenocarcinoma

NER = No evidence of recurrence

tinctive and accurately reflected the histological morphology, although the lesion is so rare that the diagnosis may be easily overlooked. In both of our cases, the FNAC reached did not indicate the correct diagnosis.

Two cases in the literature were diagnosed pre-operatively as pleomorphic adenoma^{11,14}, the most common benign neoplasm of the parotid gland. The clinical presentation of sebaceous lymphadenoma is similar to that of pleomorphic adenoma i.e., a painless parotid swelling with no facial nerve involvement. In the Shukla and Panicker case¹⁴, the true diagnosis was sebaceous lymphadenoma plus concomitant squamous cell carcinoma. One of our cases was thought pre-operatively to be a Warthin's tumour (adenolymphoma), which is the second most common benign parotid neoplasm, again with similar clinical features. Failure to make a correct pre-operative diagnosis of sebaceous lymph-adenoma did not alter the surgical management of these patients as non-urgent surgical excision is required for all these tumours. Malignancy was suspected in two cases. In the Assor case⁵, the pre-operative FNAC suggested mucoepidermoid carcinoma. In the Mayorga et al. case⁹, the sebaceous lymphadenoma was concomitant although the FNAC correctly diagnosed acinic cell adenocarcinoma. On rare occasions, sebaceous lymphadenoma can transform

into sebaceous lymph-adenocarcinoma. This is an extremely rare malignant neoplasm and only four cases have been reported¹⁹. Synchronous occurrences of a sebaceous lymphadenoma with another neoplasm such as Warthin's tumour^{8,13}, acinic cell carcinoma⁹ and squamous cell carcinoma¹⁴ in the same parotid gland have been reported, but they are also rare.

FNAC is a useful technique in evaluating salivary gland lesions pre-operatively. Cytological diagnosis of a benign neoplasm by FNAC has been found to correlate with histological diagnosis of a benign neoplasm following excision in 83% of cases²⁰. Failure to do so may be due to a variety of factors including operator inexperience, sampling error and inadequate samples. In both of our cases, FNAC correctly diagnosed benign tumours. However, when interpreting FNAC from parotid gland masses, these limitations of the procedure should be considered.

Sebaceous lymphadenoma is an unusual salivary gland neoplasm which is rarely correctly diagnosed pre-operatively in the parotid gland. Transformation into a malignant tumour is rare. FNAC identifies a benign process in the majority of patients who receive appropriate treatment on this basis. Although an uncommon tumour, it should be considered in the differential diagnosis of a solitary parotid mass.

References

- Hamperl H. *Beitrage zur normalen und pathologischen Histologie menschlicher Speicheldrusen*. Zeit Mikroskopisch Anat Forschung 1931;27:1-55.
- Linhartova A. *Sebaceous glands in salivary gland tissue*. Arch Pathol 1974;98:320-4.
- Meza-Chavez L. *Sebaceous glands in normal and neoplastic parotid glands: possible significance of sebaceous glands in respect to the origin of tumours of the salivary glands*. Am J Pathol 1949;25:627-45.
- Barton RT. *Lymphoepithelial tumours of the salivary glands: with case report of sebaceous lymphadenoma*. Am Surg 1964;30:411-4.
- Assor D. *Sebaceous lymphadenoma of the parotid gland. A case report*. Am J Clin Path 1970;53:100-3.
- Fleming KA, Morrice I. *Sebaceous lymphadenoma of the parotid gland: a report of a case*. J Path 1973;110:259-61.
- Tschen JA, McGavran MH. *Sebaceous lymphadenoma. Ultrastructural observations and lipid analysis*. Cancer 1979;44:1388-92.
- Gnepp DR, Brannon R. *Sebaceous neoplasms of salivary gland origin. Report of 21 cases*. Cancer 1984;53:2155-70.
- Mayorga M, Fernandez N, Val-Bernal JF. *Synchronous ipsilateral sebaceous lymphadenoma and acinic cell adenocarcinoma of the parotid gland*. Oral Surg Oral Med Oral Pathol Oral Radiol Endod 1999;88:593-6.
- Firat P, Hosal S, Tutar E, Ruacan S. *Sebaceous lymphadenoma of the parotid gland*. J Otolaryngol 2000;29:114-6.
- Kwon GY, Kim EJ, Go JH. *Lymphadenoma arising in the parotid gland: A case report*. Yonsei Med J 2002;43:536-8.
- Boyle JL, Meschter SC. *Fine needle aspiration cytology of a sebaceous lymphadenoma*. Acta Cytol 2004;48:551-4.
- Dreyer T, Battmann A, Silberzahn J, Glanz H, Schulz A. *Unusual differentiation of a combination tumour of the parotid gland. A case report*. Pathol Res Pract 1993;189:577-81.
- Shukla M, Panicker S. *Synchronous sebaceous lymphadenoma with squamous cell carcinoma – case report*. World J Surg Oncol 2003;1:30.
- Batsakis JG, El-Naggar AK. *Pathology consultation: Sebaceous lesions of salivary glands and oral cavity*. Ann Otol Rhinol Laryngol 1990;99:416-8.
- Rawson AJ, Horn RC. *Sebaceous glands containing of the salivary gland*. Surgery 1950;1954:93-101.
- McGavran MH, Bauer WC, Ackerman LV. *Sebaceous lymphadenoma of the parotid salivary gland*. Cancer 1960;13:1185-7.
- Auclair PL, Ellis GL, Gnepp DR. *Sebaceous lymphadenoma*. In: Ellis GL, Auclair PL, Gnepp DR, editors. *Surgical pathology of the salivary glands*. Philadelphia: WB Saunders; 1991. p. 263-8.
- Croitoru CM, Mooney JE, Luna MA. *Sebaceous lymphadenocarcinoma of salivary glands*. Ann Diagn Pathol 2003;7:236-9.
- Cohen EG, Patel SG, Lin O, Boyle JO, Kraus DH, Singh B, et al. *Fine-needle aspiration biopsy of salivary gland lesions in a selected patient population*. Arch Otolaryngol Head Neck Surg 2004;130:773-8.

Received: July 30, 2006 - Accepted: February 20, 2007