

ONCOLOGY

Contact endoscopy of the oral mucosa: preliminary results

Endoscopia per contatto nelle lesioni mucose del cavo orale: risultati preliminari

S. PELUCCHI, C. BIANCHINI, M. TRAVAGLI, A. PASTORE

Department of Medical and Surgical Specialities, Otorhinolaryngology Unit, University of Ferrara, Ferrara, Italy

SUMMARY

Contact endoscopy is a new method for studying diseases of the head and neck mucosa. The present report refers to preliminary results obtained from studies on the oral mucosa in 20 adult patients: 10 affected by benign disorders and 10 controls. This technique is easy to carry out and free of side-effects. Contact endoscopy clearly shows the cell morphology of the mucous membrane and the surface vascular network. The diagnostic reliability, comparable to a histological examination, would make contact endoscopy ideal for screening and monitoring inflammatory lesions or tumours of the oral cavity.

KEY WORDS: Oral cavity • Mucous membrane lesions • Diagnosis • Contact endoscopy

RIASSUNTO

L'endoscopia per contatto è una recente tecnica utilizzata nella valutazione delle lesioni mucose del cavo orale. Riportiamo i dati preliminari ottenuti dallo studio endoscopico della mucosa del cavo orale di venti pazienti adulti: di questi dieci affetti da patologie infiammatorie benigne e dieci casi controllo. Questa metodica, di facile esecuzione e di bassa invasività, permette di evidenziare le caratteristiche cellulari principali, la morfologia cellulare e la rete vascolare sottomucosa. L'endoscopia per contatto, a nostro parere, rappresenta una tecnica diagnostica complementare nello screening e nel monitoraggio delle lesioni infiammatorie e tumorali del cavo orale.

PAROLE CHIAVE: Cavo orale • Lesioni mucose • Diagnosi • Endoscopia per contatto

Acta Otorhinolaryngol Ital 2007;27:59-61

Introduction

Diseases of the mucosal tissue of the upper airways and digestive tracts (UADT) account for high human and social costs, due to frequency. Early diagnosis is, therefore, essential in order to reduce morbidity and mortality. For obvious anatomical reasons, the UADT have been relatively well explored using low-invasive instruments, with good diagnostic sensitivity.

The technological progress with fibre optic systems (especially when connected to digital support) have had a positive impact on the diagnostic-therapeutic process. In the case of tumour or borderline lesions, clinical diagnosis must be followed by histological or cytological examinations. The latter is carried out with brushing, washing, and needle aspiration. These methods, which are more invasive, inevitably result in a longer diagnostic process and increasing costs.

New methods that allow diagnosis in real-time warrant testing on a large number of patients, by many specialists. Contact endoscopy (CE) is one of these techniques. It was derived from microcolpohysteroscopy. In 1989, L'Estrange et al. first applied CE to the oral mucosa¹. Then, in 1995, Andrea et al. from the University of Lisbon applied this method to the larynx and nasal mucosa. Despite the good results obtained by Andrea, CE does not seem to have in-

terested many Authors to date, as few reports on this topic are available²⁻⁶.

In this preliminary report, attention has been focused on normal settings and inflammatory disease of the oral cavity. The pertinent literature is also discussed.

Materials and methods

This study was carried out at the ENT Clinic at the University of Ferrara between January 2005 and October 2005. Overall 20 adult patients were selected; informed written consent was obtained before beginning the procedure. Of these patients, 10 were affected by inflammatory diseases of the oral cavity, while 10 presented normal oral mucosa (case controls). The disorders observed were: leukoplakia (n = 6), erythroplakia (n = 2) and lichen planus (n = 2), all located in the mucosa of the cheek. Conventional endoscopy was performed prior to CE in all cases.

A contact micro-rhinoscope (Karl Storz 7215 BA, Tuttlingen, Germany) diameter 4 mm, length 18 cm, 30° angle was used for contact endoscopy in each case, magnification 60x and 150x (Fig. 1).

The video images were obtained using a 250W cold light, light source (Karl Storz 488, Tuttlingen, Germany) and a Panasonic CD1 micro video camera (Osaka, Japan) for endoscopies. The video recording was made using a VHS




Fig. 1. Contact micro-rhinoscope (Karl Storz 7215 BA): diameter 4 mm, length 18 cm, 30° angle.

system (AKAI VF 440, Tokyo, Japan). The film footage was then digitalised for computer in AVI format, with the images that appeared to be most significant.

After carefully aspirating the secretions, the mucous membrane was stained with methylene blue at a concentration between 1 and 5%, by placing a cotton applicator soaked in the solution, in contact with the surfaces for 5 minutes. The point of the endoscope was delicately positioned on the mucous membrane until the cells of the surface layers of the epithelium were displayed. Since the staining is maintained for at least 4-5 minutes and then gradually disappears, repeated stainings and aspirations were necessary in order to allow prolonged observation of the mucosal layers.

All pathological specimens obtained at CE were confirmed by histopathological examinations, whereas case controls underwent clinical observation for the following 6 months.

Results

Images obtained by CE on healthy mucosa of the cheek were evaluated first.

Micro-vascularization was clearly evident with a dynamic display of endovasal red blood cell flow. The colouring of the cytoplasm showed more hues, especially at higher dilution levels. The cellular patterns of the superficial epithelial layers also appeared clear: it was possible to analyse the nucleus contour, size and shape and also the nucleus-cytoplasm ratio (Fig. 2).

In the leukoplakia lesions, we observed a mucosal hyperkeratotic thickening with a particular cell morphology: more nuclei per campus of different size, colour and shape

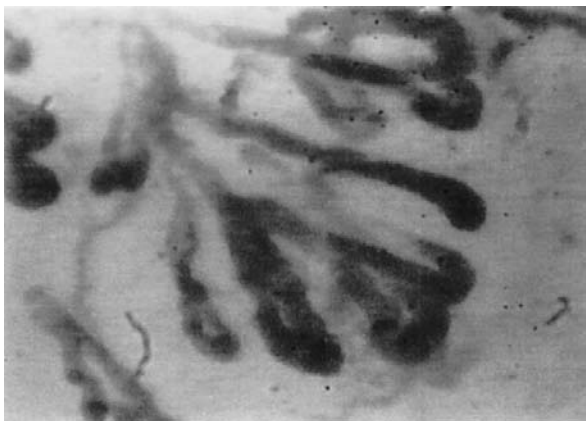

Fig. 2. Epithelium cells pattern in normal mucosa, 150X.

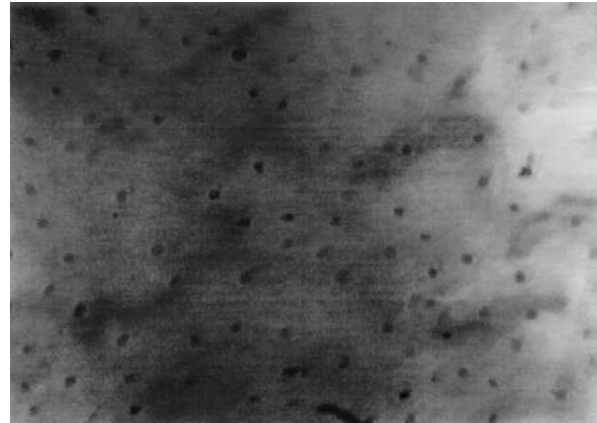


Fig. 3. More nuclei per campus in leukoplakia, 150X.

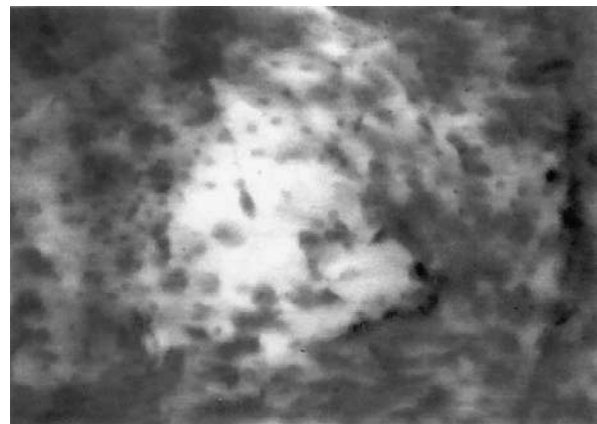


Fig. 4. Sub-mucosal venous network in erithroplakia, 150X.

(Fig. 3). Within the erithroplakia lesions, alterations of the microvascular network were present, such as increased number of anastomoses, spiral vessels and ectasias, without cellular atypia or rare mitosis (Fig. 4).

Instead, an inflammatory lymphocyte infiltrate was observed in the lichen planus lesion.

None of the patients presented side-effects that could be attributed to endoscopic manoeuvres or the use of staining dyes, furthermore, there were no cases of micro haemorrhage.

Discussion

CE is a recent diagnostic technique tested for head and neck screening and for monitoring pathological conditions thereof. Its principal characteristic lies in the "live" evaluation of the cellular patterns of the epithelial layers and the sub-mucosal microvascular network¹⁻⁷.

In the first instance, the application of CE in evaluating the oral mucosa aroused the interest of a workgroup of Australian odontologists, led by L'Estrange, who studied the oral cavity⁶. They showed, in fact, the possibility, offered by CE, of identifying the principal characteristics of cells and especially the appearance of nuclei with low invasivity and the absence of side-effects related to the manoeuvre itself and colouring⁶.

Andrea et al., in 1994, applied this technique to the larynx. During laryngomicroscopy, they observed, using CE, the ap-

pearance of superficial layers of vocal folds in 68 patients and then attempted to diagnose laryngeal disorders (benign, pre-malignant and malignant lesions), reporting also the results of histopathological studies¹⁻⁴. In 1997, these same Authors tested CE on the nasal mucosa, evaluating inflammatory diseases (for example, chronic sinusitis) and neoplastic lesions. They observed nuclei of increased size, a high nucleus/cytoplasm ratio, inflammatory infiltrates (neutrophils, lymphocytes and eosinophilia), hyaline and nuclear anomalies⁵. An analysis of the sub-mucosal vascular network has also been reported in which the size and appearance of the vessels may be useful in the diagnosis of malignancy⁵.

In 2000, also Carriero et al. studied the laryngeal epithelium using CE. They found this technique useful in the study and diagnosis of inflammatory lesions of the vocal folds in 18 patients, presenting, for example, Reinke's oedema, leukoplakia and papilloma, as well as carcinoma in situ⁶.

Wardrop et al. employed CE in 8 consecutive patients who underwent bioptic microlaryngoscopy with collection of biopsy specimens, comparing the endoscopic view with the histologic report. In 6 patients (2 of whom with carcinoma in situ), histology confirmed the endoscopic diagnosis. These Authors suggest that CE could be used, in the future, for the monitoring of dysplastic and neoplastic laryngeal diseases⁸.

Negoro et al. used CE together with video-microscopy to observe tongue papillae, studying the correlation between the appearance of fungiform papillae and taste function. Patients with taste disorders tended to show flat papillae and a poor vascular network of papillae⁹.

One limit related to this method concerns the use of a stain. In fact, methylene blue, on account of its poor penetration in the deeper layers, permits the evaluation only of the upper mucosal surface. Therefore, disorders such as cysts or nodules located in the sub-mucosal layers and any deep

tumoural infiltration cannot be fully described. For this reason, it is difficult, at times, to decide whether the image obtained is sufficiently diagnostic. Close collaboration with the pathologist is, therefore, clearly necessary.

Further disadvantages related to this technique include the difficulties sometimes experienced, by the operator, in positioning the endoscope on the mucosal surface (particularly when using 150x magnification) and in obtaining homogeneous staining of the mucosal surface, especially in localizations with physiological clearance, such as, for example, the oral cavity and nasal mucosa⁸.

We found CE easy to perform and free from side-effects, a good correlation being observed between the findings of the traditional biopsies and CE images.

Conclusion

In accordance with the literature, we consider CE relatively simple to perform, with low invasiveness and without side-effects. This technique permits good evaluation "in vivo" of the head and neck mucosal surface clearly showing the cell morphology of the mucous membrane and the vascular surface network.

At present, CE does not provide information about cells in the basal and near-basal layers of the epithelium on account of the poor penetration of blue methylene. Therefore, its usefulness in histopathological and cytological diagnosis appears to need further investigation, with a large number of patients and using other types of staining. This, would probably increase the sensitivity of the technique.

If the diagnostic reliability is confirmed, CE would, in fact, become an ideal tool for screening and monitoring inflammatory diseases and the suspected development of dysplastic lesions, not only in the oral cavity, but also in other ENT districts.

References

- 1 L'Estrange P, Bevenius J, Williams L. *Intraoral application of microlaryngoscopy. A new technique for clinical examination of oral tissues at high magnification*. Oral Surg Oral Med Oral Pathol 1989;67:282-5.
- 2 Andrea M, Dias O, Santos A. *Contact endoscopy during microlaryngeal surgery. A new technique for endoscopic examination of the larynx*. Ann Otol Rhinol Laryngol 1995;104:333-9.
- 3 Andrea M, Dias O, Santos A. *Contact endoscopy of the vocal cord. Normal and pathological patterns*. Acta Otolaryngol (Stockh) 1995;115:314-6.
- 4 Andrea M, Dias O. *Rigid and contact endoscopy associated to microlaryngeal surgery*. In: Fried M, editor. *The larynx: a multidisciplinary approach, 2nd edn*. New York: Mosby Year Book; 1995.
- 5 Andrea M, Dias O. *Atlas of rigid and contact endoscopy in microlaryngeal surgery*. Philadelphia: Lippincott-Raven Publishers; 1995.
- 6 Andrea M, Dias O, Macor C, Santos A. *Contact endoscopy of the nasal mucosa*. Acta Otolaryngol (Stockh) 1997;117:307-11.
- 7 Carriero E, Galli J, Fadda G, Di Girolamo S, Ottaviani F, Paludetti G. *Preliminary experiences with contact endoscopy of the larynx*. Eur Arch Otorhinolaryngol 2000;257:68-71.
- 8 Wardrop PJ, Sim S, McLaren K. *Contact endoscopy of the larynx: a quantitative study*. J Laryngol Otol 2000;114:437-40.
- 9 Negro A, Umamoto M, Fukazawa K, Terada T, Sakagami M. *Observation of tongue papillae by video microscopy and contact endoscopy to investigate their correlation with taste function*. Auris Nasus Larynx 2004;31:255-9.

Received: February 22, 2006 - Accepted: December 4, 2006