

## CASE REPORT

# Pneumocephalus and meningitis as a complication of acute otitis media: case report

## *Pneumoencefalo e meningite come complicanza di otite media acuta: caso clinico*

A. CIORBA, A. BERTO, M. BORGONZONI, D.L. GRASSO, A. MARTINI  
Audiology Department, University Hospital of Ferrara, Ferrara, Italy

## SUMMARY

Otogenic pneumocephalus is a rare condition. The case is described of pneumocephalus and meningitis secondary to acute otitis media. Although the rate of intracranial complications related to middle ear disease is only 0.5 to 4%, mortality still ranges between 5 and 15%.

KEY WORDS: Otitis media • Complication • Pneumocephalus • Meningitis • Endocranial hypertension

## RIASSUNTO

*Il pneumoencefalo otogeno è una condizione patologica di raro riscontro. Gli Autori presentano un caso di pneumoencefalo e meningite come complicanza di otite media acuta. Sebbene la percentuale di complicanze endocraniche dell'otite media acuta sia dello 0,5-4%, il tasso di mortalità è ancora elevato e compreso tra il 5 ed il 15%.*

PAROLE CHIAVE: *Otite media • Complicazioni • Pneumoencefalo • Meningite • Ipertensione endocranica*

Acta Otorhinolaryngol Ital 2007;27:87-89

### Case report

A 32-year-old male was admitted, in September 2002, to the Audiology Department at the University Hospital of Ferrara with a 4-day history of left otalgia, headache and fever (38 °C). Otoscopic examination showed purulent otorrhea in the left external meatus and the left tympanic membrane was slightly hyperaemic, but no swelling or tenderness were noted in the external auditory meatus or in the retroauricular area. There was also no evidence of neurological

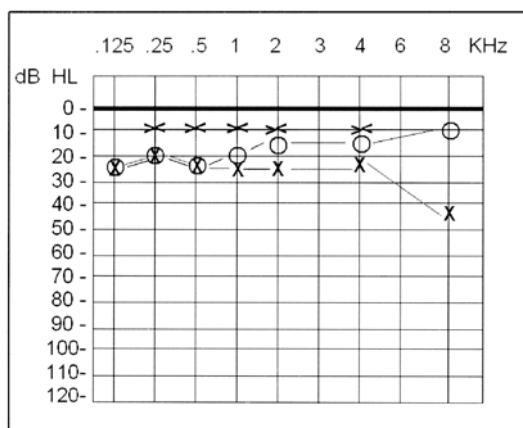


Fig. 1. Mild left conductive hearing loss can be observed at pure tonal audiogram.

impairment and no significant medical history. Audiometry revealed a mild left conductive hearing loss (Fig. 1).

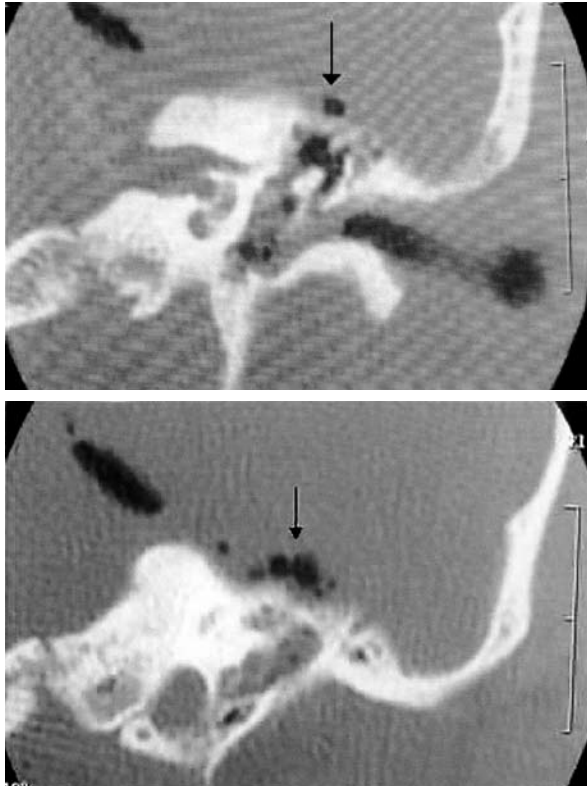
Staphylococcus aureus was isolated at microbiological investigation.

After 24 hours, the patient developed lethargy, aphasia and rigor nuchalis. Blood cell count showed leukocytosis (25,000) and neutrophilia (93.0%). Temperature reached 39.3°C. Cerebro-spinal fluid (CSF) analysis disclosed increased levels of total proteins (178 mg/dl), leukocytosis (220/mm<sup>3</sup>) and normal liquor pressure. High resolution computed tomography (Fig. 2 A and B) showed soft tissue involving the middle ear, the ossicular chain and the left mastoid, with intracranial air adjacent to the tentorium, but no signs of tegmen erosion or interruption. Cerebral magnetic resonance imaging (MRI) (Fig. 3) confirmed the presence of soft tissue in the middle ear and in the left mastoid cells with enhancement of the left tentorium.

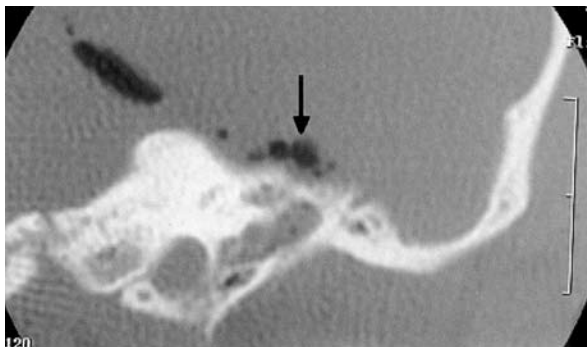These findings suggested the diagnosis of otogenic pneumocephalus and meningitis.

Medical treatment was established with ceftriaxone 2 g i.v./day, vancomycin 500 mg i.v. for 4 days, meropenem 1 g i.v./8 h, and dexamethazone 2 ml i.m./8 h.

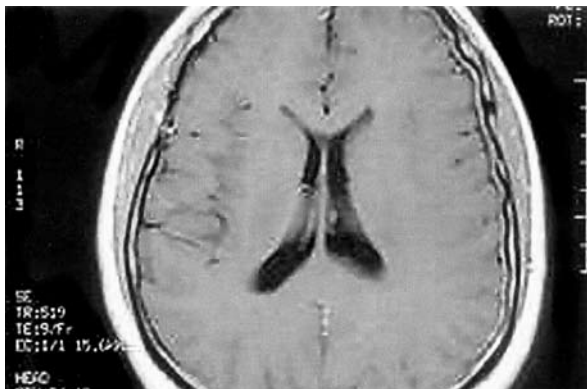
After 48 hours of medical treatment the patient's clinical status improved; after one week, the spinal fluid analysis was negative for inflammatory parameters, while the cerebral MRI showed only a mild residual enhancement of the left tentorium, with no further evidence of intra-cranial air. Once the medical therapy was



**Fig. 2 A, B.** CT scans show soft tissue density involving middle ear and ossicular chain, with intracranial air adjacent to tentorium (arrows).



**Fig. 3.** MRI: enhancement of left tentorium.



**Fig. 4.** Normal MRI with increased level of liquor pressure, but no signs of herniation.

completed, the patient was discharged with a follow-up programme.

Ten days later, he was readmitted due to diplopia caused by bilateral papilledema. Endocranial hypertension was suspected and a spinal fluid analysis was performed. Mild increased levels of liquor pressure (40 cm H<sub>2</sub>O) were found, while the cerebral MRI was normal (no signs of herniation) (Fig. 4). The patient was treated with glycerol 10%, 250 cc i.v./day for 5 days.

One month after discharge, the patient developed two seizure episodes and a left sixth cranial nerve palsy; a new cerebral MRI was promptly performed, which was negative. The clinical picture improved within one week.

At present, 30 months later, the patient is still in follow-up, and shows a normal clinical picture.

## Discussion

Despite the tremendous advances made in the treatment of all forms of otitis media, complications still occur and often represent the most life-threatening conditions, requiring immediate and precise therapeutic intervention. Otogenic infections rarely cause pneumocephalus.

Chiari (1884) was the first to diagnose, post-mortem, pneumocephalus, in a patient affected by ethmoiditis; Dandy (1926) was the first to report the case of otogenic pneumocephalus<sup>1</sup>.

At present, the reported rate of intracranial complications related to middle ear diseases ranges from 0.5 to 4% (2, 8), and even if antibiotics have substantially decreased the mortality rate associated with acute otitis media (AOM) complications, the overall mortality still ranges between 5-15%<sup>2-5</sup>.

According to a review of the literature by Andrews JC, et al.<sup>1</sup>, otogenic pneumocephalus is a consequence of head trauma in 36% of the reported cases, of otological infection in 30%, of mastoid procedure in 30%, idiopathic in 3%<sup>1</sup>.

The physio-pathologic mechanism that can explain the genesis of pneumocephalus is a break between the middle ear and either middle or posterior cranial fossa, which allows air to enter. In addition, an increase in middle ear pressure over the intra-cranial pressure must be present to permit air to enter the cranium. This may be explained by two mechanisms:

- air enters the middle ear through the Eustachian tube as nasopharyngeal pressure rises above ambient pressure during swallowing, Valsalva manoeuvre, or other conditions. Air can enter the cranium even through a middle ear micro-fistula<sup>1</sup>;
- another mechanism requires the presence of a continuous cerebrospinal fluid (CSF) leak, which results in the development of a relatively negative intra-cranial pressure, allowing the loss of fluid to be replaced by air<sup>1</sup>.

However, during the course of AOM, the pathogenesis of OP may involve the intra-cranial collection of gas, secondary to the spread of the infection, caused by gas-forming micro-organisms that may co-exist in the otogenic foci<sup>5,6</sup>. This can occur via haematogenous dissemination, even in the absence of an obvious communication between the middle ear and either the middle or posterior cranial fossa<sup>1</sup>. It has been reported that small blood vessels connect the vascular networks of the temporal bone, the dura and the venous sinuses and that direct vascular connections exist between the mucoperiosteum of the middle ear and the dura<sup>6</sup>.

Thus, considering that no signs of tegmen erosion were found in our case, and that the haematogenous dissemination is considered as one of the pathogenic mechanisms for the development of AOM complications<sup>7</sup>, this second pathway, in our opinion, seeded the infection.

In the clinical picture of otogenic pneumocephalus and meningitis, headache is one of the earliest symptoms, together with fever. Vomiting may be present, as well as agitation and irritability. Rigor nuchalis is another early sign, as well as lethargy and poor oral intake. Signs of increased endocranial pressure can also include papilledema and cranial nerve palsies<sup>8</sup>. As the disease progresses and the dura becomes involved, headache becomes intolerable, photophobia may appear and fever continues to rise. Neurological deficits, alteration in consciousness and coma may follow if treatment is not promptly established.

Otologic symptoms are frequently present, and may include otorrhea, post-auricular oedema and otalgia.

Prompt diagnosis is mandatory.

Early examination of the cerebrospinal fluid reveals the severity of the meningeal involvement and can provide cultures to guide the selection of antibiotics.

CT scans are fundamental to evaluate the ear bone architecture, and to exclude interruptions in the tegmen, especially when OP is a consequence of head trauma. In cases of otogenic infections, CT and MRI may reveal the presence of tegmen erosion, epidural abscess, cerebritis, brain abscesses, or large subdural collections requiring prompt surgical drainage.

Treatment of pneumocephalus depends on its aetiology. Surgical management of otogenic pneumocephalus is mandatory when it is the consequence of an head trauma or after an otoneurologic procedure. This can usually be performed

through an otologic approach; once the defect is identified and has been located, cartilage, free fascia, or temporalis muscle-fascia flap are best used to plug the site, depending on its size<sup>1</sup>.

When secondary to AOM with meningeal involvement, control of the infection is necessary and medical therapy is of great value, especially in the absence of a clear tegmen defect. The finding of multiple bacterial growth, reported by some authors, seems to justify the choice of a wide-spectrum antibiotic treatment, also directed to gram-negative micro-organisms<sup>2</sup>. Recommendations for the management of otogenic meningitis with pneumocephalus include a third-generation cephalosporin, either intravenous cefotaxime (75 mg/kg every 6 hrs) or ceftriaxone (50 mg/kg every 6 hrs), and vancomycin (15 mg/kg every 6 h). The need to add vancomycin to the therapeutic regimen is a consequence of the escalating prevalence of strains of germs resistant to penicillin and cephalosporins. Adding rifampin (20 mg/kg as a single daily dose, i.v.) or meropenem (40 mg/kg every 8 h) may be taken into consideration<sup>2,7</sup>. The usefulness of adding dexamethazone to the therapeutic regimen has been controversial; patients receiving steroids have been shown to have a 50% reduction of neurological sequelae, without improvement regarding the audiological outcome<sup>7</sup>.

## Conclusions

Intra-cranial complications of otitis media still occur and should be considered high-risk conditions that require prompt intervention. Multidisciplinary team support is also highly recommended. Pneumocephalus, secondary to otogenic meningitis, is a very rare condition.

## References

- Andrews JC, Rinaldo RF. *Otogenic Pneumocephalus*. Laryngoscope 1986;96:521-8.
- De Oliveira Penido N, Borin A, Iha LC, Suguri VM, Onishi E, Fukuda Y, et al. *Intracranial complications of otitis media: 15 years of experience in 33 patients*. Otolaryngol Head Neck Surg 2005;132:38-42.
- Felisati G, Di Berardino F, Maccari A, Sambataro G. *Rapid evolution of acute mastoiditis: three case reports of otogenic meningitis in adults*. Am J Otolaryngol 2004;25:442-6.
- Barry B, Delattre J, Viè F, Bedos JP, Gèhanno P. *Otogenic intracranial infections in adults*. Laryngoscope 1999;109:483-7.
- Turgut S, Ercan I, Alkan Z, Cakir B. *A case of pneumocephalus as a complication of silent otitis media*. Ear Nose Throat J 2004;83:50-2.
- Nager GT. *Pathology of the temporal bone*. Baltimore: Williams and Wilkins; 1993. p. 262-3.
- Alper CM, Bluestone CD, Casselbrant ML, Dohar JE, Mandel EM. *Advanced therapy of otitis media*. Hamilton-London: BC Decker; 2004. p. 374-8.
- Fessler RD, Sobel J, Guyot L, Crane L, Vazquez J, Szuba MJ, et al. *Management of elevated intracranial pressure in patients with cryptococcal meningitis*. J Acquir Immune Defic Syndr Hum Retrovirol 1998;17:137-42.
- Kangsanarak J, Fooanant S, Ruckphaopunt K, Navacharoen N, Teotrakul S. *Extracranial and intracranial complications of suppurative otitis media: report of 102 cases*. J Laryngol Otol 1993;107:999-1004.
- De Gans JD, van de Beek D. *Dexamethazone in adults with bacterial meningitis*. NEJM 2002;347:1549-56.

Received: October 9, 2005 - Accepted: January 19, 2006

Address for correspondence:

Prof. A. Martini, Cattedra e U.O. di Audiologia, Azienda Ospedaliero-Universitaria di Ferrara, corso Giovecca 203, 44100 Ferrara, Italy. Fax +39 0532 236887. E-mail: alessandro.martini@unife.it