

Long-surviving case of adenosquamous carcinoma of the larynx: case report and review of literature

Carcinoma adenosquamoso della laringe a lunga sopravvivenza: caso clinico e revisione della letteratura

P. PASSON, G. TESSITORI¹, M. LOMBARDO, S. CALLEA, P. POLI

Department of Surgery, Otolaryngology Section; ¹ Department of Pathology, Regione Friuli, ASS 6, Civic Hospital of San Vito al Tagliamento (PN), Italy

Key words

Larynx • Malignant tumours • Adenosquamous carcinoma • Therapy

Parole chiave

Laringe • Tumori maligni • Carcinoma adenosquamoso • Terapia

Summary

A singularly long-surviving (15 years) disease-free case of a stage II adenosquamous carcinoma of the larynx is described. A review of the literature reveals that prognosis of this aggressive malignant neoplasm is poor (mean 2-3 years free of disease) on account of local recurrences, early cervical lymph node metastasis and distant dissemination. This long survival rate emphasises the importance of early radical surgical treatment and the choice of total laryngectomy with neck dissection in stage II laryngeal neoplasm.

Riassunto

Nel presente lavoro viene descritto il caso clinico di un paziente affetto da carcinoma adenosquamoso della laringe diagnosticato al II stadio e che dopo 15 anni dal trattamento è ancora libero da malattia. Dall'analisi della letteratura si evidenzia come la prognosi di questa neoplasia altamente aggressiva sia scarsa (la media è 2-3 anni liberi da malattia) in quanto tende a dare frequenti recidive locali, precoci metastasi linfonodali ed ematogene a distanza. La lunga e singolare sopravvivenza del nostro paziente enfatizza l'importanza di un tempestivo trattamento chirurgico radicale quale può essere una laringectomia totale con svuotamento linfonodale latero-cervicale in una neoplasia laringea al II stadio d'esordio.

Introduction

Adenosquamous carcinoma (ASC) of the larynx is a very rare tumour of the upper aerodigestive tract which has well defined histopathological features. A review of the literature reveals that ACS is an aggressive malignant neoplasm characterized by local recurrences, early cervical lymph node metastasis and distant dissemination. Prognosis is poor with a 3-year survival rate of 50%. The recommended treatment of choice is surgical excision with neck dissection. Reviewing the various clinical cases in the literature, only one case of ASC of the tongue was reported with a 10-year disease-free survival. Not one case of ASC of the larynx, which accounts for 50% of the upper aerodigestive tract site of origin, reached this survival rate. The mean survival rate free of ASC disease, at this site, according to the literature, is approximately 2-3 years.

The present report refers to a singular case of ASC of the larynx treated 15 years ago with total laryngectomy and selective neck dissection that, at the present time, is still free of disease.

Case report

In 1988, a 56-year-old male presented a 4-month history of hoarseness without dysphagia. Previous medical history did not reveal any chronic diseases. The patient smoked 15 cigarettes per day, reported a moderate intake of alcohol and no cancer familiarity.

Indirect laryngoscopy showed a mass on the left false cord and impaired mobility of the ipsilateral true cord. No associated cervical lymphadenopathy was detected.

Direct microlaryngoscopy revealed a smooth reddish swelling involving the entire left false cord and the ipsilateral medial arytenoid surface. Glottidis was not involved by the mass. Biopsy results referred to adenosquamous carcinoma. With no clinical or instrumental evidence of regional or distant metastasis, the tumour was classified as stage II (T2, N0, M0) and total laryngectomy and ipsilateral selective neck dissection (level I-V) were carried out. The subsequent histological examination confirmed macroscopically the supraglottic site of origin with also ipsilateral ventricle involvement. Microscopically, the tu-



Fig. 1. Squamous differentiation of neoplasm (H&E; X100).

mour consisted (70%) of a moderately differentiated squamous cell carcinoma (Fig. 1) and of moderately differentiated glandular proliferation with foci of squamous cell proliferation (30%) (Fig. 2). The examination of cervical lymph nodes was negative. No post-operative complications occurred.

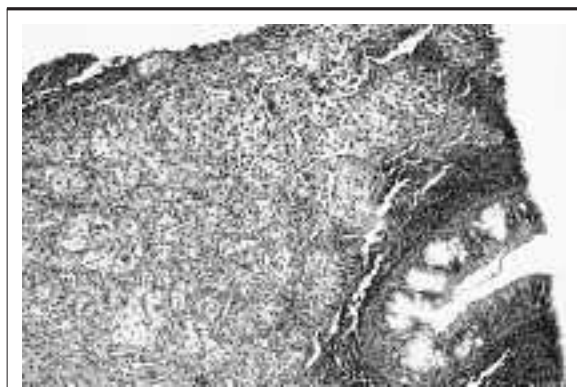


Fig. 2. Glandular differentiation of neoplasm with foci of squamous cell proliferation (H&E; X100).

The patient has been observed regularly since treatment and, at present (15-year follow-up) remains free of disease. Recently, a pathologist carefully examined the histological specimens and, agreeing with his former colleague, confirmed the initial diagnosis.

Discussion

Adenosquamous carcinoma (ASC) of the larynx is a rare neoplasm characterized by two distinct malignant

components, squamous and glandular, respectively, having a common histogenesis¹. This lesion originates from the ductal system of the submucosal glands². Albeit, some authors suggest a combined glandular and squamous epithelium origin³, others the mucosal epithelium alone⁴.

ASC is more common in males (2-4:1) with a high incidence in the 5th-6th decade of life. The larynx is the most common site of origin (almost 50%) of the upper aero-digestive tract with supraglottitis as the preferred subsite. The other sites of origin are oral cavity and oropharynx (40%), hypopharynx (8%), nose and nasopharynx (2%)⁵.

The differential diagnosis includes adenoid squamous cell carcinoma (ADSC), basaloid squamous carcinoma (BSC), mucoepidermoid carcinoma (MEC) and conventional squamous cell carcinoma (SCC).

ADSC is characterized by acantholysis (gland-like space), negative for mucin and carcinoembryonic antigen, and by better prognosis⁶.

In BSC, the squamous differentiation is accompanied by the presence of clusters of basaloid cells without a glandular malignant component⁷.

MEC is characterized by inseparable glandular and squamous malignant elements and, unlike ASC, without abnormalities of the surface epithelium⁸. Reports in the literature refer to a better prognosis in these cases.

Conventional SCC infiltrating the muco-serous glands whilst maintaining the normal lobular architecture of the gland may be confused with ASC in small biopsies. The correct diagnosis of ASC is based on the presence of separate foci of adenocarcinoma, which are clearly visible if the specimen is large enough⁵.

ASC is an aggressive neoplasm characterized by early lymph-node metastasis, local recurrence, distant metastases, with the lung as the most common site, and poor long-term prognosis².

Keelawat et al.⁵, in their clinical series, found that the 3-, 5- and 10-year survival rates were 50%, 20% and 0% respectively, with 40% of the patients dying of the disease after a mean follow-up period of 30 months. In the review of the literature made by these authors, the 3-, 5- and 10-year survival rates were 32%, 13% and 4.5% respectively, with almost 43% of patients dying of the disease after a mean follow-up period of 25 months⁵. Only one patient, with ASC of the tongue, survived more than 10 years and died of metastatic disease, 15 years after diagnosis². However, none of the patients with ASC of the larynx, in either the series of Gerughty or that of Keelawat, had a survival rate > 3 years.

As far as concerns the factors affecting such poor prognosis, the Authors attempted to find correlations between stage of disease and outcome. The results re-

vealed that the higher the stage, the worse the prognosis, which means better prognosis in stages I and II and worse in stages III and IV^{5,9}. If this were true for Gerughty's and our long-surviving patients (stage I and II, respectively), it is a contradiction in Keelawat's case of ASC of the palate, with a long survival rate and high stage of presentation (stage IV). The only feature that these 3 long-term survival cases have in common is the absence of node metastases at the time of diagnosis. Thus node status (N) appears to be the main factor affecting prognosis. It is still unknown whether the glandular or squamous composition of the tumour can influence its behaviour.

There is, instead, general agreement about the treatment of choice, that is radical surgery with neck dissection, even in the absence of clinical node metastases. Indeed, Keelawat et al., studying the case histo-

ries of their own 12 patients together with the 46 described in the literature, compare the survival rate of the patients treated only surgically with that of patients submitted to adjuvant radio-chemotherapy and surgery. Apart from rare exceptions, the results of the latter treatment do not show any advantage compared to surgical treatment alone since the two survival rates are similar. The long-term survival rate of our patient who is free of disease (15 years) justifies the choice of total laryngectomy and selective neck dissection in a stage II laryngeal neoplasm. Obviously, the small number of cases does not permit thorough studies on a standardized therapeutical protocol.

We believe, therefore, that our personal experience provides a further contribution to the clinical and therapeutic approach of this uncommon and controversial neoplasm of the upper aero-digestive tract.

References

- ¹ Ferlito A. A pathologic and clinical study of adenosquamous carcinoma of the larynx. Report of four cases and review of the literature. *Acta Otorhinolaryngol Belg* 1976;30:379-89.
- ² Gerughty RM, Hennigar GR, Brown FM. Adenosquamous carcinoma of the nasal, oral and laryngeal cavities: a clinicopathologic survey of ten cases. *Cancer* 1968;22:1140-55.
- ³ Ellis GL, Auclair PL, Gnepp DR. Other malignant epithelial neoplasms. In: Ellis GL, Auclair PL, Gnepp DR, editors. *Surgical pathology of the salivary glands*. Philadelphia, PA: Saunders; 1991. p. 455-88.
- ⁴ Napier SS, Gormely JS, Newlands C, Ramsay-Baggs P. Adenosquamous carcinoma: a rare neoplasm with aggressive course. *Oral Surg Oral Med Oral Pathol Oral Radiol Endod* 1995;79:607-11.
- ⁵ Keelawat S, Liu CZ, Roehm PC, Barnes L. Adenosquamous carcinoma of the upper aerodigestive tract: a clinicopathologic study of 12 cases and review of the literature. *Am J Otolaryngol* 2002;23:160-8.
- ⁶ Ferlito A, Devaney KO, Rinaldo A, Milroy CM, Carbone A. Mucosal adenoid squamous cell carcinoma of the head and neck. *Ann Otol Rhinol Laryngol* 1996;105:409-13.
- ⁷ Izumi K, Nakajima T, Maeda T, Cheng J, Saku T. Adenosquamous carcinoma of the tongue: report of a case with histochemical, immunohistochemical and ultrastructural study and review of the literature. *Oral Surg Oral Med Oral Pathol Oral Radiol Endod* 1998;85:178-84.
- ⁸ Spiro RH, Huvos AC, Berk R. Mucoepidermoid carcinoma of salivary gland origin: a clinicopathologic study of 367 cases. *Am J Surg* 1978;136:461-8.
- ⁹ Damiani JM, Damiani KK, Hauck K, Hyams VJ. Mucoepidermoid adenosquamous carcinoma of the larynx and hypopharynx: a report of 21 cases and a review of the literature. *Otolaryngol Head Neck Surg* 1981;89:235-43.

■ Received: March 15, 2004
Accepted: May 17, 2005

■ Address for correspondence: Dr. P. Passon, Dipartimento Chirurgico, SOC di Otorinolaringoiatria, Ospedale Civile, via Savorgnano 2, 33078 San Vito al Tagliamento (PN), Italy - Fax +39 0434 841262 - E-mail: paolo.passon@ass6.sanita.fvg.it