

## TEACHING CASE

# Schwannoma of thyroid bed. A case report and considerations on interdisciplinary collaboration

## *Schwannoma della regione tiroidea. Caso clinico e riflessioni sulla collaborazione interdisciplinare*

F. DE PAOLI, G. GIUGLIANO, C. CASADIO<sup>1</sup>, P. TREDICI, R. BRUSCHINI, E. DE FIORI<sup>2</sup>  
 Head and Neck Surgery Division; <sup>1</sup> Department of Radiology; <sup>2</sup> Department of Histology and Pathology,  
 European Institute of Oncology, Milan, Italy

## Key words

Thyroid gland • Schwannoma • Thyroidectomy • Fine-needle aspiration biopsy

## Parole chiave

Tiroide • Schwannoma • Tiroidectomia • Esame citologico

## Summary

Schwannoma of the thyroid bed is extremely rare, but is known to simulate a thyroid nodule. A retrospective review is reported of a 64-year-old female patient with a thyroid nodule who had been submitted to pre-operative fine-needle aspiration biopsy, judged inadequate, following which total thyroidectomy was performed. On histological examination, the nodule (in the thyroid bed) was found to be a schwannoma. This case report stresses the importance of interdisciplinary collaboration. Better co-operation between surgeon, pathologist and radiologist may have led to correct pre-operative diagnosis with sparing of at least half the thyroid.

## Riassunto

*Gli schwannomi della regione tiroidea sono molto rari, in genere simulano un molto più frequente nodulo tiroideo. Nel caso clinico presentato, il paziente è stato sottoposto a tiroidectomia totale dopo FNAB giudicati inadeguati ai fini della diagnosi. L'esame istologico (e la revisione degli esami citologici) ha deposto per uno schwannoma. Questo caso clinico sottolinea l'importanza della collaborazione fra chirurgo, anatomo-patologo e radiologo.*

## Introduction

Schwannomas of the thyroid bed are rare<sup>1-5</sup>. Only 18 cases have been described in the English language literature, most of which simulated a thyroid nodule<sup>6-10</sup>. The case is described of a thyroid bed schwannoma discovered after total thyroidectomy. Interdisciplinary collaboration may have led to the correct diagnosis pre-operatively<sup>4,5</sup>.

## Case report

A 63-year-old female presented, in 2002, with a nodule in the thyroid region and complained that on swallowing she felt as if there was a foreign body in her throat.

### CASE HISTORY

In 1986, a benign nodule had been surgically removed from the right lobe of the thyroid gland, at another hospital. Since then the patient had been receiving levo-thyroxin. Recent laboratory tests had shown the patient to be euthyroid. Ultrasonography

(US) of the neck, elsewhere, in 2001, revealed a markedly hypoechogenic nodule, 2.7 cm in diameter, in the lower third of the previously operated thyroid. A subsequent US-Doppler investigation had shown rich vascularisation within, and surrounding, the lesion, and no alteration of the left thyroid lobe. Fine-needle aspiration biopsy (FNAB) had been performed by the radiologist during US-Doppler and the specimen had been sent for pathological examination. The cytological report referred to "fragments of adipose tissue, rare thymocytes in aggregates resembling follicular masses, insufficient for diagnosis".

### PHYSICAL EXAMINATION

On examination, a painless hard elastic nodule, about 3 cm in diameter, was detected in the right lobe of the thyroid. The nodule was mobile upon swallowing. No cervical nodes were observed. Laryngoscopy confirmed that motility of the vocal cords was normal.

*Ultrasonography* examination was again performed which revealed that the sonographic characteristics of the lesion were unchanged compared with the previous examination although the nodule had increased in size (3.2 cm in diameter). A new US-guided FNAB

was performed and the tissue sent for cytological examination with the clinical diagnosis of "thyroid nodule". The material was again considered insufficient for diagnosis.

#### TREATMENT

The nodule was symptomatic and increasing in size, but a diagnosis was lacking. It was decided to carry out a right hemi-thyroidectomy, intending to perform an intra-operative frozen section examination which would indicate whether total thyroidectomy was necessary. During surgery, a yellowish lesion (3 cm in diameter) with irregular outline, which appeared impossible to separate from the right thyroid lobe, was revealed by displacing the lobe medially (Fig. 1). The lesion was positioned between the first and second tracheal rings and part of the lesion had pushed the rings apart to protrude into the tracheal lumen with the membrane between the rings still intact, but closely adhering to the nodule. These macroscopic characteristics suggested an advanced stage of malignancy and it was, therefore, decided to perform total thyroidectomy without sending the specimen for a frozen section examination. The lesion was dissected from the tracheal surface without difficulty, but removing the inter-ring membrane; this was followed by total removal of the thyroid. The breach was closed with separate sutures using the right sternothyroid muscle, sutured to the trachea, as protection. Subsequent permanent section examination revealed a typical neurinoma.

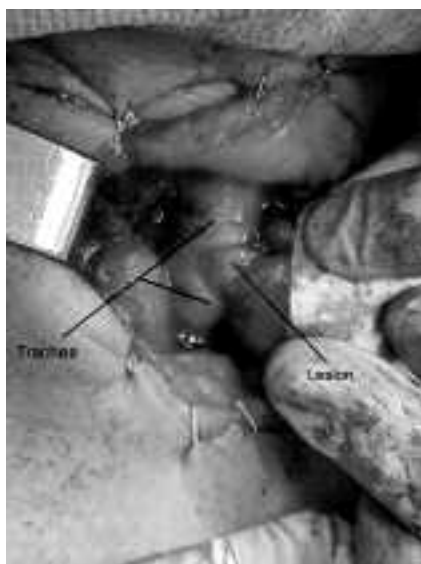


Fig. 1. Intraoperative image.

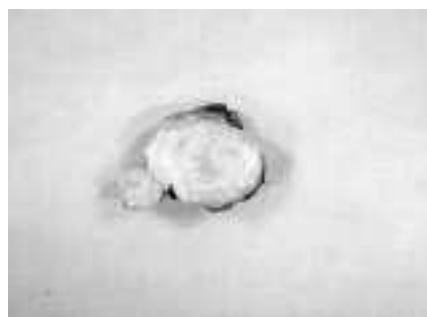

Fig. 2. Macroscopic characteristics.

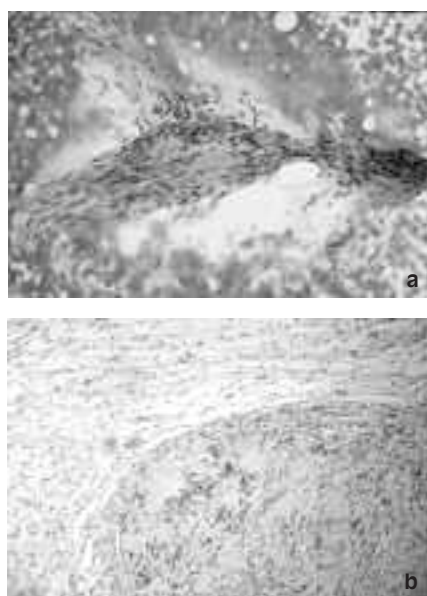


Fig. 3a-b. Histological and cytological characteristics of nodule.

#### MACROSCOPIC CHARACTERISTICS

The neoplasm adhered to the posterior surface of the right thyroid residue. It was encapsulated, 3.4 cm in diameter, with an irregular "bumpy" surface, hard-elastic consistency with a 0.9 cm protrusion into the tracheal lumen. The cut surface was whitish with a fascicular aspect (Fig. 2). The thyroid consisted of the residual right lobe (3 cm at widest point) and the left lobe of normal appearance.

#### HISTOLOGY

In haematoxylin-eosin stained sections, the neoplastic tissue was circumscribed by a thin fibrous capsule and consisted of spindle-shaped cells arranged in

compact spiralling bundles or Verocay bodies (Fig. 3). The nuclei were long undulating or comma-shaped and often arranged parallel to each other in groups of cells (pallidating). These agglomerations (Antoni A tissue) alternated with hypocellular myxoid areas, containing (sometimes dilated) blood vessels (Antoni B tissue). Mitotic figures were rare. These characteristics were typical of a schwannoma.

#### IMMUNOCYTOCHEMISTRY

Positivity for S-100 protein<sup>9</sup>, revealed by the avidin-biotin-peroxidase technique, was strong and widespread in the neoplastic tissue, confirming the schwannoma diagnosis.

#### CYTOLOGY

The cytological preparations obtained from the FNABs<sup>5,6</sup> taken in 1999 and in 2001 were re-examined. The revision revealed, in both samples, few thyrocytes, but also rare minute aggregates of spindle-shaped cells with elongated nuclei and eosinophilic cytoplasm, as well as irregular shaped cells in a loose slightly eosinophilic matrix, associated with inflammatory cells that had been originally interpreted as stromal cells. These findings are consistent with the Antoni A and B tissues characteristic of schwannoma and identified in the histological sections (Fig. 4).

#### Discussion

Non-epithelial cancers (neurinoma, teratoma, hemangioma lipoma, lymphoma, and leiomyoma) occur very rarely in the region of the thyroid. A review of the 18 published cases of thyroid bed schwannoma showed that they were often mistaken for a thyroid

nodule<sup>1</sup>. This is not surprising since they share both clinical (painless hard, elastic, mobile on swallowing) and sonographic (round or elongated, tendency to hypoechogenicity, possibly cystic aspect, thickened wall, abundant internal and peripheral vascularisation.) characteristics. Differential diagnosis, therefore, seems difficult.

In the present case, indication for surgery was the increase in size of the nodule and the intranodular vascularisation; the indication for total thyroidectomy was based only on the macroscopic clinical aspect of the lesion and the suspicious clinical pre-operative diagnosis<sup>10</sup>. The surgeon should have sent a specimen for an intra-operative frozen examination, due to the lack of a cytological diagnosis. In the present case, however, the cytological specimens did, in fact, present characteristics compatible with a schwannoma diagnosis, although they were difficult to identify and the identification could only have been expected if the cytologist was convinced the sample was adequate. When a sample labelled "from a thyroid nodule" contains few thyrocytes, the cytologist may be forgiven for considering it inadequate. It is here that the person who performed the biopsy must have an input: he/she will know whether or not the sample was representative of the lesion. It is for this reason that, in many centres, the pathologist performs the whole procedure: biopsy, slide preparation and slide evaluation.

In conclusion, in our opinion, close routine co-operation between the cytologist, and radiologist or surgeon who performs the FNAB, could help to reach an accurate pre-operative diagnosis and, furthermore, the surgeon should always ask for a frozen section in absence of a cytological pre-operative diagnosis before deciding to perform total thyroidectomy.

#### References

- 1 Million RR, Cassisi NJ. *Management of head and neck cancer*, 2<sup>nd</sup> Ed. Philadelphia: Lippincott; 1994. p. 785-810.
- 2 Mikosch P, Gallowitsch HJ, Kresnik E, Lind P. *Schwannoma of the neck simulating a thyroid nodule*. *Thyroid* 1997;7:449-51.
- 3 Al-Ghamdi S, Fageeh N, Dewan M. *Malignant schwannoma of the thyroid gland*. *Otolaryngol Head Neck Surg* 2000;122:143-4.
- 4 Gustafson LM, Liu JH, Rutter MJ, Stern Y, Cotton RT. *Primary neurilemmoma of the thyroid gland: a case report*. *Am J Otolaryngol* 2001;22:84-6.
- 5 Jayaram G. *Neurilemmoma (schwannoma) of the thyroid diagnosed by fine needle aspiration cytology*. *Acta Cytologica* 1999;43:743-4.
- 6 Sugita R, Nomura T, Yuda F. *Primary schwannoma of the thyroid gland: CT findings*. *AJR* 1998;171:528-9.
- 7 Goldstein J, Tovi F, Sidi J. *Primary schwannoma of the thyroid gland*. *Int Surg* 1982;67(Suppl 4):433-4.

- 8 Aoki T, Kumeda S, Iwasa T, Inokawa K, Hori T, Makiuchi M. *Primary neurilemmoma of the thyroid gland: report of a case*. *Surg Today* 1993;23:265-8.
- 9 Herrero Laso JL, Estrada Gormaz J, Varela Duran J, Canaveral Londono JE. *Neurinoma of the thyroid gland*. *An Otorrinolaringol Ibero Am* 1997;24:457-64.
- 10 Ahmed A, Morley A, Wilson JA. *Extracranial neurilemmoma: a case report and review of the literature*. *J R Coll Surg Edinb* 2000;45:192-4.

■ Acknowledgements: Authors thank Don Ward for help with English and for critically reviewing manuscript.

■ Received March 20, 2005  
Accepted April 2, 2005

■ Address for correspondence: Dr. F. De Paoli, Divisione di Chirurgia Cervico-Facciale, Istituto Europeo di Oncologia, via Ripamonti 435, 20124 Milano, Italy - Fax +39 02 57489491 - E-mail: fiora.depaoli@ieo.it

## The expert's comment

N. FLOR

Department of Diagnostic and Interventional Radiology, University of Milan, Milan, Italy

Sonography is highly sensitive in identifying thyroid nodules and it is significantly more sensitive than clinical palpation; a good radiologist needs to know which nodules are suspect and amenable to fine needle aspiration biopsy (FNAB).

The nodule described in this case report showed sonographic evidence (increase in dimensions, hypoechoic texture, internal flow pattern at power doppler examination) associated with intermediate or high probability of a malignant nature<sup>1</sup> and it was, therefore, decided to perform FNAB for the definitive nodule assessment.

The inadequacy of the material obtained by the two different FNAB samples, the correct diagnosis made retrospectively by the pathologist re-evaluating the same material is worthy of comment.

There is a need for close cooperation between different specialists and, in this case, in particular, between the radiologist and pathologist. If the radiologist is sure about the accuracy of two different samples,

needle within the nodule, he should discuss this with the pathologist; they should both be motivated to obtain a diagnosis and/or to improve the previous inadequate result.

In some centres, the pathologist himself collects the sample or a cytologist is present at the nodule sampling by the radiologist with ultrasound guidance; in both cases, it is possible to know immediately if the sample is adequate or if more samples should be obtained. Some Authors<sup>2</sup> have suggested that sequential FNAB increases the accuracy of the method by 22.6%, sensitivity by 13.8% and specificity by 6.2%, with a reduction in false positive/negative results of 14.2% and "non diagnostic" results by 100%.

In my opinion, close collaboration between radiologist, pathologist and head and neck surgeon is a key-point not only in dealing with difficult cases, such as that reported here (thyroid bed schwannoma is rare) but also to guide and improve surgical planning also in patients with hyperplastic or malignant nodules.

### References

<sup>1</sup> Solbiati L, Livraghi T, Ballarati E, Ierace T, Crespi L. *Thyroid gland*. In: Solbiati L, Rizzato G, editors. *Ultrasound of superficial structures*. Edinburgh: Churchill Livingstone; 1995. p. 49-85.

<sup>2</sup> Furlan JC, Bedard YC, Rosen IB. *Single versus sequential fine-needle aspiration biopsy in the management of thyroid nodular disease*. *Can J Surg* 2005;48:12-8.

---

E. MAIORANO

Pathology Department, University of Bari, Italy

The occurrence of unusual neoplasms in unusual sites is the source of many problems both for clinicians and pathologists as to the best management of the patient. The present case report carefully summarises many such problems, which, unfortunately, do not always may find adequate solutions before the administration of what is, apparently, the best cure for the patient.

We all agree that FNAB is currently the most reliable pre-operative diagnostic tool for patients harbouring thyroid nodules and that its diagnostic accuracy is very high, in expert hands. Although performing the

aspirate may allow the pathologist to acquire additional information as to the adequacy and quality of the material to be examined, this is not always the pathologist's job in many institutions, where thyroid FNAB still remains an accurate procedure, at least when dealing with "conventional" thyroid nodules.

The Authors correctly highlighted the different interpretation of the cytological preparations after the final diagnosis was achieved by histopathology, based on the presence of scattered spindle cells of possible mesenchymal nature, admixed with a reduced number of thyrocytes, that had been overlooked at first glance.

This constructive criticism is essential both for clinicians and pathologist to learn from errors and avoid future traps. Nevertheless, we should be well aware that the cytological diagnosis of mesenchymal lesions, including a considerable number of neoplastic, non-neoplastic and pseudoneoplastic lesions is "*per se*" very troublesome, even for pathologists with a particular interest in this specific field who may frequently delay, to permanent sections, the final diagnosis.

In this light, while the claim for closer interactions between clinicians and pathologists is more than welcome and would surely improve the accuracy of FNAB, a word of caution seems opportune as to the real possibility of achieving the correct result in all instances, especially when dealing with mesenchymal lesions occurring in the parenchymal organs.