

Oncological outcome after CO₂ laser cordectomy for early-stage glottic carcinoma

Risultati oncologici dopo cordectomia laser CO₂ del carcinoma glottico precoce

C. BOCCIOLINI, L. PRESUTTI¹, P. LAUDADIO

Department of Otolaryngology, Head and Neck Surgery, Ospedale Maggiore, Bologna;

¹Department of Otolaryngology, Head and Neck Surgery, Policlinico di Modena, Italy

Key words

Vocal folds • Early glottic carcinoma • Surgery • Cordectomy • Carbon dioxide laser

Parole chiave

Corde vocali • Carcinoma glottico precoce • Terapia chirurgica • Cordectomia • Laser CO₂

Summary

This study aims to define indications for micro-endoscopic laser surgery in early glottic carcinoma (Tis, T1a and T1b), to examine patterns of local recurrences and related re-treatment methods. A cohort of 79 patients with previously untreated early glottic carcinoma, subjected to endoscopic CO₂ laser excision between January 1993 and October 2000, was retrospectively examined. Patients included in data analysis had a mean follow-up of 39 months. Depth and extension of excisions were graded according to European Laryngological Society Classification, and included 5 types of cordectomy. Actuarial overall survival, determine survival, disease-free survival, ultimate local control, and laryngeal preservation rates, at 3 years, were 97.5%, 98.7%, 89.9%, 92.4%, and 97.4%, respectively. Survival curves for overall and disease-free survival were calculated from the date of diagnosis using the Kaplan-Meier method. Of the 8 patients with local recurrences, 5 were managed with larynx-sparing treatment: a second endoscopic CO₂ laser cordectomy was performed in 2 patients, a supracricoid laryngectomy in 2 patients, and one patient was treated with radiotherapy. The remaining 3 patients were submitted to total laryngectomy, one of whom died due to neck metastases. One patient died from other causes. All other patients were alive and disease-free at the last follow-up. Understanding the diffusion pathways and timing of laryngeal glottic cancer is important both for treatment and prognosis. Correct knowledge of the subsites of the larynx and the routine use of pre-operative and intra-operative diagnostic assessment is useful in the selection of the appropriate type of resection. Micro-endoscopic laser surgery is efficacious for early glottic carcinoma, with oncological results comparable to those observed following radiotherapy or conventional partial laryngectomy, however, in this case, local recurrences have a greater range of re-treatment options.

Introduction

Over the last two decades, data reported in the literature have demonstrated that micro-endoscopic laser

Riassunto

Lo scopo di questo studio è definire le indicazioni della chirurgia laser nel trattamento dei carcinomi glottici precoci (Tis, T1a e T1b); esaminare le cause delle recidive locali ed i trattamenti di recupero. Abbiamo condotto uno studio retrospettivo in 79 pazienti affetti da carcinoma glottico precoce non precedentemente trattato sottoposti a chirurgia endoscopica con laser CO₂ dal gennaio 1993 all'ottobre 2000. I dati di tutti i pazienti inclusi sono stati analizzati in un periodo di follow-up medio di 39 mesi. La profondità e l'estensione dell'escissione era classificata secondo la European Laryngological Society Classification, che include 5 tipi di cordectomia. La sopravvivenza attuariale globale, determinata, l'intervallo libero da malattia, il controllo locale e la preservazione laringea a tre anni sono stati rispettivamente del 97,5%, 98,7%, 89,9%, 92,4% e 97,4%. Le curve di sopravvivenza globale e l'intervallo libero da malattia sono state calcolate dalla data della diagnosi con il metodo di Kaplan-Meier. Degli 8 pazienti che presentavano recidiva, 5 sono stati trattati con conservazione della laringe: una seconda cordectomia laser CO₂ è stata praticata in 2 pazienti, una laringectomia ricostruttiva sopracricoidica in 2 pazienti ed un paziente è stato trattato con radioterapia. Gli altri 3 pazienti sono stati operati con laringectomia totale, uno dei quali è deceduto per metastasi laterocervicali. Un paziente è deceduto per malattia intercorrente. Tutti gli altri pazienti sono vivi e liberi da malattia all'ultimo controllo. La comprensione delle vie di diffusione del cancro laringeo glottico può essere importante sia per il trattamento che per la prognosi. La corretta conoscenza delle sottosezioni della laringe e gli accertamenti diagnostici preoperatori e intraoperatori facilitano la selezione del più appropriato tipo di resezione. La microchirurgia laser risulta essere un efficace trattamento per il carcinoma glottico precoce, con risultati oncologici sovrapponibili a quelli osservati dopo radioterapia o chirurgia parziale della laringe, ma con maggiori possibilità di opzioni nel trattamento di recupero delle recidive locali.

surgery can be considered a valid alternative to radiotherapy and open-neck surgery for the treatment of early glottic cancer¹⁻⁵. The two aims of endoscopic surgery, for Tis and T1 glottic carcinomas, are first,

to achieve the same local control as that obtained with conservative laryngeal surgery or radiotherapy, and, second, to preserve the physiological functions of the larynx as those with radiotherapy. Several Authors^{6,7} have referred to the numerous advantages of endoscopic surgery with respect to radiotherapy: favourable cost-effectiveness ratio, less morbidity, low complication rate, and the possibility of further treatment with other procedures such as surgery or radiotherapy.

Correct knowledge of the subsites of the larynx and the routine use of a pre-operative and intra-operative diagnostic assessment makes the choice of the more appropriate type of resection easier, according to the European Laryngological Society Classification⁸.

The main endpoint of this study is the measurement of the overall survival rates, determinate survival, disease-specific survival, local control with initial therapy, and organ preservation in 79 patients affected by early glottic cancer treated with transoral laser surgery between 1993 and 2000. Moreover, this study seeks to evaluate the pattern of local recurrence and re-treatments to establish indications for laser surgery in early glottic lesions.

Material and methods

Between January 1993 and October 2000, 79 consecutive patients with early-stage glottic cancer were treated by micro-endoscopic CO₂ laser surgery in the Department of Otolaryngology at Ospedale Maggiore of Bologna, Italy. Patients with a definitive histopathological diagnosis of keratosis without atypia or mild to moderate dysplasia were excluded from the study. The population comprised 75 males (95%) and 4 females (5%), age range 40-93 years (mean 66.5). All patients had biopsy-proven squamous-cell carcinoma (SCC) of the vocal cords. None of the patients had undergone previous radiotherapy or surgical treatment. These patients were classified according to the 2002 UICC TNM system⁹ and included 4 (5%) Tis, 64 (81%) T1a, 10 (12.7%) T1b, and 1 (1.3%) T2.

Pre-operative diagnostic assessment included flexible and rigid endoscopy with 90°, videolaryngostroboscopy, and, occasionally, computed tomography scan (CT), in selected patients, to exclude the presence of cartilage invasion of the anterior commissure and, invasion of the paraglottic space of the lesion. Intra-operative rigid endoscopy with 0°, 30°, 70° and 120° telescopes was performed and all patients had biopsy-proven SCC of the vocal cords, before the surgical procedure.

Inclusion criteria for the use of micro-endoscopic laser treatment was: good exposure of the glottic region and the tumour staged Tis or T1 without deep

involvement of the anterior commissure, Morgagni's ventricle, the supraglottic or subglottic region or impairment of vocal cord mobility and posterior extension of the lesion as far as the vocal process. Exclusion criteria: patients with glottic carcinoma which had extended completely to the floor of the ventricle. Only one patient was staged T2 due to superficial extension of the lesion to the supraglottic region but this patient had normal vocal cord mobility.

Endoscopic resection has progressed with the advances made in technology; the developments include modification of rigid endoscopes for improved access, digitally-enhanced telescopic visualization, powered instrumentation, and microspot CO₂ laser (Laser Opmilas CO₂ 50, Zeiss, Germany) set in the superpulse mode (1 to 3 W, 270 µm spot size).

The techniques used for laser cordectomy were in accordance with the classification proposed by the European Laryngological Society in 2000⁸. Type I (subepithelial cordectomy) was performed with resection of the superficial layer of the lamina propria and was used for those lesions that, pre-operatively, did not extend beyond the basal membrane in selected cases of erythroleukoplakia (evaluated by videolaryngostroboscopy). Type II (subligamental cordectomy) extends as far as the superficial portion of vocal muscle and was applied in cases of small superficial tumours. Type III (transmuscular cordectomy) was performed by cutting through the vocalis muscle with resection of the epithelium, the lamina propria, and part of the vocalis muscle. This cordectomy was performed for small superficial tumours involving the middle third of the true vocal fold and/or the superficial extension to the anterior commissure, without crossing the midline. Type IV (total cordectomy) extends from the vocal process to the anterior commissure. As the depth of the surgical margins reaches the internal perichondrium of the thyroid cartilage, the perichondrium was sometimes included in the resection. Type IV cordectomy was performed when the lesion extended to the anterior third of the vocal cord and/or to the anterior commissure and/or the deep infiltrative pattern. Type V (extended cordectomy) includes resection of the contralateral vocal cord, the arytenoid, the ventricular fold, or the subglottis. The cordectomy type Va was performed when the lesion extended to the anterior commissure in selected cases or crossed the midline and/or to the contralateral vocal cord, whether just a segment or involving the entire vocal cord. The margins of the resection were tumour-free in all cases. Tracheotomy was not required for any patient in this series. The patients were usually discharged from the hospital on the fourth or fifth post-operative day. All patients were then examined after one month by laryngoscopy with mirror and/or a flexible fiberoptic laryngoscope. Follow-up examinations were per-

formed every three months for the first three years, every six months for the next two years, and then annually. Repeated microlaryngoscopy and excisional biopsies were performed only when relapses were suspected.

Statistical analysis of the data was performed using the SPSS statistical package for Windows. The end-point for overall survival was the date of the patient's death (regardless of the cause) or the date of the last consultation for patients who were alive and well. For the analysis of disease determinate survival, patients who died of unrelated causes were considered censored at the date of death. The end-point for disease-free survival was the date of local or regional recurrence. The end-point for local control by endoscopic laser excision alone was the date of local recurrence that required open-neck surgery and/or radiotherapy. The end-point for laryngeal preservation was the date of the total laryngectomy. Survival curves for the overall and the disease-free survival were calculated from the date of the diagnosis by the Kaplan-Meier method. No patient was excluded from the statistical analysis.

Results

Patients included in the data analysis had a mean follow-up period of 39 months (range 7-120): no patient was lost to follow-up. Only one patient had a follow-up period of only 7 months (the patient died from other causes), the other patients had a follow-up period of at least 24 months. Of the 79 laser cordectomies performed, one was type I (1 Tis), 13 were type II (2 Tis, 11 T1a), 35 were type III (1 Tis, 34 T1a), 17 were type IV (17 T1a), 13 were type V (2

T1a, 10 T1b, 1 T2) (Table I). No intra-operative or post-operative complications were observed in any of the 79 patients. None required tracheotomy at the end of the procedure. Eight (10.1%) patients experienced local recurrence within periods varying from 4 to 55 months (mean 14.5). Three (3.8%) and five (6.3%) recurrences, respectively, referred to the T1a and T1b groups.

Rescue treatment consisted of a second endoscopic CO₂ laser cordectomy in two patients previously classed as T1a: due to recurrence, at four months, in the contralateral vocal cord and, respectively, at five months in the posterior third of the vocal cord. A supracricoid laryngectomy was performed in two patients (previously classed as T1b), associated with neck surgery, in one case: the recurrences observed in one patient at four months were found in the remaining contralateral vocal cord and, in the other patient, recurrence was observed at thirteen months in the homolateral paraglottic space. One patient, previously classed as T1b, was treated by radiotherapy for recurrence, at six months, in the homolateral vocal cord and in the anterior commissure with a subglottic extension exceeding 10 mm. Total laryngectomy was performed in three patients, two initially classed as T1b and one T1a. In the first two patients, the recurrence was observed, respectively, at 55 months in the homolateral paraglottic space with cricoarytenoid joint involvement and at 18 months in the anterior commissure with extra-laryngeal spread. In the other patient, the recurrence was observed at eleven months in the glottic region with a subglottic extension exceeding 20 mm: this was the only patient who died from neck metastases due to a second recurrence or tumour, ninety-five months after refusing treatment. All the other patients have survived and are

Table I. Distribution of the type of endoscopic cordectomy, in the 79 patients, according to European Laryngological Society Working Committee ^a.

Type of cordectomy	Tis	T1a	T1b	T2	Total
Subepithelial cordectomy (Type I)	1	-	-	-	1 (1.3%)
Subligamental cordectomy (Type II)	2	11	-	-	13 (16.4%)
Transmuscular cordectomy (Type III)	1	34	-	-	35 (44.3%)
Total cordectomy (Type IV)	-	17	-	-	17 (21.5%)
Extended cordectomy (Type V)	-	2	10	1	13 (16.5%)
Total	4 (5%)	64 (81%)	10 (12.7)	1 (1.3%)	79 (100%)

Table II. Analysis of patients who developed recurrence.

N.	Age (years)	Tumour stage (UICC) ⁹	Glottic site	Type of initial laser cordectomy	Site of recurrence	Recurrence after primary treatment (months)	Treatment of recurrence	Outcome	Months after primary treatment
1	74	T1b	Anterior and middle thirds of vocal cord, anterior commissure	5	Anterior commissure with extralaryngeal spread	18	TL	AFD	46
2	77	T1b	Vocal cord, anterior commissure	5	Paraglottic space	13	SL	AFD	30
3	58	T1a	Vocal cord	4	Vocal cord with subglottic extension	11	TL	DD	107
4	64	T1b	Vocal cord, anterior commissure	5	Contralateral vocal cord	4	SL	AFD	38
5	75	T1a	Anterior and middle thirds of vocal cord	2	Contralateral vocal cord	4	LE	AFD	34
6	64	T1b	Vocal cord, anterior commissure, anterior and middle thirds of contralateral vocal cord	5	Homolateral paraglottic space with cricoarytenoid joint involvement	55	TL	AFD	65
7	69	T1a	Vocal cord	3	Posterior third of vocal cord	5	LE	AFD	33
8	73	T1b	Vocal cord, anterior commissure	5	Anterior commissure, vocal cord with subglottic extension	6	Rt	AFD	58

SL: supracricoid laryngectomy; TL: total laryngectomy; LE: laser excision; Rt: radiotherapy; AFD: alive and free of disease; DD: died of disease

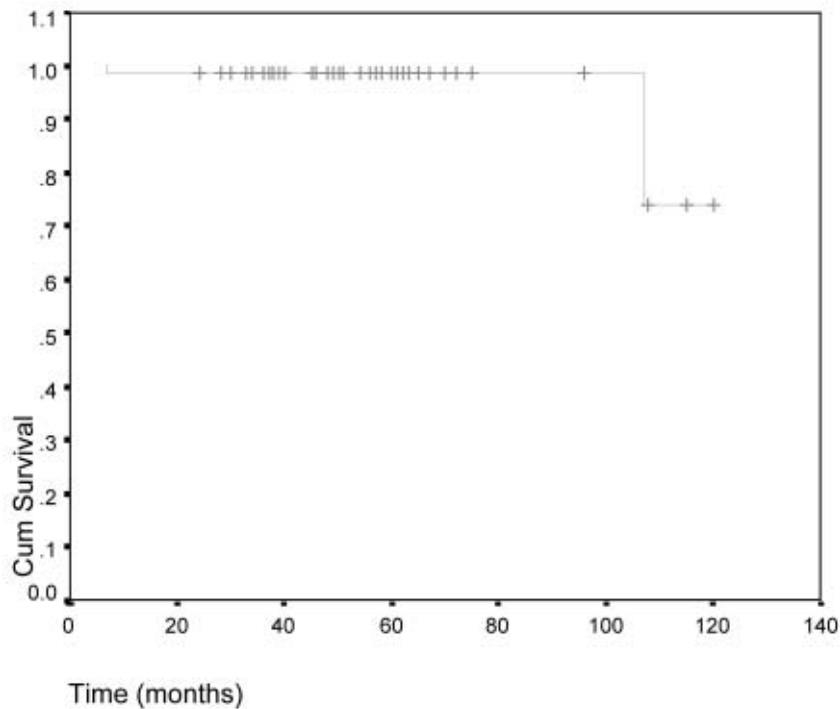


Fig. 1. Overall survival rate in 79 patients treated by micro-endoscopic laser surgery.

disease-free (Table II). One patient died after seven months due to myocardial infarction.

The overall 3-year survival rate was 97.5% (HR = 3.0; 95% confidence interval (95% CI) = 109-121) (Fig. 1), the 3-year determinate survival rate was 98.7%, the 3-year disease-free survival rate was 89.9% (HR = 4.0; 95% CI = 99-116) (Fig. 2), and the 3-year ultimate local control with laser alone was 92.4%. Of the eight patients with local recurrences, five (62.5%) were managed with further organ-sparing treatment. After salvage therapy, laryngeal preservation was achieved in 97.4% (75/77) of the surviving patients.

Discussion

Early-stage carcinomas of the vocal cords (Tis, T1a and T1b) include a wide spectrum of histopathological entities ranging from intra-epithelial neoplasias that infiltrate the full depth of the epithelium, but not the basal membrane, to microinvasive and invasive carcinomas that penetrate the basal membrane and involve the lamina propria without deep vocal muscle infiltration¹⁰.

The spread of glottic cancer depends primarily on the

anatomy of the larynx¹¹, and, therefore, attention should be focused on anatomical differences between the anterior and posterior commissure subsites. The perichondrium of the inner surface of the thyroid cartilage is interrupted, at glottic level, by an avascular zone located between the thyroid cartilage and the apices of the vocal cord. In contrast, the posterior commissure has glands and blood vessels in the lamina propria and includes a deep elastic lamina and the internal cricoid ligaments of both sides². Tumours that originate on the vocal cords can involve all or part of the anterior commissure; more rarely, the anterior commissure is the original site of the cancer that then spreads to the adjacent structures¹². Some Authors^{12 13} have recognized that commissural structures are not easily penetrated by early tumours and that invasion of the thyroid cartilage requires a superficial spread of the tumour above or below the insertion of the vocal cords. They observed that the T1 carcinoma rarely infiltrates the thyroid cartilage, due to the presence of a solid barrier represented by Broyle's ligament. The anatomical structure of the anterior commissure extends vertically both upwards and downwards from the glottic plane. In addition to the mucosa, this subsite includes the intermediate lamina of the thyroid cartilage and Broyle's ligament

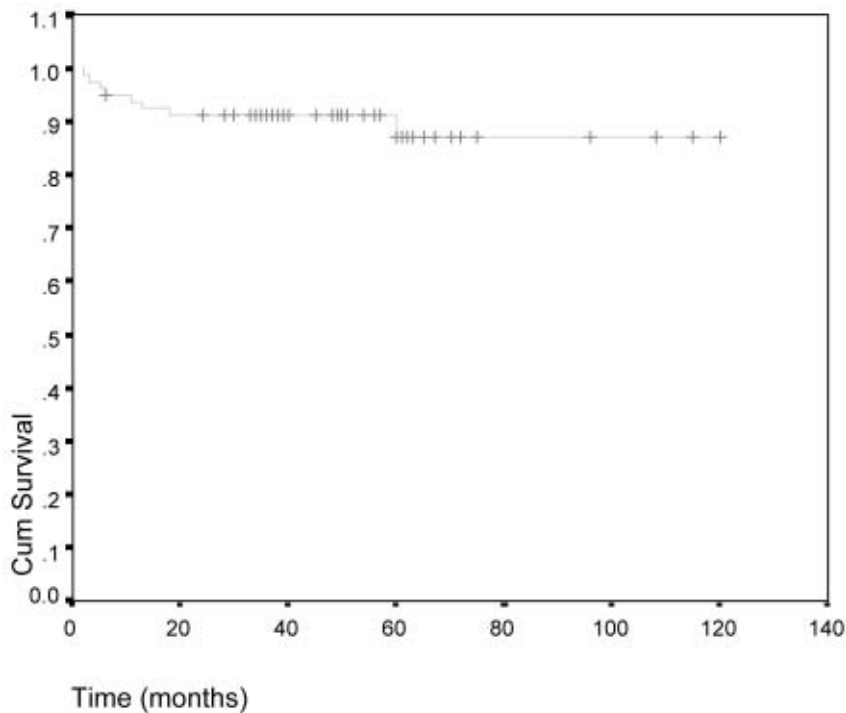


Fig. 2. Disease-specific survival rate in 79 patients treated by micro-endoscopic laser surgery.

with its correlated structures¹⁴. Tumours involving the posterior commissure are less frequent than those involving the anterior commissure. The posterior commissure corresponds to the so-called cartilaginous glottis, which includes the medial surfaces of the arytenoid cartilages and vocal processes. Most posterior commissure tumours are cordal cancers that affect the vocal process and, on rare occasions, the internal surface of the arytenoid cartilage without passing over the mid-line. Tumours originating in the posterior commissure are unusual. In this subsite, in the case of T1 glottic cancers, in addition to the high degree of vascularization, the internal cricoarytenoid ligaments may offer tumours a diffusion pathway toward the cricoarytenoid joint and subglottis region¹⁴. This might explain why posterior commissure tumours infiltrate the subglottic region: this region is in such close proximity to the posterior glottic subsite that the latter is considered a part of the subglottic region as far as concerns tumour spread⁴.

Lateral extension of glottic neoplasias can involve the base of the ventricle, the false cord, and the subglottis region, either superficially or penetrate deep into the conus elasticus. Since there is no well-defined anatomical barrier, at this level, the tumour may become a transglottic lesion with submucosal

extension into the supra- and subglottis with further extensions into the extralaryngeal tissues. These lesions are obviously not amenable to endoscopic surgery alone and prognosis is very poor.

Understanding the pathways and timing of spread of early laryngeal glottic cancer is important both for treatment and prognosis. The use of endoscopic CO₂ laser cordectomy for Tis and T1 glottic carcinomas is an oncologically safe procedure. It is an important alternative to other treatment methods such as radiotherapy and open neck surgery, as recently reported by several Authors who achieved a local control rate with laser alone ranging from 87-100%^{2 3 8 15}. In our patient group, we obtained a 3-year local control of 92.4%, a 3-year actuarial survival rate of 97.5% (Fig. 1), a 3-year determinate survival rate of 98.7%, and a 3-year disease-free survival rate of 89.9% (Fig. 2). Local control is clearly the most important single prognostic factor for T1 glottic cancer as lymph node metastases and distant spread are only rarely observed in the absence of local relapse. Therefore, curative treatment must aim for high local control rates. On the other hand, quality-of-life (QoL) issues and the preservation of a functioning larynx are other fundamental aims of a successful treatment. In the series of patients described herein, the ultimate larynx-

geal preservation rate was 97.4%. Of the patients with local recurrence, 62.5% were submitted to further organ-sparing techniques (Table II).

The advantages of trans-oral laser surgery are the haemostatic effects and precision of tissue ablation¹⁶. Furthermore, this procedure causes minimal morbidity, provides good functional results, and is a cost-effective alternative to open surgical procedures and radiotherapy^{6,7,17}. Moreover, the recently-developed phono-microsurgical approach aims to achieve the best compromise between oncological radicality and vocal function with minimal impact on the patient's QoL¹⁰.

In order to correctly diagnosis these neoplastic entities, we routinely adopted a pre-operative and intra-operative test battery to minimize the number of clinical misdiagnoses. Pre-operative diagnostic assessment included flexible and rigid endoscopy with 90°, videolaryngostroboscopy. A CT scan may be required in the case of more extensive lesions such as the T1b with anterior commissure involvement. Underestimation of the involvement of the visceral spaces and cartilaginous framework can thus be excluded. Intra-operative rigid endoscopy with 0°, 30°, 70° and 120° telescopes was performed and all patients had biopsy-proven SCC of the vocal cords before the surgical procedure. Resection of the false vocal cord was frequently performed to provide clear visualization of the superior surface of the anterior commissure as well as ventricle floor involvement. On the basis of our observations, the criteria for the use of micro-endoscopic laser treatment include: a stage Tis, T1a or T1b tumour without deep posterior involvement of the vocal process, lateral involvement the floor of the Morgagni's ventricle, or involvement of the subglottic region, according to the prognostic validity of the modification introduced in the last AJCC-UICC TNM classification (6th edition)⁹. The reason behind the variation in the treatment of a T1a lesion, namely, from cordectomy type II to type V (Table I), can be explained by the fact that the superficial small tumour of a mobile vocal fold or a larger tumour that infiltrates the muscle and spreads to the anterior commissure, without involving it, are both T1a lesions according to the TNM classification. The glottic tumours involving the anterior commissure have traditionally been controversial. Despite the negative

impact of anterior commissure invasion on the cure rate for stage I glottic carcinoma reported by a number of investigations^{18,19}, endoscopic resection of early glottic cancer involving the anterior commissure has been successfully performed by others^{5,15}.

In our experience, we recommend that endoscopic treatment be limited to selected cases of anterior commissure cancer spreading superficially at the level of the glottis without extension to the supraglottis or subglottis. Only one patient was submitted to an extended cordectomy for a T2 tumour with superficial supraglottis and anterior commissure extension. The main contraindications to laser cordectomy are:

- lesions with deep involvement of the anterior commissure that are in close proximity to the underlying cartilage;
- impaired arytenoid mobility: these tumours may invade the cricoarytenoid joint, the posterior cricoarytenoid muscle, or the posterior portion of the cricoid cartilage.

Ventricle floor involvement by the carcinoma or the impairment of vocal cord mobility might be related to infiltration of the paraglottic space. As a result, the surgical approach to anterior commissure carcinoma or tumoural ventricle floor involvement, with or without impairment of vocal cord mobility, is supracricoid laryngectomy with cricohyoidoepiglottomy. Data in the literature clearly demonstrate that this technique can lead to good control rates²⁰.

From our findings, it can be concluded that transoral endoscopic laser cordectomy offers a good oncological outcome and acceptable functional results in the treatment of Tis, T1a, and T1b glottic cancer. Local control rates and overall survival rates obtained, in our series, are comparable to those in the literature^{1-3,5-7,15}. In this study, although favourable re-treatment results, in those cases with local failure for early laryngeal cancer treated with laser cordectomy have been documented, no definitive recommendation regarding the best single treatment method can be given. As reported in the literature, conventional partial laryngectomy leads to the highest local control rates; radiotherapy is believed to best preserve the voice, and laser surgery is associated with time- and cost-effectiveness, a low level of morbidity, fair local control rates, and excellent re-treatment options for local failure with preservation of the larynx function.

References

- ¹ Damm M, Eckel HE, Schneider D, Arnold G. *CO₂ laser surgery for verrucous carcinoma of the larynx*. *Lasers Surg Med* 1997;21:117-23.
- ² Peretti G, Nicolai P, Piazza C, Redaelli De Zinis LO, Valentini S, Antonelli AR, et al. *Oncological results of endoscopic resections of Tis and T1 glottic carcinomas by carbon dioxide laser*. *Ann Otol Rhinol Laryngol* 2001;110:820-6.
- ³ Gallo A, De Vincentiis M, Manciooco V, Simonelli M, Fiorella ML, Shah JP. *CO₂ laser cordectomy for early-stage glottic carcinoma: a long-term follow-up of 156 cases*. *Laryngoscope* 2002;112:370-4.
- ⁴ Ferlito A, Carbone A, Rinaldo A, DeSanto LW, D'Angelo L, Barnes L, et al. *"Early" cancer of the larynx: the concept*

- as defined by clinicians, pathologists, and biologists. *Ann Otol Rhinol Laryngol* 1996;105:245-50.
- ⁵ Steiner W. *Results of curative laser microsurgery of laryngeal carcinomas*. *Am J Otolaryngol* 1993;14:116-21.
 - ⁶ Myers EN, Wagner RL, Johnson JT. *Microlaryngoscopic surgery for T1 glottic lesions: a cost-effective option*. *Ann Otol Rhinol Laryngol* 1994;103:28-30.
 - ⁷ Moreau PR. *Treatment of laryngeal carcinoma by laser endoscopic microsurgery*. *Laryngoscope* 2000;110:1000-6.
 - ⁸ Remacle M, Eckel HE, Antonelli A, Brasnu D, Chevalier D, Friedrich G, et al. *Endoscopic cordectomy. A proposal for a classification by the Working Committee, European Laryngological Society*. *Eur Arch Otorhinolaryngol* 2000;257:227-31.
 - ⁹ Union International Contre le Cancer. *TNM classification of malignant tumors*. 6th Ed. New York, NY: Wiley-Liss; 2002.
 - ¹⁰ Zeitels SM. *Premalignant epithelium and microinvasive cancer of the vocal fold: the evolution of phonosurgical management*. *Laryngoscope* 1995;105(Suppl 3):1-51.
 - ¹¹ Buckley JG, MacLennan K. *Cancer spread in the larynx: a pathologic basis for conservation surgery*. *Head Neck* 2000;22:265-74.
 - ¹² Rucci L, Gammarota L, Borghi Cirri MB. *Carcinoma of the anterior commissure of the larynx: I. Embryological and anatomic considerations*. *Ann Otol Rhinol Laryngol* 1996;105:303-8.
 - ¹³ Kirchner JA. *Glottic-supraglottic barrier: fact or fantasy?* *Ann Otol Rhinol Laryngol* 1997;106:700-4.
 - ¹⁴ Rucci L, Simonetti L, Gammarota L, Borghi Cirri MB. *TNM glottic: role of the vocal muscle, arytenoid cartilage, and inferior paraglottic space in impaired vocal cord mobility (T2). An embryological and clinical study*. *Ann Otol Rhinol Laryngol* 1998;107:1038-45.
 - ¹⁵ Peretti G, Nicolai P, Redaelli de Zinis LO, Berlucchi M, Bazzana T, Bertoni F, et al. *Endoscopic CO₂ laser excision for Tis, T1 and T2 glottic carcinomas: cure rate and prognostic factors*. *Otolaryngol Head Neck Surg* 2000;123:124-31.
 - ¹⁶ Rudert H. *Technique and results of transoral laser surgery for small vocal cord carcinomas*. *Adv Otorhinolaryngol* 1995;49:222-6.
 - ¹⁷ Zeitels SM, Hillman RE, Franco RA, Bunting GW. *Voice and treatment outcome from phonosurgical management of early glottic cancer*. *Ann Otol Rhinol Laryngol* 2002;190(Suppl):3-20.
 - ¹⁸ Shapshay SM, Hybels RL, Bohigian RK. *Laser excision of early vocal cord carcinoma: indications, limitations, and precautions*. *Ann Otol Rhinol Laryngol* 1990;99:46-50.
 - ¹⁹ Krespi YP, Meltzer CJ. *Laser surgery for vocal cord carcinoma involving the anterior commissure*. *Ann Otol Rhinol Laryngol* 1989;98:105-9.
 - ²⁰ Chevalier D, Laccourreye O, Brasnu D, Laccourreye H, Piquet JJ. *Cricohyoidoepiglottopexy for glottic carcinoma with fixation or impaired motion of true vocal cord: 5-year oncologic results with 112 patients*. *Ann Otol Rhinol Laryngol* 1997;106:364-9.

■ Acknowledgements: Authors are indebted to Dr. Marco Bicocchi for statistical analysis of data.

■ Received: February 25, 2004
Accepted: October 30, 2004

■ Address for correspondence: Dr. C. Bocciolini, U.O. di Otorinolaringoiatria e Chirurgia Cervico-Facciale, Ospedale Maggiore, largo D. Nigrisoli, 40100 Bologna, Italy. Fax + 39 051 6478367. E-mail: cbocciolini@hotmail.com