

# Frontal sinus osteoma complicated by palpebral abscess: case report

## *Osteoma del seno frontale complicato da ascesso palpebrale: presentazione del caso*

C. DISPENZA, F. MARTINES, F. DISPENZA, C. CARAMANNA, C. SARANITI  
ENT Institute "R", Department of Specialistic Surgery, "P. Giaccone" Polyclinic, University of Palermo, Italy

### Key words

Frontal sinus • Osteoma • Surgical treatment • Case report

### Parole chiave

*Seno frontale • Osteoma • Trattamento chirurgico • Caso clinico*

### Summary

Osteomas of the paranasal sinuses are slow-growing, benign tumours most frequently found in the frontal sinus with an incidence that varies from 47% to 80% of the cases; there are often no symptoms and they are diagnosed by chance during an X-ray examination. When there are symptoms, they are usually headaches and ocular or neurological complications. The treatment of choice is surgery. A case of frontal osteoma complicated by frontal sinusitis and by a palpebral abscess is described.

### Riassunto

*Gli osteomi dei seni paranasali sono tumori benigni a lenta crescita che coinvolgono frequentemente il seno frontale con una incidenza variabile tra 47% e 80% dei casi; spesso decorre in modo asintomatico e vengono diagnosticati durante un esame radiologico eseguito per altri motivi. I sintomi più frequenti sono cefalea e complicazioni orbitarie e neurologiche. Gli Autori riportano un caso di osteoma del seno frontale complicato da sinusite frontale ed ascesso palpebrale.*

## Introduction

Osteomas are slow-growing, benign tumours that, following surgical removal, do not give rise to either metastases or relapse; those originating in the paranasal sinuses alone account for approximately 50% of all benign neoformations of the nose and sinuses<sup>1</sup>.

The most frequent localization is the frontal sinus with an incidence varying from 47% to 80% of the cases<sup>2,3</sup>; in 37%, the neoformation originates near the frontal sinus ostium, while in the remaining cases, it can originate in any part of the frontal sinus (roof, floor, interfrontal septum, anterior or posterior wall). In the fronto-ethmoidal localization, it is often located near the nasolacrimal duct<sup>2</sup>.

The exact incidence, however, cannot be established since these neoformations often remain asymptomatic throughout the patient's life or are diagnosed, by chance, during X-ray examinations carried out for other reasons.

Males are more frequently involved than females with a ratio of 2:1. The age at onset ranges from the third to the fourth decade.

## Case Report

The patient, a 42-year-old male, suffered from type II diabetes mellitus and was under oral anti-diabetic treatment. About 3 months before being taken into hospital, he complained of an episode of stabbing fronto-orbital headaches and mucopurulent rhinorrhea on the right side. He was, therefore submitted to antibiotic therapy which resulted in regression of the clinical signs. In the 2 weeks prior to admission, the above-mentioned symptoms returned and were associated with considerable swelling and hyperaemia of the right eyelid.

Objective signs on admission: tender swelling of the right eyelid supra-ciliary ridge covered with hyperaemic and shiny skin (Fig. 1); this swelling extended to the ipsilateral and medio-frontal supra-ciliary region and was fluctuating and painful under finger pressure; the eye-ball and ocular motility were unaffected. Antibiotic (ciprofloxacin 750 mg tablets, twice a day, for 10 days) and anti-oedematous (betamethasone 4 mg i.m. twice a day, decreasing the dosage starting from the 4<sup>th</sup> to the 8<sup>th</sup> day) treatment was started. After approximately 24 hours, a sinus appeared at the level of the upper eyelid with leaking of a foul-smelling, mucopurulent exudate mixed with necrotic tissue. Culture proved negative: computed tomography (CT) scan of the face revealed: at the

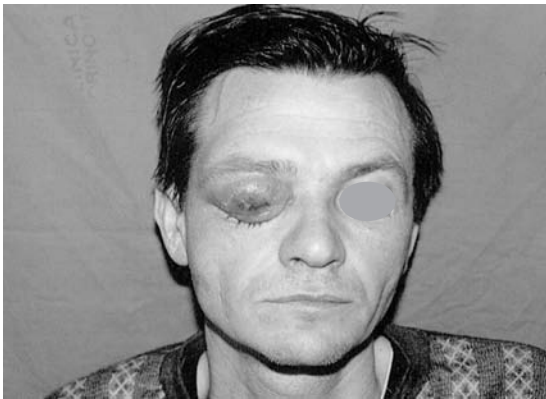

Fig. 1. Preoperative aspect.

level of the soft-tissue of the right eyelid, a dense, dyshomogeneous viscous tissue; the right frontal sinus and part of the left appeared obliterated by the osteoma (Fig. 2). No infiltration of the orbital tissues and no alterations in the adjacent bony structures were observed.

Removal of the osteoma was performed by means of the Ogston-Luc external procedure, rather than the coronal approach, as the osteoplastic technique was impossible due to the presence, not only of an osteomyelitic process of the anterior wall of the frontal sinus, but also of a cutaneous fistula which needed to be removed<sup>4</sup>; in fact, during the decollement of the periosteum, an erosion in the supra-ciliary foramen was found through which purulent exudate was leaking. The frontal sinus which was reached with a trephine and a gouge appeared to be almost completely filled by a bony neof ormation with an irregular surface originating at the level of the right frontal recess that

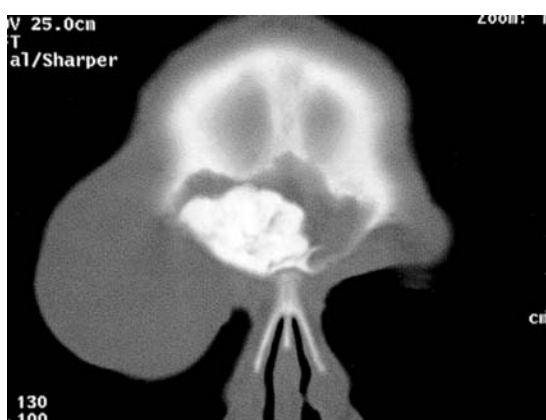


Fig. 2. CT axial scan showing extension of the osteoma.

seemed obliterated. The osteoma was removed using a mill and a gouge. An erosion of the upper frontal sinus wall was visible, at the top inner corner and at the back, involving a surface of about 4 mm<sup>2</sup>. The recess that was completely obstructed by the osteoma was milled; then an endoscopic intranasal anterior ethmoidectomy was carried out. A silicon fronto-nasal drainage was inserted; the nasal cavity operated on was plugged, the abscess cavity in the upper eyelid was cleaned and the skin of the wound was sutured in strata. The nasal packing was removed on the 3rd, and the frontal drainage on the 8th post-operative day. The patient was discharged on day 9. The post-operative course and the recovery period were uneventful. At two years' follow-up, the aesthetic result is excellent (Fig. 3) and frontal drainage is good, with no recurrence of frontal sinusitis.

## Discussion and Conclusions

Basically, three theories have been advanced regarding the aetiopathogenesis of sinus osteoma<sup>2,3,5,6</sup>: traumatic, infective and embryological. None of these theories seems to be more accredited than the others or able to exclude them. In fact, there is not always a traumatic event in the case history. Even if it has been shown that inflammation can stimulate osteoblastic activity, sinus inflammation usually follows ostium obstruction. According to the embryological theory, the osteoma would originate in the fronto-ethmoidal sutures, where there are both membranous and cartilaginous tissues, but many osteoma develop far from these areas.

A clinical picture of multiple osteoma is rare but, when present, may be associated with polyposis of the large intestine, Gardner's syndrome, subcutaneous desmoid tumours and epidermoid cysts<sup>2,3,7</sup>.

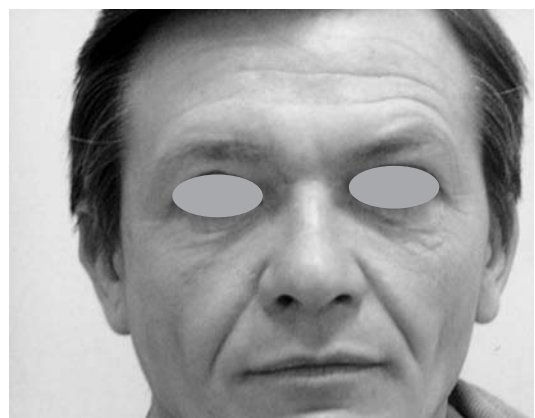

Fig. 3. The patient two years after surgery.

Histologically <sup>2,6</sup>, three types of osteoma can be distinguished:

- eburnated, compact or ivory, with bony lamellae arranged in parallel layers, slow-growing;
- spongy, areal-looking, with wide medullary spaces, without Havers' channels, of more rapid and more aggressive growth;
- mixed, in which two of the characteristics described above are present and representing the most common form with an incidence of over 50% of the cases <sup>8</sup>.

Clinically, this type of neof ormation can remain asymptomatic for a long time, even for the entire life of the patient, and may be discovered only by chance during an X-ray examination for other reasons.

The most frequent symptom is headaches, the qualitative and quantitative characteristics of which vary considerably and are related to the localisation and degree of development of the osteoma.

Although the osteoma invades the eyeball in one third of the cases, the symptoms relating to it are not frequent and consist of proptosis, diplopia and ptosis <sup>9</sup>. Cases of visual loss and epiphora, caused by the compression of the lachrymal sac by the osteoma, have been reported in the literature <sup>2</sup>.

During its slow growth, the osteoma can spread into the cranial fossae through the posterior wall of the frontal sinus or through the cribriform lamina, causing endocranial hypertension, meningitis, cerebral abscess and pneumocephalus <sup>2,5,10-16</sup>. There are other complications which are more frequently found, such as, for example, frontal mucocele, frontal sinusitis and the "vacuum sinus" syndrome <sup>17,18</sup>.

As far as concerns diagnosis, standard radiology is of fundamental importance with the aid of CT that shows the extension and the relationship of the osteoma with the adjacent structures <sup>2,3,5</sup>; the use of nuclear magnetic resonance (NMR) is justified in all

those cases in which an endocranial or orbital complication is suspected <sup>5</sup>.

As various Authors have already pointed out, the logic of surgical treatment for osteoma of the paranasal sinuses, that is universally accepted, is based on the fact that they are slow-growing benign tumours. Therefore, surgical treatment is reserved for symptomatic osteoma, while the non-symptomatic type are monitored with serial X-ray examinations <sup>19,20</sup>.

The most suitable approach and surgical technique for the removal of the osteoma will depend strictly on the dimensions, localization and extension.

Mugliston et al. <sup>19</sup> suggest applying, to the surgical treatment of the osteoma, the same evaluative criteria proposed by Cheesman (personal communication, 1984) for malignant tumours in the same localizations:

1. evaluation of intracranial disease;
2. protection of the brain;
3. avoidance of CSF leaks;
4. adequate haemostasis;
5. facilitation of resection.

The surgical techniques are represented by the fronto-orbital approach according to Ogston-Luc, which we used in the present case since there were no signs of orbital and/or endocranial compression; the transfacial approach through a Howarth-Lynch incision, extended to lateral rhinotomy and the realisation of a naso-frontal flap that allows good access to the orbital region and to the front and rear ethmoid and, finally, a coronal incision according to Untberger that allows good exploration of the frontal sinus, the ethmoid and the eyeball but is contraindicated in the case of osteomyelitis of the frontal bone and in patients who have previously undergone operations on the frontal sinus. Finally, some Authors, in cases of endocranial complications, use the endocranial approach or the mixed cranio-facial approach <sup>10,19</sup>.

## References

- <sup>1</sup> Spencer MG, Mitchell DB. *Growth of a frontal sinus osteoma*. J Laryngol Otol 1987;101:726-8.
- <sup>2</sup> Vowles RH, Bleach NR. *Imaging case study of the month: frontoethmoid osteoma*. Ann Otol Rhinol Laryngol 1999;108:522-4.
- <sup>3</sup> Marcos J, Garcia B, Herrero J, Marti M. *Osteoma frontal a proposito de un caso*. Acta Otorrinolaring Esp 1990;41:178-80.
- <sup>4</sup> Alford BR, Gorman GN, Mersol VF. *Osteoplastic surgery of the frontal sinus*. Laryngoscope 1965;75:1139-50.
- <sup>5</sup> Gil Tutor E. *Osteomas fronto-etmoidales*. An Otorrinolaringol Ibero Am 1998;25:137-46.
- <sup>6</sup> Rossillo V, Borghese M. *Su di un caso di voluminoso osteoma etmoido-frontale con iniziale invasione orbitaria*. La Nuova Clinica O.R.L. 1982;34:279.
- <sup>7</sup> Whitson WE, Orcutt JC, Walkinshaw MD. *Orbital osteoma in Gardner's syndrome*. Am J Ophthalmol 1986;101:236-41.
- <sup>8</sup> Friedmann I, Osborn DA. *Pathology of granulomas and neoplasms of the nose and paranasal sinuses*. London: Churchill Livingstone; 1982. p. 254-9.
- <sup>9</sup> Kim AW, Foster JA, Papay FA, Wright KW. *Orbital extension of a frontal sinus osteoma in a thirteen-year-old girl*. J AAPOS 2000;4:122-4.
- <sup>10</sup> Ferlito A, Pesavento G, Recher G, Mingrino S, Visona A, Fiore DL, et al. *Intracranial pneumocephalus (secondary to frontoethmoidal osteoma)*. J Laryngol Otol 1989;103:634-7.
- <sup>11</sup> Rappaport JM, Attia EL. *Pneumocephalus in frontal sinus osteoma: a case report*. J Otolaryngol 1994;23:430-6.
- <sup>12</sup> Holness RO, Attia E. *Osteoma of the frontoethmoidal sinus with secondary brain abscess and intracranial mucocele: case report*. Neurosurgery 1994;35:796-7.

- <sup>13</sup> Lunardi P, Missori P, Di Lorenzo N, Fortuna A. *Giant intracranial mucocele secondary to osteoma of the frontal sinuses: report of two cases and review of the literature.* Surg Neurol 1993;39:46-8.
- <sup>14</sup> Sente M, Topolac R, Peic-Gavran K, Aleksov G. *Frontal sinus osteoma as a cause of purulent meningitis.* Med Pregl 1999;52:169-72.
- <sup>15</sup> Olabe J, Carbonell J, Cunill L, Gata J, Bacci F. *Osteoma de seno frontal asociado a cavidad poroencefalica intracraneal.* Acta Otorrinolaring Esp 1993;44:461-4.
- <sup>16</sup> Summers LE, Mascott CR, Tompkins JR, Richardson DE. *Frontal sinus osteoma associated with cerebral abscess formation: a case report.* Surg Neurol 2001;55:235-9.
- <sup>17</sup> Duterme JP, Duhateau JP, Vanderkelen B. *Sinusite frontale, abcès palpebral et exophthalmie sur ostéome.* Acta Otorhinolaryngol Belg 1991;45:315-8.
- <sup>18</sup> Nabeshima K, Marutsuka K, Shimao Y, Uehara H, Kodama T. *Osteoma of the frontal sinus complicated by intracranial mucocele.* Pathol Int 2003;53:227-30.
- <sup>19</sup> Mugliston TAH, Stafford N. *A cranio-facial approach to large osteomas of the fronto-ethmoidal region.* J Laryngol Otol 1985;99:979-83.
- <sup>20</sup> Fobe L, de Melo EC, Cannone LF, Fobe JL. *Cirurgia de osteoma de seio frontal.* Arq Neuropsiquiatr 2002;60:101-5.

■ Received: February 18, 2004  
Accepted: May 6, 2004

■ Correspondence: Dr. Carlo Dispenza, via Paolo Emiliani Giudici 37, 90127 Palermo, Italy - E-mail: francesco.dispenza@poste.it