

Study of nasal valvular stenosis by means of acoustic rhinometry using Ognibene internal dilator

Studio delle stenosi valvolari nasali mediante rinomanometria acustica con dilatatore interno

I. TASCA, G. CERONI COMPADRETTI

Otorhinolaryngology Unit, AUSL Imola, Castel San Pietro Terme (BO), Italy

Key words

Nasal stenosis • Nasal valve • Diagnosis • Acoustic rhinometry

Parole chiave

Stenosi nasali • Valvola nasale • Diagnosi • Rinometria acustica

Summary

The nasal valve represents the main region of nasal respiratory resistance; therefore, even small deformities in this area can result in breathing disorders. A total of 93 patients (55 male, 38 female, mean age 37 years, range 16-52) suffering from nasal respiratory impairment due to valvular stenosis were recruited to study nasal function by means of rhinomanometry and acoustic rhinometry. Examinations were made in basal conditions, after decongestion and using the Ognibene internal dilator. Of these patients, 75 underwent surgery for functional correction of valvular stenosis and were observed at follow-up 3 months later, to analyse the surgical outcome. A review of the data concerning acoustic rhinometry has proven that, on the basis of post-operative tests, Minimal Cross-sectional Area values almost match pre-operative findings, carried out with nasal dilator. The aim of the present study is to demonstrate that acoustic rhinometry, associated with rhinomanometry and carried out with the aid of Ognibene internal dilator, is a valid tool for the diagnosis of nasal valvular stenosis and can also be usefully employed in post-operative follow-up.

Riassunto

L'area valvolare rappresenta il sito principale delle resistenze respiratorie nasali; pertanto, deformità anche modeste di questa regione si traducono in rilevanti disturbi respiratori. In questo studio 93 pazienti, 55 maschi e 38 femmine (età media: 37 anni), affetti da insufficienza respiratoria nasale da stenosi della valvola sono stati sottoposti a valutazione della funzionalità nasale con rinomanometria e rinometria acustica. Gli esami sono stati effettuati in condizioni di base, dopo decongestione e con dilatatore, utilizzando il dilatatore interno di Ognibene. 75 pazienti sono stati sottoposti ad intervento chirurgico di correzione funzionale della stenosi valvolare secondo la tecnica di Sulsenti e, a distanza di 3 mesi, sono stati controllati con gli stessi esami funzionali per la valutazione del risultato chirurgico. L'analisi dei dati della rinometria acustica ha dimostrato come, alla prova di base postoperatoria, i valori della Minimal Cross-sectional Area siano pressoché sovrapponibili a quelli preoperatori eseguiti con test di dilatazione. Con questo studio, si intende dimostrare che la rinometria acustica, eseguita con l'ausilio del dilatatore interno di Ognibene, è un valido strumento di diagnosi delle stenosi valvolari nasali e può essere utilizzata anche per il follow-up postoperatorio.

Introduction

The nasal valve is a complex structure responsible for 70% of nasal respiratory resistance¹ and 44% of the total inspiratory resistance². The nasal valve is anatomically defined upper-laterally by the caudal extremity of the triangular cartilage and laterally from the empty triangle, tissue fibro-adipose stretched to the edge of the pyriform opening, in the middle from the nasal septum in its caudal portion, inferiorly from the lower edge of the pyriform opening and backwards from the head of the inferior turbinate. Morpho-functional modifications of this area lead to alterations in air flow, resulting in an increase in resistances and onset of nasal obstruction

symptoms³. For several years now, we have been using, in addition to rhinomanometry (RMM), also acoustic rhinometry (AR) in the evaluation of the nasal parameters. The Ognibene internal dilator in the RMM evaluation of valvular obstruction has demonstrated, in the past, to be of great diagnostic value⁴.

The aim of this study is to show that the use of this device, even for AR, represents a useful tool in the diagnostic workup of valvular stenosis and in the evaluation of the surgical outcome. Moreover, recently, with the systematic use of the valvular collapsibility test⁵, performed before the instrumental study, it is possible to obtain a targeted selection of patients presenting this condition.

Materials and methods

A total of 93 patients (55 male, 38 female, age range 16-52 years, mean 37), suffering from nasal respiratory obstruction, due to valvular stenosis, were enrolled in the study. Each patient underwent nasal endoscopy combined with the test of valvular collapsibility, respectively, for static evaluation of valvular area morphology and dynamic study of those stenoses due to collapse of the external lateral wall. All patients underwent nasal functional studies by means of RMM (Meditronic RMAC.01) and a continuous sound AR (S.R. Electronic 2000 PC). All examinations were performed by the same operator, after a 15-minute period of acclimatization. Each test was carried out in basal conditions and after decongestion. The decongestion test offered the possibility to detect patients in whom nasal obstruction was determined also by a mucous congestive component. As a result, 18 patients positive to this test were excluded from the study. Therefore, as far as concerns the remaining 75 patients (43 male, 32 female, age range 19-49 years, mean 34), stenosis of the valvular area was exclusively determined by a structural deformity. The obstruction was due to deviation of the nasal septum in 61 cases, collapse of the external lateral wall in 9 and to both these conditions in the remaining 5. The patients then underwent RMM and AR with the Ognibene internal nasal dilator. Due to its special conformation, it mimics the physiological conditions of the valvular area (Figs. 1-5). This provided adequate adhesion of the nozzle to the nostril and avoided possible dispersion of the acoustic signal. Surgical treatment was carried out for the functional correction of the septum in 61 patients, for correction of the valve according to the Sulstenti technique in 9, while both procedures were necessary in 5 cases. After 3 months, all patients were submitted to RMM and AR for evaluation of the surgical outcome. Data regarding nasal resistance (NAR) and

Minimal Cross-Sectional Area (MCA) are expressed as mean \pm standard deviation (SD).

Results

The AR, carried out in basal conditions, showed an MCA of $0.37 (\pm 0.16) \text{ cm}^2$ on the right and $0.36 (\pm 0.13) \text{ cm}^2$ on the left, with a distance from the nostril of, respectively, $1.92 (\pm 0.18) \text{ cm}$ and $2.01 (\pm 0.09) \text{ cm}$ (Total MCA – TMCA = $0.73 \pm 0.28 \text{ cm}^2$); after decongestion a value of $0.40 (\pm 0.15) \text{ cm}^2$, on the right, and $0.41 (\pm 0.11) \text{ cm}^2$, on the left, with a distance from the nostril of $1.84 (\pm 0.10) \text{ cm}$ on the right and $1.93 (\pm 0.13) \text{ cm}$ on the left (TMCA = $0.81 \pm 0.25 \text{ cm}^2$). Then, with the application of the valvular dilator, we noticed a MCA of $0.73 (\pm 0.11) \text{ cm}^2$, on the right and $0.69 (\pm 0.16) \text{ cm}^2$, on the left, with a distance from the nostril of $1.98 (\pm 0.16) \text{ cm}$ and $2.01 (\pm 0.11) \text{ cm}$, respectively (TMCA = $1.42 \pm 0.22 \text{ cm}^2$). The surgical result was evaluated by a subjective method by means of a questionnaire on the basis of the reduction or disappearance of the nasal obstructive symptoms, and with an objective method through RMM and AR carried out in basal conditions, 3 months after the operation. AR revealed an increase in MCA values compared to the pre-operative test. The value obtained substantially matched the pre-operative test carried out in dilation conditions, that is $0.71 (\pm 0.13) \text{ cm}^2$, on the right and $0.70 (\pm 0.11) \text{ cm}^2$, on the left, with a distance from the nostril of $1.90 (\pm 0.16) \text{ cm}$ and $1.93 (\pm 0.16) \text{ cm}$, respectively (TMCA = $1.41 \pm 0.23 \text{ cm}^2$). The rhinometric data obtained were then compared to those of a control group composed of 30 normal breathing patients (16 male, 14 female, age range 18-49 years (mean 31). In this sample of patients, the MCA value was $0.75 (\pm 0.13) \text{ cm}^2$, on the right, and $0.78 (\pm 0.12) \text{ cm}^2$, on the left, with a distance from the nostril of $1.87 (\pm 0.15) \text{ cm}$ and $1.85 (\pm 0.18) \text{ cm}$ (TMCA = 1.53

Table I. AR and RMM findings: preoperative TMCAs and Total NARs in basal condition, after decongestion and using the Ognibene internal dilator in comparison with those obtained at 3-month follow-up and in the control group. Data express mean \pm standard deviation.

	Basal preop	Decongestion preop	Decongestion + dilator preop	Basal postop	Control group
TMCA (cm ²)	0.73 \pm 0.28	0.81 \pm 0.25	1.42 \pm 0.22	1.41 \pm 0.23	1.52 \pm 0.21
Total NAR (P/cm ³ /s) insp	0.37 \pm 0.06	0.21 \pm 0.01	0.15 \pm 0.01	0.14 \pm 0.07	0.11 \pm 0.03
Total NAR (P/cm ³ /s) exp	0.34 \pm 0.05	0.22 \pm 0.03	0.13 \pm 0.02	0.15 \pm 0.02	0.12 \pm 0.08

$\pm 0.21 \text{ cm}^2$). TMCA's and the corresponding RMM values of total NARs are shown in Table I. The post-operative RM and RMM data, compared with those obtained from the control group, were consequently considered physiologic and objectively confirmed the solution of the obstructive symptoms reported by all patients. In order to evaluate the possible alterations of the acoustic wave determined by the insertion of the internal dilator at MCA level, we carried out a test with the Ognibene dilator in the control group and found no significant modification in the outline, compared to the basal test. Analysis of the comparative results between AR and RMM permitted the selection of a group of 9 patients in whom the obstruction was due exclusively to the collapse of the external lateral wall. In fact, after decongestion, the RMM sinusoid outline presented a morphology compatible with Cottle type II with evidence of a major increment in inspiratory resistances such as $0.92 (\pm 0.14) \text{ P/cm}^3/\text{s}$, on the right, and $1.02 (\pm 0.11) \text{ P/cm}^3/\text{s}$, on the left; while AR detected MCA values substantially within the normal range, i.e., $0.68 (\pm 0.15) \text{ cm}^2$, on the right and $0.67 (\pm 0.13) \text{ cm}^2$, on the left, with a distance from the nostril of $1.86 (\pm 0.14) \text{ cm}$ and $1.90 (\pm 0.17) \text{ cm}$, respectively. With the dilator, the inspiratory resistances became normal: $0.32 (\pm 0.11) \text{ P/cm}^3/\text{s}$, on the right, and $0.35 (\pm 0.13) \text{ P/cm}^3/\text{s}$, on the left, while the MCA was $0.72 (\pm 0.14) \text{ cm}^2$, on the right, and $0.70 (\pm 0.12) \text{ cm}^2$, on the left, with a distance from the nostril of $1.82 (\pm 0.15) \text{ cm}$ and $1.85 \text{ cm} (\pm 0.16)$, respectively (Table II).

Discussion

Nasal resistances to air flow are localized mainly in the valvular area⁶. Even small deformities of this region can lead to relevant increments in the inspiratory resistances, thus compromising the performances

of the subject, above all during physical effort, and, sometimes, causing disturbances during sleep⁷. Several reports have appeared in the literature concerning the use of nasal devices to contrast nasal obstruction due to collapse of the wing. With RMM, Lancer and Jones⁸ documented a reduction of nasal resistances with the use of the Francis dilator. Chaudhry et al.⁹, in a study on 33 patients with anterior nasal obstruction, observed a statistically significant reduction in rhinomanometric nasal resistances with the use of the internal nasal dilator. More recently, studies regarding the use of nasal dilators in snoring patients have appeared. Petruson¹⁰, with the use of an internal dilator, showed a reduction in snoring in 88% of patients, while Hoijer et al.¹¹ noticed a drop in the frequency and severity of the obstructive respiratory events in patients suffering from OSAS (Obstructive Sleep Apnea Syndrome).

Today, several types of nasal dilators are on the market, above all external. Several recent studies have highlighted that such devices determine an increment in nasal respiratory flow through the enlargement of the valvular area^{12,13}. With the use of such devices, Sharf et al.¹⁴ observed a subjective improvement in sleep quality, a reduction in snoring and in daily somnolence. Griffin et al.¹⁵ demonstrated, with a RM study, that external dilators, acting on an increment of MCA, improve nasal respiration resulting in a relative drop in cardiac frequency, ventilation and VO_2 during physical activity, compared to placebo. Therefore, external nasal dilators are systematically used also by athletes. The rationale concerning the use of such devices consists in the increment in nasal respiratory flow through widening the area of major resistance, which is, indeed, the valvular area¹⁶. Roithmann et al.¹⁷, studying subjects presenting nasal obstruction due to valvular stenosis with RMM and AR and, comparing the results with a group of healthy subjects, concluded that the external nasal dilator is a

Table II. Valvular stenosis due to collapse of external lateral wall (9 patients). MCA and NAR (insp and exp) values after decongestion and using Ognibene internal dilator. Data express mean \pm standard deviation.

AR decongestion (cm^2)		AR decongestion + dilator (cm^2)		RMM decongestion ($\text{P/cm}^3/\text{s}$) (insp)		RMM decongestion + dilator ($\text{P/cm}^3/\text{s}$) (insp)	
R	L	R	L	R	L	R	L
0.68 ± 0.15	0.67 ± 0.13	0.72 ± 0.14	0.70 ± 0.12	0.92 ± 0.14	1.02 ± 0.11	0.32 ± 0.11	0.35 ± 0.13
Distance from nostril (cm)		Distance from nostril (cm)		(P/cm ³ /s) (exp)		(P/cm ³ /s) (exp)	
R	L	R	L	R	L	R	L
1.86 ± 0.14	1.90 ± 0.17	1.82 ± 0.15	1.85 ± 0.16	0.43 ± 0.12	0.45 ± 0.13	0.33 ± 0.10	0.31 ± 0.13

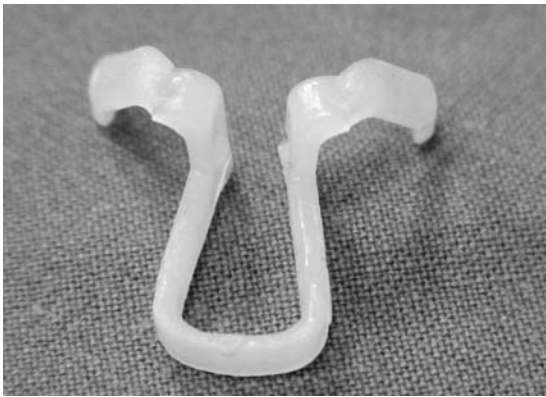

Fig. 1. Ognibene internal nasal dilator.



Fig. 2. Coupling of Ognibene internal nasal dilator with modified nozzle.

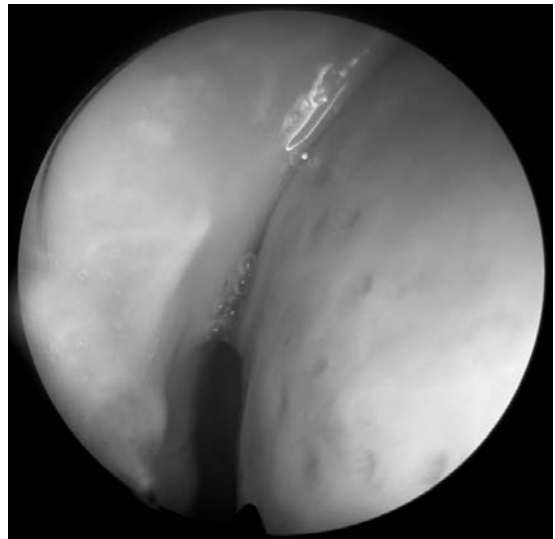


Fig. 3. Right valvular stenosis.

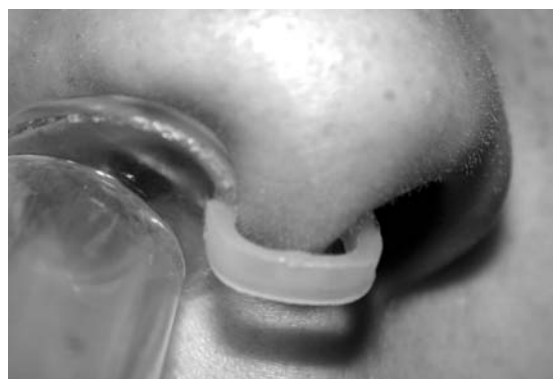

Fig. 4. Clinical application of Ognibene nasal dilator with modified nozzle for rhinometric examination.

valid non-surgical alternative in patients presenting nasal valvular obstruction. According to these data, the diagnosis of valvular stenosis can be objectively supported by RMM and AR using the Ognibene internal dilator in cases in which the decongestion test would not lead to substantial modifications compared to the examination performed in basal conditions. The association with RMM and AR plays a crucial role in the presence of obstruction due to the collapse of the external lateral wall in which an increment of nasal resistances occurs, while the rhinometric values remain within the normal range. Even if in this study no comparison between internal and external dilators has been made, the Ognibene inter-

nal dilator has, in our experience, been shown to be a reliable device which is not influenced by the inevitable variations due to the different elasticity of the tissues. In our opinion, this property could play an important role, above all, in the presence of a collapsing external lateral wall. It has the advantage of maintaining the opening of the nasal cavity constant with a physiologic angle of 15 degrees, and is, therefore, a method which can be repeated, and usefully employed in follow-up. Recently, Lorino et al.¹⁸ found, by means of a RM study, that the Nozovent internal dilator determines a greater reduction in nasal parameters compared to the external type. Zumegen et al.¹⁹ tested, by means of RMM, the Nasanita in-

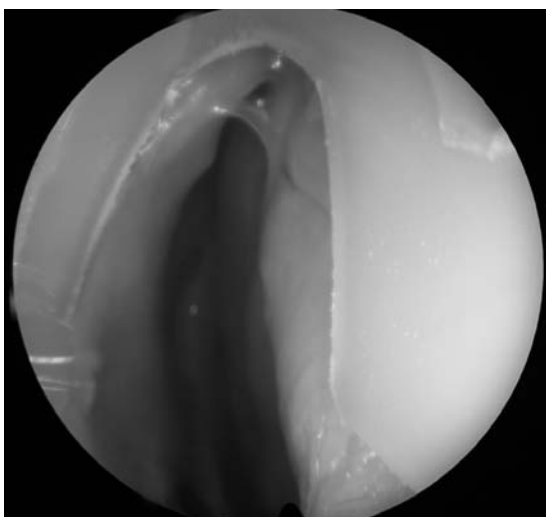


Fig. 5. Endoscopic view of internal dilator within right nasal cavity.

ternal dilator in a sample of healthy subjects and observed an increment in the expiratory and inspiratory flows of 54% and 55%, respectively. In our experience, the increment of MCA obtained with the application of the Ognibene dilator in patients with stenosis of the valvular area was of the order of 61%. Moreover, in the same sample of patients, we evaluated, through questionnaires, the grade of tolerability of the Ognibene dilator during the examination, and found a slight degree of discomfort, in 6% of the patients, which, nonetheless, allowed correct completion of the test, in each case.

References

- Uddstromer M. *Nasal respiration: a critical survey of some current physiological and clinical aspects on the respiratory mechanism with a description of a new method of diagnosis*. Acta Otolaryngol 1940;42(Suppl):3-146.
- Mann DG, Sasaki CT, Suzuki M, Fukuda H, Hernandez JR. *Dilator nasi muscle*. Ann Otol 1977;86:362-72.
- Sulsenti G, Palma P. *L'area valvolare nasale: struttura, funzione, clinica e terapia, la tecnica di correzione delle deformità valvolari secondo Sulsenti*. Acta Otolaryngol Ital 1989;22(Suppl):1-25.
- Sulsenti G. *L'uso dell'apparecchio di Ognibene nella diagnostica topografica delle deformità nasali*. In: Relazione Corso Internazionale "Chirurgia funzionale del naso". Bologna, 1980.
- Tasca I, Vicini C, Ceroni Compadretti G. *Classificazione dei siti ostruttivi nasali*. In: IV Convegno A.O.I.C.O. Gubbio, 17-18 January, 2003.

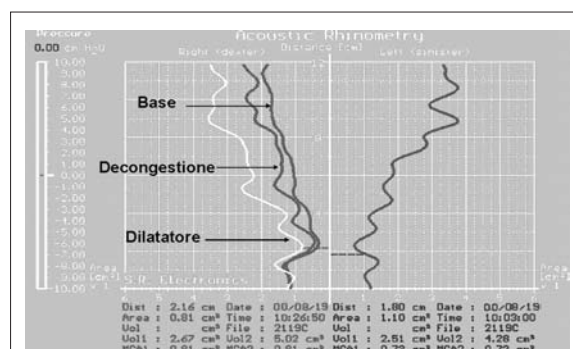


Fig. 6. Rhinometric outline with evidence of MCA variations in basal conditions, after decongestion and using Ognibene internal dilator.

Conclusions

- Study of valvular stenosis must always be carried out by means of RMM and AR, in basal conditions, after decongestion and using the nasal dilator.
- Integration of the results of these two tests is of critical value in valvular stenosis due to collapse of the external lateral wall.
- The Ognibene internal dilator is a well-tolerated diagnostic device. The geometric characteristics of this dilator and the use, in AR, of the modified nozzle offer the possibility to repeat the investigation with this method.
- RMM and AR with the dilation test are valid tools in the diagnosis of nasal valvular stenosis; and appear to be useful not only in defining the surgical strategy, but also in the follow-up.

- Haight JSF, Cole P. *The site and function of nasal valve*. Laryngoscope 1983;93:49-55.
- Irvine BWH, Dayal WS, Philippon EA. *Sleep apnea due to nasal valve obstruction*. J Otolaryngol 1984;13:37-8.
- Lancer M, Jones AS. *The Francis alae nasi prop and nasal resistance to air flow*. J Laryngol Otol 1986;100:539-41.
- Chaudhry MR, Akhtar S, Dwalsaint F. *Rhinomanometric evaluation of the improved mechanical therapeutic nasal dilator in patients with anterior nasal obstruction*. Rhinology 1996;34:32-4.
- Petruson B. *Better sleep with dilated nose*. Rhinology 1989;27:211-3.
- Hoijer U, Ejnell H, Hedner J, Petruson B, Eng LB. *The effect of nasal dilation on snoring and obstructive sleep apnoea*. Arch Otolaryngol Head Neck Surg 1992;118:281-4.
- Ng BA, Mamikoglu B, Ahmed MS, Corey JP. *The effect of external nasal dilators as measured by acoustic rhinometry*. ENT J 1998;77:840-4.

- ¹³ Kirkness JP, Wheatley JR, Amis TC. *Nasal airflow dynamics: mechanism and responses associated with an external nasal dilator strip*. Eur Resp J 2000;15:929-36.
- ¹⁴ Sharf MB, Brannen DE, McDannold M. *A subjective evaluation of a nasal dilator on sleep and snoring*. ENT J 1994;73:395-401.
- ¹⁵ Griffin JW, Hunter G, Ferguson D, Sillers MJ. *Physiologic effects of an external nasal dilator*. Laryngoscope 1997;107:1235-8.
- ¹⁶ Tasca I, Ceroni Compadretti G. *La rinomanometria e la rinometria acustica nella diagnostica della roncopia cronica*. In: *La Roncopatia Cronica*. Relazione Ufficiale, XCI Congresso Nazionale SIO; 2004. p. 235-248.
- ¹⁷ Roithmann R, Chapnik J, Cole P, Szalai, J, Zamel N. *Role of the external nasal dilator in the management of nasal obstruction*. Laryngoscope 1998;108:712-5.
- ¹⁸ Lorino A, Lofaso F, Drogou I, Abi-Nader F, Dahan E, Coste A, et al. *Effects of different mechanical treatments on nasal resistance assessed by rhinometry*. Chest 1998;114:166-70.
- ¹⁹ Zumegen C, Schneider D, Michel O. *Influence of an internal dilator (Nasanita) on nasal flow in healthy adults*. Laryngorhinootologie 2001;80:704-7.

■ Received: July 14, 2002
Accepted: June 15, 2004

■ Address for correspondence: Dr. I. Tasca, U.O. Otorinolaringoiatria, Ospedale Civile di Castel San Pietro Terme (BO), Viale Oriani 1, Castel San Pietro Terme (BO), Italy. Fax +39 051 6955229. E-mail: i.tasca@ausl.imola.bo.it