

# Tongue base reduction with hyoepiglottoplasty for the treatment of severe OSA

## Riduzione della base linguale e ioido-epiglottoplastica nel trattamento chirurgico dell'OSA severa

G. SORRENTI, O. PICCIN, G. SCARAMUZZINO, S. MONDINI<sup>1</sup>, F. CIRIGNOTTA<sup>1</sup>, A. RINALDI CERONI  
Otorhinolaryngology Unit, Department of Surgical Science and Reanimation; <sup>1</sup>Neurology Unit, "S. Orsola-Malpighi"  
Hospital, University of Bologna, Italy

### Key words

OSA • Tongue hypertrophy • Surgical treatment • Tongue base reduction

### Parole chiave

OSA • Macroglossia • Trattamento chirurgico • Resezione della base linguale

### Summary

Surgical treatment for retro-lingual obstruction in patients suffering from obstructive sleep apnea syndrome remains a problem for which there is no simple solution. The techniques most in use (tongue suspension, genioglossal advancement with hyoid suspension) are effective primarily as stabilization methods modifying neither tongue position, nor volume and only produce appreciable results when performed on non-overweight patients with respiratory disturbance index <40. For patients suffering from severe obstructive sleep apnoea syndrome in whom the most obvious morphological alteration is the presence of hypo-pharyngeal obstruction due to tongue base hypertrophy, who are overweight or suffering from moderate obesity, a surgical procedure aimed at reducing tongue volume and at repositioning the hyoid bone, even if invasive, leads to a favourable outcome. Herein, personal experience is described in a group of 8 patients presenting severe obstructive sleep apnoea syndrome incompatible with normal quality of life and normal life expectancy (mean respiratory disturbance index = 55.1) who underwent surgical resection of the tongue base with hyoepiglottoplasty. This technique, first described by Chabolle, differs radically from others inasmuch as it guarantees enlargement of the hypo-pharyngeal lumen and remodelling of the hyolingual complex. Using a suprahyoid cervical approach, it is possible to effect ample reduction of the tongue base with amplification of the hypo-pharyngeal airway without inducing problems as far as concerns either swallowing or speech.

### Introduction

The gradual increase, during the Nineties, of scientific interest in pathological snoring and obstructive sleep apnoea syndrome (OSAS) led to the development of a new branch of surgery comprising a large series of surgical techniques aimed at enlarging and stabilizing the supra-laryngeal airway. Nevertheless, due to the many causes leading to collapse of the pharyngeal airway during sleep and, indeed, to the difficulty experienced in detecting, by means of cur-

### Riassunto

La terapia chirurgica dell'ostruzione retrolinguale nei pazienti affetti da obstructive sleep apnoea (OSA) è ancora oggi un problema di non facile risoluzione. Le tecniche maggiormente utilizzate (sospensione linguale, avanzamento genioglossa con sospensione ioidica) hanno un'azione prevalentemente stabilizzatrice non modificando il volume e la posizione della lingua e, solo quando eseguiti in pazienti non in soprappeso e con RDI (respiratory disturbance index) <40, permettono di ottenere risultati apprezzabili. Nei pazienti affetti da OSA grave nei quali l'alterazione morfologica più evidente sia la presenza di ostruzione ipofaringea per macroglossia, e prevalentemente in soggetti in soprappeso o affetti da obesità, un intervento mirato alla riduzione del volume linguale ed al riposizionamento dell'osso ioidico, anche se invasivo, consente di ottenere risultati eclatanti. Gli Autori descrivono la propria esperienza relativa ad un gruppo di 8 pazienti affetti da OSA grave incompatibile con una normale qualità ed aspettativa di vita (RDI medio = 55,1) sottoposti ad intervento chirurgico di resezione della base linguale con ioido-epiglottoplastica. Tale tecnica, ideata da Chabolle, si differenzia radicalmente dalle altre in quanto garantisce una reale disostruzione dell'ipofaringe ed un rimodellamento del complesso ioido-linguale. Attraverso un approccio faringotomico mediano sovraioideo si realizza un'ampia resezione della base linguale con ampliamento reale del lume aereo ipofaringeo senza provocare disturbi della deglutizione e dell'articolazione della parola.

rent diagnostic techniques, the location, extent and pattern of the nocturnal obstruction, surgical treatment of OSAS, does not, still to-day, always lead to predictable and totally satisfactory results. Of the various surgical techniques for OSAS, tongue base reduction with hyoepiglottoplasty is considered an invasive approach to pharyngeal obstruction due to macroglossia and, more generally, to abnormalities of the hyolingual complex. This technique involves a significant reduction of the tongue base, completed by repositioning the hyoid bone, tongue muscle

structures and mouth floor into more physiological positions which results in enlargement of the pharyngeal air space as well as shortening of the length of the supralaryngeal airway, at risk of collapse resulting from endopharyngeal pressure variations during sleep. Tongue base reduction with hyoepiglottoplasty, therefore, differs radically from earlier techniques proposed for the treatment of hypo-pharyngeal obstruction in that it allows efficient remodelling of this region leading to excellent results in patients with severe OSAS in whom ventilatory treatment is not feasible. Only one trial has appeared in the literature, reported by Chabolle in 1999<sup>1</sup>, concerning 10 moderately obese patients with OSAS, in whom cure was achieved in 8 out of the 10 patients treated.

Personal experience, is herein described, in a series of 8 patients submitted to tongue base reduction and hyoepiglottoplasty.

## Patients and methods

During the period January 2001-March 2003 inclusive, 8 patients suffering from severe OSAS, non-compliant with positive airway pressure treatment (CPAP), underwent a combined operation comprising uvulopalatopharyngoplasty (UPPP) and tongue base reduction with hyoepiglottoplasty. One of the patients had already been unsuccessfully treated elsewhere with UPPP in association with tongue suspension. All patients had undergone the following pre-operative evaluations: 1) objective ENT examination completed by macroglossia assessment according to the modified Mallampati classification<sup>2</sup> and measurement of neck circumference; 2) lateral cranial teleradiography to obtain cephalometric analysis according to the Stanford protocol<sup>3</sup> (SNA – maxilla to cranial base, SNB – mandible to cranial base, PNS-P – posterior nasal spine to tip of uvula, PAS – posterior airway space, MP-H – mandibular plane to hyoid bone); 3) fibroendoscopy of the upper airways and digestive tracts using Muller's manoeuvre (inspiration against mouth and nostrils closed to generate negative pressure in the pharynx) was performed at retro-palatal and retro-lingual levels while the patient was awake. Nasopharyngoscopy with Muller's manoeuvre potentially simulates nocturnal upper airway collapse and this procedure may provide information concerning the location of upper airway closure; 4) nasal patency testing with active anterior rhinomanometry; 5) nocturnal polysomnography using ambulatory methodology (Embletta, Polymesam) and completion of a questionnaire to establish the degree of daytime sleepiness – Epworth Sleepiness Scale (ESS).

During the post-operative period, patients were monitored, in bed, by means of pulse oxymetry for 24

hours. Approximately 3 months after surgery, endoscopic and radiological (cranial teleradiography) examinations were carried out in all patients; on this occasion, patients and respective partners were asked to fill in a questionnaire to evaluate the subjective results of the operation, including ESS. The polysomnographic test was performed 4 to 6 months after the operation. In one case, the examination was repeated 18 months after surgery. Patients were considered responders to treatment if a significant reduction in the apnoea-hypoapnoea index or RDI was found (RDI reduced by 50% and <20) and improvement of subjective symptoms.

Swallowing was also studied by means of radiological assessment of the pharyngo-crico-oesophago-cardial tract following administration of a 5-10-20 cc liquid and semi-liquid bolus and of solid food to reveal the presence of eventual anomalies in the biomechanics of swallowing. Patients were also requested to complete a clinical questionnaire to assess the presence of symptoms suggesting dysphagia.

## SURGICAL PROCEDURE

The operation is performed under general anaesthesia and naso-oro-tracheal intubation must always be adequate for use of a flexible fibroscope. If scheduled, the oropharyngeal surgical phase, generally UPPP, is performed later. The pharyngotomic approach to the tongue base begins with an upper convex curvilinear median cutaneous incision 2 cm above the hyoid bone and with the preparation of a lower hinged flap comprising cutis, subcutis and platysma until the hyoid bone and the suprahyoid region are completely ex-

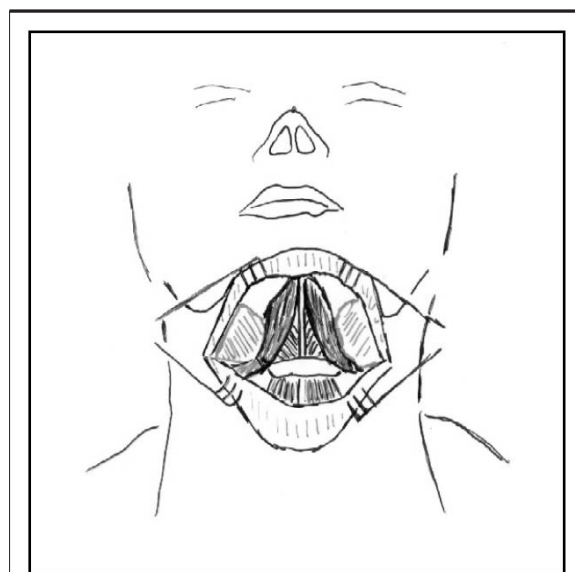


Fig. 1. Exposure of suprahyoid muscles.

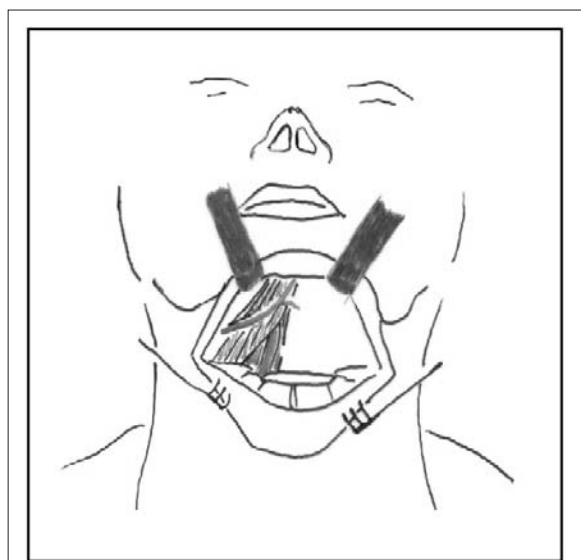


Fig. 2. Identification of neurovascular bundle.

posed. At this point, the anterior belly of the digastric muscles is isolated and displaced laterally and the buccal floor muscles are exposed (Fig. 1); thereafter, in a plane perpendicular to the laryngo-tracheal axis, an incision is made in these muscle structures which are shortened by approximately 1 cm in order to favour, in the healing phase, the upwards stabilization of the hyoid bone and the horizontalization of the mouth floor. The mylohyoid and geniohyoid muscles are first sectioned; then, before cutting the hyoglossal muscle, the hypoglossal nerve running on the muscle surface, accompanied by a vein, and the lingual artery running inside it, should be identified (Fig. 2). Dissection of these structures, which are followed as far

as entry into the body of the tongue and laterally reclined, is the most delicate stage of the operation. Thus, with the neurovascular bundles under continuous visualization, sectioning of the tongue musculature precedes inwards following a plane perfectly perpendicular to the axis of the neck before ending in the pharynx adjacent to the glossoepiglottal valleculae. Once this point is reached, the procedure continues with significant resectioning of the tongue base almost to the point of touching the circumvallate papillae, also extending laterally, if necessary (Fig. 3). After accurate haemostasis, we continue with closure of the pharyngotomic breach, with a hyoepiglottoplasty of five large reabsorbable stitches; the stitch in circles below the hyoid bone, then crosses the lingual face of the epiglottis (to promote its vertical stabilization) before including an ample section of the residual tongue base fragment (Fig. 3). The operation is then concluded performing the hyoid suspension: having created 2 openings adjacent to the lower border of the mandibular symphysis, the hyoid bone is raised as much as possible with two large absorbable stitches passed under the body of it before closing the pharyngotomic breach (Fig. 3). Reconstruction of the muscle floor and the cutaneous suture then follow. A nasogastric tube is then positioned to allow nutrition during the immediate post-operative phase. The operation is terminated with suturing of the tracheotomy.

## Results (Table I)

The mean age of the patients was 51.3 years (range 40-64), with a mean RDI of 55.1 (range 35-76) and mean body mass index (BMI) of 30.6 (range 27-34.6). The mean ESS was 14.3 (range 11-20). The coexistence of retro-palatal and retro-lingual obstruction was verified in all patients; the latter linked to significant macroglossia (grade III according to Mal-

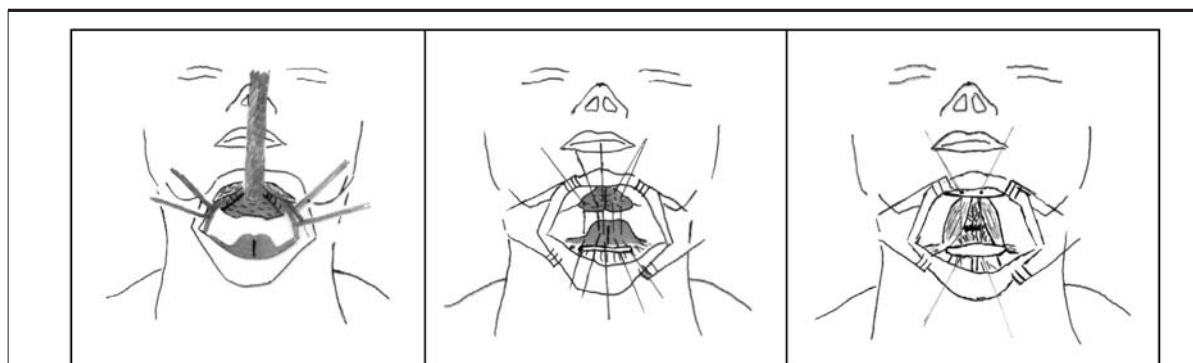


Fig. 3. Resection of tongue base (left); hyoepiglottoplasty (central) and hyoid bone suspension (right).

Table I.

Pts	Presurgical data						Post-surgical data								
	Age (yrs)	BMI	MM RL	MAL	Cephalom.			PSG			MM RL	Cephalom.			PSG
					PAS	Mp-h	RDI	Mean low SaO <sub>2</sub>	Tsleep SaO <sub>2</sub> < 90	BMI		Pas	Mp-h	RDI	
1	50	34.60	+	IV	6	25	50	73%	63%	31.83	13	17	4	89%	3%
2	52	26.98	+	IV	5	31	50	80%	53%	25.95	14	22	11	88%	4%
3	45	30.60	+	IV	10	27	70	79%	69%	27.76	14	20	18	87%	25%
4	47	30.12	+	III	8	25	55	75%	69%	27.60	13	15	12	88%	11%
5	40	27.00	+	III	11	34	50	87%	22%	25.55	15	17	18*	88%	17%
6	59	30.4	+	III	9	36	55	87%	27%	25.51	13	21	6	94%	0.5%
7	54	33.53	+	IV	11	27	76	75%	69%	28.2	14	16	2	94%	0.1%
8	64	32.2	+	IV	6	35	35	68%	63%	30.1	12	21	7	95%	3%

MM RL = retrolingual Muller manoeuvre  
 PAS = posterior airway space  
 Mp-h = mandibular plane hyoid bone distance  
 MAL = Mallampati classification for macroglossy  
 \*second control after 18 months

lamberti classification in 3 cases, grade IV in the other 5) in the absence of marked skeletal alterations (SNB  $>77^\circ$ ). No complications related to surgery were observed in the immediate post-operative phase. Tracheotomy was closed, in all patients, on the seventh day and, on average, oral feeding was recommenced after 11 days with no significant difficulties as far as concerns swallowing. Post-operative pain, treated with non-steroidal anti-inflammatory drugs i.v. for the first 4 days, was comparable to that experienced after UPPP alone. The mean period spent in bed was 15 days (range 12-19).

At 3-month follow-up, patients reported a marked improvement in the nocturnal respiratory disturbance with a clear improvement in sleep quality and reduction in daytime sleepiness (ESS = 5.3, range 4-9). Fiberoptic pharyngoscopy showed enlargement of the retrolingual air space with a negativization of Muller's manoeuvre, whilst the cephalometric analysis documented a marked enlargement of the PAS, horizontalization of the tongue floor and a rise in the physiological position of the hyoid bone with a mean MP-H reduction value from 30 (range 25-36) to 18.6 (range 15-22) (Fig. 4). The respective polysomnographic data showed cure in 7 patients. One case (patient previously submitted to UPPP surgery + tongue suspension) showed no change in results, on the first test, whilst the following polysomnographic test demonstrated a marked reduction in the nocturnal respiratory disturbance (RDI = 18).

The mean RDI improved from 51.3 to 9.7, with an 81% reduction; the mean low SaO<sub>2</sub> value from 78% to 90.4%. All patients were found to be responders to the treatment.

Videofluorographic evaluation of swallowing, performed, on average, 9.5 months after the surgical treatment, demonstrated the presence of minor sub-clinical alterations of the pharyngeal phase in 3 patients. In the first case, the presence was noted of

temporary stasis of part of the bolus, at the level of the valleculae, related to reduced tongue base propulsion, absence of deflection of the epiglottis and reduced rise of the hyoid bone and of the larynx, associated with the presence of minimal post-deglutition inhalation. In another case, evidence of reduced containment, at tongue base level, was found to be associated with a premature posterior fall of the bolus in the pyriform sinus with subsequent intradeglutitory penetration and postdeglutition inhalation. The third case presented bolus stasis, at the level of the valleculae, associated with a minimal intradeglutitory penetration. The presence of subjective symptoms, described as the sensation of "food stuck in the throat" and "less easy to swallow than normal", was encountered in 2 cases. Only one of these patients presented swallowing anomalies, upon videofluorographic examination.

## Discussion

Surgical treatment of retrolingual obstruction is still, today, a not easily solved problem. The most frequently used techniques (tongue suspension, genioglossal advancement, hyoid suspension) function above all as stabilization methods, putting the tongue and pharyngeal musculature in tension but not, in fact, modifying the volume and position of the tongue. Phase I of the Stanford protocol (UPPP + genioglossal advancement + hyoid suspension)<sup>4</sup> has also produced variable and often disappointing results, in Europe, thereby reducing the therapeutic efficiency, according to some Authors<sup>5,6</sup>. In the last few years, reports concerning surgical attempts at direct intervention on the tongue aimed at reducing the impact on the aero-hypo-pharyngeal lumen, have appeared in the literature. Fujita et al., in 1991<sup>7</sup>, reported the results obtained in a group of 12 patients with a mean RDI of 62, treated endoscopically with CO<sub>2</sub> laser to reduce obstruction, related to tongue hypertrophy (Laser Midline Glossectomy); 5 cases proved to be responders (patients having non-circumferential antero-posterior collapse). Woodson and Fujita, in 1992<sup>8</sup>, described a modification of the preceding techniques, still performed endoscopically, defined as "Lingualplasty": in this case, resectioning was carried out more laterally and further back, and the resection margins sutured in order to advance the tongue base, as much as possible. Patients were selected on the basis of endoscopic data (Fujita IIb and III) and demonstrated massive tongue basis with an antero-posterior obstructive pattern. The technique commenced with a preliminary tracheotomy; 77% of the patients proved to be responders (mean RDI = 58.8) whilst in the post-operative phase, frequent (27%) and major complications (oedema, haemor-

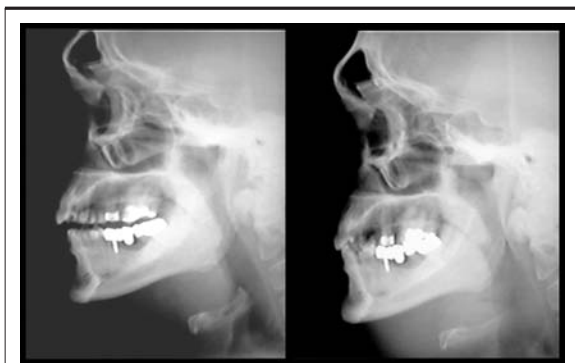


Fig. 4. Cephalometric evaluation pre (left) and post surgery (right).

rhage, persistent odynophagia) were reported. Miljetieg and Tuinnereim, in 1992<sup>9</sup>, reported good results (57% responders) in a group of 26 patients (mean RDI = 30) treated with “uvupalatopharyngoglossoplasty”, that consists in an UPPP extended to the lateral borders of the tongue base. Mickelson and Rosenthal, in 1997<sup>10</sup>, reported on 12 cases of “midline glossectomy and epiglottectomy” performed endoscopically with CO<sub>2</sub> laser, with tracheotomy for obese patients (mean BMI 36) affected with medium to severe OSAS; only in 3 cases was a positive result observed.

Powell et al., in 1999<sup>11</sup>, described a new mini-invasive technique for reduction of tongue base volume by means of radiofrequency: in a group of 18 patients, a mean tongue volume reduction of 17% was reported, with a mean RDI reduction from 39.8 to 18.6. In a later study on 56 patients, Woodson et al.<sup>12</sup> obtained a mean RDI reduction from 40.5 to 32.8. Stuck et al., in 2002<sup>13</sup>, reported the results of a group of 18 patients with a RDI reduction from 32.1 to 24.9; 6 patients achieved a post-operative RDI of <20. Riley et al.<sup>14</sup> recently described a slight variation to this technique: radiofrequency, besides application on the tongue base and the area surrounding the circumvallate papillae, was also performed on the ventral surface of the tongue and at the level of genioglossal insertion. In a group of 19 patients, a mean RDI reduction from 35.1 to 15.1 was achieved; 12 patients were cured (63.1%).

In 1999<sup>1</sup>, Chabolle reported positive results in 8 out of 10 patients using a median-pharyngotomic approach to reduce the tongue base, reserving this treatment for patients with severe OSAS (mean RDI 70), obese patients (BMI 32) and non-N-CPAP-compliant, in whom a marked anomaly of the hyolingual complex was present. According to Chabolle, these anomalies can be revealed by means of complex cephalometric measurements with MRI (total tongue surface >28 cm<sup>2</sup> and lingual area below the mandibular floor > 4 cm<sup>2</sup>) besides cranial telerradiography (oropharyngeal surface > 25 cm<sup>2</sup>). These anatomic alterations are, however, traceable to a postero-inferior

dislocation of the tongue mass with relative lowering of the hyoid bone.

Personal experience of tongue base reduction with hyoepiglottoplasty, although still numerically limited, is highly positive and encouraging: cure was achieved in all those patients who had shown very severe nocturnal respiratory disturbances, incompatible with normal life expectancy and quality of life. No post-operative complications were experienced, or negative effects on quality of life, the return to normal oral feeding was rapid and complete and, furthermore, videofluorographic examinations did not reveal significant modifications in the oral and pharyngeal phases of swallowing. Scrupulous pre-operative evaluation of patients led to a 100% rate of responders. Indications for this type of operation must be based upon the presence of a marked hypo-pharyngeal obstruction, due primarily to anomalies of the hyolingual complex, which, in our opinion, are the finding of marked lowering of the position of the hyoid bone with cephalometric measure MP-H >25 mm; marked hypopharyngeal obstructions from tongue base hypertrophy with laryngeal vestibule not visible at fibroscopy; grade IV macroglossia according to the Mallampati scale.

In the event skeletal alterations are present, causing a significant reduction in the diameter of the principle airways, we consider, in agreement with Chabolle, bimaxillary advancement as mandatory; this treatment, whilst, seemingly, less traumatic and “radical” compared to basiglossectomy, also has precise indications and is not free from risks and adverse effects for the patient<sup>15</sup>.

In conclusion, in the case of failure to tolerate N-CPAP, it is feasible, in carefully selected patients with severe OSAS, absence of skeletal anomalies and marked pharyngeal obstruction associated with macroglossia, to proceed with an invasive technique which, however, results in significant deobstruction and stabilization of the hypopharynx, resolving OSAS without leading to disorders in swallowing and speech.

## References

- Chabolle F, Wagner I, Blumen MB, Séquert C, Fleury B, De Dieuleveult T. *Tongue base reduction with hyoepiglottoplasty: a treatment for severe obstructive sleep apnea*. *Laryngoscope* 1999;109:1273-80.
- Friedman M, Tanyeri H, La Rosa M, Landsberg R, Vaidyanathan K, Pieri S, et al. *Clinical predictors of obstructive sleep apnea*. *Laryngoscope* 1999;109:1901-7.
- Riley RW, Guilleminault C, Herran J, Powell NB. *Cephalometric analysis and flow loops in obstructive sleep apnea patients*. *Sleep* 1983;6:303-11.
- Riley RW, Powell NB, Guilleminault C. *A surgical protocol for dynamic upper airway reconstruction*. *J Oral Maxillofac Surg* 1993;51:742-7.
- Vilaseca I, Moreno A, Montserrat JM, Santamaria J, Iranzo A. *Usefulness of UPPP with genioglossus and hyoid advancement in the treatment of obstructive sleep apnea*. *Arch Otolaryngol Head Neck Surg* 2002;128:435-40.
- Bettega G, Pépin JL, Veale D, Deschaux C, Raphael B, Levy P. *Fifty-one consecutive patients treated by maxillofacial surgery*. *Am J Respir Crit Care Med* 2000;162:641-9.
- Fujita S, Woodson BT, Clark JL, Wittig R. *Laser midline glossectomy as a treatment for obstructive sleep apnea*.

- Laryngoscope 1991;101:805-9.
- <sup>8</sup> Woodson BT, Fujita S. *Clinical experience with lingualplasty as a part of treatment for severe sleep apnea*. Otolaryngol Head Neck Surg 1992;107:40-8.
- <sup>9</sup> Miljetieg H, Tvinnereim M. *Uvulopalatopharyngoglossoplasty (UPPGP) in the treatment of obstructive sleep apnea syndrome*. Acta Otolaryngol (Stockh) 1992;492:96-9.
- <sup>10</sup> Mickelson SA, Rosenthal L. *Midline glossectomy and epiglottidectomy for obstructive apnea syndrome*. Laryngoscope 1997;107:614-9.
- <sup>11</sup> Powell N, Riley R, Guilleminault C. *Radiofrequency tongue base reduction in sleep related breathing: a pilot study*. Otolaryngol Head Neck Surg 1999;120:656-64.
- <sup>12</sup> Woodson BT, Nelson L, Mickelson S, Huntley T, Sher A. *A multi-institutional study of radiofrequency volumetric tissue reduction for OSAS*. Otolaryngol Head Neck Surg 2001;125:303-11.
- <sup>13</sup> Stuck BA, Maurer JT, Verse T, Hormann K. *Tongue base reduction with temperature-controlled radiofrequency volumetric tissue reduction for treatment of obstructive sleep apnea syndrome*. Acta Otolaryngol (Stockh) 2002;122:531-6.
- <sup>14</sup> Riley R, Powell N, Li K, Weaver E, Guilleminault C. *An adjunctive method of radiofrequency volumetric tissue reduction of the tongue for OSAS*. Otolaryngol Head Neck Surg 2003;129:37-42.
- <sup>15</sup> Hochban W, Brandenburg U, Peter JH. *Surgical treatment of obstructive sleep apnea by maxillomandibular advancement*. Sleep 1994;17:624-9.

■ Received: November 19, 2003  
Accepted: April 19, 2004

■ Address for correspondence: Dr. G. Sorrenti, U.O. ORL, Policlinico "S. Orsola-Malpighi", Via Massarenti 9, 40138 Bologna, Italy. Fax +039 051 6363525. E-mail: gisorrenti@yahoo.it