

Bile reflux as possible risk factor in laryngopharyngeal inflammatory and neoplastic lesions

Il reflusso biliare quale possibile fattore di rischio nella patologia flogistica e neoplastica faringo-laringea

J. GALLI, L. CALÒ, S. AGOSTINO, G. CADONI, B. SERGI, R. CIANCI¹, G. CAMMAROTA¹
Institute of Otorhinolaryngology

¹ Institute of Geriatric and Internal Medicine, Sacro Cuore Catholic University, Rome, Italy

Key words

Larynx • Inflammatory lesions • Laryngeal tumours • Bile

Parole chiave

Laringe • Patologia infiammatoria della laringe • Carcinoma della laringe • Reflusso biliare

Summary

Laryngopharyngeal reflux is now of major interest as an aetiological factor in chronic inflammatory and neoplastic lesions of upper digestive tract. However, reports in the literature refer only to the irritating action of the acid component of reflux, while possible damaging action of other reflux components remains unknown. Aim of this study was to verify the hypothesis that alkaline-bile reflux could also be involved in onset of inflammatory, precancerous and neoplastic laryngeal lesions. A total of 40 consecutive gastrectomized patients coming to our Clinic from Gastroenterology Outpatient Unit for an anamnestic and clinical evaluation with videolaryngoscopy of upper digestive airways, entered the study. All presented bile or alkaline reflux as a direct consequence of gastroduodenal anastomosis (Billroth I) and gastrojejunal anastomosis (Billroth II) performed over a time span >20 years. Oesophagogastroduodenoscopy revealed the presence of bile in the residual gastric cavity in all operated patients objectively confirming duodenogastric reflux. Examination of data showed that 3 patients (7.5%) had undergone CO₂ laser cordectomy in the 3 years prior to the study for squamous cell laryngeal carcinoma, 3 patients (7.5%) had leukoplakia, 8 (20%) vocal cord chronic oedema with signs of chronic diffuse laryngitis, 6 (15%) posterior laryngitis, 8 (20%) interarytenoid oedema while only 12 (30%) showed no ENT lesions. Statistical analysis revealed a significant correlation between incidence of inflammatory and neoplastic laryngeal lesions and type of surgery (Billroth II and total gastrectomy) with respect to other types of gastric resection. There was also a significant increase in presence and severity of laryngopharyngeal lesions in relation to time elapsed after surgery. These results, although preliminary, seem to confirm that some components of reflux (duodenal content), other than the acid component, play a damaging role involved in the onset of multiple clinical signs and symptoms of laryngopharyngeal reflux disease. It is concluded that systematic use of bile measurement, together with 24-hour pH monitoring, is advisable in subjects with clinical signs and symptoms of laryngopharyngeal reflux, but unresponsive to classic medical treatment, and in gastrectomized patients in order to confirm, on larger series, this fascinating aetiopathogenetic hypothesis.

Riassunto

Il reflusso faringo-laringeo (RFL) sembra ormai riscuotere grande interesse come fattore eziologico sia nella patologia flogistica cronica che in quella neoplastica delle VADS. Tuttavia i vari studi riportati in letteratura sono riferiti solo all'azione irritante della componente acida del reflusso, mentre non è nota, a tutt'oggi, la possibile azione lesiva di altre componenti del refluito patologico. Scopo del presente lavoro è stato quello di verificare l'ipotesi che il reflusso alcalino-biliare, in analogia con quanto riportato per il distretto gastro-esofageo, possa essere anch'esso coinvolto nell'insorgenza di lesioni flogistiche, precancerose e neoplastiche laringee. Sono stati valutati pertanto 40 pazienti consecutivi gastrectomizzati inviati dall'Ambulatorio di gastroenterologia alla nostra Clinica per una valutazione anamnesticoclinica e videolaringoscopica delle vie aereo-digestive superiori, perché affetti da reflusso biliare o alcalino come diretta conseguenza degli interventi di gastroduodenoanastomosi (Billroth I) e gastrodigiunoanastomosi (Billroth II) subiti in un arco di tempo > di 20 anni. La valutazione degli esami EGDscopici ha messo in evidenza in tutti gli operati la presenza di materiale biliare nella cavità gastrica residua confermando in modo obiettivo il reflusso duodeno-gastrico. All'analisi dei dati esaminati inoltre è emerso che 3 soggetti (7,5%) erano stati sottoposti a cordectomia laser CO₂ nei tre anni precedenti lo studio perché affetti da carcinoma squamocellulare laringeo, 3 (7,5%) presentavano leukoplakia, 8 (20%) edema cronico delle corde vocali con note di laringite cronica diffusa, 6 (15%) laringite posteriore, 8 (20%) edema della regione interarytenoidea; soltanto 12 pazienti (30%) non presentavano lesioni ORL. L'analisi statistica ha evidenziato una correlazione significativa tra incidenza di patologie laringee infiammatorie e neoplastiche e tipologia di intervento chirurgico (gastroresezione secondo Billroth II e gastrectomia totale) rispetto agli altri tipi di gastroresezione. È stato anche rilevato un incremento significativo di presenza e gravità delle lesioni faringo-laringee rispetto al tempo trascorso dall'intervento. Gli Autori sottolineano che i dati ottenuti, benché preliminari, sembrano conferire anche ad altre componenti del refluito (contenuto duodenale), oltre a quella acida, un ruolo lesivo implicato nell'insorgenza di molteplici sintomi e segni clinici della malattia da reflusso faringo-laringeo. Concludono auspicando l'utilizzo sistematico dell'indagine bilimetrica in coloro che riferiscono sintomi e segni clinici indicativi di RFL ma non responsivi alla classica terapia medica e nei pazienti gastroresecati per poter confermare su casistiche più ampie, ed in maniera altamente specifica tale suggestiva ipotesi eziopatogenetica.

Introduction

Much interest has recently been focused on laryngopharyngeal reflux (LPR) as an aetiological factor in chronic inflammatory and neoplastic lesions of the upper digestive tract¹⁻⁴.

Numerous reports have appeared in the literature, over the years, on this aetiopathogenic correlation. However, no direct relationship between the irritating action of reflux, on the laryngopharyngeal mucosa and the onset of inflammatory and neoplastic lesions, has been shown⁵⁻¹⁰.

The recent observation of cases of oesophagitis in patients with achlorhydria, previously submitted to gastrectomy (Billroth I and II, Roux-en-Y or total gastrectomy) has demonstrated the damaging effect of duodenal (alkaline) secretion on the oesophageal mucosa¹¹⁻¹³.

The aim of this study was to evaluate, in a group of patients undergoing gastric resection with different technical procedures, the possible damaging action of alkaline-bile reflux on the mucosa of the upper digestive tract and, in particular, its possible aetiopathogenic role in the onset of inflammatory, precancerous and neoplastic laryngeal lesions.

Material and Methods

Forty consecutive gastrectomized patients, 28 males (mean age 65.9 ± 9.9 years), 12 females (mean age 57.83 ± 13.84 years), sent from the Gastroenterology Outpatient Unit to our Clinic for an anamnestic and clinical evaluation with videolaryngoscopy of the upper digestive tract, entered the study. All patients underwent oesophagogastroduodenoscopy (EGDS) and ENT control with electronic videolaryngoscopy. As far as concerns gastric resections, these comprised: Billroth II in 26 patients (20 males mean age 62.95 ± 9.93 years; 6 females, mean age 67.50 ± 8.91); Billroth I in 8 (4 males mean age 73.50 ± 9.03 years; 4 females, mean age 46.75 ± 10.40 years); total gastrectomy in 4 (3 males, mean age 74.76 ± 4.72 years; 1 40-year old female): Roux-en-Y in 2 (1 69-year-old male; 1 62-year-old female). Of these, 32 (24 males; 8 females) underwent surgery (mean time after gastric resection 25.62 ± 9.81 years) for ulcer, 8 (4 males; 4 females; mean time after gastric resection 4 ± 1.77 years) for gastric cancer. In 12 patients (7 males, 5 females) gastric resection had been performed <10 years previously; in 13 (8 males, 5 females) the time elapsing after surgery was between 10 and 20 years. In the remaining 15 (13 males; 2 females), surgery had been performed >20 years previously. After giving informed consent, all patients underwent indirect laryngoscopy and electronic videolaryngoscopy and, in the case of suspected neoplastic

processes, microlaryngoscopy with biopsy was also performed. Typical symptoms of laryngopharyngeal reflux disease (heartburn, retrosternal pain, regurgitation), ENT symptoms (cough, hoarseness, foreign body sensation, dysphagia, dysphonia), smoking and alcohol habit, were evaluated, based on a questionnaire validated with a 0 to 3 score (0 = no symptoms; 3 = severe symptoms).

Statistical analysis

Fisher exact test was used in the statistical analysis ($p < 0.05$) to compare the incidence of the various laryngeal lesions in relation to the different types of gastric resection performed. Kruskal Wallis test ($p < 0.05$) was used to evaluate the correlation between the presence of the different laryngeal lesions observed and the time elapsing after gastrectomy.

Results

EGDS showed, in all patients, bile material in the residual gastric cavity, confirming the presence of gastroduodenal reflux. There were also endoscopic signs of GERD in 82.5% of patients, namely: oesophagitis in 37.5%; hiatal hernia in 25%; hiatal hernia associated with oesophagitis in 15%, Barrett's oesophagus with histological diagnosis of metaplasia without dysplasia in 5%; 17.5% of patients did not show any pathologic findings on endoscopy.

An attempt was made to correlate these findings with patient history and clinical and ENT findings. Three patients (7.5%) had undergone laser CO₂ cordectomy in the three years prior to the study on account of squamous cell laryngeal carcinoma (3 males, of whom 1 non smoker and 2 smokers; 2 treated with Billroth II operation and 1 with total gastric resection; mean time elapsing between gastric resection and the onset of laryngeal neoplasm was 31.16 ± 8.54 years). Three patients (7.5%) showed leukoplakia (2 males, 1 female of whom 2 non smokers and 1 smoker all of whom had undergone Billroth II operation, with a mean time elapsing after gastric resection of 24.75 ± 10.24 years); 8 (20%) showed chronic vocal cord oedema with signs of chronic diffuse laryngitis (6 males, 2 females) while only 12 patients (30%) did not show ENT lesions (7 males, 5 females, 6 treated with Billroth II, 1 with Roux-en-Y) of whom 8 had undergone surgery < 10 years previously (mean 3.4 ± 2.07); 4 between 10 and 20 years previously (mean 18 ± 2.82 years).

The statistical analysis revealed a significant correlation ($p < 0.05$; Fisher test) between the incidence of laryngeal neoplasms and type of surgery (Billroth II operation and total gastrectomy) with respect to the

Table I. Incidence of laryngeal lesions in patients undergoing Billroth II operation vs other types of gastric resection.

	Squamous cell carcinoma	Leucoplakia	Interarytenoid oedema	Posterior laryngitis	Laryngeal inflammation	No lesions
Billroth I	2.5%	10%	5%	7.5%		
Billroth II*	5%	7.5%	12.5%	5%	12.5%	17.5%
Gastrec. tot*	2.5%	2.5%	2.5%	2.5%		
Roux-en-Y	2.5%	2.5%				
Total	7.5%	7.5%	20%	15%	20%	30%

* p<0.05

other types of gastric resection. There was a significant increase in laryngeal lesions (leukoplakia, interarytenoid oedema, vocal cord oedema with signs of chronic laryngitis, posterior laryngitis) in those operated with Billroth II operation as compared to those submitted to other types of gastric resection (Table I). The statistical analysis using the Kruskal Wallis test to evaluate the presence of ENT lesions (inflammatory lesions, interarytenoid oedema, vocal cord oedema with signs of chronic laryngitis, posterior laryngitis, leukoplakia, carcinoma, absence of lesions) and the time elapsing after surgery (group 1: <10 years; group 2: 10-20 years; group 3: >20 years) revealed a significant increase ($p<0.01$) in the presence and severity of ENT lesions in group 3 as compared to groups 1 and 2 (Table II and Fig. 1).

No statistically significant correlation was observed between endoscopic reflux lesions and the different types of ENT lesions (Table III).

In the anamnestic evaluation, 18/40 patients reported typical ENT symptoms, distributed as follows: dysphonia (7 patients); chronic throat clearing-pharyngeal lump (8 patients); dysphagia (3 patients) (Table IV).

Discussion

The term bile or alkaline reflux indicates the retro-

grade progression of duodenal contents into the stomach and, in some cases, into the oesophagus. This is a normal physiologic event which, however, may become pathologic^{7 14 15} when it is excessive and cause the onset of gastric (gastritis, ulcer, gastric adenocarcinoma) and oesophageal (oesophagitis, adenocarcinomas, squamous cell carcinoma) diseases^{11 16-18}. This type of reflux, defined as alkaline or bile reflux up to 1999, has very recently been redefined by Vaezi et al. as duodeno-gastric reflux (DGR) or duodeno-gastro-oesophageal reflux (DGER), respectively, terms that better identify the organs involved by the reflux, its contents composed of bile as well as of other pancreatic juice components and of duodenal secretions and the associated not necessarily alkaline ($pH>7$) environment¹⁹⁻²¹. Aetiopathogenically, DGER can be subdivided into primary and secondary. Primary DGER is caused by the non-coordinated pyloric closure and duodenal contraction for altered sphincter motility (idiopathic or secondary to cholecystectomy, lithiasis, *Helicobacter pylori* infection). Secondary DGER is correlated with operations of gastric resection or pyloroplasty with consequent impairment of the anatomic integrity of the pylorus, and consequent impaired function^{17 22 23}.

As far as concerns the secondary complications of gastric resection (Billroth I with gastro-duodenal anastomosis; Billroth II with gastro-jejunal anastomosis, Roux-en-Y and total gastrectomy) DGER has

Table II. ENT disorders in patients grouped according to the time elapsed after surgery.

	Group 1 <10 years	Group 2 10-20 years	Group 3* >20 years
Squamous cell carcinoma			3
Leucoplakia			3
Inflammatory lesions§	4	9	9
No lesions	8	4	
Total	12	13	15

§: interarytenoid oedema, laryngeal inflammation, posterior laryngitis. * p<0.01

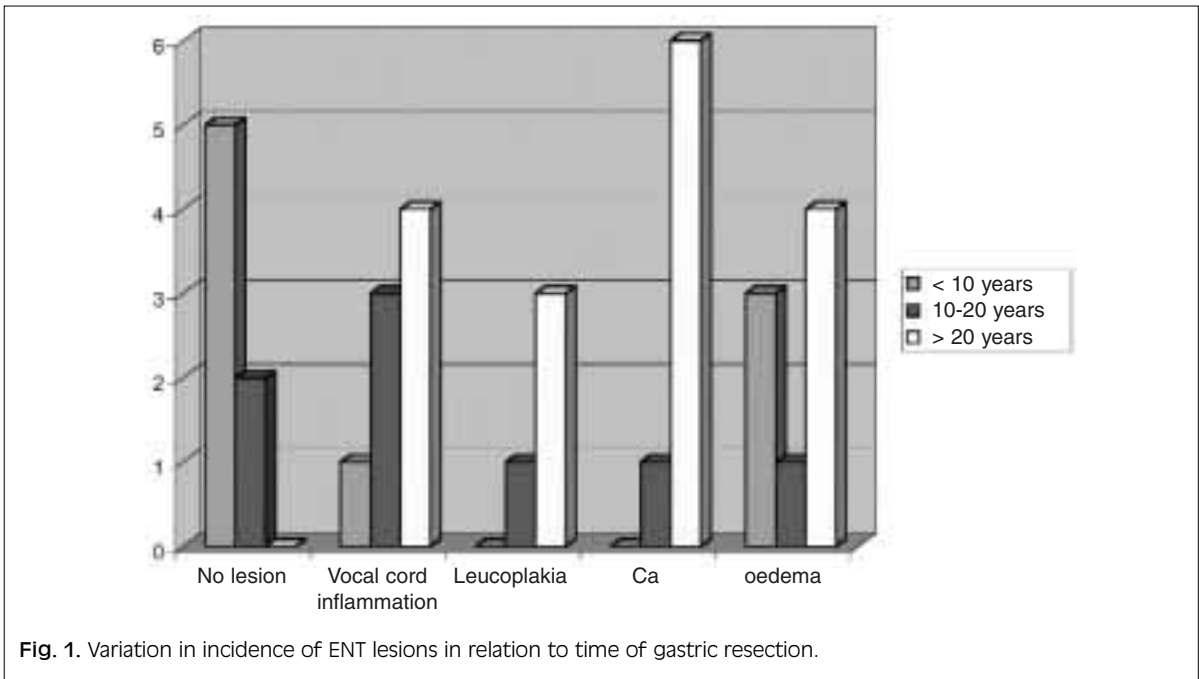


Fig. 1. Variation in incidence of ENT lesions in relation to time of gastric resection.

Table III. Incidence of endoscopic esophageal lesions observed in patients with various types of ENT lesions.

	Squamous cell carcinoma	Leucoplakia	Interarytenoid oedema	Laryngeal inflammation	Posterior laryngitis	No lesions	Total
Oesophagitis	2.5%		5%	10%	5%	5%	37.5%
Hiatal hernia	2.5%		2.5%	5%	5%	7.5%	25%
EJ-Es		5%	2.5%		5%	2.5%	15%
Barrett		2.5%			2.5%		5%
No lesions	2.5%		10%		2.5%	2.5%	17.5%
Total	7.5%	7.5%	20%	15%	20%	17.5%	100%

Table IV. Correlation between endoscopic findings and ENT symptoms.

	Cough	Dysphonia	Chronic-throat clearing-pharyngeal lump	Dysphagia
Squamous cell carcinoma		3		1
Leucoplakia	2		1	
Interarytenoid oedema		1	3	
Laryngeal inflammation			3	
Posterior laryngitis			1	
Total patients = 18	2	7	8	1

been overlooked for a long time. Only over the last few years has the clinical importance of the damaging effect of this type of reflux (bile acids, trypsin,

lysolecithin) on the gastro-oesophageal mucosa has been stressed, with the definition of inflammatory (alkaline gastritis and oesophagitis)²⁴, preneoplastic

(Barrett's oesophagus) or frankly neoplastic patterns (gastric and oesophageal adenocarcinoma, oesophageal squamous cell carcinoma)^{16 19 25} present in gastrectomized patients with secondary reflux, as well as in those with lithiasis or post-cholecystectomy syndrome with primary reflux²¹.

Indeed, the erosive alkaline action is caused by bile, pancreatic juice or both and a major role has now been identified in trypsin which, associated with other components of the duodenal content, weakens the mucosal oesophageal barrier resulting in a variation in the difference in cell potential with consequent back-diffusion of hydrogen ions²⁴.

Therefore, in agreement with these observations and considering that in the literature and in clinical practice, a new clinical entity represented by laryngo-pharyngeal reflux disease is clearly gaining ground^{2 13 26}, a possible damaging role, at the level of the upper digestive airway mucosa, is hypothesized for alkaline reflux components. A group of gastrectomized patients, enrolled at the Gastroenterology Outpatient Unit of our Polyclinic was analysed. Patients were affected by achlorhydria and, therefore, exposed to relevant episodes of secondary DGER.

The results of this study showed a significant increase ($p < 0.01$) in the presence and severity of ENT lesions in patients who had undergone gastric resection > 20 years earlier, as compared to those treated < 20 years earlier. Recent data based on the study of bile reflux in gastrectomized patients evaluated with spectrophotometry (Bilitec) have demonstrated a higher incidence of reflux after Billroth II, Roux-en-Y operation and gastric resection²². In this study, a significant increase ($p < 0.05$) in inflammatory and neoplastic lesions was observed in patients submitted with Billroth II as compared to those undergoing other types of surgery.

The present series was too small to be studied with a multivariate analysis. However, it was seen that in 6/11 non-smoking patients (54%), cancer or precancerous disease was present. This finding confirms the suspicion that bile reflux, as already hypothesized by various Authors for acid reflux, could be considered a risk factor or cofactor in the onset of inflammatory and neoplastic laryngeal lesions, although, at present, a direct causative relationship between the irritative effect of reflux on upper digestive tract mucosa and onset of the lesion remains to be demonstrated. Indeed, substances present in alkaline reflux responsible for the inflammatory and/or carcinogenic action, have not been identified, as yet, as it is not known whether they are endogenous or exogenous compounds. In the first case, they could be DGER components as bile salts and nitrosamines from which they derive, free oxygen radicals formed, in the pres-

ence of inflammation, cell proliferation and leukocyte infiltrations, could be the cause of the damaging action. In the second case, alkaline reflux might act as a predisposing factor before chronic inflammation and subsequent carcinogenesis, favouring the action of exogenous substances as volatile nitrosamines contained in cigarettes or environmental polluting substances ingested via the food chain.

However, at present, the model of chronic inflammation seems to be the most popular. In this respect, the longer distance of the larynx from the direct source of the damaging material might account for the longer time needed to allow bile reflux to develop its damaging action, at first inflammatory and then neoplastic. In fact, in the gastrectomized patients examined, inflammatory lesions were already present in subgroup 2 (10-20 years after surgery) while precancerous and/or frankly neoplastic lesions were all limited to subgroup 3 (> 20 years after surgery).

In the literature, a higher incidence of Barrett's oesophagus has been reported, in gastrectomized patients⁴ and, recently, an increased expression of EGF receptors (EGFR), by epithelial oesophageal cells, as a response to bile damage, has been observed. It would be interesting to evaluate the presence of a similar process underlying laryngo-pharyngeal lesions with molecular biology studies since the EGF-EGFR system, as already shown in a number of reports, seems to be heavily involved in the processes of laryngeal carcinogenesis²⁷⁻³².

In conclusion, to the best of our knowledge, this is the first study where among the long-term complications of gastric resection, the onset of ENT lesions was found in 70% of the study population with variable signs and symptoms correlated with the time elapsing after surgery. A larger series with a longer follow-up and a more effective and sensitive analysis in detecting the presence and quality of reflux material are necessary to validate these preliminary results and to include bile reflux among risk factors of inflammatory, precancerous and neoplastic laryngeal lesions. Based on the reported results, gastrectomized patients should, in our opinion, undergo periodical endoscopic follow-up of the upper digestive tract. In fact, a careful multidisciplinary (ENT and gastrointestinal) study could contribute to early diagnosis, in the case of associated laryngo-pharyngeal disease.

The systematic use, together with 24-hour pH monitoring, of bile measurement, in all patients with clinical signs and symptoms typical of LPR but unresponsive to the routine medical treatment as well as in gastrectomized patients, could more specifically contribute to define the role of the duodenal content in the onset of laryngo-pharyngeal reflux disease.

References

- 1 Copper MP, Smit CF, Stanojic LD, Devriese PP, Schouwenburg PF, Mathus-Vliegen LM. *High incidence of laryngopharyngeal reflux in patients with head and neck cancer*. *Laryngoscope* 2000;110:1007-11.
- 2 Gabriel CE, Jones DG. *The importance of chronic laryngitis*. *J Laryngol Otol* 1960;74:349-57.
- 3 Galli J, Frenguelli A, Calò L, Agostino S, Cianci R, Cammarota G. *Ruolo del reflusso gastroesofageo nelle precancerosi e nel carcinoma squamocellulare della laringe: nostra esperienza*. *Acta Otorhinolaryngol Ital* 2001;21:350-5.
- 4 Glanz H, Kleisasser O. *Chronic laryngitis and carcinoma*. *Arch Otorhinolaryngol* 1976;212:57-75.
- 5 Cann CI, Fried MP, Rothman KJ. *Epidemiology of squamous cell cancer of the head and neck*. *Otolaryngol Clin North Am* 1985;18:367-88.
- 6 Chen MYM, Ott DJ, Casolo BJ, Moghazy KM, Koufman JA. *Correlation of laryngeal and pharyngeal carcinomas and 24-hour pH monitoring of the esophagus and pharynx*. *Otolaryngol Head Neck Surg* 1998;119:460-2.
- 7 Dennish GW, Castell DO. *Inhibitory effect of smoking on the lower esophageal sphincter*. *N Engl J Med* 1971;284:1136-7.
- 8 Freije JE, Beatty TW, Campbell BH, Woodson BT, Schultz CJ, Toohill RJ. *Carcinoma of the larynx in patient with gastroesophageal reflux*. *Am J Otolaryngol* 1996;17:386-90.
- 9 Galli J, Agostino S, Calò L, Sergi B, Cammarota G, Cianci R. *Malattia da reflusso gastroesofageo e patologia flogistica laringea: valutazione clinica e mediante pHmetria multielettrodo*. *Acta Otorhinolaryngol Ital* 2001;21:306-11.
- 10 Koufman JA. *The otolaryngologic manifestations of gastroesophageal reflux disease (GERD): A clinical investigation of 225 patients using ambulatory 24-hour pH monitoring and an experimental investigation of the role of acid and pepsin in the development of laryngeal injury*. *Laryngoscope* 1991;101:1-78.
- 11 De Rose G, Duff JH. *Bile reflux gastritis and esophagitis*. *Canad J Surg* 1980;23:190-1.
- 12 Fuchs KH, DeMeester TR, Hinder RA, Stein HS, Barlow AP, Gupte NC. *Computerized identification of pathologic duodenogastric reflux using 24-hour gastric pH monitoring*. *Ann Surg* 1991;213:13-20.
- 13 Fuchs KH, Fein M, Maroske J, Heimbucher J, Freys SM. *The role of 24 h gastric pH monitoring in the interpretation of 24 ore gastric bile monitoring of duodenogastric reflux*. *Hepatogastroenter* 1999;46:60-7.
- 14 Collard SM. *Duodenogastric reflux bile reflux. Introduction*. *Hepatogastroenterology* 1999;46:39.
- 15 Vitale GC, Cheadle WG, Patel B. *The effect of alcohol on nocturnal gastroesophageal reflux*. *JAMA* 1987;258:2077-9.
- 16 Miwa K, Segawa M, Takano Y, Matsumoto H, Sahara H, Yagi M, et al. *Induction of oesophageal and forestomach carcinomas in rats by reflux of duodenal contents*. *Br J Cancer* 1994;70:185-9.
- 17 Palmer ED. *Subacute erosive esophagitis associated with achlorhydria*. *N Engl J Med* 1960;262:927-79.
- 18 Pellegrini CA, DeMeester TR, Wernly JA, Johnson LF, Skinner DB. *Alkaline gastroesophageal reflux*. *Am J Surg* 1978;135:117-84.
- 19 Lorusso D, Linsalata M, Pezzolla F, Berloco P, Osella AR, Guerra V, et al. *Duodenogastric reflux and gastric mucosa polyamines in the non-operated stomach and in the gastric remnant after Billroth II gastric resection. A role in gastric carcinogenesis?* *Anticancer Res* 2000;20:2197-201.
- 20 Mason R De Meester TR. *Importance of duodenogastric reflux in the surgical outpatient practice*. *Hepatogastroenterology* 1999;46:48-53.
- 21 Vaezi MF, Richter JE. *Importance of duodenogastric reflux in the medical outpatient practice*. *Hepatogastroenterology* 1999;46:40-7.
- 22 Gasbarrini G, Labriola E, Scondotto G, Addarii F. *Cholecysto-cardiac painful syndrome in patient with cholelithiasis*. *Anatomo-clinical contribution*. *Arch Patol Clin Med* 1967;44:405-21.
- 23 Stanciu C, Bennet JR. *Smoking and gastro-esophageal reflux*. *Br Med J* 1972;3:793-5.
- 24 Imada T, Chen C, Hatori S, Shiozawa M, Rino Y. *Effect of trypsin inhibitor on reflux esophagitis after total gastrectomy in rats*. *Eur J Surg* 1999;165:1045-50.
- 25 Nishimaki T, Watanabe K, Suzuki T, Hatakeyama K, Watanabe H. *Early esophageal adenocarcinoma arising in a short segment of Barrett's mucosa after total gastrectomy*. *Am J Gastroenterol* 1996;91:1856-7.
- 26 Ward PH, Berci G. *Observations on the pathogenesis of chronic non specific pharyngitis and laryngitis*. *Laryngoscope* 1982;92:1377-82.
- 27 Almadori G, Cadoni G, Cattani P, Galli J, Bussu F, Ferrandina G, et al. *Human papillomavirus infection and epidermal growth factor receptor expression in primary laryngeal squamous cell carcinoma*. *Clin Cancer Res* 2001;7:3988-93.
- 28 Almadori G, Cadoni G, Galli J, Ferrandina G, Scambia G, Exarchakos G, et al. *Epidermal growth factor receptor expression in primary laryngeal cancer: an independent prognostic factor of neck node relapse*. *Int J Cancer* 1999;20:188-91.
- 29 Maurizi M, Almadori G, Ferrandina G, Distefano M, Romanini ME, Cadoni G, et al. *Prognostic significance of epidermal growth factor receptor in laryngeal squamous cell carcinoma*. *Br J Cancer* 1996;74:1253-7.
- 30 Maurizi M, Scambia G, Benedetti-Pacini P, Ferrandina G, Almadori G, Paludetti G, et al. *EGF receptor expression in primary laryngeal cancer: correlation with clinico-pathological features and prognostic significance*. *Int J Cancer* 1992;52:862-6.
- 31 Scambia G, Panici PB, Battaglia F, Ferrandina G, Almadori G, Paludetti G, et al. *Receptors for epidermal growth factor and steroid hormones in primary laryngeal tumors*. *Cancer* 1991;67:1347-51.
- 32 Cianci R, Fedeli G, Cammarota G, Galli J, Agostino S, Di Girolamo S, et al. *Is the alkaline reflux a risk factor for laryngeal lesions?* *Am J Gastroenterol* 2000;95:2398.

■ Received: 18 February 2003
 Accepted: 15 March 2003

■ Address for correspondence: Prof. Jacopo Galli, Istituto di Clinica ORL, Università Cattolica del Sacro Cuore di Roma, Largo Agostino Gemelli, 8, 00168 Roma, Italy. Fax: +39 06 3051194. E-mail: iclot@rm.unicatt.it