

# Midfacial fractures: our experience

## *Le fratture medio-facciali: nostra esperienza*

G. PALUDETTI, G. ALMADORI, L. CORINA, C. PARRILLA, M. RIGANTE, F. OTTAVIANI<sup>1</sup>

Department of Otorhinolaryngology, Catholic University "Sacro Cuore", Rome

<sup>1</sup> Institute of Otorhinolaryngology, "Tor Vergata" University, Rome, Italy

### Key words

Midfacial fractures • Classification • Surgical treatment

### Parole chiave

*Fratture medio-facciali • Classificazione • Trattamento chirurgico*

### Summary

Authors report their experience in the treatment of midfacial fractures in 201 patients, 177 of whom underwent surgery for reduction and fixation of the fracture. Since no functional or aesthetic deficits were present, surgery was not performed in the remaining 24 cases. Of the 177 patients, the maxillary complex was involved in 70 (classified as central and centro-lateral fractures), the zygomatic-maxillary-orbital complex in another 70, isolated fractures of the orbital floor blow-out in 18, and isolated fractures of the zygomatic arch in 19. The results obtained and the degree of satisfaction were evaluated in 90 patients with clinical visits, as well as by telephone interview. A total of 88 patients expressed complete satisfaction with the results of the surgical outcome, while the remaining 2 patients were not satisfied with the aesthetic outcome. All patients were operated within 24-48 hours post-trauma in the case of incarceration of extrinsic ocular muscles, and within 10 days in other types of trauma, even in those patients in intensive care. The importance of clinical and radiological pre-operative diagnosis is stressed as well as the choice of the most suitable therapeutic approach for the different types of fractures, considering recent tendencies towards minimally invasive procedures to achieve better cosmetic results. The latest developments in fixation techniques with reference to titanium mini- and/or micro-plates that may eventually be substituted with absorbable materials are discussed.

### Riassunto

*Gli Autori riportano la propria esperienza nel trattamento delle fratture medio-facciali in 201 pazienti di cui 177 hanno effettuato un intervento chirurgico di riduzione e contenzione delle fratture, mentre 24 non stati sottoposti ad intervento data l'assenza di deficit funzionali ed estetici. 70 interessavano il mascellare superiore propriamente detto (classificate come "fratture centrali e centro-laterali"), 70 il complesso zigomatico-orbita-mascellare ("fratture laterali"), 18 erano fratture isolate ("blow out") del pavimento dell'orbita e 19 fratture isolate dell'arco zigomatico. I risultati ottenuti ed il grado di soddisfazione sono stati valutati in 90 pazienti sia con controlli clinici periodici che mediante un questionario telefonico. 88 pazienti riferivano di essere complessivamente soddisfatti del risultato chirurgico, mentre 2 non erano contenti del risultato estetico ottenuto. Gli interventi sono stati effettuati entro le 24-48 ore dal trauma in caso di incarceramento dei muscoli estrinseci dell'occhio, entro la 10a giornata negli altri casi, anche in pazienti ricoverati in rianimazione. Gli Autori sottolineano l'importanza della diagnostica preoperatoria clinico-radiologica e della scelta della via d'approccio più idonea per i diversi tipi di frattura anche alla luce della tendenza alla sempre minore invasività ed al sempre maggior riguardo riservato alla cosmesi. Discutono infine dell'evoluzione dei mezzi di contenzione specificando che la loro preferenza va alle mini e/o microplacche in titanio che potrebbero essere tuttavia progressivamente sostituite da materiale riassorbibile.*

## Introduction

In recent years, many advances have been made in the treatment of midfacial fractures of the maxillary and zygomatic-maxillary-orbital complex both as far as concerns surgical techniques and materials for stabilization and fixation<sup>1-3</sup>. The use of semi-rigid fixation with mini- and micro-plates has greatly improved treatment strategies, due to their easy adaptability and greater stabilization of the fracture site, conditions - necessary for correct recovery of the facial skeletal movements, ensuring that good dental occlusion and correct three-dimensional (3D) facial projection are maintained<sup>4-6 24 31</sup>.

Aim of the present study is to retrospectively analyse the different treatment strategies and recent develop-

ments in the management of midfacial fractures, focusing not only on the functional but also on the aesthetic results obtained.

## Patients and methods

A total of 201 patients with midface fractures, with or without mandibular involvement, have been treated in our clinic and were included in the present retrospective analysis. Considering the localization of fractures and also the anatomical complexity of the midface region, fractures were classified as follows: central, centro-lateral, and lateral (Table I). Instead zygomatic-orbital-maxillary complex fractures are classified according to the classification proposed by

**Table I.** Classification of midfacial fractures.**Central fractures**

- Fracture of the alveolar process
- Transverse fracture with horizontal separation of the nasal floor and maxillary sinus (LeFort type I or Guerin fracture)
- Transverse fracture with separation of the entire maxillary (LeFort type II or Wassmund types I and II)
- Sagittal fracture (median and paramedian)
- Fractures of the nasal skeleton (naso-maxillary and naso-ethmoidal complex)
- Mixed fractures

**Centro-lateral fractures**

- Transverse fractures characterised by complete separation of the facial skeleton and the malar from the skull base (LeFort type II or Wassmund types III and IV)

**Lateral fractures**

- Fractures of the zygomatic-orbital-maxillary complex
- Isolated orbital walls and floor fractures (blow-out)

**Table II.** Classification proposed by Zingg et al. <sup>4</sup>.**Fractures of the zygomatic-orbital-maxillary complex**

- Type A    A1 isolated zygomatic arch  
             A2 isolated orbital lateral wall  
             A3 isolated infraorbital rim
- Type B    complete monofragment fracture ("tetrapod fracture")
- Type C    multifragment zygomatic fracture

**Table III.** Lateral fractures ± involvement of the orbital floor.**Lateral fractures**

<b>Fractures of the zygomatic-maxillary complex</b>	<b>53</b>
• Fixation with mini-plates and/or micro-plates	43
• Fixation with metal sutures	8
• Fixation with mini-plates and metal sutures	2
<b>Fractures of the zygomatic-maxillary complex + fractures of the orbital floor</b>	<b>17</b>
• Caldwell-Luc + mini-plates and/or micro-plates + Lyodura strips	15
• Osteosynthesis with metal sutures + Lyodura strips	2

Zingg et al. <sup>4</sup> (Table II). After thorough clinical examination, including ophthalmological, dental, and neurosurgical evaluation. The surgical strategy was decided upon, however, scrupulous diagnostic imaging (PA skull, Waters', submentovertex, panoramic radiographs, axial and coronal CT scan and, in some cases, 3D CT and Dentscan). In the case of complex, multi-fragmentary or serious fractures, radiological examinations were associated with MR in order to detect eventual orbital and/or encephalic le-

sions. In 177 patients a surgical procedure, involving reduction and fixation, was carried out (Tables III-V), while in 24 cases no surgical treatment was performed. Surgery was always carried out between the 6th and 10th day post-trauma, even if the patient was in intensive care. Only in 17 cases was surgery performed earlier, i.e., within 24-48 hours after trauma, due to incarceration of the ocular extrinsic muscles. In complex fractures involving the superior portion of the face (zygomatic arch, lateral, inferior and me-

**Table IV.** Central and centro-lateral fractures.

<b>Central and centro-lateral fractures</b>	
<b>LeFort type I fractures</b>	<b>11</b>
• Fixation with mini-plates + IM blockage	7
• IM blockage	4
<b>LeFort type II fractures</b>	<b>12</b>
• Fixation with mini-plates	10
• Fronto-maxillary suspension	2
<b>LeFort type III fractures</b>	<b>7</b>
• Fixation with mini-plates	4
• Fixation with metal sutures	2
• Fronto-maxillary suspension	1
<b>Non-LeFort central fractures</b>	<b>40</b>
• Reduction and packing using Caldwell-Luc	21
• Reduction and packing using Caldwell-Luc + IM blockage	4
• Fixation with mini-plates	16

**Table V.** Isolated fractures.

<b>Isolated fractures</b>	
<b>Blow-out fractures of the orbital floor</b>	<b>17</b>
• Reduction and fixation with Lyodura strips (incl. palpebral)	13
• Reduction and packing using Caldwell-Luc	3
• Reduction and fixation with titanium plates (incl. palpebral)	1
<b>Isolated fractures of the zygomatic arch</b>	<b>19</b>
• Endoral reduction with blunt elevator	12
• Reduction with hook (percutaneous)	2
• Reduction by Gillies temporal incision	2
• Reduction with hook + fixation with metal wires	2
• Reduction with hook + fixation with microplates	1
Fractures not surgically treated	24

dial orbital wall, medial front, naso-frontal-ethmoid region) coronal or hemicoronal incision was made (superior degloving), reserving a mono- or bilateral intrabuccal sublabial incision (inferior degloving) in order to expose the lower 1/3 of the midface (inferior maxillary, zygoma-maxillary junction). In exposing isolated fractures, a Gillies temporal incision or intrabuccal vestibular incision was used for fractures of the zygoma arch and subciliary cutaneous incisions for blow-out fractures of the orbital floor. Trans-conjunctival incision was used only in one case with a blow-out fracture.

As far as concerns fixation, mini-plates were used for fractures of the zygomatic-maxillary junction or the piriformis process. Microplates were used for those fractures involving the naso-fronto and the fronto-zygomatic junctions as well as for those involving the

intraorbital rim. During the first few years, mainly titanium wires were used for central, non-LeFort fractures, for infraorbital rim, and fronto-zygomatic junction fractures. However, even if results with titanium wires were good, these were gradually abandoned, since application was not easy. Packing of the maxillary sinus was frequently used for mid-face fractures, in the initial years of our experience, but this too has progressively been abandoned. For fixation of the orbital floor, lyophilised dura mater was used except in 2 cases, in which titanium mesh was employed due to substantial bone loss (Fig. 1). Recently, we have used Lactosorb® resorbable plates, in 2 cases, for fixation of the infra-orbital rim and zygomatic-maxillary junction (Fig. 2a, b). During the immediate post-operative period or, in any case, before discharge, outcome of the surgical treatment was assessed by routine radio-

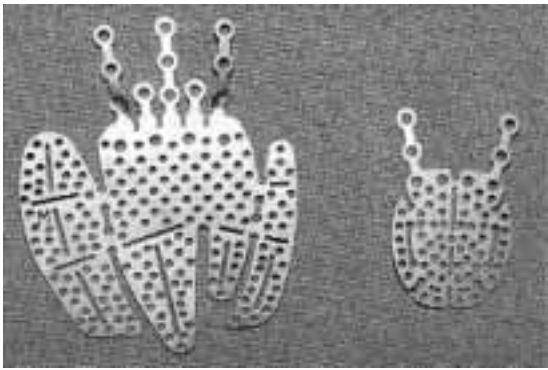


Fig. 1. Titanium mesh for repair of large bone defects of the orbital floor.

logical imaging (cranial X-ray) and, in selected cases, by CT. For long-term evaluation of functional and aesthetic results, a telephone interview was used (Table VI). A total of 65 patients were contacted, while information, in another 25 patients, was obtained from clinical charts referring to follow-up visits carried out, at least, every 4 months. Follow-up results were thus available for 44.7% of patients and were compared to the pre-operative status.

## Results

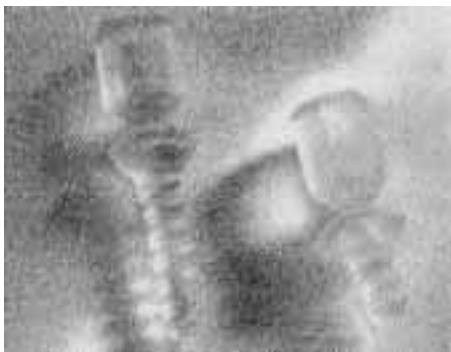Of the 90 patients, for which follow-up data were available, 32 had undergone surgical treatment due to the presence of a centro-lateral fracture (21 central non LeFort fractures, 7 type II LeFort fractures, 4 type III LeFort fractures), 33 for fractures of the zygomatic-orbital-maxillary complex, 14 for blow-out fractures of the orbital floor, and 11 for isolated fractures of the zygomatic arch. Malar depression was present in 20 patients before surgical treatment and in

2 cases after surgery (8%) (Table VII). Facial hypoesthesia and enophthalmos were present in 45 (11%) and in 16 (6%) of cases before surgery, and in 5 and 1 case, respectively, after surgery. Diplopia was present in only 5 cases prior to treatment and was completely resolved in all but one case within a few months. In 4 patients, due to persistent infection, further surgery was necessary to remove the mini-plates. A total of 88 patients were completely satisfied with the results of the surgical treatment, while in 2 cases, even if no severe functional damage was present, the patients were not pleased with the aesthetic results.

## Discussion

The midfacial region comprises the medial portion of the face including the upper maxillary region and the zygoma-orbital-maxillary complex<sup>2,28</sup>. Before surgical treatment, scrupulous physical examinations are necessary, including inspection of the face and oral cavity, facial palpation, and specialist consultations. These are carried out in addition to routine radiographic evaluation, which should include not only cranial and panoramic radiographs, but also cranial and maxillary-facial CT both in the axial and coronal projections<sup>10,11,26</sup>. In the case of complex or serious fractures, encephalic MR and orbital ultrasound should also be performed in order to exclude encephalic lesions and to evaluate the status of the orbital content<sup>12</sup>. The 3D CT scan, however, does not have added value compared to routine techniques, and serves only as an educational tool. When the fracture is evident only at radiography and has no clinical consequences, surgery, in our opinion, should not be carried out<sup>3-5</sup>.

The main aim of surgical treatment for midfacial fractures is to resolve functional deficits, especially those involving orbital structures and to overcome problems in mastication. A secondary goal is to re-



a



b

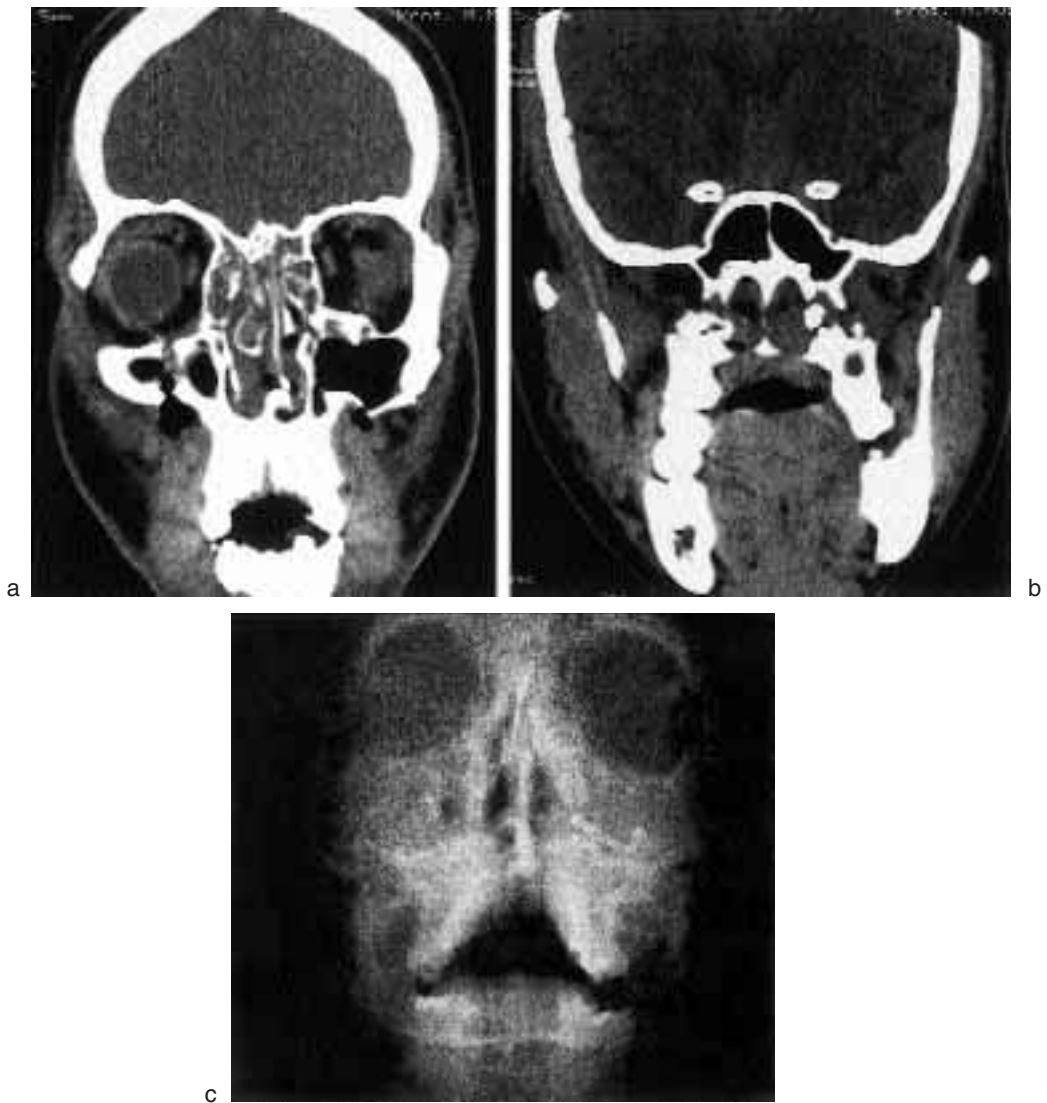
Fig. 2a, b. Resorbable screws and plates (Lactosorb®).

**Table VI.** Telephone questionnaire.

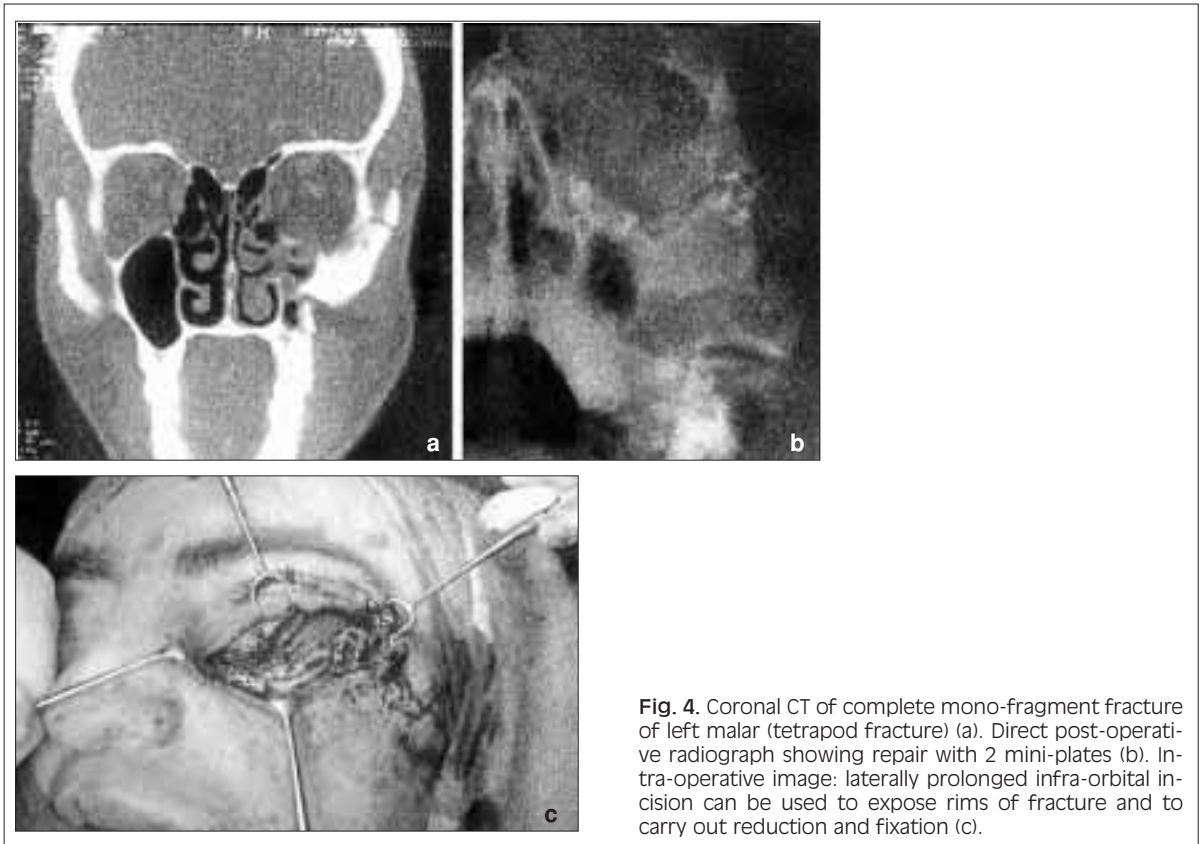
- Do you have visual disturbance?
- Are facial deformities present?
- Do you have difficulty in smelling?
- Do you have facial pain or paresthesias?
- Do you have difficulty in opening or closing your mouth?
- Do you have recurrent episodes of sinusitis?
- Do you have headaches?
- Are you satisfied with the results of your surgery?

**Table VII.** Results.

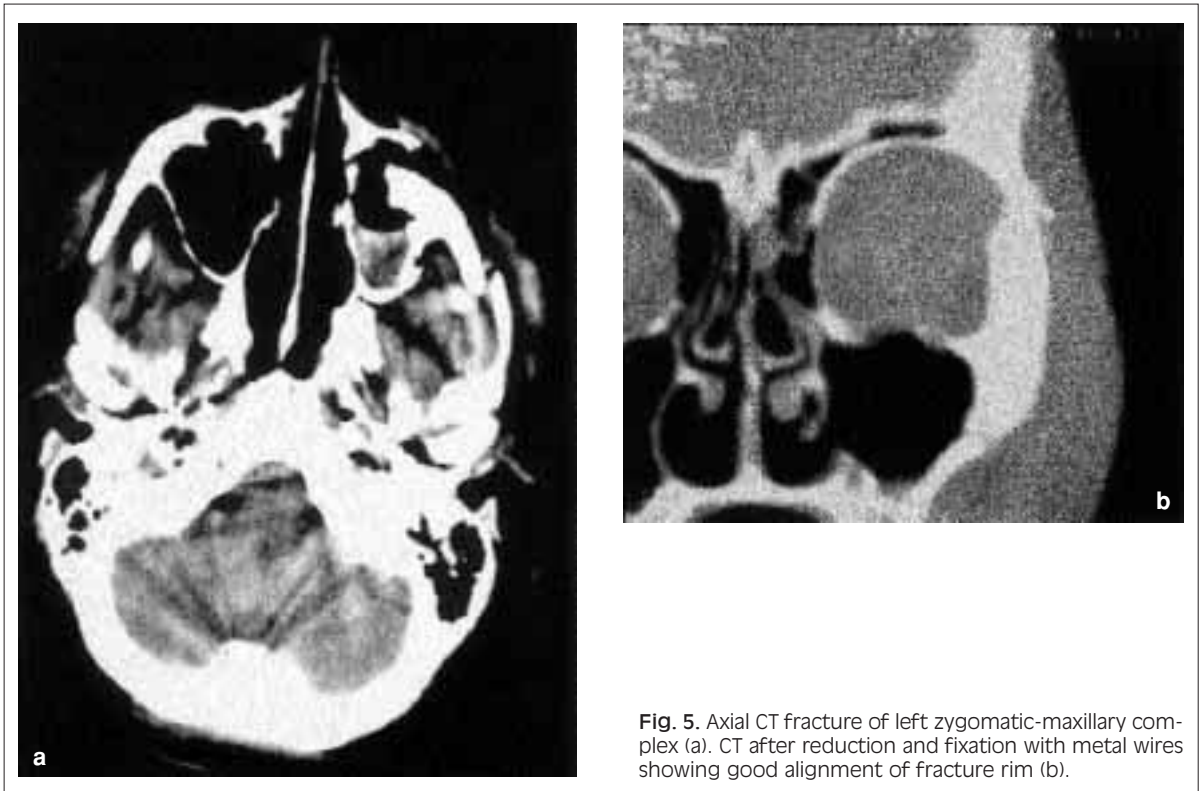	Pre-operative	Post-operative
Malar depression	20	2
Facial hypoesthesia	45	5
Enophthalmus	16	1
Diplopia	5	0
Infections	0	4



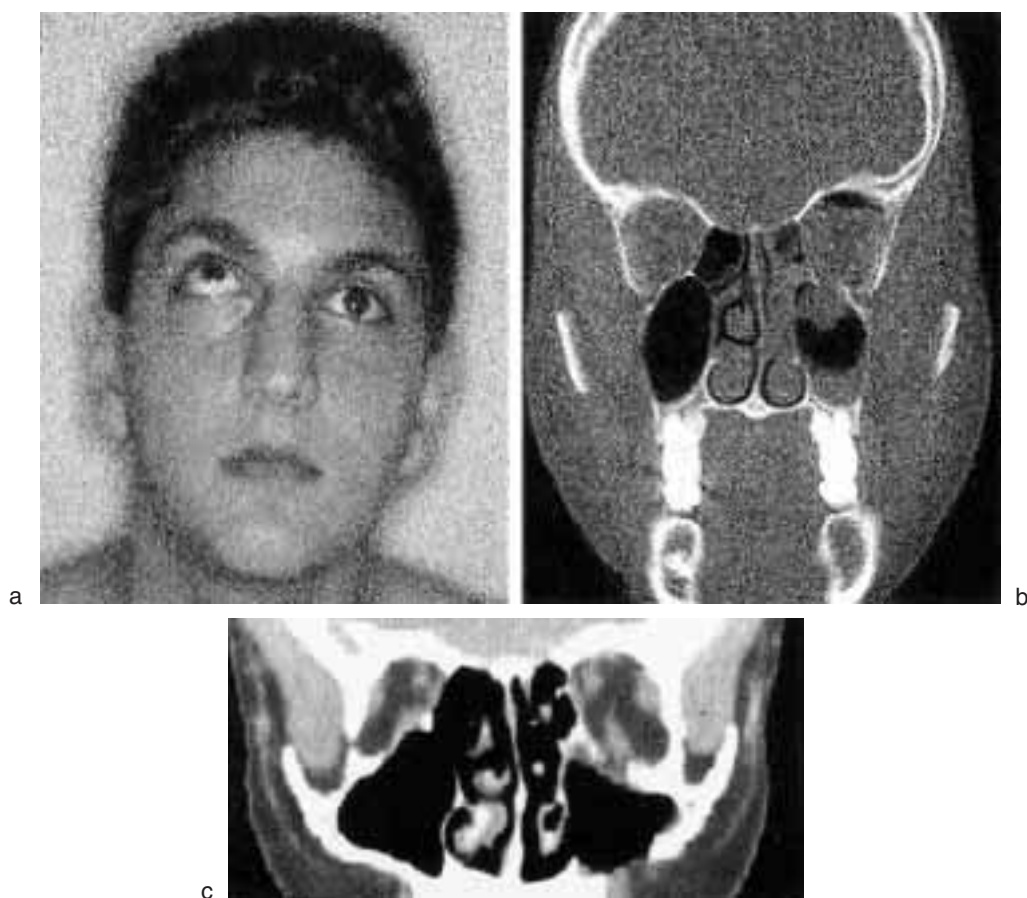
**Fig. 3a, b.** Pre-operative coronal CT of a LeFort type II fracture. Reduction and fixation with 3 mini-plates (c).



**Fig. 4.** Coronal CT of complete mono-fragment fracture of left malar (tetrapod fracture) (a). Direct post-operative radiograph showing repair with 2 mini-plates (b). Intra-operative image: laterally prolonged infra-orbital incision can be used to expose rims of fracture and to carry out reduction and fixation (c).



**Fig. 5.** Axial CT fracture of left zygomatic-maxillary complex (a). CT after reduction and fixation with metal wires showing good alignment of fracture rim (b).

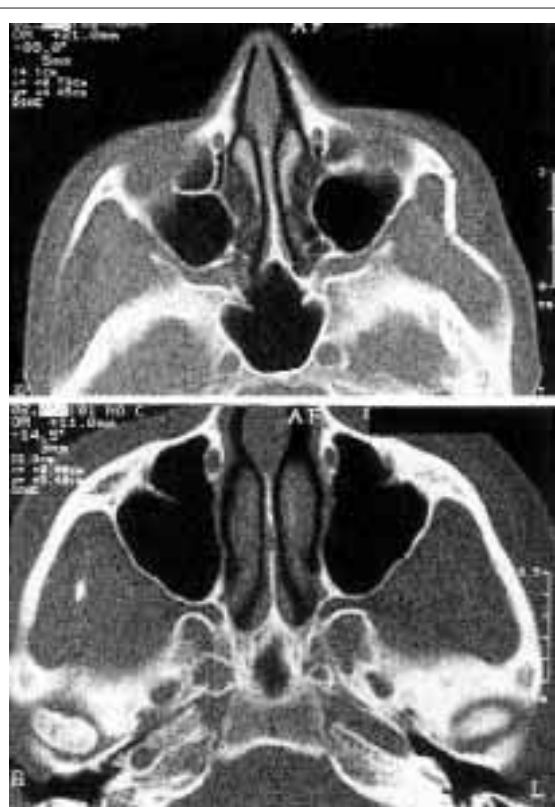


**Fig. 6.** Deficit in elevation of left ocular bulb due to entrapment of inferior rectus muscle (a). Coronal CT reveals isolated fracture of orbital floor (blow-out) with herniation of orbital content into the maxillary sinus (b). CT after fracture reduction, prolapsed orbital tissue elevation and bone defect in the orbital floor covered with silastic sheet (c). Surgery was carried out by cutaneous, infraorbital incision.

store 3D appearance of the face in order to guarantee good dental occlusion by restabilising the integrity of the nasal cavity and the orbit, in addition to zygomatic-malar alignment. In our opinion, this can be achieved until the 10th day post-trauma without any negative consequences on either the performance or success of the surgical intervention. However, in the case of trauma involving incarceration of the extrinsic ocular muscles, surgery, within 24-48 hours post-trauma, is mandatory<sup>2,14</sup>. Furthermore, in agreement with others, treatment of fractures, 20 days post-trauma, requires, in our opinion, osteotomy for both aesthetic and functional purposes<sup>3,15</sup>.

Reduction of the fracture, with correct repositioning of the osseous fragments requires adequate exposure of the fracture rim. Extensive open reduction, often associated with indirect fixation methods, used during the 1970s, have been progressively substituted, whenever

possible, with more limited approaches<sup>3,5,16,17,32</sup>. The introduction of semi-rigid fixation with mini- or microplates however, requires good exposure of the fracture rim. In fact, the use of degloving technique (superior or inferior) is the method of choice allowing easy application of the metal plates<sup>4-6,20-22,33</sup>. Wide subperiosteal exposure, however, can lead to an increase in post-operative complications, including abundant scarring, atrophy of soft tissues, and osseous resorption. For this reason, the incision may be limited, in isolated fractures, to the region close to the rim of the fracture, as, for example, cutaneous incision above the eyebrow for exposure of the zygomatic-frontal junction or cutaneous infra-orbital or trans-conjunctival incision for the orbital floor and/or infraorbital rim<sup>7-9,27,30</sup>. In some types of comminuted incomplete fractures, closed reduction without subsequent fixation has been proposed<sup>5</sup>. After exposure of the rim of the fracture



**Fig. 7.** Axial CT showing an isolated fracture of left zygomatic arch (a). CT after closed reduction with blunt elevator by buccal incision (b).

and before adequate fixation, it is important to carry out correct reduction, in the case of midfacial fractures, should take into consideration the tensile force of the pillars of resistance (medial or naso-maxillary, lateral or zygomatic-maxillary, and posterior or pterygoid-maxillary). In particular, in the zygomatic-orbital-maxillary complex, it is important to focus on correct alignment of the zygomatic-maxillary buttress as well as the junction of the malar and the large sphenoidal wing. This condition is mandatory for correct anterolateral projection of the zygomatic bone, which is often rotated medially due to traction of the masseter muscle<sup>2 5 6 17 18 24</sup>. During the last few years, a variety of systems have been used for fixation, ranging from anthral packing to inter-maxillary blockage, from the use of metal wires to mini- and micro-plates in titanium, to the application of mini-plates in absorbable materials<sup>1 3 15 23 24</sup>. In our series, we used primarily titanium mini- or micro-plates and our experience, over the years, enables us to make several important considerations concerning the surgical strategy to be adopted. In the case of fractures of the zygomatic-orbital-maxillary complex, for correct realignment, it is always

necessary, in our opinion, to fix the zygomatic-maxillary junction and the fronto-zygomatic junction with mini- and/or micro-plates, whereas it is not always necessary to fix the infraorbital rim with microplates, since this frequently realigns after stabilization of the zygomatic-maxillary buttress.

In isolated fractures of the orbital floor and in those involving the infra-orbital rim, we used a transcutaneous subciliary approach, in all patients but one, even if, to-day, a transconjunctival approach would be preferable<sup>9</sup>. Once the herniated and incarcerated orbital contents have been repositioned, we generally prefer to use lyophilised dura mater for containment rather than other materials such as Vycril, PDS strips, or Teflon, not only on account of easy adaptability but also because, in our experience, it does not give rise to post-operative complications. In the event of extensive bone defects, titanium mesh can be fixed to the orbital floor<sup>34</sup>. If the fracture is multifragmentary and comminuted, anthral packing can be used, a method rarely used and nowadays indicated as an extra means of fixation<sup>5 19</sup>. In the case of isolated fractures of the zygomatic arch, controversy exists regarding the best surgical approach to be followed. In our opinion, vestibular buccal incision with closed reduction with blunt elevator is the method of choice since it is equally effective but is less invasive than a Gillies temporal incision that might be indicated in the case of fractures with dislocated fragments<sup>20</sup>.

For fixation of the fronto-zygomatic junction (for which external access is still considered the technique of choice, and in our opinion, preferable to transconjunctival routes), titanium wires might be considered as an alternative to micro-plates, even if more difficult to apply. For isolated fractures of the infra-orbital rim, micro-plates undoubtedly represent the material of choice.

In conclusion, surgical treatment of midfacial fractures is indicated only in the presence of clinical symptoms giving rise both to functional and aesthetic defects; aim of treatment should be to correct eventual functional deficits and restore the three dimensional facial aspects. This usually involves wide exposure with correct reduction of the fracture rim and, almost always, stable fixation, using appropriate materials. However, in selected cases and in isolated fractures, closed techniques of reduction can be sufficient even without the need of fixation methods. On the other hand, the current trend, as in other surgical procedures, is to use less invasive approaches that provide good aesthetic and functional results. Use of titanium mini- and micro-plates, stabilised with titanium screws, are well-suited for surgical application since they are easy to apply and offer optimal reduction and stabilization. Mini-plates in absorbable materials would be more advantageous than mini/micro titanium plates, which are not suitable for use in pae-



diatric patients since they interfere with cranial-facial growth and, furthermore, make both CT and MR. Moreover, these could create problems, in the event of oncologic disease that require radiotherapeutic treat-

ment<sup>1 29</sup>. Last, but not least, absorbable materials reduce the risk both of short- and long-term inflammatory complications following titanium implant rejection requiring removal of these devices<sup>1 25</sup>.

## References

- 1 Suuronen R, Kallela I, Lindqvist C. *Bioresorbable plates and screws: current state of the art in facial fracture repair*. J Cranio-maxillo-facial Trauma 2000;6:19-27.
- 2 Boutault F. *Traumatisme de la face: diagnostic lésionnel, complications précoces*. Rev Praticien 2001;51:1349-59.
- 3 Zachariades N, Mezitis M, Anagnastopoulos D. *Changing trends in the treatment of zygomaticomaxillary complex fractures: a 12-year evaluation of methods used*. J Oral Maxillofac Surg 1998;56:1152-6.
- 4 Zingg M, Laedrach K, Chen J, Chowdhury K, Vuillemin T, Sutter F, et al. *Classification and treatment of zygomatic fractures: a review of 1025 cases*. J Oral Maxillofac Surg 1992;50:778-90.
- 5 Ellis E, Kittidurmkerng W. *Analysis of treatment for isolated zygomaticomaxillary complex fractures*. J Oral Maxillofac Surg 1996;54:386-400.
- 6 Marciani RD, Gonty Arthur A. *Principles of management of complex craniofacial trauma*. J Oral Maxillofac Surg 1993;51:535-42.
- 7 Vriens JPM, van der Glas HW, Moos KF, Koole R. *Infraorbital nerve function following treatment of orbitozygomatic complex fractures: a multitest approach*. Int J Oral Maxillofac Surg 1998;27:27-32.
- 8 Munoz Guerra MF, Sastre Perez J, Rodriguez-Campo FJ, Naval Gias L. *Reconstruction of orbital fractures with dehydrated human dura mater*. J Oral Maxillofac Surg 2000;58:1361-6.
- 9 Manganello-Souza LC, Rodrigues de Freitas R. *Transconjunctival approach to zygomatic and orbital floor fractures*. Int J Oral Maxillofac Surg 1997;26:31-4.
- 10 McCann PJ, Brocklebank LM, Ayoub AF. *Assessment of zygomatic-orbital complex fractures using ultrasonography*. Br J Oral Maxillofac Surg 2000;38:525-9.
- 11 Clark KC, Swallow RA, Naylor E, editors. *Clark's positioning in radiology*. 11<sup>th</sup> edn. London: Heinemann Medical Books; 1986. p. 233.
- 12 Gentry LR, Manor WF, Turski PA, Strother CM. *High resolution CT analysis of facial struts in trauma. Osseous and soft tissue complications*. AJR 1983;140:533-41.
- 13 Iinuma T, Hirota Y, Ishio K. *Orbital wall fractures: conventional views and CT*. Rhinology 1994;32:81-3.
- 14 Hong-Ryul J, See-ok S, Moo-jin Choo, Young-seok Choi. *Endonasal endoscopic reduction of blowout fractures of the medial orbital wall*. J Oral Maxillofac Surg 2000;58:847-51.
- 15 Mustarde JC. *Repair and reconstruction in the orbital region*. 3<sup>rd</sup> edn. Edinburgh: Churchill Livingstone; 1991. p. 361-75.
- 16 Rinehart GC, Marsh JL, Hemmer KM, Bresina S. *Internal fixation of malar fractures: an experimental biophysical study*. Plast Reconstr Surg 1989;84:21-5.
- 17 Davidson J, Nickerson D, Nickerson B. *Zygomatic fractures: comparison of methods of internal fixation*. Plast Reconstr Surg 1990;85:25-32.
- 18 Dingman RO, Natvig P. *The zygoma, in surgery of facial fractures*. New York: Saunders; 1964. p. 219.
- 19 Tarabichi M. *Transsinus reduction and one-point fixation of malar fractures*. Arch Otolaryngol Head Neck Surg 1994;120:620-5.
- 20 Courtney DJ. *Upper buccal sulcus approach to management of fractures of the zygomatic complex: a retrospective study of 50 cases*. Br J Oral Maxillofac Surg 1999;37:464-6.
- 21 Gillies HD, Klinner TP, Stone D. *Fractures of the malar-zygomatic compound: with a description of a new X-ray position*. Br J Surg 1927;14:651-6.
- 22 McLoughlin P, Gilhooly M, Wood G. *The management of zygomatic complex fractures - results of a survey*. Br J Oral Maxillofac Surg 1994;32:284-8.
- 23 Marciani RD. *Management of midface fractures: Fifty years later*. J Oral Maxillofac Surg 1993;51:960-8.
- 24 Stewart MG, Douglas Appling W. *Zygomatic fractures*. In: Gates G, editor. *Current therapy in Otolaryngology-Head and Neck Surgery*. 6th edn. St. Louis: Mosby 1998.
- 25 Enislidis G, Pichorner S, Kainberger F, Ewers R. *Lactosorb panel and screws for repair of large orbital floor defects*. J Cranio-maxillofac Surg 1997;25:316-21.
- 26 Tanrikulu R, Erol B. *Comparison of computed tomography with conventional radiography for midfacial fractures*. Dentomaxillofacial Radiol 2001;30:141-6.
- 27 Folkestad L, Westin T. *Long-term sequelae after surgery for orbital floor fractures*. Otolaryngol Head Neck Surg 1999;120:914-21.
- 28 Donat TL, Endress C, Mathog R. *Facial fracture classification according to skeletal support mechanism*. Arch Otolaryngol Head Neck Surg 1998;124:1306-14.
- 29 Scher N, Poe D, Kuchin F, Reft C, Weichselbaum R, Panje WR. *Radiotherapy of the resected mandible following stainless steel plate fixation*. Laryngoscope 1988;98:561-3.
- 30 Eppley BL, Prevel CD. *Nonmetallic fixation in traumatic midfacial fractures*. J Craniofac Surg 1997;8:103-9.
- 31 Ray AM, Frodel JL. *Midface fracture*. In: Gates G, editors. *Current therapy in Otolaryngology-Head and Neck Surgery*. 6th edn. St. Louis: Mosby 1998.
- 32 Holmes SB, Hardee PS, Mani RR. *Percutaneous osteosynthesis of the zygomatic buttress*. Br J Oral Maxillofac Surg 2001;39:286-8.
- 33 Baumann A, Ewers R. *Midfacial degloving: an alternative approach for traumatic corrections in the midface*. Int J Oral Maxillofac Surg 2001;30:272-7.
- 34 Park HS, Kim YK, Yoon CH. *Various applications of titanium mesh screen implant to orbital wallfractures*. J Craniofac Surg 2001;12:555-60.

■ Received February 19, 2002.  
Accepted November 12, 2002.

■ Address for correspondence: prof. G. Paludetti, Istituto di Clinica Otorinolaringoiatrica, Università Cattolica del Sacro Cuore, Largo A. Gemelli 8, 00168 Roma, Italy. Fax: +39 06 3051194. E-mail: iclot@rm.unicatt.it