

Concomitant primary hyperparathyroidism, Graves' disease and vitamin D deficiency

Coesistenza di iperparatiroidismo primitivo, morbo di Basedow e deficit di vitamina D

C. MIANI, A.M. BERGAMIN BRACALE¹, V. BRESADOLA², E. MOTZ³

Department of Surgical Sciences, Otolaryngology Section, University of Udine;

¹ Department of Otolaryngology, Civil Hospital of Udine;

² Department of Surgical Sciences, Surgery Section, University of Udine;

³ Department of Pathology, Clinical and Experimental Medicine, University of Udine, Italy

Key words

Parathyroid hormone • Primary hyperparathyroidism • Graves' disease • Thyroidectomy • Parathyroidectomy • Vitamin D deficiency

Parole chiave

Paratormone • Iperparatiroidismo primitivo • Morbo di Basedow • Tiroidectomia • Paratiroidectomia • Deficit di Vitamina D

Summary

The simultaneous occurrence of hyperthyroidism and primary hyperparathyroidism is quite rare. A case is reported here of Graves' disease and primary hyperparathyroidism. Treatment of these concomitant diseases consists in combined thyroidectomy and parathyroidectomy. Histological examination confirmed Graves' disease and revealed the presence of a parathyroid adenoma in one gland and parathyroid hyperplasia in another one. After surgical treatment, secondary hyperparathyroidism due to 25-OH Vitamin D deficiency appeared. To our knowledge, this is the first case in which a Vitamin D absorption deficit was found in presence of hyperthyroidism and hyperparathyroidism without other intestinal absorption deficits. Diagnostic and follow-up difficulties related to these three concomitant pathological conditions are discussed.

Riassunto

Il rilievo contemporaneo di iperparatiroidismo primitivo e ipertiroidismo è piuttosto raro. Riportiamo un caso clinico di Morbo di Basedow e iperparatiroidismo primitivo. Queste patologie concomitanti sono trattate con tiroidectomia e paratiroidectomia in un unico tempo. L'esame istologico ha confermato il quadro di Morbo di Basedow e ha mostrato la presenza di un adenoma paratiroidico in una ghiandola e di un'iperplasia paratiroidica in un'altra ghiandola. In seguito al trattamento chirurgico si è manifestato un iperparatiroidismo secondario dovuto ad una carenza di 25-OH vitamina D. Per quanto noto, questo è il primo caso in cui il deficit d'assorbimento di vitamina D è stato riscontrato in presenza d'ipertiroidismo e iperparatiroidismo senza altri deficit intestinali d'assorbimento. Sono discusse le difficoltà diagnostiche e di follow-up correlate a queste tre patologie concomitanti.

Introduction

The simultaneous occurrence of thyroid disease and hyperparathyroidism should always be taken into consideration when planning surgery for either disease. Particular diagnostic skills are required in the case of hyperthyroidism. Although the coexistence of primary hyperparathyroidism complicating thyroid disease is rare, especially in the absence of previous neck irradiation, this association has been described in the literature in about 0.3% of cases while the prevalence in individuals without thyroid disease is less than 1%¹. Indeed, the condition of thyrotoxicosis/bone hypermetabolism associated with Graves' disease can lead to an increase in serum calcium levels despite normal parathyroid function in as many as 22% of the patients. Due to this possibility, a primary hyperparathyroidism arising in a thyrotoxic patient may be missed^{2,3}. Treatment of these

two conditions consists in combined thyroidectomy and parathyroidectomy⁴. In addition to the "hungry bone" phenomenon, the possible presence of Vitamin D deficiency involving the onset of a compensatory secondary hyperparathyroidism may complicate the post-surgical follow-up of parathyroid hormone (PTH), calcium and phosphorus values; while other conditions such as recurrent disease, renal failure, osteomalacia and malabsorption may account for an increased PTH secretion in the post-operative period.

The case of a patient, presenting for surgical treatment, with thyrotoxicosis and asymptomatic hypercalcaemia is described. After combined surgical treatment, namely parathyroidectomy and near-total thyroidectomy, secondary hyperparathyroidism due to 25-OH Vitamin D deficiency occurred. Diagnostic and follow-up difficulties related to these three intersecting pathological processes are discussed.

Case report

A 59-year-old female with a diagnosis of Graves' disease and hyperparathyroidism was referred to our Department in November 1999 for surgical planning. Some months earlier, in January 1999, she had been admitted to the Emergency Medical Department from which, she had been discharged two weeks later, with a diagnosis of acute myocardial discrepancy ischaemia, thyrotoxicosis related to Graves' disease, hypercalcaemia possibly related to hyperparathyroidism. Her past medical and family histories were unremarkable, particularly as far as concerns any clinical endocrine or cardiac disorders.

Laboratory studies, carried out during hospitalisation whilst under antithyroid and diuretic treatment, showed marked variations in thyroid-stimulating hormone (TSH), free triiodothyronine (fT3), free thyroxine (fT4), calcium and phosphorus values (Fig. 1). Other pertinent laboratory results were as follows: osteocalcin, 28.4 ng/ml (range 3.5 to 15.0 ng/ml); intact parathormone (PTH), 360 pg/ml (range 15 to 65 pg/ml); anti-thyroid-stimulating hormone receptor antibodies, 27 U/l (normal <10 U/l); anti-thyroglobulin antibodies, >5000 U/ml (range 0 to 300 U/ml); anti-peroxidase antibodies, 40 U/ml (range 0 to 25 U/ml).

Ultrasonographic (US) examination of the neck revealed a dyshomogeneously hypoechoic, hypervascularised thyroid, increased in volume. Moreover,

the presence of a homogeneous and hypo-echoic solid oval mass of 2.5x1x0.8 cm below the inferior pole of the right thyroid lobe, with the appearance of a parathyroid adenoma, was reported. A parathyroid scintiscan revealed the presence of three areas of radioisotope accumulation in correspondence to the superior third of the left thyroid lobe, between the middle and superior third of the right lobe, and just below the inferior pole of the right thyroid lobe, described as suspected hyperplastic or adenomatous parathyroid tissue. Computed tomography (CT) of the neck, with contrast medium, showed an enlarged and heterogeneous thyroid gland due to the presence of multiple hypodense areas in each lobe. A solid roundish mass about 1 cm in maximum transverse diameter was present just below the right inferior pole of the thyroid gland, with the appearance of an enlarged parathyroid gland; the other two areas detected on the scintiscan were not visible in the CT scan. When the patient arrived at our Department, pertinent laboratory values were as follows: total serum calcium, 11.3 mg/dl (range, 8.1 to 10.4 mg/dl); phosphorus, 2.2 mg/dl (range, 2.7 to 4.35 mg/dl); TSH, 0.016 U/ml (range, 0.3 to 5 U/ml); PTH, 147 pg/ml (range, 15 to 65 pg/ml).

At the end of January, the patient was submitted to surgery with combined near-total thyroidectomy and bilateral inferior parathyroidectomy. An inferior parathyroid approximately 3 cm in maximum vertical diameter, reaching and exceeding the mediastinum

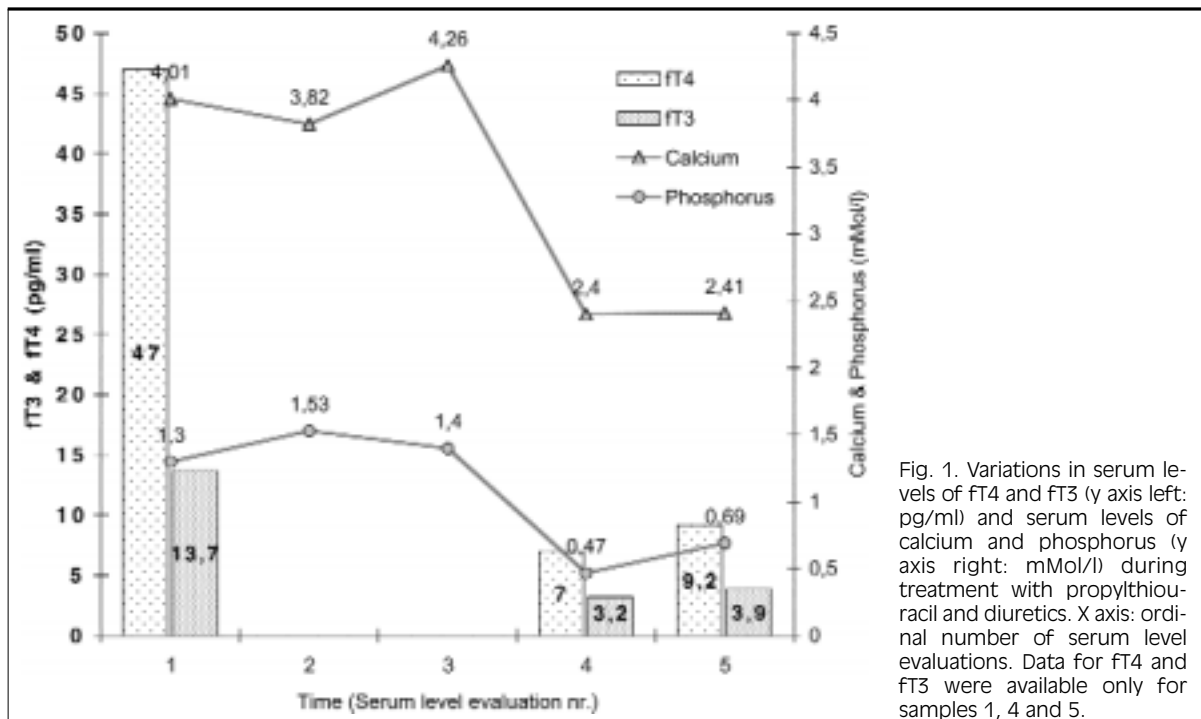


Fig. 1. Variations in serum levels of fT4 and fT3 (y axis left: pg/ml) and serum levels of calcium and phosphorus (y axis right: mMol/l) during treatment with propylthiouracil and diuretics. X axis: ordinal number of serum level evaluations. Data for fT4 and fT3 were available only for samples 1, 4 and 5.

entrance was found and removed on the right side, near the recurrent laryngeal nerve (Fig. 2a). A left inferior parathyroid, slightly increased in volume (about 1 cm in maximum diameter), was also removed (Fig. 2b). The two remaining parathyroid glands were of normal size (0.2-0.3 cm in diameter). Histological examination of the surgical specimen revealed: lymphocytic infiltration of the thyroid tissue, presence of a right inferior parathyroid adenoma and of a left inferior parathyroid hyperplasia.

Fifteen days after surgery, laboratory studies showed: normal serum calcium and phosphorus levels; PTH, 89.2 pg/ml (range, 15 to 65 pg/ml). Forty-five days after surgery, laboratory studies showed: normal serum calcium levels; phosphorus 2.40 mg/dl (range, 2.7 to 4.35 mg/dl); PTH, 129 pg/ml (range, 15 to 65 pg/ml); 25 hydroxy-Vitamin D, 12.80 ng/ml (range, 16 to 74 ng/ml); normal 1,25-dihydroxy Vitamin D value. The 24-hour urinary levels were: phosphaturia

1.23 g (range, 0.3 to 1g); hydroxyprolinuria <1 mg/l (range, 9 to 24 mg/l); creatininuria, calciuria and magnesuria were within the normal range.

US control of the neck showed no enlarged parathyroid. A parathyroid scintiscan of the residual glands showed the presence of two areas of radioisotope accumulation in correspondence to the inferior third of the right thyroid compartment and to the superior third of the left thyroid loggia, described as suspected hyperplastic or adenomatous parathyroid tissue.

Since biohumoral values suggested the possibility of a secondary hyperparathyroidism due to Vitamin D deficiency, the patient was treated with calcitriol 0.50 µg twice daily. Ten days after beginning treatment, PTH levels were normal and ten times lower than prior to treatment (12.4 pg/ml). The substitution therapy was reduced to calcitriol 0.50 µg daily. Laboratory tests performed again in December 2000 showed: normal PTH level (24.5 pg/ml); normal serum calcium and phosphorus levels. One year later, upon withdrawal of 1,25-dihydroxy Vitamin D supplementation, serum 25 hydroxy-Vitamin D levels were significantly lower than normal with PTH, serum and urine calcium and phosphorus within normal limits. In the search for causes of Vitamin D malabsorption, anti-endomysial antibodies were found to be negative, and, therefore, therapy with calcitriol 0.50 µg daily was recommenced.

Discussion

Diagnosis, treatment and follow-up of concomitant thyroid and parathyroid disease may represent a considerable challenge. Hyperthyroidism is frequently associated with an asymptomatic increase in total serum calcium levels due to increased osteoclastic bone turnover. This condition, namely hypercalcaemia with normal phosphoraemia, may mask the presence of an associated primary hyperparathyroidism at least until drug treatment of thyrotoxicosis reduces thyroid synthesis of fT3 to normal values². At this moment, reduced osteoclastic activity which implies reduction in calcium levels, stimulates parathyroid adenoma tissue, which is regulated at higher than normal calcium set point, to increase its activity. This will result in easier detection of high PTH levels that is suggested by the observation of low levels of phosphorus with a normal level of calcium (Fig. 1). Parathyroid scan is useful for the detection of single adenomas but may induce confusion in other cases like the one described here. In these cases, other imaging techniques, such as US and CT scan, are required to plan surgical treatment.

Albeit, from the surgeon's point of view, no problems arise on the side of the neck to be approached, since the simultaneous presence of thyroid disease implies

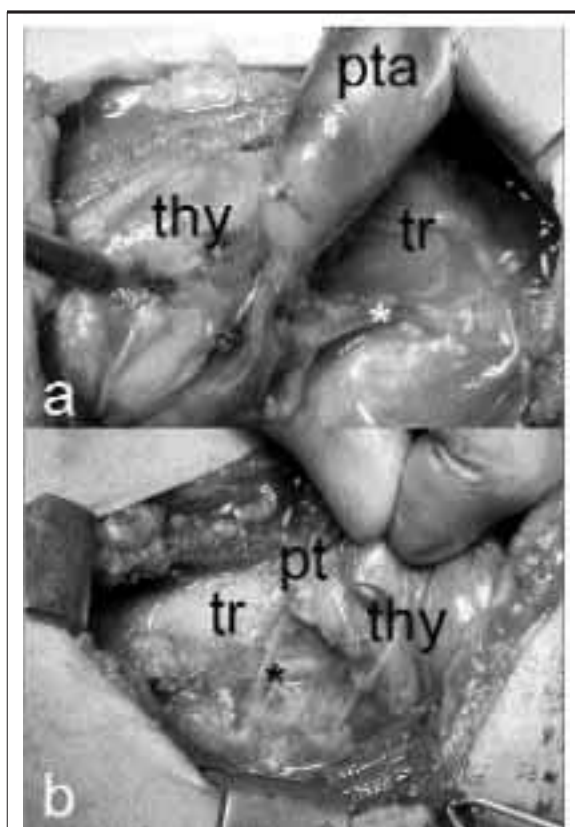


Fig. 2. a. Right inferior parathyroid adenoma (pta) 3x2 cm. b. Left inferior hypertrophic parathyroid (pt) 1x0.5 cm. thy: thyroid gland; tr: trachea; white asterisk: right inferior laryngeal nerve emerging from tracheo-oesophageal space and crossing laterally a branch of inferior thyroid artery supplying the pta; black asterisk: left inferior laryngeal nerve crossing medially a branch of inferior thyroid artery supplying the pt.

a bilateral approach. Indeed, surgical treatment consists of combined near-total thyroidectomy and parathyroidectomy⁴. This enables the risks for the recurrent laryngeal nerve to be reduced to minimum and to respect the normal residual parathyroid glands that must be left in situ. Surgery offers both definitive treatment as well as the opportunity for the pathologic diagnosis to be established.

After surgical treatment, serum calcium, phosphorus and PTH levels must be monitored, particularly when pathologic diagnosis includes the detection of any hyperplastic parathyroid and not only an isolated parathyroid adenoma. In the latter case, the finding of normal serum PTH and calcium levels, during the first month after surgery, indicates that surgical treatment is successful⁵.

Vice versa, when elevated serum PTH levels are found with normocalcaemia and normal or hypophosphoraemia, other laboratory investigations are needed. The main causes of hyperparathyroidism, after surgical treatment, are: a) residual disease, b) renal failure insufficiency and c) Vitamin D deficiency⁵, when the first is excluded, it is necessary to determine 25-OH Vitamin D levels and to evaluate renal function. In the case described here, creatinuria was normal while 25-OH Vitamin D was lower than normal indicating the presence of Vitamin D deficiency. In this case, substitution therapy with calcitriol is needed and long-term surveillance is advisable. Our patient had a dual problem: on the one hand, thyrotoxicosis had masked the presence of hypercal-

caemia and, on the other, Vitamin D deficiency had prevented PTH levels from returning to normal. It remains to be established whether secondary hyperparathyroidism due to Vitamin D deficiency had favoured the development of a primitive autonomous parathyroid adenoma from a hyperplastic parathyroid gland.

Only a few other cases of Vitamin D deficiency concomitant with primary hyperparathyroidism, have been described⁶. To our knowledge, this is the first case in which Vitamin D absorption deficit was found in the presence of hyperthyroidism and hyperparathyroidism without other intestinal absorption deficits.

In conclusion, the simultaneous occurrence of hyperthyroidism and hyperparathyroidism should always be suspected in the presence of hypercalcaemia. The protocol for the clinical classification of goitre should include laboratory studies for calcaemia, phosphoraemia and, if these are not within the normal range, then also for PTH, possibly during anti-thyroid therapy, if needed. In the presence of high PTH levels, a parathyroid scintiscan should be performed. Surgical treatment of these associated diseases should consist in combined thyroidectomy and parathyroidectomy to reduce to a minimum risks for the inferior laryngeal nerve and for the normal residual parathyroid glands. If high levels of PTH persist after adequate surgical treatment, then Vitamin D deficiency should be taken into consideration, to be treated with medical therapy.

References

- Wagner B, Begic Karup S, Raber W, Schneider B, Waldhausl W, Vierhapper H. *Prevalence of primary hyperparathyroidism in 13387 patients with thyroid diseases, newly diagnosed by screening of serum calcium*. *Exp Clin Endocrinol Diabetes* 1999;107:457-61.
- Arem R, Lim-Abraham MA, Mallette LE. *Concomitant Grave's disease and primary hyperparathyroidism. Influence of hyperthyroidism on serum calcium and parathyroid hormone*. *Am J Med* 1986;80:693-8.
- McGowan DM, Vaswani A, Shperling I. *Coexisting hyperparathyroidism with thyrotoxicosis*. *J Endocrinol Invest* 1991;14:305-10.
- Toursarkissian B, Sloan DA, Schwartz RW. *Coexisting hyperthyroidism and primary hyperparathyroidism*. *Surgery* 1993;113:716-8.
- Denizot A, Pucini M, Chagnaud C, Botti G, Henry JF. *Normocalcemia with elevated parathyroid hormone levels after surgical treatment of primary hyperparathyroidism*. *Am J Surg* 2001;182:15-9.
- Gannage MH, Abikaram G, Nasr F, Awada H. *Osteomalacia secondary to celiac disease, primary hyperparathyroidism, and Graves' disease*. *Am J Med Sci* 1998;315:136-9.

■ Received February 2, 2003.

■ Accepted March 20, 2003.

■ Address for correspondence: Dr. C. Miani, Dipartimento di Scienze Chirurgiche, Clinica Otorinolaringoiatrica, Università di Udine, Piazza S.M. della Misericordia, 33100 Udine, Italy. Fax: +39 043 2559337. E-mail: cmiani@uniud.it